

implants

international magazine of oral implantology

4²⁰¹²



| **research**

Cost effectiveness in implant dentistry

| **case report**

Implant-prosthetic rehabilitation of the severely atrophic maxilla

| **industry report**

The early abutment technique

0277113

CONFIDENCE IN LIMITED SPACE

STRAUMANN® NARROW NECK CrossFit®

The Straumann Soft Tissue Level solution to address space limitations

- Confidence when placing small diameter implants
- Wide range of treatment options
- Simplicity in daily use



reddot design award
winner 2012



More information on www.straumann.com

COMMITTED TO
SIMPLY DOING MORE
FOR DENTAL PROFESSIONALS

Dear Colleagues,



Dr Rainer Valentin

With the successful 42nd DGZI annual congress already lying in the past, we can surely say that we were offered an ambitious programme and renowned national and international speakers, as well as a nearly perfect organisation by Oemus Media AG. Titled "Quality-oriented implantation—ways to long-term success", the congress impressively demonstrated the scope of modern dentistry in general and implantology in particular, but it also and more importantly showed their limits.

Resulting from the constant increase in implants placed, implantology has grown from a budding specialty to the driving force of dentistry. Of course, the number of complications and failures was bound to increase along with the growing practical relevance of implantology. Avoiding biological, technical and aesthetic complications while ensuring long-term success have become the primary aim in implantology. Therefore, self-reflection and the reflection of individual therapy approaches have become more important.

Whether you do this by visiting congresses, in discussions with colleagues, by participating in study groups or via education and special training in curricula is entirely your choice. Since, however, more and more beginners have decided for our curricula in the past, we decided to re-design them. Because of the variations with regard to their personal experience in oral implantology, participants can now place their educational focus individually by combining five compulsory and three freely selectable modules.

With this in mind, I wish you the best of luck and pleasant work. Enjoy reading this year's final issue of implants!

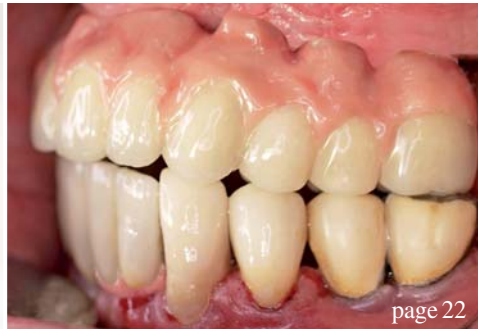Yours,



Dr Rainer Valentin



page 12



page 22



page 28

| editorial

03 Dear **Colleagues**
| Dr Rainer Valentin

| research

06 **Implant design** and the maintenance of **peri-implant tissue**
| Prof Sergio Alexandre Gehrke

12 **Cost effectiveness** in **implant** dentistry
| Dr Mauro Labanca

| overview

18 **Perio** meets **implant** dentistry
| Prof Dr Rainer Buchmann

| case report

22 **Implant-prosthetic rehabilitation** of the **severely atrophic** maxilla
| Prof Dr Gregory-George Zafropoulos *et al.*

28 **CAD/CAM patient-specific abutments** and a **new implant design**
| Prof Dr Frank Liebaug *et al.*

| industry report

34 The **early abutment** technique
| Dr S. Marcus Beschmidt

| news

38 **Manufacturer** News

48 **News**

| education

40 42nd international **annual congress: DGZI stays on target**
| Dr Georg Bach

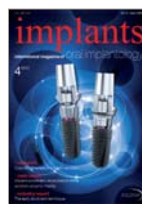44 Practical Training at **Osteology in Monaco**

| events

46 On the trail of **implant innovation** at **IDS 2013**

| about the publisher

50 | imprint




Cover image courtesy of CAMLOG Biotechnologies, www.camlog.de
Original Background: ©Mike McDonald
Artwork by Sarah Fuhrmann, OEMUS MEDIA AG.



page 40



page 44



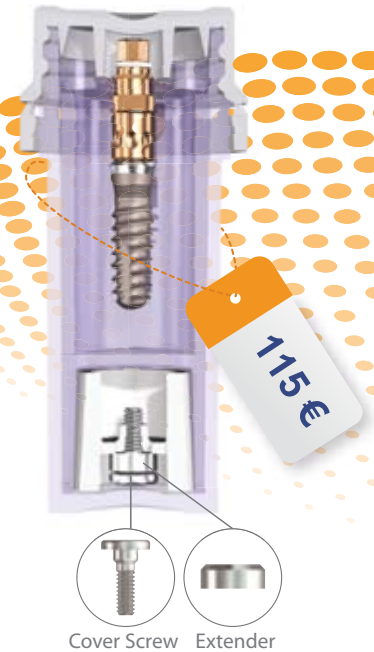
page 46

SwishPlus™

Compatible with Straumann®



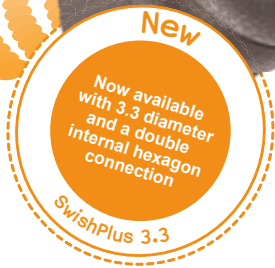All-in-One Packaging



Cover Screw Extender

SwishPlus™

Straight with Micro-Grooves & Straumann Threads



SwishPlus™ Implant

All in One Packaging includes implant, compatible carrier, cover screw & healing collar for only 115 Euro

Swish™ Implant System Advantages:

Internal Octagon (Niznick US Pat. #4,960,381 Licensed to Straumann)

Prosthetic compatibility with Straumann's Tissue-Level implants (Standard, Standard Plus and Tapered Effect)

Internal square broached in flats of octagon for fixture-mount engagement (Pat. Pend.)

SwishPlus™ : €115 includes cover screw, healing collar & carrier compatible with Straumann tool & standard ratchet

- 1 2mm neck half textured for tissue-level or esthetic placement
- 2 Micro-grooves for improved tissue attachment & reduced stress
- 3 Progressively-deeper single-lead threads for increased surface area & complete surgical compatibility
- 4 Self-tapping groove for increased initial stability
- 5 Tapered apical end to initiate self-tapping



All trademarks are property of their respective companies.
 †System Variation: 3.3mmD & 5.7mmD SwishPlus™ are tapered; 3.3mmD also has SwishPlant™ threads.

Implant design and the maintenance of peri-implant tissue

Author_Prof Sergio Alexandre Gehrke, Brazil




Fig. 1

Introduction

The number of patients whose teeth are replaced with implants in aesthetic areas has increased greatly. Proportionately, so have the requirements regarding the outcome of treatment. Unlike the early years of implant osseointegration, many are placed in the anterior maxilla and other aesthetically visible regions. Consequently, several studies have been published about implant treatment and its results in aesthetic regions (Belsler et al. 2003).

Peri-implant bone loss causes retraction of soft tissue and makes aesthetic reconstruction a rather complicated task. Several factors are cited as possible causes of peri-implant bone loss, such as inter-implant dis-

tance (Novaes et al. 2006), periodontal disease (Kozlovsky et al. 2007), occlusal overload (Mangano et al. 2010), a gap in the implant-abutment interface (King et al. 2002), the quality of peri-implant soft tissue (Kim et al. 2009), the relation between crown and implant (Blanes et al. 2007), and the location of the implant-abutment junction (IAJ; Hermann et al. 1997). The integrity of the bone-implant interface results from local microbiological control (Mangano et al. 2010) and a continuous process of bone remodelling replacing fatigued bone.

The IAJ can be located in various positions with respect to the alveolar bone crest (supra-crestal, crestal or sub-crestal; Fig. 1). This location is of great importance for aesthetic restoration. Positioning the IAJ in the most apical position can create an emergence profile best suited for prosthetic reconstruction (Buser & Von Arx 2000).

The Morse taper connection implant has been extensively studied for its benefits with respect to peri-implant tissue biology (Weigl 2004). Among the main benefits are decreased bacterial colonisation in the implant-abutment interface and the reduction of micro-movement of placed implants. These factors are

Fig. 1_Position of the implant in relation to the alveolar bone crest (supra-crestal, crestal or sub-crestal).

Fig. 2_Initial radiographic (a) and clinical (b) findings.

Figs. 3a-c_Image after the alveolar extraction (a), an illustration of an ideal position (b), and the prepared site from a more palatal direction (c).

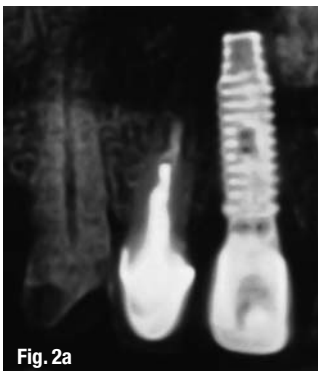

Fig. 2a

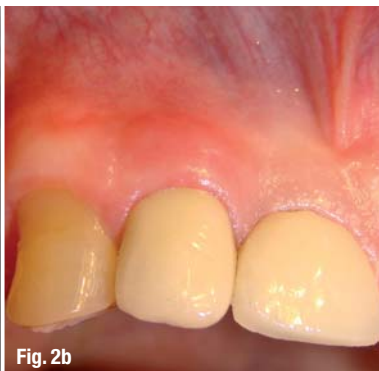

Fig. 2b

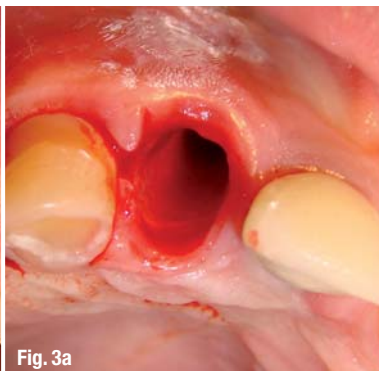


Fig. 3a

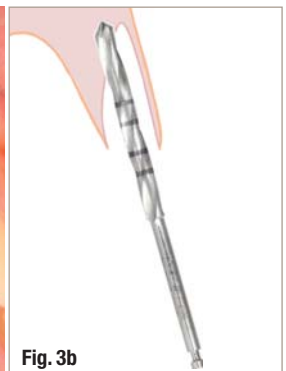

Fig. 3b



PERFECT FIT BY DESIGN

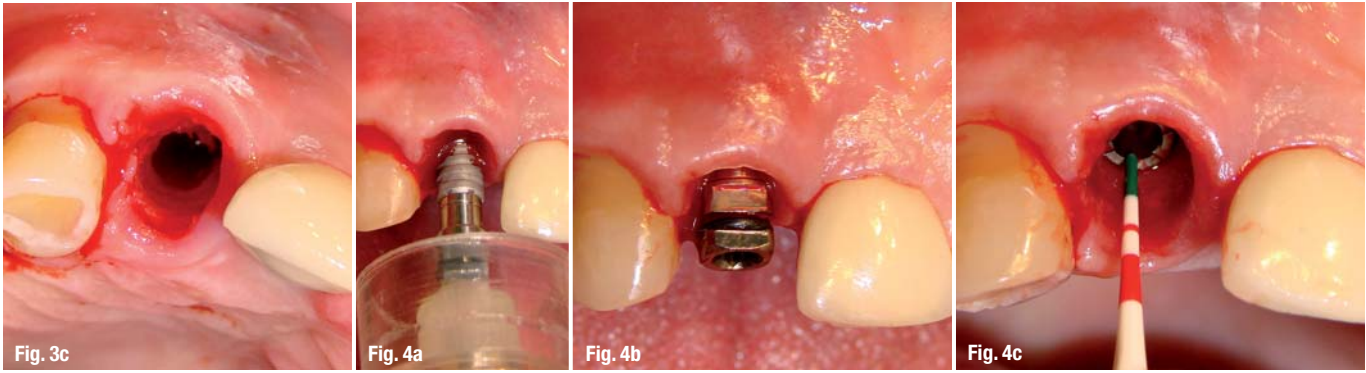
In combining Soft Tissue and Bone Level implants with a comprehensive prosthetic portfolio, Straumann has devised one system for all indications. The **Straumann® Dental Implant System** – excellent product quality designed for convincing, naturally esthetic outcomes.



Featuring the
SLActive® surface!

More information on www.straumann.com

COMMITTED TO
SIMPLY DOING MORE
FOR DENTAL PROFESSIONALS



Figs. 4a–c Image of implant being placed in the implant bed (a), its final position (b), and the probe marking about 2 mm below the level of the central alveolar bone crest of the tooth (c).

essential for the prevention of peri-implant cervical bone loss (Cochran et al. 2009; Mangano et al. 2009; Schwarz et al. 2008) because these micro-movements between the implant and the abutment could lead to the formation of a micro-gap (Rack et al. 2010), resulting in internal contamination of the implant (Jansen et al. 1997; Steinebrunner et al. 2005).

This case report is aimed at demonstrating the advantages of the design of the Morse taper implant (Implacil De Bortoli) for maintenance of the anatomy of the peri-implant tissue.

Case presentation

A 53-year-old male patient requested treatment of a coronal fracture of the right maxillary lateral incisor, which had been endodontically treated with a metal-ceramic crown with a metal core (Fig. 2). During surgical planning, factors essential to treatment success were observed, among which was the maintenance of the proximal bone crest, which is essential in determining the prognosis of the interproximal papilla of the implants (Rack et al. 2010) and future difficulties rising from the adjacent tooth, the central incisor, which was a prosthesis supported by an implant.

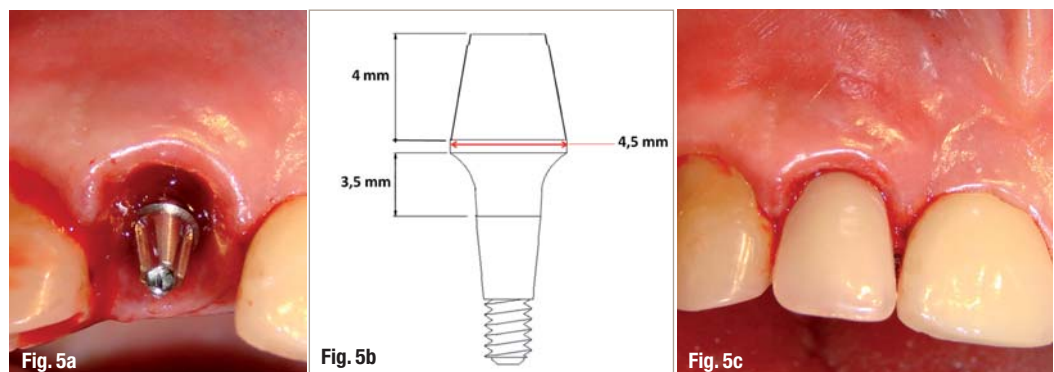
During drilling, it was observed that the pocket depth was less than 4 mm, since the fracture was fresh. After evaluating the patient's need for immediate aesthetics and his general condition, we chose to extract the remaining root and immediate placement of the implant

and of the provisional. After anaesthesia, appropriate syndesmotomy was performed without displacement of the incision or tissue, in order not to disrupt the gingival line and to keep the papilla in position in seeking to prevent bone loss. This was achieved by performing an atraumatic extraction of the tooth (Fig. 3a).

An osteotomy was then performed in order to ensure the ideal position of the implant with regard to the future position of the prosthesis (Fig. 3b). The surgical sequence of the perforations followed the standard protocol specified for the placement of tapered implants, paying attention to the mesiodistal and buccolingual positioning of the implant, which should be around 1 to 2 mm for the buccal palate in relation to neighbouring teeth. The osteotomy started with super sharp drill launches in the predetermined position towards the palatal wall of the socket, preserving the labial plate. Subsequently, we used a 2 mm drill to the planned depth with a direction indicator to verify the need for adjustments in the orientation of the implant. This was followed by conical drills of 3.5 mm and 4 mm (Fig. 3c). The selected implant was a tapered Morse cone implant of 4 mm in diameter and 13 mm in length (Implacil De Bortoli).

The implant was placed in the implant bed (Fig. 4a) manually using with a torque meter (Fig. 4b), positioning the implant approximately 2 mm below the level of the central bone crest of the alveolar bone (Fig. 4c). The crash was performed at a torque of 50 N cm. An abutment (3.5 x 4.5 x 4 mm) was immediately placed (Fig. 5a).

Figs. 5a–c The positioned abutment (a), diagram showing the dimensions of the measured values (b), and the seated provisional (c).



Nobel Biocare Global Symposium 2013 – New York

JUNE 20-23, WALDORF ASTORIA NEW YORK

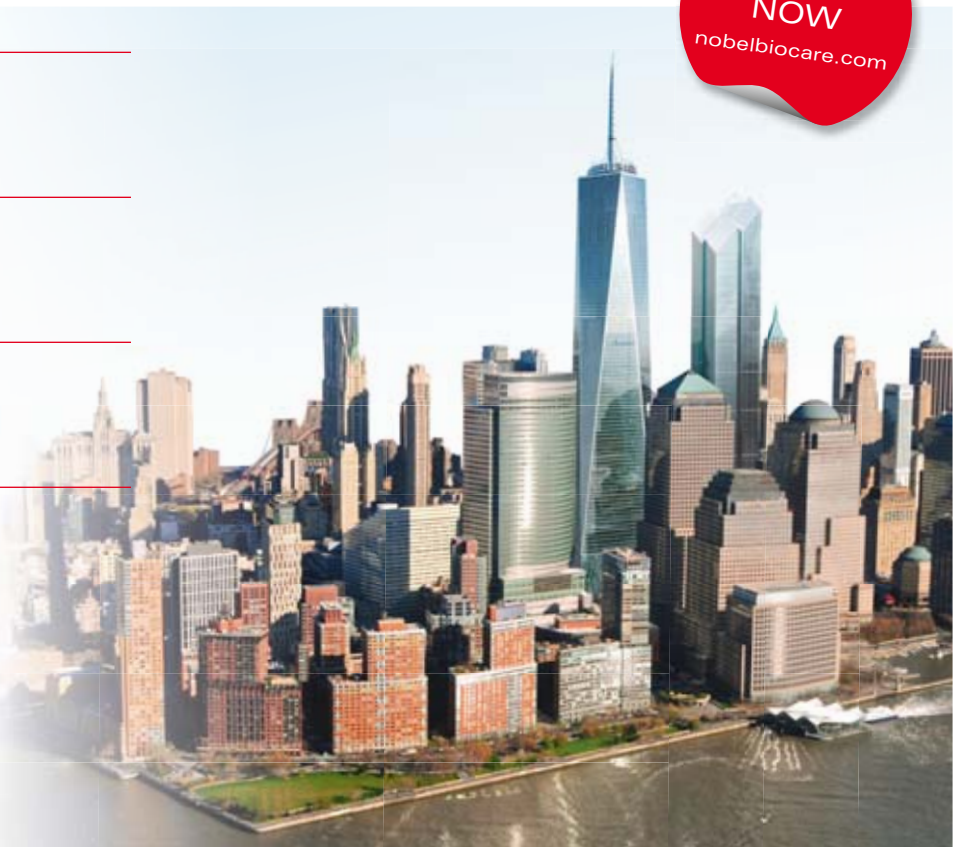

Gain insight how to treat
more patients better

Experience the best in
implant dentistry

Learn from over 100 world-
renowned leaders

Enjoy the fascinating
city of New York



Designing for Life: Today and in the future. Join the leading experts in implant dentistry at the event not to be missed in 2013. This exciting four-day Nobel Biocare Global Symposium 2013 in New York is your number one opportunity to gain the full 360-degree perspective on how you can treat more patients better. Benefit from an innovative and insightful program format designed to maximize your learning experience. Update yourself on the key factors for successful oral rehabilitation such as diagnostics

and treatment planning, surgical and restorative treatments and patient follow-up. Understand how to effectively restore missing single teeth, multiple teeth and edentulous jaws. Learn more about important clinical themes such as minimally invasive, graftless solutions, immediate replacement and function, soft tissue health and esthetics. Find out how you can utilize this knowledge to achieve even better results. **Register now!**



nobelbiocare.com/newyork2013



Fig. 6 Clinical appearance (a) and radiograph (b) after 30 days.

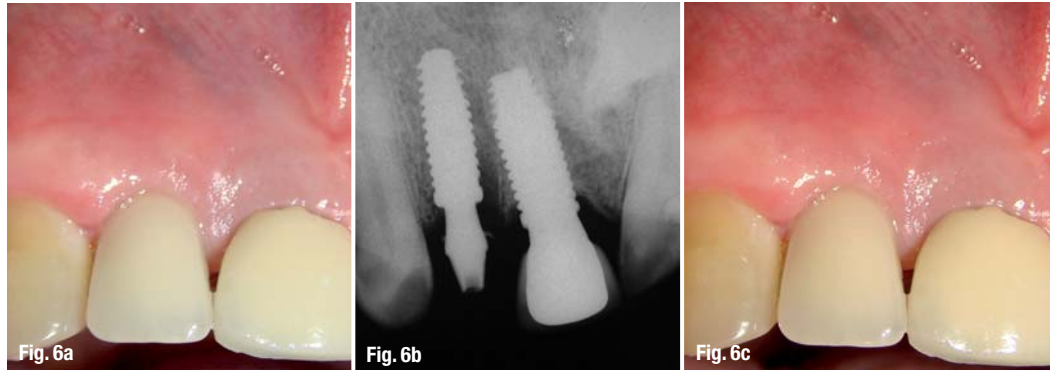


Figure 5b shows the dimensions of the abutment, on which a provisional (Fig. 5c) was fitted with a prefabricated acrylic tooth.

The follow-up radiograph and clinical follow-up demonstrated the good condition of the tissue, which facilitated subsequent rehabilitation procedures (Figs. 6 and 7).

Discussion

The placement of single implants immediately after extraction has been proven to be a treatment modality with predictable success (Lazzara 1989). However, certain precautions should be taken, such as the positioning of the implant, the presence of bone tissue to obtain the initial implant stability and the presence of alveolar bone without great resorption of the walls, as these are essential to the restoration of function and aesthetics (Tarnow & Eskow 1995). An important consideration in the placement of implants immediately after tooth extraction is the behaviour of adjacent soft tissue during the healing period because, according to Schropp et al. 2003 who studied the changes in tissue (bone and gingiva) for 12 months after tooth extraction, early implant placement is favourable, thus increasing the preservation of bone anatomy and demonstrating the effectiveness of the technique.

The 3-D position of the implant is important for the development of the emergence profile of the tooth crown, especially the location of the implant in the apical direction. Therefore, the position of the IAJ influences the long-term outcomes. Placement at 1 to 3 mm sub-crestally can improve the aesthetics. A healing cap with an emergence profile could be used. The replacement of the prosthetic component in the event of tissue recession can help to maintain the texture and tone of the peri-implant mucosa, contributing also to the restoration of the marginal tissue architecture (Bridges et al. 2008).

In a clinical and radiographic study in dogs, in which implants with reduced platform were positioned at the crest and 1.5 mm below the crest, Novaes et al. (2006)

found that the implants showed better results sub-crestally, compared with implants placed at the level of the bone crest. Positioning the implants sub-crestally resulted in a location above the bone joining the implant and abutment and bone formation above the implant shoulder.

Degidi et al. (2011) reported in their retrospective histological study on nine patients whose implants were placed at different levels with respect to the bone crest. In the sub-crestal implants, pre-existing bone formation was found on the implant shoulder and no bone resorption was found when the implant had been inserted to a depth of 3 mm, but bone formation contacting the surface of the abutment. Thus, placing the implant at a sub-crestal level seems to be a good alternative for achieving an aesthetic result; however, further studies are necessary.

Conclusion

The placement of an implant immediately after extraction and placement of the provisional, in most cases, is a suitable alternative because it helps to preserve bone structure and gingiva. Additionally, it provides the patient with immediate psychological benefit, aesthetically and functionally. With the new design concepts and relation between the abutment and the implant regarding position, implants such as Morse taper implants can help maintain a larger amount of peri-implant tissue, thus improving the aesthetic condition.

contact

implants

Prof Sergio Alexandre Gehrke

Rua Bozano, 571
Santa Maria – RS
97015-001
Brazil

Tel.: +55 55 3222 7253
sergio.gehrke@hotmail.com

Nothing changed.
Just improved.



Clean handling

No. 1 bone substitute*

Very good consistency

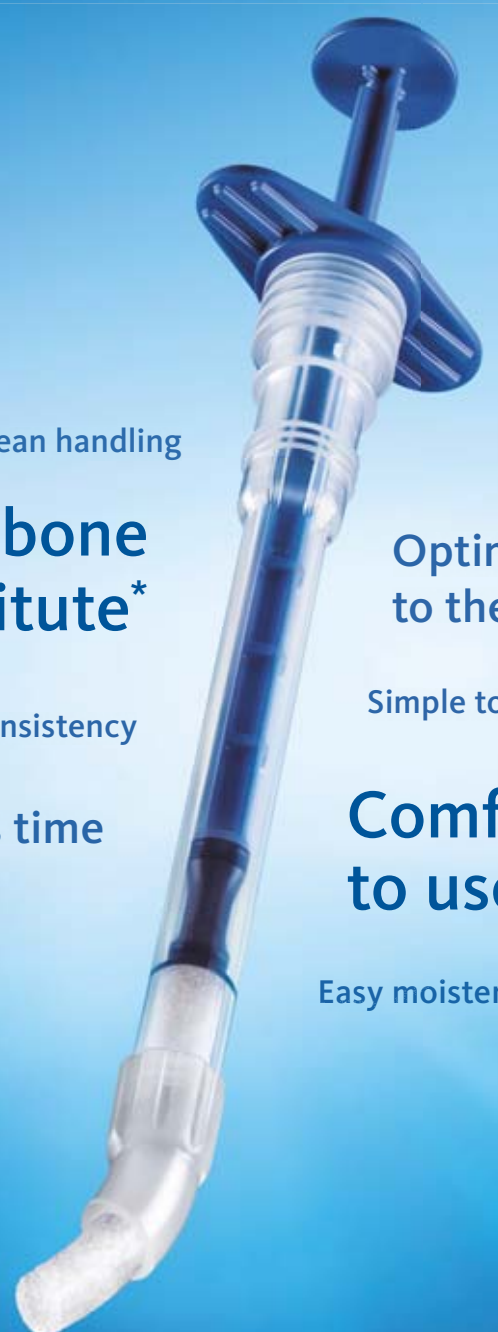Saves time

Optimal access to the defect

Simple to use

Comfortable to use

Easy moistening



New!

- ✓ Unwrap
- ✓ Moisten
- ✓ Use

* iData Research Inc., US Dental Bone Graft Substitutes and other Biomaterials Market, 2011.


iData Research Inc., European Dental Bone Graft Substitutes and other Biomaterials Market, 2010.

Please check for availability of this product with your country representative: www.geistlich-pharma.com

For more information visit:
www.bio-oss.com

Cost effectiveness in implant dentistry

Author_Prof Dr Mauro Labanca, Italy



[PICTURE: ©PESHKOVA]

_Introduction

Today, about 65% of Italian dentists are practising implantology. In Italy alone, over a million implants are placed every year. A survey commissioned by the Italian Society of Osseointegrated Implantology on implant perception among the Italian population found that 68% of the respondents would request an implant should the need for an artificial tooth arise. One Italian out of three has undergone oral implant surgery. It follows that osseointegrated implants will be offered by a growing number of professionals and be placed in an ever-larger population in the future.¹

It should also be noted that the economic crisis has severely affected even the dental field, and the repercussions of this phenomenon have been reported by newspapers, professional associations and the Ministry of Health in Italy. The Osservasalute report, an overview of health in Italy (compiled by the National Observatory on Health Status in the Italian Regions, based at the Università Cattolica del Sacro Cuore's campus in Rome), reported in 2010 that Italians are being forced to save and that both the food and dental industries will suffer as a result.²

Past president of the Italian National Association of Dentists (ANDI) Dr Roberto Callioni analysed

the consequences of the economic crisis and future prospects at a conference held under the auspices of the Ministry of Health on 29 March 2011. He stated that, according to a survey by ANDI in 2010, 30% of Italian dentists have less work because of the crisis.³

However, he also observed an increase in offerings owing to the extension of retirement age and the number of graduates, and a decline in demand related to the decrease in purchasing power, a decline in birth rate and a decrease in the DMFT index.³ In addition, dentists have to compete against low-cost dental offers and dental tourism to some locations in Eastern Europe (as was the case in the 1990s with regard to the Netherlands). The increase in offerings and the reduction in demand have resulted in the average practitioner having higher costs and lower revenues, also owing to the instability of supply and demand. Oral implantology is affected, as are other disciplines of dentistry, by the current socio-economic situation. Yet, the sense is that of a greater demand by the public and a need for the dentist to offer treatment at a lower cost.

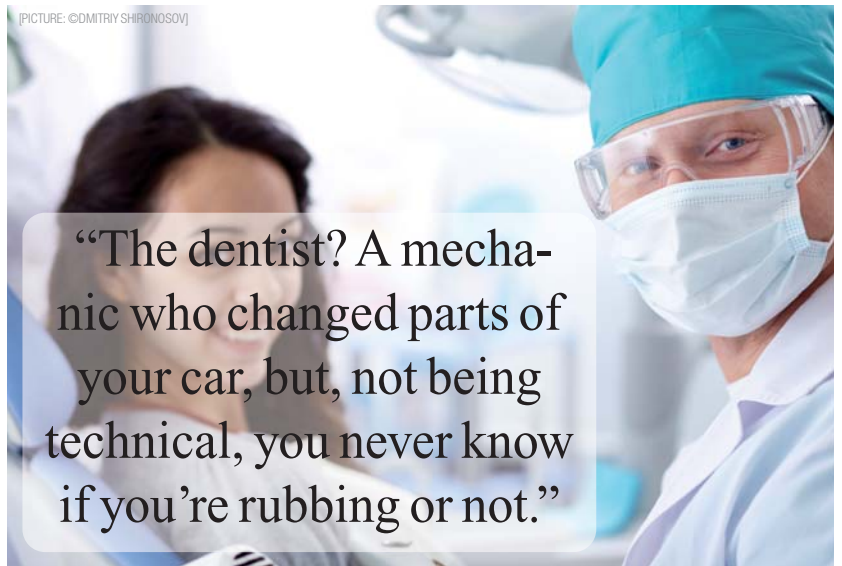
In Italy, there are more than 300 different implant systems (probably not an accurate estimate, considering the difficulty in recording copies of copies). These systems usually have the certification necessary for the market, but only a small pro-

portion of them are supported by scientific evidence, based on studies appropriately designed and conducted by independent research institutions, attesting to their clinical performance, especially in the long term and with the proper follow-up. These are the considerations that, together with the lack of reference measure for quality, led the Italian Society of Osseointegrated Implantology to organise the quality forum in implantology, held in Verona from 15–17 November 2008, in which a large number of experts analysed the various aspects of quality in implantology.

The selection of an implant system suited to the demands of the professional is strongly felt to optimise costs when trying to increase profits where possible without interfering with the quality delivered. As written by Pierluigi La Porta in the context of the forum of quality in implantology:⁴

The professional liability requires that the professional has all the factors of production under his control by deploying useful tools to measure the quality of his works, the results that follow and the tools used to achieve performance. Moreover, the information asymmetry that characterizes the doctor-patient relationship is known in the health field, making patients entrust themselves to the profes-

(PICTURE: ©DMITRY SHIRONOSOV)

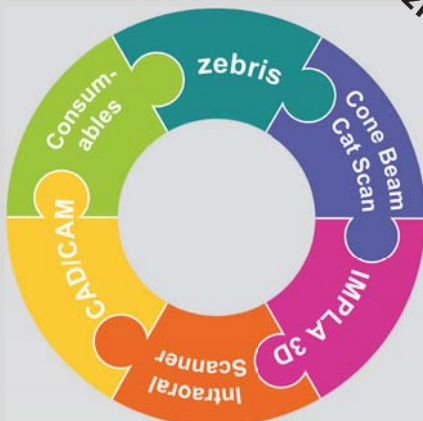


“The dentist? A mechanic who changed parts of your car, but, not being technical, you never know if you’re rubbing or not.”

sionals' decisions in order to solve their health problem. This assignment essentially denotes the inability of the patient to decide what is really best to do in that situation, even if he is well informed. His expectations are related to the solution of the problem, but he rarely pays attention to the way it is resolved or the instruments used, so the professional is solely responsible. The case law indicates the responsibility of the doctor to “act like a good father” when he is the

AD

THE FUTURE IS DIGITAL. START NOW!



Complete Digital Workflow

- » all systems from one supplier, thus perfectly coordinated
- » become even more successful
- » a different way of getting new customers
- » keep the profit

Scan me.



Register now for our newsletter:
<http://sdent.eu/newe>

Further information:
www.schuetz-dental.com



Procedure	1 fixture + 1 crown in porcelain
Protocol	Delayed-load cemented solution
Implant system	variable
Cost of the practice 1 h surgery	€130
Cost of the practice 1 h prosthetic	€80
Cost of 1 h other activities (consultation, check ...)	€70

Table 1 Cost analysis for various procedures.

one to decide for his patient. So be sure that the quality of his performance becomes a must of his action. When professionals begin to question the quality of their performance, then you are facing a true and profound cultural change.

To these considerations, one might add: why would a patient choose to seek treatment in a dental centre?

"The dentist? A mechanic who changed parts of your car but, not being technical, you never know if you're rubbing or not."

This is how one interviewee responded to the request by the well-known psychologist and professor of marketing and communication Alberto Crescentini to describe the figure of the dentist.⁵ The average patient finds it difficult to evaluate the quality of a medical service from a technical point of view because he simply does not have the skills. It is our duty not to betray him, and act according to the science and our knowledge. Bearing this all in mind, we should determine the possible savings in the management of implants and whether buying an implant at a lower cost will result in cost effectiveness. To quote Charles Darwin:

Table 2 Average price of a cheap implant system in the market, showing variable costs.

Item	Cost
Fixture	€95
Insertion	225:10 (Drills/number of uses)
Cover screw	€28
Surgical screwdriver	€54
Transfer	€45
Analogue	€27
Titanium abutment	€55
Prosthetic screwdriver	€31 + €181 (DIN Raquet)
Individual impression tray	€30
Prosthesis (single ceramic crown)	€250
Total	€568

"It is not the strongest species that survive, nor the most intelligent, but the ones most responsive to change."⁶

In the literature, there are various articles about implant placement techniques, biomaterials and loading protocols, but there is only very little information about cost analysis in relation to implant-prosthetic procedures.

Questions regarding the cost of implant placement and the amount a dentist can earn by placing fixtures tend not to be discussed at congresses, as if in fact the one and only important aspect is the finalisation of the case. In a country like Italy, where dentistry is largely private, the economic aspects are fundamental for the acceptance of the treatment plan by the patient. Even in ethical terms, if the dentist believes that his implant is really the most appropriate solution for that particular case, prohibitive costs could deprive the patient of that possible solution or push him towards other choices, both operational (other restorative solutions) and logistic (low-cost dentist or travel to a dentist abroad).

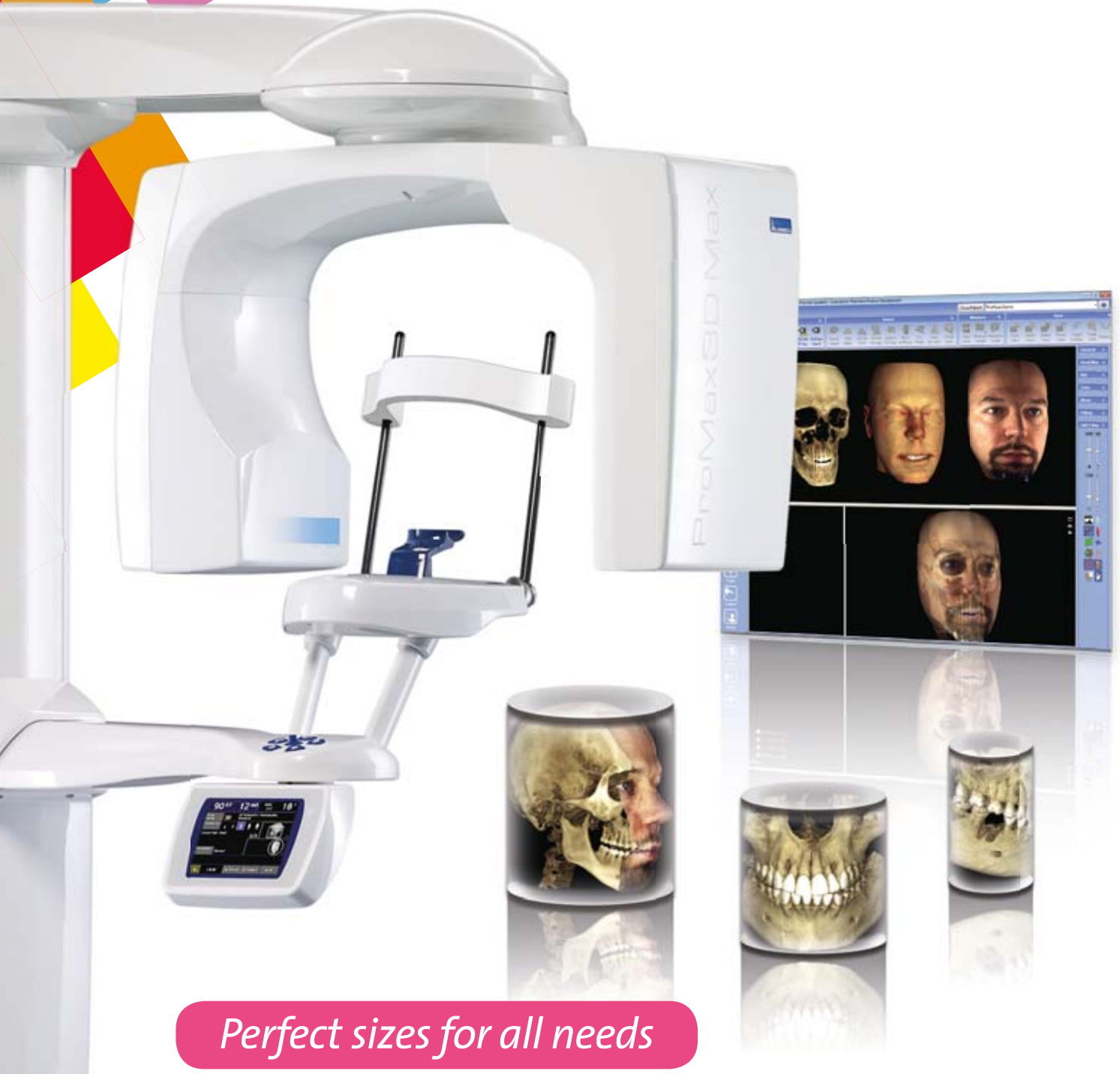

(PICTURE: ©PAKHNYUSHCHA)

As observed earlier, there are over 300 different types of implants in Italy. Conventionally, these are divided into classes based on various aspects, one of which is purchase price. We could argue, however, that all implants are osseointegrated in the end and that implants that are more expensive are simply more advertised, but in essence they are the same as others. In Italy, many "homemade" and low-cost implant systems are available on the market whose traceability is practically absent in the literature and whose manufacturers are not able to guarantee long-term reliability.⁷ If we evaluate the sales data of the leading implant-producing companies, eight to ten leading companies hold 90% of the existing market share. As a logical consequence, the remaining 10%, amounting to approximately 100,000/150,000 units, can be divided among the remaining 300 or more companies on the market. What can the average number of implants sold by each of these be (despite what their dealers tell dentists)? Are they supported by case studies or other

Planmeca ProMax[®] 3D

Unique product family



Perfect sizes for all needs

3D X-ray • 3D photo • panoramic • cephalometric

Romexis[®] software completes 3D perfection



Digital perfection™

More information

www.planmeca.com

Planmeca Oy
Asentajankatu 6, 00880 Helsinki, Finland
tel. +358 20 7795 500, fax +358 20 7795 555
sales@planmeca.com

PLANMECA

Table 3 Fixed costs relating to implant placement in a private practice.

Radiation Protection
Verification of the electrical system
Waste disposal
Insurance
Additional fees (phone, electricity, etc.)

scientific literature? We should not forget that the intervention of implantation entails placing a foreign object, even if this is made of titanium, into the mouth of a patient, hopefully for life, and with undeniable biological effects. In order to do this in a verified and ethically correct way, I believe that the operator should ask questions and go beyond just checking the CE marking, much as he would do in the case of a drug prescription. Who would recommend taking an antibiotic available on the market a few years ago and tested on an insufficient number of patients?

Cost considerations

After these considerations, procedural and ethical, I turn to what may be the cost items for the realisation of an implant-prosthetic restoration. This assessment does not come from the perspective of a marketing expert or an economic expert, but from the pure and simple perspective of a daily operator who must evaluate which elements actually affect daily clinical practice.

It takes into consideration the variable costs and fixed costs. Variable costs change more or less in proportion to changes in the production volume (the insertion of two implants and two crowns costs more than that of only one; paying an assistant for two hours costs less than paying him for eight hours). Fixed costs are defined costs that are not derived from the production volume. Fixed costs in dentistry are all the costs linked with the activity of the practice, such as those related to radiation protection, verification of the electrical system, sterilisation, waste disposal, insurance policy, building rental/payments and utilities in general.

The fixed costs are taken into account for any type of service rendered by the practice (Table 1). It is generally believed that a cheaper implant system is needed to save costs (Table 2) regarding implant treatment. From an analysis of the variable costs, it is evident that the costs of the storeroom and of the implant components are significant.

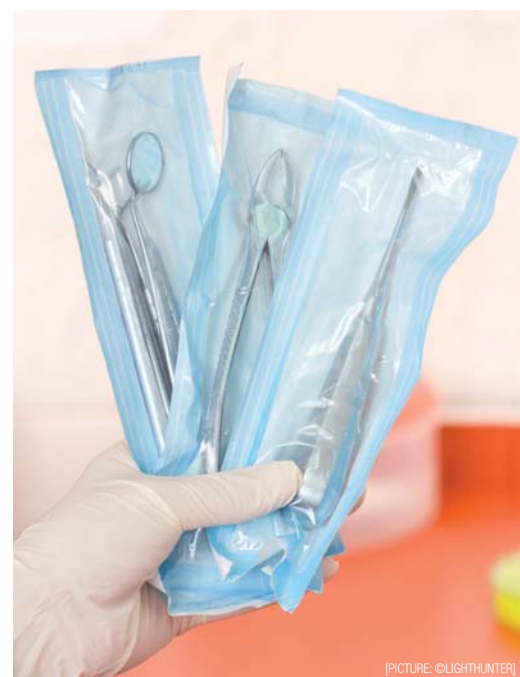If an implant system entails many surgical steps, requires the use of many drills, has different platforms depending on the diameter of the neck, re-

quires a surgical screwdriver and a prosthetic screwdriver or if different healing abutments are required for each implant placed, the final cost will change significantly, together with an increased risk of errors and inaccuracies (Tables 3 & 4). In particular, if the implant system offers different diameters, each requiring a different healing abutment, a different transfer and a different analogue, the amount of material to be kept in stock will be much higher, considering the prosthetic solution for every case. In terms of the healing abutment, stocking different heights and diameters according to each size available (at least four for the major implant systems) requires dozens of healing abutments even if only a few implants are placed. All this also inevitably leads to mistakes, organisational miscommunication, etc.

If the cover screw and the healing abutment came together with the implant, and therefore already included in the package (and price), things would be much more ergonomic. There would no longer be a need to stock other material or to re-use titanium healing abutments with the inevitable associated risk of inducing peri-implantitis during uncovering.

Costs related to sterile conditions

In a study on the success rates of osseointegration for implants placed under sterile versus clean conditions, Scharf and Tarnow found that the difference in the success rates was not statistically significant.⁸ Sterile surgery took place in an operating room setting and followed a strict sterile protocol.



[PICTURE: ©LIGHTHUNTER]

Cost of fixture
Cover screw
Surgical kit
Drills
Surgical screwdriver
Transfer
Analogue
Titanium abutment
Prosthetic screwdriver (if required)
Individual impression tray
Prosthesis (crown, bridge, etc.)

Clean surgery took place in a clinic setting with the critical factor that nothing touched the surface of the implant until it contacted the prepared bone site. The results indicate that implant surgery performed under both sterile and clean conditions can achieve the same high rate of clinical osseointegration. This means that, while it is therefore not essential to incur the costs related to absolute sterile conditions (Table 5), dentists should not undertake surgery without taking adequate precautions in this regard. The modest savings achieved with regard to the total cost of the intervention could lead to a significant increase in the risk of failure.

We have to consider that an insufficiently tested implant system may lead to trivial errors (difficulty in taking an accurate impression, tightening the components, rotation or loosening of the prosthetic components), resulting in an inevitable loss of time, which in turn affects the cost and delivery. What sense does it make to save €50 on the cost of the implant system when you have to spend as much or more in buying components separately or in seeing the patient several times owing to these trivial errors (considering the hourly rate given above)?

Also, if failure is always a factor to be taken into consideration, it follows that dentists must seek to eliminate predictable and avoidable failures, which are those for which the dentist is partly responsible (the aforementioned poor management of sterility, improper surgical planning, and an incorrect or adequate surgical sequence). Predictable and avoidable failure may not only result in easily quantifiable economic damage, but also lead to important and less easily quantifiable damage in terms of the reputation and credibility of the practice, which could affect the patient's confidence in the dentist and his willingness to promote the practice.

Conclusion

In conclusion, we should consider the following with regard to cost management in implant surgery:

- paying particular attention to the significant costs;
- simplification and streamlining of clinical and extra-clinical procedures;
- identification of alternative treatments with a different cost-benefit analysis; and
- a schedule for reduction or elimination of errors and significant associated costs.

All this will contribute towards a better understanding, and in a more responsible and ethical way, of when it is really necessary to try a new implant system and by what criteria its actual reliability can be evaluated. What is the true effect of the price of the implant on the total cost for the practice? We should not be misled in selecting an item that does not appear to be of primary importance in terms of absolute cost. A final consideration is the cost in terms of the practice's reputation, for example in the case of an avoidable failure.

Table 4_Fixed costs of the fixture.

Sterility kit	Cost
High-sterility kit (mod. Brånemark)	€80
Medium-sterility kit	€40
Minimal-sterility kit	€25

Table 5_Cost of sterility.

In the light of these considerations, by selecting protocols and materials more rigorously and by giving greater consideration to ethics in our evaluations, we will be able to achieve a real reduction in cost in areas that do not involve interference in the final quality of our work output.

We should attempt to save money in areas that affect the final result, with important consequences for us, for our professionalism and for patients who gave us their trust and confidence when entrusting their health to us. Do we have the right to betray their trust, or do we rather have the duty to preserve and respect it?

_contact	implants
<p>Prof Dr Mauro Labanca Consultant Professor Corso Magenta, 32 20123 Milano, Italy maurolab@tin.it</p>	

Perio meets implant dentistry

A time-tested relationship

Author_Prof Dr Rainer Buchmann, Germany

_Introduction

The preservation of the natural dentition is the prerequisite in daily patient care. In advanced periodontal disease, the successful realization of implant therapy requires knowledge in patient expectations, clinical diagnostics, proper surgical skills and delegation of basic services to dental hygienists. Implant treatment in severe periodontitis demands a two-step, time-tested approach, evaluating the outcomes of basic periodontal therapy before implant placement.

_Integrated dentistry: Success for today and tomorrow

The successful positioning of dental partnerships in the fast-growing health market implicates predictable treatment strategies to save permanent teeth. According to orthopedic, cardiac or vascular medicine, an on-time decision-making for implant therapy is recommended to counterbalance functional and esthetic discomfort in advanced endodontic and periodontal breakdown settings. Patient's current and future expectations drive our practices into the necessity to provide synergistic periodontal and implant treatment solutions. The advantages are:

- Optimizing implant success by preceding with periodontal therapy.
- Enhanced economic profit due to by-effects from delegated scaling and root planing.
- Promotion of oral and body health of both dental patients and staff members.

The need to preserve healthy teeth and gums, the ever-expanding influences of web, TV and magazines and an increase in low-cost implant treatment render implant dentistry internationally attractive. The transition of dental practices into the implant market is reasonable, especially for growing dental partnerships. The capital investment and running costs for a surgical im-

plant setting are redeemed by more than 30 implants a year. Because of the economic commitment, a careful financial strategy is needed not to neglect challenges and developing concepts preserving and salvaging compromised teeth from conservative and periodontal dentistry.

_Decision-making in periodontal diseases

Classical implant therapy protocols comprise must-indications resulting in an immediate treatment plan. According to patient preferences, clinical settings and insurance plans, these must-indications with an adhoc implant placement recommendation are, in order of precedence:

- Long-term missing bridgeworks or prosthesis, edentulous mandible
- Advanced endodontic damage
- Trauma (tooth fracture)
- Oral cancer surgery.

Periodontal diseases represent can-indications. Treatment planning is running more complex. The decision-making comprises a time-tested therapeutic approach. In advanced periodontal settings of more than 50 % bone loss with furcation involvement level III, patients suffer from oral discomfort. The tooth prognosis

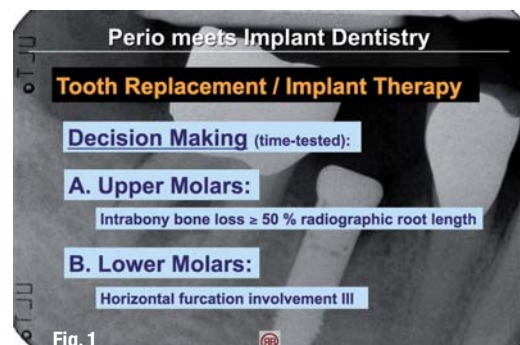


Fig. 1_Treatment of advanced periodontal disease with implants replacing the natural dentition is recommended "time-tested" 3 to 6 months following periodontal therapy (SRP).

becomes less positive, the frequencies of follow-up visits increase (Fig. 1). Periodontal therapy "before" implant planning is aimed at saving doubtful (not hopeless) teeth with a grace period of at least three to six months to evaluate for periodontal treatment outcomes. Thorough scaling and root planing frequently results in a mid-term improvement (two years) up to a long-term stabilization (five years) of preliminary affected teeth.

The decision to maintain the periodontally compromised dentition undergoes the following criteria (Fig. 2):

- Patients with no personal preferences to comfort, esthetics and costs
- Patients willing to accept enhanced tooth mobility, occasional food impaction and frequent professional tooth cleaning
- Individuals with chronic diseases and autoimmune disorders.

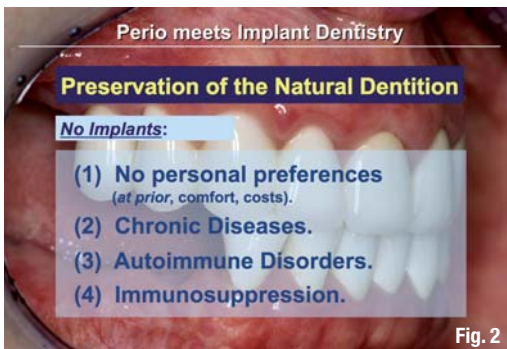


Fig. 2

The recommendation to replace affected teeth with implants is indicated in the following clinical situations and should be planned on-time after completion of periodontal therapy (three to six months):

- Patients running a demanding business striving for fixed teeth
- Enhanced masticatory and cleaning comfort
- Long-term rehabilitation with low input in time, effort and expenses.

Currently, the items above are effective at implant placements within the local bone, minor lateral hard and soft tissue deficiencies, following sinus floor elevation, in settings with sufficient implant abutment distances of 3 mm and after periodontal therapy. Extended surgical protocols enhance treatment time (Fig. 3), ren-

Implant Treatment Protocol		
1. Visit:	Basic Implant Exam	(1/2 h)
	X-Ray, Alveolar bone width, Charges, DVT (Reduced bone support)	
2. Visit:	Removal Bridgework	(Down Payment) (1 h)
3. Visit:	a. Implant Surgery*	(1 h)
	+ Sinus Elevation	(+1 h)
	+ Augmentation (lat./vert.)	(+1 h)
	b. Periodontal Regeneration	(1/2 h)
4. Visit:	1. Visit post-OP	(2 weeks) (1/4 h)
		(Bill Surgery)
5. Visit:	Fixed / Removal Prostheses	
	* Front or molars / jaw (Mandible 4, Maxilla 6 mo.)	

Fig. 3

der the case prognosis uncertain and may aggravate long-term success.

Implant therapy in advanced periodontal disease

The survival rates of teeth with severe periodontal damage published in evidence-based studies are rarely valid for patients inquiring treatment in dental offices (Fig. 4). Shortcomings in oral hygiene, lack in supportive care, oral dysfunctions, stress, smoking and general disorders abbreviate the function times of periodontally-compromised teeth sustainably.

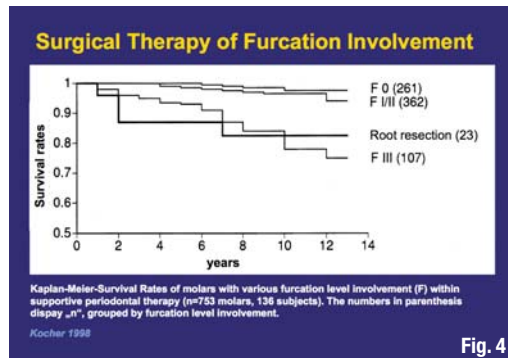


Fig. 4

The advice to replace affected teeth with implants in advanced periodontal settings within the maxilla implicates on-time patient information of the second and third molar removal: implant placement and prosthetic bridge works are scheduled in the functional masticatory area until to the first molar. In the mandible, the second molars can be preserved due to their beneficial root anatomy. They should be restored, but not included in implant planning. Following the removal of the first molar in the maxilla, implant therapy is often preceded (if the supporting bone is less than 4 mm) or accompanied by a simultaneous sinus lift. The implant treatment plan in periodontally compromised patients results in a reduced dentition (Fig. 5):

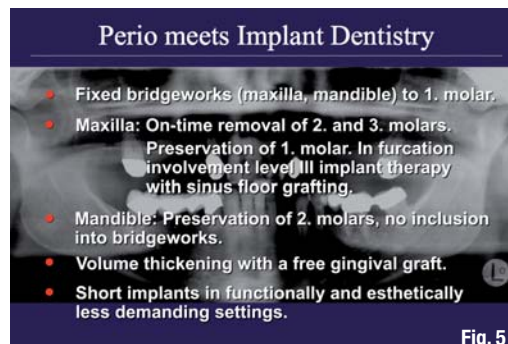


Fig. 5

- Fixed bridgeworks in the maxilla and mandible up to the first molar
- Maxilla: preservation of premolars and first molars, tooth removal and implant therapy with sinus floor elevation at furcation involvement level III (Fig. 6)
- Mandible: preservation of second molars, restoration, no inclusion into bridgeworks

Fig. 2 Exclusion criteria for implants with continuation of saving natural teeth after comprehensive periodontal therapy.

Fig. 3 Implant therapy should be performed with minimal augmentation. Extended surgical therapy prolongs treatment time, renders case prognosis unsafe and may aggravate long-term success.

Fig. 4 Unexpected life-events half cut the survival rates of teeth with advanced periodontal bone loss in daily practice down to 5-7 years.

Fig. 5 Guidelines to a safe implant treatment protocol in advanced periodontal disease.

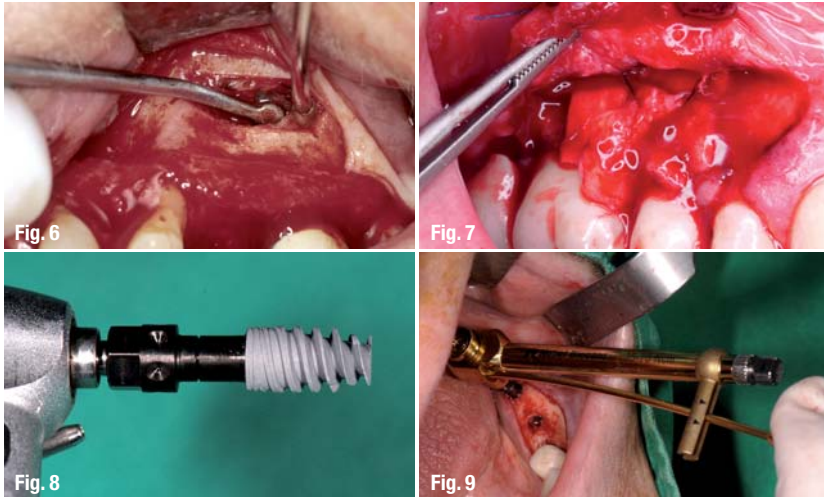


Fig. 6 The piezosurgical access to the lateral sinus is the best approach to promote implant supported bone in the maxilla. Short implants are not advocated, internal lifts technique-sensitive.

Fig. 7 Volume thickening with a free gingival graft in an initial thin tissue with buccal perforation.

Fig. 8 Short implants are advised in critical anatomic situations when the alveolar bone width is sufficient. Functionally, they represent no alternative to classical augmentation protocols. (Photo: Kochhan)

Fig. 9 Insertion of short implants close to the alveolar nerve in the mandible with sufficient alveolar bone width. (Photo: Kochhan)

Fig. 10 Implants require a comprehensive maintenance care. Periimplant inflammations display foreign body infections that are more harmful for the body health than periodontal diseases.

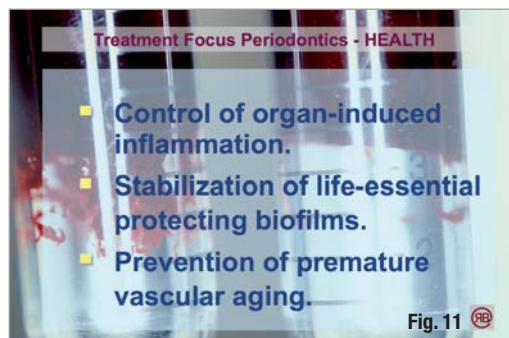
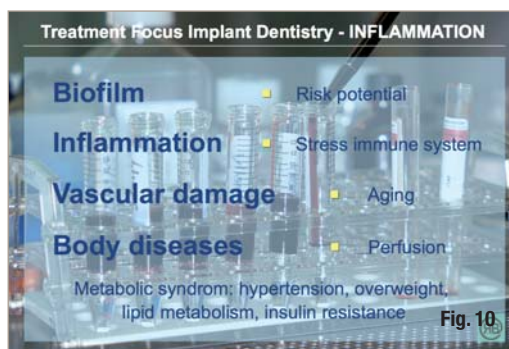
Fig. 11 Periodontal therapy lowers the inflammatory burden and promotes health while optimizing body metabolism with stimulating effects onto the vascular system.

- Volume thickening with free autogenous gingival grafts in initial thin biotype settings (Fig. 7)
- Short implants in both esthetically and functionally less demanding situations as an alternative to surgical augmentation (Fig. 8).

Low bone quality (D3/D4), lateral hard-tissue deficiencies and increased mechanical loading are contraindications for short implants. According to conventional implant rehabilitation, the horizontal width of the alveolar bone crest is the fundament for functional stabilization, vascularization and nutrition, thus for implant survival and clinical success (Fig. 9).

Inflammation and hygiene

Clinical healthy and stable implants are completely covered within the alveolar bone by osseointegration.



They also are attached to the periimplant gingiva and thereby become functionally included into the body's metabolism. This explains the high overall survival rates of oral implants between eight and more than 15 years. The combination of

- a thin biotype gingiva with lack of soft tissue protection
- functional overload due to stress, habits or a missing front-canine equilibration, and
- loss of biofilm protection by periodontal diseases

often causes mid-term damages (two years after functional loading) of the implant-to-bone interface. Like periodontally affected teeth with lack of hygiene access and enhanced biofilm accumulation, implants develop a potential risk of inflammation when bacteria enter the implant-to-bone interface (Fig. 10). If the close hard and soft tissue sealing disappears irreversibly, foreign-body infections occur within the oral cavity which are more harmful for the implant-supporting bone and the body health than periodontal diseases. The best protection against periimplant inflammation is not avoiding implants: a careful implant placement strategy with concomitant thickening of the surrounding tissues and relief from functional overload preceded by comprehensive periodontal therapy (hygiene) are the best therapeutic helpers for implant survival and oral health (Fig. 11).

Summary

In advanced periodontal diseases, the network between medical progress and ever-expanding patient's expectations requires a time-tested schedule with a grace period of three to six months to evaluate the affected dentition for periodontal treatment outcomes. If patients anticipate immediately fixed and esthetic restorations, on-time implant therapy with minimal augmentative solutions is recommended. Preservation of periodontally compromised natural teeth is advised when patients display no preference for further comfort and esthetics. Periodontal therapy is continued, supplemented with surgery in advanced intrabony settings where oral hygiene is impaired. The long-term success for the natural dentition and implants similarly depends on patient's medical and local risk factors that cannot be forecasted with any genetic or susceptibility test for sale.

<u>contact</u>	implants
<p>Prof Dr Rainer Buchmann Practice limited to Periodontics Königsallee 12, 40212 Düsseldorf, Germany Tel.: +49 211 8629120</p> <p>E-Mail: info@rainer-buchmann.de www.rainer-buchmann.com</p>	

43RD

INTERNATIONAL ANNUAL CONGRESS OF THE DGZI

October
4-5,
2013

Berlin, Germany
Hotel Palace Berlin



FAX REPLY // +49 341 48474-390

Please send me further information on the
43RD INTERNATIONAL ANNUAL CONGRESS OF THE DGZI
on October 4-5, 2013, in Berlin, Germany.

Office Stamp

Implant-prosthetic rehabilitation of the severely atrophic maxilla

Authors_Prof Dr Gregory-George Zafiropoulos, Aiman Abdel Galil, Germany

Introduction

Modern instrumentation and improvements in regenerative techniques have facilitated both the surgical treatment and the subsequent prosthetic restoration. Nevertheless, dentists and patients frequently are conflicted when deciding between fixed or removable full-arch restorations. Many patients, especially those requiring extensive rehabilitation, clearly prefer fixed, implant-retained restorations. Under certain circumstances, the patient's aesthetic demands, however, can be difficult to satisfy with this type of restoration. Aesthetic outcomes are most frequently hindered by bone

loss resulting from advanced periodontal disease or by bone resorption following tooth loss. Although several methods can be used to augment hard and soft tissue to meet aesthetic demands, the patient can reject these options or the dentist might not be entirely familiar with the procedure selected. Both scenarios may produce unsatisfactory results that become apparent only when treatment is complete.

Removable restorations that use telescopic crowns as attachments are an alternative to full-arch rehabilitation with fixed bridges. Removable restorations can be used especially in cases with extensive jawbone atrophy (e.g. resorption), re-

Fig. 1_First examination. Palatal view.

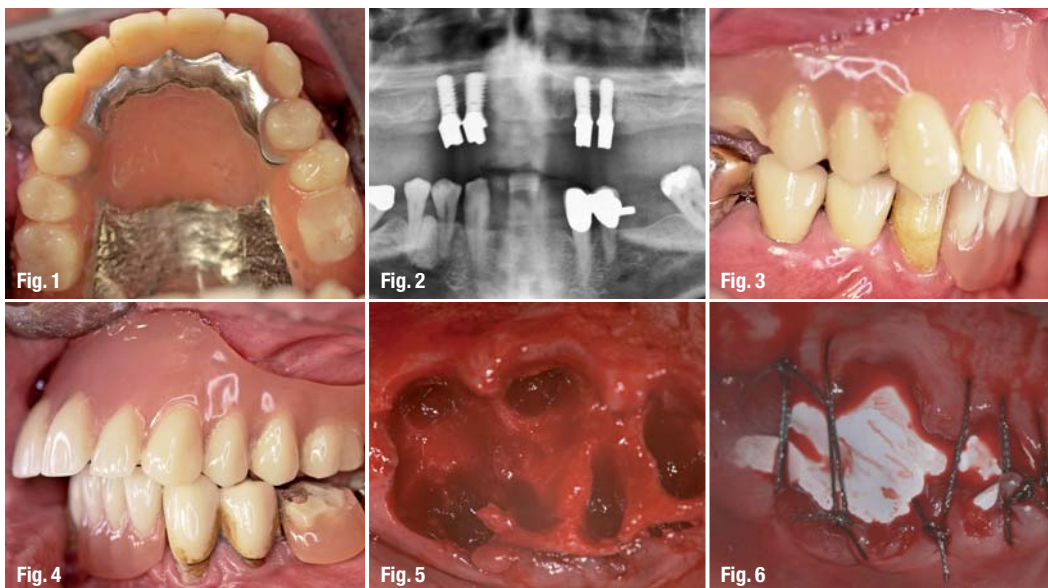
Fig. 2_First examination. Orthopantomograph. Periimplant defects in the maxilla, deep vertical defect #47, generalised horizontal bone loss.

Fig. 3_First examination. Clinical view, Right.

Fig. 4_First examination. Clinical view, Left.

Fig. 5_Socket preservation: cleaning of the extraction sockets.

Fig. 6_Socket preservation: sockets coverage.





Tribune CME

Clinical Masters Program in Implant Dentistry

March 2013 to September 2013, a total of **12 days** in **Heidelberg (DE), Como (IT), Gran Canaria (ES)**

Program director
Dr. Marius Steigmann

Live surgery and **hands-on** with the masters in their own institutes plus online mentoring and on-demand learning at your own pace and location.



Dr. Tiziano Testori



Dr. Hom-Lay Wang



Dr. Scott D. Ganz



Dr. Jose Navarro



Dr. Philippe Russe

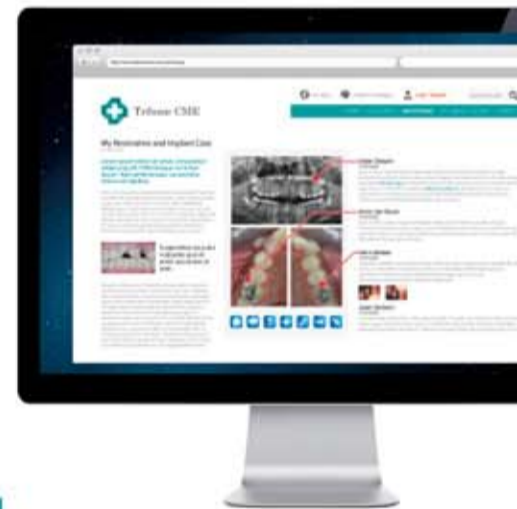

Dr. Marius Steigmann

and others

This comprehensive implant curriculum is composed of **100 hours of learning** in four blended online and offline modules, covering all aspects of implant dentistry. It is unique due to the fact that each module covers a whole range for several specific topics of implant dentistry. For each specific topic, a focus module has been designed including a hands-on exercise. The overall course covers diagnostic, thorough planning, ideal implant placement, grafting (both basic and advanced), prosthetic planning and construction, soft tissue manipulation, complications management, as well as implant maintenance.

During each module, the participants will have the opportunity to practice their new skills on hands-on casts, porcine models, and to watch or assist live surgery.



Course fee: € 11,900

Register by the end of 2012 and you will receive a complimentary iPad preloaded with premium dental courses.

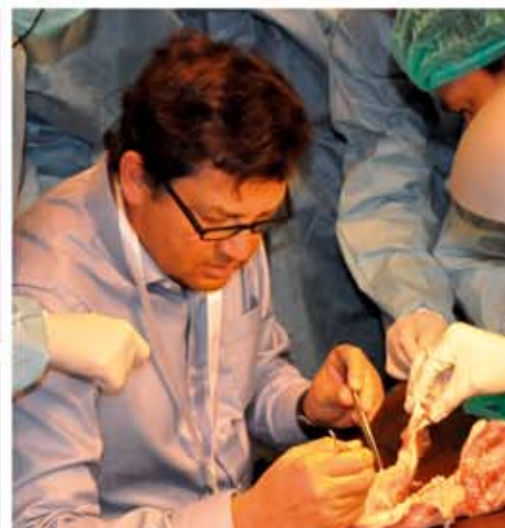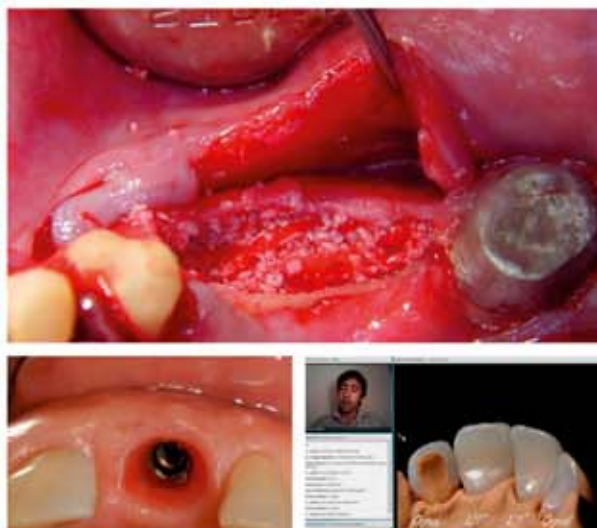Tel.: +49-341-48474-302
email: info@tribunecme.com
www.TribuneCME.com

+ Access our online learning platform: hours of premium video training and live webinars. Collaborate with peers and faculty on **your cases.**

ADA CERP® | Continuing Education Recognition Program

Tribune America LLC is the ADA CERP provider. ADA CERP is a service of the American Dental Association to assist dental professionals in identifying quality providers of continuing dental education. ADA CERP does not approve or endorse individual courses or instructors, nor does it imply acceptance of credit hours by boards of dentistry.

Discover the Masters' secrets and enjoy three superb locations.



100
C.E. CREDITS

ADA CERP®

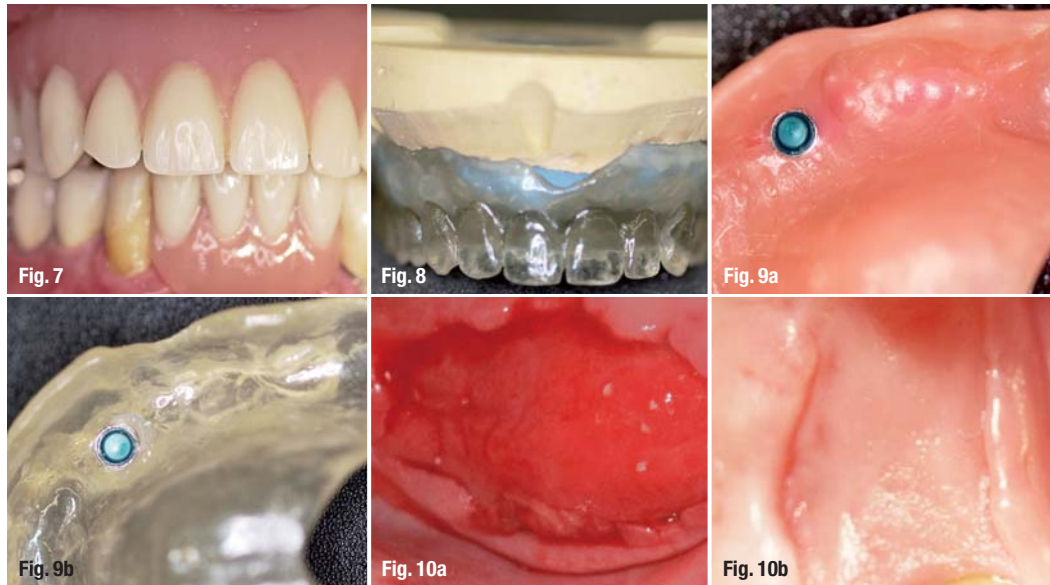


Fig. 7 New interim denture in the maxilla and improved partial denture in the mandible.

Fig. 8 Duplicate of the maxillary denture (DentDu).

Fig. 9a–b Locator-matrice(s) embedded in the basis of the denture (a) and of the duplicate (b).

Fig. 10a–b Socket preservation: a: after removal of the membranes, b: soft tissue healing.



sulting in a large vertical dimension.¹⁻⁴ This article presents the treatment of such a case.

Case

The 55-year-old patient (male, nonsmoker, in good general health) presented for consultation and treatment in our clinic in August 2010. The patient had a three-year-old removable denture (with mid-palatal strap) in the maxilla, supported by four implants using telescopic crowns as attachments (Table 1; Figs. 1 & 2). It was shown that the premolars/molars of the maxillary denture were not in occlusion with the mandibular teeth (Figs. 3 & 4). Furthermore, the denture was fabri-

cated with a sagittal malposition in the anterior area (Figs. 3 & 4). Around the implants, pockets of 6–10 mm with spontaneous bleeding, swelling of the soft periimplant tissue and pain by palpation were recorded (Fig. 2).

A 15-year-old removable partial denture and fixed partial dentures (FPDs) were found in the mandible. The removable partial denture used the following attachments: a) direct retainers (clasps, areas #37 and #43), b) customised gold attachment (area #34–33), c) a gold double crown (area #47) (Figs. 3 & 4). The periodontal tissue showed an inflamed gingiva, pockets of a depth of 5–6 mm and a deep vertical bone defect at the mesial site of the tooth #47 (Fig. 2).

Table 1 Implant Characteristics

Implant area, Restoration (new/old)	Implant Line Diameter x Length (mm)	Time (Months) until uncovering	Customized Abutments
13 (old)	RN #, 4,1x10	4	Gold †
14 (old + new)	RN #, 4,1x10	4	Gold †
23 (old)	RN #, 4,1x10	4	Gold †
24 (old)	RN #, 4,1x10	4	Gold †
16 (new)	SB *, 4,5 x 11,5	4	CrCo ‡
15 (new)	SB *, 3,75 x 10	4	CrCo ‡
12 (new)	SB *, 3,75 x 10	4	CrCo ‡
23 (new)	SB *, 3,75 x 10	4	CrCo ‡
25 (new)	SB *, 3,3 x 10	4	CrCo ‡
26 (new)	SB *, 4,5 x 10	4	CrCo ‡

Treatment

Implants #13, 23, and 24 were explanted, the bone defects were cleaned and augmented by using non-resorbable dPTFE membranes (Cytoplast, Regentex GBR-200; Osteogenics Biomedical, Lubbock, TX, USA) without additional use of any grafting materials, as previously described (Fig. 5, Fig. 6).^{5,6} Flaps were repositioned with interrupted sutures. Membranes were left partially exposed (Fig. 6). The implant #14 (incl. abutment) was saved and used for supporting the maxillary denture. In the same clinical session, sinuses were augmented using a demineralised bovine xenograft (DBX; CompactBone B, Dentegris, Duisburg, Germany).

In the mandible, the natural teeth were treated by scaling and root planing and the crown margins were shorted and finished for allowing a better healing of the soft tissue. Tooth #37 was extracted and the socket was preserved/augmented as above described.

RN # = Regulat Neck, Institut Straumann, Basel, Switzerland
SB * = Soft Bone, Dentegris, Duisburg, Germany

† = Portadur P4, Au 68.50%, Wieland, Pforzheim, Germany
‡ = Ankatit, Anka Guss, Waldaschaff, Germany

Impression was taken in the maxilla for the fabrication of a new denture. An impression was taken from the mandible using an alginate material with the partial removable denture in situ, so that the dental laboratory could put new denture teeth in occlusion with the maxillary denture (Fig. 7). A duplicate of the new maxillary denture (DentDu) was fabricated using clear methyl-methacrylate (Paladur; Heraeus, Hanau, Germany) and kept for later use (Fig. 8). The customised gold abutment from implant # 14 was replaced through a locator and locator matrices were embedded in the basis of both the denture and the DentDu (Fig. 9).

Four weeks after socket augmentation and preservation, membranes were removed (Figs. 10a & b). Four implants were placed in the mandible (#36, 35, 32, 42; Table 1) and the periodontal pocket #47 was regenerated using DBX and a resorbable collagen membrane (BoneProtect, Dentegris, Duisburg, Germany). Additionally, FPDs #34, 33, 44-47 were removed and the natural teeth abutments were prepared. Impression of the mandibular teeth abutments was taken using a polyether material (Impregum Penta Soft, 3M ESPE) and a master cast was made. After that, chairside temporary FPDs for the natural teeth abutments in the mandible were fabricated, using a self-curing composite material (Structur 2, VOCO, Cuxhaven, Germany). The dental technician fabricated: a) metal-reinforced long term provisional FPDs and b) final metal-ceramic FPDs (which were kept for later).

On the next day, the metal-reinforced temporary FPDs were fixed using a provisional cement (TempBond, Kerr, Bioggio, Switzerland) and both maxillary denture and DentDu were fitted and the occlusion was controlled (Fig. 11).

The analysis of the articulated casts showed large vertical distances between the occlusal plane and the maxillary alveolar crest: 1.7 cm in the left premolar/molar area, 1.4 cm in the right premolar/molar area, 1.5 cm in the anterior area (Fig. 12). Therefore, a removable restoration was suggested.

Six months after augmentation in the maxilla, the DentDu were used as planning templates for assigning the implant positions (Fig. 13). Six implants were placed and implant # 14 was also kept (Table 1, Fig. 14).

Four months after implant placement, the implants were recovered and system-specific healing caps were mounted. An open-tray impression was taken using a polyether material (Impregum Penta Soft, 3M ESPE) and the working cast was fabricated.

DentDu supported by the locator was used for recording the maxillo-mandibular relationship. A bite registration was taken with a resin (pattern resin®, GC, Alspir, IL, USA) and DentDu was placed on the cast and mounted in the articulator (Fig. 15).

Implant abutments were fabricated using system specific customisable abutments (PTIR, Dentegris, Duisburg, Germany) casted with a CoCrMo alloy (Ankatit Laser, Ankatit-Anka Guss, Waldaschaff, Germany) and served as primary telescopes. Electroformed gold copings (0.25 mm thick; AGC Galvanogold, Au>99.9%, Wieland Dental, Pforzheim, Germany) were also fabricated over the customised implant abutments. The DentDu, the customized abutments and the gold copings were used for scanning, creating and milling of a titan framework (Zenotec Ti, Wieland Dental, Pforzheim, Germany). For veneering of the framework, a micro-ceramic composite was used (Ceramage, SHOFU Dental, Ratingen, Germany).

After veneering, the abutments were mounted with 35 Ncm (Fig. 16). The electroformed copings were placed on the abutments (Fig. 17) and fixed in the super-construction using a self-curing cement (AGC Cem, Wieland Dental, Pforzheim, Germany).

sticky granules
bionic



easy-graft®
CRYSTAL

Ingenious: Simple handling and accelerated osteoconduction for long-term volume preservation.

SUNSTAR
GUIDOR®

Degradable Solutions AG
A Company of the Sunstar Group
Wagistrasse 23
CH-8952 Schlieren/Zurich
www.easy-graft.com

Fig. 11_Mandibular temporaries in situ and fitting of the denture duplicate.

Fig. 12_Planing casts mounted in the articulator.

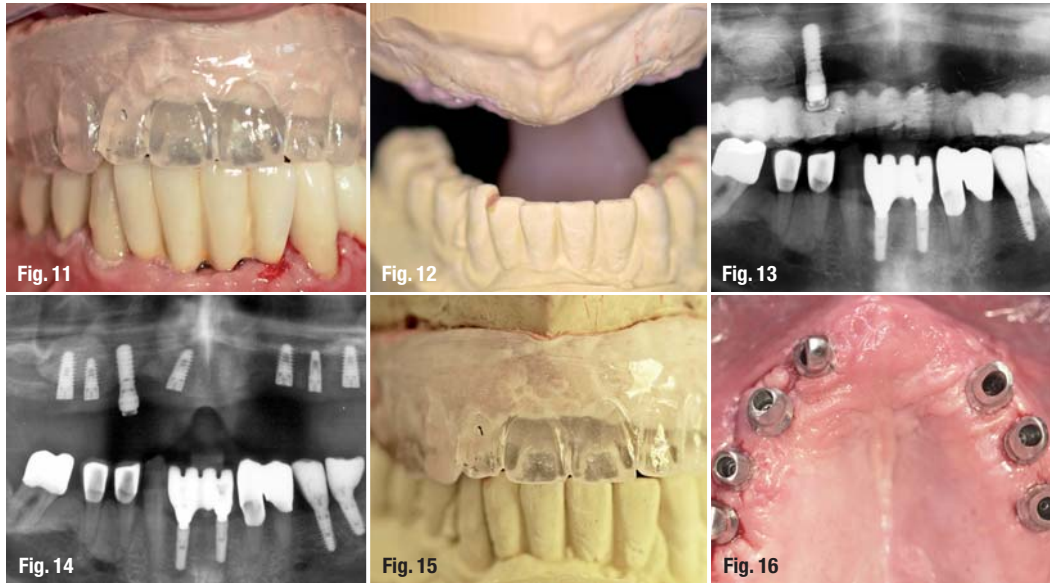
Fig. 13_Orthopantomograph.

Maxilla: after augmentation (sinus, periimplant defect), implant planing. Mandible: after regeneration surgery, temporary restoration.

Fig. 14_Maxilla: implant placement.

Fig. 15_Mounting of the casts using the denture duplicate.

Fig. 16_Customised abutments in situ.



At the same session, the final mandibular FPDs were fixed using an acrylic/urethane based temporary cement (Implant Provisional, Alvelogro Inc., Snoqualmie, WA, USA; Figs. 18–22).

Discussion

This case report details the treatment of a patient with insufficient maxillary alveolar ridge height caused by generalised advanced periodontal disease, as well as by subsequent implant treatment, insufficient implant-prosthetic restoration, failure of maintenance, and development of periimplantitis. A considerable distance between the occlusal plane of the mandible and alveolar ridge of the maxilla was caused by extensive bone resorption.

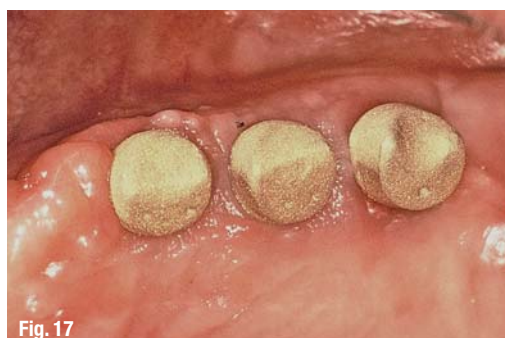Telescopic crowns have been used successfully to connect dentures to natural teeth for several decades. Recent clinical data have indicated that the use of telescopic crowns with implant-supported overdentures can lead to predictable long-term treatment outcomes.^{7–11} The patient's ability to remove the secondary structure also facilitates abutment hygiene, providing an additional peri-

odontal advantage for the telescopic crown system.^{2,11} Furthermore, the high retention achieved through friction force leads to good mastication and phonetics. Further advantages of treatment with telescopic crowns include (a) maximisation of masticatory-force transmission that are always axial to the abutments; (b) facilitation of effective oral hygiene; (c) ability to position teeth favourably; (d) avoidance of several soft- and hard-tissue augmentative surgeries; (e) achievement of favourable aesthetics, even with severe atrophy of the jawbone, which can be covered by the lip shield; (f) the ability to renew veneering at any time; and (g) stability of the restoration, even when an abutment implant is lost. The main disadvantages of this type of construction are cost and technical requirements, as well as possible psychological burdens experienced by the patient provided with a removable appliance.^{5,11}

The initially delivered denture allowed for the correction of the interocclusal relationship, tooth shape, colour, and angulation throughout the treatment period. In this way, the patient could become acclimated to the function and aesthetics of the denture. By using a duplicate of this denture to take the bite records and as a mounting guide, the maxillo-mandibular relationship was recorded and transferred accurately and the aesthetic outcome previously accepted by the patient was achieved. Thus, it was not necessary to repeat the usual clinical recordings (e.g., centric relation, occlusal vertical dimension, tooth position and aesthetics, wax try-in) at the time of final restoration fabrication.¹²

Additionally, the combined use of the DentDu and the silicon key allowed for the selection of im-

Fig. 17_AGCs fitting.



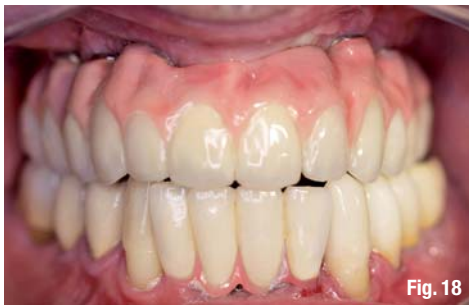

Fig. 18

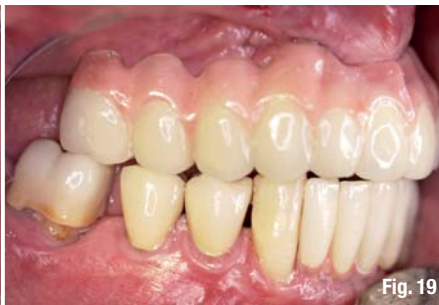

Fig. 19

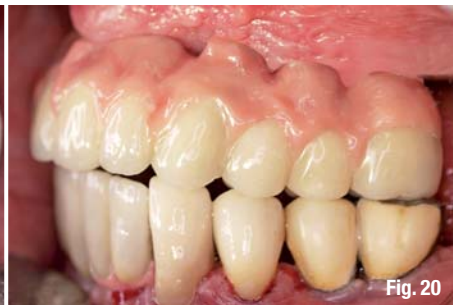

Fig. 20

plant abutments of optimal angulation and shape, and also facilitated the fabrication of an aesthetically pleasing implant-supported restoration.

In the case presented here, the customised abutments were not removed after mounting and torquing until the final restoration was fitted and placed. Thus, the position of the abutments remained unchanged, eliminating or minimising errors that might occur during repeated attachment of the abutments (for various test fittings of the restoration) to the implants and master cast. The fixation of the electroformed gold copings after and not before veneering eliminates additional errors which may occur due to the influence of the veneering composite during polymerization. In the present report, the patient wished for a fixed restoration of the maxilla. Based on the planning model, he accepted a telescopic construction. In the case of a fixed implant-based denture, the crown-to-root ratio would have been unfavourable had natural teeth been used to support the restoration.

To date, no long-term studies have documented the influence of the crown-to-root ratio on the success rate of implants fully. Researchers have postulated that an increase in crown-to-tooth and crown-to-implant ratios will cause an increase in the magnitude of non-axial forces transmitted to the tooth or implant. This, in turn, could cause increased vulnerability of either teeth or implant abutments and lead to the loss of

supporting bone around the implants (Gomez-Polo et al. 2010). The existing data does not allow any definitive conclusions to be drawn.

In the present case, the patient's hard and soft tissues could have been augmented surgically to provide an aesthetically and functionally acceptable rehabilitation using fixed restorations. Cases such as this raise the question of whether it is preferable to exhaust all surgical possibilities or to pursue the path of least resistance by combining classic prosthetic experience with modern techniques and materials. In many circumstances, the latter is a better and safer treatment alternative. For this reason, oral surgeons and periodontists should consider the prosthodontic treatment plan extremely carefully before selecting any course of action.

Editorial note: A complete list of references is available from the publisher.

Fig. 18_Final restoration. Frontal view.
Fig. 19_Final restoration. Right view.
Fig. 20_Final restoration. Left view.

_contact

implants

Prof Dr Dr habil Gregory-George Zafiropoulos

Sternstr. 61, 40479 Düsseldorf, Germany

zafiropoulos@prof-zafiropoulos.de

www.prof-zafiropoulos.de

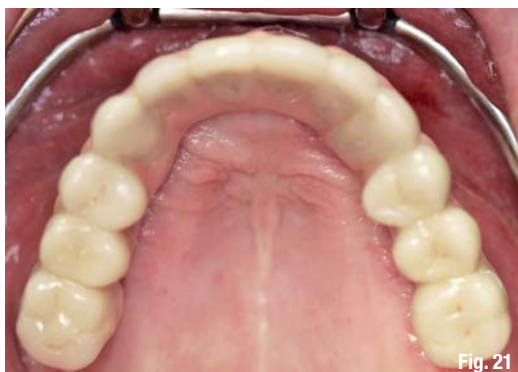

Fig. 21

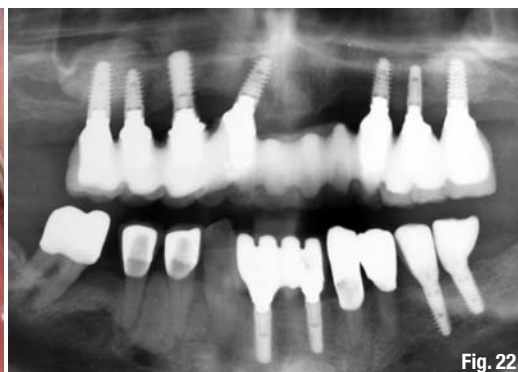

Fig. 22

Fig. 21_Final restoration. Palatal view.
Fig. 22_Final restoration. Orthopantomogram.

CAD/CAM patient-specific abutments and a new implant design

Authors_Prof Dr Frank Liebaug & Dr Ning Wu, Germany

Introduction

The objective of any dental reconstruction is the natural, functional reconstruction of the stomatognathic system and the functionally unimpaired or functionally treated masticatory organ. This objective can only be achieved if individual patient parameters and distinctive anatomical features are incorporated into surgical planning and the subsequent prosthetic restoration.

Implant-prosthetic care methods must be established as independent therapy alternatives for specialists and patients, and the possibility of achieving this objective is high. With attention focused on the prosthetic functional aspects of implantology, the prosthetic therapy objective is currently becoming the focal point of all efforts.

From the point of view of the practising dentist, the main emphasis in treatment planning for implant-supported dentures is placed on the prosthetic specialist. If said specialist is also trained in implants and surgery, he will place the implant him-

self as a support measure for his prosthetic therapy, which results in great simplification with regard to planning and the treatment process. As a rule, however, a dentist who deals with prosthetics will complete his implant prosthesis in close collaboration with an oral surgeon or oral-maxillofacial surgeon.

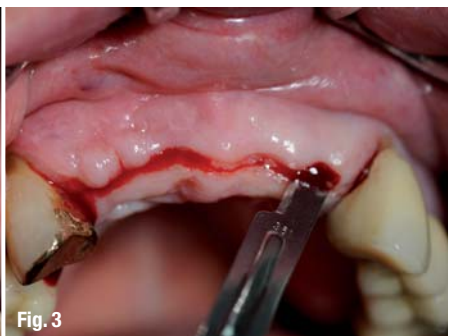
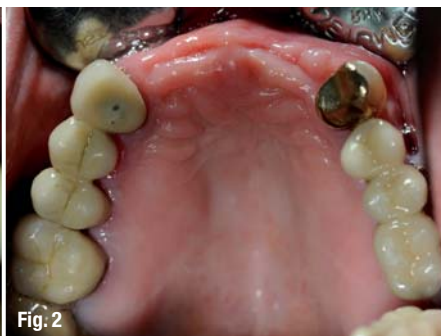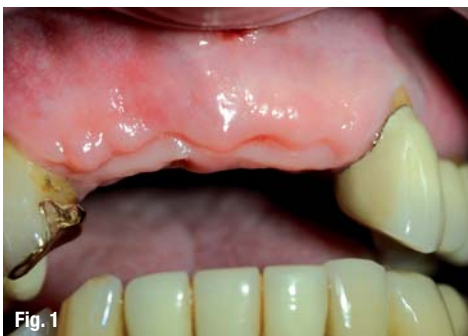While surgeons are concerned with the best possible implant procedure or implant design, prosthetic specialists bring us back to the starting point of implantology: the patient's wishes. Patients do not want implants; rather they want beautiful new teeth with which they feel confident in day-to-day life.¹

Team-work is gaining increasing importance in this regard, since, depending on the functional prosthetic objective, prosthetic specialists, dental technicians and implant surgeons might have to work together on the optimal implementation of the planned results using navigation and CAD/CAM systems. In the future, this method of integrating implantology will be found in just about every practice. As the hardware for 3-D planning is currently very

Fig. 1 Maxillary anterior gap in regions 12, 11, 21 and 22 (Kennedy Class IV), four months after implant insertion.

Fig. 2 Occlusal view of the maxilla with an interdental gap between teeth #13 and 23.

Fig. 3 Implant exposure four months post-op.



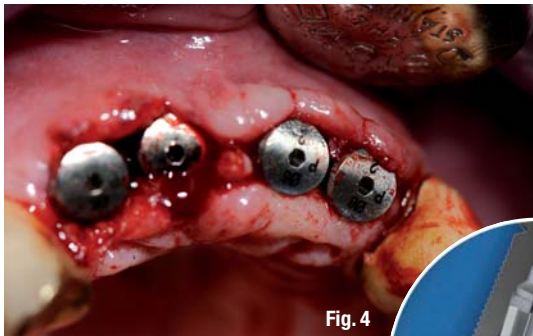


Fig. 4

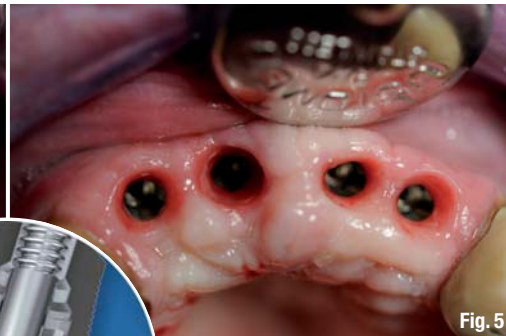

Fig. 5

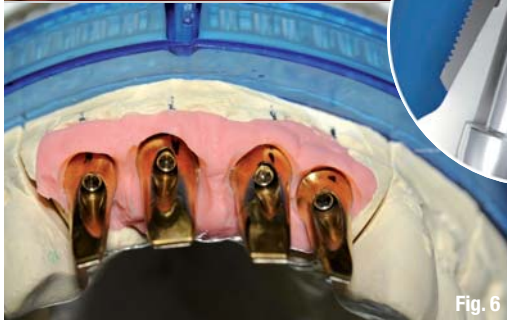

Fig. 6

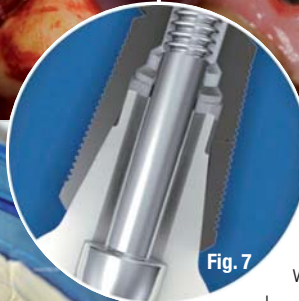

Fig. 7

Fig. 4_ Condition immediately after the healing abutments were placed (height of 2 mm).
Fig. 5_ Three weeks of good healing and moulding of the peri-implant soft tissue.
Fig. 6_ Schematic depiction of the Conical Seal Design for a custom-fitted conical connection between the implant and abutment.
Fig. 7_ Abutments on the master cast with the gingival mask.

tures using the CNC (computer numerical control) procedure began more than ten years ago. Attempts with this kind of CAD/CAM technology demonstrated that the achievable precision of current constructions—between 20 and 30 μm —is better than the precision of fit achieved with cast precious metal structures.³

expensive, dentists should seek suitable partners to support them in the integration of current therapy options.

Furthermore, from a biological and an economic perspective, production should rely on the most biologically compatible material with sufficient mechanical stability, for example titanium and cobalt-chromium alloys. Zirconium oxide is also an option. However, in terms of casting engineering, the processing of these alternative materials does not offer sufficient precision of fit. Cast implant structures manufactured from non-precious metals have been found to exhibit gaps with an average width of 200 to 230 μm between the superstructure and the implant abutment.² In contrast, cast structures manufactured from precious metal alloys have been found to have gaps with an average width of 40 to 50 μm .³ The use of alternative materials thus requires the use of alternative production technologies, if only to obtain the required precision.

Ideally, a superstructure is milled from an industrially prefabricated solid material in order to eliminate inhomogeneities safely. Following this line of thought, milling-based manufacture of superstruc-

With modern scanning and software technology, this production principle has been extended to the area of virtual construction. Thus, the CNC milling procedure, which has been used for years, is supplemented with the possibility of a purely virtual construction. This technology is now offered by various manufacturers.

_Objective

Our objective as specialists must not only be the replacement of a lost tooth as soon as possible after extraction, but also be the satisfaction of our patients' constantly increasing aesthetic demands—with regard to the anterior tooth area in particular—through suitable bone and soft-tissue management.

Thus, even when the implant is being inserted, preference must be given to keeping the crestal bone structure as unchanged as possible because in this way the interdental papilla and the peri-implant gingiva can be maintained in the long term.⁴

_Case presentation

The realisation of the patient's wish was facilitated in the following case in close collaboration

Fig. 8_ Virtual 3-D model for abutment planning below the subsequent crowns.
Fig. 9_ Virtual 3-D model for patient-specific abutment planning.
Fig. 10_ Occlusal view of the abutment and adjustment thereof.

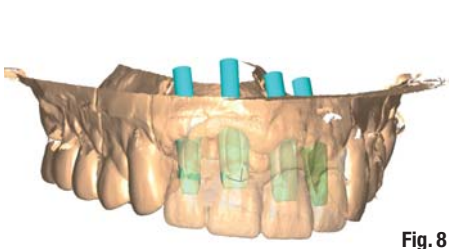


Fig. 8

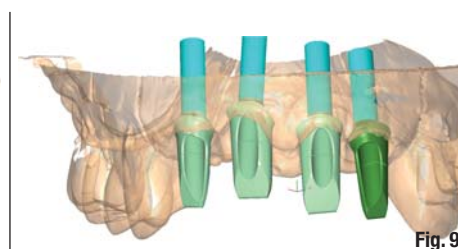


Fig. 9

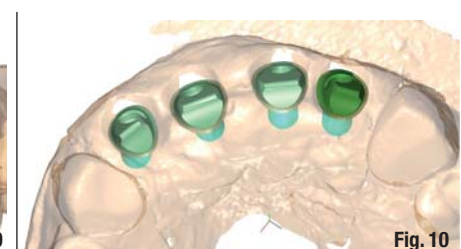

Fig. 10



Fig. 11 Patient-specific abutment prior to insertion.

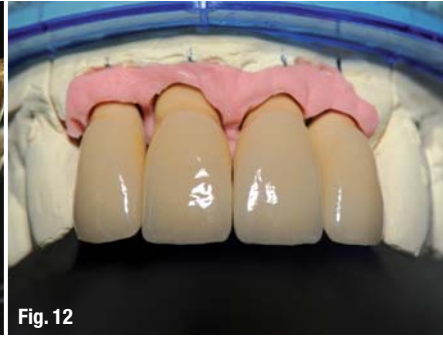

Fig. 12 Complete individualised crown restoration on master cast.

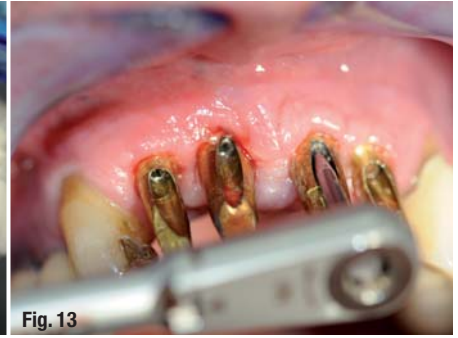

Fig. 13 Abutment insertion and mounting with a torque wrench at 25 Ncm.

Fig. 11 Patient-specific abutment prior to insertion.

Fig. 12 Complete individualised crown restoration on master cast.

Fig. 13 Abutment insertion and mounting with a torque wrench at 25 Ncm.

with Zahntechnik Zentrum Eisenach after the tooth replacement was firmly in place, despite alveolar bone loss and difficult gingival conditions (Figs. 1 & 2). The surgical procedure for this case is described in Liebaug and Wu (2011).⁵

The anatomically formed and bevelled OsseoSpeed TX Profile implants (DENTSPLY Implants) were used in regions #12, 11, 21 and 22. These implants are specially designed to preserve the marginal bone in an alveolar ridge with angular atrophy both vestibularly and orally, that is, 360 degrees around the implant.⁶ Restoration with patient-specific ATLANTIS abutments (DENTSPLY Implants) was planned in order to complete prosthetic restoration optimally after successful implantation and osseointegration. As described in Noelken (2011),⁷ the marginal bone can be preserved cheaply by the use of these implants, which are new to the dental market. Optimal soft-tissue support can be achieved with individualised manufactured abutments.

Challenge in terms of maxillary anterior tooth loss

While replacing a missing tooth with an implant can now be considered routine, rehabilitation in the maxillary anterior region still represents a particular challenge for the treatment team. In addition to successful osseointegration of the implant, particular attention must be given to functional and aesthetic parameters to achieve a restoration that perfectly harmonises with natural teeth.⁸

Prior to surgery: Addressing the patient's wishes and providing information

The patient's wishes must always be considered before treatment begins. The patient should be offered clarification prior to treatment, particularly in difficult initial situations with evident hard-tissue loss and unfavourable gingival conditions. For forensic reasons, photographic documentation of the initial situation is an indispensable aid in addition to diagnostic casts. It should also be used as the basis for discussion with the patient.

If bone on the labial side has already been lost and the optimal bone contours have not been restored with a bone transplant, achieving the desired aesthetic result is nevertheless often not difficult.

In terms of this 67-year-old patient, the implants were exposed by incision to the middle of the alveolar ridge from regions #12, 11, 21 and 22 after a four-month healing phase (Fig. 3).

It should be noted that, owing to the bevelled design of the implants used, an almost seamless insertion into the natural osseous alveolar process is achieved, and thus the plastic cover and the primary wound closure are simplified for the surgeon. This is also the basis for a quick and smooth healing process.

Three-dimensional bone structures can be preserved using the above-mentioned OsseoSpeed TX

Fig. 14 Occlusal view of the inserted abutment.

Fig. 15 Closing of the screw opening with Cavit (3M ESPE) prior to cementing the superstructure.

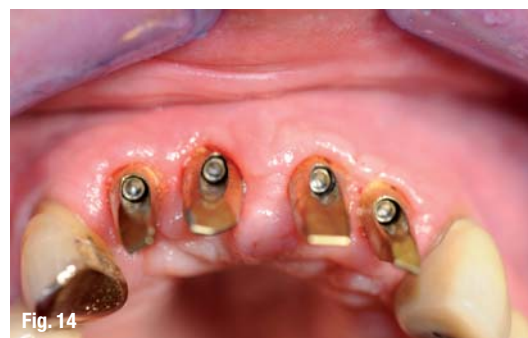

Fig. 14

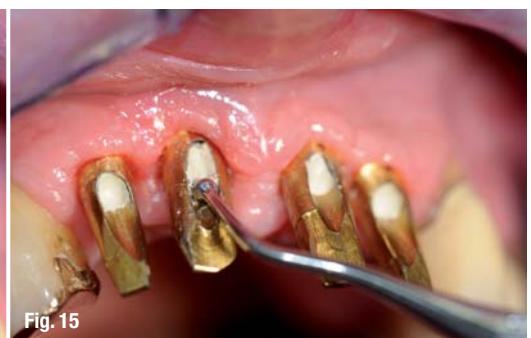

Fig. 15

Profile implant. Healthy bone is a prerequisite for optimal prosthetic restoration with regard to aesthetics. The otherwise often necessary hard- and soft-tissue transplants can now mostly be avoided.⁵

The extent to which a temporary restoration can be screwed together after prosthetic pretreatment and after the implant region has been moulded, or whether a removable device can be used temporarily, depends significantly on the patient's financial resources. In addition to the use of gingiva formers native to the system, temporary restorations aid the moulding, preparation and stabilisation of the peri-implant soft tissue during and after the healing phase. As the interim prosthesis guaranteed functionality and aesthetics that satisfied the patient, additional moulding of the soft tissue was achieved through special gingiva formers or healing abutments (Figs. 4 & 5).

The results obtained in terms of preservation of the marginal bone using the AS-TRA TECH Implant System (DENTSPLY Implants) are documented in Palmer et al. (2000) and Wennström et al. (2005).^{9, 10} Preservation of the marginal bone level and healthy soft tissue are indispensable for the long-term success of implant treatment both clinically and aesthetically. The bone provides the soft tissue with stability, while the soft tissue protects the bone from micro-organisms.

A special feature of the implant system used is the patented Conical Seal Design, which prevents micro-movements and micro-gaps at the interface between the implant and abutment, reliably protecting the implant and bone from bacteria. The clinical relevance of the pump effect caused by micro-movement and possible crestal bone resorption were experimentally tested by Zipprich et al. (2007).¹¹ Furthermore, arising stress is distributed farther into the bone and peak loads are simultaneously reduced.^{12, 13} In this regard, the preference for preserving the marginal bone level must be clarified as well. The implant-abutment connection is thus reliably sealed against bacteria and the bone is thereby protected from external influences. Maintenance of the superstructure is also made easier for the patient.

The integration of the abutment is simplified by the conical implant-abutment connection (Fig. 6). However, with regard to the bevelled OsseoSpeed TX Profile implants, particular attention must be given to the precise transfer of the clinical situation to the model being manufactured using moulding aids and transfer posts during precision moulding, which requires specific experience and a good instinct.

The individualised ATLANTIS abutments are a good solution for cemented crowns or bridges, as they guarantee optimal functionality, are the basis for sophisticated prostheses and are easy to use.

ATLANTIS abutments fabricated from titanium, titanium nitride-coated titanium (ATLANTIS GoldHue) or zirconium oxide are available for all established implant systems. All abutments are supplied by the manufacturer with the corresponding abutment screws. The ATLANTISVAD (virtual abutment design) software allows the production of abutments that are based on the final tooth form and thus guarantees not only a natural, aesthetic result but also optimal functionality. A model was produced from the impression following healing, implant exposure (Fig. 3) and insertion of temporary gingiva formers (Fig. 4).

The master cast should have a stable removable gingival mask made of silicone (Fig. 7). Casts should be placed onto articulators before the dentist or dental laboratory sends them in to Astra Tech so they can subsequently be sent with the ATLANTIS CaseSafe shipping box. The models can be converted into a virtual image using a 3-D scanner after the model has been produced in a high-tech dental lab-

Live, Interactive Webinars and On Demand Courses

A growing education platform where you can find more than 400 dental courses, live Webinars, live Education Symposia.

Interested in C.E. credits and quality learning?

Learn from the experts:

Richard Niederman	Marius Steigmann
Louis Malcmacher	David Hoexter
Eduardo Mahn	Dwayne Karateew
Robert Horowitz	Fotinos S. Panagakos
Paul Weigl	George Freedman
Shamshudin Kherani	Howard S. Glazer
Christian Coachman	Lynn Mortilla
Ron Kaminer	Maria Emanuel Ryan
Edgar Garcia Hurtado	Michael Glick
Glenn van As	Peter Barry
Marc Gottlieb	Barry Levin
John Fluke	Fay Goldstep

Interested in sponsoring education?

Some of our partners:



Register for FREE on www.DTStudyClub.com

How to receive your C.E. Credits?

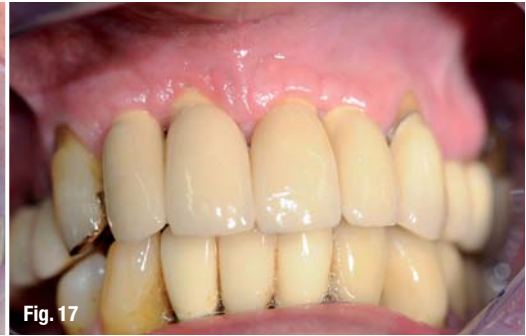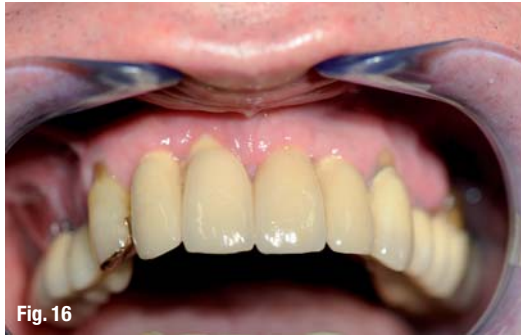1. Go to www.DTStudyClub.com and log in.
2. Not a member yet? Register for a free account.
3. Find the courses you're interested in and register to access them.
4. Watch the course.
5. Take the Quiz and print the C.E. certificate.

ADA CERP® | Continuing Education Recognition Program

ADA CERP is a service of the American Dental Association to assist dental professionals in identifying quality providers of continuing dental education. ADA CERP does not approve or endorse individual courses or instructors, nor does it imply acceptance of credit hours by boards of dentistry.

Fig. 16 Condition immediately after placement of the individualised crown restoration.

Fig. 17 Despite difficult soft-tissue conditions, a good gingival stippling effect was achieved in the cervical area, which attests to sufficient osseous support.



oratory or after the model has been sent, should no scanner be available immediately (Figs. 8–10).

After the specialist has confirmed the virtual abutment design, which is sent via e-mail, the ATLANTIS abutment is manufactured, verified and sent to the attending dentist (Figs. 7 & 11). Individualised prostheses can be manufactured in the dental laboratory after the precision of fit and the position of the patient-specific abutment have been verified (Fig. 12).

It must always be ensured that the abutment screw delivered with the abutment is used for the final insertion of the abutment in the mouth. The ATLANTIS abutments are designed to correspond to the form of the dentine core of natural teeth. Of course, the ATLANTIS VAD software allows for consideration of the specialist's preferences, which should take the patient situation into account, with regard to the production of the individualised abutment. The size of the abutment is determined by the average profile created by the form and size of the healing or temporary abutment.

The mucosa may be temporarily anaemic when the abutment is inserted into the patient's mouth (Figs. 13–15). ATLANTIS abutments are manufactured with standard gingival moulding if the specialist does not select or provide any particular options when the order is placed.

Considering the extremely unpromising initial situation (Figs. 1 & 2), a result that was satisfying in terms of functionality and aesthetics for both the patient and the dental/prosthetic specialist was achieved after the individualised crown restoration had been placed (Figs. 16 & 17).

The patient's wish for stable and natural-looking teeth was fully satisfied, which was ultimately the main criterion and motivation for our efforts as the treating team. Additional improvement of the soft-tissue situation is expected if the patient adheres to the appropriate cleaning technique.

Conclusion

Implantology is a central component of modern therapy procedures in dentistry. Continuous development of materials, implant design and the relevant technologies seeks to obtain high reliability with a good long-term prognosis for a wide range of indications. Careful diagnosis and detailed planning are indispensable if patients' increasing demands are to be satisfied. In particular, care in aesthetically demanding clinical situations requires interdisciplinary treatment in many cases. The possibilities presented by this case report for the production of patient-specific abutments on anatomically formed and bevelled OsseoSpeed TX Profile implants constitute a gain and are the basis for long-term success, even in the event of reduced bone and difficult soft-tissue conditions.

Acknowledgement

The authors would like to thank Z.T.M. Blum from the Zahntechnik Zentrum Eisenach for his collaboration and laboratory work, as well as Franzisko Fischer from Astra Tech for his support during planning. Finally, we would like to offer special thanks to my father, Manfred Liebaug, who supported us throughout, from surgery to prosthetic placement, as well as while exploring new methods.

contact

implants

Prof Dr Frank Liebaug

Praxis für Laserzahnheilkunde und Implantologie
Arzbergstr. 30
98587 Steinbach-Hallenberg
Germany

Tel.: +49 36847 31788

frankliebaug@hotmail.com

Under the Patronage of
H. H. Sheikh Hamdan Bin Rashid Al Maktoum
Deputy Ruler of Dubai, Minister of Finance
President of the Dubai Health Authority

تحت رعاية
سمو الشيخ حمدان بن راشد آل مكتوم
نائب حاكم دبي، وزير المالية
رئيس هيئة الصحة بدبي



UAE INTERNATIONAL DENTAL CONFERENCE & ARAB DENTAL EXHIBITION

5 - 7 February, 2013

Dubai International Convention & Exhibition Centre

Delivering Science & Technology

www.aeedc.com

- Excellent platform to network with over **28,000** dental professionals and oral health care providers.
- More than **900** exhibitors from **80** representing countries.
- **3 days** of quality education and business opportunities.



Find AEEDC Dubai on

BlackBerry
PIN: 286FC1C7



twitter



facebook



LinkedIn



YouTube



Organised by



In Cooperation with



Strategic Partner



Supported by

ADA CERP Continuing Education
Recognition Program

INDEX Conferences & Exhibitions Organisation Est is an ADA CERP Recognized Provider.
ADA CERP is a service of the American Dental Association to assist dental professionals in identifying quality providers of continuing dental education. ADA CERP does not approve or endorse individual courses or instructors, nor does it imply acceptance of credit hours by boards of dentistry.
INDEX Conferences & Exhibitions Organisation Est. designates this activity for continuing education credits on an hour for hour basis.

INDEX® Conferences & Exhibitions Organisation Est.

Dubai Healthcare City, Ibn Sina Medical Complex #27, Block B, Office 203 | P.O. Box: 13636, Dubai, United Arab Emirates
Tel: +971 4 3624717, Fax: +971 4 3624718 | E-mail: info@aeedc.com, Website: www.index.ae

The early abutment technique

Author_Dr S. Marcus Beschmidt, Germany

Information on patient and treatment

The female patient was 40 years old at the beginning of the treatment. The high smile line and the thin gingival phenotype significantly complicated the case. Tooth 11 and tooth 12 had grayish crowns and livid gums. The roots of both of the two teeth had been treated, before a metal pin had been inserted in tooth 11 alio loco. An apicoectomy had also been conducted on tooth 12, which had left scarring with partial retraction of the gingiva. The apicoectomy was not fully healed when the medical history was taken, and the root canal filling at tooth 12 appeared too short apically.

Tooth 11 had to be atraumatically removed, and we decided in favor of an immediate implant placement followed by a temporary restoration using a temporary shell crown. An impression was taken during the procedure with the "early abutment technique" to allow the implant position to be transferred to the master cast for early manufacture of the final abutment.

After regenerative measures for rebuilding hard and soft tissue by the pouch technique and delivery of the long-term temporary denture, the patient was discharged. The final abutments were placed only two days later and were not unscrewed, again. This was the only way of establishing a thick periimplant soft-tissue collar and minimizing the soft-tissue retrac-

tion. The final full-ceramic crown was placed twelve months later.

Initial situation

The patient had a smile line level with and above the cervix. The line of the gingiva and upper lip appeared irregular (Fig. 1). Incipient papilla loss could be seen in regions 11 to 13. The gum showed scarring as a result of a previous apicoectomy. The crowns appeared gray. The gingiva had a livid discoloration, where the dark root stumps showed through because of the thin phenotype (Fig. 2). The crowding of teeth 11 and 12 and the convoluted dentition made the situation implantologically and esthetically difficult (Fig. 3).

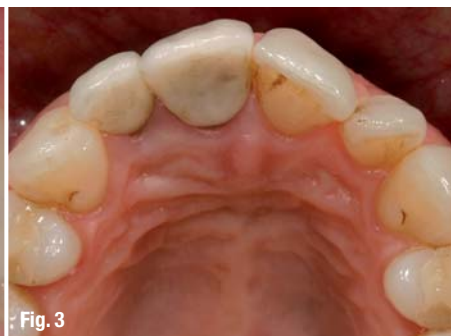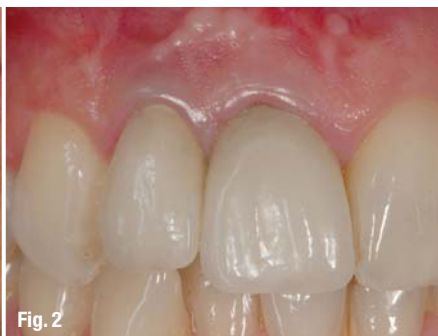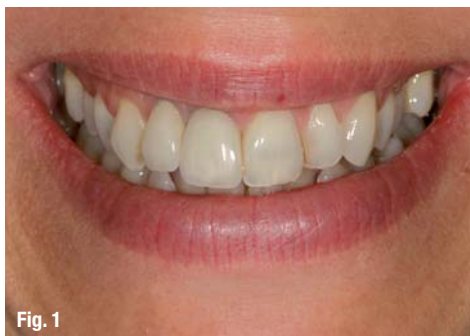Atraumatic removal of the residual root

A metal pin placed alio loco was visible at tooth 11. The apicoectomy had not yet healed. The root canal filling at tooth 12 appeared too short at the apex (Fig. 4). To remove tooth 11, a computer-controlled injector (The Wand, Milestone) was used for a palatal injection. This protects the scarred tissue almost completely and does not affect the blood supply (Fig. 5). Atraumatic removal of the residual root 11 followed. The inflamed tissue was completely scraped out (Fig. 6).

Fig. 1 Initial situation: smile line level, line of the gingiva and upper lip.

Fig. 2 Scarring of the gum as a result of a previous apicoectomy.

Fig. 3 Crowding of teeth 11 and 12, convoluted dentition.



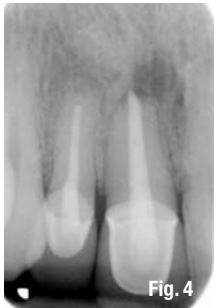

Fig. 4

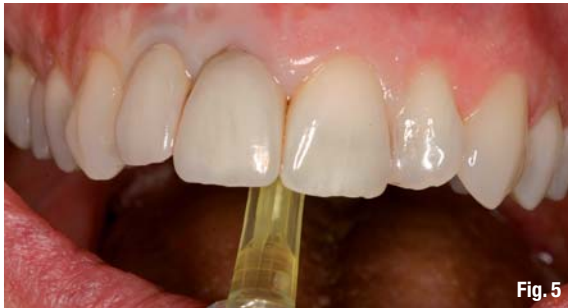

Fig. 5

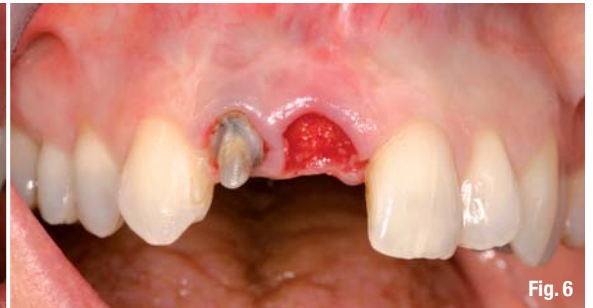

Fig. 6

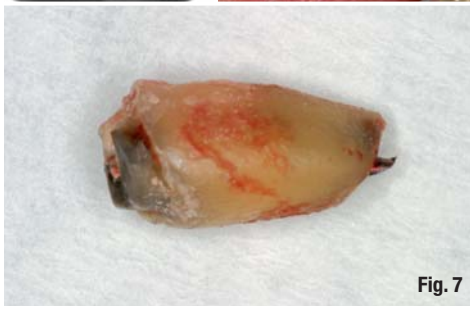

Fig. 7

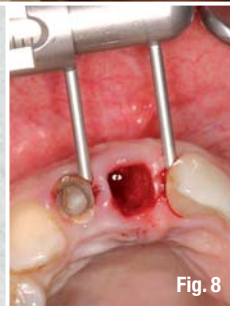


Fig. 8

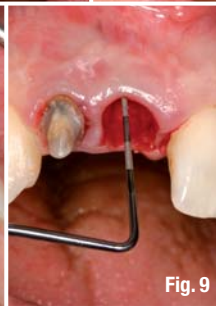

Fig. 9

Fig. 4 Metal pin placed alio loco visible at tooth 11.

Fig. 5 Palatal injection via computer-controlled injector (The Wand, Milestone).

Fig. 6 Atraumatic removal of the residual root 11.

Fig. 7 Metal pin on the apex of the removed root.

Fig. 8 Measuring of the implant diameter with a vernier caliper (Zepf Medizintechnik).

Fig. 9 Probing of the alveolar cavity with the periodontal probe.

Fig. 10 Insertion of the form drill into the alveolar cavity.

Fig. 11 Insertion of a CAMLOG® Screw-Line Promote® implant.

Fig. 12 Impression-taking.

Fig. 13 Details of the impression.

Fig. 14 Relining of a temporary shell crown on a titanium abutment.

Fig. 15 Positioning of the temporary shell crown via insertion key.

Fig. 16 Filling of the labial gap with a non-resorbable bone replacement material.

Fig. 17 Compression of the soft tissue with a free subepithelial connective tissue graft.

Fig. 18 Connective tissue graft in situ.

Fig. 19 Cementation of the trimmed provisional crown.

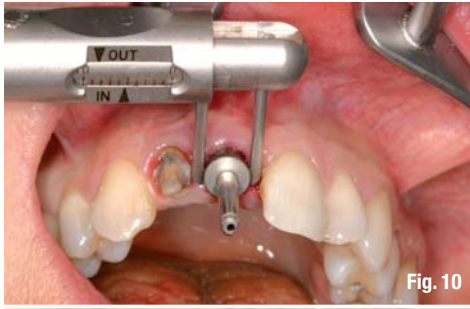

Fig. 10

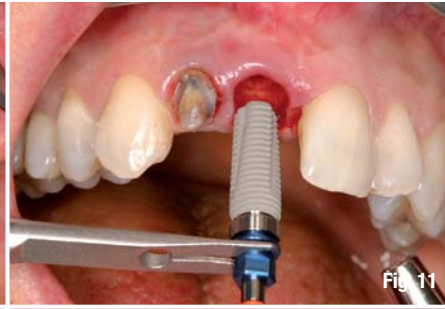

Fig. 11

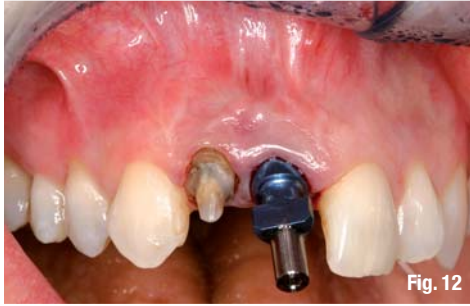

Fig. 12

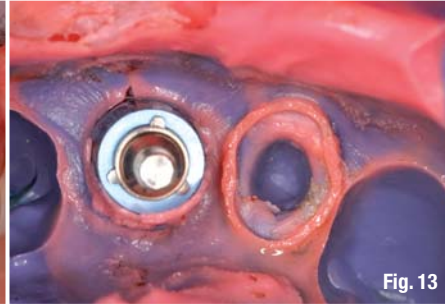


Fig. 13

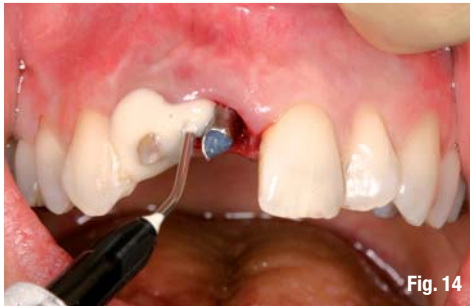


Fig. 14

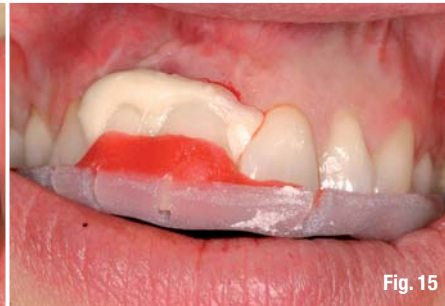

Fig. 15

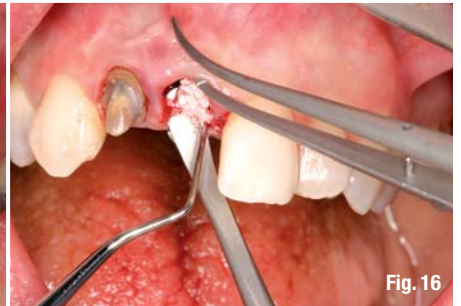

Fig. 16

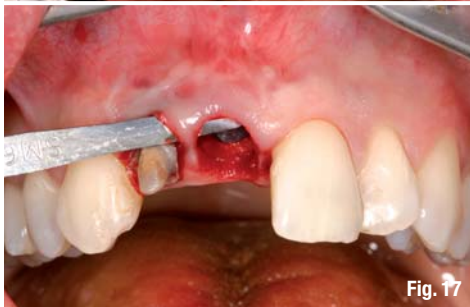

Fig. 17

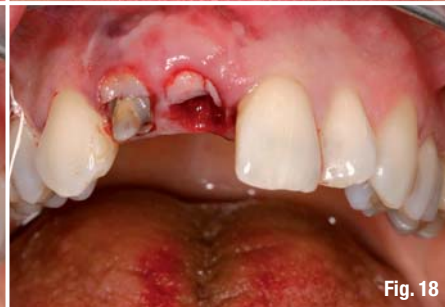

Fig. 18

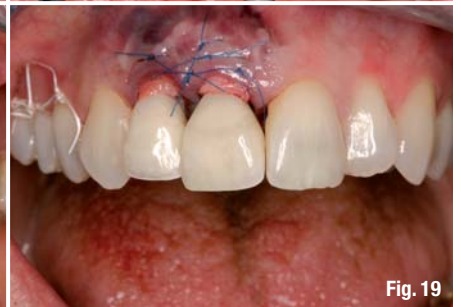

Fig. 19

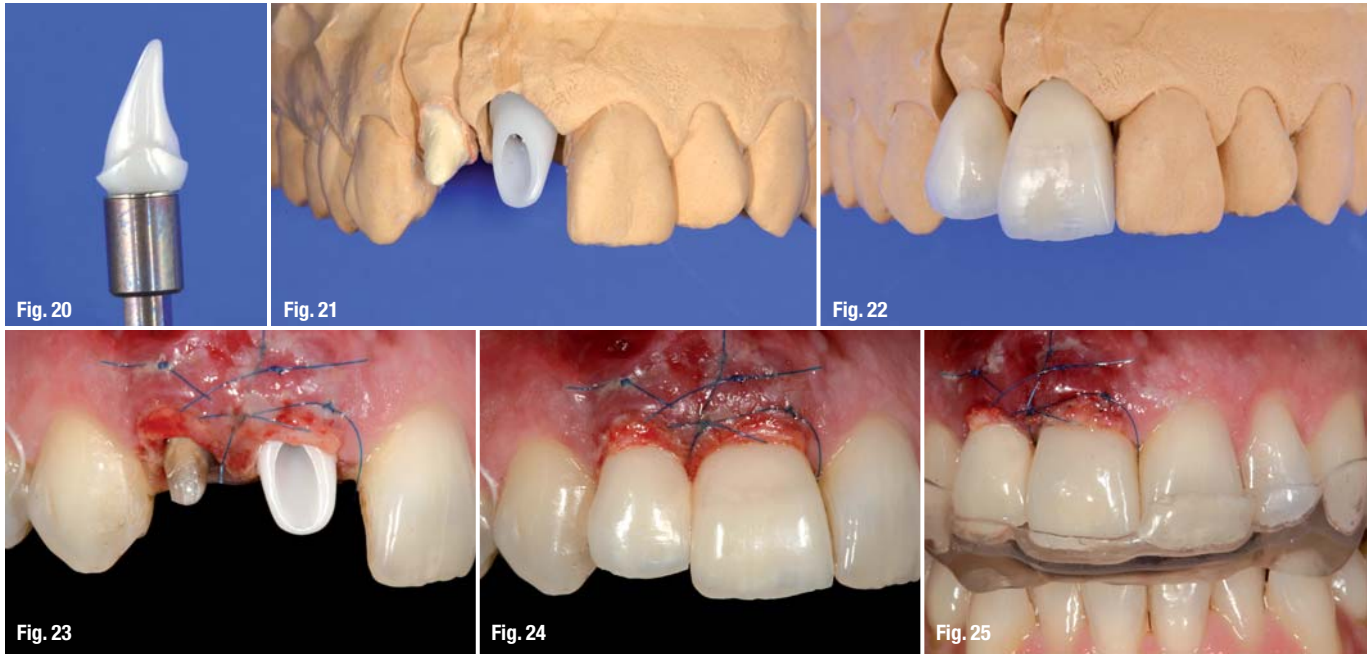


Fig. 20_Ceramic abutment cemented to a titanium base.

Fig. 21_Definitive screw-retained abutment on the lab analog.

Fig. 22_Splinting of the long-term temporary crown in region 11 with the crown on the natural stump.

Fig. 23_Two days post-op.

Fig. 24_Fixed long-term temporary crown.

Fig. 25_Michigan splint to protect the surgical site from pressure.

_Implant placement

The metal pin was clearly visible on the apex of the removed root (Fig. 7). Accurate measurement of the alveolar cavity is essential with immediate implant placement. This is the only way to find out where the bone is and whether it is intact. The implant diameter was measured with a vernier caliper (Zepf Medizintechnik, Fig. 8). The alveolar cavity was also probed with the periodontal probe to detect any defects on the alveolar margin. The gingival height was analyzed as well in order to allow an estimate of future resorption (Fig. 9).

_Impression and temporary abutment

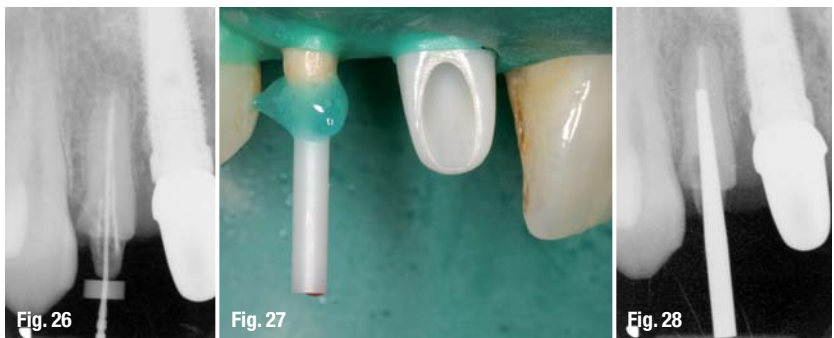The planned implant axis and the distances to neighboring structures can be checked with the form drill inserted into the alveolar cavity (Fig. 10). Figure 11 shows the insertion of a CAMLOG® SCREW-LINE Promote® implant 5 mm in diameter and 16 mm long. Impression-taking with an impression post and open tray followed for fabrication of the "early abutment" and long-term tempo-

rary crown (Fig. 12). Fig. 13 gives the details of the impression for precise transfer of the implant position to the master cast. The temporary shell crown was relined on an intraorally marked and laboratory-customized titanium abutment. In low heights, titanium with its greater stability is more suitable than PEEK (Fig. 14). The temporary shell crown was positioned with the aid of an insertion key (Fig. 15). The labial gap between implant and alveolar cavity should be filled with a non-resorbable bone replacement material for bone and soft-tissue regeneration (Fig. 16). The soft tissue was compressed with a free subepithelial connective tissue graft. A pouch was prepared without vertical incision and without injuring the papillae (Fig. 17).

_Early abutment and long-term temporary denture

Figure 18 shows the connective tissue graft in situ; it is important to keep the papillae intact. In the meantime, the provisional crown was trimmed in the laboratory; it can be cemented in after screwing in the titanium abutment (Fig. 19). A ceramic abutment cemented to a titanium base was fabricated within two days. The zirconium-oxide-ceramic has a smaller diameter for platform switching (Fig. 20). Figure 21 depicts the definitive screw-retained abutment on the lab analog.

The long-term temporary crown in region 11 was splinted with the crown on the natural stump (Fig. 22). Two days post-op, the temporary titanium abutment was replaced with the definitive ceramic abutment (Fig. 23) and the long-term temporary



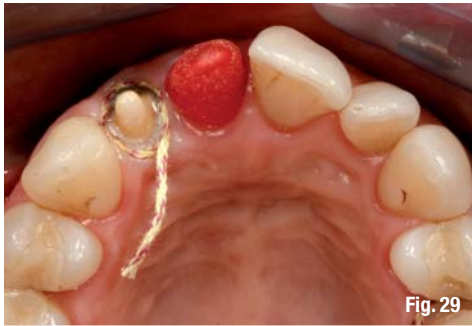

Fig. 29

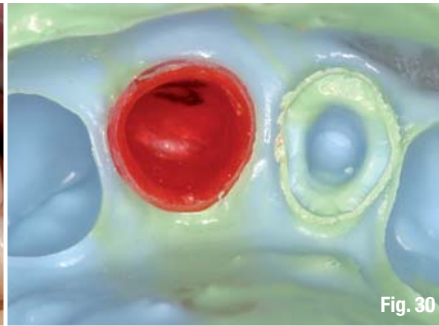

Fig. 30

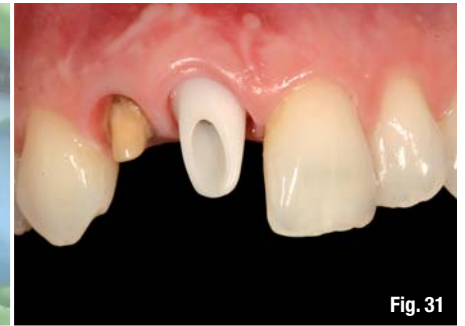

Fig. 31

crown was fixed (Fig. 24). It will remain in situ for at least six months, in this case, even for twelve months.

_Additional measures

A Michigan splint protects the surgical site from pressure. It should be worn for eating and sleeping for at least four weeks. Figure 26: The root-canal treatment in region 12 was revised. After revision of the root-canal treatment and internal bleaching, a ceramic pin was fitted into the root canal and cemented in (Fig. 27). Figure 28 gives the results of the X-ray examination of the inserted ceramic pin. In addition, impression-taking of the definitive abutment was conducted and the natural post for manufacture of the definitive full ceramic restoration was placed (Fig. 29). Figure 30: The position of the abutment was transferred to the master case with the aid of a plastic coping. Figure 31 shows the situation twelve months after implant placement: The tissue has matured and the gingival recession was minimal. Also, the definitive full-ceramic crowns were placed; the dentition was compensated to the contralateral teeth (Fig. 32). Care was taken not to crush the papillae between 11 and 21. Figures 33–35 give the results one year, two and five years after loading.

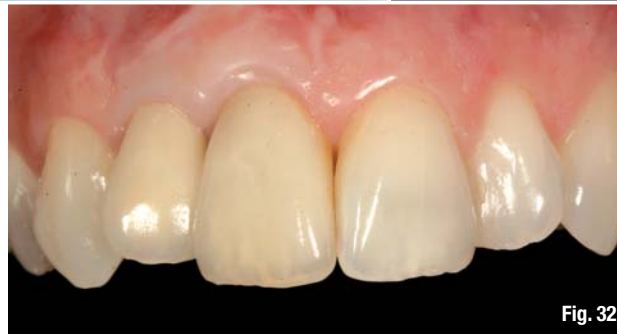

Fig. 32

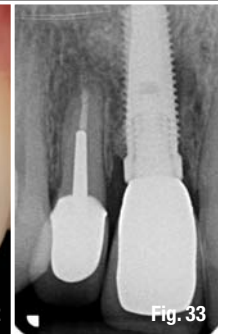


Fig. 33

crossurgery: few vertical incisions, minimal incisions, checking the bone and soft-tissue situation by probing. The healing phase should last at least six to nine months to allow the tissue to mature. In our experience, platform switching is also required after formation of the soft tissue, because the soft tissue has more space with this technique. The combination of techniques described here offers a way of increasing the probability of optimum tissue retention with the right indications.

Fig. 29 Impression-taking of the definitive abutment and the natural post.

Fig. 30 Transfer of the abutment position to the master case.

Fig. 31 Twelve months post-op. **Fig. 32** Twelve months post op: placement of the definitive full-ceramic crowns.

Fig. 33 X-ray one year after loading.

_Conclusion

In esthetically high-risk cases (high smile line, thin gingiva, prior operations), it is important to carry out all required measures in only one surgical procedure, if possible at all: atraumatic tooth extraction, scar correction, gingiva thickening, implant placement and possibly bone grafting. In this case, a partial socket preservation was conducted. Using the "early abutment technique" after two days –during the healing phase–the definitive ceramic abutment was placed and left in situ. As a result, the wound adhered to the abutment, and there was a tissue adhesion in the implant shoulder region.

This procedure has been in use in our practice since 2002 and has proven successful. A decisive factor is the application of minimally invasive mi-

_contact	implants
<p>Dr S. Marcus Beschnidt Privatpraxis für Zahnheilkunde Lichtentaler Allee 1 76530 Baden-Baden, Germany Tel: +49 7221 3939719</p> <p>info@beschnidt.com www.beschnidt.com</p>	

Fig. 34 Two years after immediate implant placement.

Fig. 35 Five years after loading.

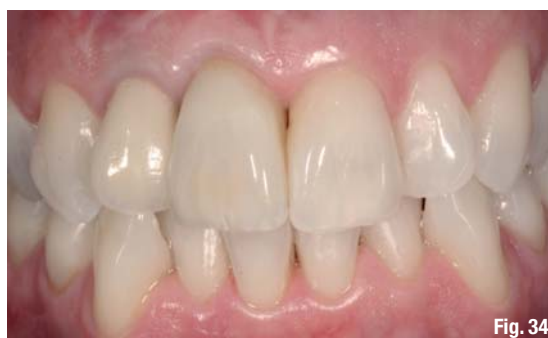

Fig. 34

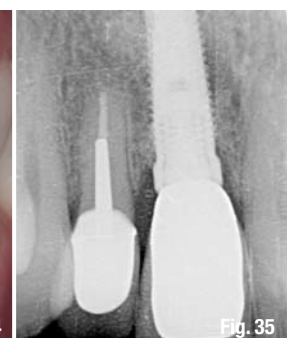

Fig. 35

Manufacturer News

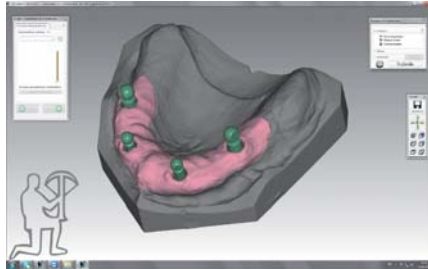
Schütz Dental

Individual implant-supported restorations

The new Tizian scan abutments and adhesive basis for the Schütz Dental implant product lines Dual Surface, Micro Retention and Cylindrical provide the opportunity to acquire new customers.

A scan abutment serves to determine the exact position (height and angle) of an implant in the model or in the jaw. The precise position is displayed virtually by matching the data. It is thereby defined exactly for the preparation of the supraconstruction. The special shape of the scan abutment with a partial ball head increases the precision and thus offers even more safety.

In the virtual model, the adhesive basis is only displayed as a place marker. The supraconstruction is designed over the adhesive basis to fit accurately and is then produced with the desired material. Suitable for the production of the supraconstruction are, among others, Tizian Cut eco plus, Tizian Cut and Tizian Cut 5. In addition, Schütz Dental offers a wide range of blanks in different shapes



made from different materials, e.g. zirconium dioxide, titanium and CoCr. After the milling procedure has been completed, the adhesive basis is glued to the milled construction.

Schütz Dental

Dieselstr. 5-6
61191 Rosbach, Germany
export@schuetz-dental.de
www.schuetz-dental.com

Planmeca

Planmeca signs record-breaking contracts

Finnish dental equipment manufacturer Planmeca delivers three fully digital teaching environments to King Saud University College of Dentistry and the National Guard of Saudi Arabia Health Affairs as part of an



extensive local health care development and investment to education. This substantial delivery agreement includes a turnkey solution with more than 1.000 dental units, simulation units, 2-D and 3-D X-ray systems combined with an innovative software platform, which seamlessly incorporates the devices and partner solutions into a high-tech, attractive learning concept. A similar solution with 127 dental units and a complete imaging and teaching system will also be delivered to the University of Eastern Finland in Kuopio. Planmeca's solution for dental universities has been adopted by numerous leading dental universities around the world. "Planmeca's sales growth in 2012 is more than 30%, ex-

cluding these university agreements. Our success proves that universities appreciate Planmeca's technology leadership and customer-focused product design. We are delighted to be working with these prestigious institutions.

Planmeca's competitive advantage has been achieved by considerable investments in in-house R&D, cooperation with leading academic research groups and strong commercial partners", says Mr Heikki Kyöstilä, President of Planmeca Oy.

Planmeca Vertriebs GmbH

Walther-Rathenau-Str. 59
33602 Bielefeld, Germany
info@planmeca.de
www.planmeca.de

CAMLOG Foundation

CAMLOG Foundation Research Award 2012/2013 launched

For the third time, the CAMLOG Foundation announces its renowned CAMLOG Foundation Research Award. The Research Award is presented every two years at the International CAMLOG Congress and is open to all young, talented scientists or researchers and dedicated professionals from universities, hospitals and practices under 40 years of age.



The expected extraordinary scientific papers must be published in a recognised scientific journal and can be submitted either in English or German. They should treat one of the following topics in implant dentistry or related disciplines: diagnostics and planning in implant dentistry, hard- and soft-tissue management in implant dentistry, sustainability of implant-supported prosthetics, physiological and pathophysiological aspects in implant dentistry, and advances in digital procedures in implant dentistry.

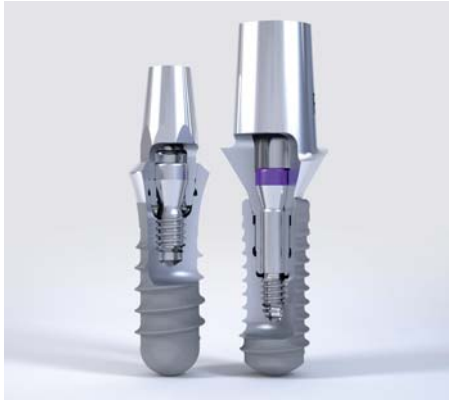The contributions will be judged and evaluated by the CAMLOG Foundation Board. The winner of the CAMLOG Foundation Research Prize 2012/2013 will be given the opportunity of presenting his/her work to a wider audience on the occasion of the 2014 International CAMLOG Congress. Furthermore, the authors of the three best contributions will receive attractive cash prizes (each EUR 10,000, EUR 6,000 and EUR 4,000). The entry conditions and the mandatory registration form can be downloaded from www.camlogfoundation.org/awards. Registration deadline is November 30, 2013.

CAMLOG Foundation

Margarethenstr. 38
4053 Basel, Switzerland
info@camlogfoundation.org
www.camlogfoundation.org

Straumann

Designed to last a lifetime: original implants



They may look and seem identical, but they are not: so-called “compatible” look-alikes are different from original implants. Clinical success is built on numerous individual elements – the choice of raw materials, consistent surface quality, a precise fit or manufacturing precision. Changes in manufacturing tolerances and deviations in materials can lead to problems. In the worst case, what appeared to be a cheaper alternative may result in an unpleasant experience for the patient and expensive repair work for the dentist and the laboratory.

Over time, prosthetic elements may need replacing. If an implant system is uncommon or no longer available, obtaining the matching original components could prove difficult. In the long run, such a system is hardly cost-efficient.

Straumann has always developed and manufactured products based on innovation, precision, reliability and simplicity. As an example, both Straumann’s SLA® and SLActive® surfaces have been investigated extensively in preclinical as well as clinical studies; becoming some of the most documented and clinically validated surfaces in the industry.

Straumann’s expertise has been built in decades of scientific research and development. It is only through accurate documentation of the product performance that dentists can be secure in recommending a treatment that corresponds to state-of-the-art science and technology to reduce possible risks to a minimum.

Institut Straumann AG
 Peter-Merian-Weg 12
 4052 Basel, Switzerland

 info@straumann.com
 www.straumann.com

Implant Direct

Interview with Sales Director Germany Timo Bredtmann

Hello Mr. Bredtmann, Implant Direct claims to be “simply smarter”. What is it that you offer implantologists?
 What we offer are further developments of proven implant concepts, and with the compatibility feature we are able to make them accessible to a large number of users.

Does this mean that the compatibility of Implant Direct systems is just a means to that end?

Absolutely. I cannot emphasise enough that our job is to present the compatibility feature to dentists as a state-of-the-art, safe, and successful strategy. Therefore, many dental practices will be able to profit from our know-how. The TriLobe system is compatible with Nobel Biocare, the Swiss system is compatible with Straumann, and the



Legacy system is compatible with Zimmer Dental. Furthermore we also offer our own Spectra line.

What is it that fascinates you about your new responsibility as sales director Germany for Implant Direct in Germany?

Implant Direct for me is one of the particularly innovative implant manufacturers. The market asks for our strengths and capabilities. My assumption is confirmed by

our raising sales numbers. We grow from our own strengths, and at a significantly faster pace than the market.

Mr. Bredtmann, thank you very much.

Nobel Biocare

New iPad®-operated drill motor

Dental drilling has been taken to another level as Nobel Biocare has launched its next generation iPad®-operated drill motor, the OsseoCare Pro. This new and innovative drill motor is part of a continued effort by Nobel Biocare to shape a more efficient digital treatment flow with patient safety at the forefront.

The new OsseoCare Pro is the first drill motor to be operated by an iPad®. Its intuitive user interface offers handling features providing clinicians and their patients with the highest treatment efficiency and security.

Available free of charge from the Apple® App Store, the OsseoCare Pro application delivers highly user-friendly operations during surgery and opens up numerous avenues in terms of customisation options. For better planning and increased treatment safety, the intuitive iPad® interface makes it possible to plan and set up the treatment sequence prior to surgery. Pre-programmed free-hand and guided drilling protocols provide additional increased safety features. The speed, torque, irrigation flow and light intensity can be controlled and modified through the application which also offers a built-in recording and exporting function. Additionally, the app allows multiple-user log-ins for



sharing treatment data between different clinical partners.

New features and functions will be added to the app and will be updated regularly to provide users with improvements as well as enhancing the performance of the system. The contra-angle with its extremely small head is equipped with a double LED system that ensures ample and stable lighting during surgery while the combination of internal and external irrigation ensures optimal cooling. Learn more at nobelbiocare.com/osseocare

Nobel Biocare
 PO Box
 8058 Zurich Airport

 info.switzerland@nobelbiocare.com
 www.nobelbiocare.com

42nd international annual congress: DGZI stays on target

Author: Dr Georg Bach, Germany

Translated by: Gladia Jahn, Germany



Not only was “quality-oriented implantology” the topic of this year’s annual congress of Europe’s oldest implantological society in Hamburg, Germany, but it is also a concept to which DGZI is committed.

This commitment showed especially during the press conference on Friday afternoon and continued to be the recurrent theme of the two congress days, starting 5 October 2012.



Prof Dr Frank Palm

By the end of the congress, the DGZI organisers were pleased to conclude that the dental society is well-positioned and ready for the future. “DGZI does differ!”, therefore was the appropriate welcome of DGZI president Prof Dr Dr Frank Palm for more than 500 participants from 18 countries, among them also visitors from partner societies from Japan and Arabia. DGZI vice president Dr Roland Hille proudly reported that more than forty expert speakers had agreed to participate in the congress and that each lecture was written exclusively for the DGZI congress.

_ Implantology called into question

With Prof Dr Jörg R. Straub, Freiburg, Germany, Prof Dr Thomas Weischer, Essen, Germany, and basic research Prof Dr Werner Götz, Bonn, Germany, with his co-speaker Dr Rolf Vollmer, three internationally renowned lecturers entered the podium. Dr Daniel Ferrari, Düsseldorf, Germany, complemented the sometimes critical tone of the previous speakers in an ideal fashion when he talked about minimising patient discomfort by effective surgical management. Dr Albert Mehl from the Federal Institute of Technology in Zurich inspired the audience with his speech on the opportunities CAD/CAM applications provide for implant restorations.

Dr H. P. Weber, Boston, USA, added to the speech by Dr Mehl with his talk on the digital process chain in implant prosthetics. Dr Kai-Olaf Henkel ("Complications and Failures in Implantology") and Prof Dr Herbert Deppe dealt with the less pleasant aspects of implantology. Prof Dr Deppe, associate professor for dental implantology and oral surgery from Munich, questioned the plausibility of implants in organ transplant patients. Prof Dr Deppe was followed by Prof Dr Anton Sculean, Bern, Switzerland, who took his audience to the world of innovative techniques and materials used in covering multiple recessions. Prof Dr Peter Rammelsberg from Heidelberg, Germany, gave his speech on the "Effects of simultaneous augmentation procedures on the implant prognosis", whereas PD Dr Torsten Mundt presented a multi-centre research on mini implants by 3M-Espe. Finally, Prof Dr Dr George Khoury, Hamburg, Germany, addressed the regenerative effects of hyaluronic acid.

International Podium

Like in previous years, well-known speakers of fellow dental societies filled the large international audience of the DGZI annual congress. The speakers came mainly from Arabic and Asian areas and discussed current but also highly charged problems in implantology. The international podium therefore assembled a cornucopia of valuable speech items and insights from laser applications, over 3-D diagnosis and planning to immediate loading and risk patients. Mohamed Moataz Khamis, Egypt, reported on the advantages of uncovering the implant via Er:CR:YSGG laser by which the contouring of soft tissues can be achieved almost free of pain and without bleeding or scar formation.

Prof Suheil Boutros, USA, gave an account on how the new MTX trabecular implant by Zimmer dental helps to reduce treatment times, which is a real benefit for the patients. Dr Sami Sade from Lebanon spoke about life-threatening bleeding after implantation in the supposedly "safe" frontal areas of the mandible. His message: Never implant in the anterior mandible without lingual flap formation. Prof Shoji Jyaschi, Japan, proved that



countersinks need not be used in the maxilla on the basis of more than 1,000 follow-ups of implant patients (Periost values were identical in groups with and without countersink).

Dr Osamu Yamashita, Japan, reported on a significant decline in the oral germination rate by 40 per cent resulting from HOCl-solution. Finally, Dr Ramy Rezkallah, Egypt, stated that CBCT diagnosis had some advantages over conventional two-dimensional imaging techniques with regard to implantology, resulting from the higher dose of radiation. However, he also highlighted that a patient-specific estimate of costs and benefits is always necessary.

Prosthetics Podium

Master dental technician Christian Müller is the first "non-dentist" to be a member of the executive board of Europe's oldest dental society, following the explicit request of both members of the executive board and last year's DGZI general meeting, which assigned the highest priority to the "intersection between dentistry and dental technology".

Another success of this pleasant development is the curriculum implant prosthetics, which is offered by DGZI in collaboration with the company Fundamental from Essen, Germany. More than 250 dental technicians



Prof Dr Dr Jörg R. Strub



Prof Dr Hans-Peter Weber



Prof Dr Herbert Deppe



Prof Dr Anton Sculean



have passed this curriculum last year and gained further qualification. Christian Müller's first task as a member of the executive board was therefore to organise the special podium "implant prosthetics". As chairman of this podium, he maintained a leading function together with Prof Dr Rammelsberg, Heidelberg, Germany.

Prof Dr Rammelsberg also contributed a speech to the prosthetics podium and discussed the controversial question, "Is the inclusion of the natural dentition in implant-supported bridges or prostheses a risk or a gain with regard to the preservation of tooth structures"? His almost Solomon-like résumé with regard to the areas around bridges: "Both of the two alternatives work, in detachable and fixed prostheses". Rammelsberg first compared solely implant-supported dentures to composite bridges. The two kinds of bridges show high survival rates with regard to fixed prostheses. However, ceramic-only restorations displayed more complications than restorations made of metal and ceramics. Prof Dr Rammelsberg encounters frequently occurring chipping with non-ceramicly veneered ceramic-only restorations. Implant-supported detachable prostheses showed a slightly but significantly increased success rate than those of combined anchorage. All in all, detachable prostheses showed only little failure rates with regard to both types of restoration. Failures were mostly technical, for example wear of the plastic. Prior to this, PD Dr Andreas Bindl, Switzerland, gave an overview on the high number of varieties in implant planning via 3-D technology and digital impression taking. The

"mount Olymp" of his elaborations was the virtual planning of prosthetics, "digital backward planning" at its best. The auditorium was highly interested in the possibility to produce drill templates in the dental practice via 3-D planning.

Master dental technician Tom Lassen, Germany, contributed his speech on passive fit as a fundamental requirement for the long-term success in prosthetics. He said that the ideal of the almost passive fit has to be pursued at any rate. However, mistakes in impression taking techniques and the production of the model can inhibit an ideal passive fit. Nevertheless, many dental technological processes have been clarified, fixation in the mouth, for example, has been a great relief. As Lassen stated, "Producing the model accurately is the crux of the matter". New member of the DGZI executive board Christian Müller of course also took the opportunity to pick up the microphone and discuss casting vs. milling as future techniques for implant-based restorations. Master dental technician Andreas Kunz, Berlin, Germany, raised the question of design and materials most suitable for implant abutments. Master dental technician Christian Müller and the author put forward their troubleshooting update, taking up their presentation from the previous annual congress and adding new troubleshooting cases in implantology.

Special podium "Periimplantitis: Explanation or Therapy?"

Ever since the first annual congresses, the DGZI special podiums have been an inherent part of their scientific programme and are turning more and more to be among the highlights of these educational events. Hosted by DGZI president Prof Dr Dr Frank Palm, Prof Dr Herbert Deppe, Prof Dr Andrea Mombelli and Prof Dr Anton Sculean, the participants discussed the highly unpleasant topic periimplantitis. As a quasi-introduction, federal periodontologist Prof Dr Mombelli held his speech on the epidemiology of periimplantitis. Mombelli realised that "exactly 25 years ago, periimplantitis was born" when he spoke about the phenomenon periimplantitis for the first time in a publication in



Dr Tomohiro Ezak



Prof Dr Amr Abdel Azim



Dr Mazen Tamimi



Mohamed Moataz M. Khamis



Prof Dr Suheil Boutros

1987. An extensive literary research showed that ten per cent of the implants are affected by periimplantitis in 20 per cent of the patients after five or up to ten years. Mombelli also relativized the study by Zitzmann, which is often quoted by the layman press, since the patients examined were preselected and criteria such as BOP were evaluated. Mombelli highlighted that "Bleeding does not necessarily mean periimplantitis" and pointed out that nicotine abuse and the patient's "perio history" are factors which have to be taken into account.

Already in the beginning of the discussion, the dogma of "no probing in implants" was replaced by the overall opinion that probing in implants is an important diagnostic tool. Another view on which the members agreed was that it is important to diagnose periimplantitis as early as possible and then to immediately induce the respective therapeutic measures. The "tests" which are offered to evaluate the increased risk of periimplantitis were seen negatively by the participants. They agreed that a correct anamnesis and estimation of individual risk factors were more important. In order to avoid cementitis, which can be the starting point of periimplantitis, supraconstructions can be screwed on. The podium voiced a critical opinion on implant plastics as presented by Frank Schwarz and colleagues. In severe cases such as these, explantation was seen as the preferable choice. All agreed that an implant-specialised evaluation will become more important in the future.

Corporate podium

Another highly estimated tradition is the corporate podium, which gives DGZI members and registered doctors the opportunity to report on their practical experience and findings. Contributions from the realm of university research complement the podium, among them Prof Rother, Germany, who spoke about "CBCT today and in the future". All of the eight speakers dedicated their talks to the motto of the 42nd DGZI international annual congress "Sustainability and long-term success in quality-oriented implantology", among them topics such as augmentation procedures, aesthetics and sedation.



Concluding, the DGZI annual congress has successfully communicated the concern of Europe's oldest dental society regarding sustainability in implantology. Therefore, the overall tone during the congress can also be taken as its summary: DGZI is well positioned to face current and future challenges in implantology and takes responsibility with regard to both the education of members and colleagues ("Focus: Registered Practice") and patients ("Focus: Information").

contact

implants

Dr Georg Bach

Rathausgasse 36
79098 Freiburg im Breisgau, Germany

doc.bach@t-online.de

DGZI

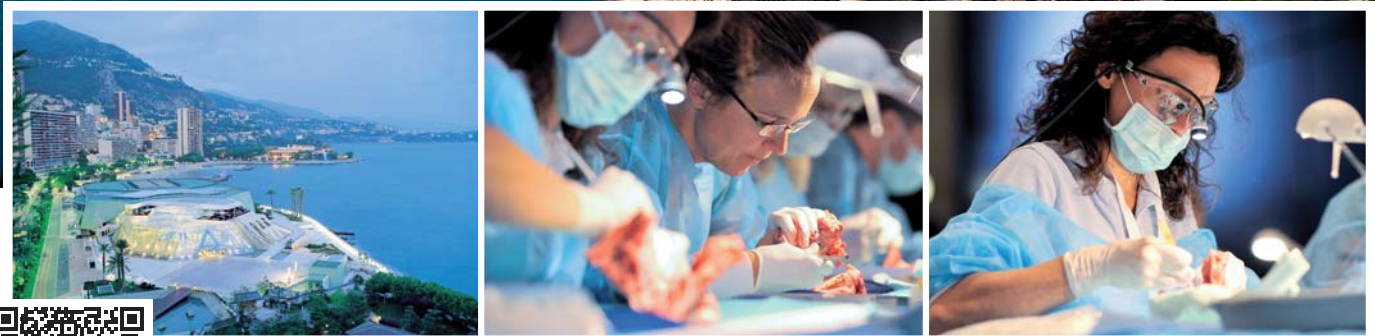Zentrale Geschäftsstelle
Paulusstraße 1
40237 Düsseldorf, Germany

sekretariat@dgzi-info.de
www.DGZI.de



Practical Training at Osteology in Monaco

Source_Osteology



Scan me to watch the Osteology Image Movie!

_Regenerative therapies require a high degree of dexterity—from the first incision to the last suture. Anyone wanting to remain up to date is dependent on regular practice and trial, because the repertoire of therapies is constantly being supplemented by new techniques and materials. Thus, the Osteology Foundation clearly focuses on hands-on training at all symposia it organises.

Once again on May 2, 2013, the pre-symposium day of the International Osteology Symposium, 17 practical workshops in German, English and French will be inviting attendees to train their own skills.

"Decision making with oral tissue regeneration" is the symposium's main topic. Top speakers from all over the world will be spending two days presenting and discussing the current state of knowledge relating to regenerative therapies. However, the day prior to the congress is dedicated solely to practice. The Osteology Foundation alone is organising seven practical and two

theoretical workshops. Further there are eleven workshops being organised by the Gold Partners viz., BioHorizons, CAMLOG, DENTSPLY Implants, Geistlich Biomaterials, Nobel Biocare and Straumann.

Procedures for both bone and soft tissue regeneration and the topic of periimplantitis are at the core of the practical exercises. Using pig's jaw models, attendees can gradually learn flap formation, incision types and suture techniques, practice widening up of keratinised mucosa, perform vertical and horizontal bone augmentation, practice ridge preservation combined with socket seal or try out various surgical and non-surgical procedures for periimplantitis treatment. The clear objective of the workshops is to teach attendees current therapy concepts and give them practical tips for everyday dental practice.

The Osteology Foundation is also proud to premier workshops for researchers. Two theoretical workshops will deal with the experimental evaluation of biomaterials and the correct selection of models for translational research.

The congress website www.osteology-monaco.org lists the congress programme and all workshops including details of the speakers, languages, etc. You can register online via the congress website or by fax (+377 97 97 35 50). Needless to emphasise your prompt action as the number of places in every workshop is limited.



The editors of implants would like to thank all authors for dedicating their time and efforts to this year's issues.

Issue 1/2012

| Dr Maen Aburas, UAE
 | Dr Georg Bach, Germany
 | Dr Surheil M. Boutros, USA
 | Dr Ralf Gutwald, Germany
 | Dr Stefanos G. Kourtis, Greece
 | Dr Gian Luigi Telara, Italy
 | Prof Marcel Wainwright, Germany



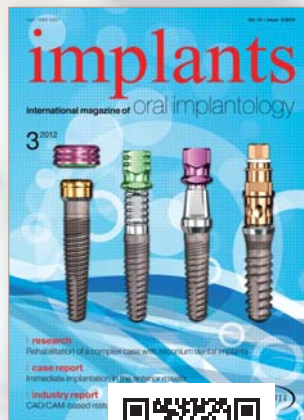Issue 2/2012

| Dr Georg Bach, Germany
 | Prof Dario Bertossi, Italy
 | Dr Igor Cernavin, Australia
 | Dr Luca Di Alberti, Italy
 | Prof Sergio Alexandre Gehrke, Brazil
 | Bruno Konig Jr., Brazil
 | Prof Dr Frank Liebaug, Germany
 | Prof Lorenzo Lo Muzio, Italy
 | Prof Pierfrancesco Nocini, Italy
 | Dr Eric Normand, France
 | Prof Alessandro Pozzi, Italy
 | Dr Tussavir Tamba, UK
 | Giovanni Wiel Marin, Italy
 | Dr Ning Wu, Germany



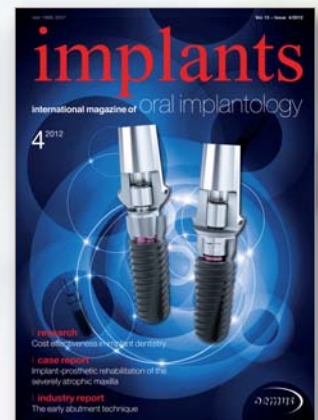Issue 3/2012

| Dr Oscar Arnaboldi, Italy
 | Dr Andrea Enrico Borgonovo, Italy
 | Dr Rachele Censi, Italy
 | Dr Olaf Daum, Germany
 | Dr Marcello Dolci, Italy
 | Dr Dirk U. Duddeck, Germany
 | Dr Andrea Grandoch, Germany
 | Dr Viktor E. Karapetian, Germany
 | Arnd Lohmann, Germany
 | Prof Carlo Maiorana, Italy
 | Dr Mauro Marincola, Italy
 | Dr Vincent J. Morgan, USA
 | Dr Nikolas Papagiannoulis, Germany
 | Stefano Lapucci, Italy
 | Angelo Perpetuini, Italy
 | Dr Eduard Sandberg, Germany
 | Dr Marius Steigmann, Germany
 | Dr Virna Vavassori, Italy
 | Dr Rolf Vollmer, Germany
 | Prof Dr Gregory-George Zafiropoulos, Germany



Issue 4/2012

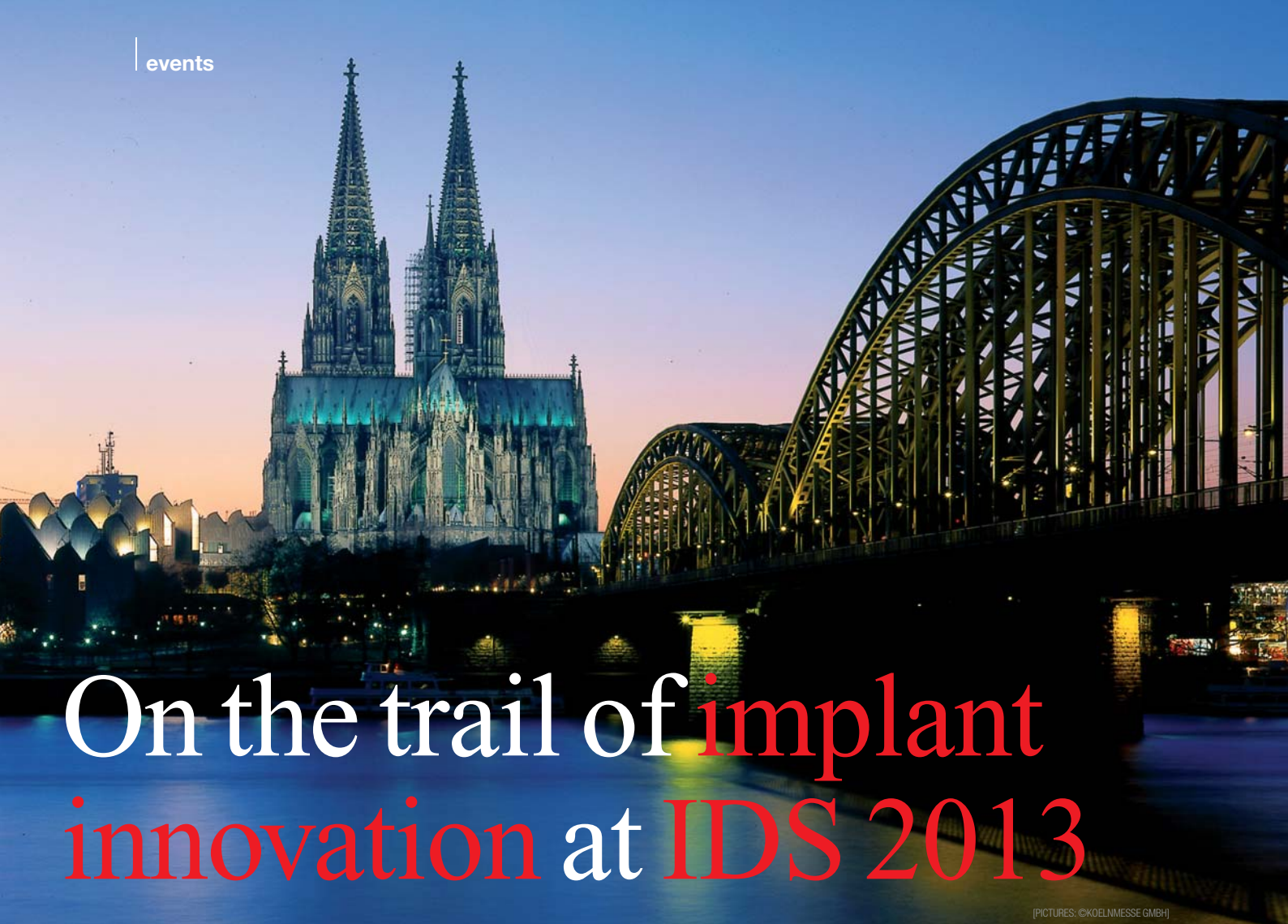| Dr Georg Bach, Germany
 | Dr S. Marcus Beschnidt, Germany
 | Prof Dr Rainer Buchmann, Germany
 | Aiman Abdel Galil, Germany
 | Prof Sergio Alexandre Gehrke, Brazil
 | Dr Mauro Labanca, Italy
 | Prof Dr Frank Liebaug, Germany
 | Dr Rainer Valentin, Germany
 | Dr Ning Wu, Germany
 | Prof Dr Gregory-George Zafiropoulos, Germany



become an author
 for "implants"

Please contact Claudia Jahn
 ✉ c.jahn@oemus-media.de





On the trail of **implant** innovation at **IDS 2013**

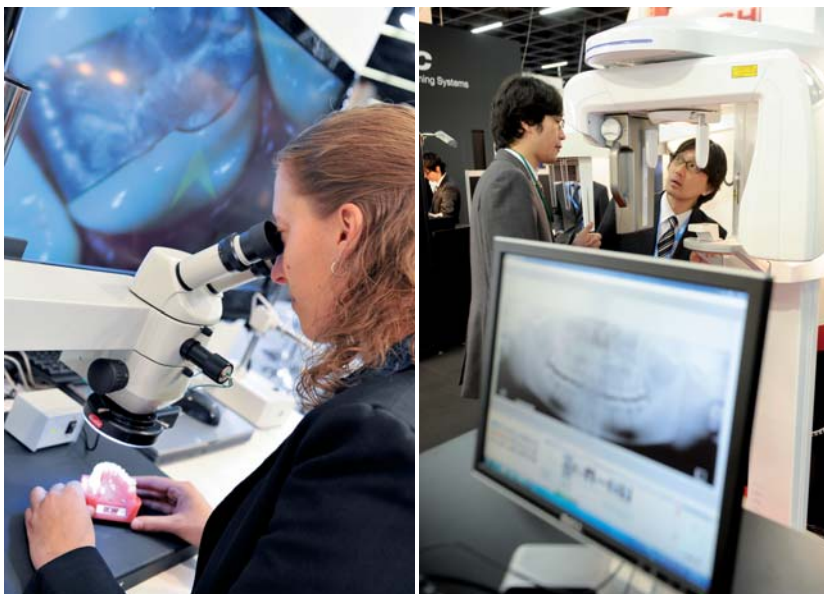[PICTURES: © KOELNMESSE GMBH]

Source_Koelnmesse

Around 15 million implants are to be found in German mouths alone, with over 800,000 more being implanted every year. So it's no wonder that this growth area of modern dentistry is also a regular fea-

ture at the International Dental Show (IDS) in Cologne. Every two years, implant specialists in particular are among the dentists and dental technicians who attend the world's biggest leading trade fair serving the dental sector to gather information about new products and current trends. After all, keeping up with progress is vital in this innovation-driven sector. Optimised implant surfaces, individual abutments or software for guided implantation—the trends are so diverse that it isn't always easy to maintain an overview. That's why using IDS as an aid to decision-making is an excellent way to keep a practice on the right track with new ideas.

The focus is on different developments, depending on objective and target group. For example, anyone who has specialised in metal-free prostheses from root to crown will also be interested in new products in the field of zirconium oxide implants. Current study results in this field are lending new momentum to innovation in both practice and research in equal degree. The results of this development will first be visible in Cologne—as is typical for IDS.





While some materials are only of interest to certain practitioners, business planning systems and methods for improving the workflow are becoming more important everywhere. The topic of guided implantation in particular is currently arousing great interest. Modern software systems now make even 3-D planning possible without a DVT unit in the practice—a compelling argument, especially for smaller practices without a great deal of scope for substantial investment.

No matter where the main areas of interest lie, every visitor will find the appropriate solutions at IDS, which will take place from 12 to 16 March 2013. And the best part is that, alongside the opportunity to interact with the latest developments in the dental industry live, numerous experts are also on hand to give advice face-to-face. Planning your participation in IDS in advance therefore provides the best opportunities to take home important advice and information.

"The broad field of implantology, in particular, benefits from a structured approach. A plan drawn up in advance helps in locating the innovations of interest for a specific practice," says Dr. Markus Heibach, President of the VDDI. "IDS in Cologne offers a unique opportunity to experience producers and their products

in person. In this way, dentists and dental technicians can benefit directly from the dental industry's know-how, seek out discussions with experts and take home insights of real relevance to their practices."

IDS takes place in Cologne every two years and is organized by the GFDI Gesellschaft zur Förderung der Dental-Industrie mbH, the commercial enterprise of the Association of German Dental Manufacturers (VDDI) and staged by Koelnmesse GmbH, Cologne.

Photos from the last IDS Cologne are available in our image database on the Internet (www.ids-cologne.de), "For the Press". If you reprint this document, please send a voucher copy.



First European oral health summit

Takes place in Brussels

In early September, the Platform for Better Oral Health in Europe, a forum that brings together European organisations for the promotion of oral health and the prevention of oral diseases, celebrated its first anniversary. At its first summit, participants of the event



were presented with the "State of oral health in Europe" report commissioned by the organisation. In celebration of World Oral Health Day, over 140 European oral health experts attended the summit in Brussels, which was organised under the patronage of the Cyprus Presidency of the Council of the EU, supported by Karin Kadenbach and Dr Cristian Silviu Buşoi, who

are members of the European Parliament and presented the report.

"The good news is that we have witnessed incredible progress in the last decades in the prevention of caries in children. The bad news is that having damaged, missing or filled teeth is still the norm rather than the exception in Europe, and oral diseases remain among the most important health burdens," Kadenbach concluded.

According to the report, the EU currently spends almost €79 billion on health care and the figure is likely to rise to €93 billion by 2020. It also emphasises the challenges that demographic changes may pose to oral health. However, Kadenbach emphasised that there are also rising inequalities among member states in terms of access to oral care. In many EU member states, oral health care is not fully integrated into national or community health programmes, the report states. Therefore, Prof Kenneth Eaton, Chairman of the Platform for Better Oral Health in Europe, called for greater policy attention and action on the topic of oral health. The report recommends that EU decision-makers make a commitment to improving oral health by 2020 as part of EU policies.

New logo

showing all-round quality

To mark its 90th anniversary, Komet treats itself and its customers to a brand new Corporate Design. Introduced on 01 September 2012, our fresh and dynamic new Corporate Design captures the spirit of modern times while still representing the traditional Komet values of quality, innovation and tradition. Our new logo is impressive: The distinctive Komet lettering is now placed above the Komet spiral.

These two symbols—standing for dynamics and innovative power—will ensure global brand recognition with our 100,000 customers world-wide. The eye-catching new design will successively appear on all



printed matters, our website and at trade fairs. Frank Janßen, our Head of Marketing, says: "We created a dynamic, up-to-date Corporate Design that reflects what we stand for: A reputable company with a professional approach."

When asked how the company will be addressed in future, Mr. Janßen stated: "The brand name Komet will be predominantly used in all our communication, but we will continue to operate as Gebr. Brasseler GmbH & Co. KG." There's nothing left for us to add, other than, "Happy Birthday, Komet, and congratulations on your great new design!"

20 nations represented at the

tioLogic® Advanced Training Course

From July 13–16, 2012, more than 200 participants from 20 countries were treated to a comprehensive programme at the Westin Grand Hotel in Frankfurt/Main as part of the tioLogic® Advanced Training Course. Proceedings got underway on Friday evening with a get-together in relaxed surroundings and a lively entertainment programme where guests could already engage in in-depth discussions.



Over the two days that followed, interested participants had the opportunity to gain valuable insights into the latest developments of the tioLogic® system. A variety of practical tips and solution-oriented approaches were also presented for implantology scenarios, sinus and bone augmentation, and risk management, as well as for handling complications in a professional manner.

The in-depth discussions during breaks and following each presentation were just one indication of how impressed participants were by the implantology experience on display in the presentations and workshops held by our team of international speakers comprising Prof Tobias M. Böckers and Dr Joachim Hoffmann from Germany, Dr Vincenzo Catalano and Dr James Galea from Malta, Dr Umberto Pratella from Italy, and Dr Manfred Sontheimer from Germany. The presentation by Dr Santiago Isaza Penco, which looked at synergies between dental and orthodontic implants such as the tomas® system from Dentaurum, also encouraged participants to share knowledge across different disciplines.

And although it was not part of the official programme, many participants also chose to take the 160-kilometre journey to Ispringen to visit Dentaurum, and to see for themselves onsite just why Dentaurum quality "made in Germany" is so special.

New study reveals

Oral health's growing price tag for Europe

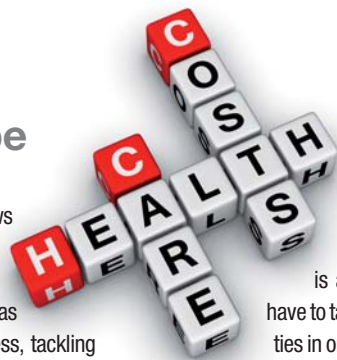Treatment costs for oral and dental conditions across Europe often exceed those of other major diseases, including cancer, heart disease, stroke, and dementia, according to a pan-European study released in September 2012. The State of Oral Health in Europe Report estimates current spending in dental treatment in the EU 27 to be close to €79 billion per year, a figure set to reach €93 billion by the year 2020 if adequate action is not taken now. The report reveals that oral health-related costs are still on the rise despite the fact that caries and their complications are highly preventable through a healthy, balanced diet and routine oral hygiene practices.

The study was commissioned by the Platform for Better Oral Health in Europe, a forum that brings together European organisations that work towards the promotion of oral health and the prevention of oral diseases in Europe. The report analysed data from 12 European countries (Austria, Cyprus, Denmark, France, Germany, Ireland, Italy, Lithuania, Poland, Romania, Spain

and the United Kingdom). The report shows that—despite significant achievements in the prevention of cavities in Europe—much remains to be done in areas such as: promoting oral health awareness, tackling oral health inequalities and addressing common risk factors. Further indispensable tools in the fight for better oral health in Europe include the development of high quality, comparable oral health data and better cost-effectiveness studies to assess the impact of prevention initiatives.

On the basis of the report findings, the Platform has developed a series of recommendations and calls on policymakers.

Presenting the results of the study at the first European Oral Health Summit, held 5 September, 2012, at the European Parliament in Brussels, Member of the European Parliament Ms Karin Kadenbach said, "In a time of austerity measures and growing pressure on health-



[PICTURE: ©ALMAGAM]

care budgets, this report is a timely reminder that we have to tackle the persisting disparities in oral health across and within EU countries, with regards to socioeconomic status, age, gender, or indeed general health status."

Speaking at the Summit, Professor Kenneth Eaton, Chairman of the Platform for Better Oral Health in Europe, called for more policy attention and action on the topic of oral health. "At the EU level, there is currently a lack of understanding about the integral role oral health plays in overall health and well-being," he said. "On behalf of the Platform for Better Oral Health in Europe, I hope and believe we finally have the adequate tools and procedures in place to work effectively together and foster policy decisions which will benefit the oral health of everyone in Europe in the years to come."

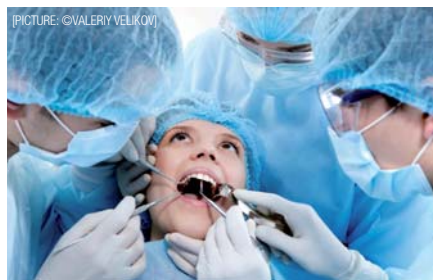Source: www.oralhealthplatform.eu

Minimally Invasive Surgery

Boosts Outpatient Procedures

More and more surgical procedures are being performed globally every year, driving the demand for new and improved surgical equipment, states a new report by healthcare experts GBI Research. The new report Surgical Equipment Market to 2018—Increased Access to Ambulatory Surgical Centers to Drive Outpatient Surgery Volumes shows that this increase in surgical procedures is due to improving healthcare infrastructure in emerging countries, increasing cases of lifestyle diseases and technological innovations boosting the possible workload of surgeons.

According to the Centre for Disease Control (CDC), approximately 48 million surgical procedures are performed in the US each year, while emerging countries such as India and China hold huge future potential for surgery due to increased healthcare expenditure and huge patient populations. The spread of westernised living standards has led to a worldwide increase in diseases such as obesity, lung cancer, cardiovascular diseases and kidney disorders, expanding the patient population eligible for surgery.



[PICTURE: ©VALERIY VELIKOV]

Accessibility, affordability and patient comfort are also driving up the demand for outpatient procedures. Outpatient surgery is found to be more cost-effective than inpatient surgeries, as they eliminate hospitalization costs, minimize the time spent in the operating theatre, and cut costs for staffing and travel. The increasing volume of surgical procedures being carried out is resulting in a growing demand for surgical equipment such as surgical sutures, electrosurgical devices and hand instruments. The global market for surgical equipment is therefore forecast to exceed \$7 billion by 2018, following growth at a Compound Annual Growth Rate (CAGR) of 4.2% during 2011–2018.

Flavoured toothpaste suppresses

Appetite for sweets

A German manufacturer of dental care products has developed a flavoured toothpaste that reduces a person's desire for sweets. The product promises healthy teeth and curbs one's sweet tooth. Users only have to brush three times a day for at least three minutes to benefit from the product, which promotes dietary change and can lead to weight loss of up to almost 7 kg.

According to Dr Weiler, a newly founded company, natural flavours in the toothpaste are responsible for the effect.

A randomised, placebo-controlled, blind study with 48 participants over four weeks and an application study over three months with 36 people found that 90 per cent of the participants reported a significantly reduced appetite for sweets.

Some of them saw a weight reduction of up to 6.8 kg within three months as giving up sweets became easier when using the toothpaste regularly.



[PICTURE: ©GRASKOJ]

implants
international magazine of oral implantology



Publisher

Torsten R. Oemus
oemus@oemus-media.de

CEO

Ingolf Döbbecke
doebbecke@oemus-media.de

Members of the Board

Jürgen Isbaner
isbaner@oemus-media.de

Lutz V. Hiller

hiller@oemus-media.de

Chief Editorial Manager

Dr Torsten Hartmann (V. i. S. d. P.)
hartmann@dentalnet.de

Editorial Council

Prof Dr Dr Frank Palm
frank.palm@klinikum-konstanz.de

Dr Roland Hille

dr-hille@t-online.de

Prof Dr Dr Kurt Vinzenz

kurt.vinzenz@aon.at

Dr Torsten Hartmann

hartmann@dentalnet.de

Dr Suheil Boutros

SMBoutros@aol.com

Editorial Office

Georg Isbaner
g.isbaner@oemus-media.de

Claudia Jahn

c.jahn@oemus-media.de

Executive Producer

Gernot Meyer
meyer@oemus-media.de

Designer

Sarah Fuhrmann
s.fuhrmann@oemus-media.de

Customer Service

Marius Mezger
m.mezger@oemus-media.de

Published by

OEMUS MEDIA AG
Holbeinstraße 29
04229 Leipzig, Germany
Tel.: +49 341 48474-0
Fax: +49 341 48474-290
kontakt@oemus-media.de

Printed by

Messedruck Leipzig GmbH
An der Hebemärchte 6
04316 Leipzig, Germany

implants

international magazine of oral implantology
is published in cooperation with the German
Association of Dental Implantology (DGZI).

DGZI President

Prof Dr Dr Frank Palm
DGZI Central Office
Feldstraße 80, 40479 Düsseldorf, Germany
Tel.: +49 211 16970-77
Fax: +49 211 16970-66
office@dgzi-info.de

www.dgzi.de
www.oemus.com

Copyright Regulations

_implants international magazine of oral implantology is published by Oemus Media AG and will appear in 2012 with one issue every quarter. The magazine and all articles and illustrations therein are protected by copyright. Any utilization without the prior consent of editor and publisher is inadmissible and liable to prosecution. This applies in particular to duplicate copies, translations, microfilms, and storage and processing in electronic systems.

Reproductions, including extracts, may only be made with the permission of the publisher. Given no statement to the contrary, any submissions to the editorial department are understood to be in agreement with a full or partial publishing of said submission. The editorial department reserves the right to check all submitted articles for formal errors and factual authority, and to make amendments if necessary. No responsibility shall be taken for unsolicited books and manuscripts. Articles bearing symbols other than that of the editorial department, or which are distinguished by the name of the author, represent the opinion of the afore-mentioned, and do not have to comply with the views of Oemus Media AG. Responsibility for such articles shall be borne by the author. Responsibility for advertisements and other specially labeled items shall not be borne by the editorial department. Likewise, no responsibility shall be assumed for information published about associations, companies and commercial markets. All cases of consequential liability arising from inaccurate or faulty representation are excluded. General terms and conditions apply, legal venue is Leipzig, Germany.

implants

international magazine of oral implantology



Subscribe now!

You can also subscribe via
www.oemus.com/abo

I would like to subscribe to **implants** international magazine of oral implantology (4 issues per year) for €44 including shipping and VAT for German customers, €46 including shipping and VAT for customers outside Germany, unless a written cancellation is sent within 14 days of the receipt of the trial subscription. The subscription will be renewed automatically every year until a written cancellation is sent to OEMUS MEDIA AG, Holbeinstr. 29, 04229 Leipzig, Germany, six weeks prior to the renewal date.

▶ Reply via Fax +49 341 48474-290 to OEMUS MEDIA AG or per E-mail to grasse@oemus-media.de

Last Name, First Name	
Company	
Street	
ZIP/City/County	
E-mail	Signature

Notice of revocation: I am able to revoke the subscription within 14 days after my order by sending a written cancellation to OEMUS MEDIA AG, Holbeinstr. 29, 04229 Leipzig, Germany.

Signature



IDENTICAL
IMPLANT SHAPE



TUBE-IN-TUBE™
CONNECTION



CONICAL
CONNECTION

CAMLOG IS
TWICE AS GOOD

Conical – and of CAMLOG quality: The CONELOG® Implant System. First-class Tube-in-Tube™ or conical implant-abutment connection – all from one source.

For more information: www.camlog.com

a perfect fit™

camlog