

Lasers in the treatment of traumatically fractured frontal teeth

Author_Dr Carlo Fornaini, Italy

Introduction

Dental traumatology is a multidisciplinary branch of dentistry that requires a number of specific skills. In cases of emergency, decisions have to be made within a limited time frame and with effects that can only be evaluated at a later date.¹ The techniques of tooth fragment re-attachment should be adapted for cases of simple coronal fracture (enamel and superficial dentin) as well as complicated coronal fracture (deep dentin with pulp exposure).²

In cases of simple fracture, a fragment may be re-attached immediately, while in complicated coronal fractures, the main concern should be the protection of the pulp and not necessarily the fragment,

which should be maintained hydrated and refrigerated in a container marked with the patient's full name and the date of the trauma. The solution in the container should be changed at regular intervals and the seal checked, since in some cases fragments may be stored for several months before being re-attached.³

The field of adhesive dentistry was born in 1955 by Buonocore, with the description of the utilisation of orthophosphoric acid and composite resin in order to obtain restorations with high bond strength and reduced microleakage.^{4,5} In 1990, laser technology was introduced in conservative dentistry by Hibst and Keller, who described the use of an Er:YAG laser as an alternative to conventional instruments, such as the turbine and micromotor.^{6,7} Widespread

Fig. 1_Coronal fracture of the permanent right central incisor.

Fig. 2_After treatment with Er:YAG, SSP mode.

Fig. 3_The reposition of the fragment.

Fig. 4_The preparation of the borderline surface area.

Fig. 5_Completed treatment.

Fig. 6_Crown fracture of the permanent, right central incisor.

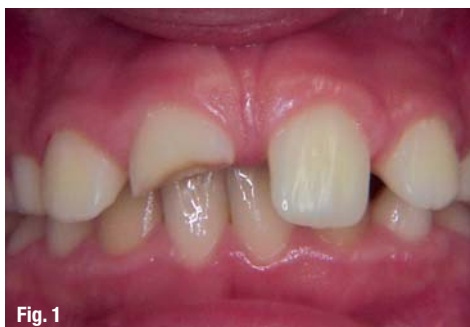

Fig. 1

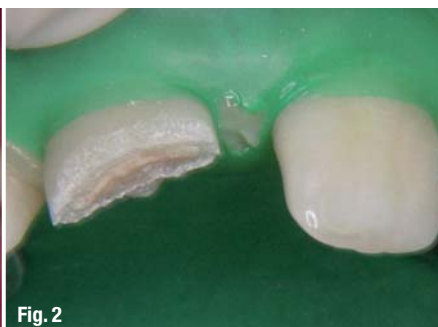

Fig. 2

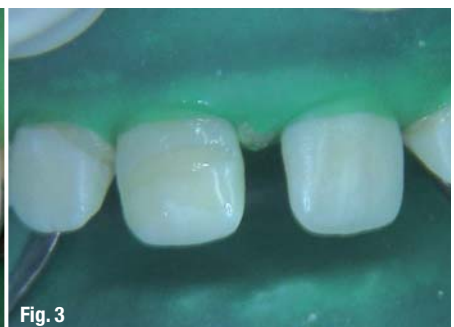

Fig. 3

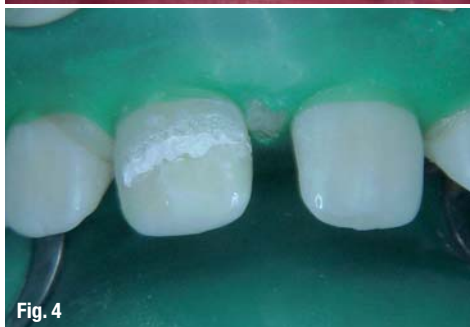

Fig. 4

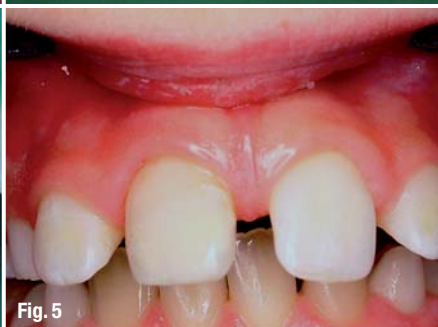

Fig. 5

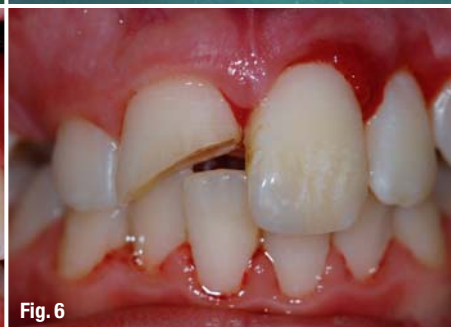
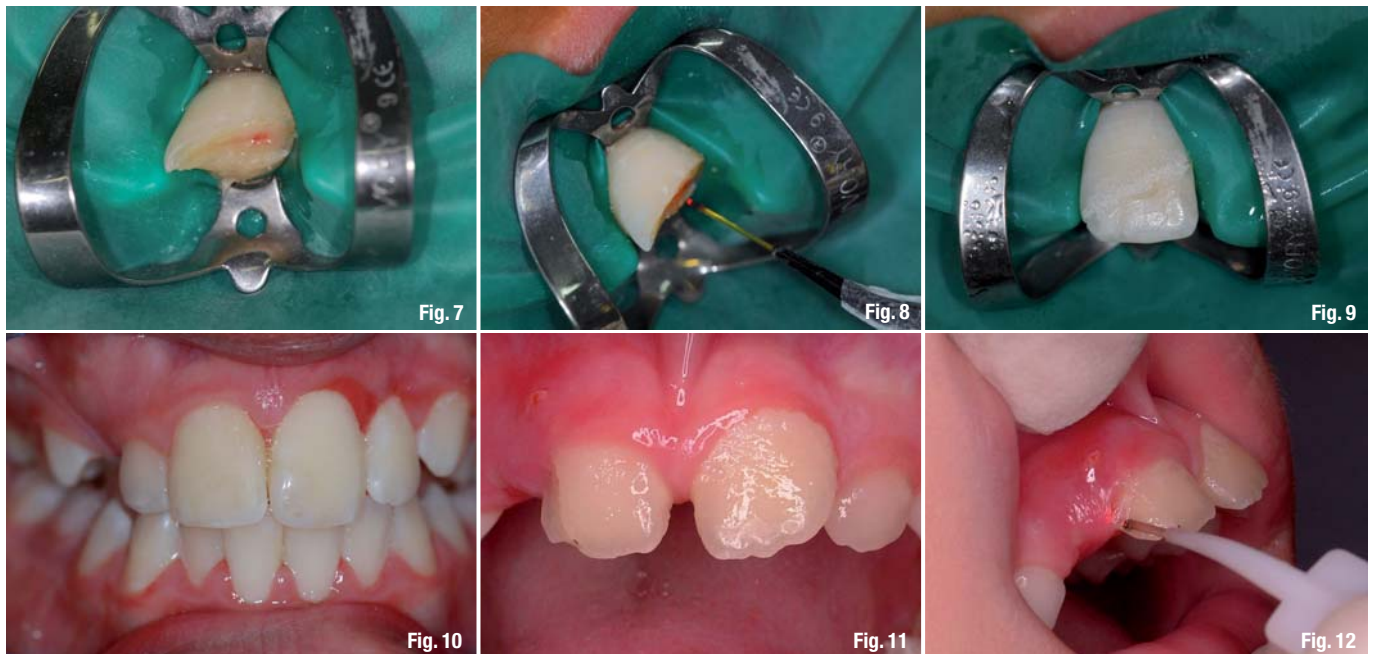
Fig. 6



interest in employing this new technology is related to its significant number of advantages, as described in several scientific studies. Thanks to the affinity of its wavelength to water and hydroxyapatite, Er:YAG laser technology allows for the efficient ablation of hard dental tissues without the risk of micro- and macro-fractures, which have been observed when using conventional rotating instruments.^{8,10} The dentin surface treated by laser appears clean, without a smear-layer and with the tubules open and clear.¹¹

Thermal elevation in the pulp, recorded during Er:YAG laser irradiation, is less than that recorded by using turbine and micro-motor, in the same conditions of air/water spray.^{12,13} This wavelength also has an antimicrobial decontamination effect on the treated tissues, which destroys both aerobic and anaerobic bacteria.¹⁴ The most interesting aspects of this new technology are related to the goals of modern conservative dentistry, namely "minimally invasive" treatments and better adhesive methods. Er:YAG lasers can reach spot dimensions smaller than 1 mm, which allows the possibility to make a selective ablation of the affected dentin while preserving the sound tissue in order to realise very limited restorations.¹⁵

Several in-vitro studies demonstrated that the preparation of enamel and dentin by Er:YAG laser, followed by orthophosphoric acid-etching, enhances effectiveness in terms of reduced microleakage and increased bond strength.¹⁶ Several authors have proposed the utilisation of laser technology also for the restoration of frontal teeth fractured by traumatic events.¹⁷

In some cases of frontal teeth trauma, it is necessary to perform gingival recontouring because the traumatic event has also damaged the soft tissue; in other cases, due to pulp exposure, a pulp-capping procedure is needed. In both of these clinical situations, the utility of laser therapy was demonstrated.¹⁸⁻²⁰ We prefer to use VSP Er:YAG laser technology for soft- and pulp-tissue treatments, without air/water spray and with a long pulse duration in order to transform all the energy delivered into heat, although the complementary Nd:YAG wavelength (1,064 nm) present in the same device can also be used.

The aim of this clinical study was to demonstrate the usefulness of the Er:YAG laser in the treatment of tooth fractures by showing several cases and describing the advantages of using a device based on VSP technology²¹ and an additional integrated wavelength (Nd:YAG).

Clinical cases

Case 1

A ten-year-old patient came to one of our clinics after an accident during a football game. Upon clinical examination it was evident that there was a coronal fracture of the permanent right central incisor (Fig. 1). The patient, instructed by his coach, had preserved the fractured portion of the tooth in a container of milk. It was decided to re-bond the fragment to the tooth by means of an Er:YAG laser-assisted technique after a vitality check. Both the fragment and the tooth were treated by Er:YAG laser (Fidelis Plus III, Fotona, Slovenia) with the following parameters: SSP mode, 200 mJ, 10 Hz, tipless hand-piece (Fig. 2); subsequently they were etched by or-

Fig. 7 Exposed pulp.

Fig. 8 Nd:YAG laser pulp capping.

Fig. 9 Replaced fragment after the preparation of fragment and tooth bonding surfaces with Er:YAG, SSP mode.

Fig. 10 Final result.

Fig. 11 Permanent right central incisor longitudinally fractured in the distal portion.

Fig. 12 Gingival margin recontoured with Nd:YAG laser.

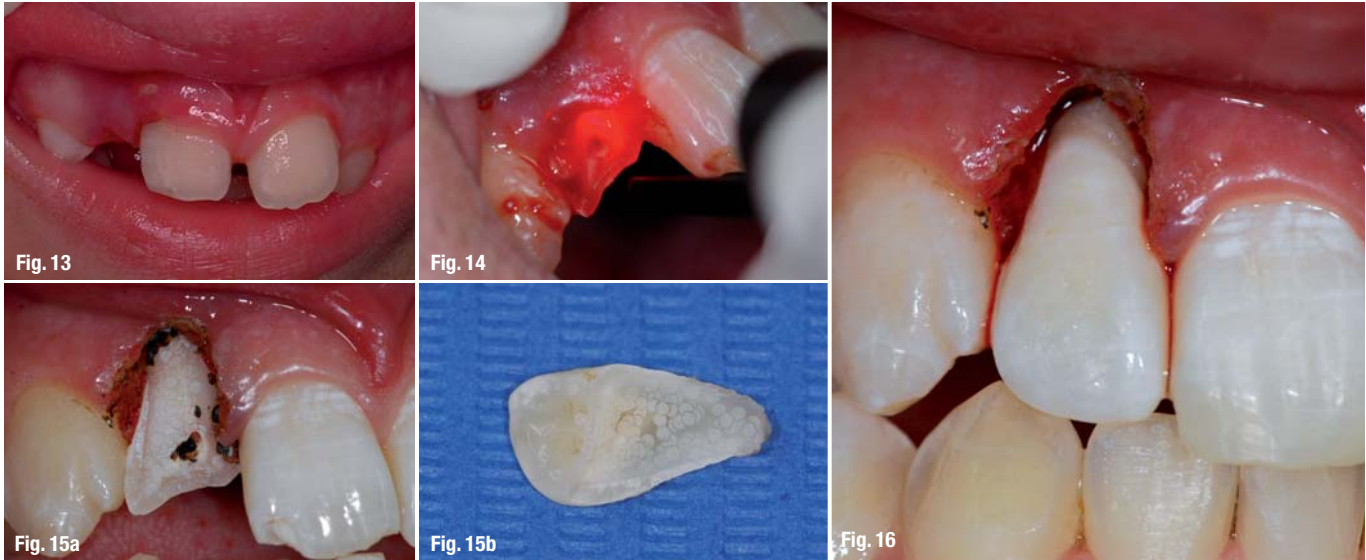


Fig. 13 Completed treatment.
Fig. 14 Gingival margin recontouring and pulp capping with Er:YAG, VLP mode.
Fig. 15a & b Both hard dental tissues prepared with Er:YAG, SSP mode before the attachment of the fragment.
Fig. 16 Completed intervention.

thophosphoric acid, after which bonding was applied and the fragment was re-positioned with flow composite resin (Fig. 3).

In the borderline surface area, these steps were all repeated to improve the aesthetic result (Fig. 4). During the whole procedure, no anaesthesia were used and the compliance of the patient was very high; he confirmed that there was no pain or discomfort. The tooth was checked monthly for six months and vitality tests were found to be positive (Fig. 5).

Case 2

A fourteen-year-old patient came to one of our clinics presenting a traumatic crown fracture of the permanent, right central incisor (Fig. 6). The patient had preserved the broken fragment in her mouth. To lessen the ordeal for the already traumatized young patient we decided to perform the treatment with the Er:YAG and Nd:YAG lasers we have at hand in our practice (Fidelis Plus III, Fotona, Slovenia). The trauma had left the pulp exposed (Fig. 7); our first decision was to perform a Nd:YAG laser pulp capping (SP mode, 4W, 40Hz, 300 µm contact fiber, Fig. 8). We then proceeded to use the same device but with another wavelength (Er:YAG) to prepare both the fragment's and tooth's bonding surfaces (SSP mode, 200mJ, 10Hz, tipless handpiece, Fig. 9). The same surfaces were further prepared with orthophosphoric acid, bonding was applied and subsequently flow composite resin was used in order to replace the fragment (Fig 10).

The Er:YAG laser played a pivotal role in this particular case; we were able to work without causing any additional pain to the patient, keeping trauma for both patient and parents to a minimum. In addition, the Er:YAG's inherent lasering effect provided decontamination and increased bond strength. For aes-

thetic purposes, we prepared the borderline surface area with Er:YAG before once more applying orthophosphoric acid and finally flow composite resin. No form of anaesthesia was deemed necessary by us or even requested by the patient. The tooth was checked monthly for six months and vitality tests were found to be positive.

Case 3

An eight-year-old patient came to our clinic with his permanent right central incisor longitudinally fractured in the distal portion (Fig. 11). He had preserved the fragment in physiological solution. After a check of the vitality and the fragment's fit to the tooth, the gingival margin was recontoured with an Nd:YAG laser (Fidelis Plus III, Fotona, Slovenia; SP mode, 4W, 40Hz, 300 µm contact fiber, Fig. 12) in order to expose all the borders of the restoration. Since it was impossible to use a rubber dam, it was decided to use the same device but with the other wavelength (Er:YAG) to prepare both the surfaces of the fragment and the tooth (SSP mode, 200mJ, 10Hz, tipless handpiece). After a total etching of the laser-irradiated surfaces, the bonding was applied and the fragment repositioned with a coat of flow composite. A LED lamp was used to polymerize the resin and abrasive discs mounted on a micro-motor were used to polish the restoration (Fig. 13).

During the intervention no anaesthetic was used and the patient confirmed the absence of pain and discomfort. The tooth was checked monthly for six months and vitality tests were found to be positive.

Case 4

An eighteen-year-old patient came to one of our clinics after experiencing a trauma on the face. During the clinical observation, damage to the right lateral permanent upper incisor was noticed. The whole

coronal portion of the tooth, while still in position, fractured vertically and in the frontal plane, and pulp tissue was exposed. It was decided to use the Er:YAG laser (Fidelis Plus III, Fotona, Slovenia) in two different ways: without air/water spray (VLP mode, 120 mJ, 15 Hz) to re-contour the gingival margin without bleeding (Fig. 14) and for pulp capping and with air/water spray (SSP mode, 200 mJ, 10 Hz) tipless handpiece to prepare the hard dental tissues in order to provide stronger adhesion (Fig. 15). After the laser preparation, a full-etching was performed with orthophosphoric acid and the attachment of the fragment was made with bonding and flow composite resin (Fig. 16). The intervention was conducted without using anaesthetics, and the compliance of the patient was good since he did not experience pain or discomfort. The tooth was checked monthly for six months and vitality tests were found to be positive.

Conclusion

Er:YAG lasers may be used in conservative dentistry as an alternative to conventional instruments and in association with orthophosphoric acid, with several advantages, such as better bond strength²² and reduced microleakage²³, as well as lower discomfort and higher patient satisfaction.²⁴ The availability of different Er:YAG pulse durations and a comple-

mentary Nd:YAG laser in the same device make interventions easier and faster.

This clinical study, even if considered as preliminary due to the limited number of samples, confirms that Er:YAG lasers can also be employed in dental traumatology to restore frontal teeth after coronal fractures, with the advantages of better cooperation from patients (in particular when young), reduced pain, sensitivity and discomfort during the restoration process, and better final results from an aesthetic point of view.

contact

laser

Carlo Fornaini

MD DMD MSc

Via Varini, 10 29017 Fiorenzuola d'Arda, PC
Italy

Tel.: +39 0523 982667

Fax: +39 0523 242109

info@fornainident.it

www.fornainident.it

AD

*become an author
for "laser"*

[PICTURE: ©SHUKYAWA]



Please contact Claudia Jahn

✉ c.jahn@oemus-media.de