

Replacement of a single anterior tooth

Surgical procedure and three-year results

Author_Dr Peter Randelzhofer, Germany

Initial presentation:

Fig. 1_ The patient had a high smile line, and tooth #11 was discoloured and had a poor prognosis.

The gingiva was thick and the interdental papillae had a high-scalloped appearance.

Fig. 2_ Radiograph showing endodontic infection of tooth #11.

Tooth extraction:

Fig. 3_ Careful extraction of tooth #11.

Fig. 4_ Good preservation of the marginal hard and soft tissue.

Fig. 5_ Intact coronal buccal bone plate: Note the thin interdental papillae. The remaining scar tissue of the former apex resection is clearly visible.

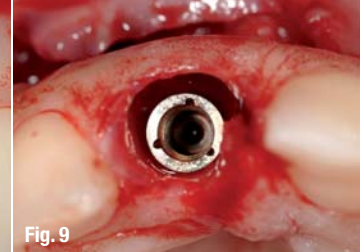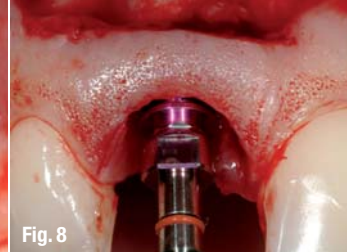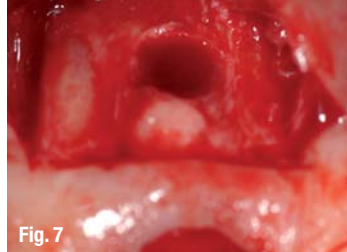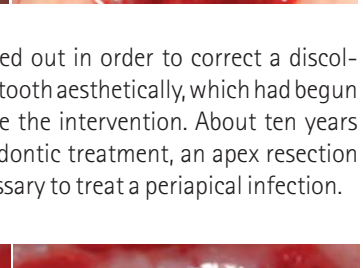
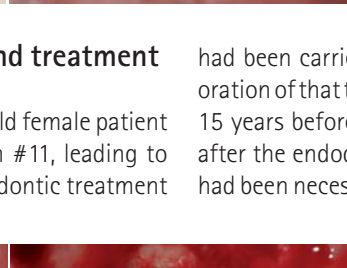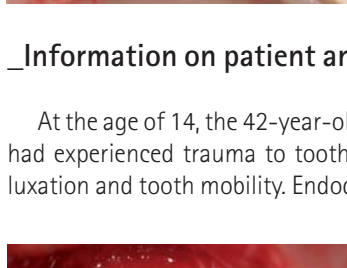
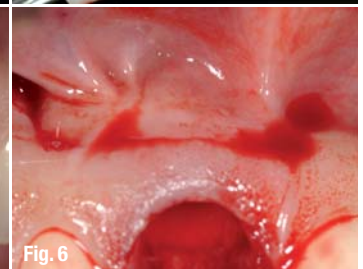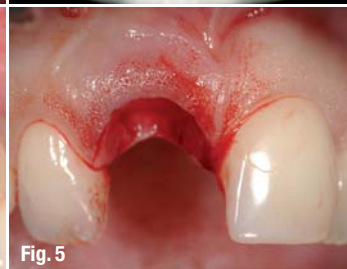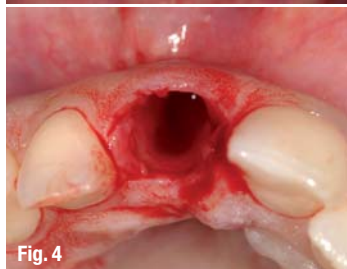
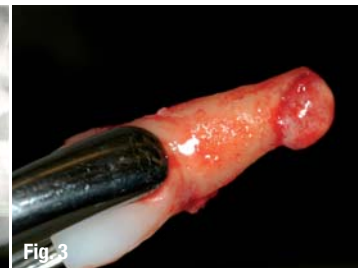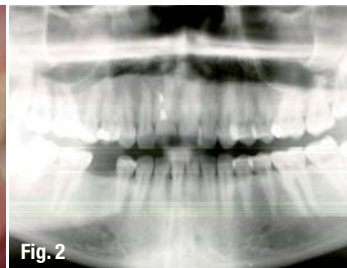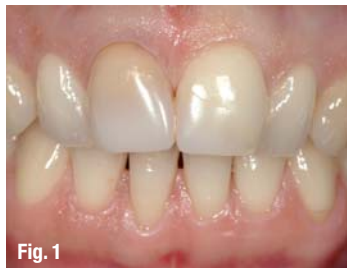Fig. 6_ After a vestibular half-circle incision in the apical part of the keratinised gingiva, a flap was reflected downwards.

Fig. 7_ The apical bone defect is visible. Granuloma tissue and endodontic material were accurately removed with the help of a magnifying glass.

Implant placement:

Fig. 8_ Accurate 3-D placement of a 4.3 mm diameter implant.

Fig. 9_ The implant was inserted with a palatinal orientation and a minimum distance of 2 mm to the buccal bone plate in order to prevent its resorption. The implant depth was 2 mm below the gingival sulcus and was dependent on the sulcus of tooth #21. To achieve a primary stability of a minimum of 35 Ncm, the final drill was not taken to its maximum depth.



Information on patient and treatment

At the age of 14, the 42-year-old female patient had experienced trauma to tooth #11, leading to luxation and tooth mobility. Endodontic treatment

had been carried out in order to correct a discoloration of that tooth aesthetically, which had begun 15 years before the intervention. About ten years after the endodontic treatment, an apex resection had been necessary to treat a periapical infection.

FDI 2013 Istanbul Annual World Dental Congress

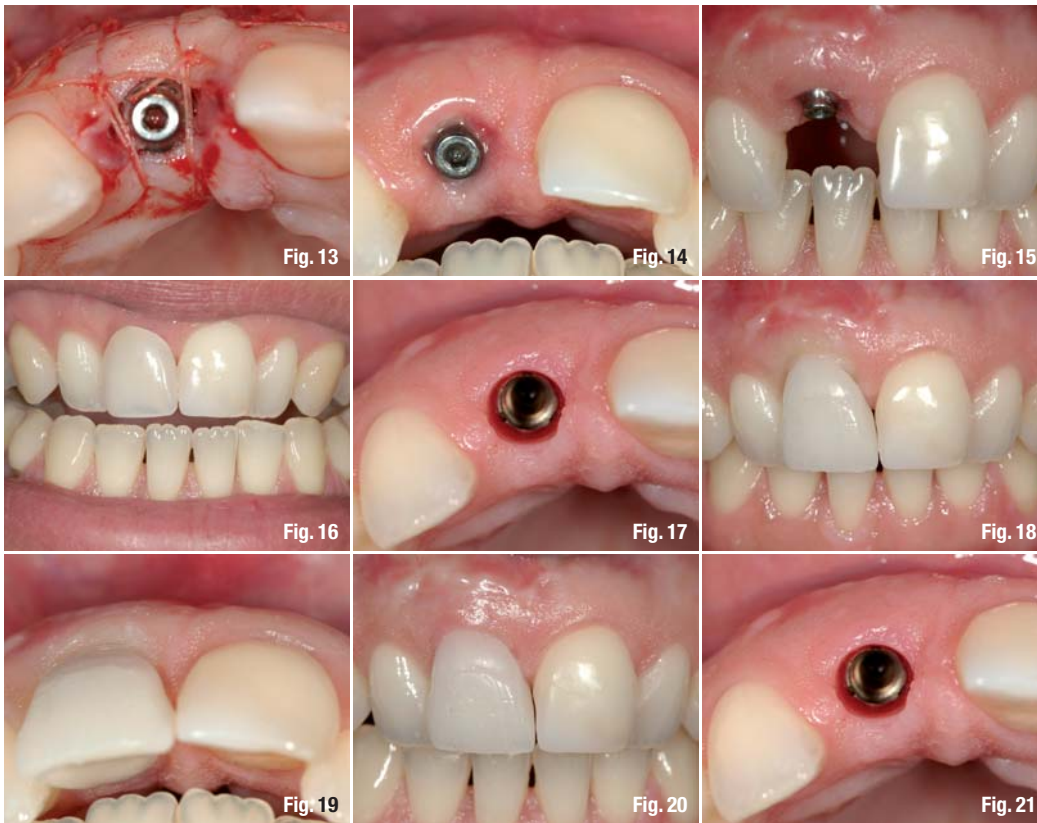
28 to 31 August 2013 - Istanbul, Turkey

Bridging Continents for Global Oral Health



2013 ISTANBUL

www.fdi2013istanbul.org
congress@fdi2013istanbul.org



Owing to pulsating pain and the previous endodontic treatment, the tooth was considered hopeless with regard to an optimal long-term outcome and was to be extracted. The X-ray examina-

tion confirmed a chronic infection around the apex. The soft tissue was intact with a satisfactory attachment level to the neighbouring teeth. The quality of the rather thick gingiva was good. The incision

Bone augmentation:

Fig. 10_Augmentation of the remaining spaces between the 4 mm bottle-neck healing abutment and the buccal bone plate with Bio-Oss particles (Geistlich).

Fig. 11_Additional augmentation of the apical bone plate with grafting material. Use of a membrane was not necessary because of the anatomical shape of the defect.

Fig. 12_Primary wound closure with 5.0 resorbable vicryl sutures. The apical flap was closed conventionally.

Fig. 13_The bottle-neck design of the transmucosal abutment enabled a tensionless wound closure.

Healing:

Fig. 14_Four weeks post-op: Good soft-tissue healing and gingival adaptation around the bottle-neck abutment.

Fig. 15_Stable papillae, nicely preserved soft-tissue volume. The temporary crown was used to establish a natural sulcus around an implant crown.

Fig. 16_The removable provisional, used by the patient for the four-month healing period, showed adequate gingival height for a functionally and aesthetically acceptable result.

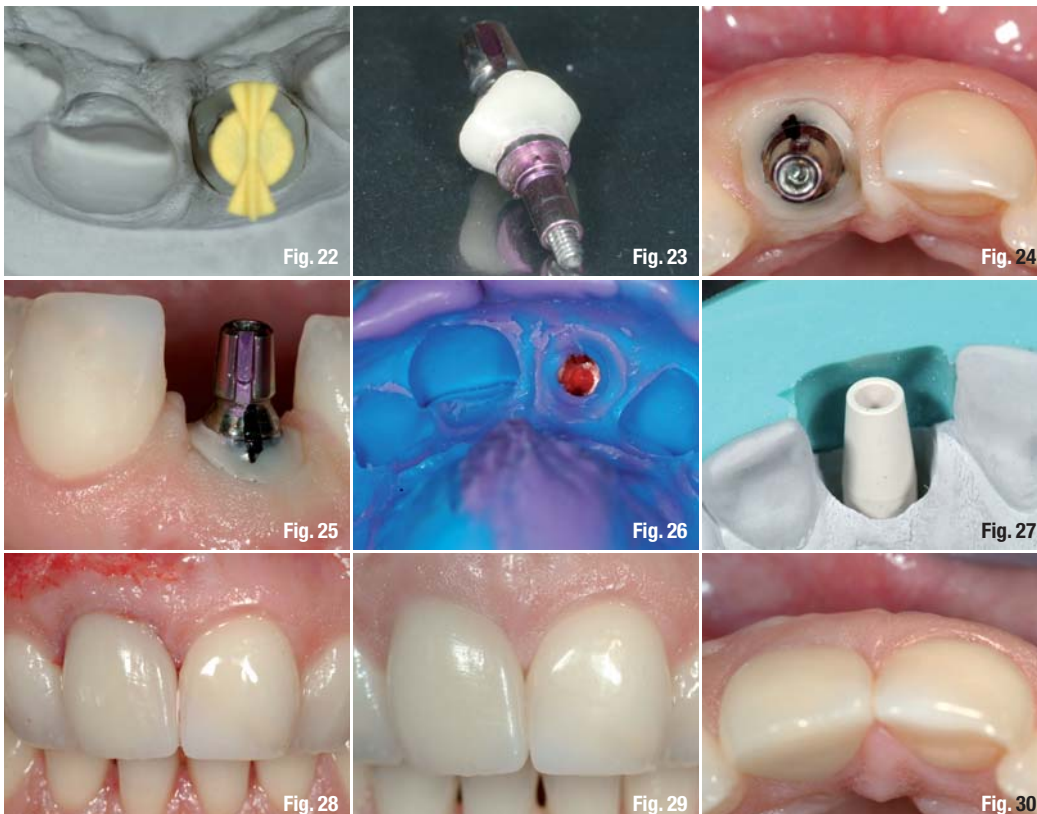
Fig. 17_Nicely healed and healthy soft tissue around a well-integrated implant, replacing tooth #11. The absence of scar tissue thanks to the flap design is obvious.

Soft-tissue management:

Fig. 18_Placement of a temporary crown with soft-tissue management for a natural looking emergence profile. The submerged part of the occlusal screw-retained crown (concave tulip-shaped design) supported the subgingival soft tissue.

Fig. 19_The screw channel (perforating the labial part of the crown) was covered with a composite inlay. Farther apically, the scar tissue from the earlier apex resection was easily removed.

Fig. 20_Natural-looking emergence profile. The mesial part needed to be built up a little more.



Impression taking and prosthetic reconstruction:

Fig. 21_Clinical situation before impression taking.

Fig. 22_The ideal emergence profile of the temporary crown was copied with an individual impression post and reproduced on the master model.

Fig. 23_Individual impression post.

Fig. 24_Individual impression post placed on the implant and the opening of the sulcular structures.

Fig. 25_Lateral view of the implant with impression post.

Fig. 26_Impression tray capturing the crown-gingiva interface.

Fig. 27_Master model with temporary abutment and silicone index showing the preservation of the backward-planning information.

Fig. 28_IPS e-max crown (Ivoclar Vivadent) immediately after definitive placement on the individualised ceramic abutment with PANAVIA cement (Kuraray). The apical scar tissue was shaped with a diamond drill for a smoother gingival outcome.

Result after one year:

Fig. 29_Final result one year after implant placement. The soft tissue shows a stable and near-perfect interface with the implant crown.

Fig. 30_Optimal tissue contour.

Results after three years:

Fig. 31_Stable soft tissue showing no resorption at the implant-crown interface or gingival sulcus.

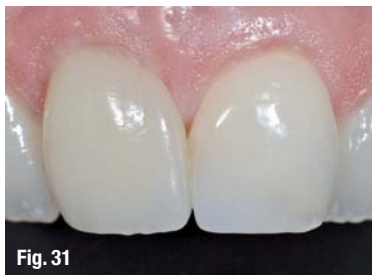Conclusion:

Fig. 32_Initial situation before extraction.

Fig. 33_Initial situation with non-preservable tooth #11.

Fig. 34_Clinical situation three years after implantation.

Fig. 35_Final X-ray after one and three years.



for the apex resection had resulted in scar tissue at the junction of the keratinised and non-keratinised gingiva. Tooth #21 had been filled with a four-side composite filling at the mesial side.

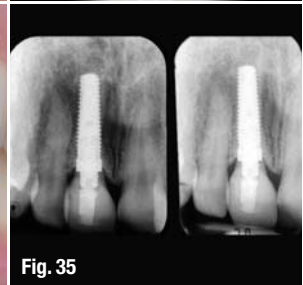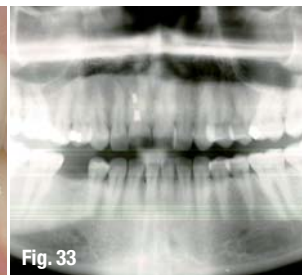
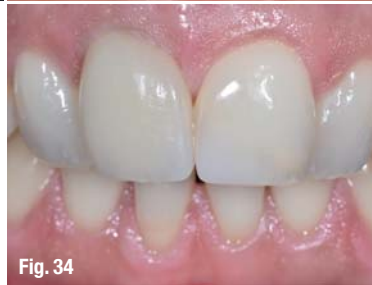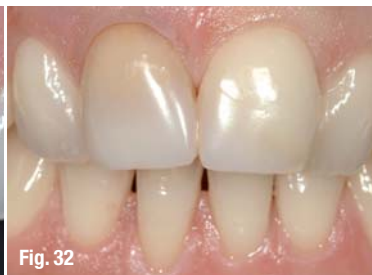Since the expectations of the patient regarding the aesthetic outcome were very high, we decided on immediate implant placement with a CAMLOG SCREW-LINE Implant after extraction of tooth #11. The soft- and hard-tissue structures were preserved as far as possible. Bone augmentation was performed at the time of implantation to treat the bone defect. The prosthetic treatment was to take place three to six months post-operatively, depending on the size of defect.

Conclusion

Implant-borne reconstruction of missing anterior teeth is challenging, especially in fresh extraction sockets. For a functionally and aesthetically stable outcome, sufficient hard and soft tissue is needed. Care has to be taken to preserve the existing tissue structures. Vertical and horizontal bone loss after insertion of the implant due to remodeling processes has to be taken into account.

In the present case, the patient had high expectations regarding the aesthetic outcome. An alternative treatment of this case would have been a bridge solution combined with augmentation of the pontic area. Such a solution would have held fewer risks and allowed achievement of a more predictable soft-tissue situation. The patient was informed of the risks and alternatives. However, she decided on implant reconstruction.

We aimed to preserve the soft- and hard-tissue structures to achieve an adequate level of marginal gingiva together with an adequate interdental bone peak. Therefore, we decided on immediate implant placement after extraction of tooth #11, creating optimal soft- and hard-tissue structures around the implant at the time of implant placement. The soft tissue around coronal part remained untouched and the coronal aperture was closed with a trans-



mucosal abutment. The flap preparation was performed in the apical region only. This technique was chosen to provide the best possible interface between crown and gingiva.

We were able to achieve an ideal 3-D positioning of the implant and an optimal aesthetic result that was still stable after three years.

_about the author

cosmetic
dentistry



Dr Peter Randelzhofer

studied dentistry in Munich, Germany, and received his training in prosthetics and implant dentistry at the University of Freiburg, Germany. In 2001, he was appointed Assistant Director of the Centre for

Implantology and Periodontology, a private practice in Amstelveen, Netherlands. In 2002, he received his certification as an implantologist from the NvOI (the Dutch oral implantology association). From 2005 to 2009, he worked at the Centre for Implantology and Periodontology. In 2009, he founded the group practice for implantology and periodontology in Munich, Germany, together with Dr Claudio Cacaci. Dr Randelzhofer is author of numerous publications and he is an internationally renowned speaker. He is active as a trainer and teacher at various institutions in the Netherlands and Germany, and he is a member of several national and international study groups.

Implantat Competence Centrum in München

Weinstraße 4
80333 Munich
Germany