

cosmetic

dentistry _ beauty & science

4²⁰¹²

| **CE article**

The digitized occlusion:
Using something old with something new

| **special**

Cost effectiveness in implant dentistry

| **case report**

The same-day tooth:
From the diagnosis to the final restoration

0377113



Includes indication for
implant restorations!

**Easy to remove –
hard to forget!**



PANAVIA™ SA CEMENT

The self-adhesive resin cement – easy to clean up
excess material whilst creating a strong bond.



SA CEMENT Automix by Kuraray has now been relaunched as part of the PANAVIA™ brand with an expanded range of indications including cementation of restorations on implant abutments.

PANAVIA™ SA CEMENT Automix is a dual-curing, self-adhesive resin cement in an auto-mix syringe for routine restorations - the guarantee for you and your patient's satisfaction. The easy removal of the excess paste reduces the risk of injuring the gingival sulcus and damages of the prosthetic.

This is due to Kuraray's adhesive technology based on a proprietary adhesive phosphate monomer "MDP". This unique adhesive monomer from Kuraray provides high bond strength and secures low technique sensitivity for consistent, reliable results. The high mechanical stability gives excellent marginal seal for long lasting restorations.

The PANAVIA™ brand can look back on a scientific and clinical track record spanning more than 25 years!

Dear Reader,

_As the **Co-Editor-in-Chief** of the official journal of the Asian Academy of Aesthetic Dentistry (AAAD), I am very pleased to announce that the 12th AAAD and 23rd Japan Academy of Esthetic Dentistry (JAED) joint meeting was held in Sapporo, Japan, from 20 to 22 July 2012 under the great leadership of Dr Hisashi Hisamitsu (President of AAAD) and Dr Akira Senda (President of JAED). The scientific programme, including lectures, poster presentations and hands-on workshops, was very well received by the attendees and the social events cultivated a comfortable environment in which to foster friendship among international colleagues.

Many changes, as we well know, are taking place in the dental profession. One of the most significant paradigm shifts in aesthetic dentistry is the emphasis on colour science. Colour measurement of human teeth and restorative materials has become an integral component of both clinical practice and dental research. This change can be traced back to several pioneers who contributed their knowledge and passion to the art and science of colour: Dr Bruce Clark in the 1920s and 1930s, Dr Robert Sproull in the 1960s, Dr Jack Preston and Dr Stephen Bergen in 1970s.

The same passion of these colour pioneers has been kept alive by the Society for Color and Appearance in Dentistry (SCAD), which was founded in 2008 as a consortium of dental professionals and other experts interested in the area of aesthetic dentistry specifically related to scientific investigation and the relationship between colour and appearance. As an active member of SCAD, I personally value the SCAD colour training program (Dental Color Matcher), which is available free online (www.scadent.org). Dental Color Matcher already has thousands of users from over 100 countries. It is a very useful tool for teaching dental students or for continuing education for dental professionals. Therefore I would like to encourage all readers interested in colour related to dentistry to read the 2012 SCAD meeting report which will appear in the next issue.

In this year's last issue of **cosmetic dentistry**, we have virtually kept the best for last. This issue will especially attract our readers interested in implantology. The beautifully illustrated and documented articles cover the whole scope, including diagnosis and treatment planning, surgical procedures and long-term results. Also of interest is the evaluation of cost effectiveness in implant dentistry.

I sincerely hope that you will enjoy this edition and apply your new knowledge to your daily practice successfully. Finally, I would like to thank our valued readers, contributing authors, supporting companies and the **cosmetic dentistry** team for their great support in making our magazine so outstanding!

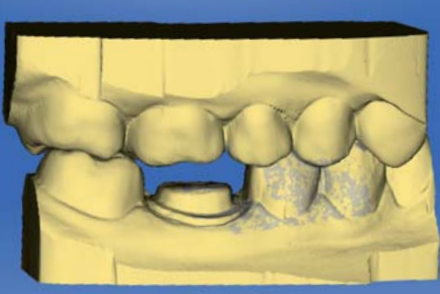
Yours faithfully,



Dr So Ran Kwon
Co-Editor-in-Chief
President, Korean Bleaching Society
Seoul, Korea



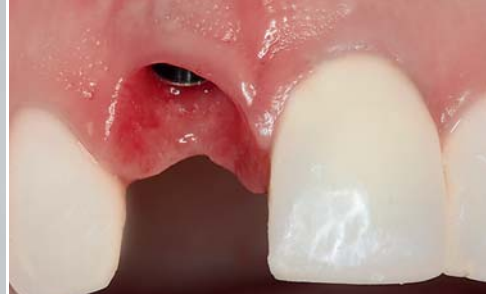Dr So Ran Kwon
Co-Editor-in-Chief



page 6



page 14



page 24

| editorial

03 **Dear Reader**

| Dr So Ran Kwon, Co-Editor-in-Chief

| CE article

06 **The digitized occlusion:**

Using something old with something new

| Dr Todd Ehrlich

| special

14 **Practical periodontics** in daily practice

| Dr Amit Patel

18 **Cost effectiveness** in implant dentistry

| Prof. Mauro Labanca

| case report

24 **The same-day tooth:**

From the diagnosis to the final restoration

| Dr Stefanos G. Kourtis

30 **Replacement of a single anterior tooth**

Surgical procedure and three-year results

| Dr Peter Randelzhofer

34 **Modified clinical approach** for improved aesthetics in full-arch restoration

| Dr Henriette Lerner, Germany, Prof. Z. Jacobson & Dr Hugh Flax

| industry news

39 **CLEARFIL DC CORE PLUS KIT:**

Stressless and reliable

| Kuraray

| meetings

38 **ESCD & SSER joint meeting** in Bucharest

—Some say “the best!”

| Dr Philip Lewis

40 **International Events**

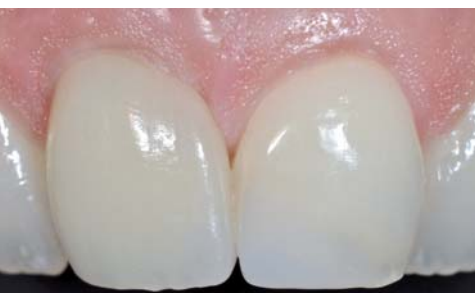| about the publisher

41 | submission guidelines

42 | imprint



Cover image courtesy of Galina Deinega.



page 30



page 39

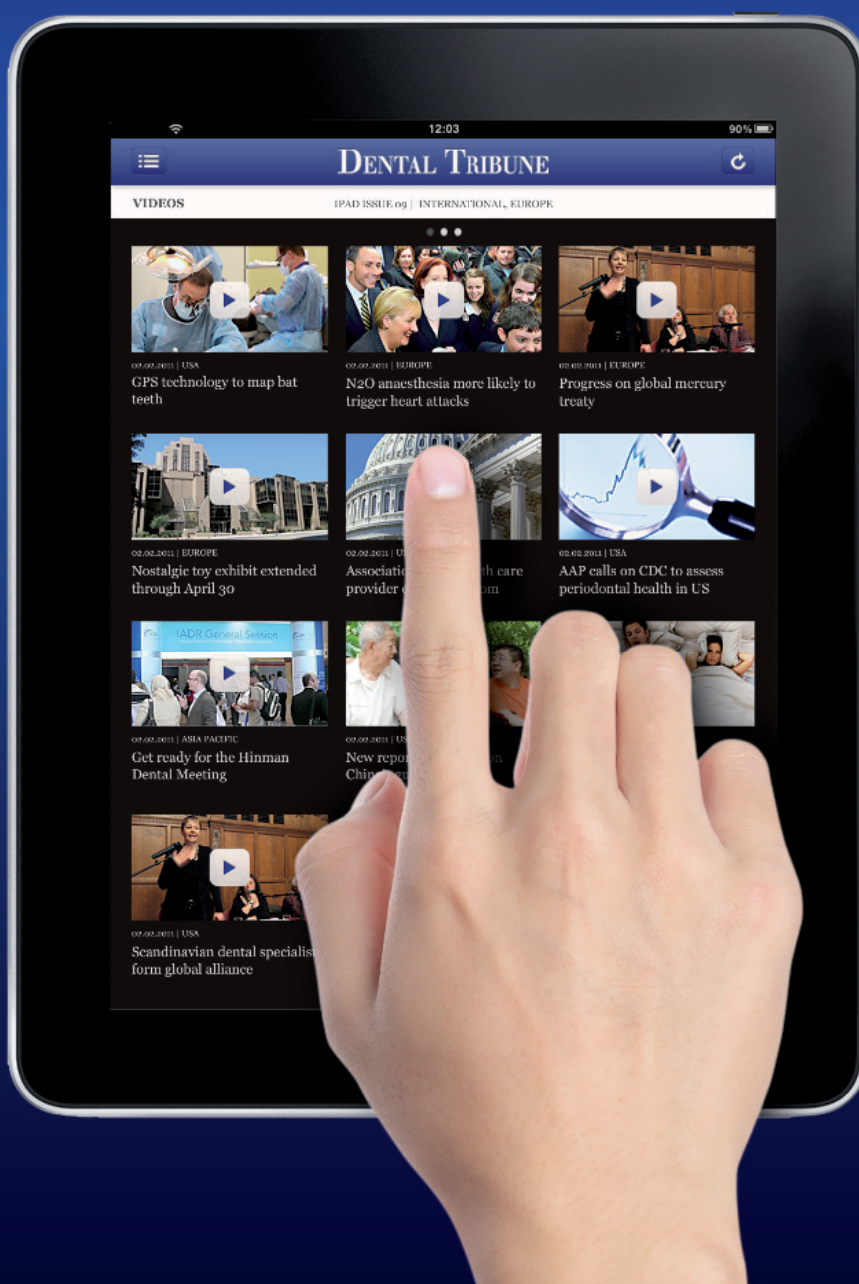

page 40

Dental Tribune for iPad – Your weekly news selection

Our editors select the best articles and videos from around the world for you every week. Create your personal edition in your preferred language.

ipad.dental-tribune.com



The digitized occlusion: Using something old with something new

Author_Dr Todd Ehrlich, USA

Fig. 1_Tooth #30 being designed in the CEREC Software 4.0.

Fig. 2_The Biogeneric calculation evaluates adjacent teeth or user-defined teeth.

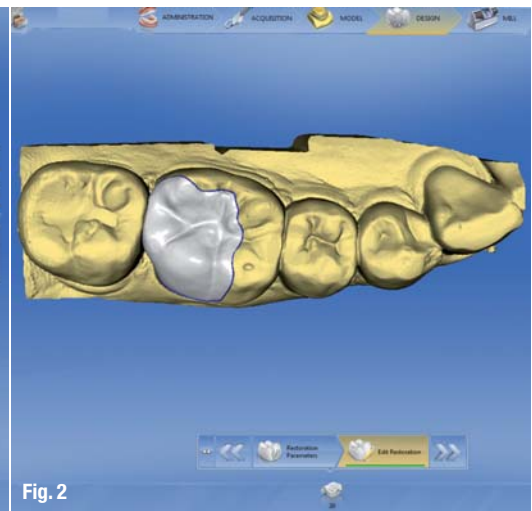
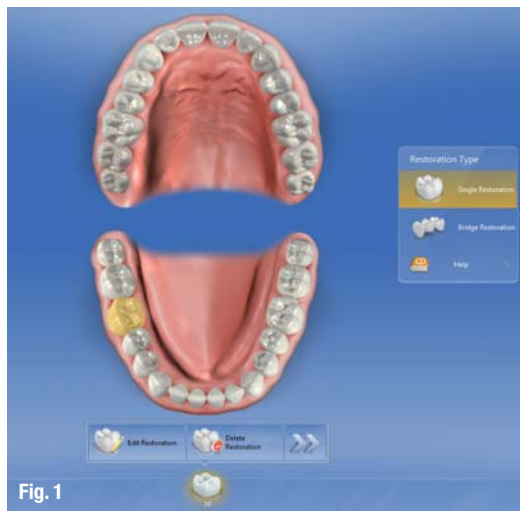


Fig. 3_Occlusal and interproximal contacts are also taken into consideration.

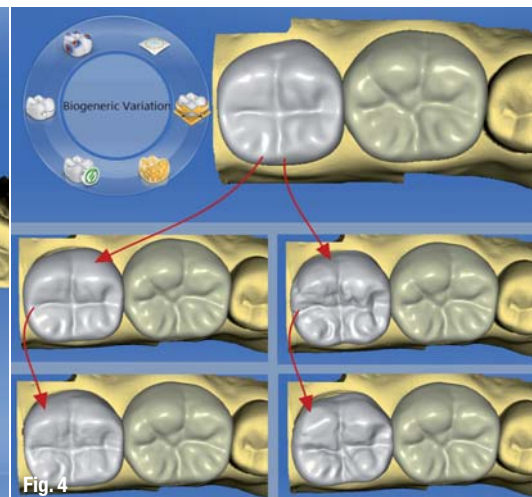
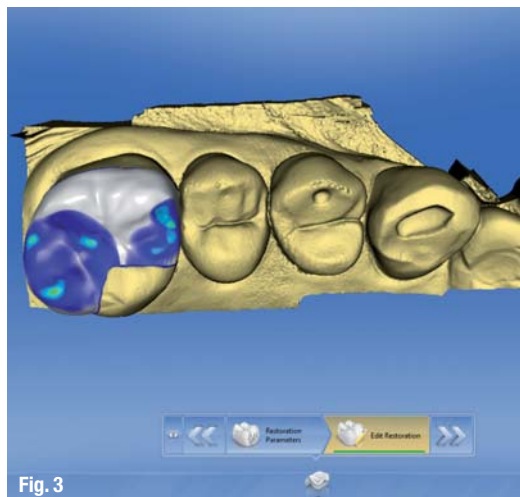
Fig. 4_The clinician has control of the "Biogeneric Shape" by scrolling through its database of teeth.

_There is an envelope of occlusal function that we are constantly mastering for our patients. Many times it is exceptionally easy to find a position or shape of a tooth that fits within the patient's comfort and functional zones. However, there are many instances where it can be quite challenging. Using something old with something new can be of great assistance to achieving a

restorative shape that the patient will immediately find comfortable.


_Using something new

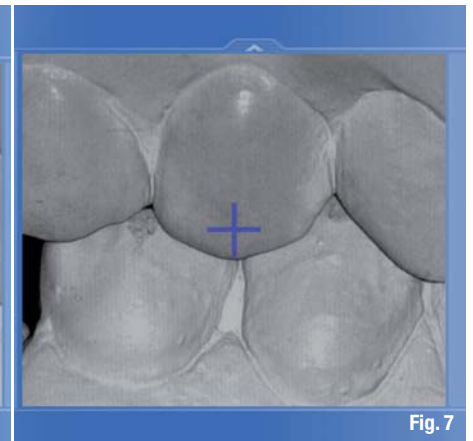
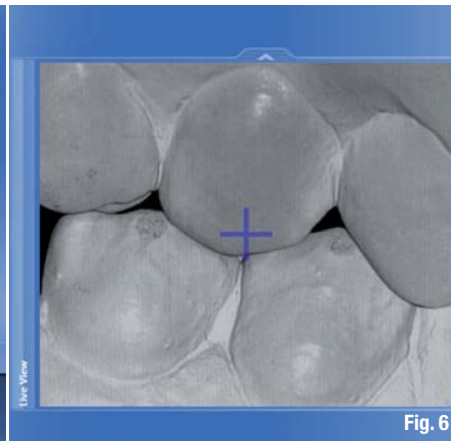
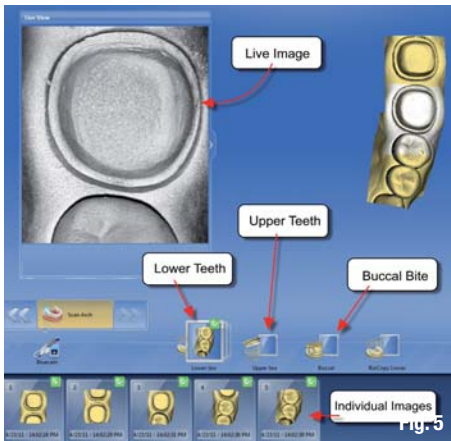
Computerized dental anatomies have greatly evolved over the years. There was a time during CAD/CAM computer design where only limited



_ce credit **cosmetic dentistry**

By reading this article and then taking a short online quiz, you will gain one ADA CERP CE credit. To take the CE quiz, visit www.dtstudyclub.com. The quiz is free for subscribers, who will be sent an access code. Please write support@dtstudyclub.com if you don't receive it. Non-subscribers may take the quiz for a \$20 fee.





anatomies were available, and these patterns had to be manipulated greatly by the doctor to fit the clinical situation. This made for a longer design time and, most importantly, made the restoration appear more natural.¹ Today, there are more advanced mathematical calculations for dental anatomy.

Modern tooth-modeling software uses a database detailing the measurements of several thousand naturally occurring tooth samples. Common structures such as cusp tips, cusp slopes, marginal ridges and fissures give the blueprint for computer determination of the "average tooth." The differences between this average tooth and the scanned referenced teeth make up the core for the mathematical calculation, much like with facial recognition software used by government intelligence agencies. Analysis reveals that only 20 data location points are necessary to describe 83 per cent of the variability in naturally occurring tooth surfaces.^{2,3,4,5} This mathematical calculation for tooth morphology therefore predicts the virgin state of the tooth.

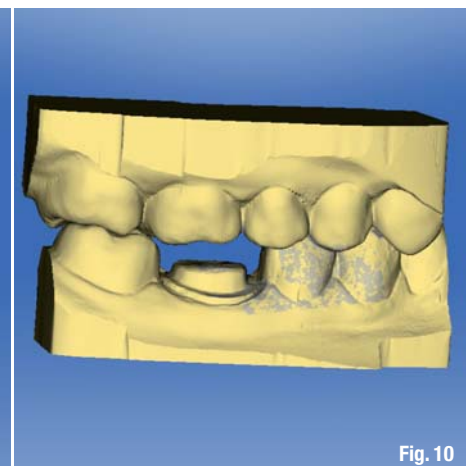
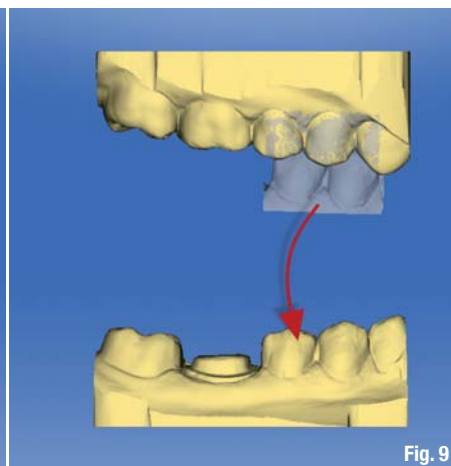
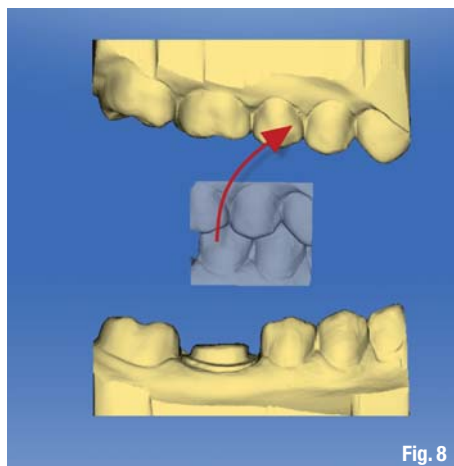
It has been shown to have a digitally proposed surface within 156 μ of the original surface.¹ Be-

cause the described process obtains its results through data derived from naturally occurring teeth, the method is referred to as "Biogeneric tooth modeling."^{2,3}

This mathematical calculation of dental anatomy starts with designating the tooth number to be designed. This establishes which database of dental anatomies that it will use to determine the calculations. In other words, the true tooth number needs to be selected for the calculation, or a different tooth number anatomy will be generated (Fig. 1).

The next step for the calculation is to show the computer a tooth that it can use for guidance on the proposed design. This can be done a couple of ways. Primarily, a tooth within the prepared quadrant (not the prepared tooth) will be analyzed automatically by the computer, and is typically the distal neighbor of the prepared tooth (Fig. 2). If the clinician knows of a better tooth to reference, this can easily be selected within the prepared arch, within another area of the dentition, or even off a model. This referenced dataset will trigger the computer to search the entire database, which may contain hundreds of different virgin anatomies for that particular tooth number.^{2,3,4}

Fig. 5 Digitally scanned teeth are organized into specific libraries.
Fig. 6 During imaging, the position of the upper and lower teeth is not correct and space is seen.
Fig. 7 The dentist sees the error and instructs the patient to close properly.



Figs. 8 & 9 The buccal bite images are used to articulate the upper and lower models.
Fig. 10 The digital articulation is completed.

The computer proposal will morph into various shapes as it is going through the calculation. It also looks for ratios of tooth size and position within the arch. This is a great advantage, because these digital dental anatomies are not limited by size, but can fit within any range of tooth dimensions. The finalized digital anatomy is a reflection of what the computer discovered through its analysis of the reference tooth. It also places the three-dimensional shape in contact with the opposing teeth (Fig. 3). If the clinician would like to see variations of the Biogeneric calculation, a slider allows that to happen. This tool is referred to as "BiogenericVariation." If images have to be re-taken, "BiogenericVariation" is the new name (Fig. 4). The slider travels through

There are never any tears or bubbles with digital impressions. They also never distort. Therefore, they have tremendous value to the doctor and the patient, especially because the images are taken so easily and within a minute. After the upper and lower arches are captured, they are articulated by images taken from the buccal direction.

The articulation for the upper and lower jaws is done in a static maximum intercuspation position utilizing what is referred to as the "buccal bite." This would be similar to a triple tray type using physical impression material, but by doing it digitally, the position never changes. Articulation of the models is completed within the software, and the maximum intercuspation position is always repeatable. There is never flex or variation with the articulator because of its digital nature. Therefore, if taken correctly, the buccal bite can place the maxillary and mandibular teeth in a very specific position that can be designed to within microns of space.⁵ Another major advantage of an optical buccal jaw registration is that the position can be seen in the computer as the scan is taking place, much like when preparation images are being taken.

How many times does a patient try and help the procedure by biting toward the area of work during an impression? Or, can you even find their centric occlusion through impression material and while anesthetized? The relation is hidden under physical impression material, and may not be realized until physical stone models are mounted on an articulator. However, with digitally scanned articulation, it can easily be seen that it may be incorrect, or the jaws are not stable, during the imaging (Fig. 6). The clinician simply stops the scan, coaches the patient into the proper position, and then scans again (Fig. 7). This greatly enhances the predictability of occlusion of the final restoration.

The operator takes control of the articulation of the three models: upper, lower and buccal bite. The buccal bite is dragged to the corresponding portions of the upper and lower models. The software then recognizes similar surfaces and "shrink wraps" the buccal bite down. The same is done for the opposing arch. This establishes the digital maximum intercuspation position within the software (Figs. 8-10).

The repeatable digital maximum intercuspation position also allows for multiple units to be designed in a highly predictable manner. Whether the restorations are being designed side by side or from one arch to another, the occlusal morphology and pinpoint placement of occlusal stops can be confidently placed knowing the arches are stable within the digital world.

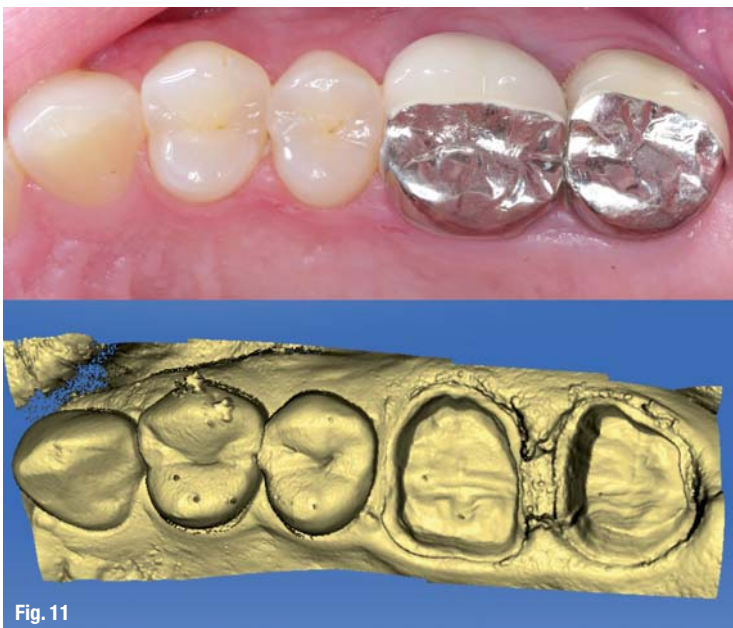


Fig. 11

Fig. 11 _The prior crowns are removed and teeth prepared.

anatomies within the Biogeneric database and reveals them through morphing of the proposal. This allows for a truly customized shape for the clinical situation, and within function.

Digital scanning

During the course of treatment, the upper and lower arches or quadrants are scanned into the computer using the CEREC Bluecam digital scanning camera. The CEREC system can have multiple preparations within the same arch or in opposing arches. Each arch is saved in its corresponding library of images within the software and evaluated for quality of margin integrity, path of draw, preparation geometry, etc. (Fig. 5). The major advantage of digital impressions is that the physical impression is eliminated from the process. This allows for immediate feedback to the clinician if the information is correct, rather than waiting to evaluate the inverse of the physical impression many minutes later.

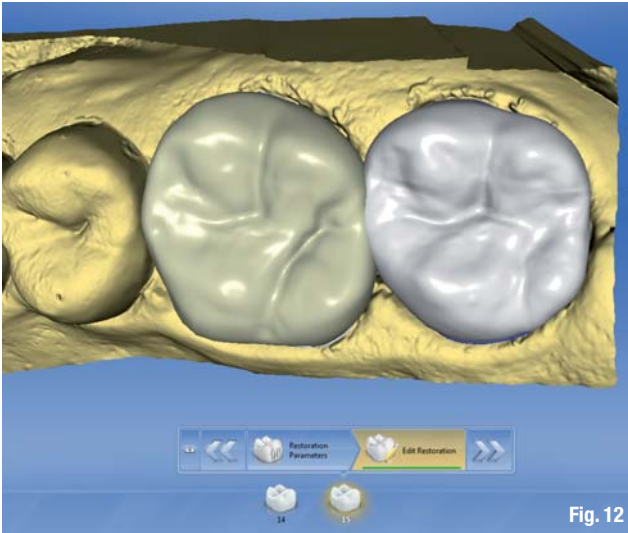


Fig. 12

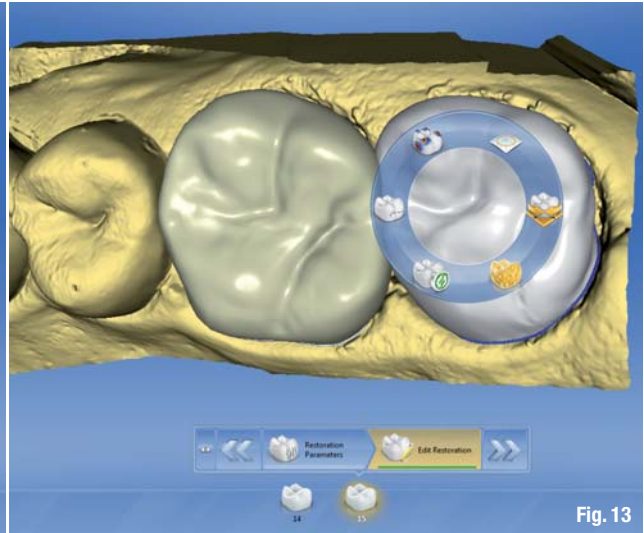


Fig. 13

_Case 1

A 45-year-old female presented with two porcelain-fused-to-metal crowns with recurrent caries on tooth numbers 14 and 15. They were estimated to be about five years old. Her chief complaint was that it was difficult to floss between them. Clinically, the crowns had very tight interproximal contacts and closed embrasures. Dental floss was nearly impossible to penetrate through the contact, and recurrent caries subsequently developed (Fig. 11). The crowns were removed, core build-ups completed, and the intraoral scans taken:

- _Preparation quadrant (upper left);
- _Opposing quadrant (lower left);
- _Buccal bite images.

The models within the CEREC Software 4.0 were articulated, and the Biogeneric calculation was com-

pleted for the two teeth. Because the interproximal contacts were of utmost concern for the patient, both designs were manipulated at the same time to achieve better contact strength and embrasure shape. The interproximal contact between 13 and 14 was designed to mimic the same shape between 12 and 13. The initial Biogeneric proposal for #15 placed the mesial portion into the distal of #14 (Figs. 12, 13). Right-clicking the proposal brought up the myriad of tools to adjust the proposal (Fig. 14). A tool was selected that would reposition just the mesial portion of #15. It could then be repositioned in any direction (Figs. 15, 16). It was simply moved distally. A broader contact was established between the two designs, but with better embrasures than the prior crowns. Minor customization of the occlusal scheme was then done.

The digital crowns were milled with CEREC's MCXL milling chamber out of IPS e.max CAD blocks (Ivoclar Vivadent). Each crown milled in roughly 10 minutes

Fig. 12_The initial proposals for 14 and 15 were excellent; however, 15 encroached into 14. **Fig. 13_**A design tool wheel emerges when right-clicking on the design.

Fig. 14_The mesial portion of 15 was selected for movement. **Fig. 15_**The mesial portion was moved into the appropriate position.

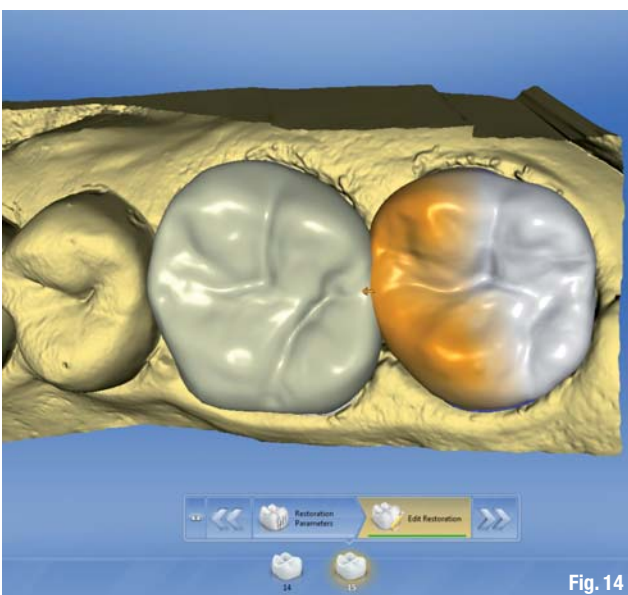


Fig. 14




Fig. 15

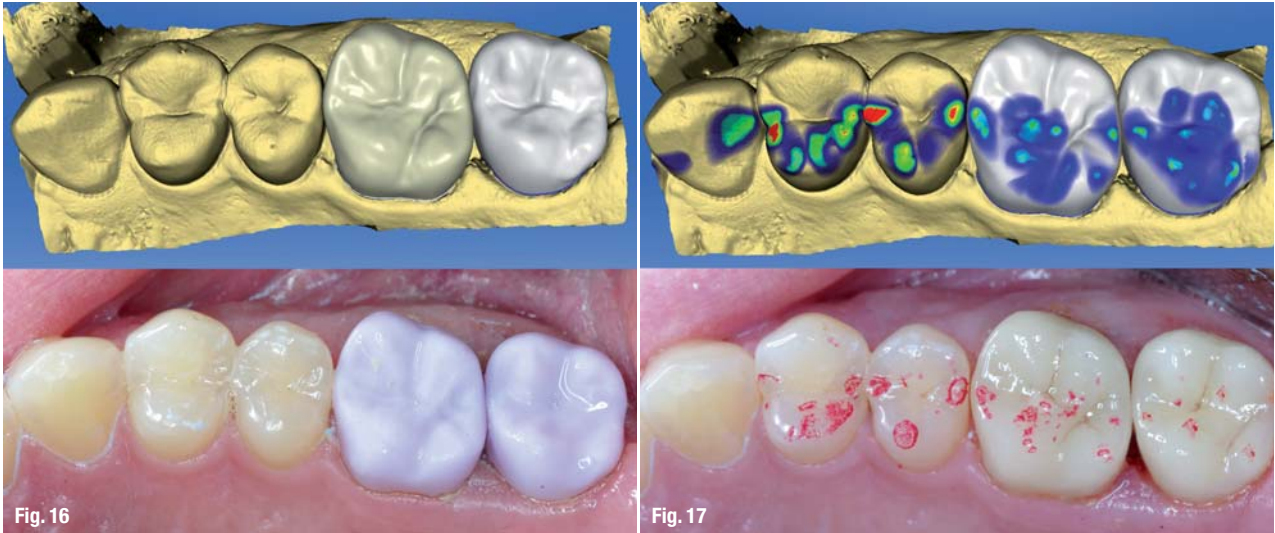


Fig. 16

Fig. 17

Fig. 16_A comparison of the final Biogeneric anatomy and milled IPS e.max CAD prior to firing.
Fig. 17_A comparison of the finalized CEREC occlusal contacts with occlusal contacts made intraorally.

and they were tried in to evaluate fit and interproximal contact. The crowns were then fired in a ceramic oven CS (Ivoclar Vivadent) to convert the lithium metasilicate material ("blue block") into the final lithium disilicate structure known as e.max (colour conversion and glazing also occurs during this process).

The crowns were removed from the oven, tried in and inserted. Because of the accuracy of CEREC's design calculations, easy modification methods and milling accuracy, no adjustment was required for this case (Fig. 17). The patient was shocked that there were no adjustments, as she remembered multiple adjustments being made for her prior restorations. She was quite pleased with the result.

clusal pattern of the old restoration may not have detailed anatomy, but it most likely has the occlusal guidance paths already worked out over many years of service. For instance, a tooth may have a very large amalgam restoration with recurrent caries that requires replacement. Although failing, it has tremendous value to the design steps in the CAD software. The surfaces of the restoration have the occlusal motion paths developed over it (Fig. 18). Using the pre-operative surface as a guideline for a digital restoration could very well aid in preventing occlusal interferences from being designed into the restoration. This is a feature within the CEREC program, and is referred to as "Biogeneric Copy." This is an alternative method from the Biogeneric Tooth Model "Biogeneric Individual" with buccal bite articulation.

Fig. 18_An old restoration may still have valuable occlusion information.
Fig. 19_The preoperative model is spliced with the preparation model during imaging.

Using something old

Many times, large direct restorations will fail and eventually require an indirect restoration. The oc-

The pre-operative occlusal pattern is easily scanned into prior to treatment. This is usually done while waiting for anesthesia, and is done similarly

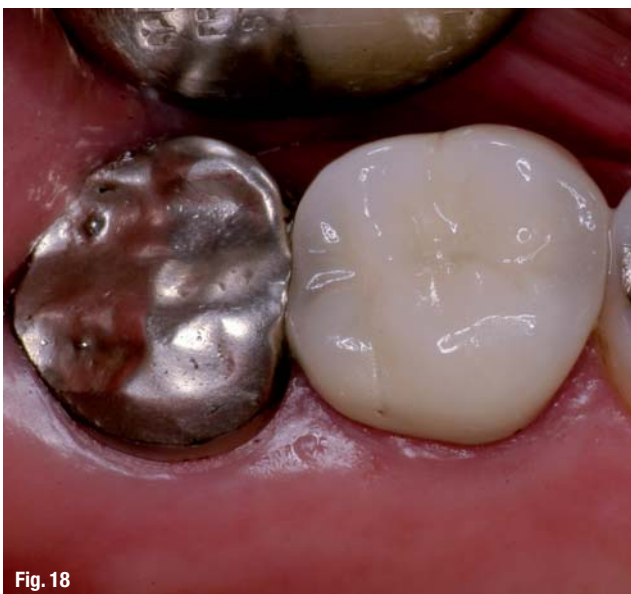

Fig. 18

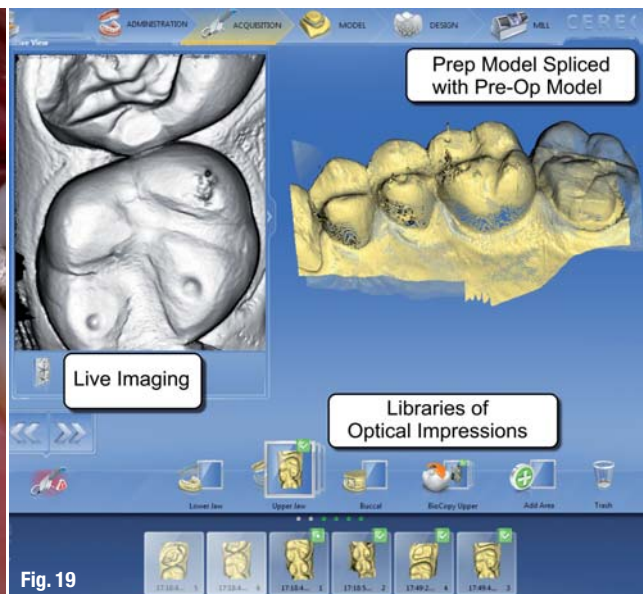


Fig. 19

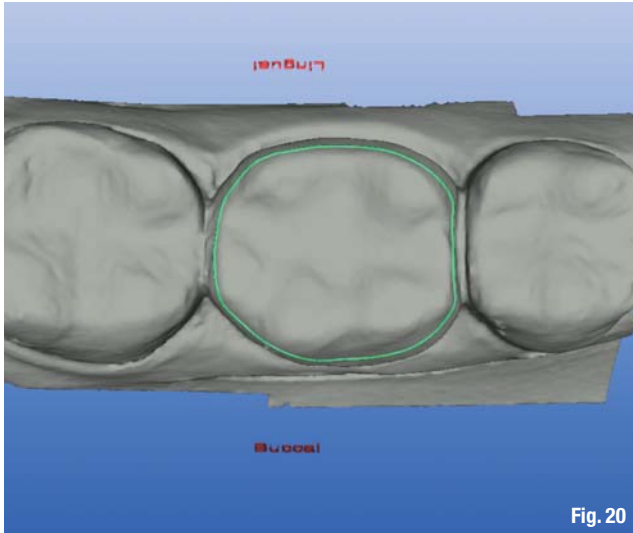


Fig. 20

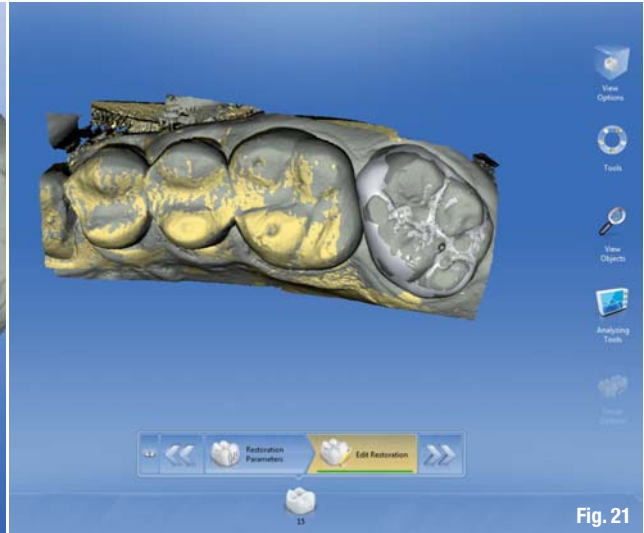

Fig. 21

to a physical impression to be used for a provisional restoration. A pre-operative scan must accurately capture the three-dimensional shape of the soon-to-be-prepared tooth, along with adjacent teeth. Crossing the midline is not usually necessary unless working on anterior teeth. The adjacent teeth's anatomies are used as stitching abutments within the software. This means that the pre-operative model will be compared with the prepared tooth digital model and the two models are spliced three-dimensionally (Fig. 19). If the stitching abutments within the preoperative model and the prepared model were not the same or lacking data, the models would not be able to be spliced. The scanned data is saved within the program and used later during the restoration design phase.

The design phase of Biogeneric Copy is simply drawing a zone for which the computer will duplicate (Fig. 20). Then the design is manipulated as the clinician sees fit. Decisions can be made for resto-

ration shape while comparing the proposed design to the pre-operative scan taken before tooth preparation. The pre-operative surface is essentially a shell to construct the digital design of the restoration. The Biogeneric calculation determines the rest of the areas outside of the copied zones. The design (in white) is compared to the pre-operative scan (in gray) (Fig. 21). A speckled gray/white appearance shows that the two surfaces are in complete congruence. For any area where there is white, it is protruding outside the boundary of the original tooth surface and may cause an interference with occlusion. With good clinical judgment, this is usually not a problem.

_Case 2

A 38-year-old male went through extensive jaw surgery and orthodontics to alleviate a severe class 2 malocclusion. His vertical dimension of occlusion was opened up about 2 mm in the posterior and

Fig. 20_A circle is placed to designate areas for the computer to copy the preoperative surface.
Fig. 21_The preoperative shell (gray) is compared to the digitally designed restoration (white).

Fig. 22_New vertical dimension of occlusion established intraorally with composite and ready for reproduction in ceramic.
Fig. 23_The finalized ceramic crowns (IPS e.max CAD) at 18, 19 and 20 reflect the occlusion and shape established in composite.

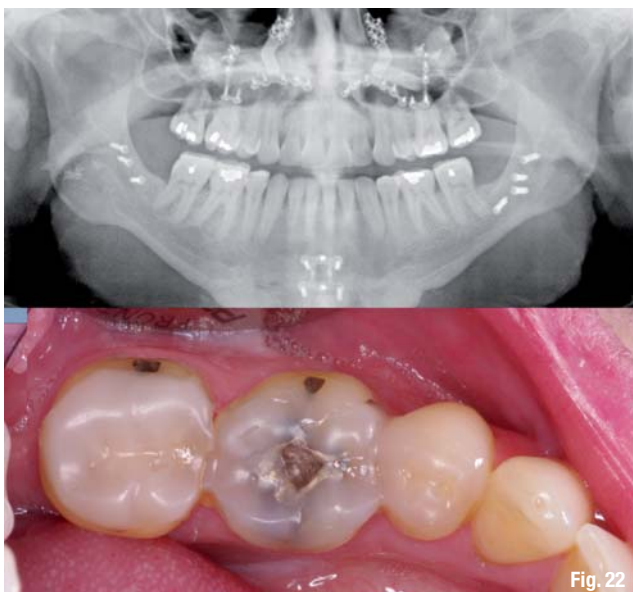


Fig. 22

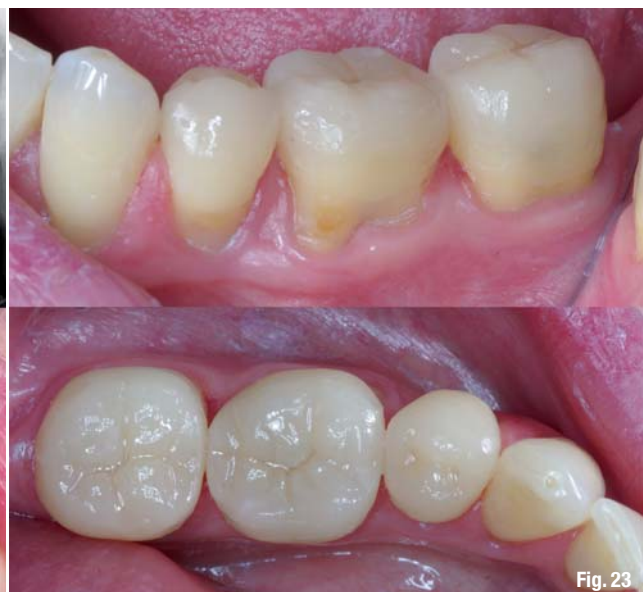

Fig. 23

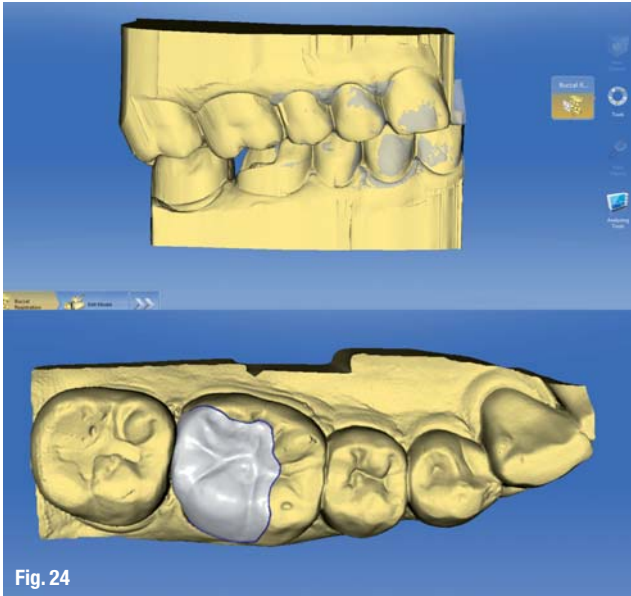


Fig. 24

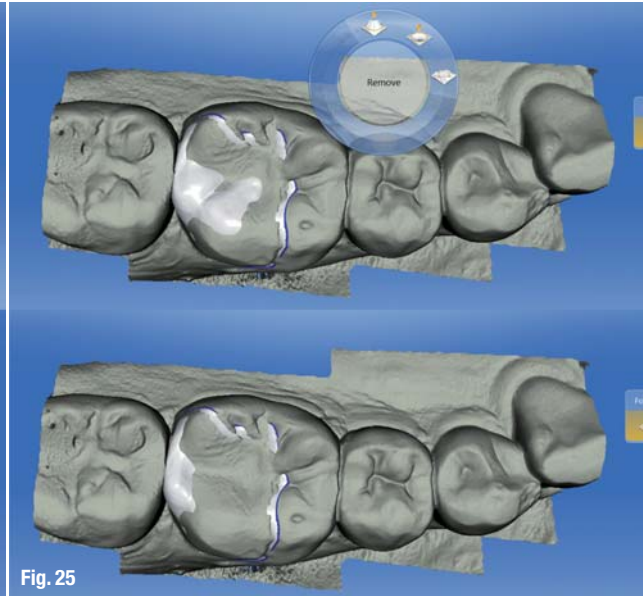


Fig. 25

Fig. 24_The upper and lower models were articulated and the Biogeneric proposal was calculated.

Fig. 25_The Biogeneric proposal was compared with the preoperative amalgam surface and adjustments were made.

stabilized with composite. Over the course of many months, the composite was adjusted and monitored for chewing efficiency and comfort (Fig. 22). After many occlusion checks in the office, it was time for the definitive restorations.

Having all of the patterns of occlusion agreeable to the patient, the three-dimensional shapes just needed to be reproduced into ceramic. Biogeneric Copy was the method of choice. Anesthesia was given, and the lower quadrants were scanned in prior to removing the composite and amalgam. Conservative preparations were completed and the prepared quadrant was scanned into the software. Using the pre-operative shape as a guideline for the final restoration, CEREC was able to reproduce the shape developed into composite over many months. The crowns were milled and inserted with no occlusal adjustment. The patient was happy that there was no difference between the established composite shapes and the finalized ceramic shapes (Fig. 23). The major advantage to this technique is that it uses the ultimate articulator: the patient himself.

Using something new with something old

There are two exceptional methods used in the CEREC Software 4.0 program to establish anatomical design and occlusion:

1. Biogeneric Individual: a mathematical calculation with buccal bite articulation
2. Biogeneric Copy: the reproduction of current anatomy.

The buccal bite articulation sets the digital teeth in one static occluding position and does not show lateral or protrusive interferences. A CR-CO movement

is also not capable in this static position. This should be considered a snapshot of the patient's occlusion, and the doctor needs to be very aware of potential interferences outside the CO position. This is not difficult to do because adjacent tooth incline planes can be compared, as well as cusp tip positions, for example. With the articulation of upper and lower models with the buccal bite, one can see the true intermaxillary space and build the design appropriately. However, there are no motion paths within the CEREC program, and this will probably be a desirable feature in the future. The pre-operative surface is the best indicator to the motion paths of the jaws currently.

The Biogeneric Copy method as illustrated earlier will show motion paths of the mandible through years of service. However it has a limitation as well: a previously placed restoration may not have complete three-dimensional height for occlusion in some areas. In other words, it may not have function in all areas that it possibly could because the restoration was made in infraocclusion in some areas. For instance, a large amalgam may not have a marginal ridge that is in occlusion because the operator did not make it high enough directly in the mouth years ago. Therefore, the new Biogeneric Copy milled restoration copied from this amalgam would be limited as well at the same amalgam marginal ridge.

Although each method has a specific limitation, they can now be utilized together in the new CEREC Software 4.0. Therefore, the best of both methods can be used to determine the occlusion points and avoid interferences with jaw motion paths. The Biogeneric mathematical calculation is used to make the best anatomy and place the design in harmony with the maximum intercuspation position. Then, the Biogeneric Copy model can be utilized to analyze

potential interferences that were not present with the prior failing restoration. It is truly the best of both worlds to establish anatomy and determine occlusion in the digital world.

_Case 3

An onlay was necessary for tooth #30 after recurrent caries of a large amalgam. Prior to preparation, preoperative images were taken for the Biogeneric Copy model. The tooth was prepared and three sets of images were then taken: preparation quadrant, opposing quadrant and buccal bite images. The software now had everything required to calculate the restoration.

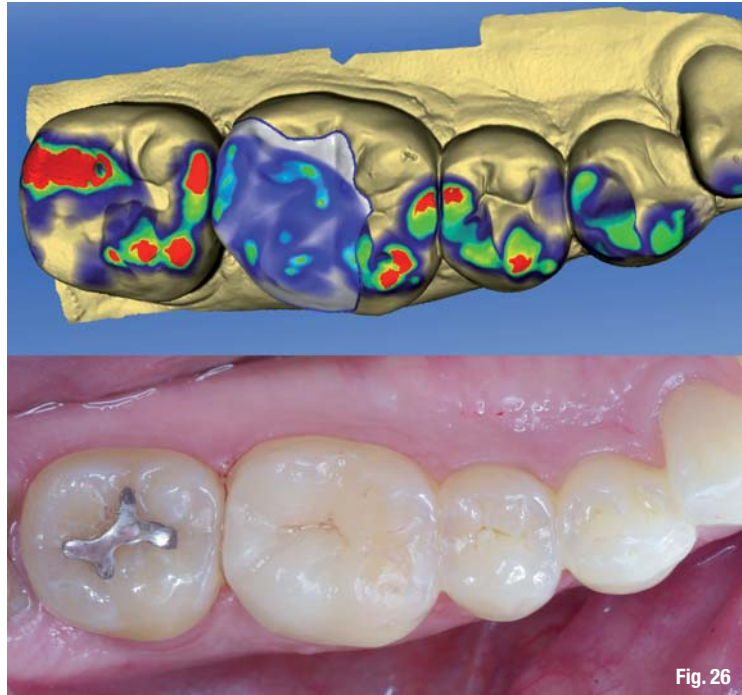
The upper and lower digital models were articulated using the buccal bite images and the lower Biogeneric Copy model was automatically spliced to the lower preparation model. The margin was marked and the Biogeneric calculation took place (Fig. 24). The occlusal contacts of the Biogeneric proposal appeared to be correct; but after comparing it to the preoperative Biogeneric Copy model, it revealed that there was an interference along the incline plane of the buccal cusp. So, this area was relieved (Fig. 25). However, the Biogeneric proposal actually calculated a better position for the distal marginal ridge and it was left as designed. The prior amalgam was deficient in height at the marginal ridge.

The digital restoration was milled out of IPS e.max CAD (Ivoclar Vivadent) and crystallized. The restoration was bonded in with Multilink Automix (Ivoclar Vivadent) and no occlusal adjustments were required (Fig. 26).

_Conclusion

The newest CEREC Software 4.0 has opened doors that were only dreams years ago: better flow, more efficient tools, multiple models and multiple-unit design. Having the ability to design multiple restorations in unison has greatly increased the design mode. It has a major impact when designing any adjacent restorations, but it is phenomenal at the midline between teeth numbers 8 and 9. The esthetic position of the midline is achieved easily because of this.

Esthetic dental anatomies are also easier to achieve with the ability of the software to calculate exceptional designs that are customized for every tooth. But the function does not suffer because the design can be compared to a preoperative shape, as well as the intermaxillary space. This makes for a very efficient method in achieving proper occlusion digitally and ultimately in the final restoration delivered to the patient.



_References

1. Ender A, Mörmann WH, Mehl A. Efficiency of a mathematical model in generating CAD/CAM-partial crowns with natural tooth morphology. *Clin Oral Investig*. 2011 Apr; 15(2):283-9. Epub 2010 Feb 9.
2. Dunn M. Biogeneric and User-Friendly: The CEREC 3D Software Upgrade 3.00. *Int J Comput Dent*. 2007;10(1):109-117.
3. Richter J, Mehl A. Evaluation for the full automatic inlay reconstruction by means of the biogeneric tooth model. *Int J Comput Dent*. 2006;9(2):101-111.
4. Mehl A, Blanz V. Biogeneric tooth reconstruction—new fundamental method to describe and reconstruct the occlusal morphology of teeth. In: Mörmann WH, ed. *State of the Art CAD/CAM Restorations*. Hanover Park, Ill: Quintessence Publishing Co; 2006:113-121.
5. Fasbinder DJ, Poticny DJ. Accuracy of occlusal contacts for crowns with chairside CAD/CAM techniques. *Int J Comput Dent*. 2010;13(4):303-16. English, German.

Fig. 26 The digitized occlusion was completed with anticipation of a glaze layer. The final restoration did not require any adjustment.

_about the author

cosmetic
dentistry



Dr Todd Ehrlich graduated Magna Cum Laude from UTHSC at San Antonio and served as president of its Alumni Association. His "CERECOLGY" advanced training program is considered one of the premier training seminars for CEREC. He is a beta tester for Sirona, and is an administrator on Dentaltown's website. He can be contacted at drehrllich@cerecology.com.

Practical periodontics in daily practice

Author_Dr Amit Patel, UK

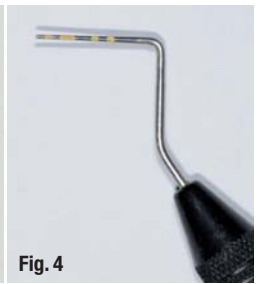
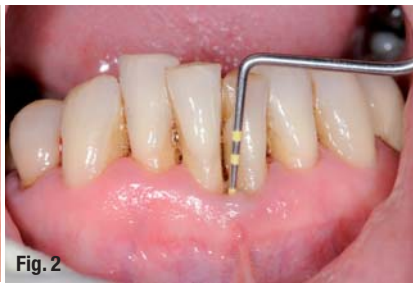
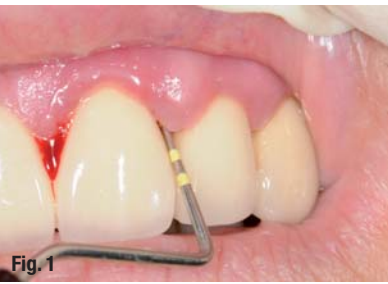
Fig. 1 Inflamed gingival tissue and pocketing around a bridge abutment.

Fig. 2 Healthy-looking gingival tissues, but the patient is a smoker and 5 mm pocketing is noted.

Fig. 3 BPE probe.

Fig. 4 Williams' probe.

_Cosmetic and implant dentistry has become increasing popular among dentists and patients. As this type of dentistry increases, so does litigation. Legal defence organisations have noted that their highest litigation costs are due to an increase in undiagnosed periodontal disease, as well as poorly planned cosmetic and implant dentistry. A failure to diagnose periodontal disease, inadequate records, poor quality treatment and treatment planning, supervised neglect, and failure to refer all lead to increased litigation within the profession.

The guidance for standards set by the General Dental Council states that a clinician should work within his or her knowledge, professional competence and physical abilities, should refer patients for a second opinion and for further advice when necessary, and should refer patients for further treatment when necessary.

It is important as the clinician to assess the periodontal condition before starting any restorative dentistry, whether simple or complex. There is very good long-term evidence that once the foundation

of the periodontium is stable and good plaque control has been achieved, the restorative treatment will have a better long-term prognosis. This article will briefly discuss the simple tools we have in our surgeries to help diagnose periodontal disease and when to treat and when to refer using the British Society of Periodontology's referral guidance.

The clinical signs of chronic periodontal disease are gingival inflammation and bleeding, pocketing, gingival recession, tooth mobility and migration, alveolar bone loss and halitosis. Figure 1 shows a patient with gingival inflammation and bleeding on probing with a pocket depth of greater than 5 mm. A good predictor of gingival health is no bleeding on probing, but it is important to note that in smokers the gingival tissues look relatively healthy and in most cases do not bleed on probing, as smoking masks the presence of disease (Fig. 2).

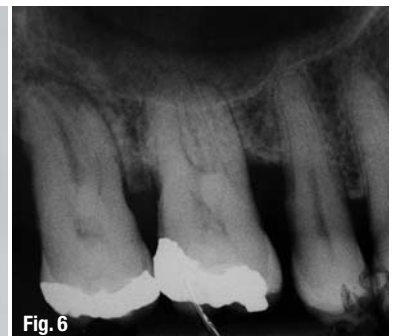An essential tool for the assessment of the periodontal tissues is the BPE (basic periodontal examination) probe, otherwise known as a WHO 621 probe (Fig. 3). This probe has a ball tip of 0.5 mm in diameter

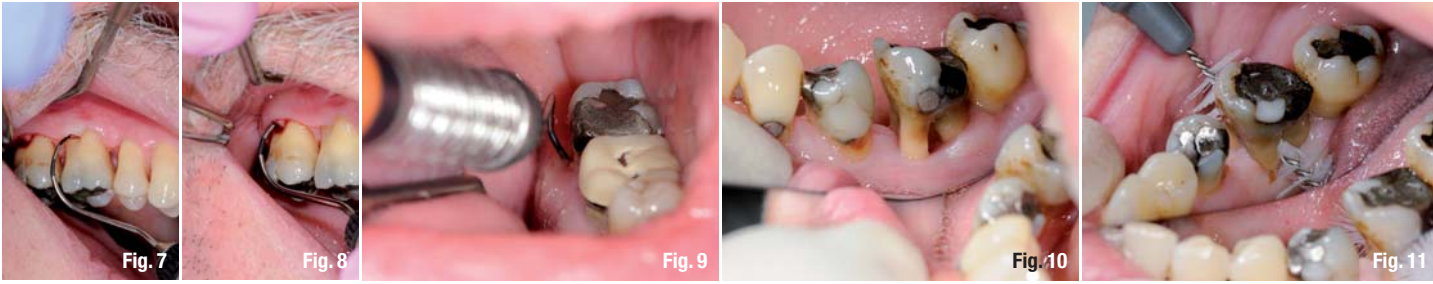Table I Basic periodontal examination codes.

Fig. 5 Furcation probe.

Fig. 6 Long cone radiograph of teeth 14 to 17.

Code Signs	Treatment
0 No bleeding on probing Pocket depth of \leq 3 mm	No treatment
1 Bleeding on probing	Hygiene instruction
2 Plaque retentive factors present No pocket depth of $>$ 3.5 mm	Hygiene instruction and scaling
3 Pocket depth of $>$ 3.5 mm but $<$ 5.5 mm	Hygiene instruction, supra- and subgingival scaling
4 Pocket depth of \geq 5.5 mm	Full periodontal assessment
* Furcation	Full periodontal assessment





and a black band marked at 3.5–5.5 mm. The BPE is a simple and quick way of screening our patients for any underlying periodontal disease. Williams' probes are also commonly used to assess the periodontal tissue (this probe has graduated markings at 1–2, 3–5, 7–8, 9–10 mm; Fig. 4).

The BPE was developed by the British Society of Periodontology. It is a method of screening patients to determine the treatment required for the level of disease present. The BPE is an index for treatment need and does not estimate the level of disease present. Rather, a loss of attachment chart is used to determine this.

The BPE divides the mouth into sextants. All the teeth in a sextant are examined and scored accordingly (Table I). Recently, the British Society of Periodontology has made a slight change to the BPE scoring. Code* has now been changed to denote the presence of a furcation only, whereas previously it was to denote the presence of a furcation or attachment loss of 7 mm or greater. The society has also said that the other BPE codes and Code* should be recorded for each sextant where a furcation is present. An example is shown in Table II.

A furcation probe or Nabers' probe is also an essential tool for assessing the degree of furcation involvement of a molar tooth. We can measure the amount of horizontal bone loss that has occurred within the furcation, classifying it as a Class 1, 2 or 3 furcation. The dark bands represent 3 mm markings (Fig. 5). A Class 1 furcation is noted when the furcation probe penetrates less than 3 mm into the furcation (Fig. 6). A Class 2 furcation is when the probe penetrates greater than 3 mm but does not go all the way through the furcation

(Figs. 7 & 8). A Class 3 furcation is when the probe passes through the furcation unimpeded (Figs. 9 & 10). Radiographs are another important tool used to assess the bone levels around each tooth, root morphology and furcation involvement, and therefore the support present and long-term prognosis of the teeth (Fig. 8). Long-cone parallel radiographs or vertical bitewings are taken of sextants when the score is 3 or more (Fig. 11).

_Risk factors

The clinician should also be aware of risk factors that can exacerbate the existing periodontal disease: diabetes, smoking and genetics. A combination of these factors makes certain patients susceptible to higher risks of periodontal disease. These cases may be treated in practice but referral to a specialist would be required if the disease is not stabilised. Recognition of risk factors includes:

- _BPE Codes 3, 4 or * in patients under 35 years old;
- _smoking ten or more cigarettes a day;
- _a medical condition directly affecting the periodontal tissues, for example diabetes, stress and certain types of medication;
- _a root morphology that adversely affects prognosis;
- _rapid periodontal breakdown (> 2 mm attachment loss in any one year);
- _a high bleeding percentage with a low plaque score; and
- _a family history of early tooth loss due to periodontal disease.

_Oral hygiene

A high standard of oral hygiene is critical for successful periodontal therapy. There is a great deal

Fig. 7 Class 1 buccal furcation in tooth 16.
Fig. 8 Class 2 buccal furcation in tooth 17.
Fig. 9 Class 2 lingual furcation in tooth 47.
Fig. 10 Class 3 furcation in tooth 46.
Fig. 11 Class 3 furcation in tooth 46.

4	2	4*
3*	3	2

Table II Example of BPE scoring and Code* for each sextant where a furcation is present.

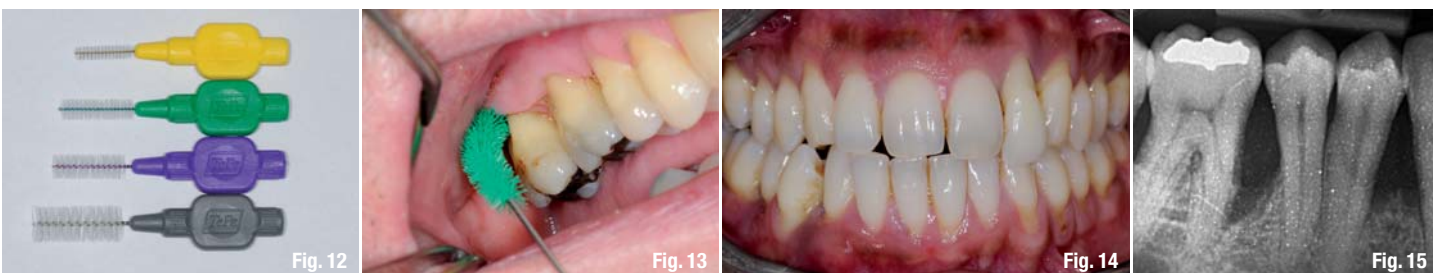

Fig. 12 Interdental brushes.
Fig. 13 Interdental brush used to maintain a Class 2 buccal furcation.
Fig. 14 Consultation visit.
Fig. 15 Long-cone periapical radiograph of teeth #43 to 46.

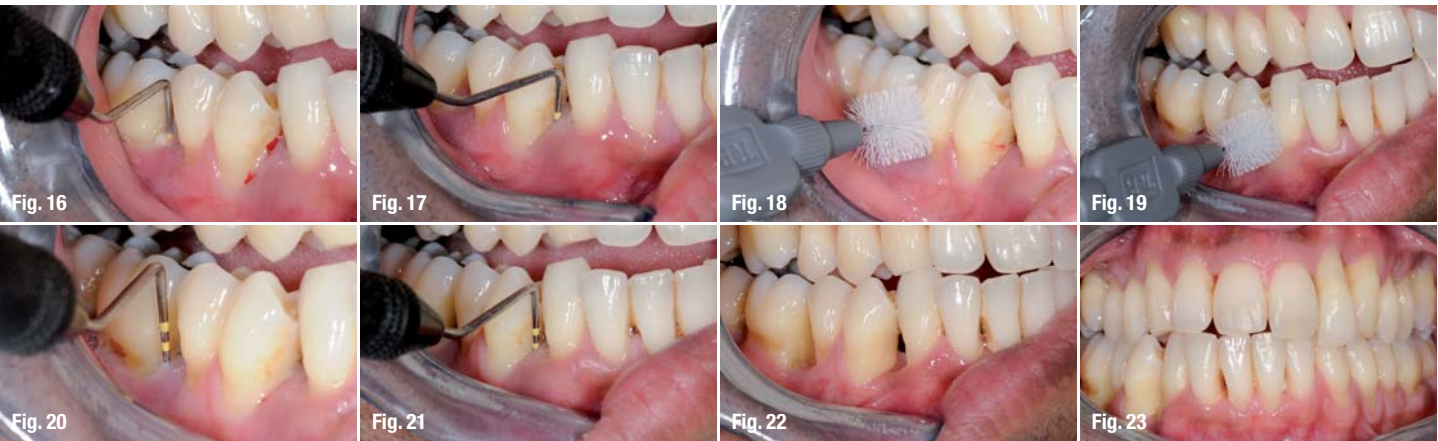

Fig. 16_Tooth #46 with 10 mm pocketing mesially.

Fig. 17_Tooth #45 with 9 mm pocketing mesially.

Fig. 18_Largest interdental brush for tooth #46 demonstrated to patient.

Fig. 19_Largest interdental brush for tooth #45.

Fig. 20_Tooth #46 with 6 mm pocketing mesially after simple oral hygiene instruction given (large interdental brushes).

Fig. 21_Tooth #45 with 7 mm pocketing mesially after simple oral hygiene instruction given (large interdental brushes).

Fig. 22_Teeth #43 to 46 show increased recession and a reduction in probing depth to 3 mm after non-surgical therapy.

Fig. 23_Gingival health after initial therapy with a reduction in probing depth.

of evidence that regular plaque removal around periodontally involved teeth at a level that prevents bleeding on probing leads to a reduction in disease progression. It is essential that the patient be taught simple, yet effective ways to improve his or her plaque control at home with daily use of a rotating-oscillating electric toothbrush and interdental brushes (Fig. 12). A systematic review by the Cochrane Library has shown that a rotating-oscillating electric toothbrush is far more effective at removing plaque.¹

A study has shown that using the correct size interdental brushes can improve the periodontal condition significantly.² A recent systematic review has also shown that flossing by patients has no effect on the plaque index or gingival index and that flossing is not effective in periodontally compromised patients. Interdental brushes have been shown to remove more plaque than flossing.³

It is important to motivate your patients to use the largest interdental brushes (Figs. 12 & 13), but this can be a little difficult because they may not be able to see the short-term benefits, as their gums may bleed more and the interproximal spaces will become larger. It is essential to reinforce the same message. This will reassure the patient and after a short time they will see visible benefits, that is, less bleeding on cleaning and a healthier-looking gingiva.

Case report

A 32-year-old male patient was referred to me complaining of loose teeth and bleeding gums for over 12 months. He was fit, apparently healthy and a non-smoker. A diagnosis of generalised aggressive periodontitis was made from the clinical examination (Figs. 14-17). At the consultation appointment, oral hygiene instruction was given and the largest interdental brushes demonstrated. At the following appointment, the full-mouth non-surgical phase was carried out with systemic antibiotics.⁴ From Figures 18 to 21, it can be noted that using the

correct size interdental brushes can lead to a reduction in inflammation and therefore a reduction in pocket depth.


Eight weeks after the non-surgical phase, the patient was reviewed for a periodontal reassessment. It was noted that the periodontal tissue had responded extremely well to the initial therapy with pocket depth of 3 to 4 mm throughout the mouth (Figs. 22 & 23). At this point, the patient would be placed on a three-monthly maintenance regime, with reinforcement of oral hygiene instruction and subgingival plaque removal for any deep sites. This would be carried out by his general dentist or hygienist. My plan would be to review the patient in six months' time to review his periodontal condition.


It is important to know that periodontal therapy works and a healthy periodontium is the backbone of good restorative dentistry. Treating periodontal disease can be challenging but can also be very rewarding. Careful assessment, treatment, referral to a specialist if necessary and monitoring of your patients are essential for avoiding any future problems.

For further information regarding the BPE and referral guidance, contact the British Society of Periodontology or refer to its website: www.bsperio.org.uk

Editorial note: A complete list of references is available from the publisher.

_about the author





Dr Amit Patel
Specialist in Periodontics & Implant Dentist, Associate Specialist Birmingham Dental Hospital, Honorary Clinical Lecturer University of Birmingham School of Dentistry



Tribune CME

Clinical Masters Program in Aesthetic and Restorative Dentistry

10-14 January 2013 and 24-27 April 2013 in Dubai, for a total 9 days

Dubai, UAE

2 on location sessions with **live patient treatment**
and **hands on** in each session!
+ online live and recorded lectures, **online mentoring**



Didier Dietschi



Francesco Mangani



Panos Bazos

Session I: 10 - 14 January 2013 (5 days)

- Direct/Indirect composite Artistry in the Anterior Segment
- Direct/Indirect composite Artistry in the Posterior Segment
- Photography and shade analysis

Clinical Masters:

Didier Dietschi, Francesco Mangani, Panos Bazos



Mauro Fradeani



Urs Brodbeck

Session II: 24 - 27 April 2013 (4 days)

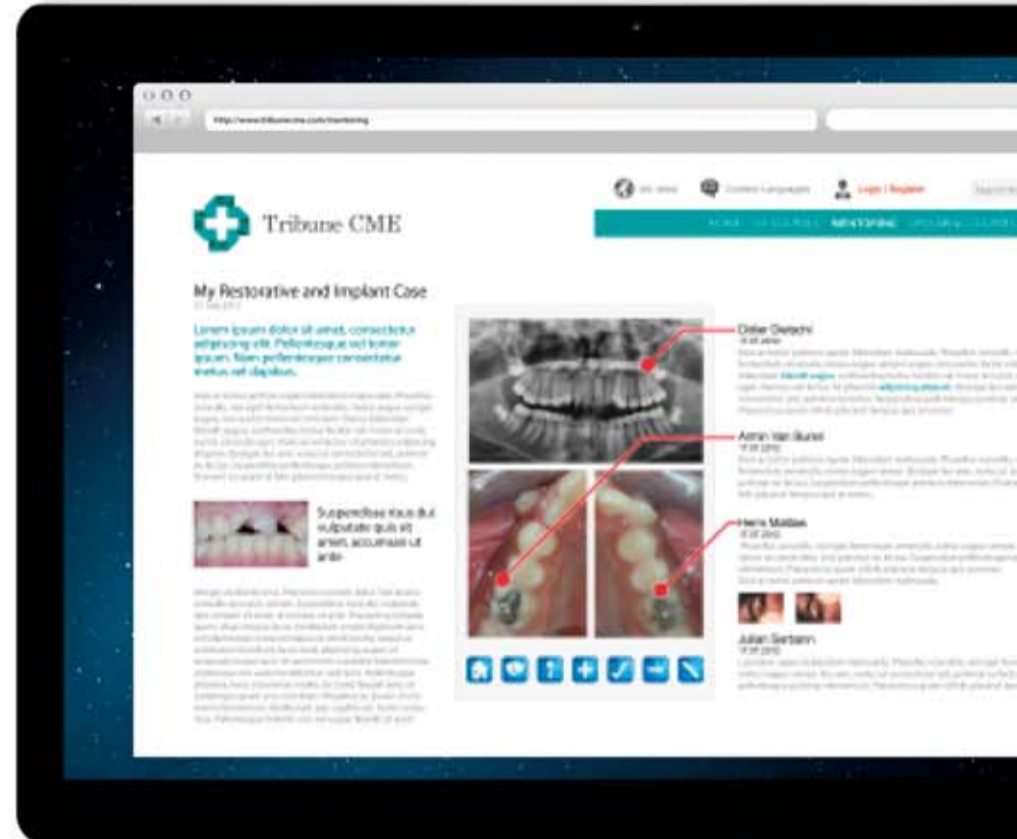
- Full coverage Anterior/Posterior Restoration
- Partial coverage Anterior/Posterior Restoration, Ceramic Restoration

Clinical Masters:

Mauro Fradeani, Urs Brodbeck

ADA C.E.R.P.® | Continuing Education
Recognition Program

Tribune America LLC is the ADA CERP provider.
ADA CERP is a service of the American Dental Association to assist dental professionals in identifying quality providers of continuing dental education. ADA CERP does not approve or endorse individual courses or instructors, nor does it imply acceptance of credit hours by boards of dentistry.



Full access to our online learning platform:
hours of premium video training and live webinars
collaborate with peers and faculty on **your cases**

Registration info

Course fee: € 8,900

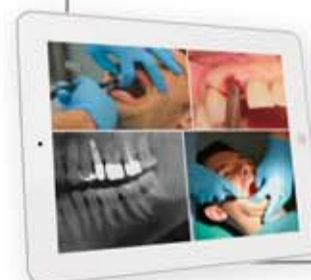Register by the end of October and you
will receive a complimentary iPad
preloaded with premium dental courses

Tribune CME

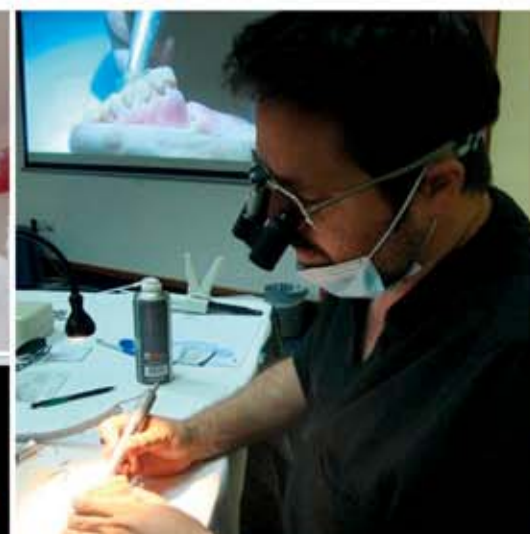
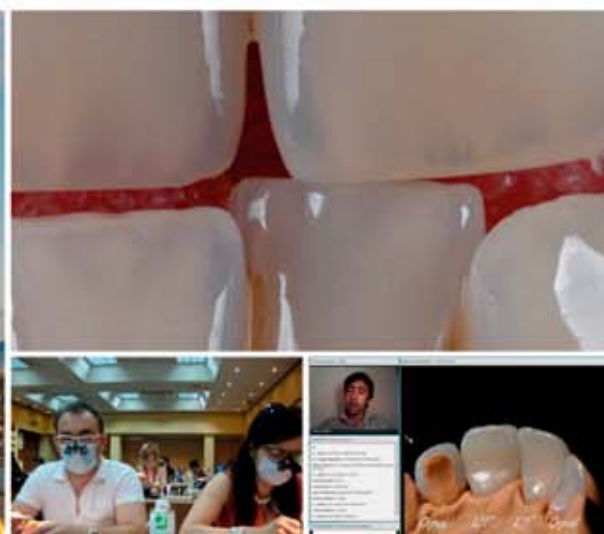Tel.: +49-341-48474-302

email: info@tribunecme.com

www.TribuneCME.com



Discover the Master's secrets and Dubai's superlatives



100 C.E. CREDITS

ADA CERP® | Continuing Education
Recognition Program

Cost effectiveness in implant dentistry

Author_Prof. Mauro Labanca, Italy



Introduction

Today, about 65% of Italian dentists are practising implantology. In Italy alone, over a million implants are placed every year. A survey commissioned by the Italian Society of Osseointegrated Implantology on implant perception among the Italian population found that 68% of the respondents would request an implant should the need for an artificial tooth arise. One Italian out of three has undergone oral implant surgery. It follows that osseointegrated implants will be offered by a growing number of professionals and be placed in an ever-larger population in the future.¹

It should also be noted that the economic crisis has severely affected even the dental field, and the repercussions of this phenomenon have been reported by newspapers, professional associations and the Ministry of Health in Italy. The Osservasalute report, an overview of health in Italy (compiled by the National Observatory on Health Status in the Italian Regions, based at the Università Cattolica del Sacro Cuore's campus in Rome), reported in 2010 that Italians are being forced to save and that

both the food and dental industries will suffer as a result.²

Past president of the Italian National Association of Dentists (ANDI) Dr Roberto Callioni analysed the consequences of the economic crisis and future prospects at a conference held under the auspices of the Ministry of Health on 29 March 2011. He stated that, according to a survey by ANDI in 2010, 30% of Italian dentists have less work because of the crisis.³

However, he also observed an increase in offerings owing to the extension of retirement age and the number of graduates, and a decline in demand related to the decrease in purchasing power, a decline in birth rate and a decrease in the DMFT index.³

In addition, dentists have to compete against low-cost dental offers and dental tourism to some locations in Eastern Europe (as was the case in the 1990s with regard to the Netherlands). The increase in offerings and the reduction in demand have resulted in the average practitioner having

“The dentist? A mechanic who changed parts of your car, but, not being technical, you never know if you’re rubbing or not.”

Photo: Dmitry Shironosov

higher costs and lower revenues, also owing to the instability of supply and demand. Oral implantology is affected, as are other disciplines of dentistry, by the current socio-economic situation. Yet, the sense is that of a greater demand by the public and a need for the dentist to offer treatment at a lower cost.

In Italy, there are more than 300 different implant systems (probably not an accurate estimate, considering the difficulty in recording copies of copies). These systems usually have the certification necessary for the market, but only a small proportion of them are supported by scientific evidence, based on studies appropriately designed and conducted by independent research institutions, attesting to their clinical performance, especially in the long term and with the proper follow-up. These are the considerations that, together with the lack of reference measure for quality, led the Italian Society of Osseointegrated Implantology to organise the quality forum in implantology, held in Verona from 15–17 November 2008, in which a large number of experts analysed the various aspects of quality in implantology.

The selection of an implant system suited to the demands of the professional is strongly felt to optimise costs when trying to increase profits where possible without interfering with the quality delivered. As written by Pierluigi La Porta in the context of the forum of quality in implantology:⁴

The professional liability requires that the professional has all the factors of production under his control by deploying useful tools to measure the quality of his works, the results that follow and the tools used to achieve performance. Moreover, the information asymmetry that characterizes the doctor-patient relationship is known in the health field, making patients entrust themselves to the professionals' decisions in order to solve their health problem. This assignment essentially denotes the inability of the patient to decide what is really best to do in that situation, even if he is well informed. His expectations are related to the solution of the problem, but he rarely pays attention to the way it is resolved or the instruments used, so the professional is solely responsible. The case law indicates the responsibility of the doctor to “act like a good father” when he is

Procedure	1 fixture + 1 crown in porcelain
Protocol	Delayed-load cemented solution
Implant system	xxx
Cost of the practice 1 h surgery	€ 130
Cost of the practice 1 h prosthetic	€ 80
Cost of 1 h other activities (consultation, check ...)	€ 70

Table 1 _ Cost analysis for various procedures.

the one to decide for his patient. So be sure that the quality of his performance becomes a must of his action. When professionals begin to question the quality of their performance, then you are facing a true and profound cultural change.

To these considerations, one might add: why would a patient choose to seek treatment in a dental centre?

"The dentist? A mechanic who changed parts of your car but, not being technical, you never know if you're rubbing or not."

This is how one interviewee responded to the request by the well-known psychologist and professor of marketing and communication Alberto Crescentini to describe the figure of the dentist.⁵ The average patient finds it difficult to evaluate the quality of a medical service from a technical point of view because he simply does not have the skills. It is our duty not to betray him, and act according to the science and our knowledge. Bearing this all in mind, we should determine the possible savings in the management of implants and whether buying an implant at a lower cost will result in cost effectiveness. To quote Charles Darwin:

Table 2 _ Average price of a cheap implant system in the market, showing variable costs.

Item	Cost
Fixture	€ 95
Insertion	225:10 (Drills/Number of uses)
Cover screw	€ 28
Surgical screwdriver	€ 54
Transfer	€ 45
Analogue	€ 27
Titanium abutment	€ 55
Prosthetic screwdriver	€ 31 + € 181 (DIN Raquet)
Individual impression tray	€ 30
Prosthesis (single ceramic crown)	€ 250
Total	€ 568

"It is not the strongest species that survive, nor the most intelligent, but the ones most responsive to change."⁶

In the literature, there are various articles about implant placement techniques, biomaterials and loading protocols, but there is only very little information about cost analysis in relation to implant-prosthetic procedures.

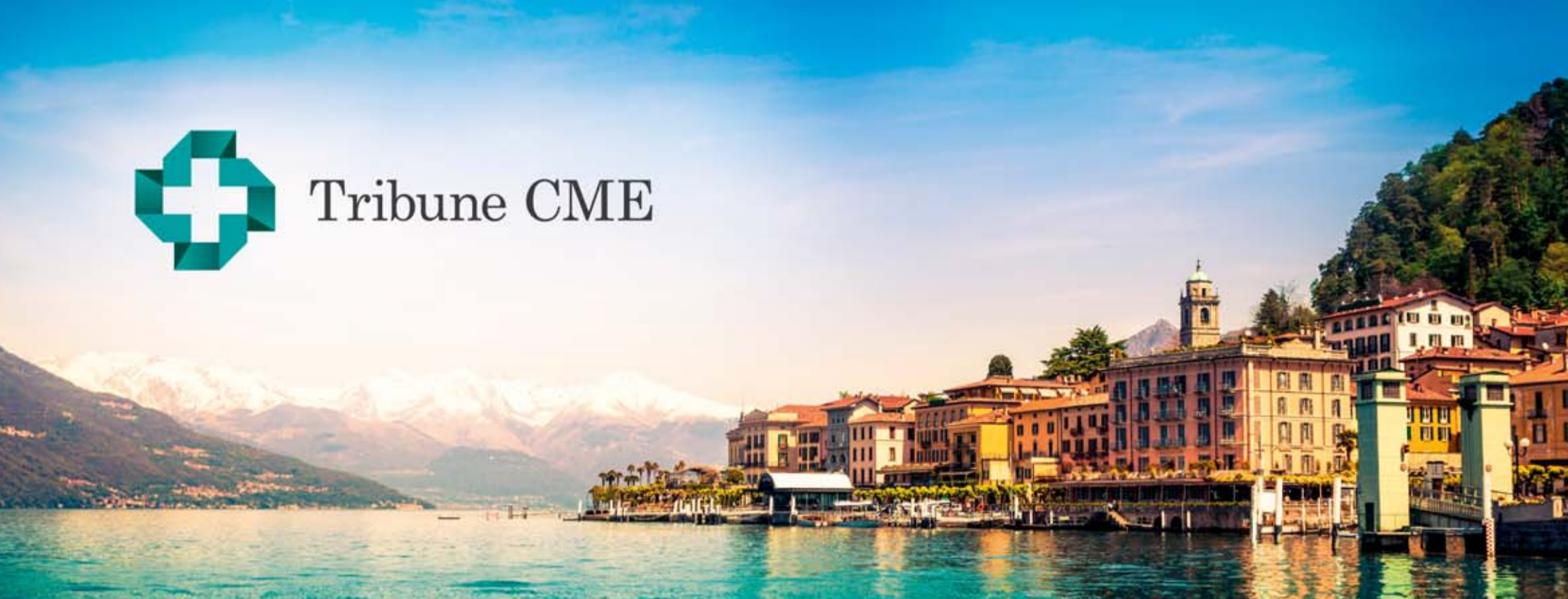Questions regarding the cost of implant placement and the amount a dentist can earn by placing fixtures tend not to be discussed at congresses, as if in fact the one and only important aspect is the finalisation of the case. In a country like Italy, where dentistry is largely private, the economic aspects are fundamental for the acceptance of the treatment plan by the patient. Even in ethical terms, if the dentist believes that his implant is really the most appropriate solution for that particular case, prohibitive costs could deprive the patient of that possible solution or push him towards other choices, both operational (other restorative solutions) and logistic (low-cost dentist or travel to a dentist abroad).



As observed earlier, there are over 300 different types of implants in Italy. Conventionally, these are divided into classes based on various aspects, one of which is purchase price. We could argue, however, that all implants are osseointegrated in the end and that implants that are more expensive are simply more advertised, but in essence they are the same as others. In Italy, many "homemade" and low-cost implant systems are available on the market whose traceability is practically absent in the literature and whose manufacturers are not able to guarantee long-term reliability.⁷ If we evaluate the sales data of the leading implant-producing companies, eight to ten leading companies hold 90% of the existing market share. As a logical consequence, the remaining 10%, amounting to approximately 100,000/150,000 units, can be divided among the remaining 300 or more companies on the market. What can the average number of implants sold by each of these be (despite what their dealers tell dentists)? Are they supported by case studies or



Tribune CME



Clinical Masters Program in Implant Dentistry

March 2013 to September 2013, a total of **12 days** in **Heidelberg (DE), Como (IT), Gran Canaria (ES)**

Program director
Dr. Marius Steigmann

Live surgery and **hands-on** with the masters in their own institutes plus online mentoring and on-demand learning at your own pace and location.



Dr. Tiziano Testori



Dr. Hom-Lay Wang



Dr. Scott D. Ganz



Dr. Jose Navarro



Dr. Philippe Russe

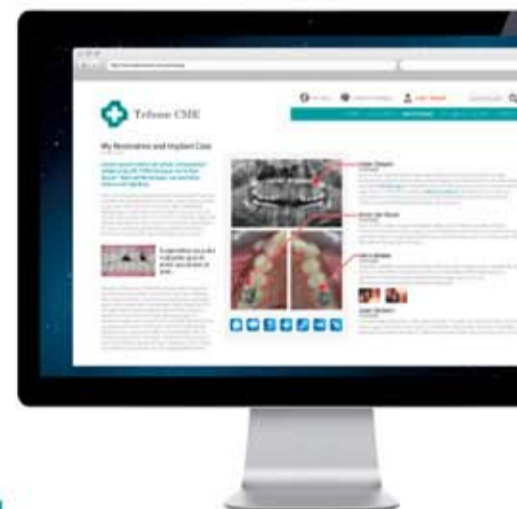

Dr. Marius Steigmann

and others

This comprehensive implant curriculum is composed of **100 hours of learning** in four blended online and offline modules, covering all aspects of implant dentistry. It is unique due to the fact that each module covers a whole range for several specific topics of implant dentistry. For each specific topic, a focus module has been designed including a hands-on exercise. The overall course covers diagnostic, thorough planning, ideal implant placement, grafting (both basic and advanced), prosthetic planning and construction, soft tissue manipulation, complications management, as well as implant maintenance.

During each module, the participants will have the opportunity to practice their new skills on hands-on casts, porcine models, and to watch or assist live surgery.



Course fee: € 11,900

Register by the end of 2012 and you will receive a complimentary iPad preloaded with premium dental courses.

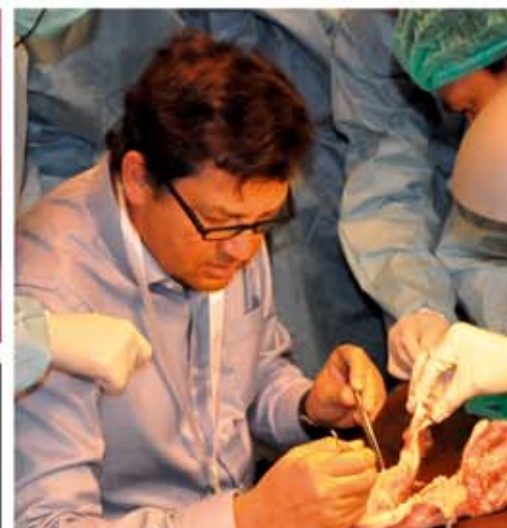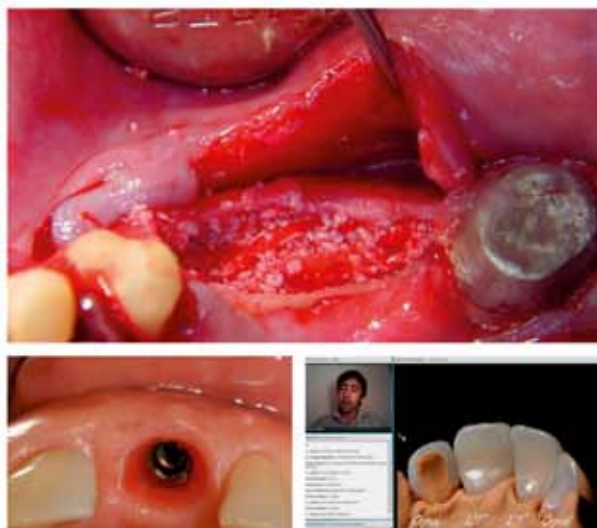Tel.: +49-341-48474-302
email: info@tribunecme.com
www.TribuneCME.com

+ Access our online learning platform: hours of premium video training and live webinars. Collaborate with peers and faculty on **your cases.**

ADA CERP® | Continuing Education Recognition Program

Tribune America LLC is the ADA CERP provider. ADA CERP is a service of the American Dental Association to assist dental professionals in identifying quality providers of continuing dental education. ADA CERP does not approve or endorse individual courses or instructors, nor does it imply acceptance of credit hours by boards of dentistry.

Discover the Masters' secrets and enjoy three superb locations.



100
C.E. CREDITS
ADA CERP®



Table 3 Fixed costs relating to implant placement in a private practice.

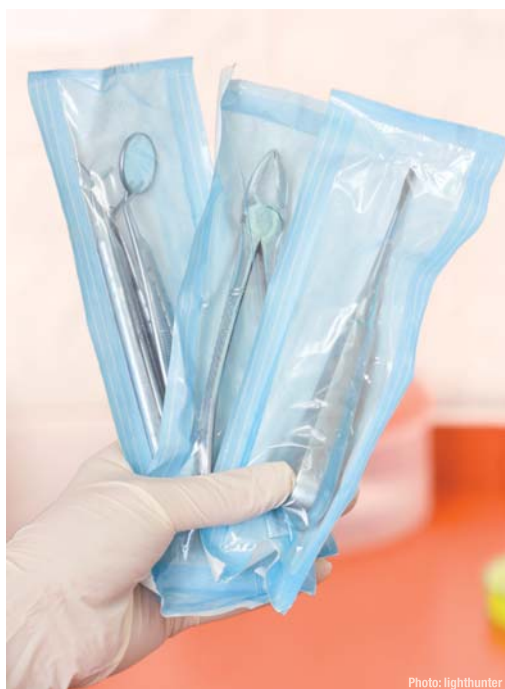Radiation Protection
Verification of the electrical system
Waste disposal
Insurance
Additional fees (phone, electricity, etc.)

other scientific literature? We should not forget that the intervention of implantation entails placing a foreign object, even if this is made of titanium, into the mouth of a patient, hopefully for life, and with undeniable biological effects. In order to do this in a verified and ethically correct way, I believe that the operator should ask questions and go beyond just checking the CE marking, much as he would do in the case of a drug prescription. Who would recommend taking an antibiotic available on the market a few years ago and tested on an insufficient number of patients?

Cost considerations

After these considerations, procedural and ethical, I turn to what may be the cost items for the realisation of an implant-prosthetic restoration. This assessment does not come from the perspective of a marketing expert or an economic expert, but from the pure and simple perspective of a daily operator who must evaluate which elements actually affect daily clinical practice.

It takes into consideration the variable costs and fixed costs. Variable costs change more or less in



proportion to changes in the production volume (the insertion of two implants and two crowns costs more than that of only one; paying an assistant for two hours costs less than paying him for eight hours). Fixed costs are defined costs that are not derived from the production volume. Fixed costs in dentistry are all the costs linked with the activity of the practice, such as those related to radiation protection, verification of the electrical system, sterilisation, waste disposal, insurance policy, building rental/payments and utilities in general.

The fixed costs are taken into account for any type of service rendered by the practice (Table 1). It is generally believed that a cheaper implant system is needed to save costs (Table 2) regarding implant treatment. From an analysis of the variable costs, it is evident that the costs of the storeroom and of the implant components are significant.

If an implant system entails many surgical steps, requires the use of many drills, has different platforms depending on the diameter of the neck, requires a surgical screwdriver and a prosthetic screwdriver or if different healing abutments are required for each implant placed, the final cost will change significantly, together with an increased risk of errors and inaccuracies (Tables 3 & 4). In particular, if the implant system offers different diameters, each requiring a different healing abutment, a different transfer and a different analogue, the amount of material to be kept in stock will be much higher, considering the prosthetic solution for every case. In terms of the healing abutment, stocking different heights and diameters according to each size available (at least four for the major implant systems) requires dozens of healing abutments even if only a few implants are placed. All this also inevitably leads to mistakes, organisational miscommunication, etc.

If the cover screw and the healing abutment came together with the implant, and therefore already included in the package (and price), things would be much more ergonomic. There would no longer be a need to stock other material or to re-use titanium healing abutments with the inevitable associated risk of inducing peri-implantitis during uncovering.

Costs related to sterile conditions

In a study on the success rates of osseointegration for implants placed under sterile versus clean conditions, Scharf and Tarnow found that the difference in the success rates was not statistically significant.⁸ Sterile surgery took place in an operating room setting and followed a strict sterile protocol.

Clean surgery took place in a clinic setting with the critical factor that nothing touched the surface of the implant until it contacted the prepared bone site. The results indicate that implant surgery performed under both sterile and clean conditions can achieve the same high rate of clinical osseointegration. This means that, while it is therefore not essential to incur the costs related to absolute sterile conditions (Table 5), dentists should not undertake surgery without taking adequate precautions in this regard. The modest savings achieved with regard to the total cost of the intervention could lead to a significant increase in the risk of failure.

We have to consider that an insufficiently tested implant system may lead to trivial errors (difficulty in taking an accurate impression, tightening the components, rotation or loosening of the prosthetic components), resulting in an inevitable loss of time, which in turn affects the cost and delivery. What sense does it make to save € 50 on the cost of the implant system when you have to spend as much or more in buying components separately or in seeing the patient several times owing to these trivial errors (considering the hourly rate given above)?

Also, if failure is always a factor to be taken into consideration, it follows that dentists must seek to eliminate predictable and avoidable failures, which are those for which the dentist is partly responsible (the aforementioned poor management of sterility, improper surgical planning, and an incorrect or adequate surgical sequence). Predictable and avoidable failure may not only result in easily quantifiable economic damage, but also lead to important and less easily quantifiable damage in terms of the reputation and credibility of the practice, which could affect the patient's confidence in the dentist and his willingness to promote the practice.

Conclusion

In conclusion, we should consider the following with regard to cost management in implantsurgery:

- _paying particular attention to the significant costs;
- _simplification and streamlining of clinical and extra-clinical procedures;
- _identification of alternative treatments with a different cost-benefit analysis; and
- _a schedule for reduction or elimination of errors and significant associated costs.

All this will contribute towards a better understanding, and in a more responsible and ethical way, of when it is really necessary to try a new implant system and by what criteria its actual reliability can

Cost of fixture
Cover screw
Surgical kit
Drills
Surgical screwdriver
Transfer
Analogue
Titanium abutment
Prosthetic screwdriver (if required)
Individual impression tray
Prosthesis (crown, bridge, etc.)

Table 4_Fixed costs of the fixture.

Sterility kit	Cost
High-sterility kit (mod. Brånemark)	€ 80
Medium-sterility kit	€ 40
Minimal-sterility kit	€ 25

Table 5_Cost of sterility.

be evaluated. What is the true effect of the price of the implant on the total cost for the practice? We should not be misled in selecting an item that does not appear to be of primary importance in terms of absolute cost. A final consideration is the cost in terms of the practice's reputation, for example in the case of an avoidable failure.

In the light of these considerations, by selecting protocols and materials more rigorously and by giving greater consideration to ethics in our evaluations, we will be able to achieve a real reduction in cost in areas that do not involve interference in the final quality of our work output. We should attempt to save money in areas that affect the final result, with important consequences for us, for our professionalism and for patients who gave us their trust and confidence when entrusting their health to us. Do we have the right to betray their trust, or do we rather have the duty to preserve and respect it?

Editorial note: A complete list of references is available from the publisher.

_contact

cosmetic
dentistry

Prof. Mauro Labanca

Consultant Professor
Corso Magenta 32
20123 Milano, Italy

maurolab@tin.it

The same-day tooth: From the diagnosis to the final restoration

Author_Dr Stefanos G. Kourtis, Greece

_Introduction

The restoration of missing anterior teeth is both a challenging task for the clinician and a stressful treatment for the patient. The final aesthetic result is of major importance—for the patient, dentist and dental technician. Moreover, the patient has high expectations, aesthetic demands and concerns about the cosmetic result of the final restoration. Even before treatment is started, the patient is usually concerned about the final outcome, as well as the provisional restoration used during osseointegration. The aim of this case report is to

present the clinical stages of rehabilitation of a central incisor from diagnosis to final restoration.

_Case presentation

A 29-year-old female patient without any apparent contributory medical history presented for treatment. The patient complained about the aesthetic appearance of the anterior maxillary region. The right central incisor appeared elongated, showed increased mobility (Grade I+) and was sensitive to palpation. The gingival margin of this tooth showed signs of infection, both labially and

Fig. 1_Initial clinical situation.

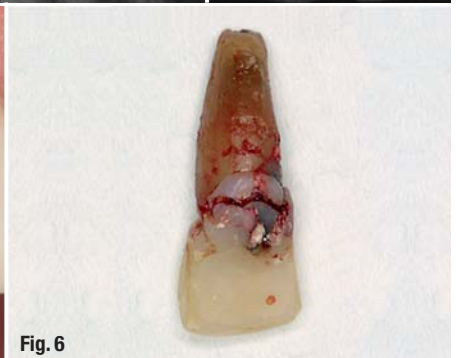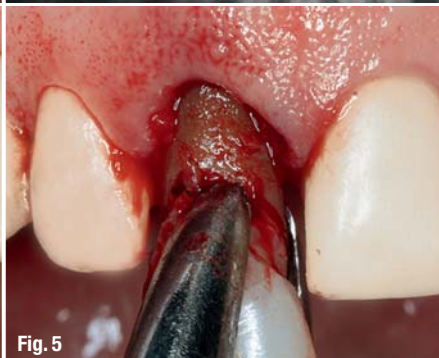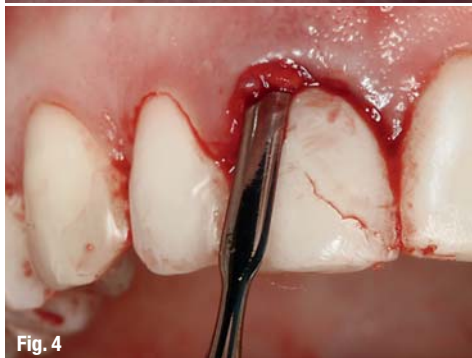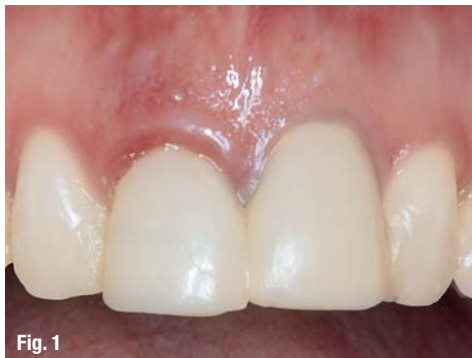Fig. 2_Initial radiographic situation.

Fig. 3_Detailed X-ray examination.

Fig. 4_Periodontal fibres cut by utilising a periosteal elevator.

Fig. 5_Atraumatic tooth extraction.

Fig. 6_The horizontal root fracture was evident on the extracted tooth.

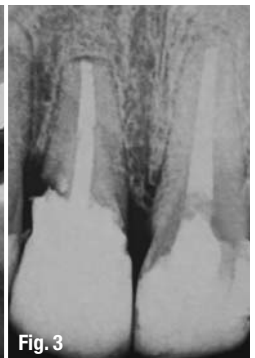
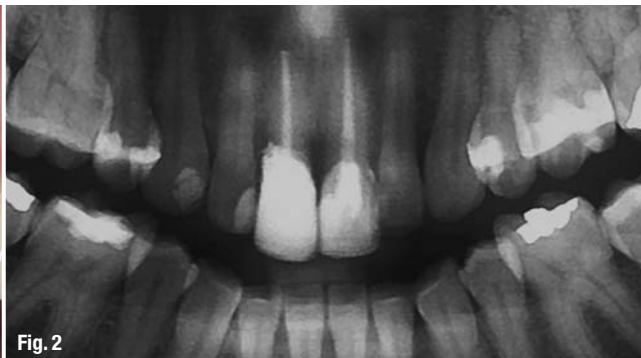
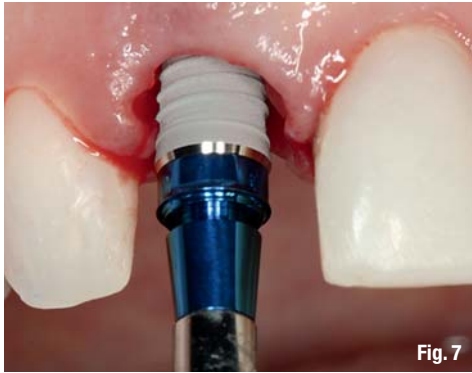



Fig. 7

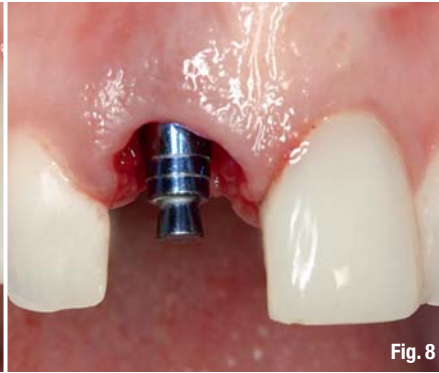

Fig. 8

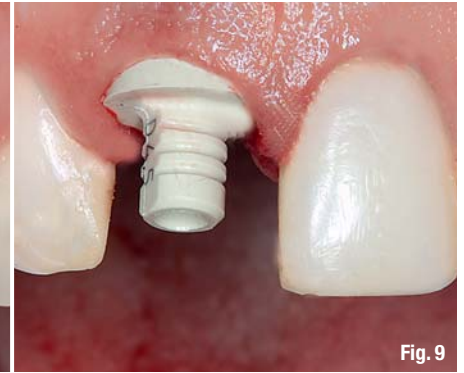


Fig. 9

palatally. Hence, its periodontal conditions differed evidently from those of the remaining dentition. The left central incisor was discoloured and had extensive composite resin restorations with inadequate fit at the margins (Fig. 1).

A possible tooth or root fracture was suspected. The patient was asked about recent injuries or trauma to the maxillary region, and she reported a traffic accident six months previously. After this incident, both incisors showed extreme sensitivity and were treated endodontically. Radiographic examination with panoramic and intra-oral X-rays revealed a root fracture of the right central incisor

2 mm below the cemento-enamel junction (Figs. 2 & 3). The tooth had a poor prognosis and needed to be extracted. In contrast, the left central incisor showed no signs of root fracture. The treatment plan included the extraction of tooth #11, an immediate implant placement and the use of an immediate implant provisional. In addition, the prosthetic rehabilitation of the natural tooth #21 completed the rehabilitation. All-ceramic crowns were selected as the final restorations for the two central incisors at the end of the osseointegration period of the implant.

The patient had a high smile line and was extremely concerned about her aesthetic appearance

Fig. 7 _ Immediate placement of a XIVE S plus implant.
Fig. 8 _ Final position of the implant.
Fig. 9 _ Insertion of an EsthetiCap provisional abutment.

AD

implants

international magazine of oral implantology

One issue free of charge!



Subscribe now!

You can also subscribe via www.oemus.com/abo

I hereby agree to receive a free trial subscription of **implants international magazine of oral implantology** (4 issues per year). I would like to subscribe to **implants** for € 44 including shipping and VAT for German customers, € 46 including shipping and VAT for customers outside of Germany, unless a written cancellation is sent within 14 days of the receipt of the trial subscription. The subscription will be renewed automatically every year until a written cancellation is sent to OEMUS MEDIA AG, Holbeinstr. 29, 04229 Leipzig, Germany, six weeks prior to the renewal date.

Reply via Fax +49 341 48474-290 to OEMUS MEDIA AG or per E-mail to grasse@oemus-media.de

Last Name, First Name

Company

Street

ZIP/City/Country

E-mail

Signature

Notice of revocation: I am able to revoke the subscription within 14 days after my order by sending a written cancellation to OEMUS MEDIA AG, Holbeinstr. 29, 04229 Leipzig, Germany.

Signature



CDE 4/12



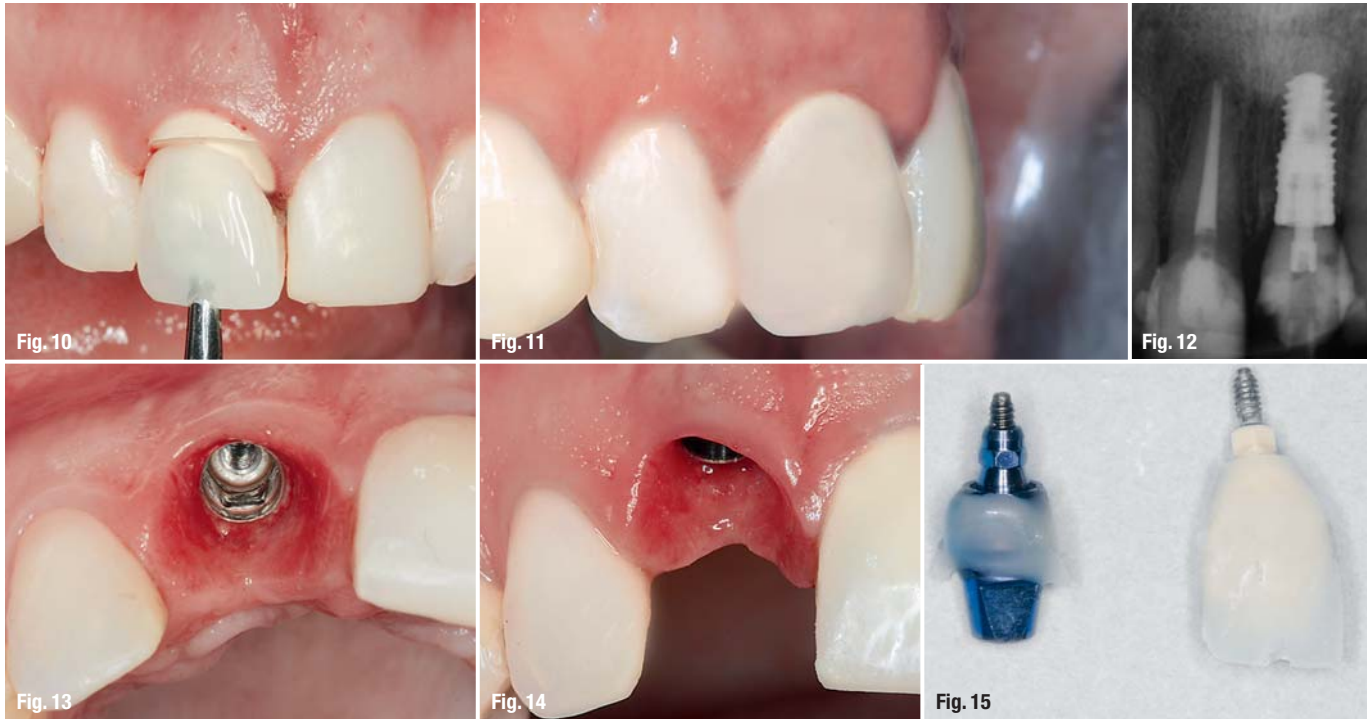

Fig. 10 Implant-supported, screw-retained provisional restoration.
Fig. 11 Clinical situation one week post-implant placement.
Fig. 12 Corresponding X-ray.
Fig. 13 Occlusal view of the soft-tissue contour at the end of osseointegration.
Fig. 14 Facial view of the soft-tissue contour at the end of osseointegration.
Fig. 15 Impression coping customised in the cervical area to match the emergence profile of the provisional crown.

at all stages of the treatment. Before the start of the surgical treatment, initial impressions were taken with alginate. Study models were fabricated based on these and then mounted on a semi-adjustable articulator. A detailed wax-up was made for tooth #11 and a provisional crown was fabricated from heat-polymerised acrylic resin. The provisional crown was trimmed at the interior surfaces for use with a provisional implant abutment.

The periodontal fibres surrounding tooth #11 in the alveolar socket were loosened with a periosteal elevator (DENTSPLY Implants) and the tooth was extracted atraumatically (Figs. 4 & 5). The horizontal fracture of the root below the cervical area of the extracted tooth verified the initial diagnosis (Fig. 6). The socket walls were considered intact and inspection revealed no signs of fenestration. Any residual fibres were scraped off. The implant site was then prepared according to the manufacturer's guidelines and a XIVES plus implant (DENTSPLY Implants; 4.5x11 mm) was inserted with sufficient initial stability, which was mainly achieved on the palatal side of the implant site. The implant collar was placed 3 mm below the cemento-enamel junction of the adjacent teeth (Figs. 7 & 8).

The titanium TempBase abutment, which acted as the placement head, was removed from the implant and an EsthetiCap plastic abutment (both DENTSPLY Implants) was fitted on the implant (Fig. 9). The design of this anatomically shaped abutment supports the soft tissue and interdental papillae adequately. Furthermore, it enables the creation of

a suitable emergence profile from the moment of implant placement. The highly polished surfaces prohibit accumulation of dental plaque and facilitate oral hygiene. At this stage, soft-tissue support is crucial for achieving an aesthetic result for the provisional restoration and maintaining it to the final stage.

The previously fabricated provisional crown was fitted on the abutment with autopolymerised acrylic resin, maintaining the access hole on the palatal aspect for the fixation screw (Fig. 10). Furthermore, the outer contour of the provisional crown was checked repeatedly to ensure support of the gingival margin without excessive pressure, which could lead to tissue shrinkage. The provisional crown was designed 1 mm shorter than tooth #21 to avoid possible occlusal loading at maximum intercuspation or side movement (Fig. 11). The implant position in the socket and the abutment fit were checked radiographically (Fig. 12).

The osseointegration period of four months was uneventful and the soft tissue around the implant did not exhibit any signs of inflammation. The interdental papillae were maintained in shape, height and volume (Figs. 13 & 14). In order to support the soft tissue around the implant for impression taking, a prefabricated impression coping was customised using photopolymerised low-viscosity composite material (Figs. 15 & 16). For this implant, an all-ceramic prefabricated zirconium CERCON abutment (DENTSPLY Implants) was selected. This abutment offers adequate soft-tissue support and a suitable



Academy of Osseointegration *28th Annual Meeting*

March 7-9, 2013

Tampa Convention Center • Tampa, Florida



Moving Forward: Evidence, Experience, Excellence

- Opening Symposium: *Quality Evidence – Quality Treatment – Quality Outcomes*
Featuring: Edward Alan; Daniel Buser; Lyndon Cooper; Richard Roblee; Clark Stanford & Robert Winter
- 36 Corporate Forum Presentations
- Commercial Exhibits
- Emerging Treatment Option Sessions (New)
- Limited Attendance Lectures
- Lunch and Learn Presentations
- Poster Presentations
- Round Table Clinics
- Restorative & Surgical Tracks
- Social Events
- Treatment Approaches
- Closing Symposium: *Where Are We Today and What Does the Future Hold?*
Featuring: Urs Belser; David Garber; Joseph Kan; Henry Salama; Maurice Salama; & William Scarfe



osseo.org



ADA CERP® | Continuing Education
Recognition Program

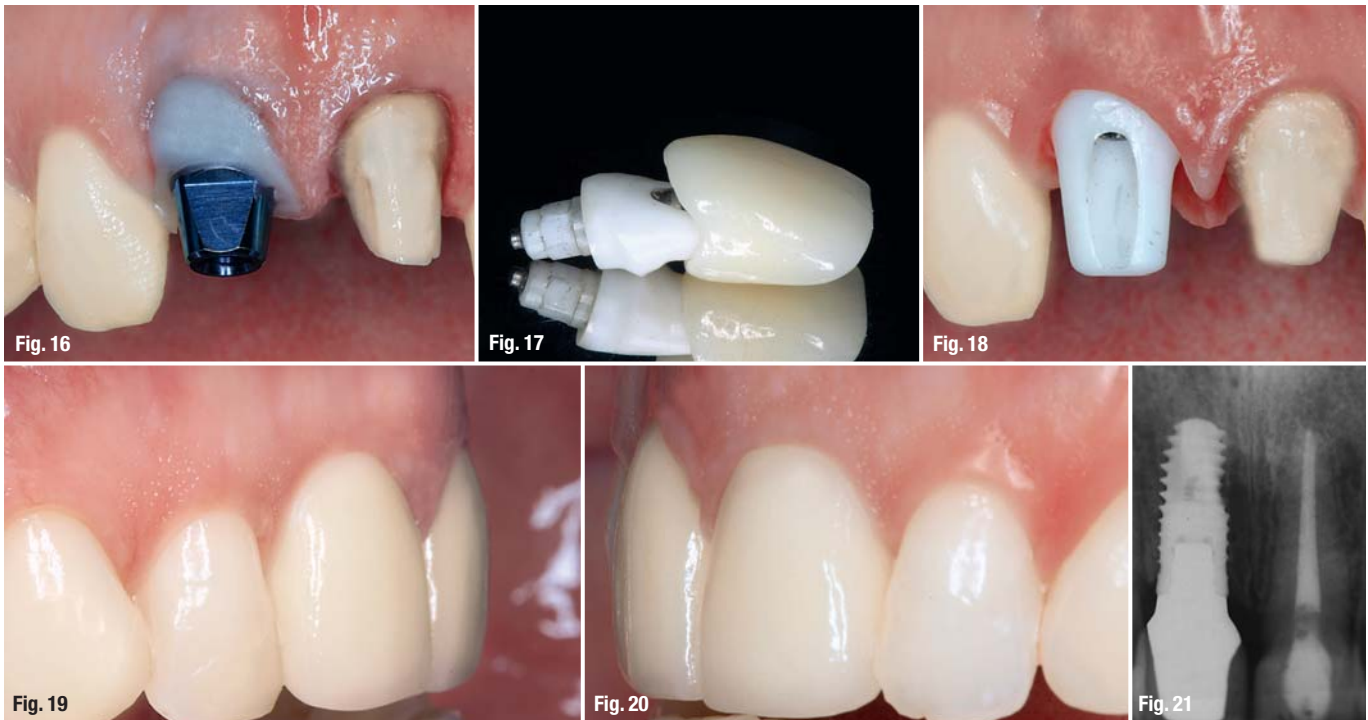

Fig. 16_ Impression for the prepared natural tooth and the XiVE S plus implant.

Fig. 17_ All-ceramic crown and corresponding implant abutment (CERCON).

Fig. 18_ Try-in of the modified ceramic CERCON abutment.

Fig. 19_ Final clinical result: buccal view of the implant restoration.

Fig. 20_ Buccal view of the restored natural tooth.

Fig. 21_ Radiographic control at one year post-implant placement.

emergence profile for the crown (Figs. 17 & 18). The use of ceramic abutments prevents discoloration in the gingival area even when the soft tissue is thin. Two porcelain crowns were fabricated to the desired shape and colour (Figs. 19 & 20). The final result fulfilled the patient's aesthetic demands and her initial insecurity dissolved after the insertion of the implant and the provisional restoration. The hard- and soft-tissue condition around the implant was stable at the one-year recall (Fig. 21).

Discussion and conclusion

Implant placement subsequent to tooth extraction in conjunction with the use of provisionals in the anterior maxillary region is certainly challenging for the dental practitioner. However, this treatment modality offers several advantages, including reduced clinical time, a single local anaesthetic injection, a flapless procedure and immediate placement of the implants. From the patient's point of view, the immediate incorporation of a fixed implant-supported provisional restoration is very acceptable and even requested. With the clinical procedure described here, both dentist and patient can evaluate the aesthetics of the restoration. Soft-tissue support is enhanced and achievement of the desired result is facilitated. With initial implant stability, proper tissue management and correct use of the available implant components, a predictable aesthetic result can be produced. On the other hand, occlusal control, oral hygiene and a regular recall programme should be considered prerequisites for maintaining a long-lasting restoration.

Single-tooth implants have shown high success rates in both the anterior and the posterior regions of the maxilla and the mandible.¹⁻⁴ Immediate post-extraction implant placement has been done since the early years of the clinical application of implants with very good clinical outcomes.⁵⁻⁸ Decisive factors for immediate implant placement are lack of infection in the periodontal tissues and an intact tooth socket. Immediate incorporation of a temporary restoration has been presented in the literature with most encouraging results.⁷⁻¹⁴ Although clinical experiences have advocated this clinical technique for many years, more extended long-term clinical studies are necessary to prove the efficacy of the method and establish a stable clinical protocol.

Editorial note: A complete list of references is available from the publisher.

contact

cosmetic
dentistry

Dr Stefanos Kourtis

Dept. of Prosthodontics, University of Athens
Plaza Chrys. Smyrnis 14
17121 Athens
Greece

Tel.: +30 21 0 935 7306

stefkour@dent.uoa.gr



2013
中国口腔种植年
Year of Oral
of Implantation

2013
CDS
China Dental Show



The 15th CSA Annual Meeting & 2013 China Dental Show

2013·Shanghai

Shanghai Everbright Convention & Exhibition Center

15th–18th Aug 2013

主承办单位
Organizer
协办单位
Co-organizer
支持单位
Supported By



中华口腔医学会



通过ISO9001质量体系认证

国药励展



上海市口腔医学会



美国商务部

Contact us:

Germany and Austria
Ms. Rahel Hilker
Reed Exhibitions GmbH
Tel: +49 211 55 628 521
Fax: +49 (0) 211 55 62 31
E-mail: rahel.hilker@reedexpo.de

Japan
Ms. Keiko Itai
Reed Exhibition ISG Japan
Tel: +81 (0) 3-5575-7510
Fax: +81 (0) 3-5575-0440
E-mail: itaik@reedexpo.co.jp

Korea
Ms. Cui Yinxia
Sinoseoul Co., Ltd.
Tel: +82 2 6370 8850
Fax: +82 2 6371 8004
E-mail: yinxia@seline.co.kr

United States and Canada
Mr. David Thomas
International Sales Group USA
Tel: +1-203-840-5420
Fax: +1-203-840-9420
Email: dthomas@reedexpo.com

Taiwan
Ms. Angel Su
Formosa Cultural Corporation
Tel: +886-2-82273269
Fax: +886-2-82273269
E-mail: angel@fmh.com.tw

Other countries and regions
Mr. Gu Ying
Reed Sinopharm Exhibition Co., Ltd.
Tel: +86-10-84556603
Fax: +86-10-82022922
E-mail: ying.gu@reedsinopharm.com

www.ChinaDentalShow.com

Replacement of a single anterior tooth

Surgical procedure and three-year results

Author_Dr Peter Randelzhofer, Germany

Initial presentation:

Fig. 1 The patient had a high smile line, and tooth #11 was discoloured and had a poor prognosis. The gingiva was thick and the interdental papillae had a high-scalloped appearance.

Fig. 2 Radiograph showing endodontic infection of tooth #11.

Tooth extraction:

Fig. 3 Careful extraction of tooth #11.

Fig. 4 Good preservation of the marginal hard and soft tissue.

Fig. 5 Intact coronal buccal bone plate: Note the thin interdental papillae. The remaining scar tissue of the former apex resection is clearly visible.

Fig. 6 After a vestibular half-circle incision in the apical part of the keratinised gingiva, a flap was reflected downwards.

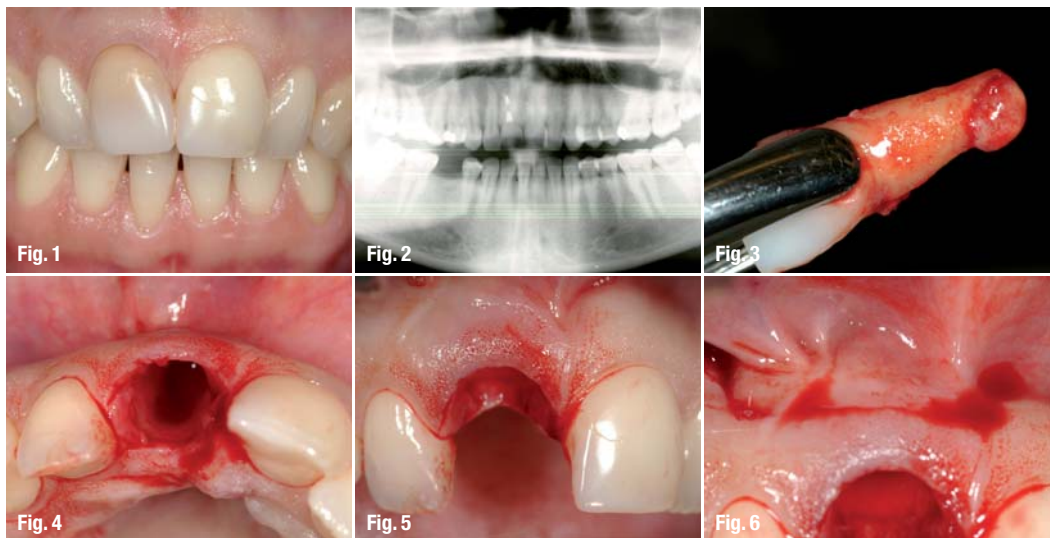
Fig. 7 The apical bone defect is visible. Granuloma tissue and endodontic material were accurately removed with the help of a magnifying glass.

Implant placement:

Fig. 8 Accurate 3-D placement of a 4.3 mm diameter implant.

Fig. 9 The implant was inserted with a palatinal orientation and a minimum distance of 2 mm to the buccal bone plate in order to prevent its resorption.

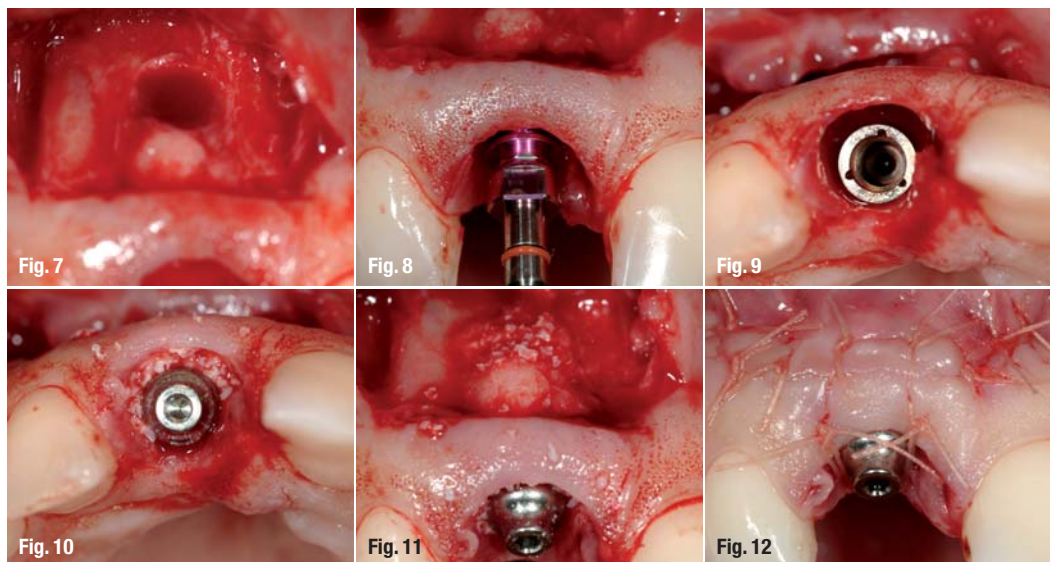
The implant depth was 2 mm below the gingival sulcus and was dependent on the sulcus of tooth #21. To achieve a primary stability of a minimum of 35 Ncm, the final drill was not taken to its maximum depth.



Information on patient and treatment

At the age of 14, the 42-year-old female patient had experienced trauma to tooth #11, leading to luxation and tooth mobility. Endodontic treatment

had been carried out in order to correct a discoloration of that tooth aesthetically, which had begun 15 years before the intervention. About ten years after the endodontic treatment, an apex resection had been necessary to treat a periapical infection.



FDI 2013 Istanbul Annual World Dental Congress

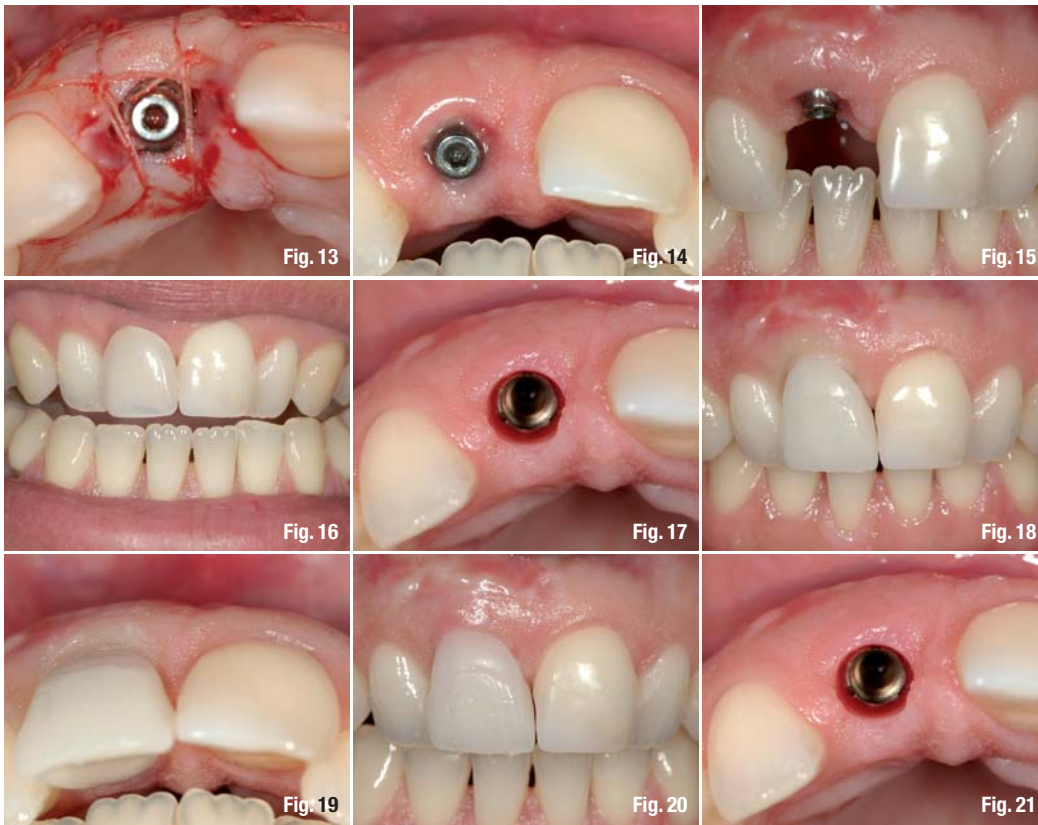
28 to 31 August 2013 - Istanbul, Turkey

Bridging Continents for Global Oral Health



2013 ISTANBUL

www.fdi2013istanbul.org
congress@fdi2013istanbul.org



Owing to pulsating pain and the previous endodontic treatment, the tooth was considered hopeless with regard to an optimal long-term outcome and was to be extracted. The X-ray examina-

tion confirmed a chronic infection around the apex. The soft tissue was intact with a satisfactory attachment level to the neighbouring teeth. The quality of the rather thick gingiva was good. The incision

Bone augmentation:

Fig. 10 Augmentation of the remaining spaces between the 4 mm bottle-neck healing abutment and the buccal bone plate with Bio-Oss particles (Geistlich).

Fig. 11 Additional augmentation of the apical bone plate with grafting material. Use of a membrane was not necessary because of the anatomical shape of the defect.

Fig. 12 Primary wound closure with 5.0 resorbable vicryl sutures. The apical flap was closed conventionally.

Fig. 13 The bottle-neck design of the transmucosal abutment enabled a tensionless wound closure.

Healing:

Fig. 14 Four weeks post-op: Good soft-tissue healing and gingival adaptation around the bottle-neck abutment.

Fig. 15 Stable papillae, nicely preserved soft-tissue volume.

The temporary crown was used to establish a natural sulcus around an implant crown.

Fig. 16 The removable provisional, used by the patient for the four-month healing period, showed adequate gingival height for a functionally and aesthetically acceptable result.

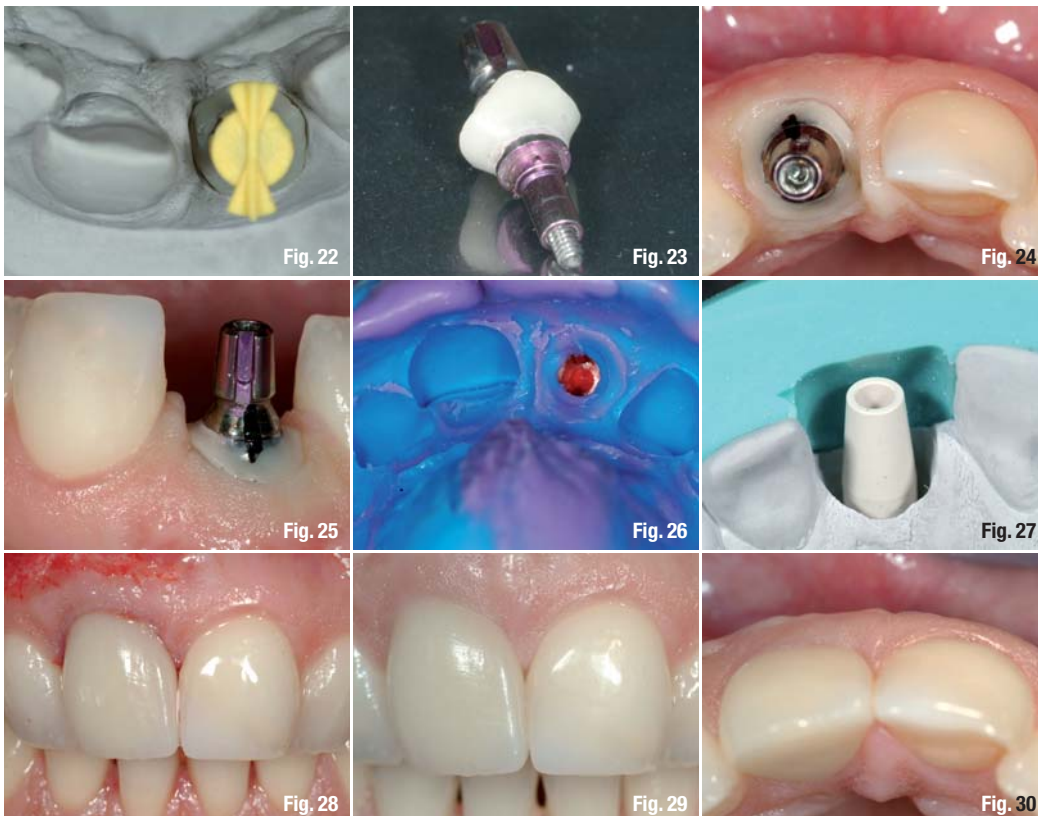
Fig. 17 Nicely healed and healthy soft tissue around a well-integrated implant, replacing tooth #11. The absence of scar tissue thanks to the flap design is obvious.

Soft-tissue management:

Fig. 18 Placement of a temporary crown with soft-tissue management for a natural looking emergence profile. The submerged part of the occlusal screw-retained crown (concave tulip-shaped design) supported the subgingival soft tissue.

Fig. 19 The screw channel (performing the labial part of the crown) was covered with a composite inlay. Farther apically, the scar tissue from the earlier apex resection was easily removed.

Fig. 20 Natural-looking emergence profile. The mesial part needed to be built up a little more.



Impression taking and prosthetic reconstruction:

Fig. 21_Clinical situation before impression taking.

Fig. 22_The ideal emergence profile of the temporary crown was copied with an individual impression post and reproduced on the master model.

Fig. 23_Individual impression post.

Fig. 24_Individual impression post placed on the implant and the opening of the sulcular structures.

Fig. 25_Lateral view of the implant with impression post.

Fig. 26_Impression tray capturing the crown-gingiva interface.

Fig. 27_Master model with temporary abutment and silicone index showing the preservation of the backward-planning information.

Fig. 28_IPS e-max crown (Ivoclar Vivadent) immediately after definitive placement on the individualised ceramic abutment with PANA VIA cement (Kuraray). The apical scar tissue was shaped with a diamond drill for a smoother gingival outcome.

Result after one year:

Fig. 29_Final result one year after implant placement. The soft tissue shows a stable and near-perfect interface with the implant crown.

Fig. 30_Optimal tissue contour.

Results after three years:

Fig. 31_Stable soft tissue showing no resorption at the implant-crown interface or gingival sulcus.

Conclusion:

Fig. 32_Initial situation before extraction.

Fig. 33_Initial situation with non-preservable tooth #11.

Fig. 34_Clinical situation three years after implantation.

Fig. 35_Final X-ray after one and three years.

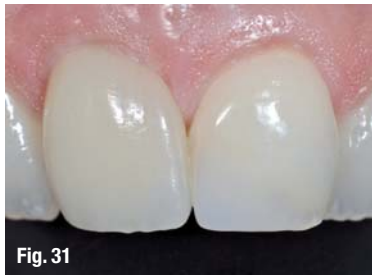

Fig. 31

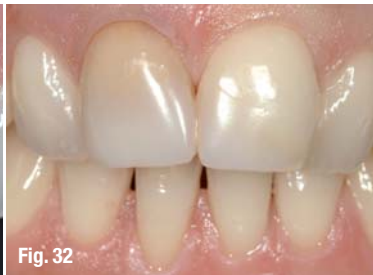

Fig. 32

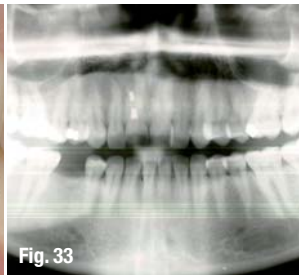

Fig. 33

for the apex resection had resulted in scar tissue at the junction of the keratinised and non-keratinised gingiva. Tooth #21 had been filled with a four-side composite filling at the mesial side.

Since the expectations of the patient regarding the aesthetic outcome were very high, we decided on immediate implant placement with a CAMLOG SCREW-LINE Implant after extraction of tooth #11. The soft- and hard-tissue structures were preserved as far as possible. Bone augmentation was performed at the time of implantation to treat the bone defect. The prosthetic treatment was to take place three to six months post-operatively, depending on the size of defect.

Conclusion

Implant-borne reconstruction of missing anterior teeth is challenging, especially in fresh extraction sockets. For a functionally and aesthetically stable outcome, sufficient hard and soft tissue is needed. Care has to be taken to preserve the existing tissue structures. Vertical and horizontal bone loss after insertion of the implant due to remodeling processes has to be taken into account.

In the present case, the patient had high expectations regarding the aesthetic outcome. An alternative treatment of this case would have been a bridge solution combined with augmentation of the pontic area. Such a solution would have held fewer risks and allowed achievement of a more predictable soft-tissue situation. The patient was informed of the risks and alternatives. However, she decided on implant reconstruction.

We aimed to preserve the soft- and hard-tissue structures to achieve an adequate level of marginal gingiva together with an adequate interdental bone peak. Therefore, we decided on immediate implant placement after extraction of tooth #11, creating optimal soft- and hard-tissue structures around the implant at the time of implant placement. The soft tissue around coronal part remained untouched and the coronal aperture was closed with a trans-

mucosal abutment. The flap preparation was performed in the apical region only. This technique was chosen to provide the best possible interface between crown and gingiva.

We were able to achieve an ideal 3-D positioning of the implant and an optimal aesthetic result that was still stable after three years.

_about the author



Dr Peter Randelzhofer

studied dentistry in Munich, Germany, and received his training in prosthetics and implant dentistry at the University of Freiburg, Germany. In 2001, he was appointed Assistant Director of the Centre for

Implantology and Periodontology, a private practice in Amstelveen, Netherlands. In 2002, he received his certification as an implantologist from the NvOI (the Dutch oral implantology association). From 2005 to 2009, he worked at the Centre for Implantology and Periodontology. In 2009, he founded the group practice for implantology and periodontology in Munich, Germany, together with Dr Claudio Cacaci. Dr Randelzhofer is author of numerous publications and he is an internationally renowned speaker. He is active as a trainer and teacher at various institutions in the Netherlands and Germany, and he is a member of several national and international study groups.

Implantat Competence Centrum in München

Weinstraße 4
80333 Munich
Germany

Modified clinical approach for improved aesthetics in full-arch restoration

Authors _ Dr Henriette Lerner, Germany, Prof. Z. Jacobson & Dr Hugh Flax, USA

_Introduction

The target of modern dentistry is the achievement of a natural aesthetic outcome, function and stability using a minimally invasive, maximally effective technique and in a reasonable period. This case study demonstrates that new philosophies concerning implant design, provisional and final abutment design, as well as paradigm shifts in treatment approaches, can lead to superior aesthetic results. In full-arch implant-supported restoration, immediate placement with immediate loading has been well documented. The literature shows a high success rate of 97% with this kind of treatment in the mandible¹¹⁻¹⁷ and of 96% in the maxilla.¹⁸⁻²⁰ Osseointegration of implants has been achieved routinely and with a high degree of success. Contemporary implant dentistry focuses on aesthetic success aside from functional results. One of the compromises in aesthetics in a situation of adjacent implants is the short papilla between two implants, where a maximum length of 3.5 mm can be achieved.¹ This can be explained by loss of the inter-implant bone.

The advantages of a platform-switched implant design regarding bone and tissue stability are well documented in the literature.²⁻⁶ The resulting stability of the bone is explained through the increased

distance of the micro-gap from the bone (a minimum of 0.45 mm is adequate). Another way to preserve bone in the long term is by selecting an implant design with a micro-thread design at the collar. The positive influence of the micro-thread design at the collar of the implant has been biomechanically explained by Steigenga et al.⁷ Bone is stronger when loaded in compression, and 30% weaker when subjected to tensile forces. During function, the shear forces are transformed into small compression and traction forces. Another observed benefit of platform switching is the non-surgical increase in tissue volume in the healing phase.

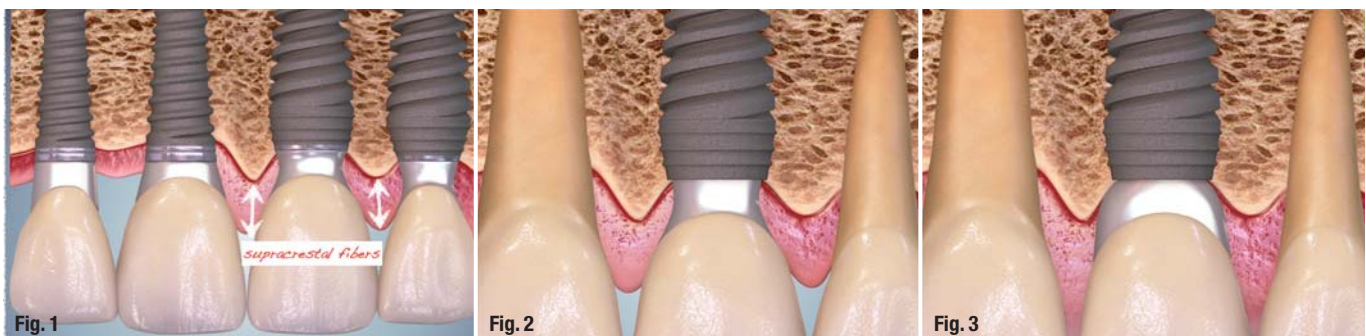_Papillary area

Additionally, Gargiulo⁸ has demonstrated that the higher the peri-implant soft tissue, the lower the risk of bone loss in the process of increasing the biological width.⁸ Through decreased bone loss and a resulting reduction in bone instability, as well as increased thickness of the tissue, more supra-crestal fibres can be gained (Figs.1 & 2). Owing to this philosophy in designing the provisional, the final abutment and the crown, we were able to manipulate the soft tissue (Fig. 3) and gain an inter-implant papilla length comparable to the length of the papilla between two natural teeth (5 mm, Fig. 4).

Fig. 1 _ The platform-switching design of the implants facilitated preservation of bone at the collar and the gaining of supra-crestal fibres.

Fig. 2 _ Concave profile of the provisional abutment.

Fig. 3 _ Convex profile of the final individual abutment.



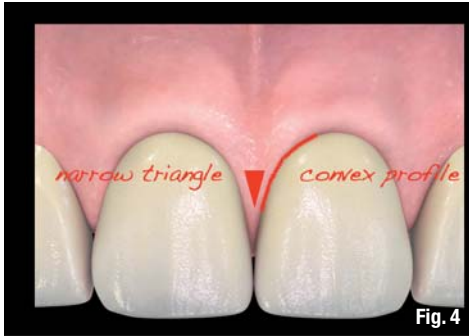

Fig. 4

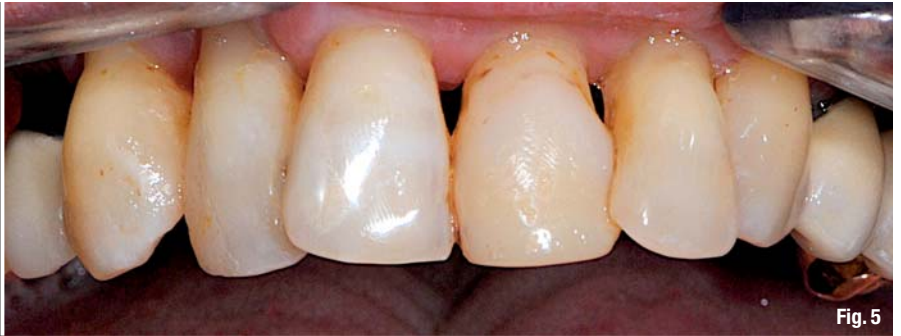

Fig. 5

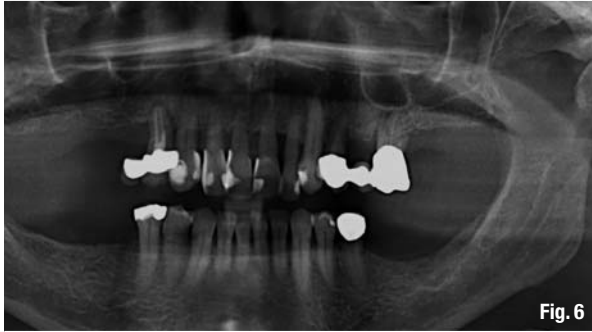

Fig. 6

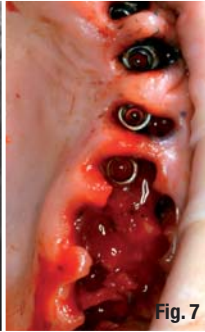

Fig. 7

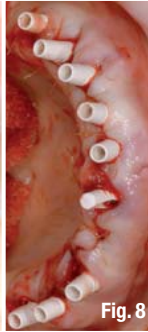

Fig. 8



Fig. 9

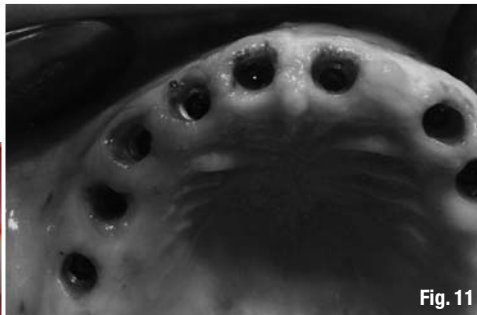

Fig. 11

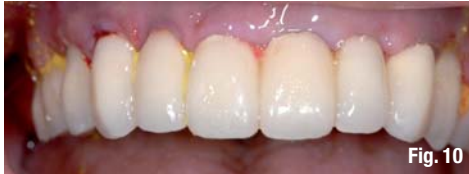

Fig. 10

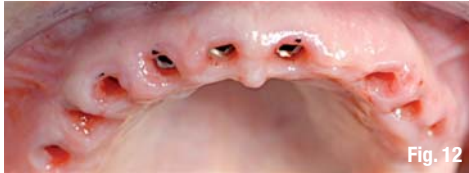

Fig. 12



Fig. 13

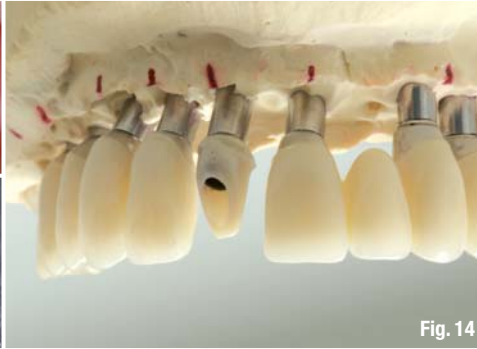

Fig. 14



Fig. 15

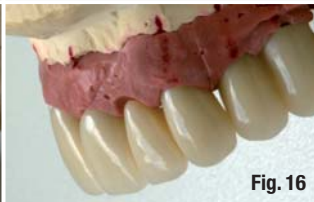

Fig. 16

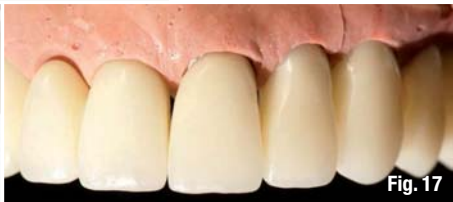

Fig. 17

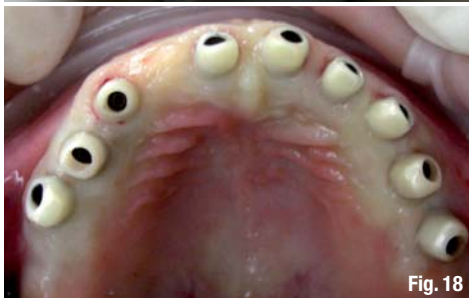

Fig. 18

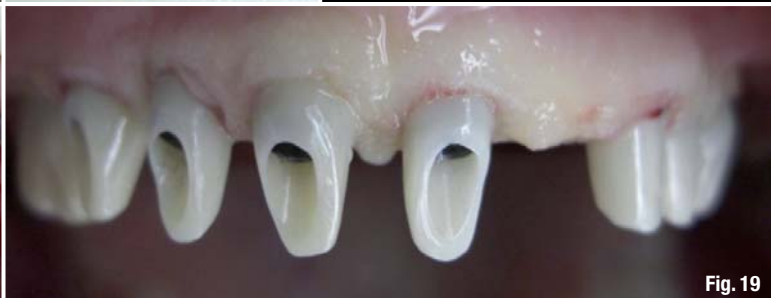

Fig. 19

Fig. 4 Narrow triangles between the final crowns, restoring the physiological and aesthetic contact points.
Fig. 5 Periodontally damaged teeth, mobility Grade II.
Fig. 6 Horizontal bone loss.
Fig. 7 Immediate implant placement with immediate loading.
Fig. 8 PEEK abutments.
Fig. 9 Provisional PEEK abutment with concave running room.
Fig. 10 Provisional bridge during post-op treatment with iodoform.
Fig. 11 Situation after healing/osseointegration.
Fig. 12 After healing.
Fig. 13 Modification of the soft-tissue biotype to a straight or slightly convex profile.
Fig. 14 Individually fabricated zirconia abutments (LAVA) on a titanium base, with a preparation limit of 0.5 mm below the gingival margin.
Fig. 15 Individually fabricated zirconia CAD/CAM abutments and IPS e-max lithium disilicate (Ivoclar Vivadent) ceramic crowns.
Fig. 16 Manipulation of the soft tissue to achieve the desired aesthetic outcome.
Fig. 17 Aesthetic gingival outcome shown on the model.
Fig. 18 Insertion of the abutments, allowing one minute of compression.
Fig. 19 Positive effect on the length of the papilla.

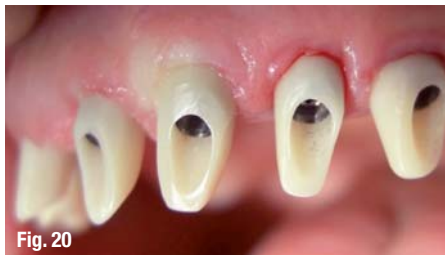

Fig. 20

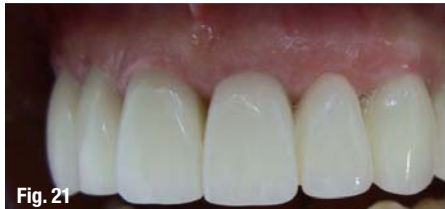

Fig. 21

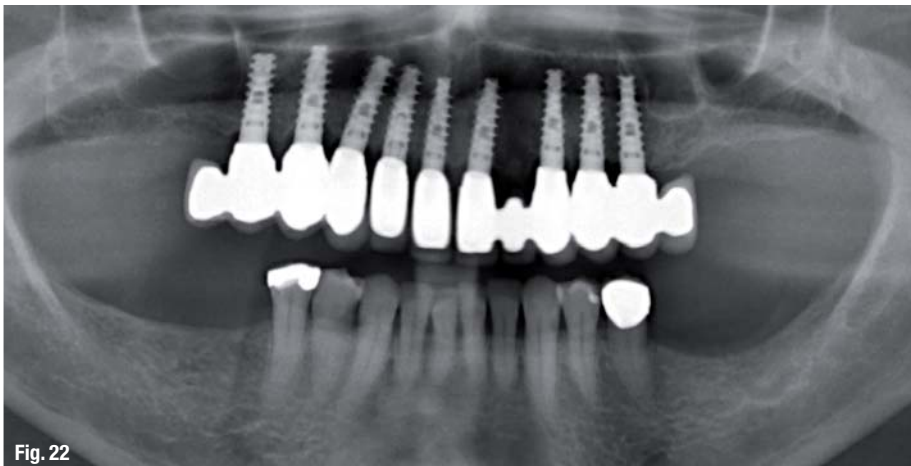


Fig. 22

Fig. 20 Revascularisation after one minute.

Fig. 21 Crowns inserted.

Fig. 22 Situation after inserting the crowns.

Fig. 23 Restoration.

Abutment

The running room for the provisional abutment was concave (Figs. 1 & 2).⁹ After osseointegration, we modified the running room to a straight or slightly convex profile (Fig. 3), especially approximally. The tissue extended from 0.5 to 1 mm in the direction of the contact point. The final construction followed the natural parameters of the interdental contact points in the natural dentition, as defined by Chu et al.¹⁰ Designing the interdental spaces as narrow triangles with slight convexities, we managed to guide this tissue by another 0.5 to 1 mm to the ideal contact point, and give the entire construction a natural appearance.

Clinical case example

A 50-year-old patient presented with a tooth mobility of Grade II to III (Figs. 5 & 6). He wished to have his aesthetic restoration fixed. In cases such as this, an alternative chairside and laboratory workflow can guide our treatment. Chairside workflow included an aesthetic analysis, impressions, a functional analysis, X-rays, CT, and evaluation of the hard and soft tissue. The treatment plan should be minimally invasive, of maximum effectiveness and aim for the best aesthetic results. This means immediate implant placement and immediate loading. At the laboratory, a mock-up of the intended result was created. Afterwards, the mock-up was discussed with the patient and tried in chairside. At the next appointment, implant placement using a provisional and surgical, aesthetic-driven guide, fabricated by the laboratory in advance, and immediate restoration followed chairside. The implants were selected in order to allow immediate loading (Fig. 7). For immediate loading, an implant's features and insertion protocol have to provide for high primary stability. Therefore, self-cutting threads and a drilling protocol for undersized implant site preparation were necessary. Furthermore, the rough sur-

face of the implant shoulder and the micro-thread design at the collar were important for long-term bone and soft-tissue stability. Platform-switched provisional abutments with concave running room and made of PEEK (polyether ether ketone) were additional features that qualified the implant selected for immediate loading (Figs. 8 & 9).

Another important aspect was the parameters applied in the immediate loading of the implants inserted in extraction sockets. Primary stability was achieved with an insertion torque of 35 Ncm. About three quarters of the implant surface should be covered by the host bone. The gap between the implant and the buccal bone was augmented to a maximum of 1.5 mm (Tarnow 1997) (Fig. 7). Owing to these conditions, we were able to insert immediate implants and to perform immediate loading with a rigid fixed bridge (Fig. 10). After the osseointegration (Figs. 11 & 12) individual abutments were CAD/CAM fabricated from zirconia (LAVA, 3M ESPE). Individually, the running room was modified to a slightly convex or straight profile (Figs. 13–15), so that the tissue was shifted interdentially (Figs. 18–20) and another 0.5 to 1 mm was gained in papilla length. Tooth reconstruction was employed to produce the crowns. The convexities of the crown contour at the gingival margin were produced with respect to the harmony of the pink and white aesthetics (Figs. 16 & 17). Symmetry, the golden proportion and the individual demands of the patient were given particular consideration (Figs. 21–23).

Conclusion

This treatment method, with the main aim of imitating or even improving the natural dentition, has been used for 12 full-arch cases over the last two years. Now, the paradigm of the short papilla between two implants is over. In order to obtain the natural gingival architecture between implants, we adhere to the following:

1. immediate implant placement in perfect implant position;
2. immediate loading of the implant under initial stable conditions;
3. use of implant systems with a platform-switching design;
4. use of provisional abutments with a convex profile;
5. use of provisional crowns with a flat profile;
6. use of final abutments with a slightly convex profile to move the tissue gained into the interdental space;
7. restoration of the natural proportion of the interdental spaces and contact points; and
8. creation of narrow triangles, forming space for the papillae.

The authors wish to acknowledge Roland Danneberg, master technician, for the prosthetic work. Dr Lerner wishes to acknowledge Dr Morton Perel for his professional support.

All images were created in DentalMaster. Material copyright by MD Simulation Ltd (www.dentalmaster.net).

Editorial note: A complete list of references is available from the publisher.

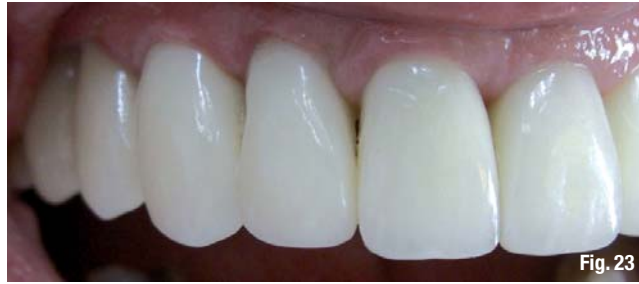

Fig. 23

_contact

cosmetic dentistry

Dr Henriette Lerner

Implantologie, Parodontologie, Oral Chirurgie & Ästhetische Zahnheilkunde
HL-DENTCLINIC
Ludwig-Wilhelm-Straße 17
76530 Baden-Baden, Germany


Tel.: +49 7221 398730
Fax: +49 7221 3987310

info@hl-dentclinic.de
www.hl-dentclinic.de

AD

CAD/CAM

international magazine of digital dentistry



One issue free of charge!

 **Subscribe now!**

I hereby agree to receive a free trial subscription of **CAD/CAM** (4 issues per year). I would like to subscribe to **CAD/CAM** for € 44 including shipping and VAT for German customers; € 46 including shipping and VAT for customers outside of Germany unless a written cancellation is sent within 14 days of the receipt of the trial subscription. The subscription will be renewed automatically every year until a written cancellation is sent to Dental Tribune International GmbH, Holbeinstr. 29, 04229 Leipzig, Germany, six weeks prior to the renewal date.

▶ **Reply** via Fax +49 341 48474-173 to Dental Tribune International GmbH or per E-mail to: n.dehmel@dental-tribune.com

Last Name, First Name	
Company	
Street	
ZIP/City/Country	
E-mail	Signature

Notice of revocation: I am able to revoke the subscription within 14 days after my order by sending a written cancellation to Dental Tribune International GmbH, Holbeinstr. 29, 04229 Leipzig, Germany.

Signature

CDE 4/12

DENTAL TRIBUNE INTERNATIONAL GMBH
Holbeinstr. 29, 04229 Leipzig, Germany, Tel.: +49 341 48474-302,
Fax: +49 341 48474-173, E-Mail: n.dehmel@dental-tribune.com



ESCD & SSER joint meeting in Bucharest—Some say “the best!”

Author_Dr Philip Lewis, UK

This year, the annual meeting of the European Society of Cosmetic Dentistry (ESCD) was hosted by the Society of Esthetic Dentistry in Romania (SSER). The event was held along with the ninth International Congress of Esthetic Dentistry from 17 to 19 May 2012. Hundreds of enthusiastic practitioners gathered to enjoy three days of some of the best educational material offered during 2012. Speakers from across the world joined Romanian lecturers to present a seminar second to none.

The event took place in Bucharest's finest and architecturally impressive J.W. Marriott Grand Hotel. Bucharest is an excellent location. Easily accessed, the city boasts superb conference facilities, as well as world-class accommodation and dining. Nightlife can be as quiet or as exciting as you please, ranging from theatre and cultural events to lively nightspots and revues. Dentists and their families deserve a little relaxation after hard study and in Bucharest there is something for everybody.

Instrumental to the organisation of the meeting was ESCD member Dr Florin Lăzărescu (Vice-President of ESCD since May 2012). As a leading member of the SSER too, he was able to provide us with an exclusive tour of headquarters and explain how dentistry in his country has developed to become among the best in the world. The social events at ESCD meetings are legendary, and this meeting was no exception. Nightclubs, restaurants and even a short tour of the city allowed people to interact. Old friends were greeted and many new friends were made. Enthusiasm for quality aesthetic dentistry knows no boundaries, and discussing the similarities and differences between communities brings people closer together and leads to the forging of valuable new alliances.

Lectures in two main halls were complemented by numerous tutorials and hands-on sessions. Topics covered included just about everything of importance to the modern aesthetic dentist. Tooth whitening, implants, facial aesthetics, composites; all these practical skills were considered in depth. Further lectures dwelt on pure science and explored future techniques and technologies. There were many presentations, both by household names in dentistry and the less well known, all united in providing information that would be of immediate benefit to every delegate. It is impossible

for any course reviewer to attend every lecture and tutorial at a meeting like this so I apologise to those clinicians whose presentations I missed. The highlights of the meeting for me included:

Dr Nadim Aboujaoude: Nadim is one of those unusually skilful lecturers who is able to make delegates feel they are being entertained rather than educated! His presentation on smile enhancement was both informative and useful, and left delegates thinking about how modern technologies can be of real benefit to both their patients and themselves.

Dr George Freedman: This world-respected clinician did not disappoint! George is a mine of practical information and as usual presented tips that could be introduced into practice the very next day.

Prof. Marcel Wainwright: Facial aesthetics is becoming increasingly popular as an enhancement to general dentistry. This master described the use of dermal fillers from the standpoint of a clinician with a thorough knowledge of when they might be of benefit.

Robert Mopper: The famous Mopper family not only lecture on but also manufacture high-class composites! For this reason, Robert was able to demonstrate reliable techniques in his hands-on workshop.

Dr Marcus Tröltzsch: It is so easy to become obsessed by our small area of interest that we sometimes forget that the teeth are actually joined to the rest of the body! Marcus expanded on this, inviting clinicians to adopt a holistic approach to the well-being of the individual.

Dental seminars are great but it is often the events that take place outside the lecture halls that are the most important. Delegates from all over the world are given the opportunity to speak to each other and share experiences. Visiting the trade exhibitions allows clinicians to source vital supplies and materials that will enhance their practices. Trade exhibitors are also an invaluable source of information about products and how best they can be used. This was truly a meeting not to be missed. Delegates who attended certainly have an advantage. Their practices are likely to grow both financially and in terms of respect from the information they learned. If you want to be at the leading edge of practices in 2013, I strongly recommend you attend the next ESCD annual meeting. It will be held in the outstanding Italian city of Turin from 3 to 5 October 2013, so reserve the dates now! Full details can be found on the ESCD website: www.escdonline.eu.

_author

cosmetic
dentistry

Dr Philip Lewis has a private dental practice on the Isle of Wight, UK. He is the General Secretary of the European Society of Cosmetic Dentistry. He can be contacted at philip-lewis@btconnect.com.

CLEARFIL DC CORE PLUS KIT: Stressless and reliable

Today dentists are looking for a core build-up material that offers not only reliability and good performance but also ease of use. Such core material has to be aimed at high-quality and long-lasting restoration. Therefore, at the beginning of 2012, Kuraray introduced its new core build-up material, CLEARFIL DC CORE PLUS KIT. This material meets all the demands of today's dental practice.

CLEARFIL DC CORE PLUS is a dual-cure (light curing with self-curing property), two-component core build-up material supplied in an automix delivery system for aesthetic and reliable restoration. The self-curing property of this new core material is the perfect solution for those areas of the root canal that cannot be accessed for light curing. For all other areas, curing time can be reduced by light curing.

For core build-up restorations, it is essential to reduce the risk of contamination using a short and easy application procedure. CLEARFIL DC CORE PLUS is designed for stressless restoration, thanks to its simplified procedure and optimal paste handling. Only one mixing tip is needed for all steps, from application in the root canal to the core build-up, resulting in a working time of three minutes. Furthermore, the self-etching technology offers effective and reliable adhesion to dentine without damaging the dentine. Owing to its outstanding self-etching adhesive properties, CLEARFIL S3 BOND PLUS is the perfect complement to CLEARFIL DC CORE PLUS, which enables excellent long-term clinical performance.

CLEARFIL DC CORE PLUS is yet further proof of Kuraray's outstanding competence in dental materials and its extensive scientific experience. As science and society continue to develop, new questions and challenges also arise for dental materials. Kuraray has been at the forefront of such advancement for over 30 years. Through an intensive and regular exchange of information with its customers, comprehensive research and development, and ongoing training, Kuraray ensures that dentists will always have a reliable partner in the company, which offers attractive solutions for a new era of protective filling therapy.

About Kuraray Europe GmbH

Established in Kurashiki, Japan, in 1926, Kuraray Co. Ltd has a broad knowledge and experience base

in polymer chemistry, chemical synthesis and chemical engineering. Starting with the industrial production of synthetic fibres from viscose, Kuraray soon extended its pioneering technologies and expertise to many more fields of business such as the dental industry, continuously providing effective solutions with a high level of service and a focus on the customer.



In 1978, five years after entering the field of dental materials, Kuraray paved the way for adhesive dentistry with the introduction of the first bonding system, CLEARFIL BOND SYSTEM F. At the same time, the company developed the total-etch technique for enamel and dentine, which marked the beginning of minimally invasive dentistry. Today, Kuraray continues to steadily produce innovative quality products that meet the requirements of a profession that too is developing constantly. Its products that have made history—PANAVIA F2.0, CLEARFIL PROTECT BOND, CLEARFIL SE BOND, CLEARFIL AP-X and ESTENIA C&B—are proof of Kuraray's capability in developing solutions for practice through its pioneering research.

contact

cosmetic
dentistry

Kuraray Europe GmbH

BU Medical Products
Philipp-Reis-Str. 4, 65795 Hattersheim am Main
Germany

dental@kuraray.eu
www.kuraray-dental.eu (EU)
www.kuraraydental.com (USA)

International Events

2013

2nd BIOMET 3i European Symposium
11 & 12 January 2013
Madrid, Spain
www.biomet3ieuropeansymposium.com

International Dental Show
12–16 March 2013
Cologne, Germany
www.ids-cologne.de

AACD Annual Meeting
24–27 April 2013
Seattle, USA
www.aacd.com

DGKZ Annual Meeting
26 & 27 April 2013
Berlin, Germany
www.dgkz.com

8th CAD/CAM & Digital Dentistry International Conference
2 & 3 May 2013
Dubai, UAE
www.cappmea.com

SSER Annual Meeting
16–18 May 2013
Bucharest, Romania
www.sser.ro

EAED Spring Meeting
30 May–1 June 2013
Crete, Greece
www.eaed.org

MIS' 2nd Global Conference
6–9 June 2013
Cannes, France
www.mis-implants.com

Nobel Biocare Global Symposium
20–23 June 2013
New York, USA
www.nobelbiocare.com

IACA 2012
1–3 August 2013
Calgary, Canada
www.theiaca.com

AAED Annual Meeting
7–10 August 2013
Washington, USA
www.estheticacademy.org

FDI Annual World Dental Congress
28–31 August 2013
Istanbul, Turkey
www.fdiworldental.org

ESCD Annual Meeting
3–5 October 2013
Turin, Italy
www.escdonline.eu

BACD Annual Conference
7–9 November 2013
London, UK
www.bacd.com



Cologne. Photo: S. Borisov

submission guidelines:

Please note that all the textual components of your submission must be combined into one MS Word document. Please do not submit multiple files for each of these items:

- _ the complete article;
- _ all the image (tables, charts, photographs, etc.) captions;
- _ the complete list of sources consulted; and
- _ the author or contact information (biographical sketch, mailing address, e-mail address, etc.).

In addition, images must not be embedded into the MS Word document. All images must be submitted separately, and details about such submission follow below under image requirements.

Text length

Article lengths can vary greatly—from 1,500 to 5,500 words—depending on the subject matter. Our approach is that if you need more or less words to do the topic justice, then please make the article as long or as short as necessary.

We can run an unusually long article in multiple parts, but this usually entails a topic for which each part can stand alone because it contains so much information.

In short, we do not want to limit you in terms of article length, so please use the word count above as a general guideline and if you have specific questions, please do not hesitate to contact us.

Text formatting

We also ask that you forego any special formatting beyond the use of italics and boldface. If you would like to emphasise certain words within the text, please only use italics (do not use underlining or a larger font size). Boldface is reserved for article headers. Please do not use underlining.

Please use single spacing and make sure that the text is left justified. Please do not centre text on the page. Do not indent paragraphs, rather place a blank line between paragraphs. Please do not add tab stops.

Should you require a special layout, please let the word processing programme you are using help you do this formatting automatically. Similarly, should you need to make a list, or add footnotes or endnotes, please let the word processing programme do it for you automatically. There are menus in every programme that will enable you to do so. The fact is that no matter how carefully done, errors can creep in when you try to number footnotes yourself.

Any formatting contrary to stated above will require us to remove such formatting before layout, which is very time-consuming. Please consider this when formatting your document.

Image requirements

Please number images consecutively throughout the article by using a new number for each image. If it is imperative that certain images are grouped together, then use lowercase letters to designate these in a group (for example, 2a, 2b, 2c).

Please place image references in your article wherever they are appropriate, whether in the middle or at the end of a sentence. If you do not directly refer to the image, place the reference at the end of the sentence to which it relates enclosed within brackets and before the period.

In addition, please note:

- _ We require images in TIF or JPEG format.
- _ These images must be no smaller than 6x6 cm in size at 300 DPI.
- _ These image files must be no smaller than 80 KB in size (or they will print the size of a postage stamp!).

Larger image files are always better, and those approximately the size of 1 MB are best. Thus, do not size large image files down to meet our requirements but send us the largest files available. (The larger the starting image is in terms of bytes, the more leeway the designer has for resizing the image in order to fill up more space should there be room available.)

Also, please remember that images must not be embedded into the body of the article submitted. Images must be submitted separately to the textual submission.

You may submit images via e-mail, via our FTP server or post a CD containing your images directly to us (please contact us for the mailing address, as this will depend upon the country from which you will be mailing).

Please also send us a head shot of yourself that is in accordance with the requirements stated above so that it can be printed with your article.

Abstracts

An abstract of your article is not required.

Author or contact information

The author's contact information and a head shot of the author are included at the end of every article. Please note the exact information you would like to appear in this section and format it according to the requirements stated above. A short biographical sketch may precede the contact information if you provide us with the necessary information (60 words or less).

Questions?

Magda Wojtkiewicz (Managing Editor)
m.wojtkiewicz@oemus-media.de

cosmetic dentistry _ beauty & science

Publisher

Torsten R. Oemus
oemus@oemus-media.de

CEO

Ingolf Döbbecke
doebbecke@oemus-media.de

Members of the Board

Jürgen Isbaner
isbaner@oemus-media.de

Lutz V. Hiller

hiller@oemus-media.de

Editor-in-Chief

Dr Sushil Koirala
skoirala@wlink.com.np

Co-Editor-in-Chief

Dr So Ran Kwon
smileksr@hotmail.com

Managing Editor

Magda Wojtkiewicz
m.wojtkiewicz@oemus-media.de

Executive Producer

Gernot Meyer
meyer@oemus-media.de

Designer

Franziska Dachsel
f.dachsel@oemus-media.de

Copy Editors

Sabrina Raaff
Hans Motschmann

Published by

Oemus Media AG
Holbeinstraße 29
04229 Leipzig, Germany
Tel.: +49 341 48474-0
Fax: +49 341 48474-290
kontakt@oemus-media.de
www.oemus.com

Printed by

Löhnert Druck
Handelsstraße 12
04420 Markranstädt, Germany

Advisory Board

Dr Michael Miller, USA
Dr Seok-Hoon Ko, Korea

Editorial Board

Dr Anthony Au, Australia
Dr Bao Baicheng, China
Dr Helena Lee, Singapore
Dr Hisashi Hisamitsu, Japan
Dr Jiraporn Charudilaka, Thailand
Dr Mostaque H. Sattar, Bangladesh
Dr Ratnadeep Patil, India
Dr Suhit Raj Adhikari, Nepal
Dr Takashi Nakamura, Japan
Dr Vijayaratnam Vijayakumaran, Sri Lanka



Magda Wojtkiewicz, Managing Editor

cosmetic
dentistry _ beauty & science
is the official publication of:



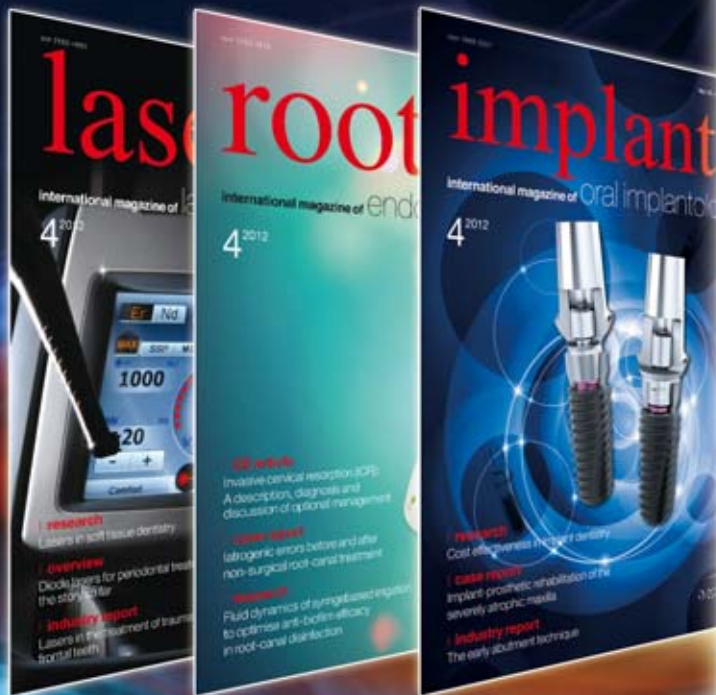Copyright Regulations

_cosmetic dentistry_beauty & science is published by Oemus Media AG and will appear in 2012 with one issue every quarter. The magazine and all articles and illustrations therein are protected by copyright. Any utilisation without the prior consent of editor and publisher is inadmissible and liable to prosecution. This applies in particular to duplicate copies, translations, microfilms, and storage and processing in electronic systems.

Reproductions, including extracts, may only be made with the permission of the publisher. Given no statement to the contrary, any submissions to the editorial department are understood to be in agreement with a full or partial publishing of said submission. The editorial department reserves the right to check all submitted articles for formal errors and factual authority, and to make amendments if necessary. No responsibility shall be taken for unsolicited books and manuscripts. Articles bearing symbols other than that of the editorial department, or which are distinguished by the name of the author, represent the opinion of the afore-mentioned, and do not have to comply with the views of Oemus Media AG. Responsibility for such articles shall be borne by the author. Responsibility for advertisements and other specially labeled items shall not be borne by the editorial department. Likewise, no responsibility shall be assumed for information published about associations, companies and commercial markets. All cases of consequential liability arising from inaccurate or faulty representation are excluded. General terms and conditions apply, legal venue is Leipzig, Germany.

cosmetic

dentistry _ beauty & science



You can also subscribe via
www.oemus.com/abo

 **Subscribe now!**

I would like to subscribe to **cosmetic dentistry** for € 44 including shipping and VAT for German customers, € 46 including shipping and VAT for customers outside Germany, unless a written cancellation is sent within 14 days of the receipt of the trial subscription. The subscription will be renewed automatically every year until a written cancellation is sent to OEMUS MEDIA AG, Holbeinstr. 29, 04229 Leipzig, Germany, six weeks prior to the renewal date.

▶ **Reply** via Fax +49 341 48474-290 to OEMUS MEDIA AG or via E-mail to grasse@oemus-media.de

Last Name, First Name

Company

Street

ZIP/City/County

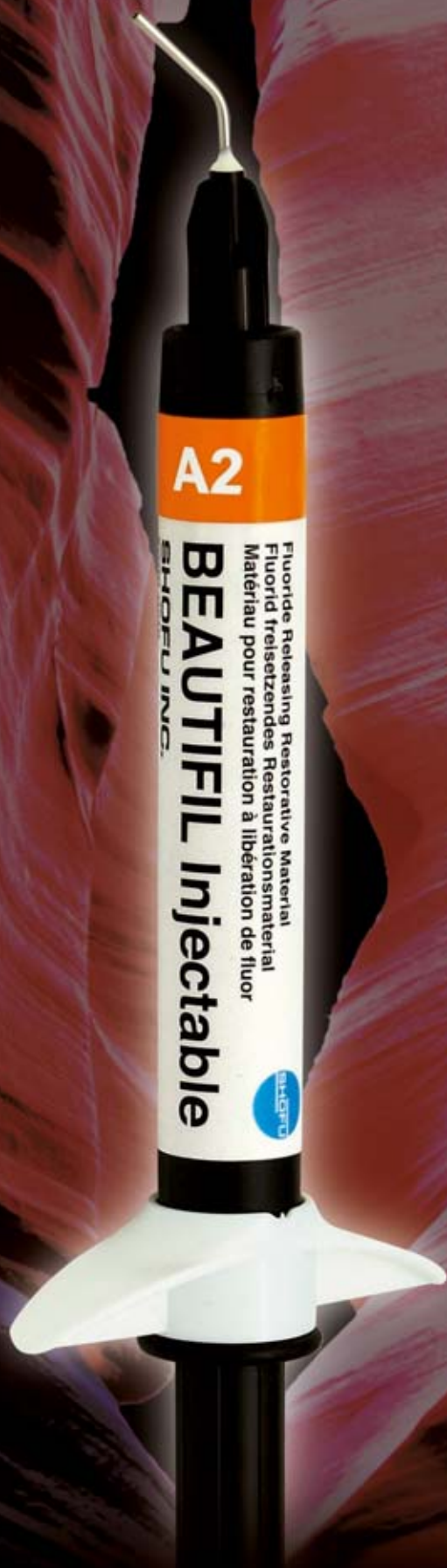E-mail

Signature

Notice of revocation: I am able to revoke the subscription within 14 days after my order by sending a written cancellation to OEMUS MEDIA AG, Holbeinstr. 29, 04229 Leipzig, Germany.

Signature

In a LEAGUE of its own ...



Inject Beauty & Strength as you directly stack and shape Beautifil Injectable into life-like aesthetic restorations that exhibit superior endurance to occlusal load, sustained fluoride protection and unique anti-plaque effect.

SHOFU INC. SINGAPORE BRANCH
Tel (65) 6377 2722 Fax (65) 6377 1121
mailbx@shofu.com.sg website www.shofu.com.sg



Official Partner



Minimally Invasive
Cosmetic Dentistry