

Endodontic management of a hypertaurodontic maxillary first molar—

A case report with a two-year follow-up

Authors_ Drs Jojo Kottoor, Denzil Valerian Albuquerque, Anuj Bhardwaj, Sonal Dham & Natanasabapathy Velmurugan, India

_Introduction

Taurodontism is a morphological variation in which the body of the tooth is enlarged and the roots are reduced in size. Taurodontic teeth have large pulp chambers and apically positioned furcation.¹ This variation was first described by Gorjanović-Kramberger;² however, the term "taurodontism" was first introduced by Sir Arthur Keith³ to describe molar teeth resembling those of ungulates, particularly bulls. The term "taurodontism" comes from the Latin term "*tauros*", which means "bull" and the Greek term "*odus*", which means "tooth" or "bull tooth".⁴ Such morphological variations are an endodontic challenge and even more difficult to treat when additional roots and/or canals are present. The endodontic management of one such taurodontic molar is reported in this case report.

_Case report

A 44-year-old male patient was referred to our clinic for treatment of the right maxillary first molar

(tooth #16). The preoperative periapical radiograph (Fig. 1a) suggested the following possibilities:

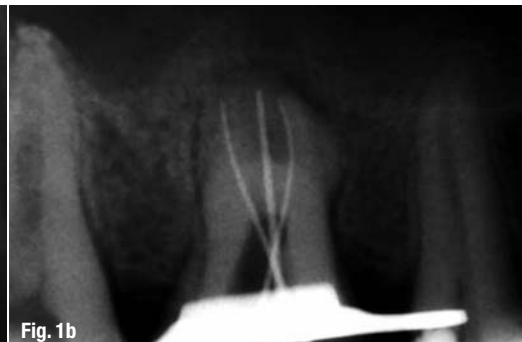- _ a mesio-occlusal carious lesion with endodontic involvement;
- _ a highly calcified and elongated pulp chamber extending up to the trifurcation;
- _ three short roots with the trifurcation in the apical third; or
- _ a periapical radiolucency in relation to the mesio-buccal and palatal root apex.

Clinically, vitality tests were negative and a diagnosis of hypertaurodontism, according to Shifman and Chanannel,⁵ with pulpal necrosis was made for tooth #16 and endodontic treatment was planned.

Local anaesthesia of 2% lidocaine with 1:100,000 epinephrine was administered to the patient. The mesial surface of the tooth was restored with composite resin (Z100, 3M ESPE) after caries excavation to enable optimal isolation. Under rubber dam isola-

Fig. 1a _Diagnostic radiograph of tooth #16 demonstrating hypertaurodontism and coronal pulp chamber obliteration.

Fig. 1b _Initial working length radiograph with three canals located.

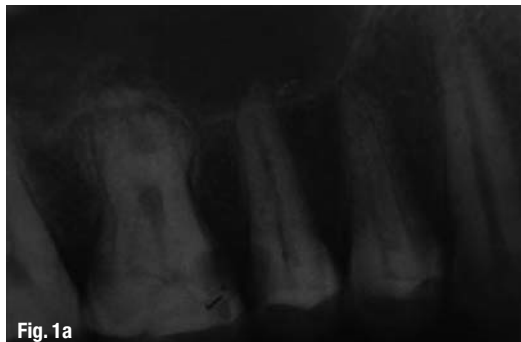

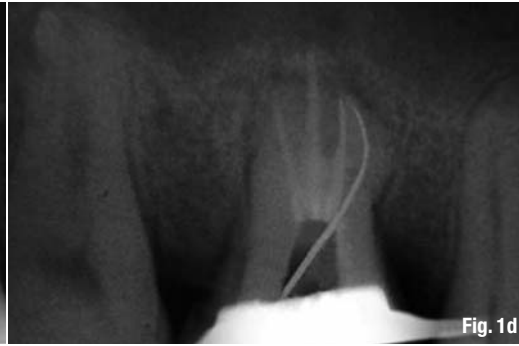
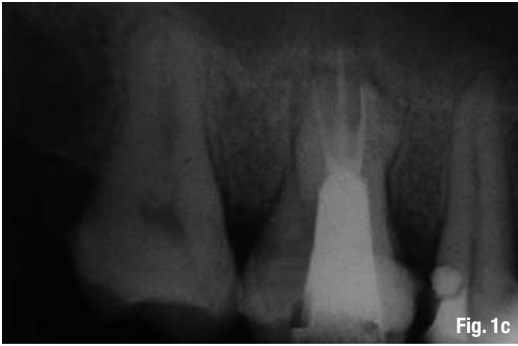

Fig. 1c_ Post-op radiograph with a coronal filling.

Fig. 1d_ Working length radiograph after re-entry into the tooth, showing the additional mesiobuccal canal.

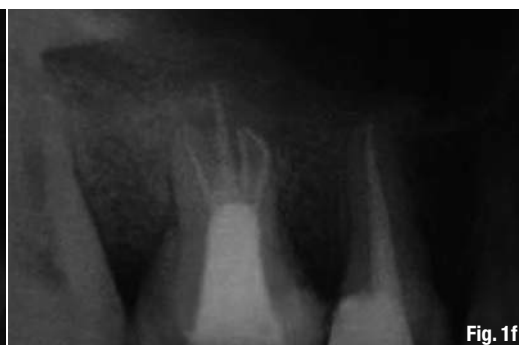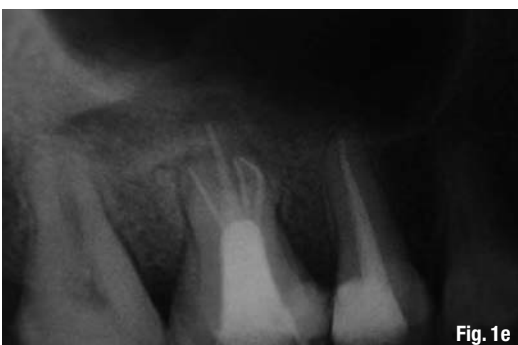tion, the access cavity was established with an Endo Access bur and an Endo Z bur (DENTSPLY Tulsa). A dental operating microscope (DOM; Seiler Revelation) was used throughout the procedure to facilitate visualisation. The calcified mass occluding the pulp chamber was removed using ET 18D ultrasonic tips (Satelec/Acteon). Three root-canal orifices were located: two narrow orifices, the mesiobuccal and distobuccal, and a wide palatal orifice. Root-canal orifices were named according to the nomenclature proposed by Kottoor et al.⁵ An electronic apex locator (Root ZX, Morita) was used to determine the initial working length, which was confirmed radiographically (Fig. 1b). The root canals were cleaned and shaped with ProTaper (DENTSPLY Maillefer) rotary instruments. The buccal canals were instrumented up to F2 and palatal canal to F4. The canals were irrigated with 2.5% sodium hypochlorite using ultrasonics, 17% aqueous solution of EDTA, and 0.2% w/v chlorhexidine gluconate. The canals were dried using sterile paper points and obturated with gutta-percha cones and AH Plus sealer (DENTSPLY DeTrey) using the cold lateral compaction and vertical compaction techniques. The access cavity was then restored with miracle mix (cermet and Ketac Silver, 3M ESPE; Fig. 1c).

The patient returned to the endodontic clinic after three weeks with sensitivity in the same tooth on consumption of cold foods. The longevity of the complaint prompted a re-entry into the tooth to evaluate the possibility of any additional canal/s. The coronal restoration was removed and the pulpal floor was carefully inspected again under the DOM at a higher magnification. The visual and tactile examination

under the DOM revealed a second mesiobuccal canal (P-MB). Under the microscope, it was possible to insert a #15 K-file and the existence of the additional canal was confirmed using an electronic apex locator. A working length radiograph was taken with a #20 K-file in the untreated canal (Fig. 1d). The P-MB canal was instrumented to F2 under irrigation with 3% sodium hypochlorite and EDTA and obturated by cold lateral compaction of the gutta-percha and AH Plus sealer (Fig. 1e). Follow-up clinical examination after a week revealed that the tooth was asymptomatic and was not sensitive to percussion or palpation. Subsequently, endodontic management of tooth #15 was completed. The 24-month follow-up radiograph showed complete resolution of the periapical radiolucency in relation to the mesiobuccal and palatal root apices (Fig. 1f).

Discussion

Taurodontism is frequently associated with other anomalies and syndromes. These include Klinefelter syndrome,⁶ ectodermal alterations,⁷ Down syndrome,⁸ Mohr syndrome,⁹ Wolf-Hirschhorn syndrome,¹⁰ Lowe syndrome,¹¹ Tricho-dento-osseous syndrome,¹² Williams syndrome,¹³ and Seckel syndrome,¹⁴ but it is not a constant feature of these syndromes.¹⁵ However, identification of patients with multiple taurodontic teeth could lead to early recognition of a systemic disorder and improve quality of life. It has also been found to be associated with dental anomalies such as oligodontia, supernumerary teeth, and amelogenesis imperfecta.¹⁶ In this case, the patient was a healthy male with a negative medical history.



Figs. 1e & f_ Immediate post-op radiograph (e) and follow-up radiograph at 24 months, showing periapical healing (f).

Its aetiology is still unknown, but it has been suggested that it may be caused by a failure of the diaphragm of Hertwig's epithelial root sheath to invaginate at the correct time and horizontal level or changes in the mitotic activity of cells of the developing teeth that can affect root formation or influence by external factors on the development of the teeth.¹⁸ Differences in opinion exist regarding the amount of displacement and/or morphological change required to constitute taurodontism. Based on the relative amount of apical displacement of the pulp chamber floor, Shaw¹⁹ classified taurodontism as hypotaurodontism, mesotaurodontism, and hypertaurodontism. This subjective, arbitrary classification led normal teeth to be misdiagnosed as taurodontism. Feichtinger and Rossiwall²⁰ state that the distance from the bifurcation or trifurcation of the root to the cemento-enamel junction should be greater than the occluso-cervical distance for a taurodontic tooth. Keene²¹ proposed the Taurodont Index, relating the height of the pulp chamber to the length of the longest root. Although there are many classification systems to determine the severity of taurodontism,²² the classification proposed by Shifman and Chananel¹⁵ in 1978 is the most widely used system. According to this index, taurodontism is present if the distance from the lowest point at the occlusal end of the pulp chamber to the highest point at the apical end of the chamber, divided by

the distance from the occlusal end of the pulp chamber to the apex and multiplied by 100 is 20 or above (hypotaurodontism: TI 20–30; mesotaurodontism: TI 30–40; hypertaurodontism: TI 40–75).

Except for a higher prevalence of taurodontism among females in a Chinese sample,²³ no study has found a gender difference for this abnormality. Although permanent mandibular molars are most commonly affected,²³ taurodontism is occasionally observed in mandibular premolars and even in maxillary premolars, mandibular canines, and incisors.^{24–26} Its prevalence has been reported as ranging from 5.67 to 60% of subjects.^{27,28} In a recent study, it accounted for 18% of all anomalies.²⁹

Endodontic treatment in taurodontic teeth has been described as complex and challenging because the apical position of the pulpal floor can make it difficult to identify and locate root-canal orifices. In the present case, an apical third trifurcation with four root canals was observed. The mesiobuccal and distobuccal canal orifices were very narrow and close to each other, which made identification and negotiation of these orifices very difficult. Additionally, the proximity of the orifices and deeply situated opening of the canals made it difficult to identify the P-MB during the initial visit. However, during the second visit, the use of DOM enhanced the visualisation of the pulpal floor by better illumination of the depths of the cavity. Hence, success was largely dependent on the use of magnification, which allowed for the identification of the P-MB canal with ease. During instrumentation, the shortened length of these canals allowed for instrumentation with only the apical third of the file, also making it time consuming. Thus, endodontic treatment of taurodontic teeth may be complex, particularly regarding the cleaning and shaping of the root canals and root-canal obturation, especially in hypertaurodontic teeth.

_Conclusion

The case report has described the successful endodontic treatment of a hypertaurodontic maxillary first molar that would have seemed impossible to perform with conventional techniques. Success was mostly attributed to the use of magnification, which allowed better visualisation of the four canal orifices. This case report has served to illustrate to clinicians that sound knowledge and modern equipment facilitate enhanced management of endodontically challenging taurodontic teeth.

Editorial note: A complete list of references is available from the publisher.

_about the authors

roots



Dr Jojo Kottoor

He is the first author worldwide to have reported seven and eight root canals in a maxillary molar. His work consequently made the cover page of the *Journal of Endodontics*. He has a special interest in root-canal anatomy and is currently an Associate Professor in conservative dentistry and endodontics at Mar Baselios Dental College in Kochi, India.



Dr Denzil Valerian Albuquerque

is an Associate Professor at Terna Dental College and Hospital in Navi Mumbai, India.



Dr Anuj Bhardwaj

is an Endodontist at Bhardwaj Dental Clinic in Indore, India.



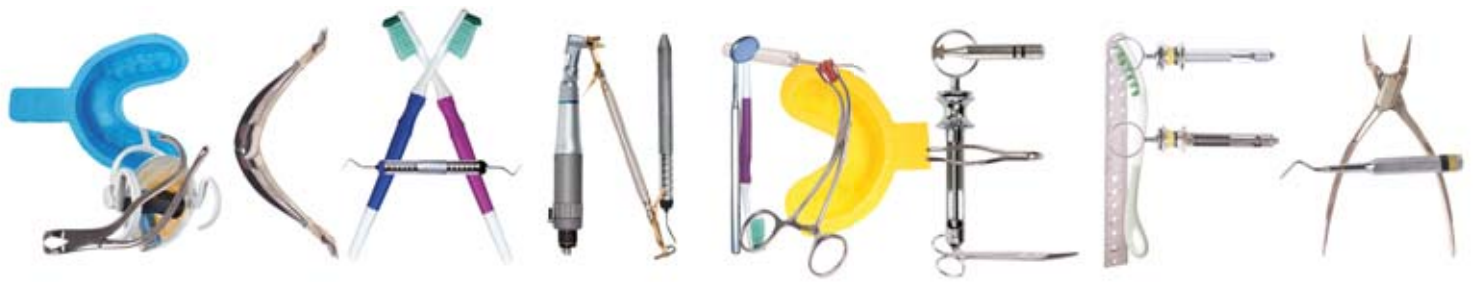Dr Sonal Dham

is an Associate Professor at Guru Teg Bahadur Hospital in New Delhi, India.



Dr Natanasabapathy Velmurugan

is a Professor and Head at Meenakshi Ammal Dental College in Chennai, India.



APRIL 11- 13, 2013 • BELLA CENTER • COPENHAGEN • DENMARK

**Welcome to the 46th Scandinavian Dental Fair
The leading annual dental fair in Scandinavia**

SCANDEFA 2013



The 46th SCANDEFA invites you to exquisitely meet the Scandinavian dental market and sales partners from all over the world in springtime in wonderful Copenhagen

SCANDEFA 2013

Is organized by Bella Center and is being held in conjunction with the Annual Scientific Meeting, organized by the Danish Dental Association (www.tandlaegeforeningen.dk).

183 exhibitors and 10.562 visitors participated at SCANDEFA 2012 at approx. 14,000 m² of exhibition space.

Exhibit at Scandefa

Book online at www.scandefa.dk
Account Manager Tommy Louens
tlo@bellacenter.dk, T +45 32 47 21 33

Travel information

Bella Center is located just a 10 minute taxi drive from Copenhagen Airport. A regional train runs from the airport to Orestad Station, only 15 minutes drive.

Check in at Bella Center's newly built hotel

Bella Sky Comwell is Scandinavia's largest design hotel. The hotel is an integral part of Bella Center and has direct access to Scandefa. Book your stay on www.bellasky.dk