

From orthopaedics to dental implantology

Author_Dr Suheil M. Boutros, USA

Introduction

Trabecular Metal (Zimmer Dental), a porous (80%) tantalum biomaterial with a trabecular structure for 3-D bone in-growth, has been used for over a decade in orthopaedic surgery.¹ As a result of great success in orthopaedics, a new tapered, threaded titanium dental implant with a Trabecular Metal midsection was developed and tested in animal models, followed by human trials. The current findings suggest that Trabecular Metal implants with both on-growth and in-growth (due to active bone formation in the Trabecular Metal pores) provide good bone anchorage during early healing when placed in extraction sockets. The preliminary pilot study demonstrated that immediate loading of Trabecular Metal implants with non-occluding provisional restorations within 48 hours and definitive loading of the implants with fully occluding restorations seven to 14 days later in selected patients was safe and effective over the six-month follow-up period.²

Porous tantalum material has the ability to facilitate osseointegration and provide a substrate for cell adhesion that makes it desirable for use in orthopaedic surgery.¹ In a dog study, Trabecular Metal implants were compared with standard titanium implants (control). Osseointegration of control implants was achieved via on-growth, whereas the Trabecular Metal implants achieved osseointegration via both on-growth around the threaded sections and in-growth through the pores of the Trabecular

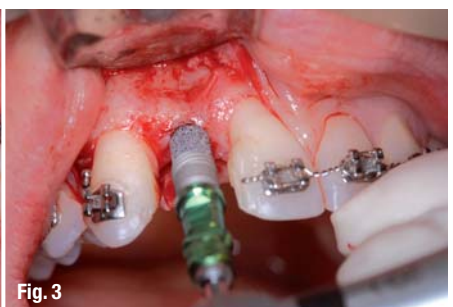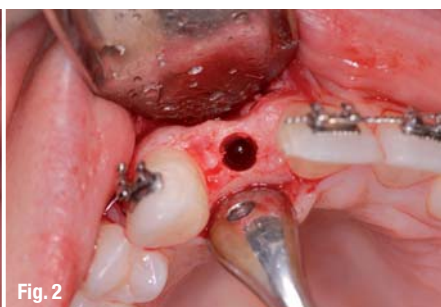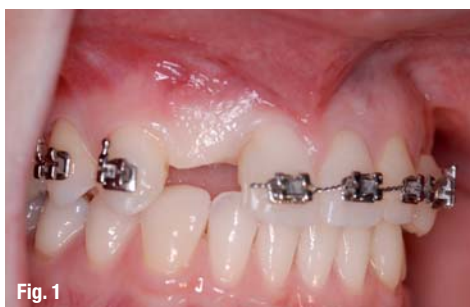Metal shell. The ISQ values for the Trabecular Metal implants illustrated an increasing trend over a 12-week healing period, whereas the ISQ values for the control implants did not demonstrate any such trend—although the values were greater than 60. The histopathological findings indicated no evidence of acute inflammation for any Trabecular Metal or control implant.²⁻³

In a proof of principle study, two investigational sites with up to 20 subjects for each site, with up to two implants per subject (total of 36 implants), were examined. Implant sizes were 4.7 and 6 mm in diameter and 10, 11.5 and 13 mm in length, with posterior indication only. Healthy, sufficient bone volume and primary stability (>35 Ncm) were the inclusion criteria. The prosthetic treatment followed the One Abutment—One Time restoration protocol (Zimmer Dental), with immediate provisionalisation within 48 hours and the final restoration at or before two weeks post-implant placement. The six-month follow-up with a survival rate of 97.2% was comparable to the 97.9% survival rate of immediately loaded molar implants reported in a systematic review and meta-analysis of seven studies with 188 implants by Atieh et al. (2010). Within the limitation of the preliminary pilot study, immediate loading of the Trabecular Metal implants with non-occluding provisional restorations within 48 hours and definitive loading of the implants with fully occluding restorations seven to 14 days later in selected patients was safe and effective over the six-month follow-up period.

Fig. 1 Pre-op view of missing upper right lateral incisor.

Fig. 2 Osteotomy.

Fig. 3 Engaging the Trabecular Metal portion of the implant allows for early bone in-growth.



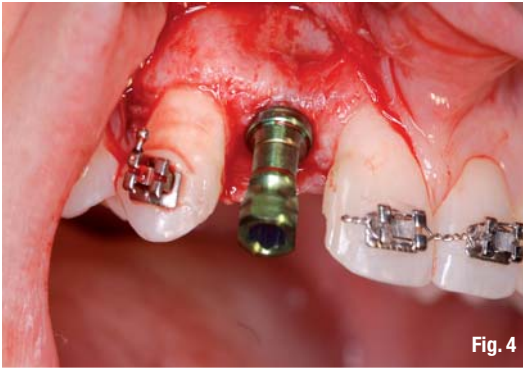

Fig. 4

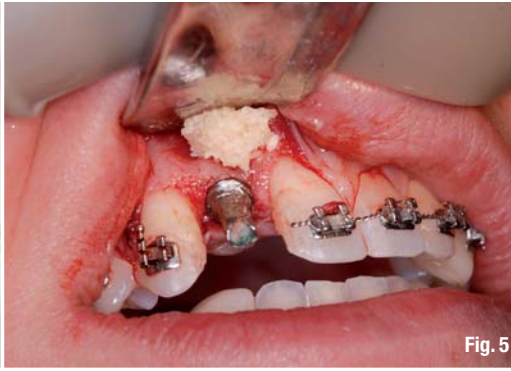

Fig. 5

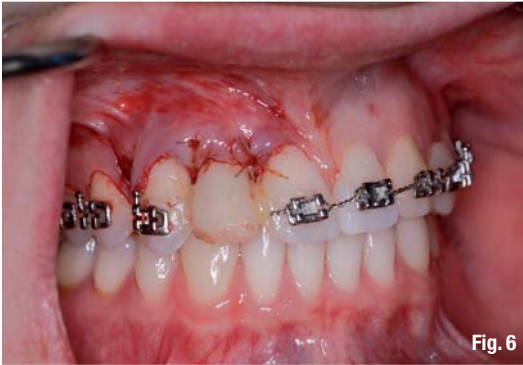

Fig. 6

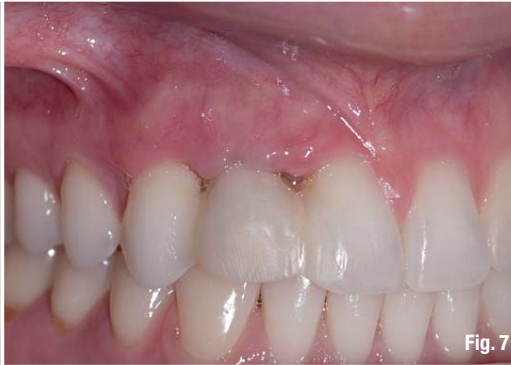

Fig. 7

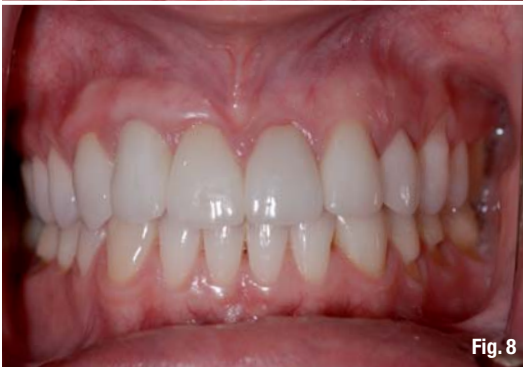

Fig. 8

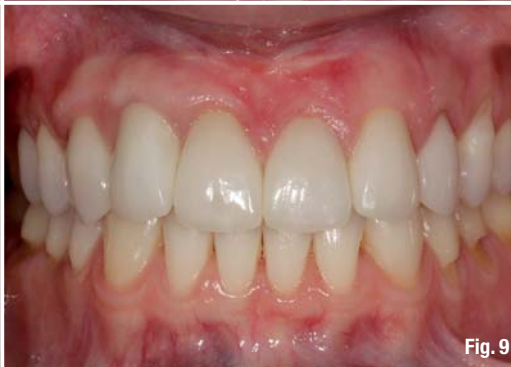

Fig. 9

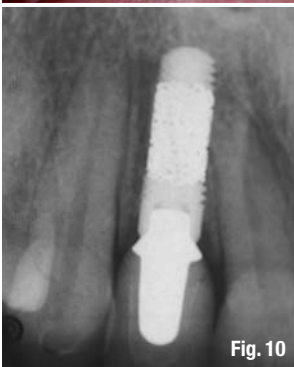

Fig. 10

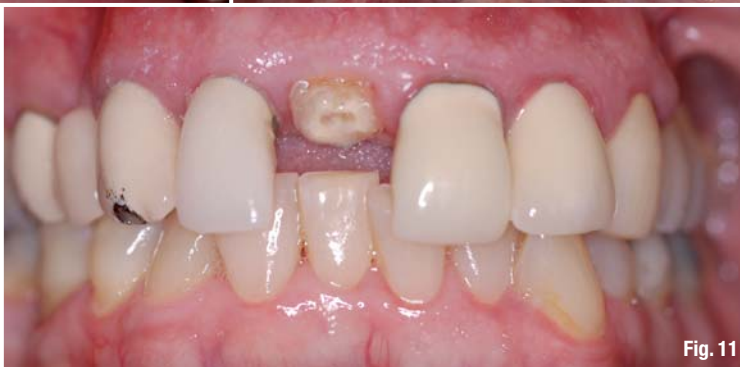

Fig. 11

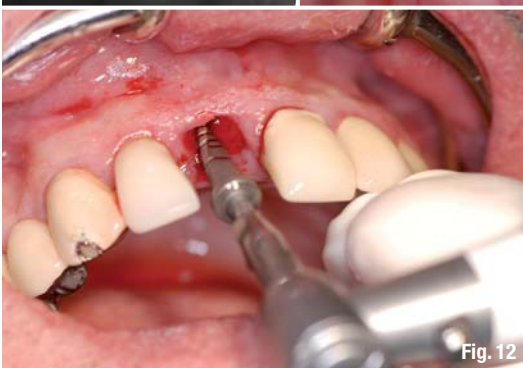

Fig. 12



Fig. 13

Fig. 4_ The coronal microgrooves engage the cortical bone and allow for better primary stability.
Fig. 5_ Prepared transfer coping in place with the Puros Cortico-Cancellous Particulate Allograft.
Fig. 6_ Non-occluding provisional restoration with the flap suture using chromic gut suture.
Fig. 7_ Ten days post-implant placement.
Fig. 8_ Final crown three months post-implant placement.
Fig. 9_ Final crown six months post-implant placement.
Fig. 10_ Radiograph six months post-loading.
Fig. 11_ Fractured, non-restorable central incisor.
Fig. 12_ The final 2.8/3.4 x 13 mm drill.
Fig. 13_ A Trabecular Metal implant of 4.1 x 13 mm.

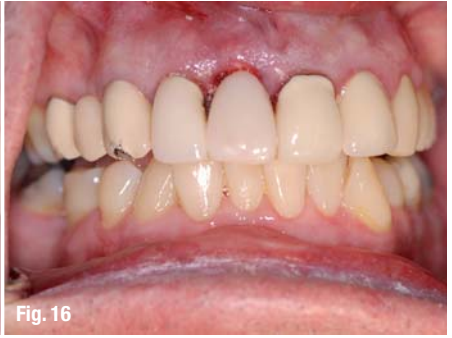
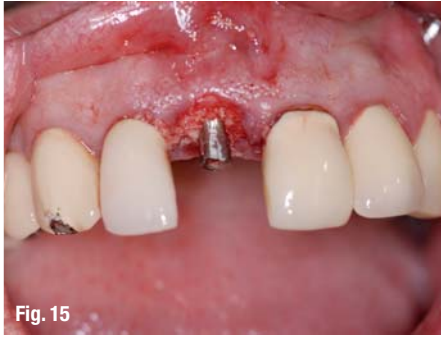
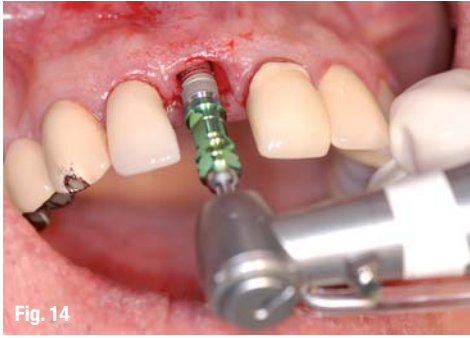Fig. 14 A Trabecular Metal implant placed in the extraction socket.

Fig. 15 Prepared transfer coping with Puros Cortico-Cancellous Particulate Allograft filling the critical gap.

Fig. 16 Non-occluding provisional restoration at the time of implant placement.

Case presentation: Patient 1

A 30-year-old female patient without medical contra-indication for implant therapy presented with a congenitally missing maxillary right lateral incisor. The clinical and radiographic examination demonstrated that the patient was a good candidate for Trabecular Metal implant placement and restoration (Fig. 1). The patient was given the option of implant placement and immediate non-occlusal loading as an alternative to a staged approach if the implant did not achieve good primary stability.

Surgical treatment

At the surgical appointment, following administration of local anaesthesia, a full thickness flap was reflected. The osteotomy was performed using a pointed starter drill, followed by a 2.3 mm twist drill. It was determined that the bone density was D2-3. Using a soft-bone drilling protocol,⁶⁻⁷ the next drill was used. No bone tap drills were used in order to ensure implant stability (Fig. 2). The fixture transfer coping was prepared to support a non-functional provisional crown. The deficient alveolar ridge was augmented using an allograft (Puros Cortico-Cancellous Particulate Allograft, Zimmer Dental—a mix of 70% cortical bone and 30% cancellous bone; Figs. 5 & 6). After implant placement, the patient was given post-surgical instructions, including the use of 0.12% chlorhexidine gluconate (Peridex, Procter & Gamble) three times a day and was prescribed 500 mg of amoxicillin (every six hours for seven days). The patient was seen for a follow-up visit ten days later and healing was uneventful (Fig. 7).

Prosthetic treatment

After allowing the soft tissue to mature for four weeks, the final fixture-level impression was taken and a final cast custom abutment was used to support a porcelain-fused-to-metal crown (Fig. 8).

Follow-up and maintenance

After six months, the patient returned for a follow-up visit. The clinical and radiographic exam demonstrated that the implantation had been a great success (Figs. 9 & 10). The patient was placed on a six-month recall to maintain the implant and the restoration properly.

Case presentation: Patient 2

A 65-year-old male patient without medical contra-indication for implant therapy presented with a fractured maxillary right central incisor. The clinical and radiographic examination demonstrated that the patient was a good candidate for the extraction of the tooth and immediate implant placement (Fig. 11). The patient was given the option of immediate implant placement and immediate non-occlusal loading as an alternative to a staged approach if the implant did not achieve primary stability at > 35 Ncm insertion torque.

Surgical treatment

At the surgical appointment, following administration of local anaesthesia, a flapless, atraumatic extraction of the maxillary right central incisor was performed using periostomes. The osteotomy was performed using a pointed starter drill, followed by a 2.3 mm twist drill. It was determined that the bone quality was D2-3. Using a soft-bone drilling protocol, the next drill used was 2.8, 2.8/3.4 x 13 mm. No bone tap drills were used in order to ensure implant stability (Fig. 12). A Trabecular Metal implant of 4.1 mm in diameter and 13 mm in length was inserted. The insertion torque exceeded 35 Ncm (Figs. 13 & 14). The fixture transfer coping was prepared to support a non-functional provisional crown. The critical gap between the extraction socket and the implant was grafted using an allograft (Puros Cortico-Cancellous Particulate Allograft; Figs. 15 & 16).

Prosthetic treatment

After allowing the soft tissue to mature for four weeks, the final fixture-level impression was taken and a final cast custom abutment was used to support a porcelain-fused-to-metal crown (Fig. 17).

Follow-up and maintenance

After six months, the patient returned for a follow-up visit. The clinical and radiographic exam demonstrated that the implantation had been a great success (Figs. 18 & 19). The patient was placed on a six-month recall to maintain the implant and the restoration properly.

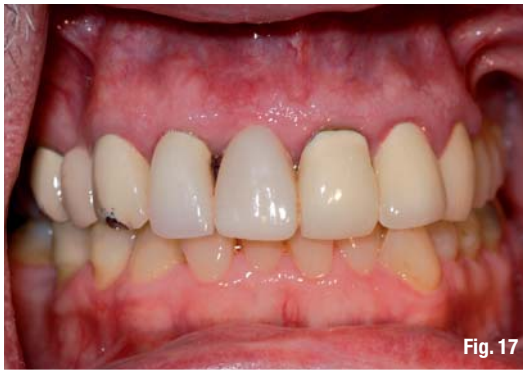

Fig. 17

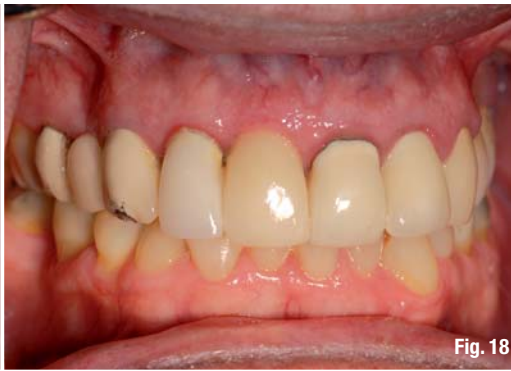

Fig. 18

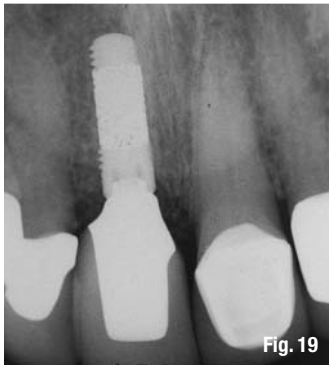

Fig. 19

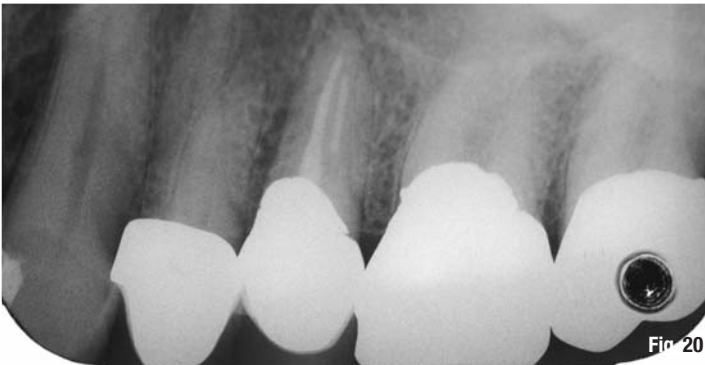


Fig. 20

Fig. 17_Four weeks post-implant placement.

Fig. 18_Final restoration six months post-implant placement.

Fig. 19_Final radiograph six months post-implant placement.

Fig. 20_Pre-op radiograph of the fractured second premolar.

Fig. 21_Atraumatic extraction.

Fig. 22_A Trabecular Metal implant of 4.1 x 13 mm.

Fig. 23_A Trabecular Metal implant placed in the extraction socket.

Fig. 24_Puros Cortico-Cancellous Particulate Allograft.

Fig. 25_A screw-retained provisional crown at the time of implant placement.

Fig. 26_Two weeks post-implant placement with the provisional crown in place.

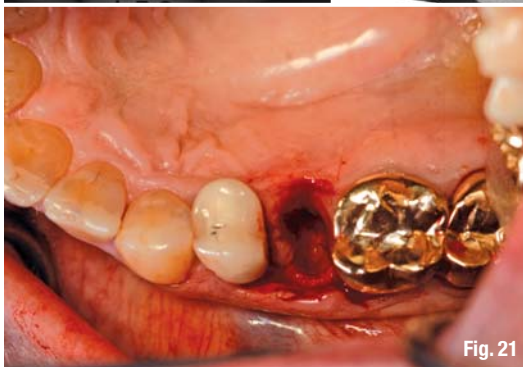

Fig. 21

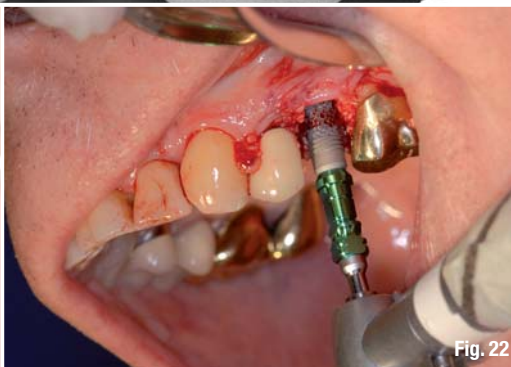

Fig. 22

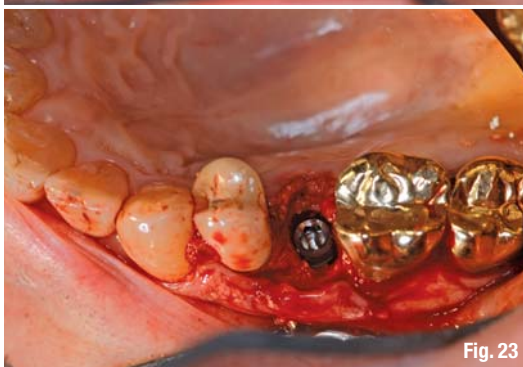

Fig. 23

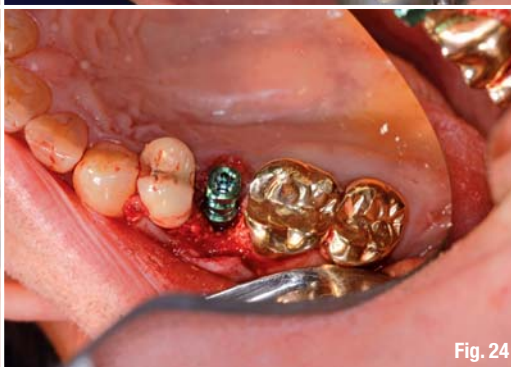

Fig. 24

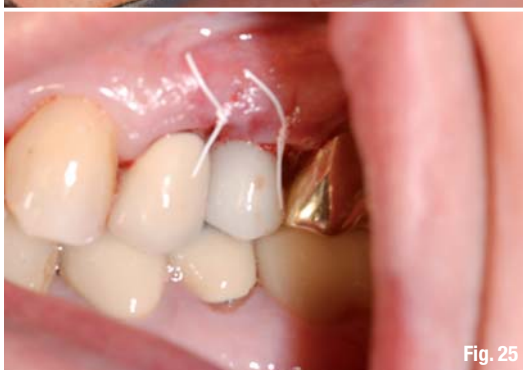

Fig. 25

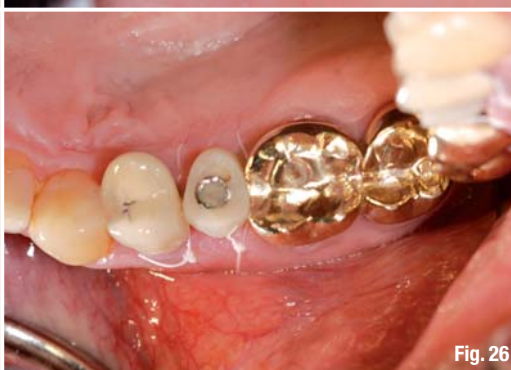
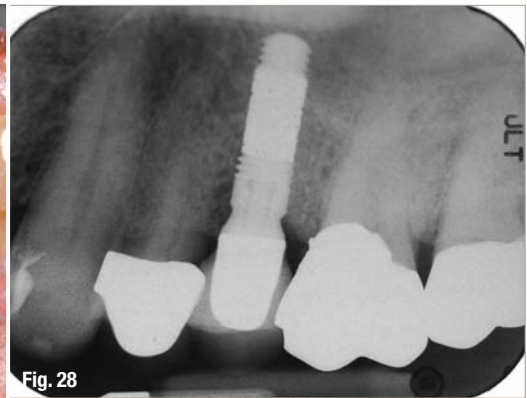
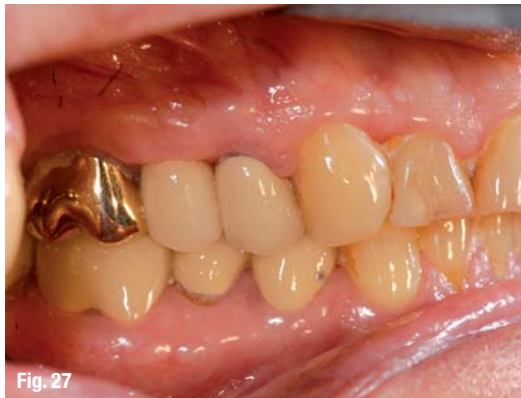Fig. 26

Fig. 27 The final restoration six months post-implant placement.
Fig. 28 The radiograph six months post-implant placement shows the stable bone level around the apical and coronal aspects.



Case presentation: Patient 3

A 70-year-old male patient without medical contra-indication for implant therapy presented with a fractured maxillary left second premolar. The clinical and radiographic examination demonstrated that the patient was a good candidate for the extraction of the tooth and immediate implant placement (Fig. 20). The patient was given the option of immediate implant placement and immediate non-occlusal loading as an alternative to a staged approach if the implant did not achieve primary stability at > 35 Ncm insertion torque.

Surgical treatment

At the surgical appointment, following administration of local anaesthesia, a flapless, atraumatic extraction of the maxillary left second premolar was performed using periostomes (Fig. 21). The osteotomy was performed using a pointed starter drill, followed by a 2.3 mm twist drill. Due to maxillary sinus proximity, a sinus crestal approach (Sinus Crestal Approach Kit, Zimmer Dental) was followed first to gain more space apically for the placement of a longer implant. It was determined that the bone quality was D2–3. Using a soft-bone drilling protocol, the next drill used was 2.8, 2.8/3.4 x 13 mm. No bone tap drills were used in order to ensure implant stability. A Trabecular Metal implant of 4.1 mm in diameter and 13 mm in length was inserted. The insertion torque exceeded 35 N cm (Figs. 22 & 23). The critical gap between the extraction socket and the implant was grafted using allograft (Puros Cortico–Cancellous Particulate Allograft; Fig. 24). The fixture transfer coping was prepared to support a non-functional screw-retained provisional crown (Fig. 25). The patient was given post-surgical instructions, including the use of 0.12% chlorhexidine gluconate (Peridex) three times a day and was prescribed 500 mg of amoxicillin (every six hours for seven days). The patient was seen for a follow-up visit 14 days later and healing was uneventful (Fig. 26).

Prosthetic treatment

After allowing the soft tissue to mature for four weeks, the final fixture-level impression was taken and

a final cast custom abutment was used to support a porcelain-fused-to-metal crown (Fig. 27).

Follow-up and maintenance

After six months, the patient returned for a follow-up visit. The clinical and radiographic exam showed that the implantation had been a great success (Fig. 28). The patient was placed on a six-month recall to maintain the implant and the restoration properly.

Clinical relevance

With higher demand by patients for immediate implant placement and immediate loading, the use of tapered implants that provide a high degree of primary stability and the addition of the Trabecular Metal technology provides faster secondary stability through bone in-growth, and can help achieve quick and predictable final restorations.

Conclusion

Forty Trabecular Metal TMT, TMM implants were placed. During surgery, an insertion torque of > 35 Ncm was used in 90% of the implants, and 85% were placed at the crest of bone. Fifteen implants received provisional restoration at the time of placement. Fully functional occluding final restorations were seated as early as two weeks in 18 implants and as long as twelve weeks in the remaining twelve implants. After six months, 30 Trabecular Metal implants had been successfully restored with no signs of implant failure.

contact

implants

Dr Suheil M. Boutros

Periodontal Specialists of Grand Blanc
 Suite 19, 8185 Holly Rd.
 Grand Blanc
 MI 48439, USA

www.PeriodonticsOnline.com

Editorial note: A list of references is available from the publisher.



Tribune CME

6 Months Clinical Masters Program in Implant Dentistry

May 2013 to November 2013, a total of **12 days** in Heidelberg (DE), Como (IT), Maspalomas (ES)

Program director Dr. Marius Steigmann



Live surgery and **hands-on** with the masters in their own institutes plus online mentoring and on-demand learning at your own pace and location.



Dr. Tiziano Testori



Dr. Hom-Lay Wang



Dr. Scott D. Ganz



Dr. Jose Navarro



Dr. Phillippe Russe



Dr. Stavros Pelekanos



Dr. Marius Steigmann

Session 1

Heidelberg, Germany - May 2-5

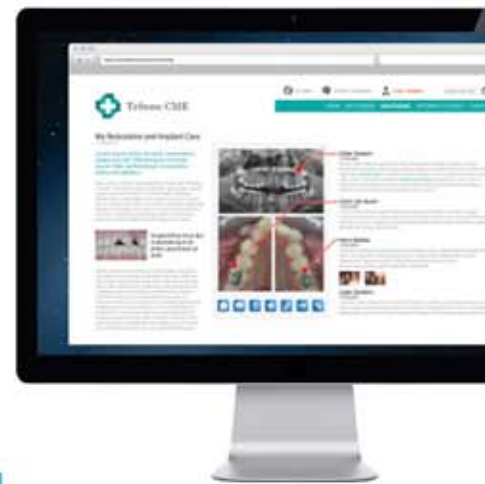Session 2

Como, Italy - July 4-7

Session 3

Maspalomas, Canary Islands - November 6-10

During each module, the participants will have the opportunity to practice their new skills on hands-on casts, porcine models, and to watch or assist live surgeries.



Course fee: € 11,900

Register by the end of 2012 and you will receive a complimentary iPad preloaded with premium dental courses.

Tel.: +49-341-48474-302

email: info@tribunecme.com

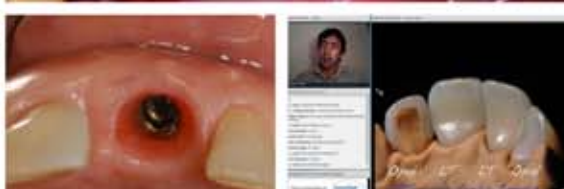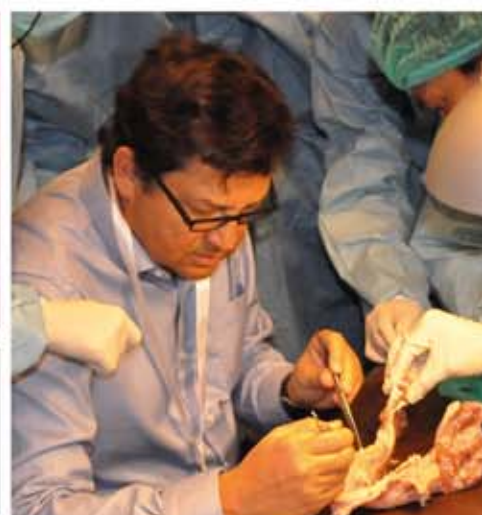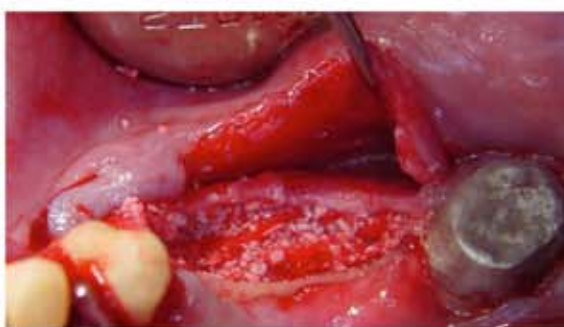www.TribuneCME.com

+ Access our online learning platform: hours of premium video training and live webinars. Collaborate with peers and faculty on **your cases**.

ADA CERP® | Continuing Education Recognition Program

Tribune America LLC is the ADA CERP provider. ADA CERP is a service of the American Dental Association to assist dental professionals in identifying quality providers of continuing dental education. ADA CERP does not approve or endorse individual courses or instructors, nor does it imply acceptance of credit hours by boards of dentistry.

Discover the Masters' secrets and enjoy three superb locations.



100
C.E. CREDITS
ADA CERP® | Continuing Education Recognition Program

