

Structure and volume in delayed immediate implantation

Authors_Dr Georg Bach & Christian Müller, Germany

Introduction

Delayed immediate implantation is a viable alternative to immediate implantation, for which there is no distinct evaluation in the literature, and a "regular" implantation after complete osseous healing of the former extraction area, generally associated with volume loss.

Loss of osseous volume after extraction of a non-conservable tooth may be a limiting factor for later implantation. To avoid this problem, many authors recommend immediate implantation, where an implant is inserted immediately after careful and gentle tooth extraction. In cases where immediate implantation is not wanted or possible, delayed immediate implantation after reconstruction of the former tooth area, which is generally carried out three to four weeks after extraction of the non-conservable tooth, is a viable alternative. If the alveolus is (still) mostly intact after extraction, the precondition for immediate implantation can be optimised with a collagen membrane and cone unit.

The procedure presented in the form of the following three exemplary patient cases also acknowledges this easy surgical procedure.

The focus of interest is on procedures for preserving osseous volume after extraction—many authors emphasise the value of closing the wound by means of a "punch", which they claim to have considerable advantages with regard to protection against resorption. Undisturbed growth of bone-forming cells in the former tooth socket is promoted by preventing the connective tissue from growing into the alveolus. However, this procedure presents more of a challenge for the surgical skills of the dental surgeon in terms of production and insertion, and it is more demanding for the patient, both surgically and financially.

The insertion of so-called collagen membrane and cone units can simplify closure of the alveolus considerably and avoid removal of the punch at a later time. A second procedure is not required because of the absorbability of the material, since the collagen membrane cone unit does not have to be removed.

Procedure

The manufacturer recommends the following procedure for the insertion of collagen membrane and cone unit:

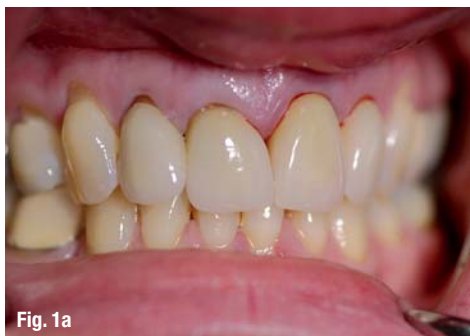

Fig. 1a

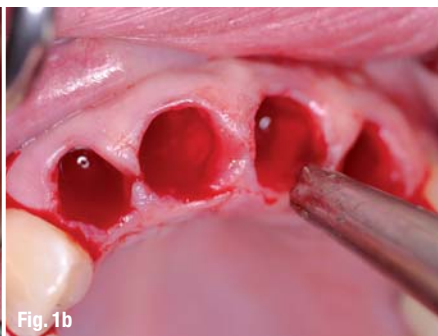


Fig. 1b

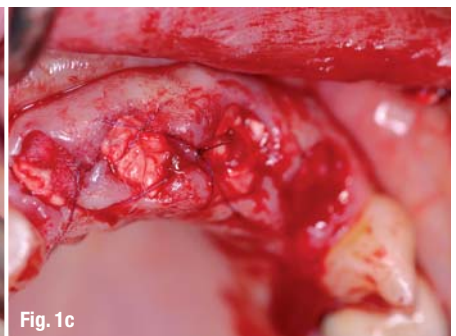
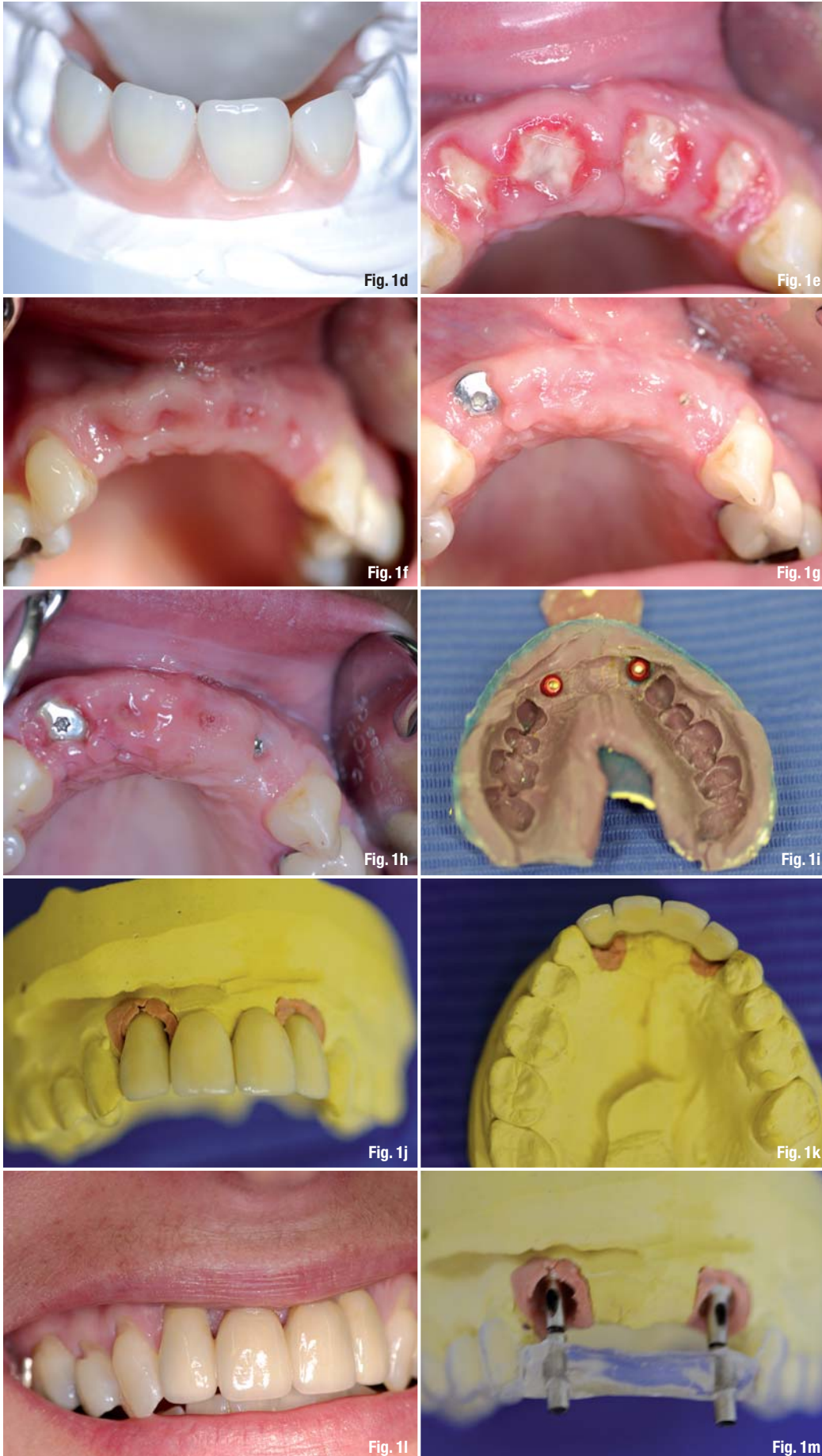


Fig. 1c



Case 1

Due to an extensive dental history, none of the anterior teeth of the maxilla were conservable (Fig. 1a) and had to be removed gently (Fig. 1b). Immediately following extraction of the teeth, collagen and membrane cones were inserted (Fig. 1c) for the purpose of socket preservation and integration of the previously produced (Fig. 1d) interim prosthesis. Figures 1e and 1f show the clinical situation one and four weeks after surgery; Figure 1g shows the situation after delayed immediate implantation. The intraosseous suture material was removed seven days after implantation (Fig. 1h). After completion of the osseointegration phase, the casting was done (Fig. 1i), followed by insertion of the abutments using the prepared insertion aid (Figs. 1j–l). Figure 1m shows the exact conformity between planning (template) and achieved result (abutments).

Case 2

In the right half of the maxilla, the two remaining posterior teeth were fractured and deeply damaged by caries (Fig. 2a), thus non-conservable. The two alveoli remained largely intact (Fig. 2b) after gentle removal of the roots, and a customised collagen membrane and cone unit was inserted (Fig. 2c).

The suture material was removed one week after surgery (Fig. 2d).

After four weeks, the bone bed showed no irritation and a primary reconstruction to a large extent. We were able to insert two implants after this short waiting period. Figure 2e shows the condition after implant bed drilling; Figure 2f shows the two inserted implants. Please also see the corresponding dental panoramic X-ray (Fig. 2g).

Upon completion of the osseointegration period, the implants showed no irritation (Fig. 2h), so that the impression could be taken with a customised spoon (Fig. 2i) and the dental lab work (Figs. 2j and k) was executed. Figure 2l shows the inserted abutments, and figure 2m shows the integrated product in the patient's mouth. Figure 2n shows the corresponding sagittal view.

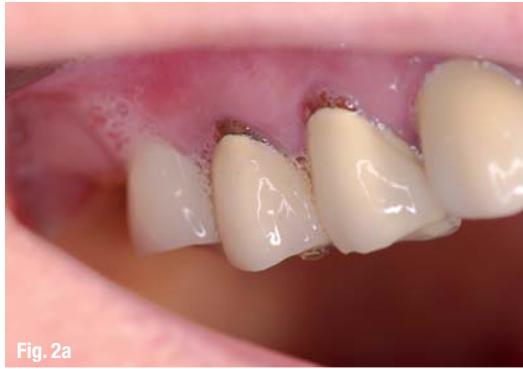

Fig. 2a

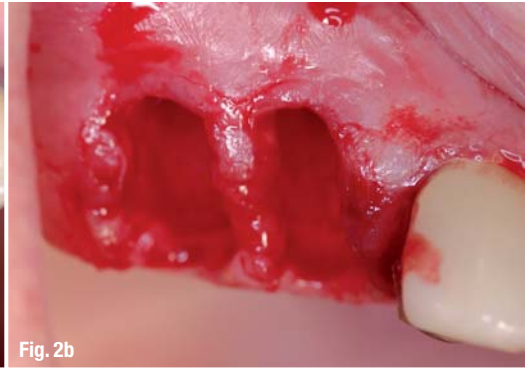

Fig. 2b

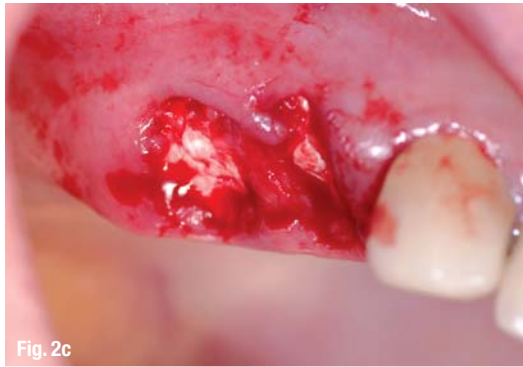

Fig. 2c

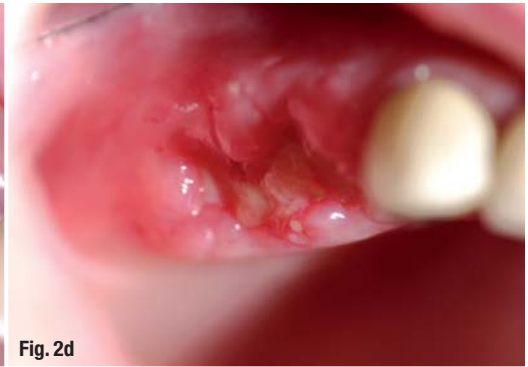

Fig. 2d

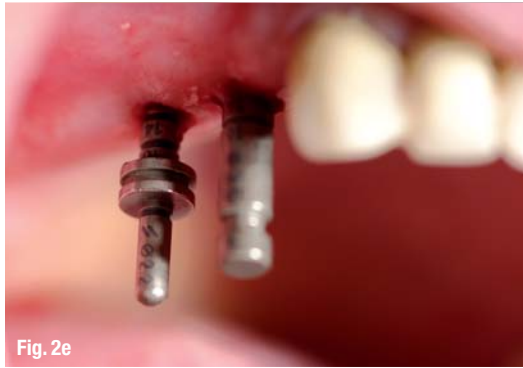

Fig. 2e

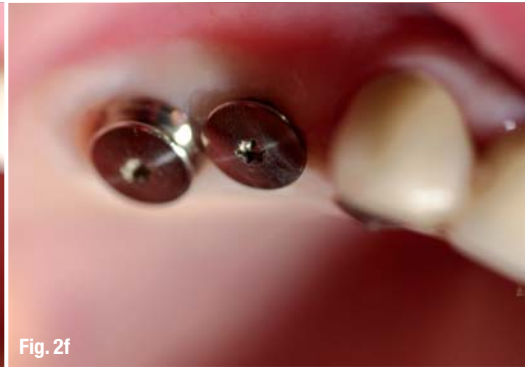

Fig. 2f

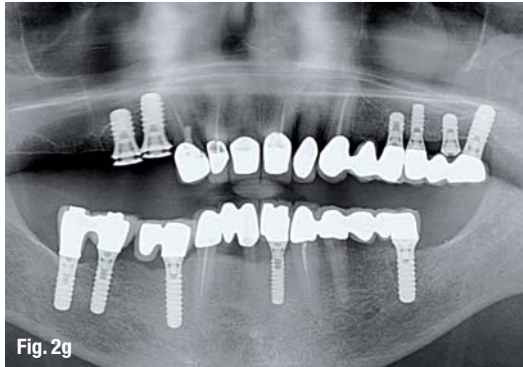


Fig. 2g

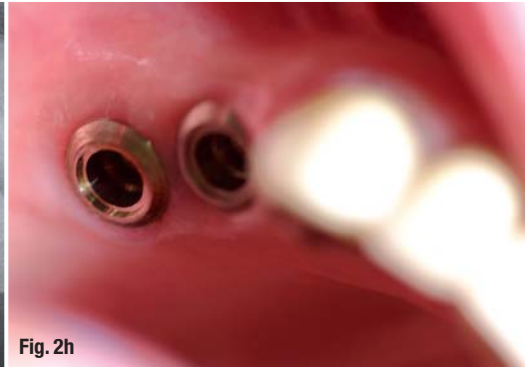


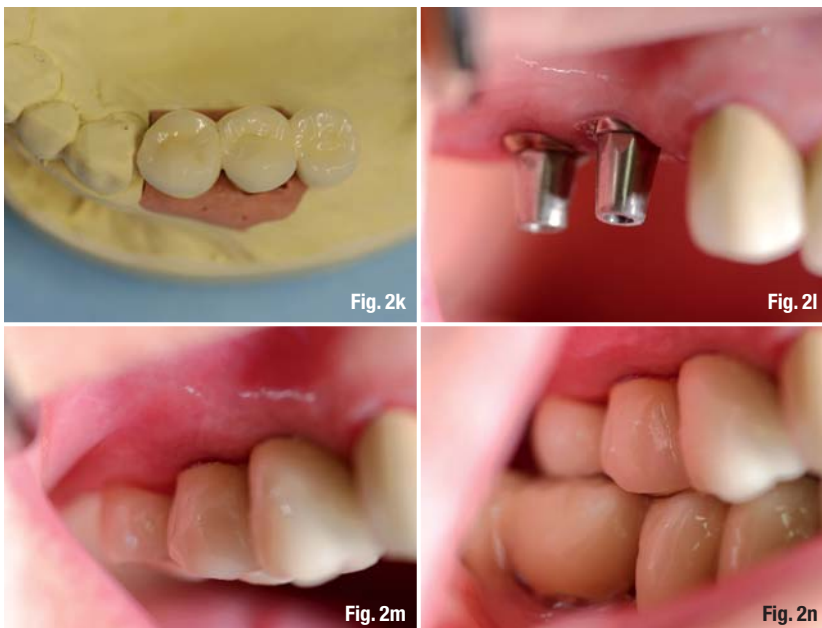
Fig. 2h

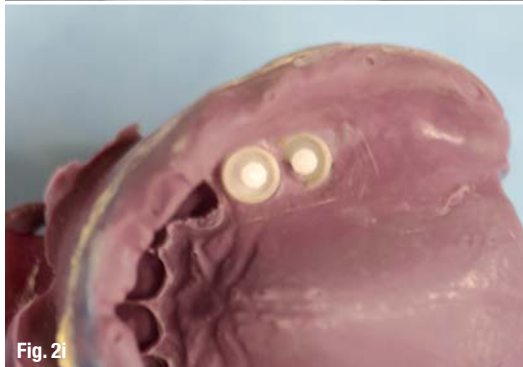

Fig. 2i

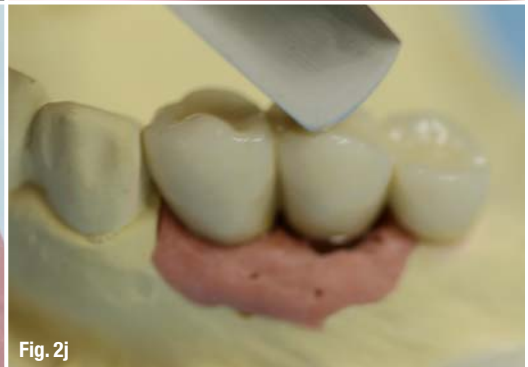

Fig. 2j



1. Preparation for a tight closure

After gentle and non-traumatic extraction of the non-conservable tooth, the marginal gingiva is minimally detached to the alveolar process so that the free membrane side of the collagen membrane and cone unit can be inserted.

2. Customising collagen membrane and cone unit

Moistening is to be avoided because this would make it more difficult to achieve a good fit to the alveolus. Rather, the collagen cone is fitted to the alveolus with the scalpel, and the membrane is configured with small scissors to facilitate insertion under the marginal edges, while at the same time achieving an ideal defect-congruent coverage. To achieve this, the dimensions of the membrane should be approximately 1–2 mm wider than the diameter of the alveolus.

3. Insertion of collagen membrane and cone unit

Using dry, anatomical, wide tweezers, the collagen membrane and cone units are inserted into the alveolus and then pushed in deep with a moist swab. The membrane part should be seated exactly at the level of the marginal gingiva. Now the free and slightly oversized part of the membrane is pushed carefully under the edges of the marginal gingiva.

4. Protective measures

A back-and-forth suture with a non-absorbable suture material will secure the position of the collagen membrane and cone unit in the alveolus and also adapt the free gingiva edges on the membrane.

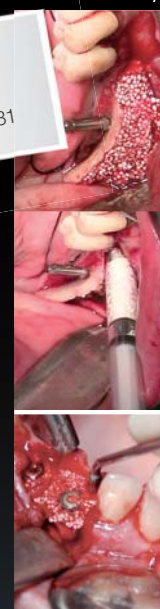Case presentations

The following three patient cases serve to illustrate and ultimately evaluate the procedure of a delayed immediate implantation using an absorbable collagen membrane and cone unit.

Case 1: Four non-conservable teeth in the anterior maxilla

Due to a trauma of the anterior teeth during adolescence, the patient received endodontic treatment and crowns on the four front teeth, which—after recurring problems—resulted in apicoectomies. The second set of crowns at ten years after the first prosthetic treatment was followed immediately by a second resection due to persistent discomfort. The patient is in her late thirties, and now the four front teeth 12,

Visit us!
Hall 11.3,
K030/L031



easy-graft®
CRYSTAL

Ingenious: Simple handling and accelerated osteoconduction for long-term volume preservation.

SUNSTAR
GUIDOR®

Degradable Solutions AG
Member of Sunstar Group
Wagistrasse 23
CH-8952 Schlieren/Zurich
www.easy-graft.com

AD
easy-graft®CRYSTAL

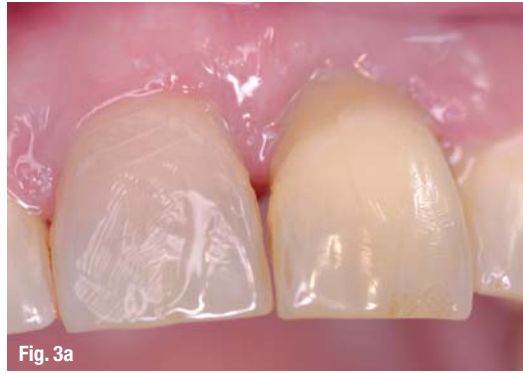

Fig. 3a

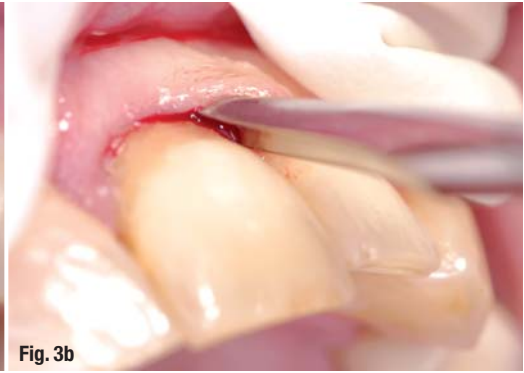

Fig. 3b

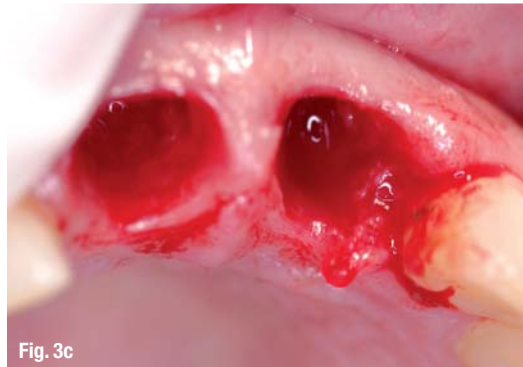

Fig. 3c

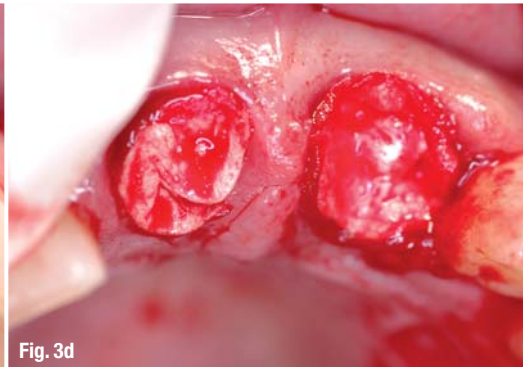


Fig. 3d

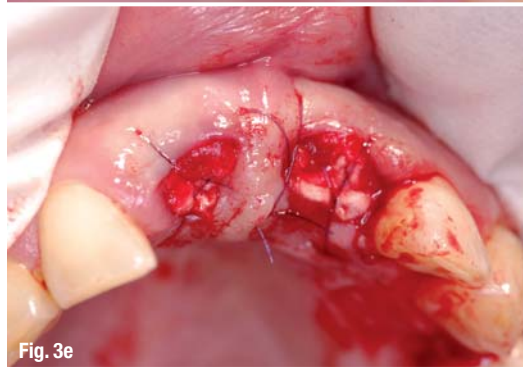


Fig. 3e

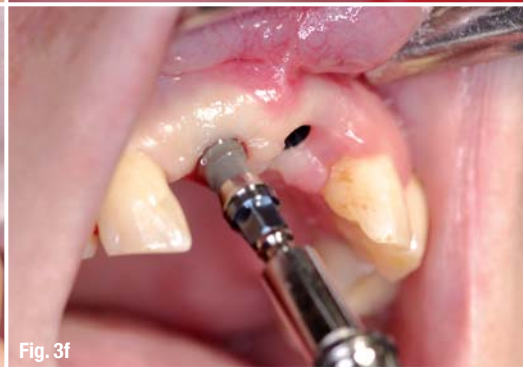

Fig. 3f

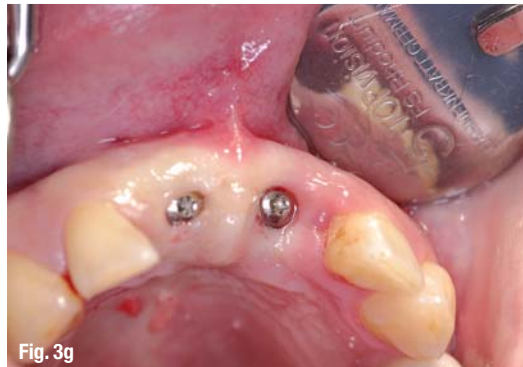

Fig. 3g

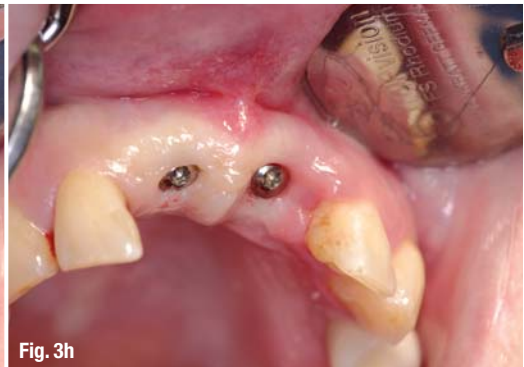

Fig. 3h

Case 3

The teeth were marked by a severe previous periodontitis, and the two upper central incisors were damaged so severely (Fig. 3a) that they were considered non-conservable.

After minimally invasive removal of the two upper central incisors (Fig. 3b), the alveoli of the incisors were found to be intact (Fig. 3c) so that, for the purpose of socket preservation, collagen cone and membrane units were inserted (Fig. 3d) and fixated (Fig. 3e).

Two implants (Fig. 3f) were inserted after primary healing of the soft tissue. Figure 3g shows the immediate postoperative status; Figure 3h shows the status after one week.

The two implants were fitted with crowns upon completion of further eight weeks of healing time.

Figure 3i shows the clinical findings after six months within the scope of a recall appointment.

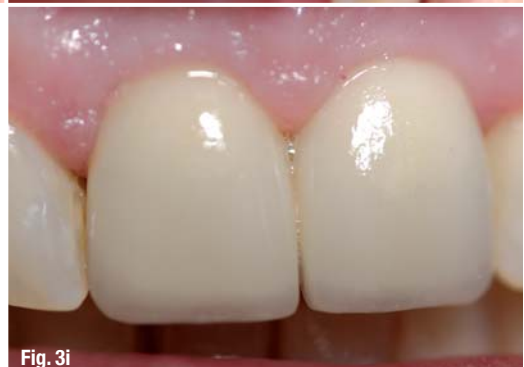

Fig. 3i

CONFIDENCE IN LIMITED SPACE


STRAUMANN® NARROW NECK CrossFit®

The Straumann Soft Tissue Level solution to address space limitations

- Confidence when placing small diameter implants
- Wide range of treatment options
- Simplicity in daily use



reddot design award
winner 2012



More information on www.straumann.com

COMMITTED TO
SIMPLY DOING MORE
FOR DENTAL PROFESSIONALS

11, 21, 22 are no longer conservable. They showed mobility grades of I–II, high circular probing depths and bleeding on probing.

After a removable interim prosthesis 12–22 was produced, the four teeth in the anterior maxilla were extracted gently and the periradicular granulation tissue was also removed as non-traumatically as possible. The wound was closed with four collagen membranes and cone units; they were fitted to the alveolus by resizing the collagen part. The membrane part facing the oral cavity was adapted to the edges of the wound to enable a tight closure with suture material. Four weeks after extraction of the teeth, the former tooth area 12–22 was non-irritated with good remaining structure and volume. ITI implants were inserted in areas 12–22 which were fitted with a fixed bridge after twelve weeks of healing.

Case 2: Free-end situation in the right half of the maxilla

The free-end situation in the right half of the maxilla that occurred 31 years ago had been fitted with a disto-cantilever bridge 16–15–14 BM-KM-KM. At a later time, both of the two premolars (abutment teeth) received endodontic treatment and a root filling. Both teeth fractured so unfavourably that they were non-conservable. The patient requested "the same treatment, but with implants instead of teeth".

To prevent further fractures of the teeth that had fractured on the subgingival level, the remaining two root portions were extracted gently and carefully. Two collagen-cone units were customised with a scalpel (collagen part) and scissors (membrane) in such a way that they were flush with and filled the former alveolus in addition to providing a finish. The final closure was achieved by way of intraosseous sutures. A delayed immediate implantation was also carried out after about four weeks; two implants were inserted in areas 14, 15, which were again fitted with a cantilever bridge (16 as a premolar pontic) after several weeks of osseointegration.

Case 3: Replacement of periodontally severely damaged teeth 11, 21

The patient in her mid-thirties had already lost several teeth in the lateral dental area of the maxilla. The fact that she is a heavy smoker was certainly a considerable co-factor in this unpleasant situation. A trauma of the front teeth (a fall at home) that had occurred many years ago had required splinting of the two upper central incisors which now, only ten years after the procedure, showed a high degree of mobility. The patient also complained of pain when biting.

After the production of a clip-free interim partial prosthesis, the two upper central incisors were extracted, taking care to avoid any traumatisation. A collagen membrane cone unit was also used for treating both of the two alveoli. Since the patient was not prepared to stop smoking, maintaining structure and volume was just as important as achieving a fast and tight closure by using the collagen membrane and cone unit. After four weeks of primary healing time, two implants were inserted in areas 11, 21, which then received two crowns as a supra-contruction after eight weeks.

Evaluation

The procedure presented here is definitely not a substitute for a proven treatment scheme, but it can serve to simplify it. If the alveolus is largely intact, which must be defined as the precondition for executing the treatment steps described here, a GBR procedure can be performed quickly and without any further trauma to the tissue. The goal is to conserve as much volume of the former tooth socket as possible, thus creating favourable preconditions for a delayed immediate implantation. The procedure has obvious limitations in cases where the former tooth socket has been largely destroyed (due to a complicated extraction or previous procedures resulting in a loss of most of the buccal bone lamella), where the non-conservable tooth shows a profound infection, and in situations where the patient does not want the use of materials of animal origin.

Information regarding the employed collagen product: Absorbable collagen membrane-cone – PARASORB-Sombrero® – Absorbable local hemostatic agent with membrane for guided bone regeneration of equine origin. Manufacturer: RESORBA (Germany).

The authors hereby confirm that there is no conflict of interest.

contact

implants

Dr Georg Bach

Oral surgery specialist
Rathausgasse 36
79098 Freiburg/Breisgau, Germany

doc.bach@t-online.de

Christian Müller

Master Dental Technician
Christian Müller Dental-Technik
Carl-Kistner-Straße 21
79115 Freiburg/Breisgau, Germany

SwishPlus™



100% Surgical and Prosthetic Compatibility with Straumann® Implants¹



Reality Check
Straumann Customers
 All-in-One Packaging includes implant, compatible carrier, cover screw & healing collar



SwishPlus Advantages²:

Internal Octagon (Niznick US Pat. #4,960,381 Licensed to Straumann)

Prosthetic compatibility with Straumann's Tissue-Level implants (Standard, Standard Plus and Tapered Effect)

Internal square broached in flats of octagon for fixture-mount engagement (Pat. Pend.)

More Diameter Options

Narrow 3.3mm and wide 5.7mm diameters available in addition to the standard 4.1mm and 4.8mm diameters

- 1 Only 1mm of 2mm neck remains smooth for bone preservation³ with deeper placement
- 2 Micro-grooves for improved tissue attachment & increased surface area
- 3 Progressively-deeper threads for increased initial stability and surface area
- 4 Vertical self-tapping grooves for ease of insertion and increased initial stability
- 5 Tapered apical end to initiate self-tapping insertion
- 6 Carrier demarcations align with flats of octagon for use with indexed Swish abutments
- 7 Frictional carrier engages internal square, eliminating need for counter torque on removal

Carrier

Compatible with Straumann tool & standard ratchet



Price based upon EU list prices as of January 2013.

All trademarks are property of their respective companies.

¹Compatibility claims based upon Straumann's Tissue-Level implants.

²System Variation: 3.3mmD & 5.7mmD SwishPlus are tapered; 3.3mmD also has SwishPlant threads.

³Buser et. al. Int J Oral Maxillofacial Implants 2005; 20: 677-686

**BE ORDER
 SMART ONLINE**

www.implantdirect.eu | 00800 4030 4030