

implants

international magazine of oral implantology

1 2013



| **research**

Structure and volume in delayed immediate implantation

| **overview**

Applications of hollow osteotomes in dental Implantology

| **case report**

Treatment of a mandibular cyst with synthetic bone graft substitute



tiologic[®]

Implant system

Quality in Motion.



Discover it now on the IDS – Hall 10.1, Stand E10 / F11.



New augmentation materials—What is the gold standard?



Dr Rolf Vollmer

Now that we are on the verge of IDS, International Dental Show, I personally am eager to see what is going to be presented, especially with regard to the latest developments in bone augmentation materials. Osteogenesis takes place only in the sense of enclosing newly formed bone, which remains a biofunctionally foreign body within the augmented area for many years. The maxillary sinus seems to be a special subject and location with regard to osteogenesis. In sinus lift procedures with or without simultaneous implantation, many materials are working very well because of its special conditions. Lundberg et al. found out that the sinus is a sterile cavity. Its sterility is based on the epithelium cells' potential to produce nitric oxide, which has an aseptic effect. Another important factor for the regeneration of the augmented material is the blood supply, according to Benner and Schlehuber.

I think we all agree that, for small multi-wall defects, xenogeneic grafts are helpful and usually produce a non-vital, hard ceramic regeneration result. The subsequent drilling at such sites, however, is probably not a pleasure. In addition, many xenogeneic materials cannot be absorbed and the blending of autologous bone with xenogeneic material seems a challenge. In their studies at the University of Düsseldorf, Becker and Schwarz observed the best results with 50 % and a minimum of 30 % of autogenous bone in a mixture with a two-phase bone substitute material. Sinus lifts by crumbly grafts are easy to handle, but they should be given at least six to twelve months to heal. This amount of time can be a disaster for the patient. If it comes to an infection, the decomposition products of consequent mass cell deaths are a feast for invading bacteria. The situation for vertical augmentation is even worse. Bone graft materials of varying forms are available in unlimited quantities, which might make them suitable even for large defects. But do they really have high resorption stability and do they thus serve as guide rails for the ingrowths of new blood vessels and a subsequent osteoneogenesis?

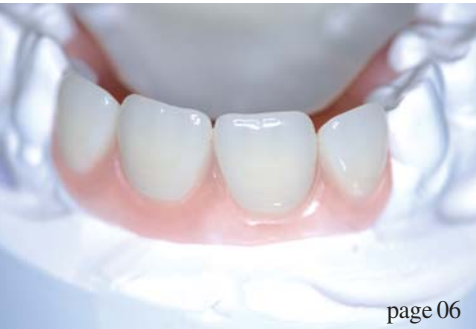In endogenous bone augmentation, I transfer vital cells, mineralised bone, fibrin and platelets and achieve a high biological potency for regeneration. In addition, I can then be sure that there will be no problems with the material I added to the bony structures. The fear of a second surgical defect is justified, but for smaller defects I can usually use the bone from the surgical site or nearby. Furthermore, I do not have additional material costs with autologous bone. Because of these considerations, I still use the endogenous bone for augmentation.

The surgeon has to decide upon the procedure after investigating the amount of bone that is missing. For this, DGZI wants to support our colleagues by postgraduate education and aid to decision-making.

I hope to see you all in Cologne, Germany, at our DGZI booth and look forward to discussing everything which can make our life easier and help our patients in the future.

Yours,

Dr Rolf Vollmer



page 06



page 24



page 28

| editorial

03 New **augmentation** materials—What is the **gold** standard?
| Dr Rolf Vollmer

| research

06 **Structure** and **volume** in delayed immediate **implantation**
| Dr Georg Bach *et al.*

14 **Mini implants**: a useful **complement** to conventional **implants**?
| Dr Friedhelm Heinemann *et al.*

20 **Ridge augmentation** for an **atrophied posterior mandible**—Part I
| Dr Omar Soliman *et al.*

| overview

24 Applications of **hollow osteotomes** in dental Implantology
| Dr Rolf Vollmer *et al.*

| case report

28 From **orthopaedics** to dental **implantology**
| Dr Suheil M. Boutros

34 Treatment of a **mandibular cyst** with **synthetic bone graft substitute**
| Dr Damian Dudek *et al.*

| industry report

38 Time proven **clinical success** of the SHORT™ **implant**
| Dr Vincent Morgan *et al.*

| news

42 **Manufacturer** News

48 **News**

| education

45 The next chapter in the **IDS success** story
| Koelnmesse

| events

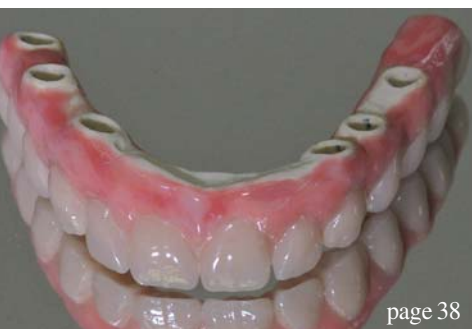46 More than 500 attendees visit **ISOI Conference** in **Tokyo/Japan**
| Dr Georg Bach

| about the publisher

50 | imprint



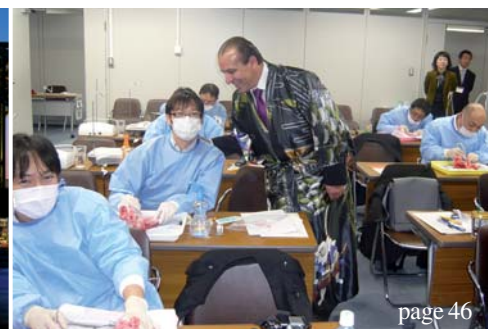Cover image courtesy of Bicon, www.bicon.com



page 38



page 45



page 46



CONOLOG® offers benefits!
www.camlog.com

**VISIT US
AT THE IDS
HALL 11.3
BOOTH A10-B19**



Excellent conical connection

Simple abutment positioning through three grooves and cams

Millionfold proven SCREW-LINE outer geometry

Highly precise transfer without transfer aid

High radial position precision

7 mm implants optionally available

BENEFITS

The CONOLOG® Implant System offers a comprehensive prosthetic portfolio for all indications. The conical implant/abutment connection with its proven CAMLOG positioning through three grooves and cams provides maximum precision and user-friendliness. More infos: www.camlog.com

CAMLOG® offers benefits!

a perfect fit™

camlog

Structure and volume in delayed immediate implantation

Authors_Dr Georg Bach & Christian Müller, Germany

Introduction

Delayed immediate implantation is a viable alternative to immediate implantation, for which there is no distinct evaluation in the literature, and a "regular" implantation after complete osseous healing of the former extraction area, generally associated with volume loss.

Loss of osseous volume after extraction of a non-conservable tooth may be a limiting factor for later implantation. To avoid this problem, many authors recommend immediate implantation, where an implant is inserted immediately after careful and gentle tooth extraction. In cases where immediate implantation is not wanted or possible, delayed immediate implantation after reconstruction of the former tooth area, which is generally carried out three to four weeks after extraction of the non-conservable tooth, is a viable alternative. If the alveolus is (still) mostly intact after extraction, the precondition for immediate implantation can be optimised with a collagen membrane and cone unit.

The procedure presented in the form of the following three exemplary patient cases also acknowledges this easy surgical procedure.

The focus of interest is on procedures for preserving osseous volume after extraction—many authors emphasise the value of closing the wound by means of a "punch", which they claim to have considerable advantages with regard to protection against resorption. Undisturbed growth of bone-forming cells in the former tooth socket is promoted by preventing the connective tissue from growing into the alveolus. However, this procedure presents more of a challenge for the surgical skills of the dental surgeon in terms of production and insertion, and it is more demanding for the patient, both surgically and financially.

The insertion of so-called collagen membrane and cone units can simplify closure of the alveolus considerably and avoid removal of the punch at a later time. A second procedure is not required because of the absorbability of the material, since the collagen membrane cone unit does not have to be removed.

Procedure

The manufacturer recommends the following procedure for the insertion of collagen membrane and cone unit:

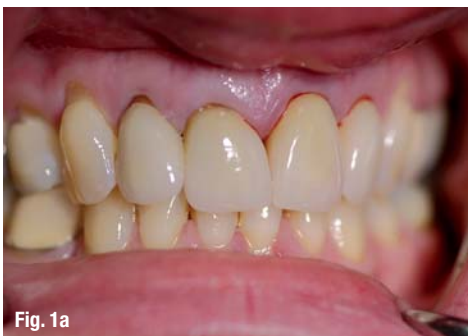

Fig. 1a

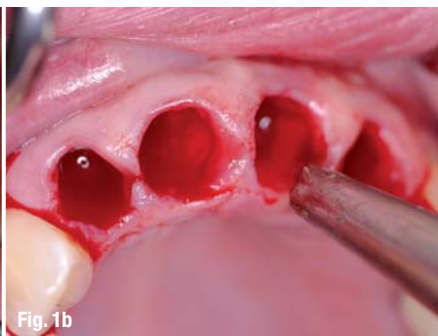


Fig. 1b

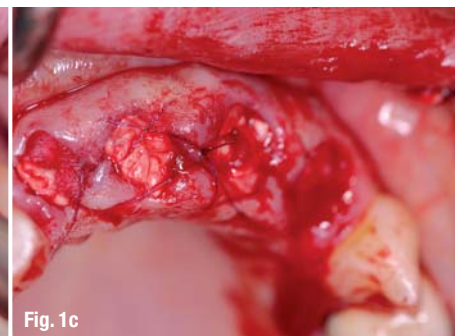


Fig. 1c

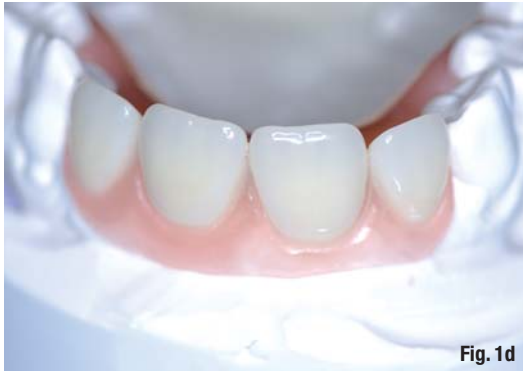

Fig. 1d

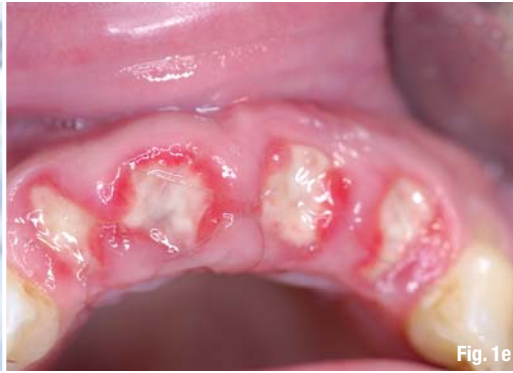

Fig. 1e

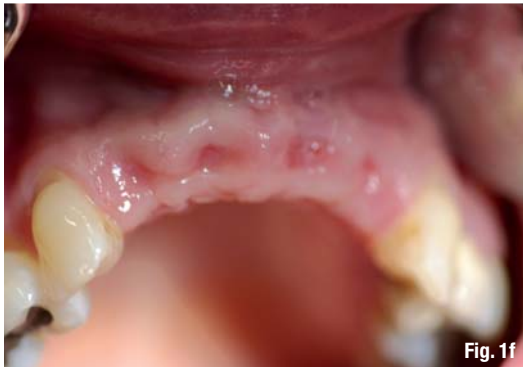

Fig. 1f

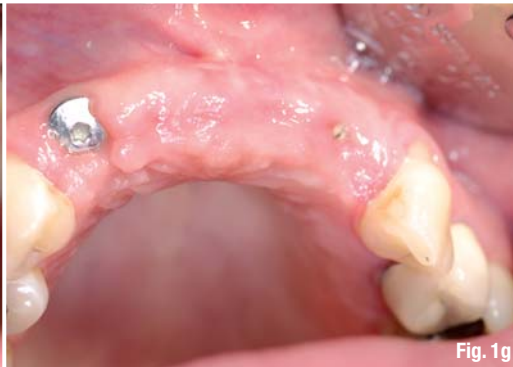

Fig. 1g

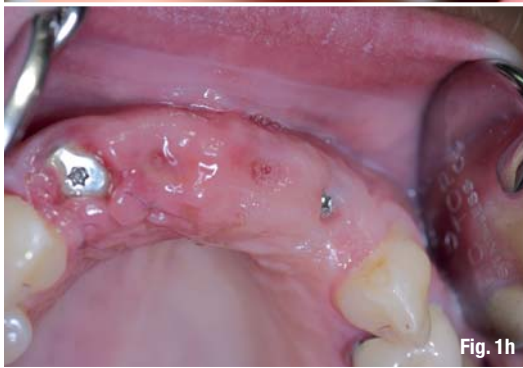

Fig. 1h

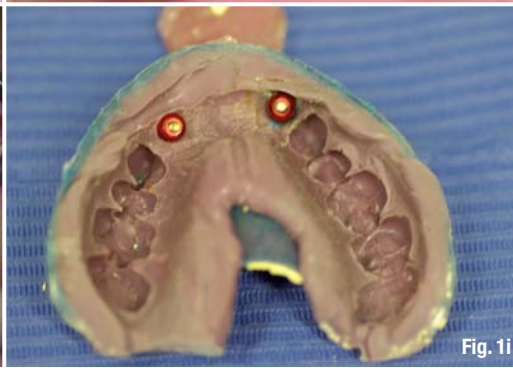

Fig. 1i

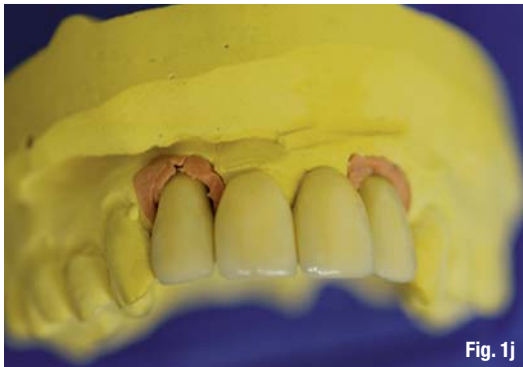

Fig. 1j

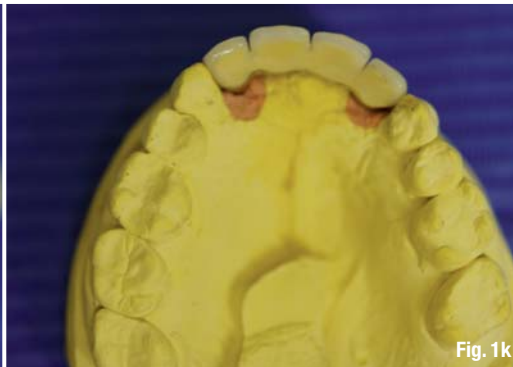

Fig. 1k

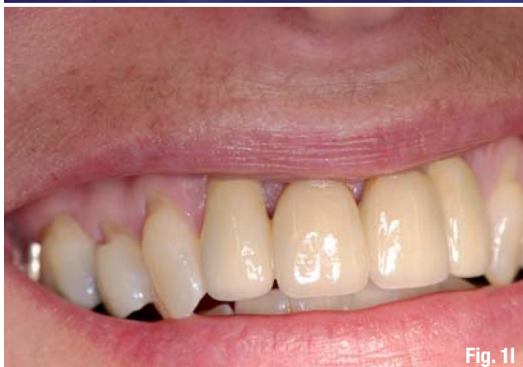

Fig. 1l

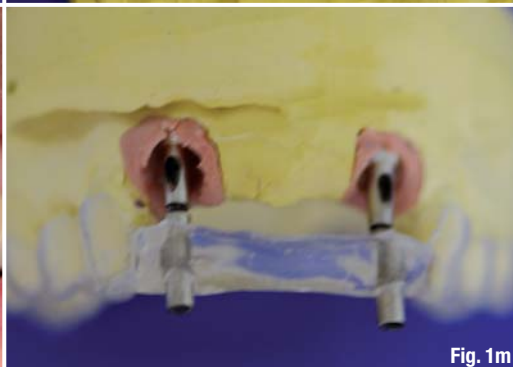

Fig. 1m

Case 1

Due to an extensive dental history, none of the anterior teeth of the maxilla were conservable (Fig. 1a) and had to be removed gently (Fig. 1b). Immediately following extraction of the teeth, collagen and membrane cones were inserted (Fig. 1c) for the purpose of socket preservation and integration of the previously produced (Fig. 1d) interim prosthesis. Figures 1e and 1f show the clinical situation one and four weeks after surgery; Figure 1g shows the situation after delayed immediate implantation. The intraosseous suture material was removed seven days after implantation (Fig. 1h). After completion of the osseointegration phase, the casting was done (Fig. 1i), followed by insertion of the abutments using the prepared insertion aid (Figs. 1j–l). Figure 1m shows the exact conformity between planning (template) and achieved result (abutments).

Case 2

In the right half of the maxilla, the two remaining posterior teeth were fractured and deeply damaged by caries (Fig. 2a), thus non-conservable. The two alveoli remained largely intact (Fig. 2b) after gentle removal of the roots, and a customised collagen membrane and cone unit was inserted (Fig. 2c).

The suture material was removed one week after surgery (Fig. 2d).

After four weeks, the bone bed showed no irritation and a primary reconstruction to a large extent. We were able to insert two implants after this short waiting period. Figure 2e shows the condition after implant bed drilling; Figure 2f shows the two inserted implants. Please also see the corresponding dental panoramic X-ray (Fig. 2g).

Upon completion of the osseointegration period, the implants showed no irritation (Fig. 2h), so that the impression could be taken with a customised spoon (Fig. 2i) and the dental lab work (Figs. 2j and k) was executed. Figure 2l shows the inserted abutments, and figure 2m shows the integrated product in the patient's mouth. Figure 2n shows the corresponding sagittal view.

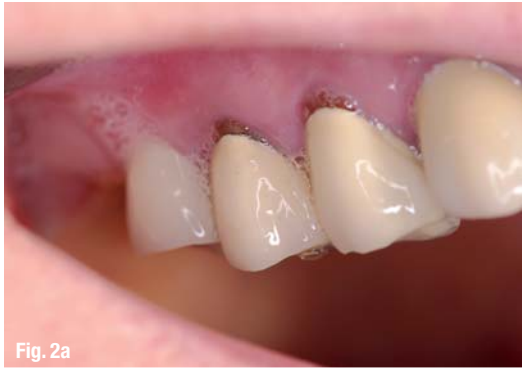

Fig. 2a

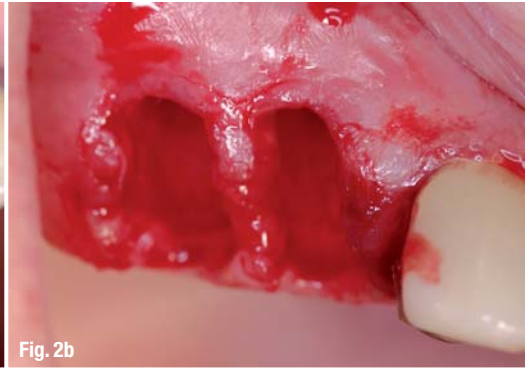

Fig. 2b

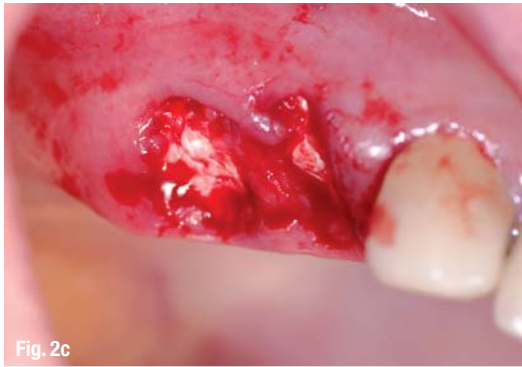

Fig. 2c

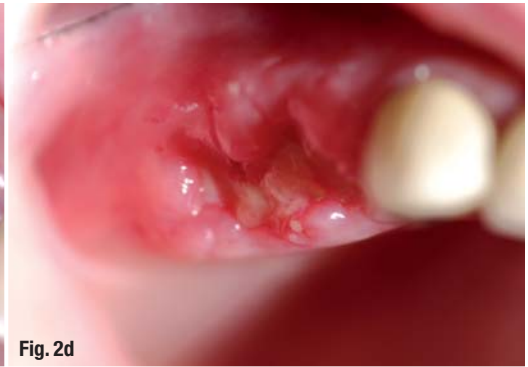

Fig. 2d

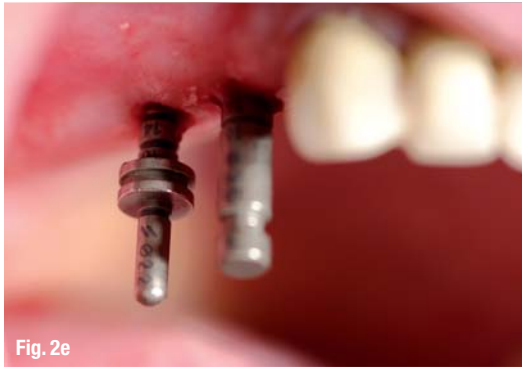

Fig. 2e

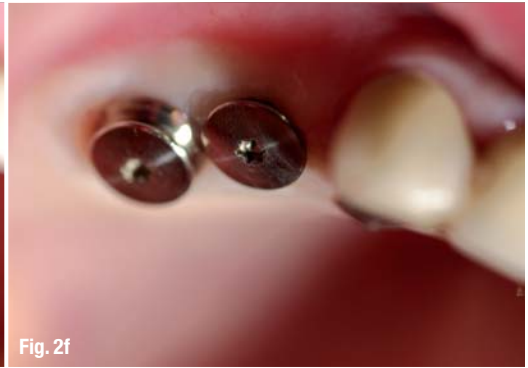

Fig. 2f

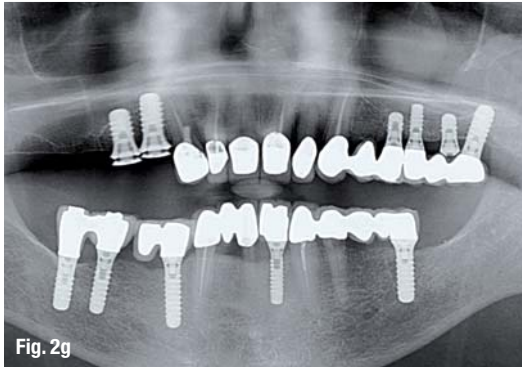


Fig. 2g

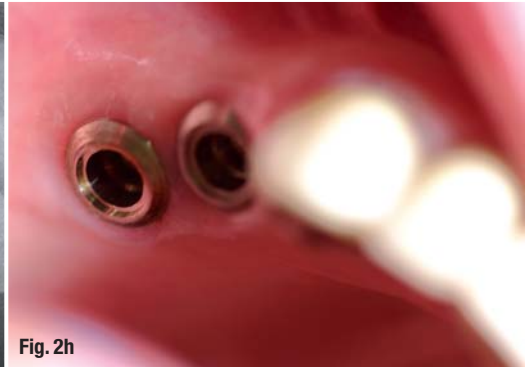


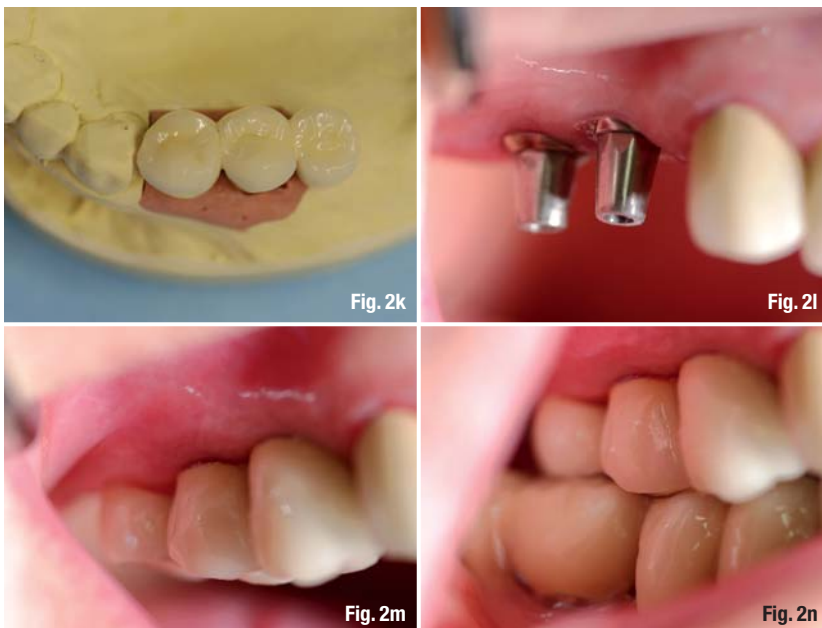
Fig. 2h

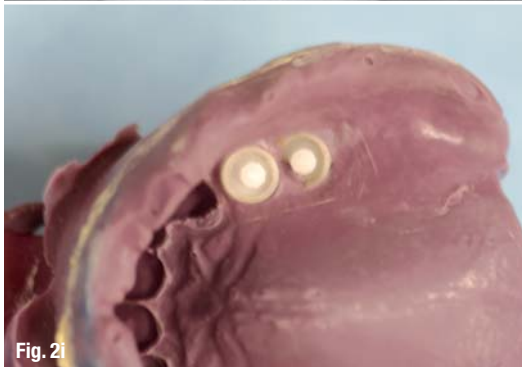

Fig. 2i

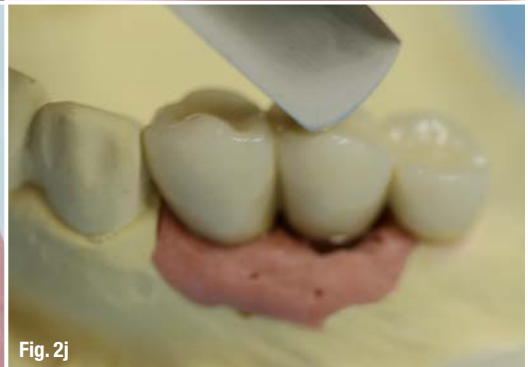

Fig. 2j



1. Preparation for a tight closure

After gentle and non-traumatic extraction of the non-conservable tooth, the marginal gingiva is minimally detached to the alveolar process so that the free membrane side of the collagen membrane and cone unit can be inserted.

2. Customising collagen membrane and cone unit

Moistening is to be avoided because this would make it more difficult to achieve a good fit to the alveolus. Rather, the collagen cone is fitted to the alveolus with the scalpel, and the membrane is configured with small scissors to facilitate insertion under the marginal edges, while at the same time achieving an ideal defect-congruent coverage. To achieve this, the dimensions of the membrane should be approximately 1–2 mm wider than the diameter of the alveolus.

3. Insertion of collagen membrane and cone unit

Using dry, anatomical, wide tweezers, the collagen membrane and cone units are inserted into the alveolus and then pushed in deep with a moist swab. The membrane part should be seated exactly at the level of the marginal gingiva. Now the free and slightly oversized part of the membrane is pushed carefully under the edges of the marginal gingiva.

4. Protective measures

A back-and-forth suture with a non-absorbable suture material will secure the position of the collagen membrane and cone unit in the alveolus and also adapt the free gingiva edges on the membrane.

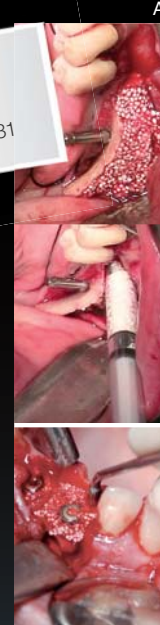Case presentations

The following three patient cases serve to illustrate and ultimately evaluate the procedure of a delayed immediate implantation using an absorbable collagen membrane and cone unit.

Case 1: Four non-conservable teeth in the anterior maxilla

Due to a trauma of the anterior teeth during adolescence, the patient received endodontic treatment and crowns on the four front teeth, which—after recurring problems—resulted in apicoectomies. The second set of crowns at ten years after the first prosthetic treatment was followed immediately by a second resection due to persistent discomfort. The patient is in her late thirties, and now the four front teeth 12,

Visit us!
Hall 11.3,
K030/L031



easy-graft®
CRYSTAL

Ingenious: Simple handling and accelerated osteoconduction for long-term volume preservation.

SUNSTAR
GUIDOR®

Degradable Solutions AG
Member of Sunstar Group
Wagistrasse 23
CH-8952 Schlieren/Zurich
www.easy-graft.com

AD
easy-graft®CRYSTAL

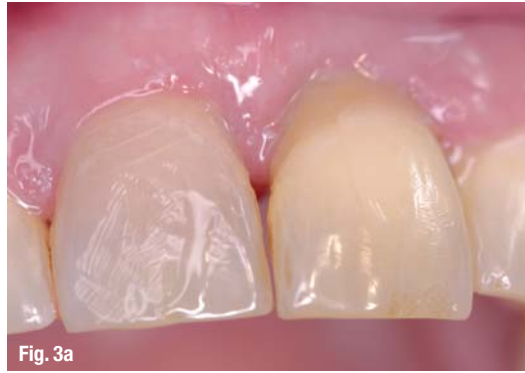

Fig. 3a

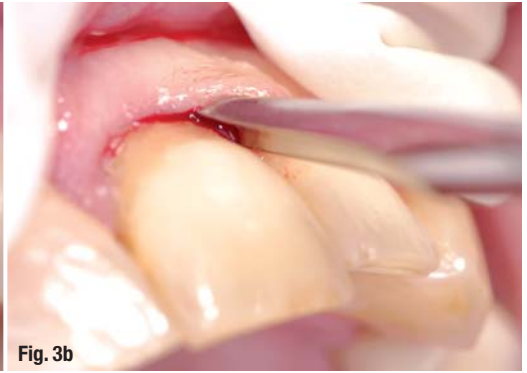


Fig. 3b

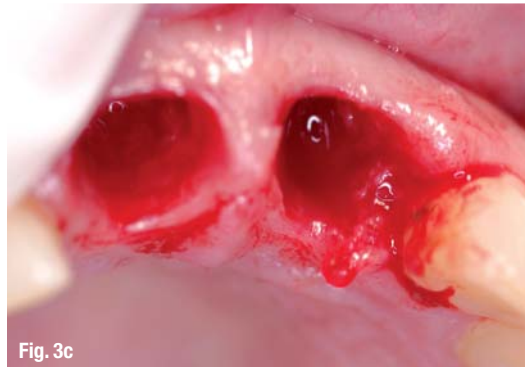

Fig. 3c

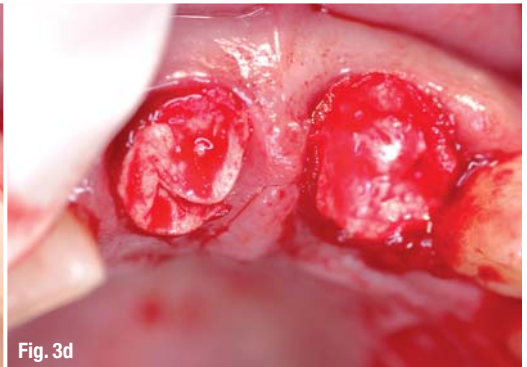


Fig. 3d

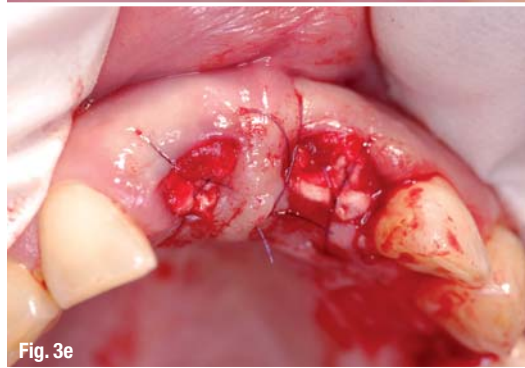


Fig. 3e

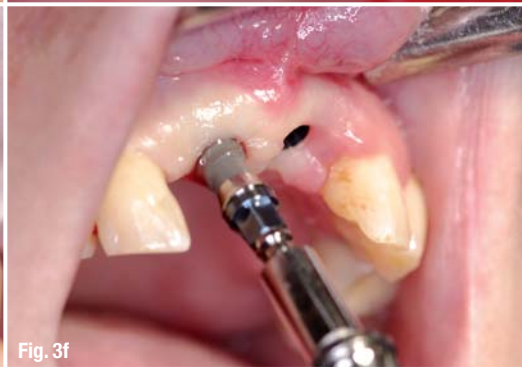

Fig. 3f

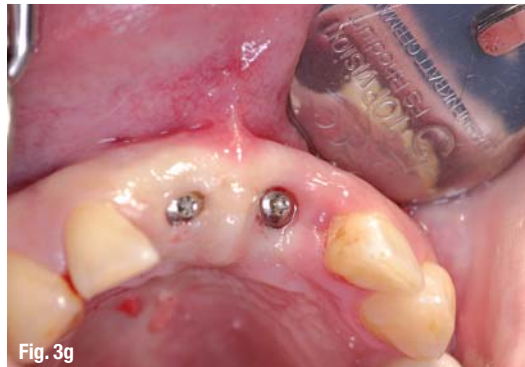


Fig. 3g

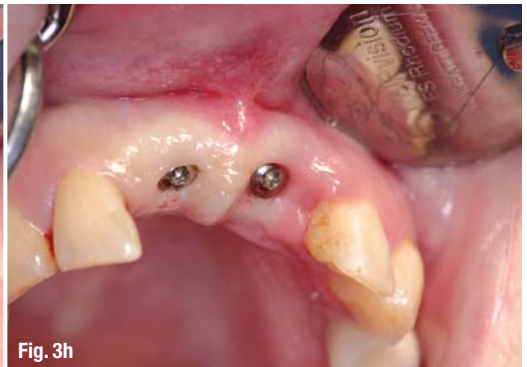

Fig. 3h

Case 3

The teeth were marked by a severe previous periodontitis, and the two upper central incisors were damaged so severely (Fig. 3a) that they were considered non-conservable.

After minimally invasive removal of the two upper central incisors (Fig. 3b), the alveoli of the incisors were found to be intact (Fig. 3c) so that, for the purpose of socket preservation, collagen cone and membrane units were inserted (Fig. 3d) and fixated (Fig. 3e).

Two implants (Fig. 3f) were inserted after primary healing of the soft tissue. Figure 3g shows the immediate postoperative status; Figure 3h shows the status after one week.

The two implants were fitted with crowns upon completion of further eight weeks of healing time.

Figure 3i shows the clinical findings after six months within the scope of a recall appointment.

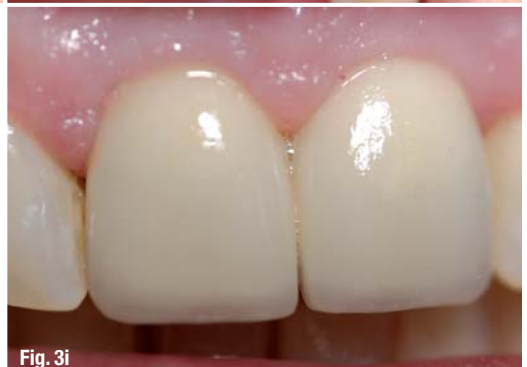

Fig. 3i

CONFIDENCE IN LIMITED SPACE


STRAUMANN® NARROW NECK CrossFit®

The Straumann Soft Tissue Level solution to address space limitations

- Confidence when placing small diameter implants
- Wide range of treatment options
- Simplicity in daily use



reddot design award
winner 2012



More information on www.straumann.com

COMMITTED TO
SIMPLY DOING MORE
FOR DENTAL PROFESSIONALS

11, 21, 22 are no longer conservable. They showed mobility grades of I–II, high circular probing depths and bleeding on probing.

After a removable interim prosthesis 12–22 was produced, the four teeth in the anterior maxilla were extracted gently and the periradicular granulation tissue was also removed as non-traumatically as possible. The wound was closed with four collagen membranes and cone units; they were fitted to the alveolus by resizing the collagen part. The membrane part facing the oral cavity was adapted to the edges of the wound to enable a tight closure with suture material. Four weeks after extraction of the teeth, the former tooth area 12–22 was non-irritated with good remaining structure and volume. ITI implants were inserted in areas 12–22 which were fitted with a fixed bridge after twelve weeks of healing.

Case 2: Free-end situation in the right half of the maxilla

The free-end situation in the right half of the maxilla that occurred 31 years ago had been fitted with a disto-cantilever bridge 16–15–14 BM-KM-KM. At a later time, both of the two premolars (abutment teeth) received endodontic treatment and a root filling. Both teeth fractured so unfavourably that they were non-conservable. The patient requested "the same treatment, but with implants instead of teeth".

To prevent further fractures of the teeth that had fractured on the subgingival level, the remaining two root portions were extracted gently and carefully. Two collagen-cone units were customised with a scalpel (collagen part) and scissors (membrane) in such a way that they were flush with and filled the former alveolus in addition to providing a finish. The final closure was achieved by way of intraosseous sutures. A delayed immediate implantation was also carried out after about four weeks; two implants were inserted in areas 14, 15, which were again fitted with a cantilever bridge (16 as a premolar pontic) after several weeks of osseointegration.

Case 3: Replacement of periodontally severely damaged teeth 11, 21

The patient in her mid-thirties had already lost several teeth in the lateral dental area of the maxilla. The fact that she is a heavy smoker was certainly a considerable co-factor in this unpleasant situation. A trauma of the front teeth (a fall at home) that had occurred many years ago had required splinting of the two upper central incisors which now, only ten years after the procedure, showed a high degree of mobility. The patient also complained of pain when biting.

After the production of a clip-free interim partial prosthesis, the two upper central incisors were extracted, taking care to avoid any traumatisation. A collagen membrane cone unit was also used for treating both of the two alveoli. Since the patient was not prepared to stop smoking, maintaining structure and volume was just as important as achieving a fast and tight closure by using the collagen membrane and cone unit. After four weeks of primary healing time, two implants were inserted in areas 11, 21, which then received two crowns as a supra-contruction after eight weeks.

Evaluation

The procedure presented here is definitely not a substitute for a proven treatment scheme, but it can serve to simplify it. If the alveolus is largely intact, which must be defined as the precondition for executing the treatment steps described here, a GBR procedure can be performed quickly and without any further trauma to the tissue. The goal is to conserve as much volume of the former tooth socket as possible, thus creating favourable preconditions for a delayed immediate implantation. The procedure has obvious limitations in cases where the former tooth socket has been largely destroyed (due to a complicated extraction or previous procedures resulting in a loss of most of the buccal bone lamella), where the non-conservable tooth shows a profound infection, and in situations where the patient does not want the use of materials of animal origin.

Information regarding the employed collagen product: Absorbable collagen membrane-cone – PARASORB-Sombrero® – Absorbable local hemostatic agent with membrane for guided bone regeneration of equine origin. Manufacturer: RESORBA (Germany).

The authors hereby confirm that there is no conflict of interest.

contact

implants

Dr Georg Bach

Oral surgery specialist
Rathausgasse 36
79098 Freiburg/Breisgau, Germany

doc.bach@t-online.de

Christian Müller

Master Dental Technician
Christian Müller Dental-Technik
Carl-Kistner-Straße 21
79115 Freiburg/Breisgau, Germany

SwishPlus™



100% Surgical and Prosthetic Compatibility with Straumann® Implants¹



Reality Check
Straumann Customers
 All-in-One Packaging includes implant, compatible carrier, cover screw & healing collar



SwishPlus Advantages²:

Internal Octagon (Niznick US Pat. #4,960,381 Licensed to Straumann)

Prosthetic compatibility with Straumann's Tissue-Level implants (Standard, Standard Plus and Tapered Effect)

Internal square broached in flats of octagon for fixture-mount engagement (Pat. Pend.)

More Diameter Options

Narrow 3.3mm and wide 5.7mm diameters available in addition to the standard 4.1mm and 4.8mm diameters

- 1 Only 1mm of 2mm neck remains smooth for bone preservation³ with deeper placement
- 2 Micro-grooves for improved tissue attachment & increased surface area
- 3 Progressively-deeper threads for increased initial stability and surface area
- 4 Vertical self-tapping grooves for ease of insertion and increased initial stability
- 5 Tapered apical end to initiate self-tapping insertion
- 6 Carrier demarcations align with flats of octagon for use with indexed Swish abutments
- 7 Frictional carrier engages internal square, eliminating need for counter torque on removal

Carrier

Compatible with Straumann tool & standard ratchet



Price based upon EU list prices as of January 2013.

All trademarks are property of their respective companies.

¹Compatibility claims based upon Straumann's Tissue-Level implants.

²System Variation: 3.3mmD & 5.7mmD SwishPlus are tapered; 3.3mmD also has SwishPlant threads.

³Buser et. al. Int J Oral Maxillofacial Implants 2005; 20: 677-686

**BE ORDER
 SMART ONLINE**

www.implantdirect.eu | 00800 4030 4030

Mini implants: a useful complement to conventional implants?

Authors_Dr Friedhelm Heinemann, PD Dr Torsten Mundt & Prof. Dr Christoph Bourauel, Germany

Fig. 1_Finite element model of an experimental mini implant in an idealised bone segment of an anterior mandibular jaw (left). Calculated strains in the implant. The maximum strain level is found in the area where the corticalis is penetrated (red spots in the middle). The picture on the right shows an overhead shot of the corticalis. In the grey area, the bone is overloaded.⁵

_Introduction

Mini dental implants with a diameter of less than 3 mm have been used increasingly often in dental implantology. Several years ago, they were typically placed in combination with conventional implants and served as provisional solutions for the stabilisation of dentures during the healing phase.⁵ Today, they are also approved for long-term use. On the

one hand, mini dental implants are placed to fix complete or partial dentures and contribute to increased stability. On the other hand, they are used as abutments for fixed bridges in specific situations, e.g. in small gaps.¹²

_Risks of mini implants

Although one-piece implants have been used for retention of definitive restorations for several years—the first approval was granted in 1997 by the US Food and Drug Administration (FDA) for today's 3M™ ESPE™ MDI Mini Dental Implants—there are still reservations in many practices regarding their suitability for permanent use. This is due to study results which reveal that implants with a reduced diameter might have a higher failure rate than conventional implants.^{9,13} In an investigation analysing the biomechanics (FEM analysis) of mini implants, it was shown that, in comparison with conventional implants, those with a small diameter cause a significantly increased stress on the bone.⁷

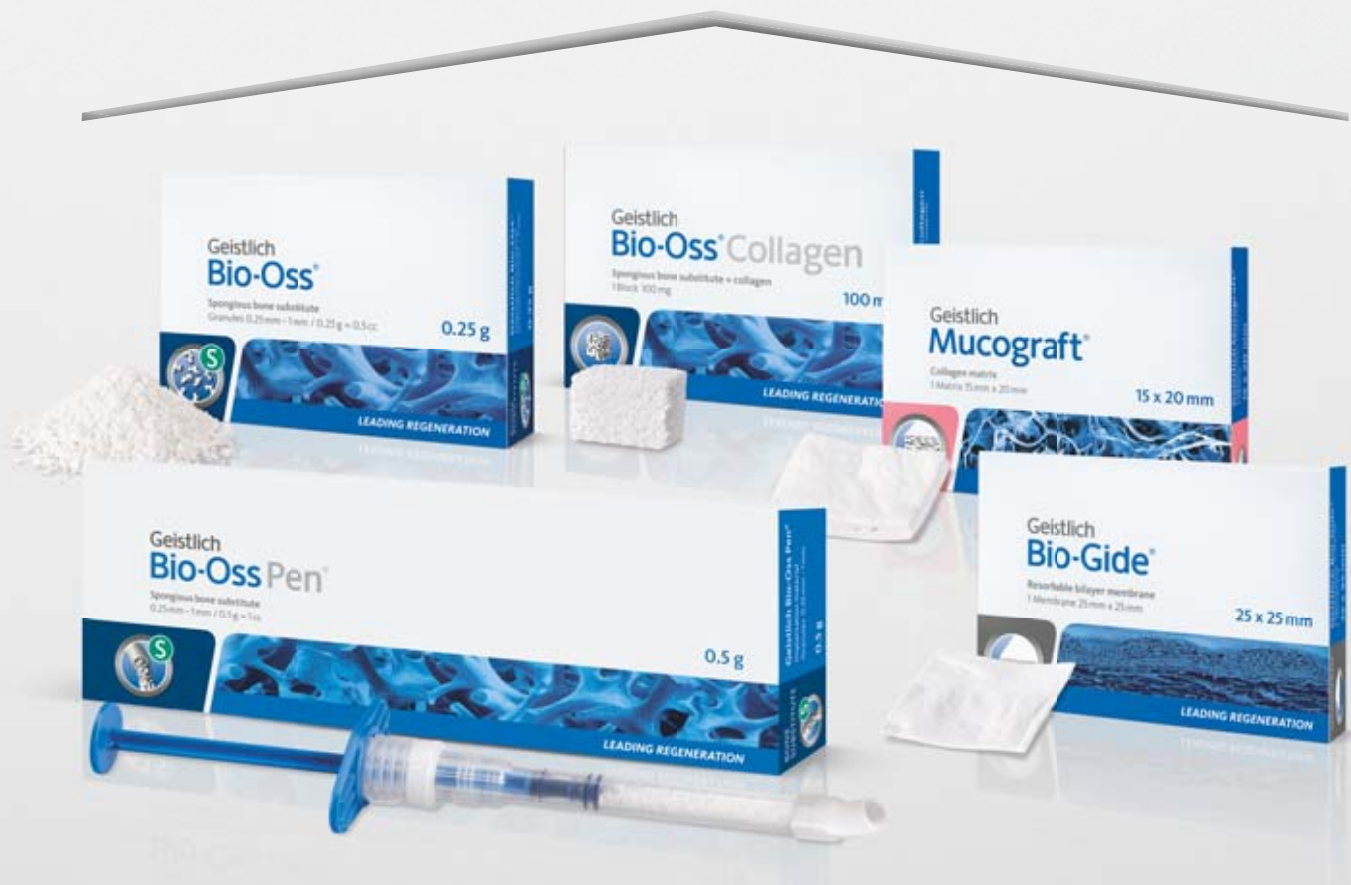Figure 1 shows the FE model of an experimental implant. In this investigation, the implants were surrounded by a thin bone segment representing bone loss in analogy with the clinical situation. The corticalis was modelled with a relatively high thickness and the turn of the thread stood in contact with the corticalis. The presumed load was a force transmission of 150 N with an angle of 30° to the implant axis. The load on the implant and the bone under these conditions is represented in Figure 1. While the strains in the implant are 600 MPa and thus below the flow limit of the material, a load on the oral corticalis of up to 200 MPa was measured. This is twice the permissible limit stress for the bone



Fig. 1



The home of regenerative dentistry



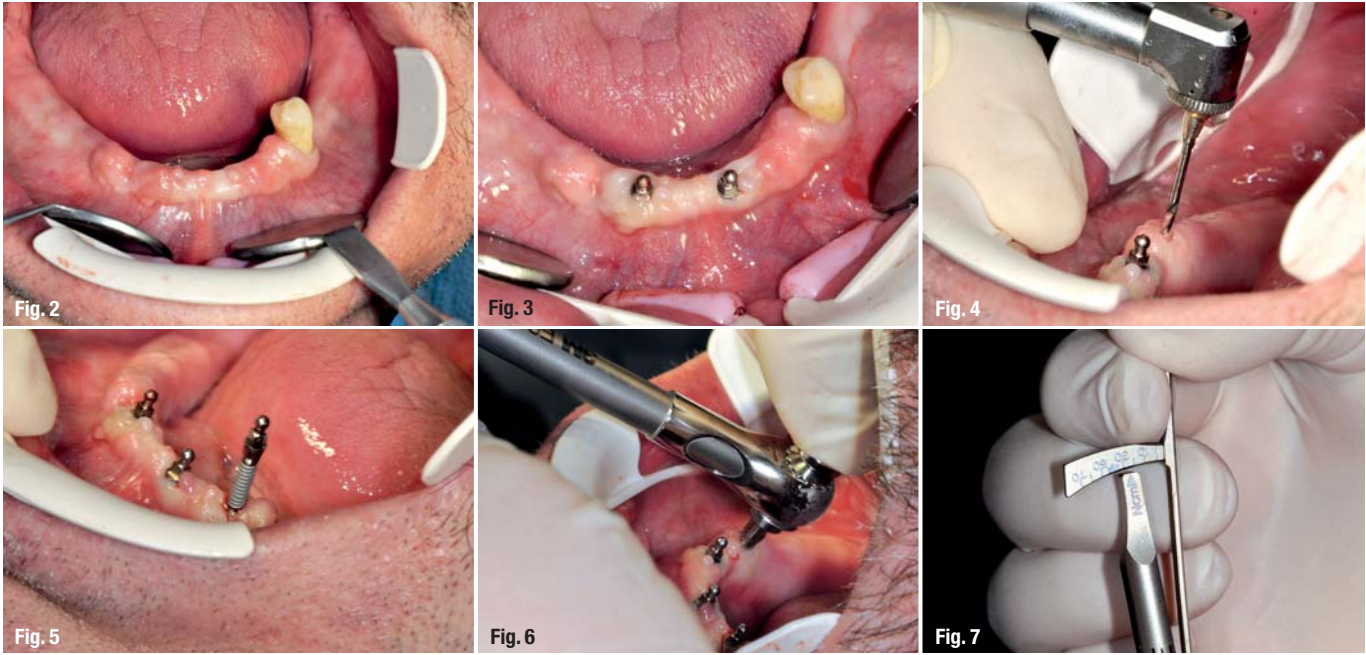


Fig. 2_Initial situation in the mandible.
Fig. 3_Situation after placement of two mini implants in the anterior area.
Fig. 4_Drilling of the pilot hole.
Fig. 5_Insertion of another implant.
Fig. 6_Use of the torque wrench.
Fig. 7_Adjustment of the torque wrench.

(100 MPa) from which damage is to be expected. The investigation was based on the assumption that the same prosthetic concept that used for conventional implants was applied, causing a direct load distribution on the implant.

The observed higher load might be an explanation for the partly increased failure rates. However, a current literature survey shows that the survival rate of implants with a reduced diameter is indeed comparable to the ones obtained for conventional implants.¹¹ In addition, there are references pointing towards a lower stability of mini implants and those indicating the risk that these might fracture due to their reduced diameter.^{1,6} However, these fractures also do not seem to be a frequent problem associated with mini implants.^{4,8}

Alternative solution with reduced bone volume

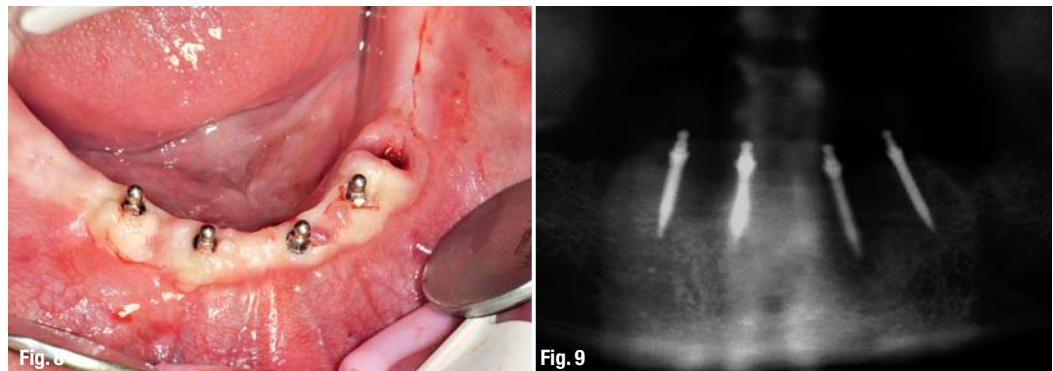
Mini implants prove their worth in the clinical long-term use, provided that they are placed in ac-

cordance with the protocol recommended by the manufacturer and inserted by trained dentists or implantologists.^{2,3,10} Under these conditions, they present a sensible supplement to implants with a conventional diameter in many cases.

For example, mini implants are indicated in cases where the horizontal bone volume is not sufficient for conventional implant placement and where bone quality is not impaired. In many cases, augmentative measures or bone splitting would be necessary in order to create sufficient space for the implant. By use of a mini dental implant, a complex augmentation procedure can be avoided and in particular cases, e.g. in medically compromised patients, implant treatment is only possible with implants with a small diameter, since the surgical risk can be reduced this way.

In the following paragraphs, two patient cases are described in which mini dental implants were used for denture stabilisation in the mandible.

Fig. 8_Final situation.
Fig. 9_Radiograph for checking the final implant positions.





Made in Germany



IVORY *Line* German Implant System

two-piece bone level implant
with internal hex connection
also as narrow line NL Ø 3mm
one-piece implant with
external connection
super nano **surface**
quick **osseo-integration**
self tapping **threads**
clever and easy **handling**
all necessary **abutments and tools**
clearly arranged **system**
excellent **price**



NEW

Come and find your heart at Ritter
...ask for your special IDS Offer:
Set price, incl. Implants, Analogs, Transfers
Abutments, Healing Caps and Starter Tool Kit!



IDS Cologne
GERMANY
12.-16.3.2013

IDS
2013

Hall 2.2
Stand C10



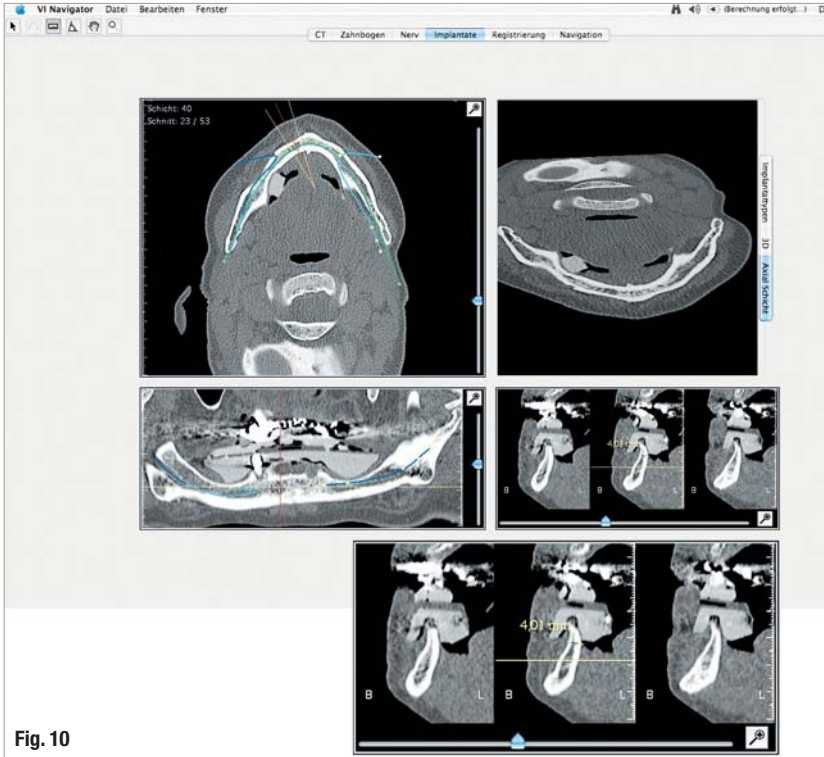


Fig. 10

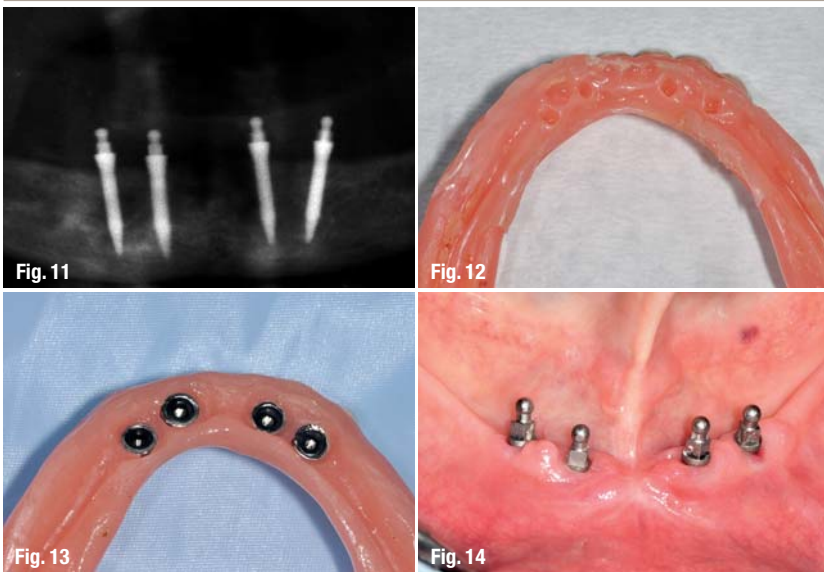


Fig. 11

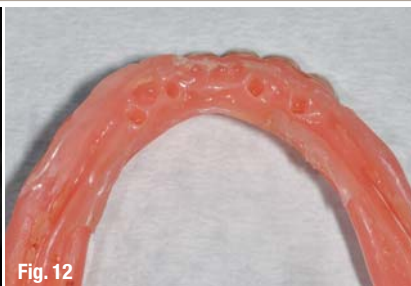

Fig. 12

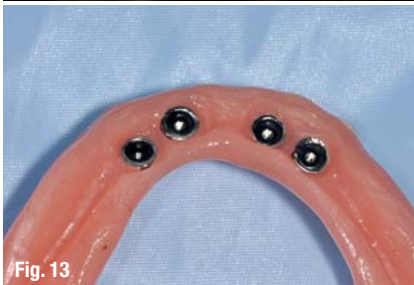

Fig. 13

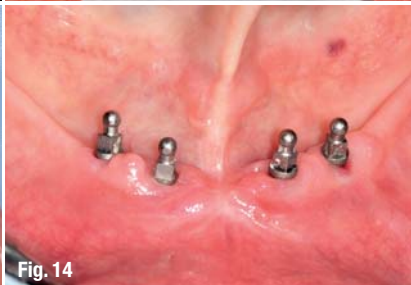

Fig. 14

Fig. 10_CBCT scan for analysis of the anatomical situation.

Fig. 11_ Checking of the implant positions on the OPG.

Fig. 12_ Marking of the implant positions on the denture base.

Fig. 13_ Basal view of the denture after embedding the metal housings.

Fig. 14_ Clinical situation in the mandible after placement of four mini implants.

_Patient case I

Originally, the male patient had received a partial mandibular denture which was supported by the remaining natural teeth. The remaining premolar (Fig. 2) was not considered to be worth preserving. Since the anxious patient also asked for a treatment with a reasonable price, the placement of four one-piece Mini Dental Implants (3M ESPE MDI) with a diameter of 1.8 mm and an O-ball head was planned. Within the context of the implant procedure, the premolar should be extracted. Due to the low thickness of the gingiva, it was not necessary to create a flap: the location of the bone could be identified exactly. Initially, the desired implant positions

were determined. The positions should be chosen in a way that the mesial distance from the mental foramen and the neurovascular bundle is at least 7 mm. In addition, a gap between the implants of minimally 5 mm is required. In this way, it is ensured that sufficient space is left between the metal housings which are placed on the implants later on and are used for fixation of the denture base.

In the first step, two implants were inserted in the anterior region following the protocol which is recommended by the manufacturer (Fig. 3). For the preparation of the pilot hole, a drill with a diameter that is smaller than that of the selected implant was used. Moreover, the drilling depth should be one half to one third of the implant length in order to cause bone compression and condensation during implant insertion. This contributes to an increased primary stability of the implants and is possible due to the self-tapping design of MDI. For turning the implant, a silicone cap, a finger driver, a winged thumb driver and a torque wrench were used one after the other. All instruments—with the exception of the torque wrench—were used until clear resistance was felt. The insertion of the distal implants followed in the same manner after extraction of the premolar (Figs. 4–6). With the aid of the torque wrench, an insertion torque of 35 Ncm was obtained in order to ensure sufficient stability of the implant (Fig. 7). Figure 8 shows the final situation. On the control radiograph it became clear that the implants were placed in the desired positions (Fig. 9).

_Patient case II

In this case, the female patient, approximately 65 years old, was not happy with the stability of her denture. Moreover, she reported that she frequently had sore spots which could be explained by a very narrow and pointed alveolar ridge after the initial clinical examination. The patient obtained detailed information about the situation and the available treatment options and finally settled for three-dimensional radiographic diagnosis in order to lay the foundation for a simplified decision making regarding different prosthetic concepts.

The radiograph (Fig. 10) confirmed a high and entirely small alveolar bone. Without complex augmentative measures, implant placement was not possible. Moreover, it was revealed that, in accordance with the small ridge, the bone was dense and thus ideally suited for the use of mini dental implants—judged by the results of the FEM analysis. Since the patient did not desire complex augmentation procedures, she opted for fixation of a complete denture with MDI Mini Dental Implants.

Four mini implants with a diameter of 2.1 mm and a length of 13 mm were inserted in the mandible following the procedure described above. Their position was checked on the OPG (Figs. 11 and 12). Afterwards, SECURE Soft Reline Material (3M ESPE) was applied into the denture base, which was cautiously placed into the mouth of the patient. In this way, the implant positions were marked in the material (Fig. 13). Subsequently, the metal housings were embedded in the denture base using SECURE Hard Pick-Up Material (3M ESPE). The housings were pressed into the denture intraorally during occlusion. When the cold cure resin was polymerised, the denture was removed from the mouth and finished.

Since the metal housings enable highly elastic anchorage via rubber O-rings, the denture is still supported by the soft tissue and the load on the implants is reduced. Thus, immediate loading is possible if the required primary stability is obtained, as is usually the case in the mandible. The resilient connection concept without contact of metal to metal (soft loading) should also reduce the risk of overload of the implant or the surrounding bone bed as observed in the FEM analysis described above. However, a scientific verification of the interface remains to be done.

Conclusion

As shown by both patient cases, mini dental implants are a useful alternative or complement to implants with a conventional diameter. The patient is often spared complex augmentative measures which are time-consuming and invasive. In addition, new treatment options are created for medically compromised as well as anxious patients. After a thorough evaluation of the risks and benefits of a treatment involving mini implants and provided that they are placed by an implantologically experienced dentist who follows the insertion protocol, excellent clinical results can be obtained.

Editorial note: A complete list of references is available from the publisher.

_contact

implants

Dr Friedhelm Heinemann

Im Hainsfeld 29
51597 Morsbach, Germany
Tel.: +49 2294 9920-10

friedhelmheinemann@web.de

AD

*become an author
for "implants"*

[PICTURE ©SURYAVAKI]



Please contact Claudia Jahn
✉ c.jahn@oemus-media.de

Ridge augmentation for an atrophied posterior mandible—Part I

NanoBone block *versus* allograft bone block

Authors Dr Omar Soliman, Prof. Dr Mohamed Nassar, Ass. Prof. Dr Mahmoud Shakal & Ass. Prof. Dr Eman Mohy El-din Megahed, Egypt

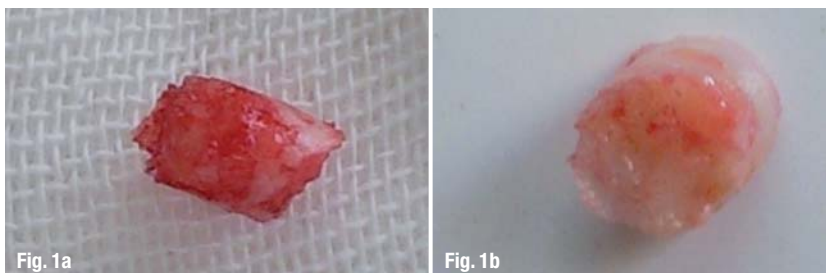
Introduction

Alveolar bone first forms when the Hertwig's root sheath develops from the tooth germ. The alveolar bone does not form in the absence of primary or secondary tooth development. The close relationship between the tooth and the alveolar process continues throughout life. Wolff's Law (1892) states that bone remodels in relation to the forces applied. Every time the function of the bone is modified, a definite change occurs in the internal architecture and external configuration.

Bone needs stimulation to maintain its form and density. Roberts et al.¹ report that a 4% strain to the skeletal system maintains bone and helps balance resorption and formation. When a tooth is lost, the lack of stimulation to the residual bone causes a decrease in trabeculae and bone density in the area, with loss in external width and height of the bone volume, and eventually leads to atrophic edentulous ridges. A primary reason to consider dental implants for replacing missing teeth is the maintenance of alveolar bone. A dental implant placed into the bone serves both as an anchor for the prosthetic device and as a means of preventive maintenance in dentistry. When stress and strain are

applied to the bone surrounding the implant, the bone trabeculation decrease after tooth extraction is reversed. There is an increase in bone trabeculae and density once the dental implant has been placed and is functional. In addition, the dental implant helps maintain the overall volume of the bone.²

Ridge augmentation is designed to widen ridges prior to implant placement. Various grafting procedures have been utilised for grafting an edentulous ridge, including an allograft, autogenous graft or xenograft with or without a titanium reinforced membrane, ridge splits, distraction osteogenesis, and onlay grafting with an autogenous or allograft bone block. Traditionally, onlay ridge augmentation has entailed the use of an autogenous graft from a separate intra-oral surgical area such as the ramus, chin or posterior ridge, or from extra-oral sites such as the tibia, iliac crest or ribs.³ The need for a second surgical site could be eliminated were a graft material such as an allograft bone block or NanoBone block be shown to provide adequate volume and quality of new bone in atrophic sites. Tissue engineering is an interdisciplinary field that applies the principles of engineering and life sciences to the development of biological substitutes that can replace, restore, or improve tissue function.⁴ One tissue-engineering approach is the use of 3-D scaffolds to provide a suitable environment for tissue formation. Ideal scaffolds act as a guide supporting cell growth and differentiation and utilise the deposition of regenerated tissue.⁵ In bone-tissue engineering, the scaffold should be biocompatible, osteoconductive and osteoinductive. The scaffold allows cells to attach and proliferate and to form an extracellular matrix. It should have an open and interconnected pore structure (with a porosity of > 90%) that allows nutrients to



penetrate into the scaffold *in vitro* and then vascularisation to occur *in vivo*.⁶ It should also degrade at a suitable rate to match the rate of tissue formation.⁷ However, micron-sized hydroxyapatite (HA) particles might lead to a low resorbability and fragile constructs.⁸ Overcoming the constraints in applying calcium phosphate ceramics as well as enhancing their bio-reactivity has become the latest concern in biomaterials. Thereby, unique advantages of nanotechnology can be explored. Nanotechnology can help improve the bio-reactivity of HA as a bone constituent, thus increasing the biomaterial-bone interface. The chemico-physical and biological properties of HA are strictly related to their dimensions, the regulation of which requires a high level of chemical control at the nanoscale. Because of their composition, structure and their nano-dimensional and -morphological likeness to bone crystals, biomimetic HA synthetic crystals are believed to be a great hope for orthopaedics. In comparison to particle-sized traditional materials, nanostructured biomimetic materials show a better performance, resulting from their large surface-to-volume ratio and rare chemical and electronic synergistic effects.⁹

In addition, the bone-mineral phase with carbonated HA crystals of a length of 100 nm, a width of 20–30 nm and a thickness of 3–6 nm results in a biomimetic need for synthesising with similar nanoscale dimensions. Moreover, a low crystallinity, a non-stoichiometric composition and crystalline disorder as well as the presence of carbonate ions in the crystal lattice are indicated. The good biological quality of HA, for example non-toxicity, its lack of inflammatory and immunity response as well as high bio-resorbability are increased even more by decreasing the crystallinity of synthetic apatite.

Size and crystallinity of the HA particles are important with regard to stability and inflammatory response in collagen-HA implants. In bones, carbonate-substituted HA crystals are mineralised in small gaps of the collagen fibrils and have been found to have a length of 50 nm, a width of 25 nm and a thickness of 2–5 nm.¹⁰ As the local source of calcium to the surrounding cells, they become integrated with collagen fibrils, thus achieving the high mechanical properties of bone. Nonetheless, small sintered particles of a size of less than 1 μm have been warned against when used in bone implants. Reasons for this are their high inflammatory response¹¹ and their cell toxicity *in vitro*.¹² Contrarily, smaller plate-like particles (200 nm x 20 nm x 5 nm) have been shown to create increased osteoblastic adhesion and proliferation when compared to larger HA particles, such as carbonate-substituted HA particles, unsintered and produced at physiological temperatures.¹³

A nanocrystalline HA in a silica-gel matrix (NanoBone, ARTOSS) with a very large internal surface

(about 84 m²/g) was used in this study.¹⁴ In addition, nanocrystalline HA showed faster bone formation and resorption in animal studies when compared to commercially available HA, tricalcium phosphates and gelatine sponges¹⁵, resulting from their porous structure, rough surface and interconnecting pores of 10–20 nm of the silica gel.

Signs of osteoconduction and osteoinduction,¹⁶ high biocompatibility and angiogenic response¹⁷ became visible in histological and immunohistochemical investigations after implantation. Furthermore, it was postulated that nanocrystalline HA has osteoconductive and biomimetic properties and is integrated into the host's physiological bone turnover at a very early stage.¹⁸ Newly formed bone of limited quantities was found at three months of healing¹⁹, while new trabecular bone was found at six month of healing²⁰ in recent histological investigations of human biopsies from sinus augmentations with nanocrystalline HA.

The aim of the present study was to compare the clinical outcome of and radiographic bone changes in augmented ridges utilising a synthetic NanoBone block versus an allograft bone block, and to investigate histologically the success of a synthetic NanoBone block versus an allograft bone block for augmentation.

Materials and methods

Subject selection

Twenty patients ranging between the ages of 35 and 55 were included in this study. All patients selected for this study required bone augmentation procedures because of severe alveolar ridge atrophy in the posterior mandible, either unilateral or bilateral, with standing anterior teeth. Furthermore, the participants were healthy and free from any systemic conditions. Other than any systemic condition that might have affected bone formation, osseointegration or soft-tissue rehabilitation (such as immune systemic disease, diabetes, pulmonary diseases, renal and cardiovascular diseases, and blood diseases), exclusion criteria were malignant neoplasias, hepatitis, drug abuse, chemotherapy and radiotherapy. In addition, smokers were excluded from the study. All the participants were informed about the study and completed an informed consent form. The participants were divided randomly into two groups of ten patients. The first group (group A) underwent ridge augmentation using a NanoBone block and the second group (group B) underwent ridge augmentation using an allograft bone block.

AD



100% SAFETY DOCTOR - PATIENT GOAL REACHED

Since our beginnings, we have always been focused on quality and innovation toward the battle against cross-contamination and infections.

In the last 20 years, we have ensured safety and protection to you and your patients, with advanced and reliable products. Tools that represent the ideal solution for who is operating in dentistry, implantology/oral surgery and general surgery.

With Omnia sure to be safe.

Surgical Line **Safety Line** **MAXI**

IDS 2013 Cologne, 12-16.03.2013
Visit us!
Hall 4.1 Stand C088- D089

OMNIA

OMNIA S.p.A.
Via F. Delnevo, 190 - 43036 Fidenza (PR) Italy
Tel. +39 0524 527453 - Fax +39 0524 525230
VAT. IT 01711860344 - R.E.A. PR 173685
Company capital € 200.000,00
www.omniaspa.eu

Preliminary subject evaluation

A preliminary clinical and radiographic evaluation (panoramic tomogram and CT scan) was performed. The results, along with the dental casts, confirmed posterior mandibular atrophy.²¹

Study materials

A NanoBone block (Artoss Co) was used for group A and an allograft bone block (Fisiograft, Ghimas) was used for group B. The tiologic dental implant system (Dentaurum Implants) was used for both groups in a two-stage procedure.

Ridge augmentation

Antibiotic prophylaxis (1 g Augmentin, orally) was administered to all patients two hours preoperatively. After preoperative medication, posterior mandibular ridge augmentation was carried out under local anaesthetic combined with a sedative (5 mg midazolam, intramuscularly).²¹

Surgical procedures

Kazanjian's vestibuloplasty was performed according to the method described by Khoury et al.²² After exposure of the bone surface, bleeding points were created in the vestibular sulcus using a fine round bur.²³ The bone block was adapted to the ridge using a scalpel. Once the blocks were flush with the ridge, it was affixed by a two-hole micro-plate and two micro-screws, resulting in rounded edges. A lingual pedicled flap was then reflected and sutured to the periosteum as far as possible in the vestibule to prevent relapse of the muscle attachment, representing a second-layer closure over the grafted area.²²

A Systemic antibiotics (1 g Augmentin twice a day for ten days) and non-steroidal analgesic (400 mg Ibuprofen twice a day for three days) were administered to both groups post-operatively. The participants were advised to follow a soft-food diet for two weeks and an appropriate oral hygiene routine, including rinsing with 0.2% chlorhexidine digluconate twice a day. Sutures were removed seven to ten days after the surgical procedure. The participants attended a clinical examination every week in the first month after surgery, and twice in the second and third months. They were not permitted to use removable dentures. Radiographic assessment (panoramic tomogram and CT scan) was carried out after six months.

Efficacy of the ridge augmentation

Standardised measurements for each patient were recorded before and after ridge augmentation.²⁴ An acrylic reference stent was fabricated for each patient to assist in standardisation of all measurements. The stent was designed to cover the occlusal surface of the teeth adjacent to the augmentation site. Each stent had predetermined measurement points to determine the

alveolar height using a periodontal probe on the occlusal side and to determine the alveolar width using a calliper on the buccal and lingual sides.

Assessment of alveolar ridge dimensions by CT

Bone induction was compared by CT scans before (baseline) and six months after ridge augmentation. The holes in the stent were filled with gutta-percha to provide radiopaque landmarks to indicate the locations for comparative ridge measurements. The image with the clearest gutta-percha imprints was selected for measurement of the buccal and lingual aspects. The measurements were performed using a software measurement tool.²⁴ Measurements were taken at baseline and six months after augmentation.²⁵ The density of the newly induced bone was assessed using CT with the aid of a standard density block. The change in bone gain or bone loss after treatment is the six-month measurement minus the baseline measurement. Alveolar ridge dimensions were assessed by measurements.²⁶ Alveolar height was determined with a periodontal probe, measuring the distance from a fixed point on the occlusal surface of the stent to the crest of the alveolar ridge. Measurements were taken with the probe placed perpendicular to the ridge. The change in bone height after treatment is the six-month measurement minus the baseline measurement. Buccolingual width measurements for each patient were recorded using a calliper device, which was sterilised properly and used for each patient. The change in bone width after treatment is the six-month measurement minus the baseline measurement.

Histopathological examination

During the placement of the dental implant, full-thickness bone core biopsies were obtained by a trephine (Figs. 1a & b). The biopsies were immediately stored in 10% buffered formalin, decalcified in EDTA and processed for haematoxylin-eosin stain and Masson's trichrome.²¹ Each specimen was evaluated histologically.

Editorial note:

To be continued with results, discussion and conclusion and an extensive photo documentation in implants 2/2013.

A complete list of references is available from the publisher.

_contact

implants

Dr Omar Soliman

PhD candidate Perioimplant dentistry

Tel.: +20 1009634358, +20 1201005457
Omar.Soliman77@yahoo.com

Prof. Dr Mohamed Nassar

Professor of Perioimplant dentistry
Faculty of Dentistry, Tanta University, Egypt.

Tel.: +20 1121522221
Prof_Nassar@yahoo.com

43RD

INTERNATIONAL ANNUAL CONGRESS OF THE DGZI



"Practice-Oriented Implantology"

October 4–5, 2013 // Berlin, Germany // Hotel Palace Berlin

Congress President // Prof. Dr. Dr. Frank Palm/DE
Scientific Director // Dr. Roland Hille/DE

Gold Sponsor:



Silver Sponsor:



Bronze Sponsor:



FAX REPLY // +49 341 48474-390

Please send me further information on the
43RD INTERNATIONAL ANNUAL CONGRESS OF THE DGZI
on October 4–5, 2013, in Berlin, Germany.

Office Stamp

Applications of hollow osteotomes in dental implantology

Authors Dr Rolf Vollmer, Dr Mazen Tamimi, Dr Rainer Valentin, Dr Suheil Boutros & Dr Martina Vollmer, Germany

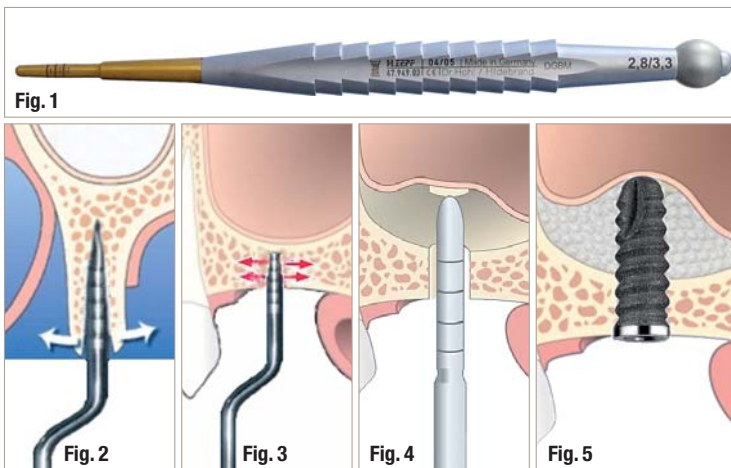


Fig. 1 Example of an osteotome.
Fig. 2 Bone expansion (splitting) by osteotome.
Fig. 3 Bone density via osteotome.
Fig. 4 Indirect sinus lift according to Summers' osteotome technique.
Fig. 5 Indirect sinus lift according to Summers' augmentation and implant insertion.

Introduction

In the early days of implant dentistry, the main objective was to achieve a good stability for removable dentures. However, the range of indications has changed quickly. Today, patients are treated although they have thin crestal bone or a poor bone quality. Poor bone quality is found in the categories D3 and D4 (according to Carl E. Misch, Table 1). In contrast to the lower anterior region, which often corresponds to category D1, categories D3 and D4 are found mainly in the posterior maxilla, but also in the premaxilla (Table 1, green marks).

Materials and methods

Bone of the qualities D3 or D4 can be improved and is thus made available for dental implantation. Osteotomes (Fig. 1) of different shapes were developed to help enhance bone density. They compress the cancellous bone and thus provide good primary

stability of an endosseous implant (Fig. 2). This way, the bone quality can be improved by one category.

The primary stability is a "sine qua non" and necessary for a strong bone-implant bond (osseointegration). Further applications of specially modified osteotomes are splitting or bone spreading in cases of single-tooth implantation (Fig. 3). Additionally, osteotomes can be used in indirect sinus lift procedures (Figs. 4 and 5). Note that the implant screw shown in Figure 5 is a sample drawing (source: Impla, Schütz Dental GmbH).

All methods using osteotomes depend on the initial drilling of a pilot hole with a minimal diameter (2 mm). Drilling the pilot hole always goes along with a loss of bone mass, which only rarely is available in abundance. For this reason, hollow osteotomes have been developed, which combine the advantages of conventional osteotomes with the simultaneous removal of bone at the implant site. Additional bone can also be harvested easily via hollow osteotome (Figs. 6a-c) in other appropriate sections of the jaw.

The authors have already published this bone extraction technique with a bone trephine drill. In this way, a circular hole is drilled into the jaw bone. A bone cylinder is stuck inside the drill or remains in the jaw. As a result, a cylindrical piece of bone can be removed for later use, e.g. as autogenous augmentation material. The design of the trephine drill (Figs. 7a and b) requires a relatively solid wall thickness, so only a bone cylinder which is relatively small when compared to the outer diameter of the trephine drill can be applied. Furthermore, there are disadvantages and substantial difficulties in positioning that

arise when placing the saw tooth portion of the trephine drills head on an uneven surface. The drill can drift off when starting to move. Therefore, it is very difficult to create the implant site exactly in the desired location. Conditional remedies here are the use of drill sleeves, a switch of the engine to reverse turn and a higher speed. However, an excessive heat production and the associated potential damage of the bone is a disadvantage.

In the field of dental implantology, it is important that an accurate hole is placed exactly at the desired position in the jaw bone in order to insert an implant. The desired accuracy cannot be achieved with a trephine drill. Furthermore, significant inaccuracies can occur and injury to the soft and hard tissue can be caused when starting the drill as described previously.

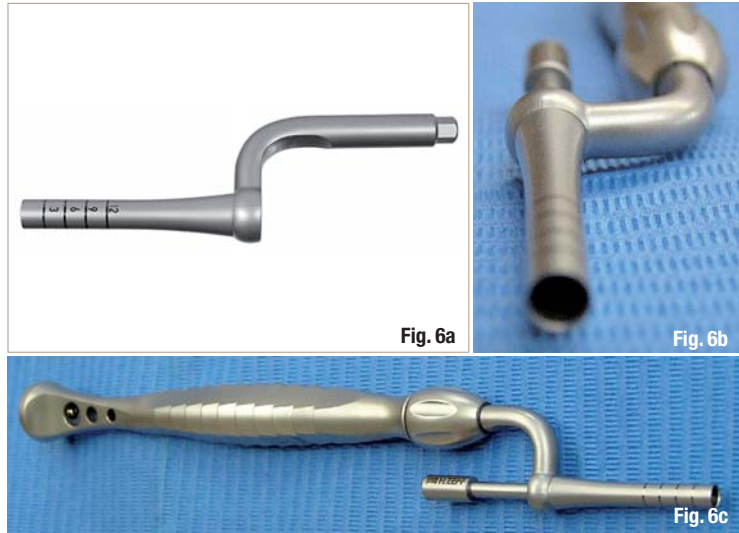


Fig. 6a-c_Hollow osteotome (Design H. Zepf).

Bone density	Hounsfield units	Upper front	Upper posterior	Lower front	Lower posterior
D1	>1,250	0	0	3	6
D2	850-1,250	25	10	66	50
D3	350-850	65	50	25	46
D4	150-350	10	40	3	1
D5	<150				

Table 1_Bone densities in Hounsfield units. Occurrence and frequency of bone density (in %) in the jaw area, according to Carl E. Misch.

Results

The task ahead was to develop an instrument for the removal of bone without causing any injury. In particular, an implant osteotomy exactly at the desired position was to be achieved with the greatest possible accuracy and safety and without bone or mucosal damage. It should also be noted that this instrument must be applicable in navigated implantation procedures. The newly developed instrument, which was named hollow osteotome, is designed in the manner of a punch and has an operating element, which essentially is a hollow cylinder. At its distal end, the cylinder has a peripheral cutting edge. The cutting edge of a hollow os-

teotome like this can be seated precisely in the desired implant position (Figs. 8a-c). Note that the larger bone core is formed with an outer diameter of the instrument smaller than the trephine drill site. The hollow osteotome succeeds in creating a "standard-implant-cavity" with an outer diameter of 3 mm and the extraction of a bone cylinder with a diameter of 2.4 mm.

The hollow cylinder can be held exactly at the preferred position since it is not driven to rotate. Therefore, it can be placed exactly at the desired point for the respective cavity preparation and/or bone removal. Also, the implant axis can be specified exactly. The sharp edges of the hollow instrument can be pushed



Fig. 7a

Figs. 7a and b_Trephine drill. Fig. 8a-c_Implant cavity preparations (a) via trephine drill (b) and hollow osteotome (c).

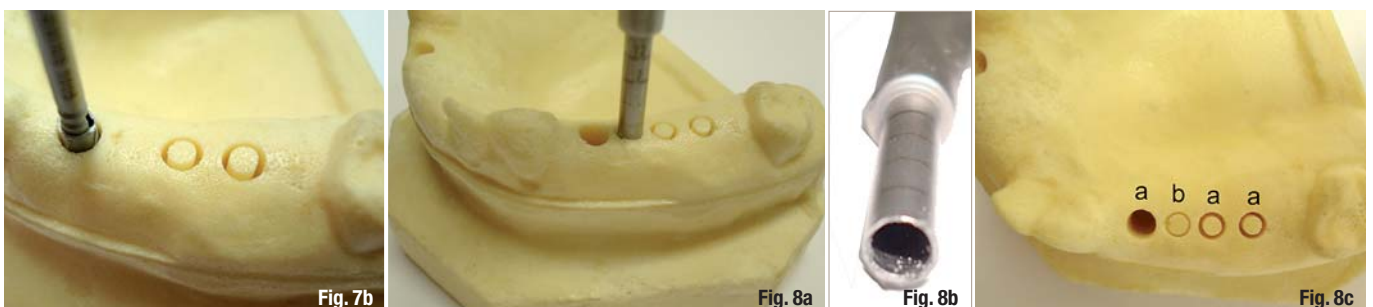


Fig. 9_Osteotome set (Design H. Zepf).

Figs. 10a-c_Bone harvesting via hollow osteotome.

Fig. 11_Transmucosal punching and simultaneous preparation of a bone cavity for dental implantation.

Figs. 12_Application of hollow osteotomes in navigated implantology in order to avoid overheating by drilling with reduced irrigation.

Figs. 13a-c_Preparation and transformation of an extraction site for the removal of autologous bone and simultaneous immediate implant placement.

Fig. 14a-c_Application of the indirect sinus lift technique by hollow osteotome: a) extraction of the bone core; b) pushing in the cortical plate; c) augmentation and simultaneous implantation.

Fig. 15_Final X-ray.

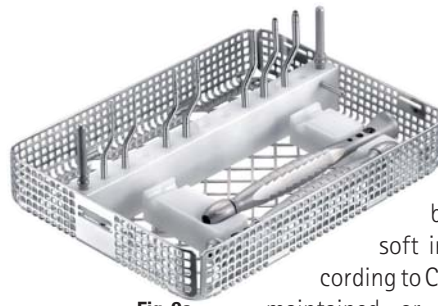


Fig. 9a

manually or inserted in the alveolar bone with the aid of gentle taps on the proximal end of the working element because the jaw bone is relatively soft in some areas (D3/D4 bone, according to C.E. Misch). The implant axis can be maintained or corrected. Larger hollow osteotomes are available for bigger implant diameters. Further additional compression of the surrounding bone can be done with a full thickness osteotome.

On the one hand, the cutting edge helps to keep and fix the osteotome in the desired position. On the other hand, it facilitates pushing or driving the osteotome into the jaw bone. When inserting the osteotome into the alveolar bone, the plates are displaced outwards.

As a result, the surrounding bone is condensed. A bone core penetrates into the lumen of the hollow cylinder. Upon removal, this bone cylinder inside the cutting element of the osteotome usually remains in the instrument and can then be used as an autologous bone graft. As there is no rotation of the hollow cylinder while seated and inserted into the jaw bone, no injury to the soft tissue or jaw bone can arise.

In addition, the cutting edge of the instrument is bevelled to the distal end of its outside wall. In this way, a three dimensional chisel or wedge-like circumferential distal working end results. This facilitates the introduction of the osteotome operating element into the jaw bone.

Markers (Fig. 6a) are arranged around the outside of the operating element, which show the distance to the distal end of the working element on a scale. Thus, the user is provided with information of how far the operating element of the hollow osteotome has already penetrated into the jaw bone.

The wall thickness is significantly lower than in the known trephine drills because of the non-rotating application. Reduced or no loss of bone material is achieved and a bone cylinder of a larger diameter can be removed by using the osteotome. The wall thickness of the hollow cylinder instrument is less than 0.3 mm (Fig. 6b).

This version of the osteotome is designed as a two-piece entity, so that the handle can also be used for other osteotomes. This means that the number of instruments (Fig. 9) can be kept relatively small since only the operating element has to be exchanged.

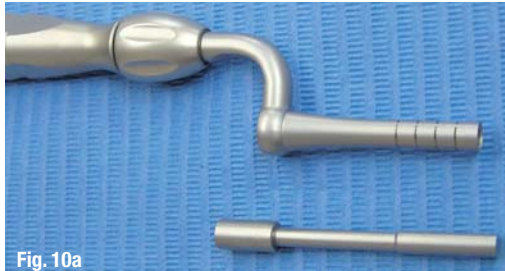

Fig. 10a



Fig. 10b

Fig. 10c

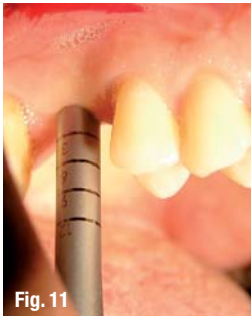

Fig. 11

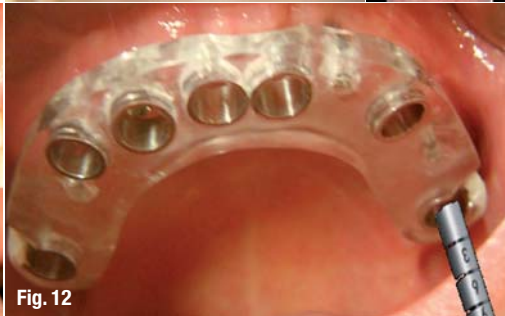

Fig. 12

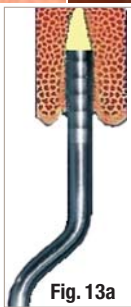

Fig. 13a

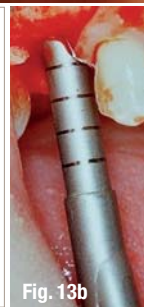

Fig. 13b

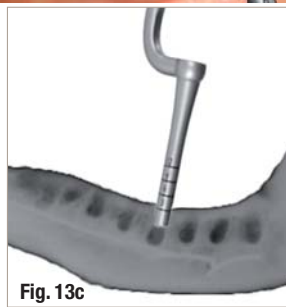

Fig. 13c

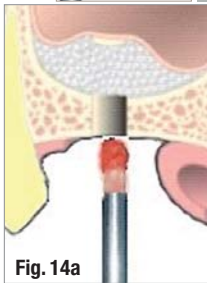


Fig. 14a

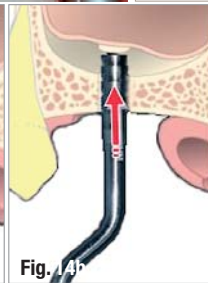


Fig. 14b

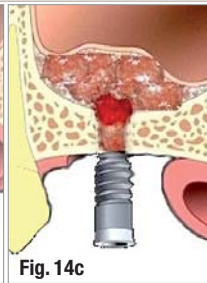


Fig. 14c

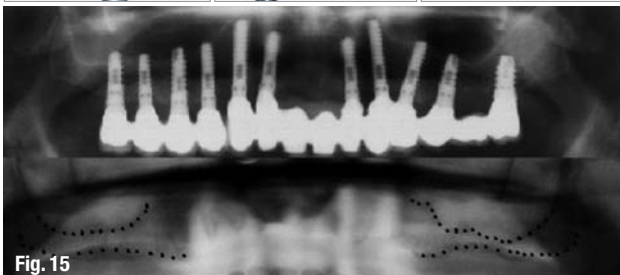


Fig. 15

Collagens and suture materials for dental surgery

In order to push the bone material out of the operating element, a special ejector has been developed which can be inserted into the lumen of the working element. In this way, the bone material can be removed from the lumen of the hollow osteotomes easily and without damage. The bone material then is ready to be used for autogenous augmentation (Figs. 10a–c). Since there is a special indication for the application of osteotomes in the posterior jaw bone at a bone quality of D3 and D4, the operating element was formed with an angle, thus designed to be universally applicable both in the front and in the posterior jaw regions.

Indications for use of the hollow osteotomes

1. Bone quality D3 or D4
2. Mucosal punch (Fig. 11)
3. Preparation of a bone cavity for a dental implant
4. Preparation of a bone cavity using a navigation template (Fig. 12)
5. Preparation and transformation of an extraction site for immediate implant placement (Fig. 13)
6. Preparation of a bone cavity and simultaneous removal of autologous bone material (Figs. 10a–c)
7. Preparation of a bone cavity with simultaneous compression (improvement of bone quality) of the surrounding bone and bone harvesting
8. Preparation and application during indirect sinus lift procedures (Figs. 13a–c and 14a–c)

Discussion

Maximum autologous bone harvesting from the jaws, performed in a minimally invasive surgical procedure, is an advantage of the above-presented instrument. Another advantage is the low risk of overheating the bone compared to rotating instruments, particularly when using navigation templates due to non-existent irrigation.

Risks and side effects

Vertigo may occur in the application of traumatising instruments in exceptional cases of a pre-damaged patient. The subsequent and relatively simple non-invasive treatment is performed by an ENT doctor. However, side effects can occur in all dental procedures, even in treatments with turbines, as well as in the leisure sector, for example with mountain bikers. Because these side effects occur only rarely, they are outweighed by the benefits of the method described above.

Summary

Hollow osteotomes broaden the spectrum of autologous bone removal, especially from the jaw, while the bone structure is condensed simultaneously. They have proved effective in the minimally invasive removal of autologous bone at the same time as an exact preparation and quality improvement of the local bone of a density of D3 or D4 (Carl Misch).

contact

implants

Dr. Rolf Vollmer
Nassauer Str. 1
57537 Wissen, Germany

Tel.: +49 2742 968930
Fax: +49 2742 2547
info.vollmer@t-online.de



PARASORB Sombrero®
Absorbable Membrane-Cone



PARASORB RESODONT®
Absorbable collagen membrane



PARASORB® Cone
PARASORB® Cone Genta
Collagen-cone for the treatment of extraction sockets



RESORBA® sutures
The optimal suture for each indication

2013-01 A0019

RESORBA®
REPAIR AND REGENERATE

RESORBA Medical GmbH
Am Flachmoor 16, 90475 Nürnberg, Germany

Tel. +49 9128 / 91 15 0
Fax +49 9128 / 91 15 91
www.resorba.com

SILVERSPONSOR
OF THE **DGI**

From orthopaedics to dental implantology

Author_Dr Suheil M. Boutros, USA

Introduction

Trabecular Metal (Zimmer Dental), a porous (80%) tantalum biomaterial with a trabecular structure for 3-D bone in-growth, has been used for over a decade in orthopaedic surgery.¹ As a result of great success in orthopaedics, a new tapered, threaded titanium dental implant with a Trabecular Metal midsection was developed and tested in animal models, followed by human trials. The current findings suggest that Trabecular Metal implants with both on-growth and in-growth (due to active bone formation in the Trabecular Metal pores) provide good bone anchorage during early healing when placed in extraction sockets. The preliminary pilot study demonstrated that immediate loading of Trabecular Metal implants with non-occluding provisional restorations within 48 hours and definitive loading of the implants with fully occluding restorations seven to 14 days later in selected patients was safe and effective over the six-month follow-up period.²

Porous tantalum material has the ability to facilitate osseointegration and provide a substrate for cell adhesion that makes it desirable for use in orthopaedic surgery.¹ In a dog study, Trabecular Metal implants were compared with standard titanium implants (control). Osseointegration of control implants was achieved via on-growth, whereas the Trabecular Metal implants achieved osseointegration via both on-growth around the threaded sections and in-growth through the pores of the Trabecular

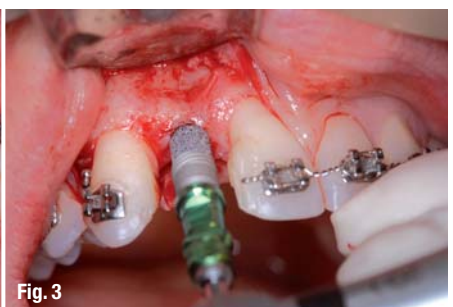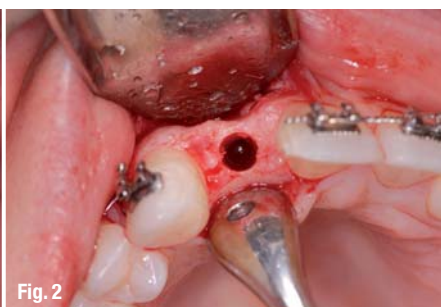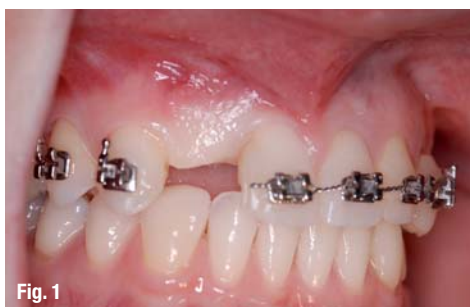Metal shell. The ISQ values for the Trabecular Metal implants illustrated an increasing trend over a 12-week healing period, whereas the ISQ values for the control implants did not demonstrate any such trend—although the values were greater than 60. The histopathological findings indicated no evidence of acute inflammation for any Trabecular Metal or control implant.²⁻³

In a proof of principle study, two investigational sites with up to 20 subjects for each site, with up to two implants per subject (total of 36 implants), were examined. Implant sizes were 4.7 and 6 mm in diameter and 10, 11.5 and 13 mm in length, with posterior indication only. Healthy, sufficient bone volume and primary stability (>35 Ncm) were the inclusion criteria. The prosthetic treatment followed the One Abutment—One Time restoration protocol (Zimmer Dental), with immediate provisionalisation within 48 hours and the final restoration at or before two weeks post-implant placement. The six-month follow-up with a survival rate of 97.2% was comparable to the 97.9% survival rate of immediately loaded molar implants reported in a systematic review and meta-analysis of seven studies with 188 implants by Atieh et al. (2010). Within the limitation of the preliminary pilot study, immediate loading of the Trabecular Metal implants with non-occluding provisional restorations within 48 hours and definitive loading of the implants with fully occluding restorations seven to 14 days later in selected patients was safe and effective over the six-month follow-up period.

Fig. 1 Pre-op view of missing upper right lateral incisor.

Fig. 2 Osteotomy.

Fig. 3 Engaging the Trabecular Metal portion of the implant allows for early bone in-growth.



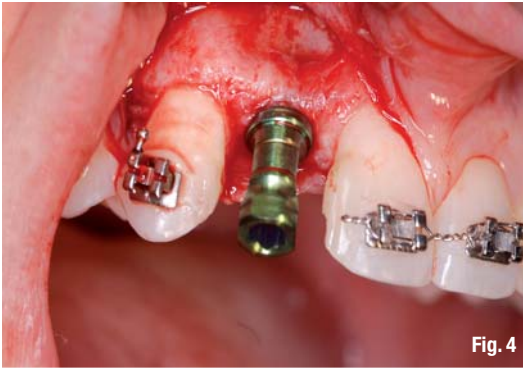

Fig. 4

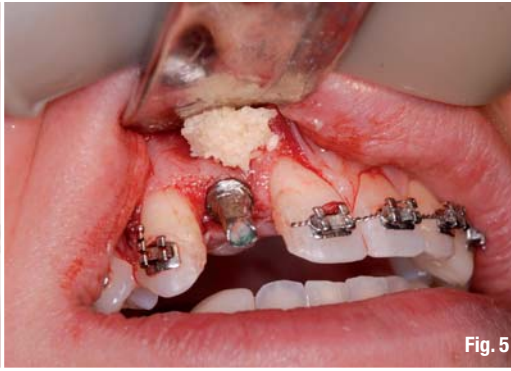

Fig. 5

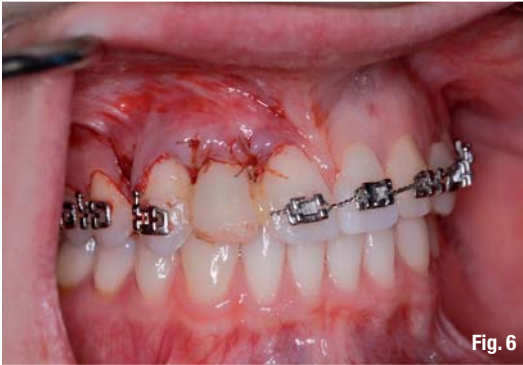

Fig. 6

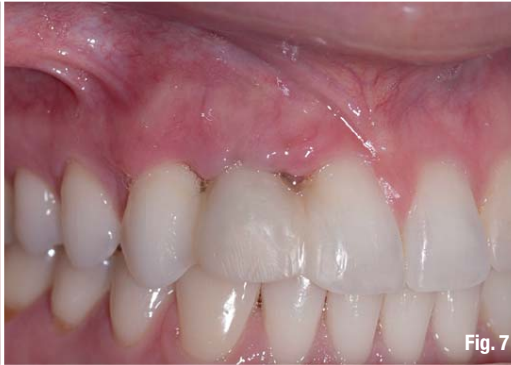

Fig. 7

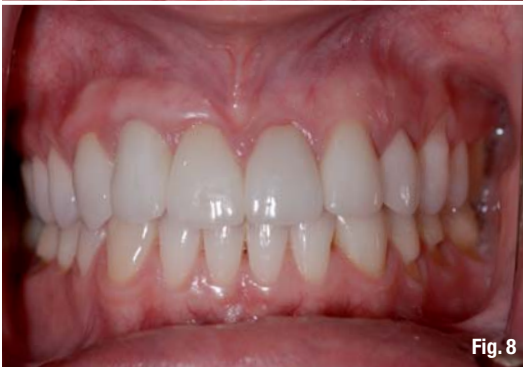

Fig. 8

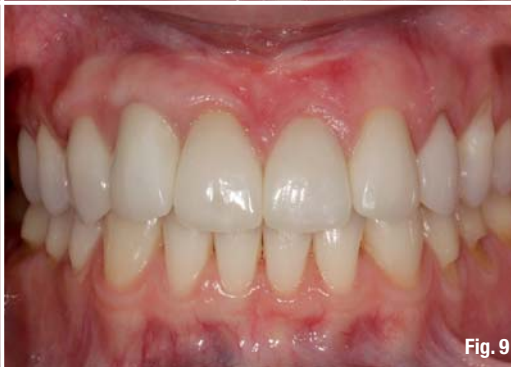

Fig. 9

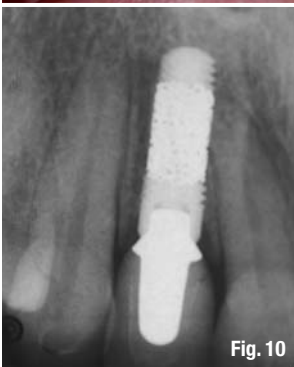

Fig. 10

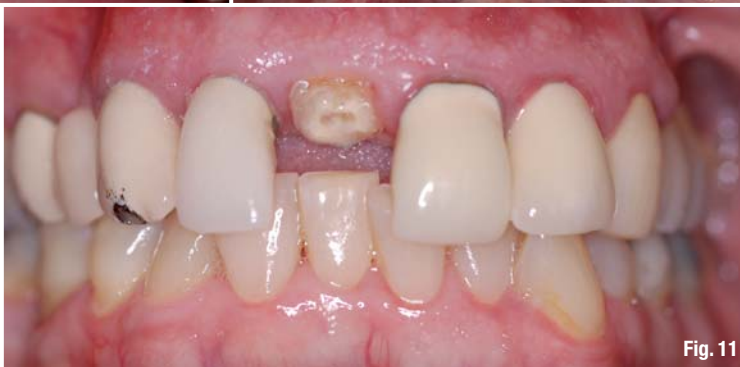

Fig. 11

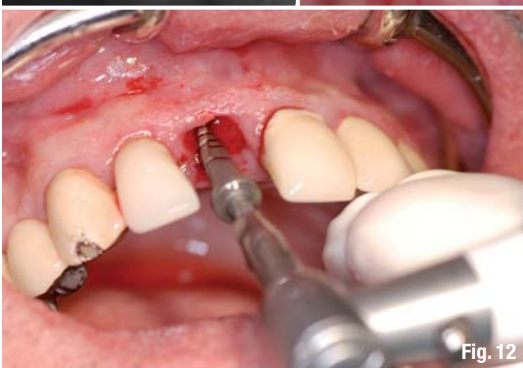

Fig. 12



Fig. 13

Fig. 4_ The coronal microgrooves engage the cortical bone and allow for better primary stability.
Fig. 5_ Prepared transfer coping in place with the Puros Cortico-Cancellous Particulate Allograft.
Fig. 6_ Non-occluding provisional restoration with the flap suture using chromic gut suture.
Fig. 7_ Ten days post-implant placement.
Fig. 8_ Final crown three months post-implant placement.
Fig. 9_ Final crown six months post-implant placement.
Fig. 10_ Radiograph six months post-loading.
Fig. 11_ Fractured, non-restorable central incisor.
Fig. 12_ The final 2.8/3.4 x 13 mm drill.
Fig. 13_ A Trabecular Metal implant of 4.1 x 13 mm.

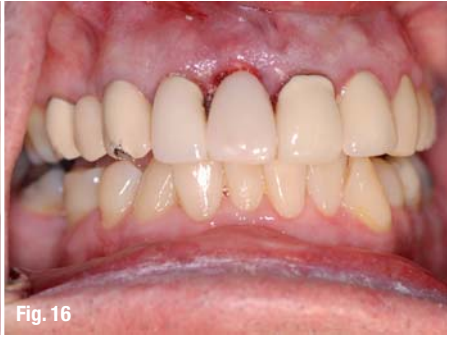
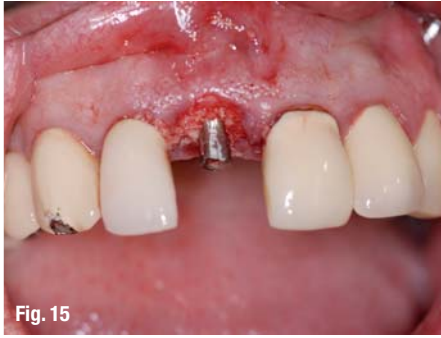
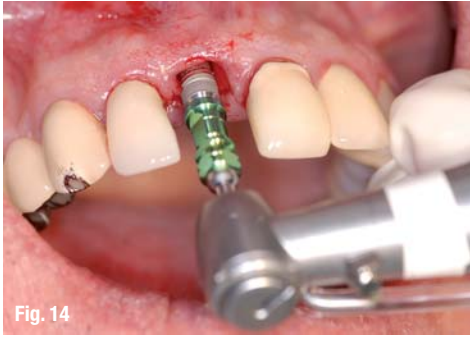Fig. 14 A Trabecular Metal implant placed in the extraction socket.

Fig. 15 Prepared transfer coping with Puros Cortico-Cancellous Particulate Allograft filling the critical gap.

Fig. 16 Non-occluding provisional restoration at the time of implant placement.

Case presentation: Patient 1

A 30-year-old female patient without medical contra-indication for implant therapy presented with a congenitally missing maxillary right lateral incisor. The clinical and radiographic examination demonstrated that the patient was a good candidate for Trabecular Metal implant placement and restoration (Fig. 1). The patient was given the option of implant placement and immediate non-occlusal loading as an alternative to a staged approach if the implant did not achieve good primary stability.

Surgical treatment

At the surgical appointment, following administration of local anaesthesia, a full thickness flap was reflected. The osteotomy was performed using a pointed starter drill, followed by a 2.3 mm twist drill. It was determined that the bone density was D2-3. Using a soft-bone drilling protocol,⁶⁻⁷ the next drill was used. No bone tap drills were used in order to ensure implant stability (Fig. 2). The fixture transfer coping was prepared to support a non-functional provisional crown. The deficient alveolar ridge was augmented using an allograft (Puros Cortico-Cancellous Particulate Allograft, Zimmer Dental—a mix of 70% cortical bone and 30% cancellous bone; Figs. 5 & 6). After implant placement, the patient was given post-surgical instructions, including the use of 0.12% chlorhexidine gluconate (Peridex, Procter & Gamble) three times a day and was prescribed 500 mg of amoxicillin (every six hours for seven days). The patient was seen for a follow-up visit ten days later and healing was uneventful (Fig. 7).

Prosthetic treatment

After allowing the soft tissue to mature for four weeks, the final fixture-level impression was taken and a final cast custom abutment was used to support a porcelain-fused-to-metal crown (Fig. 8).

Follow-up and maintenance

After six months, the patient returned for a follow-up visit. The clinical and radiographic exam demonstrated that the implantation had been a great success (Figs. 9 & 10). The patient was placed on a six-month recall to maintain the implant and the restoration properly.

Case presentation: Patient 2

A 65-year-old male patient without medical contra-indication for implant therapy presented with a fractured maxillary right central incisor. The clinical and radiographic examination demonstrated that the patient was a good candidate for the extraction of the tooth and immediate implant placement (Fig. 11). The patient was given the option of immediate implant placement and immediate non-occlusal loading as an alternative to a staged approach if the implant did not achieve primary stability at > 35 Ncm insertion torque.

Surgical treatment

At the surgical appointment, following administration of local anaesthesia, a flapless, atraumatic extraction of the maxillary right central incisor was performed using periostomes. The osteotomy was performed using a pointed starter drill, followed by a 2.3 mm twist drill. It was determined that the bone quality was D2-3. Using a soft-bone drilling protocol, the next drill used was 2.8, 2.8/3.4 x 13 mm. No bone tap drills were used in order to ensure implant stability (Fig. 12). A Trabecular Metal implant of 4.1 mm in diameter and 13 mm in length was inserted. The insertion torque exceeded 35 Ncm (Figs. 13 & 14). The fixture transfer coping was prepared to support a non-functional provisional crown. The critical gap between the extraction socket and the implant was grafted using an allograft (Puros Cortico-Cancellous Particulate Allograft; Figs. 15 & 16).

Prosthetic treatment

After allowing the soft tissue to mature for four weeks, the final fixture-level impression was taken and a final cast custom abutment was used to support a porcelain-fused-to-metal crown (Fig. 17).

Follow-up and maintenance

After six months, the patient returned for a follow-up visit. The clinical and radiographic exam demonstrated that the implantation had been a great success (Figs. 18 & 19). The patient was placed on a six-month recall to maintain the implant and the restoration properly.

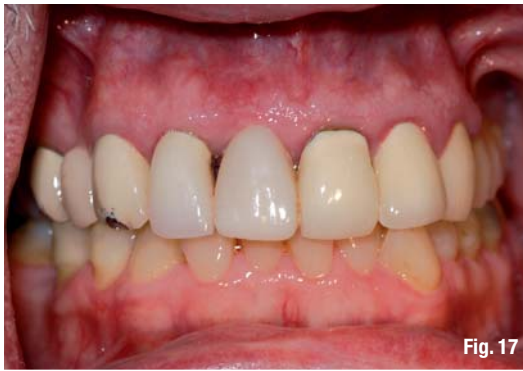

Fig. 17

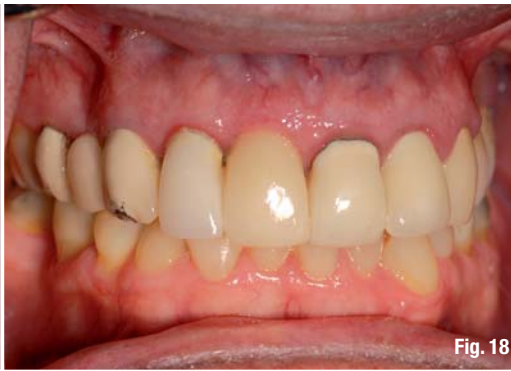

Fig. 18

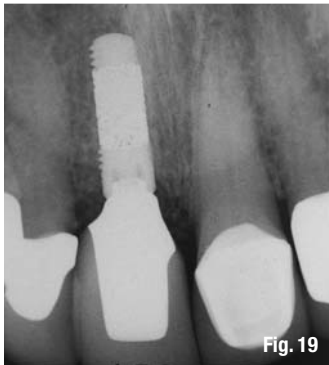

Fig. 19

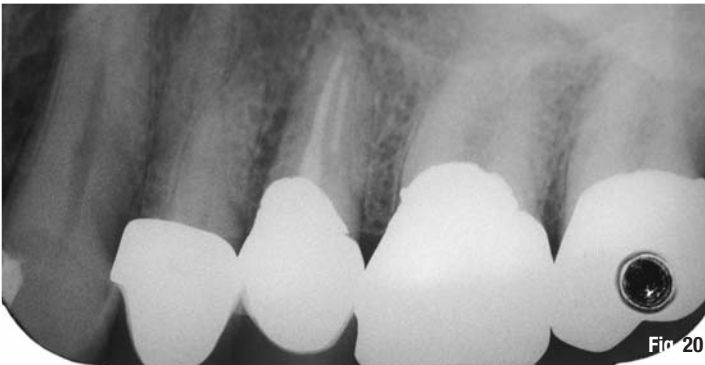


Fig. 20

Fig. 17_Four weeks post-implant placement.

Fig. 18_Final restoration six months post-implant placement.

Fig. 19_Final radiograph six months post-implant placement.

Fig. 20_Pre-op radiograph of the fractured second premolar.

Fig. 21_Atraumatic extraction.

Fig. 22_A Trabecular Metal implant of 4.1 x 13 mm.

Fig. 23_A Trabecular Metal implant placed in the extraction socket.

Fig. 24_Puros Cortico-Cancellous Particulate Allograft.

Fig. 25_A screw-retained provisional crown at the time of implant placement.

Fig. 26_Two weeks post-implant placement with the provisional crown in place.

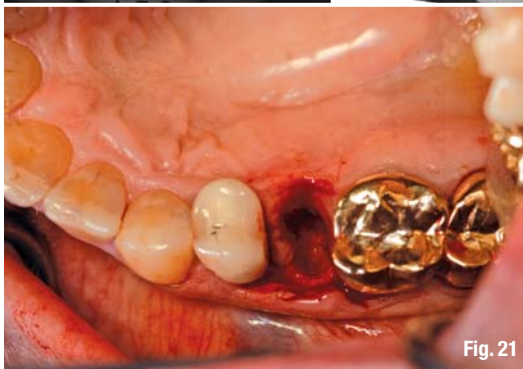

Fig. 21

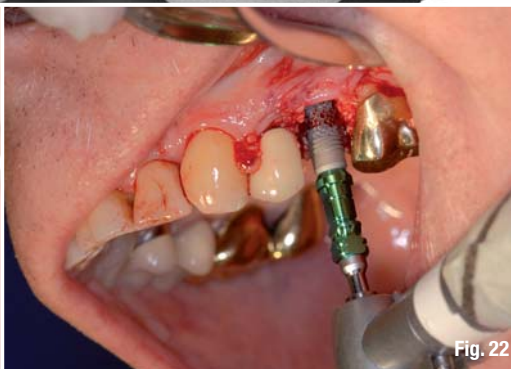

Fig. 22

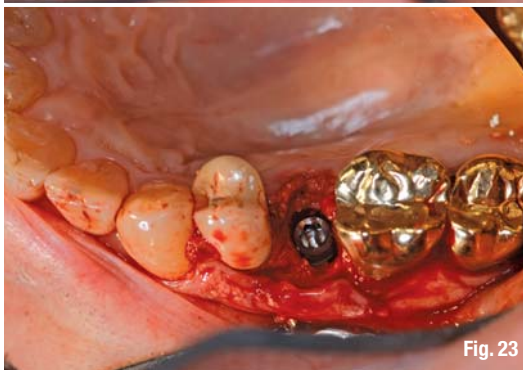

Fig. 23

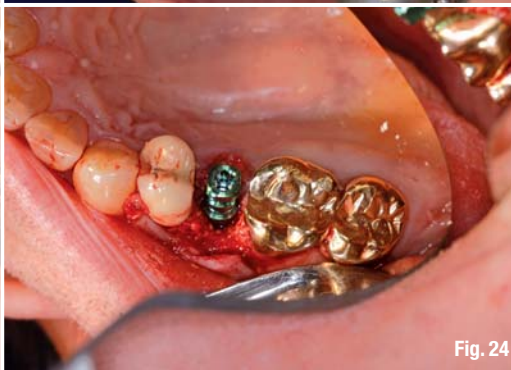

Fig. 24

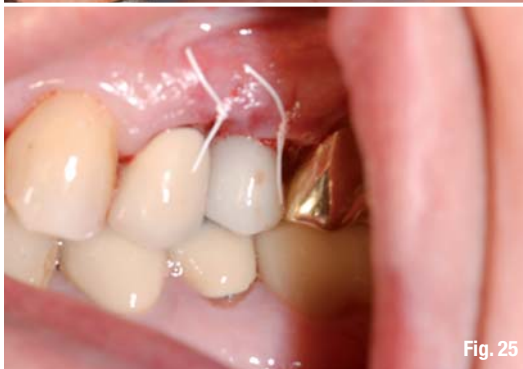

Fig. 25

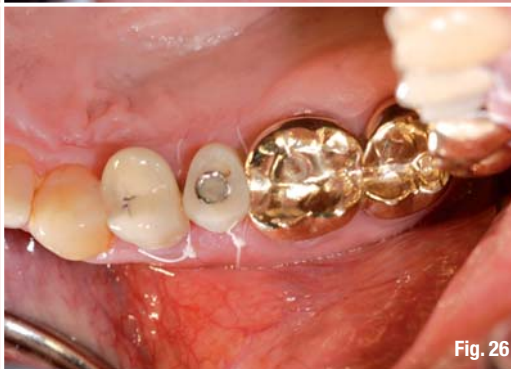
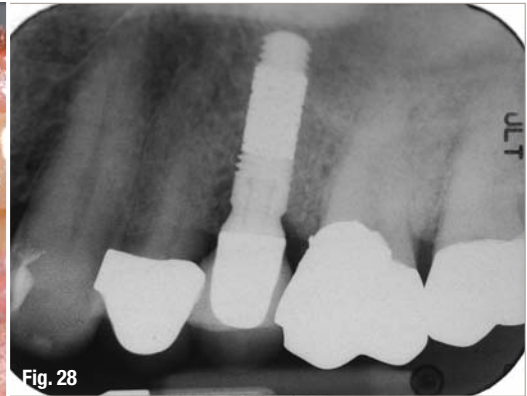
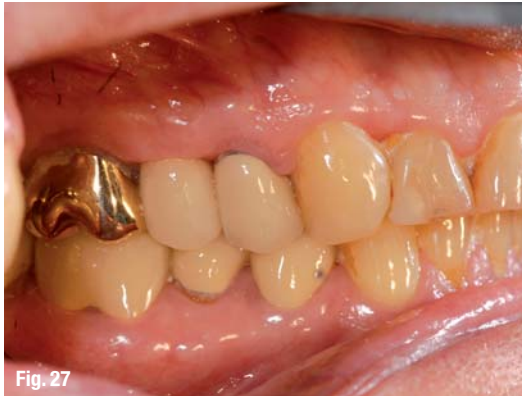Fig. 26

Fig. 27 The final restoration six months post-implant placement.
Fig. 28 The radiograph six months post-implant placement shows the stable bone level around the apical and coronal aspects.



Case presentation: Patient 3

A 70-year-old male patient without medical contra-indication for implant therapy presented with a fractured maxillary left second premolar. The clinical and radiographic examination demonstrated that the patient was a good candidate for the extraction of the tooth and immediate implant placement (Fig. 20). The patient was given the option of immediate implant placement and immediate non-occlusal loading as an alternative to a staged approach if the implant did not achieve primary stability at > 35 Ncm insertion torque.

Surgical treatment

At the surgical appointment, following administration of local anaesthesia, a flapless, atraumatic extraction of the maxillary left second premolar was performed using periostomes (Fig. 21). The osteotomy was performed using a pointed starter drill, followed by a 2.3 mm twist drill. Due to maxillary sinus proximity, a sinus crestal approach (Sinus Crestal Approach Kit, Zimmer Dental) was followed first to gain more space apically for the placement of a longer implant. It was determined that the bone quality was D2–3. Using a soft-bone drilling protocol, the next drill used was 2.8, 2.8/3.4 x 13 mm. No bone tap drills were used in order to ensure implant stability. A Trabecular Metal implant of 4.1 mm in diameter and 13 mm in length was inserted. The insertion torque exceeded 35 N cm (Figs. 22 & 23). The critical gap between the extraction socket and the implant was grafted using allograft (Puros Cortico–Cancellous Particulate Allograft; Fig. 24). The fixture transfer coping was prepared to support a non-functional screw-retained provisional crown (Fig. 25). The patient was given post-surgical instructions, including the use of 0.12% chlorhexidine gluconate (Peridex) three times a day and was prescribed 500 mg of amoxicillin (every six hours for seven days). The patient was seen for a follow-up visit 14 days later and healing was uneventful (Fig. 26).

Prosthetic treatment

After allowing the soft tissue to mature for four weeks, the final fixture-level impression was taken and

a final cast custom abutment was used to support a porcelain-fused-to-metal crown (Fig. 27).

Follow-up and maintenance

After six months, the patient returned for a follow-up visit. The clinical and radiographic exam showed that the implantation had been a great success (Fig. 28). The patient was placed on a six-month recall to maintain the implant and the restoration properly.

Clinical relevance

With higher demand by patients for immediate implant placement and immediate loading, the use of tapered implants that provide a high degree of primary stability and the addition of the Trabecular Metal technology provides faster secondary stability through bone in-growth, and can help achieve quick and predictable final restorations.

Conclusion

Forty Trabecular Metal TMT, TMM implants were placed. During surgery, an insertion torque of > 35 Ncm was used in 90% of the implants, and 85% were placed at the crest of bone. Fifteen implants received provisional restoration at the time of placement. Fully functional occluding final restorations were seated as early as two weeks in 18 implants and as long as twelve weeks in the remaining twelve implants. After six months, 30 Trabecular Metal implants had been successfully restored with no signs of implant failure.

contact

implants

Dr Suheil M. Boutros

Periodontal Specialists of Grand Blanc
 Suite 19, 8185 Holly Rd.
 Grand Blanc
 MI 48439, USA

www.PeriodonticsOnline.com

Editorial note: A list of references is available from the publisher.



Tribune CME

6 Months Clinical Masters Program in **Implant** Dentistry

May 2013 to November 2013, a total of **12 days**
in **Heidelberg (DE), Como (IT), Maspalomas (ES)**

Program director
Dr. Marius Steigmann



Live surgery and **hands-on** with the masters in their own institutes plus online mentoring and on-demand learning at your own pace and location.



Dr. Tiziano Testori



Dr. Hom-Lay Wang



Dr. Scott D. Ganz



Dr. Jose Navarro



Dr. Phillippe Russe



Dr. Stavros Pelekanos



Dr. Marius Steigmann

Session 1

Heidelberg, Germany - May 2-5

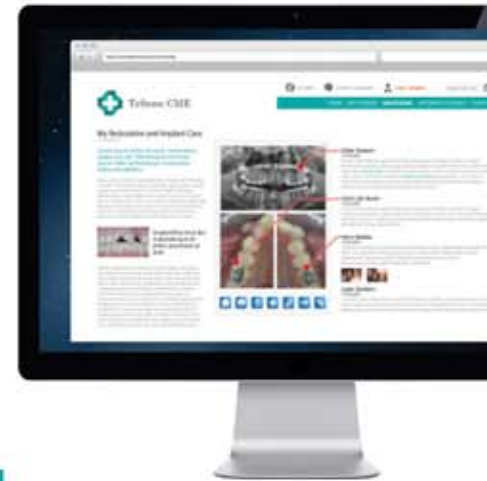Session 2

Como, Italy - July 4-7

Session 3

Maspalomas, Canary Islands - November 6-10

During each module, the participants will have the opportunity to practice their new skills on hands-on casts, porcine models, and to watch or assist live surgeries.



Course fee: € 11,900

Register by the end of 2012 and you will receive a complimentary iPad preloaded with premium dental courses.

Tel.: +49-341-48474-302

email: info@tribunecme.com

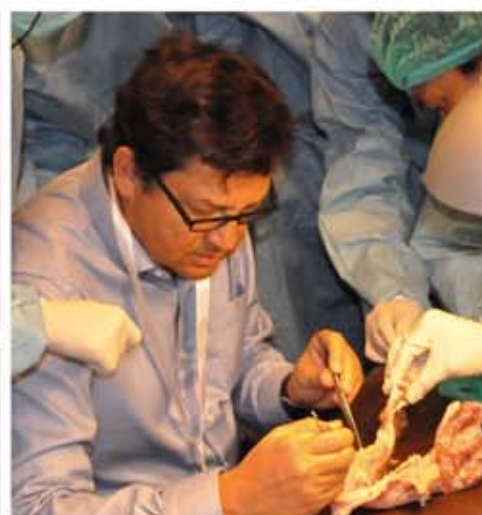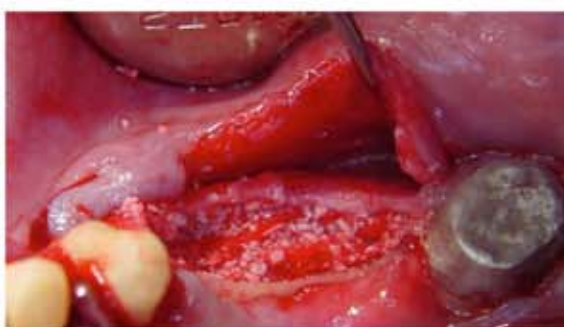www.TribuneCME.com

+ Access our online learning platform: hours of premium video training and live webinars. Collaborate with peers and faculty on **your cases**.

ADA CERP® | Continuing Education Recognition Program

Tribune America LLC is the ADA CERP provider. ADA CERP is a service of the American Dental Association to assist dental professionals in identifying quality providers of continuing dental education. ADA CERP does not approve or endorse individual courses or instructors, nor does it imply acceptance of credit hours by boards of dentistry.

Discover the Masters' secrets and enjoy three superb locations.



100
C.E. CREDITS
ADA CERP® | Continuing Education Recognition Program



Treatment of a mandibular cyst with synthetic bone graft substitute

Authors Dr Damian Dudek, Katarzyna Sołtykiewicz, Krzysztof Helewski, Grzegorz Wyrobiec, Marzena Harabin-Słowinska, Grażyna Kowalczyk-Ziomek & Romuald Wojnicz, Poland

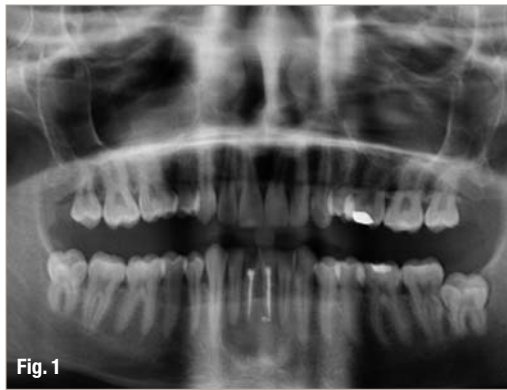

Fig. 1_Panoramic radiogram.

Fig. 1

Introduction

Radicular cysts appear as a result of pulp necrosis caused by inflammation, trauma or improper dental treatment. They are cavities enclosed by a wall of connective tissue with an inner epithelial layer, usually filled with fluid or pulp. Radicular cysts cause few clinical symptoms and are painless in many cases. Mobility of adjacent teeth may be noted, as well as swelling of the bone. If the cortical bone is thinned or destroyed by the growing cyst, cracking under palpation may be noticed. Although radicular cysts are benign, they grow slowly but steadily and may lead to complications, depending

on their size and location. Large cysts in the mandible may cause pathological fractures.¹

The treatment of maxillary and mandibular cysts is common in oral and maxillofacial surgery. The most widespread treatment methods are curettage and radical enucleation of the cyst (cystectomy).^{2,3} In cases of very large cysts, or if cystectomy is contra-indicated owing to the risk of damaging nearby anatomical structures, cystostomy is recommended. In cystostomy, the cystic lumen is opened in order to reduce the pressure inside the cyst. The cyst's volume is reduced subsequently by bony apposition on the cyst walls until it reaches a size that allows its safe removal by cystectomy.^{2,4}

The removal of a cyst evidently results in a bone defect. Depending on its size and location, the bony lesion has to be treated with regard to functional and aesthetic aspects using autogenous grafts or bone substitutes.⁵ The authors present the treatment of a radicular cyst in a male patient in this case report. The lesion probably occurred as a consequence of earlier trauma in the frontal section of the mandible. The cyst was asymptomatic and an incidental finding. After endodontic treatment, cystectomy and bone augmentation were performed.

Case report

A 27-year-old male patient visited the dentist for a routine visit. In the dental panoramic tomogram and subsequent CT scan, a pathological radiolucent lesion of about 30 x 20 x 25 mm was observed in the alveolar bone of the mandible (Figs. 1–3). In the clinical examination, teeth 41 and 42 showed mobility but were painless. A pulp vitality

Fig. 2_Frontal CT.

Fig. 3_(a) Horizontal and (b) lateral CT.

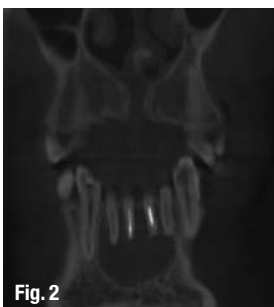

Fig. 2

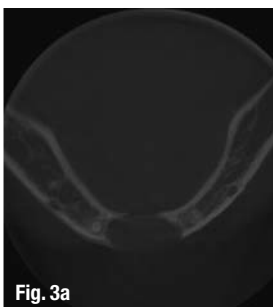


Fig. 3a

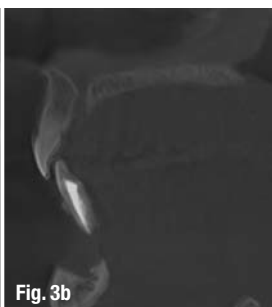
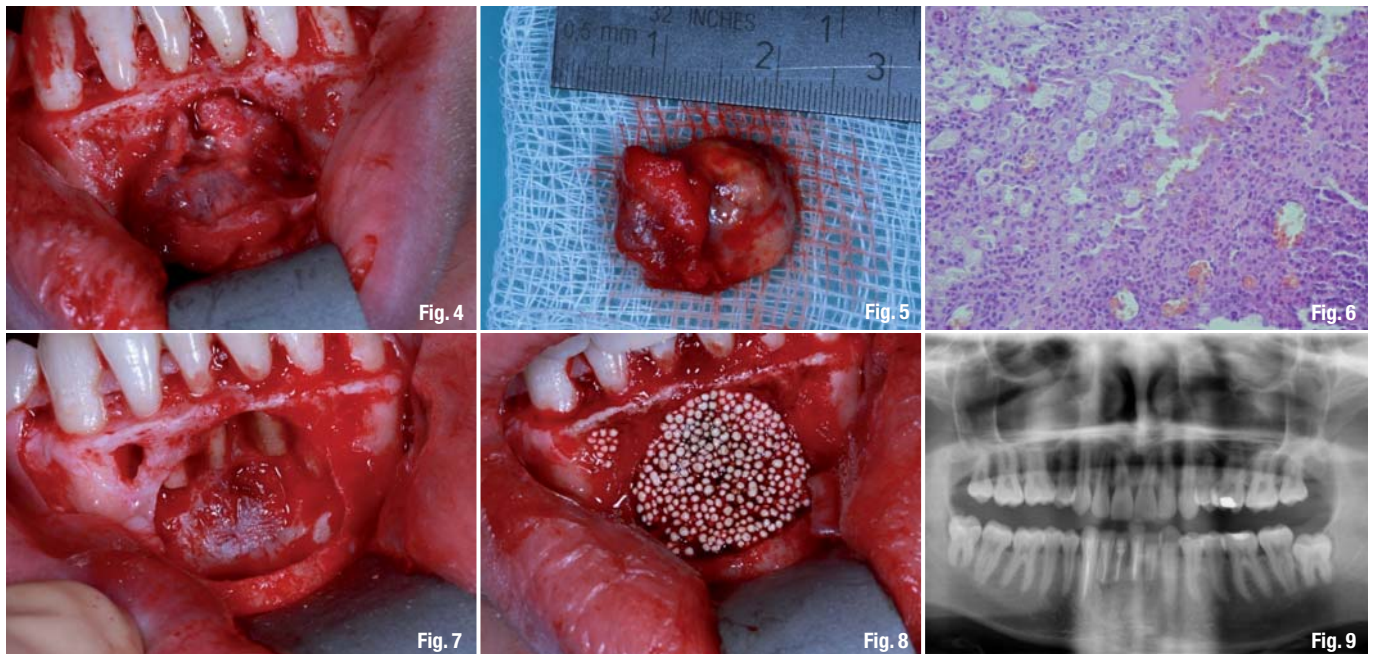


Fig. 3b



test revealed necrosis in teeth 31 and 41 to 43. The soft tissue surrounding the radiolucent lesion was intact and showed no signs of inflammation. There were neither fistulas nor swelling. In the physical examination, neither sensitivity of the gingiva nor pain was noted.

Cyst enucleation was performed under local anaesthetic with 4% articaine. Teeth 31 and 41 to 43 were treated endodontically. Upon elevation of a trapezoid mucoperiosteal flap from teeth 33 to 43, the destruction of the vestibular cortical bone was evident (Fig. 4). The cyst was enucleated and sent for histopathological examination (Figs. 5 & 6). The roots of teeth 31, 41 and 42 were resected.⁶ Tooth 43, although non-vital, was not directly involved in the cystic lesion and thus was not subjected to root-end resection. The root canals were prepared and filled with MTA (Fig. 7). After thorough debridement, the large bone defect with partial destruction of the vestibular and lingual cortical bone walls was filled with a synthetic bone substitute (easy-graft CRYSTAL, Degradable Solutions; Fig. 8). The material consists of biphasic calcium phosphate, which is composed of 60% hydroxyapatite and 40% β -tricalcium phosphate. Bone substitute granules adhere to each other, forming a mouldable but porous mass. The material hardens into a stable scaffold upon contact with blood. After application, the material was covered with a porcine collagen membrane using a double-layer technique. Teeth 41 and 42 remained mobile after filling the defect, but mobility did not increase during apicectomy and cyst enucleation. The wound was closed using 6.0 nylon sutures.

The patient received analgesics and 1,200 mg clindamycin twice a day for six days. The post-operative healing was uneventful. The sutures were removed after seven days. Six months after the cystectomy, the patient returned for a clinical and radiological follow-up visit (Figs. 9–11). Clinical examination showed no sensitivity of the gingiva, nor did the patient report pain. The shape and volume of the alveolar ridge were normal, and the teeth did not show mobility. Slight scarring was observed at the sites of the vertical incisions.

Radiological examination (panoramic tomogram and CT scan) after six months confirmed that the alveolar bone had been reconstructed within the anatomical contours and the hard tissue at the former defect site showed radiopacity similar to the surrounding bone (Figs. 9–11). A small region of reduced opacity was detected around the apex of tooth 42, which may be an effect of remodelling. This region will remain under observation.

Discussion

The diagnosis and treatment of bone cysts of the jaws, including radicular cysts, is very common in oral and maxillofacial surgery. After the removal of a cyst, the bone defect will usually be filled with blood. The blood clot contracts during early healing, which results in loss of contact between the clot and the walls of the surrounding bone. The formation and in-growth of blood vessels and, consequently, oxygen and nutrient supply—a prerequisite for bone regeneration—may be disturbed. Furthermore, the blood clot may be destroyed by the fibrinolytic activity of bacteria from the oral cavity,

Fig. 4 Local status after flap opening.

Fig. 5 Cyst after removal.

Fig. 6 Histopathological examination of a fragment of the cyst wall showed the characteristics of congestion, including chronic lymphocytic and plasmocytic inflammatory infiltration by foamy macrophage clusters (40x, hematoxylin & eosin staining).

Fig. 7 The bone defect and roots of 31, 41, and 42 after the cyst removal and resection.

Fig. 8 easy-graft® CRYSTAL in situ.

Fig. 9 Panoramic radiogram after six months.

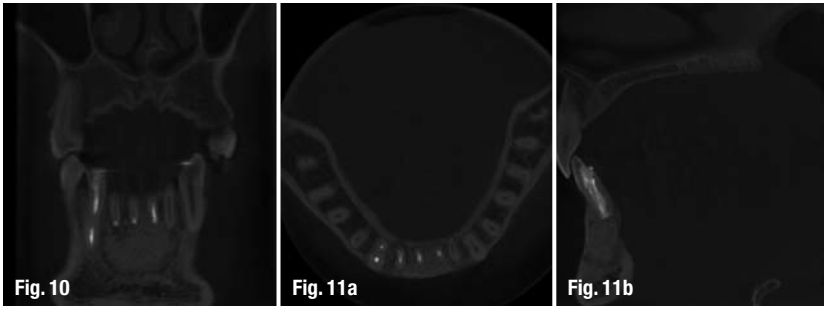


Fig. 10 Frontal CT after six months.
Fig. 11 (a) Horizontal and (b) lateral CT after six months.

which may result in wound infection. Leaving a post-resection area of a size similar to the presented case unfilled could lead to an aesthetic defect or even complications such as loss of the resected teeth or fracture.

In the literature, various treatments are described to avoid such complications and to promote bone regeneration. Schulte describes a method in which the blood clot is stabilised with collagen sponges soaked with antibiotics to reduce the contraction of the clot.⁷ Later, this method was modified by using centrifuged blood.⁸ Alternatively, the curetted defect may be filled with autogenous bone, which however will cause additional morbidity at the graft donor site. The use of bone substitutes enables the surgeon to stabilise the clot without graft harvesting. Bone substitutes differ in their origin (allogeneic, xenogeneic or synthetic) and their behaviour in the human body (resorbable or non-resorbable). Most bone substitutes are applied in granular form. Depending on defect size, form and location, securing the material with dental membranes is necessary. Generally, bone defects resulting from cyst enucleation are multi-walled and not mechanically challenged, thus bone regeneration is reproducible and reliable if appropriate osteoconductive scaffolds are used.

In the case presented, the authors used an in situ hardening biphasic bone substitute to fill a large bone defect. The size of the defect and the partially missing lingual and vestibular cortical bone walls constituted a challenging situation for which the in situ hardening property of the material used and its slow resorption were advantageous.

The material could be modelled to fit the defect shape and to follow the anatomical contour of the lost alveolar bone. The material hardens upon contact with blood. Thus, mobility of graft particles or deformation of the graft during early healing is prevented, which is important for large bone defects.

Bone regeneration is centripetal (i.e. bone formation starts from the defect walls and continues towards the defect centre). It is evident that bony regeneration thus will take longer in large defects than

in small defects (e.g. extraction sockets). Consequently, resorbable materials such as phase-pure β -tricalcium phosphate or calcium sulphate may be degraded before regeneration of large defects can be attained, which may result in incomplete bone fill. Biphasic calcium phosphates are compounds of hydroxyapatite (virtually non-resorbable) and β -tricalcium phosphate (resorbable). Materials with a composition of 60% hydroxyapatite and 40% β -tricalcium phosphate have a long and successful history of clinical use. Histologically, bone substitute particles appear to be integrated into newly formed bone. The histological findings are similar to the results obtained with bovine bone substitutes.⁹⁻¹¹ For the present case, a biphasic calcium phosphate was preferred in order to guarantee integrity of the calcium phosphate scaffold during the expected prolonged period of bone regeneration owing to the size of the defect. Histological evaluation of the regenerated hard tissue in the present case was not possible, since it would have necessitated reopening the site. However, the radiological results demonstrated that the entire cavity was filled with radiopaque tissue, which is consistent with complete bone regeneration and adequate bone substitute resorption for large cavities.

Conclusion

The case report has demonstrated how an in situ hardening biphasic bone substitute (easy-graft CRYSTAL) can be used successfully to treat large defects originating from cystectomy in oral and maxillofacial surgery. The material's in situ hardening property and slow resorption were considered to be crucial for the treatment of the case. The authors used a resorbable membrane to cover the bone graft on the vestibular side. Further studies will be necessary to determine the indications for which the application of a membrane is useful, or whether a bone substitute used without a membrane is sufficient.

Editorial note: A complete list of references is available from the publisher.

_contact	implants
<p>Dr Damian Dudek</p> <p>ul. Ruska 32A, 42-200 Czestochowa, Poland Tel.: +48 604 124-520</p> <p>damiandudek@op.pl</p>	

implants wishes you a
successful **IDS 2013!**



© 2012 IDS, Inc. All rights reserved. www.implants-journal.com

Time proven **clinical success** of the **SHORT™ implant**

Authors Prof. Dr Mauro Marincola, MDS Angelo Paolo Perpetuini, Dr Stefano Carelli, Prof. G. Lombardo, Italy & Dr Vincent Morgan, USA

Introduction

In 1892, Julius Wolff, a German surgeon, published his seminal observation that bone changes its external shape and internal, cancellous architecture in response to stresses acting on it (Wolff's law of bone modelling and remodelling). Therefore, it is a significant engineering challenge to design a short implant that biocompatibly transfers occlusal forces from its prosthetic restoration to the surrounding bone. It requires the understanding and application of many basic biological, mechanical, and metallurgical principles. It is paramount that the entire design of a SHORT™ implant optimises the effectiveness of each of its features within the implant's available surface area and length. Clinical success cannot be met by any single implant design feature such as surface area, but rather requires the appropriate integration of all of its features.

Since an implant's design dictates its clinical and mechanical capabilities, it is scientifically approved that bone healing around a plateau-designed implant is different than the appositional bone (the

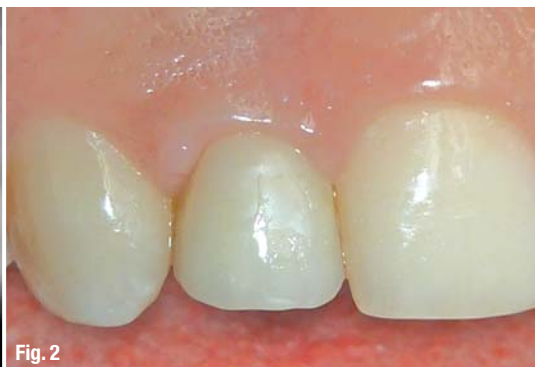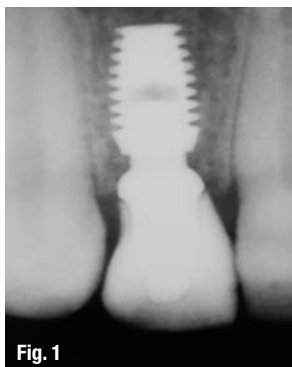
bone that is formed by osteoblasts after cell mediated interfacial remodelling) around threaded implants. The plateaued, tapered and root-formed implant body provides for 30% more surface area than comparably-sized threaded implants. But more importantly, the plateaus provide for an intramembranous-like and faster bone formation (20-50 microns per day), resulting in a unique Haversian bone with clinical capabilities different from the slower forming (1-3 microns per day) of appositional bone around threaded implants.^{1,2} Additionally, the plateaus provide for the transfer of compressive forces to the bone throughout the entire implant.^{3,4}

Description

We analysed the most time-proven short implant on the market that was called the Driskol Precision Implant in the early 1980s, than Stryker and the Bicon Dental Implant from 1993 (Boston, USA).

The Bicon implant has a bacterially-sealed 1.5 degree locking taper (galling or cold welding) connection^{5,6} between the abutment and implant, with the ability for 360 degrees of universal abutment positioning. Having a bacterially-sealed connection eliminates the bacterial flux associated with clinical odours and tastes and reduces inflammation and bone loss consistently.

Another unique characteristic is the sloping shoulder that facilitates the appropriate transfer of occlusal loads to the bone when positioned below the bony crest. But more practically, the sloping shoulder facilitates aesthetic implant restorations, for it provides space for the interdental papillae with bony support even when an implant is contiguous



to another implant or tooth. The sloping shoulder design has been, since 1985, the basis of a sensible biological width and the origin of platform switching.

The 360 degrees of universal abutment positioning provides for the extraoral cementation of crowns; the use of the cementless and screwless Integrated Abutment Crown (IAC™), the intraoral bonding of fixed bridges, which eliminates the need for cutting, indexing and soldering of bridge frameworks, multiple and easy removal of abutments over time; and the slight aesthetic rotational adjustments during and prior to the seating of a restoration.

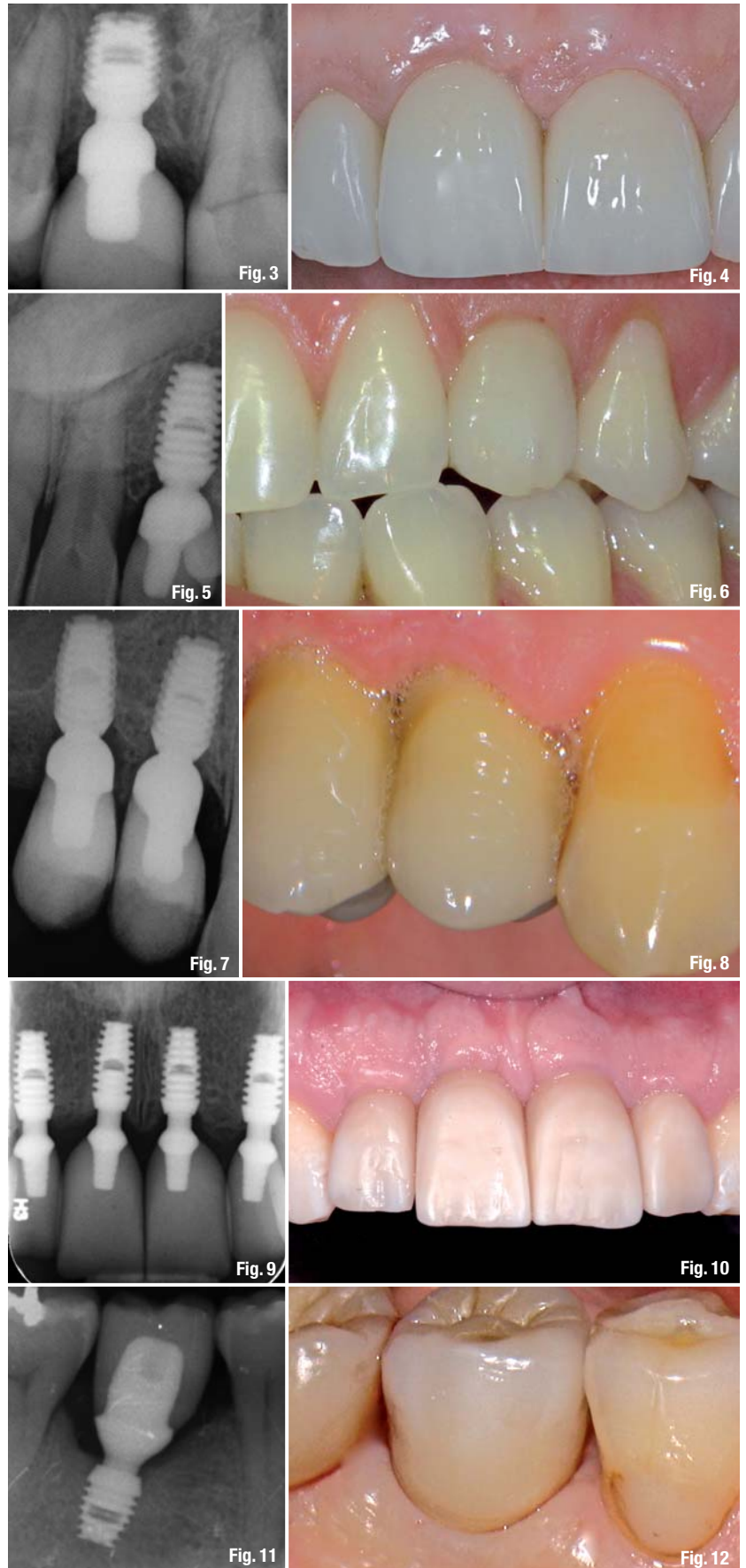
Clinical long-term results

In the following long-term case description we can observe the stability of the crestal bone around the sloping shoulder of the plateau implant. Clinically, the soft tissue contour around the Integrated Abutment Crowns indicates a healthy and stable epithelial tissue.

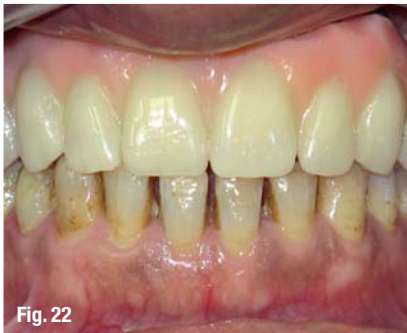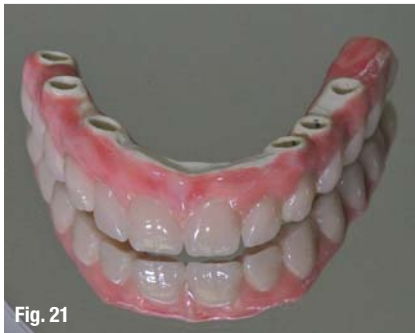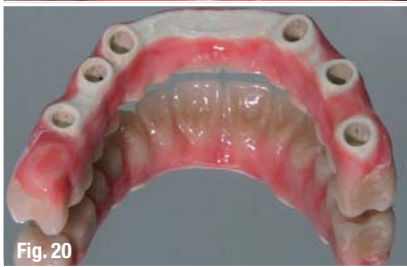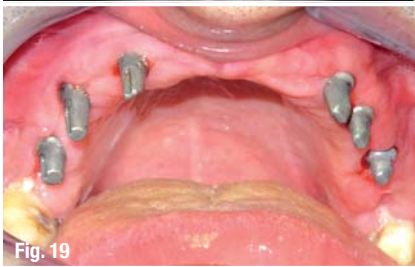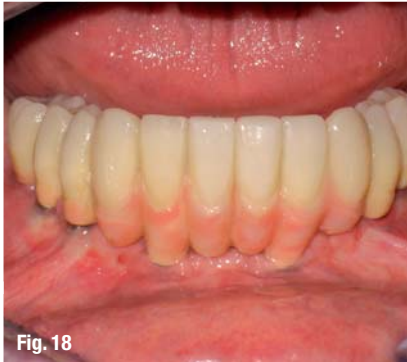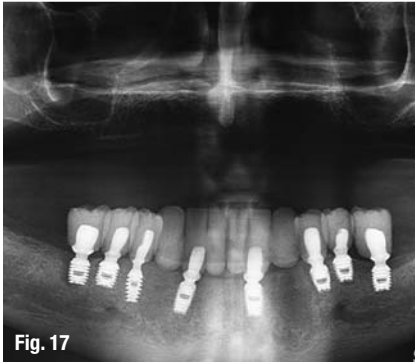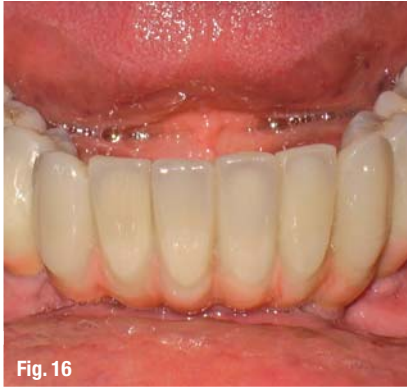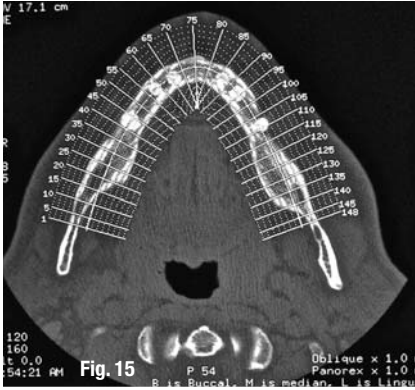
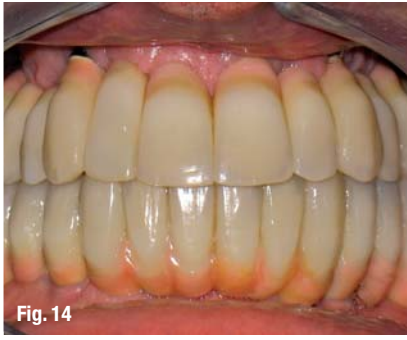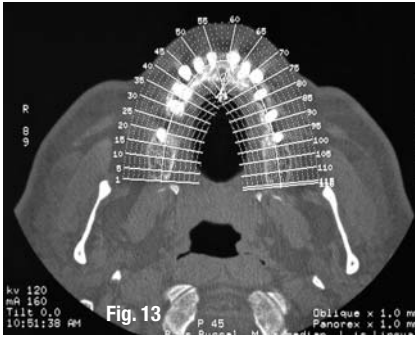
The single-tooth implant is a viable alternative for single tooth replacement.⁸ Single-tooth replacement with endosseous implants has shown satisfactory clinical performance in different jaw locations.

Minimal or no crestal bone resorption is considered to be an indicator of the long-term success of implant restorations. Mean crestal bone loss ranging from 0.12 mm to 0.20 has been reported one year after the insertion of single-tooth implant restorations.⁹ After the first year, an additional 0.01 mm to 0.11 mm of annual crestal bone loss has been reported on single-tooth implant restorations. Some implants demonstrate no crestal bone loss and/or crestal bone gain after insertion of definitive restorations.¹⁰

Crestal bone gain has been documented on immediate and early loaded implants with a chemically modified surface after one year of follow up.¹¹ A six-year prospective study reported that 43.8 % of splinted Morse taper implants experienced some bone gain.¹² Crestal bone gain has been documented around immediately loaded Bicon implants.¹³ The factors that lead to periimplant bone gain in different implant designs have not been investigated. It would be beneficial for the dental practitioner to understand what factors are associated with crestal bone gain on single-tooth implants after crown insertion. Radiographic long-term control also as a clinical observation of the soft tissue structures surrounding the abutment emergence profile can pro-



Figs. 1–12_ Radiographic long-term control helps maintain the implant's bone/soft tissue stability.



vide the clinician with a better understanding of an implant's bone/soft tissue stability (Figs. 1–12).

The ideal scenario in modern implant dentistry would be the implant replacement for every missing single tooth (Figs. 13–14). The single tooth replacement guarantees good aesthetics, consequently to the fact that a single crown that follows all criteria of a natural-looking soft tissue emergence profile can support the soft tissue in order to recreate papillae anatomy.

Another important aspect of single crown restorations on implants is that the patient can follow a better oral hygiene compared to bridgeworks. Nevertheless, bridgeworks are commonly used as alternatives to single tooth replacement. The reasons are multifactorial, with the cost-benefit factor at first place (Figs. 15–16). Another significant facet is the atrophic bone situation of the patient, where complicated and expensive bone graft procedures are needed before even thinking of placing single implants.

Alternatively to sophisticated and expensive bridgeworks (Figs. 17–18), cost-effective and simple prosthetic techniques were developed in the last years. One of these techniques, the Fixed on SHORT™, allows to provide the patients with bone atrophies or partial bone deficiencies with a fixed, metal free prosthetic that can be supported by four to six short implants (Figs. 19–22).

Conclusion

In this short and synthetic article, the authors like to show the variety of treatment options when implants and prosthetic materials are used with the criteria of long-term crestal bone preservation, recreation and long-term stabilisation of the biological width around the implant/crown and the use of short- and ultra-short implants in all clinical situations. The proper selection of an ultra-short or short implant depends strictly on the implant design which dictates the implant's function.

Editorial note: A complete list of references is available from the publisher.

_contact	implants
<p>Prof Dr Mauro Marincola Via dei Gracchi, 285 I-00192 Roma, Italy mmarincola@gmail.com</p>	

Figs. 15–16_Bridgeworks.

Figs. 17–18_Complex bridgeworks.

Figs. 19–22_Fixed-on-SHORT™ technique for fixed, metal free prosthetics.

2 0 1 3



GREATER NEW YORK DENTAL MEETING

SCIENTIFIC MEETING:

Friday, November 29 -
Wednesday, December 4

EXHIBIT DATES:

Sunday, December 1 -
Wednesday, December 4

NO PRE-REGISTRATION FEE

Attend At No Cost
Never a pre-registration fee at the
Greater New York Dental Meeting

Mark Your Calendar
Educational Programs:
Friday through Wednesday,
November 29 - December 4

Exhibits:
Sunday through Wednesday,
December 1 - December 4

More than 600 Exhibitors
Jacob K. Javits Convention Center
11th Avenue between 34-39th Streets (Manhattan)

Headquarters Hotel
New York Marriott Marquis Hotel

Live Dentistry Arena - No Tuition

Latest Dental Technology & Scientific Advances

More Than 350 Scientific Programs
Seminars, Hands-on Workshops, Essays & Scientific
Poster Sessions as well as Specialty and Auxiliary
Programs

Educational Programs in various languages

Social Programs for the Entire Family

**ENJOY NEW YORK CITY AT ITS BEST DURING THE
MOST FESTIVE TIME OF THE YEAR!**

**The Largest Dental Meeting/Exhibition/
Congress in the United States**

89th ANNUAL SESSION



For More Information:
Greater New York Dental Meeting®
570 Seventh Avenue - Suite 800, New York, NY 10018 USA
Tel: (212) 398-6922 / Fax: (212) 398-6934
E-mail: victoria@gnydm.com / Website: www.gnydm.com



WWW.GNYDM.COM

Sponsored by: The New York County Dental Society and The Second District Dental Society

Manufacturer News

Bicon Dental Implants

Simple. Predictable. Profitable.

Since 1985, the Bicon Dental Implant System has offered dentists a proven solution for missing dentition. The Bicon implant design comprises plateaus, sloping shoulders and a bacterially-sealed, 1.5°



locking taper implant to abutment connection. With the plateau design, cortical like bone forms around and between each plateau. This Haversian bone allows for the routine use of 5.0 mm short implants. The sloping shoulder provides the necessary room for bone to support interdental papillae that are gingivally aesthetic. Bicon's 360° of universal abutment positioning provides for the revolutionary cementless and screwless Integrated Abutment Crown™, which consistently provides for a non-metallic aesthetic gingival margin.

Bicon Dental Implants

Arborway 501
Boston, MA 02130, USA

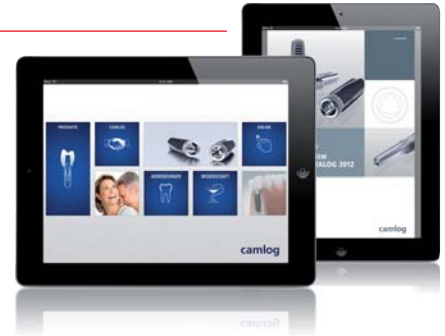
support@bicon.com
www.bicon.com

IDS: Hall 4.2, booth G070

CAMLOG

Tap-by-tap always well-informed

At the start of the New Year, CAMLOG is proud to present its first app. Now it can offer CAMLOG customers access to all relevant information about the company, its products and the numerous service and training services on a mobile user interface. Developed on the basis of iOS, the app is supported by iPad 2 and all subsequent models, including iPad mini. Clean lines, a sleek design and a user interface with intuitive features characterise this new communication tool by CAMLOG. Numerous applications can be controlled via the Apple-typical handling and allow users to navigate easily through the application. The focus of the app lies entirely on the products as well as on all necessary information for their use. The tap on the product range provides a clear view on all important aspects of the implant lines CAMLOG and CONELOG and get to the heart of the matter: Two implant lines – one surgical solution! An extensive library with numerous documents covering the area of application of the CAMLOG/CONELOG implants and prosthetic components sums up the app content comprehensively. Nu-



merous features and direct access to other interesting sites turn the app into a practical and diverse tool that can be used in either German or English. iPad users can download the app for free via their Apple account from the iTunes store.

CAMLOG Biotechnologies AG

Margarethenstr. 38
4053 Basel, Switzerland

info@camlog.com
www.camlog.com

IDS: Hall 11.3, booths A10-B19

Dentaurum Implants

tioLogic® scan abutment and titanium base

Dentaurum Implants extends its CAD/CAM product portfolio with the tioLogic® scan abutments and titanium bases.

The scan abutments were specially designed to allow precise digital recording of the geometries in the respective software. The titanium bases are used to fabricate customised hybrid abutments for adhesive retention of zirconia ceramic mesostructures fabricated using CAD/CAM. The geometry of the titanium bases was specially designed to ensure reliable, aes-

thetic bonding with the ceramic mesostructure. It is now possible to fabricate a highly precise, patient-specific prosthetic restoration using the scan abutments and titanium bases quicker and more cost-effectively. tioLogic® scan abutments and titanium bases are available in all three prosthetic series of abutments S, M and L for the tioLogic® implant system. Dentaurum Implants service: Download the tioLogic® CAD/CAM datasets for 3Shape, Dental Wings and exocad from www.dentaurum.de and integrate them into the respective software.



Dentaurum Implants GmbH

Turnstr. 31
75228 Ispringen, Germany

info@dentaurum-implants.de
www.dentaurum-implants.de

IDS: Hall 10.1, booths E010, F011

Straumann

NNC—when space or bone is limited

Used for limited interdental spaces or narrow bone ridges, the Straumann® Standard Plus Narrow Neck CrossFit® (NNC) combines Straumann's Roxolid® material, the osseointegration of the SLActive® surface, and the reliability and handling advantages of the Straumann® CrossFit® connection. The NNC implant brings together Straumann's experience in design, technology, and clinical application, combining new and established features to enhance convenience and open up new treatment possibilities.

Roxolid has been the key to the development of the NNC. The material's physical strength has enabled Straumann to develop a small diameter implant with an internal rather than an external connection. The implant-abutment interface is designed to provide an excellent seal and distribute the biting pressure optimally. It also offers great flexibility for prosthetic angulation. Being a soft-tissue-level design, the implant facilitates soft-tissue management and can be placed in a one-step procedure that avoids a second surgical intervention. It is thus designed to simplify treatment and reduces the number of dental visits. The NNC complements Straumann's small-diameter bone-level implant.



The NNC implant is complemented by a broad portfolio of surgical and standard prosthetic components. It also features a new convenient transfer piece, which holds the implant in the surgeon's drill and is then easily detached from the implant after insertion in the jawbone.

Institut Straumann AG

Peter Merian-Weg 12
4052 Basel, Switzerland

info@straumann.com
www.straumann.com

IDS: Hall 04.2, booths G080, K089

Implant Direct Europe

Three IDS questions for sales director Germany Timo Bredtmann

What do you expect from IDS 2013?

We're looking forward to plenty of curious visitors, some penetrating questions and a lot of new customers. You don't have to be able to see into the future to predict new visitor records. I assume that most visitors will continue to come from the German-speaking countries, but IDS remains the leading international dental show.

What will you offer to your guests?

Our guests will learn that Implant Direct is an active member of the major Sybron group of companies alongside KaVo and KerrHawe. Naturally, we are proud to present our four lines of implants and highlight the advantages of their compatibility. Meanwhile, many of our guests, perhaps for the first time, will find out about our biologicals: membranes, bone replacement materials and sewing materials, as well as our prosthetic segment products. The guiding principle of Implant Direct is "simply smarter", which defines the way we develop our products and offer them in an all-in-one packaging concept to our customers.

Why should you visit IDS 2013?

IDS 2013 provides the best opportunity to directly compare product solutions and services. Where, if not in Cologne, will you get a better opportunity



to check out their promises and benefits more rapidly?

Implant Direct Europe AG

Hardturmstr. 161
8005 Zurich, Switzerland

info@implantdirect.eu
www.implantdirect.de


IDS: Hall 10.1, booths J020, K029

Omnia

New PTFE surgical sutures

In addition to the traditional surgical sutures made of silk, polyester and absorbable PGA, Omnia expands its offer of surgical sutures by introducing the new generation of surgical sutures, PTFE sutures.

Omnia PTFE sutures are soft, biologically inert and chemically non-reactive. Main features of the PTFE sutures are a great fluency of the thread along the tissues, strong knot holding and a stable long-term quality. Compared to other monofilament synthetic sutures, this material is highly tolerated in the oral cavity. Further, PTFE sutures are ideal to limit inflammation, bleeding and other collateral effects which may occur during the soft tissue approximation. These sutures are available in different combinations of diameter and length with different kind of needles.



Omnia PTFE sutures are ideal for any implant, periodontal and bone graft surgery where the usage of a monofilament suture with low bacterial adhesion is recommended.

PTFE sutures are available in convenient boxes of twelve pieces each.

Omnia SpA

Via F. Delnevo,
190sx, 43036 Fidenza (PR), Italy

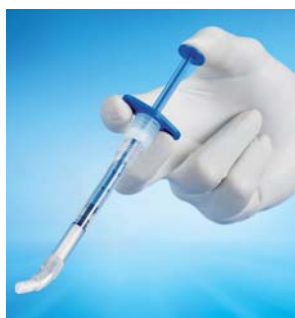info@omniaspa.eu
www.omniaspa.eu

IDS: Hall 04.1, booths C088, D089

Geistlich

Bio-Oss Pen®—Convenience Dentists Need

The number 1 bone substitute* is again leading the way in oral bone regeneration. The Geistlich Bio-Oss Pen® is putting improved precision power into the hands of oral surgeons. With the new applicator, Geistlich Bio-Oss® granules are conveniently delivered to the surgical site. In a recent survey**, Geistlich Bio-Oss® users revealed the Geistlich Bio-Oss® Pen to be a welcome new tool with excellent handling properties.



parameters of clinical user-friendliness and technical aspects. Nine out of ten dentists who tested the Geistlich Bio-Oss Pen® were convinced that the streamlined design provides an advantage. Geistlich Bio-Oss®, which has proven itself in clinical use for more than 25 years, fills the pen. With a track record of good functional and aesthetic results, predictable outcomes, and

long term success, dentists can rely on the new Geistlich Bio-Oss Pen® with the same confidence as with the Geistlich Bio-Oss® vials: nothing changed – just improved.

The pen design simplifies handling of the biomaterial particles by allowing accurate delivery of Geistlich Bio-Oss® granules to the surgical site. A curved applicator tip facilitates optimal access to defects, particularly in posterior regions difficult to reach. The Geistlich Bio-Oss Pen® is available in three variants: large granules (0.5g ~1.5cc) and small granules (0.25g ~0.5cc; 0.5g ~1cc). To evaluate the performance of the new device, we asked Geistlich Bio-Oss® users to judge the

Geistlich Pharma AG

Bahnhofstr. 4
6110 Wolhusen, Switzerland

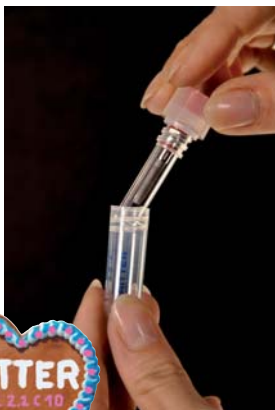www.geistlich-pharma.com

IDS: Hall 04.2, booths N091, L090

RITTER

125 Years of experience

Founded in 1887 by the German Frank Ritter in New York, Ritter is one of the oldest prestige brands of dental chairs worldwide. Due to innovative ideas and a great entrepreneurial spirit, Ritter produced the first dental units already more than 125 years ago. One of the first smart treatment units included a range of constantly required equipment tools and instruments, such as drills, saliva ejectors, floating table, water and air syringes. For the first time, this model met all expectations and ergonomic requirements of dentists and made Ritter a worldwide leading company in this sector. Since that time, owner-managed, German company Ritter has been famous for the development and production of high-quality dental treatment units. In the course of the last two years, Ritter has started to write a new success story with the launch of an innovative state-of-the-art implant line. The Ritter Implant Ivory Line provides Two Piece Implants as the QSI Spiral Implant and TFI Twin Fissure Implant as well as One Piece Implants called Mono Compress Im-



plant MCI. The system contains logically reduced and clearly arranged components of tools and abutments with the best features for all clinical cases. Due to the super nano-surface, a quick and reliable osseointegration is guaranteed. Clever and easy handling is provided by self-tapping threads and a coloured system of drills and implants according to their diameters. Today Ritter dental units and implants are more than ever an essential element in dental practices worldwide. Users appreciate the Ritter product range for high-quality aspects and reliability—made in Germany.

Ritter Implants GmbH & Co. KG

Grüner Weg 32
88400 Biberach/Riß, Germany

info@ritterimplants.com
www.ritterimplants.com

IDS: Hall 02.2,
booths E021/019, C010

Nobel Biocare

Dental news app released

ZURICH, Switzerland: Swiss dental manufacturer Nobel Biocare has developed an app to provide dentists and partners with the latest information about the company in addition to its existing print and online newsletter. The program can be downloaded from the Apple App Store and Google Play online store.

According to Nobel Biocare, any dental product news items posted to the Nobel Biocare website will also appear in the app. The app additionally provides bonus content like extra images, extended text or multimedia that add depth to articles not possible with traditional print.



Nobel Biocare News is a newsletter for the global dental community and serves as Nobel Biocare's flagship communication tool for both its customers and the dental industry. The newsletter is a key means of highlighting dental innovations, products and solutions, clinical expertise, customer experiences and patient outcomes. It is intended to promote a sense of community among its readers around the world by reporting on innovative and advanced restorative dentistry from their perspective.

Nobel Biocare

P.O. Box
8058 Zurich Airport, Switzerland

Info.switzerland@nobelbiocare.com
www.nobelbiocare.com

IDS: Hall 04.1, booths A090/091, B099

* iData Research Inc., US Dental Bone Graft Substitutes and other Biomaterials Market, 2011.
iData Research Inc., European Dental Bone Graft Substitutes and other Biomaterials Market, 2012.
**Geistlich Pharma AG practice test, June 2012.

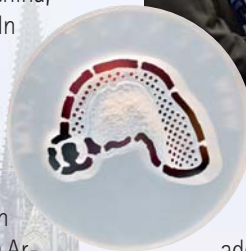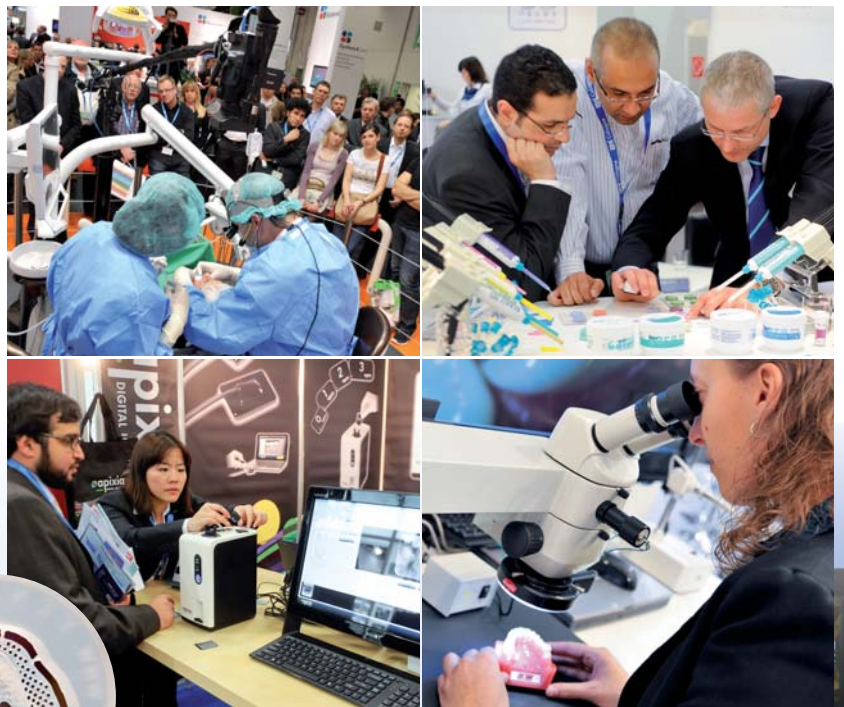The next chapter in the IDS success story

Source_Koelnmesse

IDS 2013 will continue a positive tradition that began 90 years ago, when the first dental show took place in Germany. More than 1,900 exhibitors from over 55 countries are expected to be in Cologne from 12–16 March 2013 for the world's largest trade show for dentistry and dental technology. Thanks to the tremendous demand for space, the fair will also occupy Hall 2.2 in addition to Halls 3, 4, 10 and 11. Altogether, 150,000 m² of gross exhibition space will be covered.

The International Dental Show will once again be the global meeting point for the international dental sector in 2013. Around 68 per cent of the exhibiting companies will come to Cologne from abroad. Following Germany, the nations that will be the most strongly represented include Italy, the USA, the Republic of Korea, the People's Republic of China, Switzerland, France and Great Britain. In addition, there will again be a large number of joint participations from abroad in March 2013. These are organised in conjunction with state or private export promotion organisations and associations. At present, 13 joint participation groups have registered. These come from Argentina, Brazil, Bulgaria, The People's Republic of China, Great Britain, Israel, Italy, Japan, the Republic of Korea, Pakistan, Russia, Taiwan and the USA.

Once again in 2013, the International Dental Show will stick to its time-tested recipe for success. The concept of the event will continue to focus on business at the stands and product information provided by the exhibitors. Correspondingly and according to tradition, 12 March 2013, the first day of the show—also referred to as Dealer's Day—will concentrate on dental trade and importers. This special focus will provide participants with an appropriate atmosphere for undisturbed and intensive sales negotiations. Another well-established part of the IDS programme—the Speakers' Corner—will take place in Hall 3.1, right next to the Entrance South. Here, IDS exhibitors will



present new product information, services and process techniques every day. In addition, speakers will report on the latest findings from the worlds of science and research.

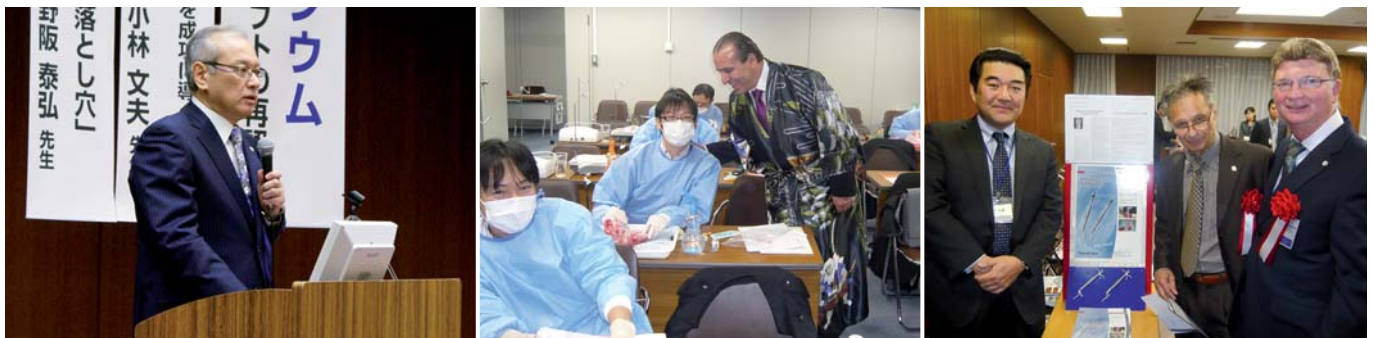A number of digital services are available to help visitors plan the optimal trade show visit. These services contribute to goal-oriented trade show preparations and help make the visit more effective. In order to ensure optimal support, the update for the trade show's own IDS app for iPhone, Blackberry and other operating systems is available since December. The app can be downloaded free of charge from the IDS website.

Travel arrangements, hotels and admission tickets for the trade fair can be booked quickly and easily online, thanks to a number of services on the IDS website. Registration and ticket sales are available now through the online ticket shop.

PICTURES: © KÖLN MESSE GMBH

More than 500 attendees visit ISOI Conference in Tokyo/Japan

Authors: Dr Rolf Vollmer, Dr Rainer Valentin & Prof. Dr Mazen Tamimi



From 17 to 18 November 2012, ISOI president Dr Naotaka Sugiyama, conference president Dr Tomohiro Ezaki and Prof. Shoji Hayashi from Kanagawa Dental College in Yokohama proved superb conference hosts. In his opening speech, Dr Sugiyama particularly highlighted the importance of the collaboration between ISOI and DGZI. To honour this partnership, ISOI, which has around 1,000 members, founded a DGZI Japan Section in 2007. Dr Sugiyama also emphasised the importance of the scientific exchange between the two partner associations for those Japanese members who want to maintain German dentistry standards, especially in the field of oral implantology.

Before starting the lectures, Dr Sugiyama announced this year's many activities of ISOI. He also talked about the participation of ISOI board members at the DGZI Congress in Hamburg, Germany, last October. ISOI and DGZI confirmed their partnership for an exchange of scientific and technical information in

implantology, today and in the future. In this vein, ISOI's President encouraged the audience to participate in the 2013 DGZI Congress in Berlin, Germany. He expressed his hope that many friends and colleagues of ISOI will take part. Members would benefit from this, since a high number of Japanese participants will result in a simultaneous interpretation of the lectures. In addition, he advised ISOI members who have already gained authority or a clinical certificate of AIAI in Japan to become DGZI Experts and Specialists. This certificate of the German Association of Oral Implantology (DGZI) is highly esteemed both in Germany and Japan. Already before the congress began, authorisation and clinical examination for dentists as well as implant authorisation for hygienist and technician were carried out by written and oral examination.

The DGZI board was represented by its vice president Dr Rolf Vollmer, Dr Rainer Valentin and Prof. Dr Mazen Tamimi from the DGZI International Section.



first implantology curriculum in Japan at a private university in Yokohama. At present, this type of post-graduate education has not been offered anywhere in Japan. Meanwhile, however, the Japanese ISOI members have acknowledged the potential of improving implantological treatment by rigorous professional training, consequently raising standards significantly.

All attendees of the ISOI conference in Japan were met with warm hospitality, and there was an exceedingly positive attitude towards DGZI, which bodes well for a continued successful collaboration and scientific exchange in the future. At the subsequent social gathering and party, participants gave us a pat on the back and a positive feedback for the questionnaire of this meeting.

The congress' central topics were the opportunities and risks of aesthetic, surgical and prosthetic implantology as well as dental CT, anaesthesiology and ENT. In addition, clinical cases and failure cases were presented. While Dr Vollmer reported on the latest research with regard to heat development during implant site preparation, Dr Valentin introduced a new technique of harvesting autogenous bone. Participants were also very interested in a hands-on seminar on pig jaws, in which nerve transpositioning techniques were practiced. The course was led by Prof. Dr Tamimi, who gave a theoretical introduction to the topic and demonstrated a step-by-step procedure supported by video transmission. The contents of those lectures held the key to a successful operation and a final implant stage. They also gave us the latest technology and knowledge of dental implantology. During the post-discussion session, the audience was asked to contribute questions and suggestions. Lectures for hygienists and dental technicians were held in the other congress rooms. For example, Dr Ezaki explained the opportunities of risk management to auxiliaries in a special session.

The success of this meeting has contributed to our goals and we look forward to the future of ISOI and DGZI. The many positive reactions from ISOI members and the many things we have learned from the lectures were both delighting and encouraging. Therefore, the boards of both of the two associations agree that the meeting in Japan and the meeting at the DGZI Congress in Germany should become recurring elements in their calendars.

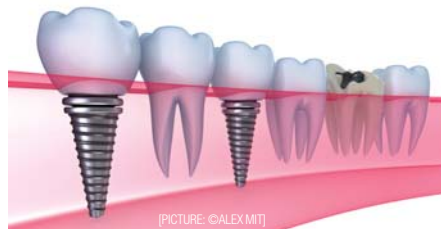
We hope to see many colleagues from Japan at our meeting at the Palace Hotel in Berlin on 4 and 5 October this year and we invite our friends from Germany to join us in Japan from 16 to 17 October to experience the warm welcome and hospitality of the Japanese people and colleagues.

The Japanese colleagues were especially interested in utilising the DGZI's vast experience and in adopting its successful educational design. This is exemplified by Prof. Hayashi's goal of implementing the



Researchers increase

Success rate of tooth implants



Spanish researchers have developed an implant coating with a novel biodegradable material aimed at people with inadequate jawbone. According to the inventors, it will also increase the overall success rate of implants through its enhanced biocompatibility and reduce osseointegration time.

Elderly people or people with osteoporosis, smokers, diabetics or people who have had cancer are sometimes not good candidates for dental implants, as their jawbone is unable to integrate the implants adequately. While a titanium implant takes at least two months to become anchored in the jawbone, the new prototype, developed at the Universitat Jaume I in Castellón and the University of the Basque Country in Bilbao, reduces this period so that the ceramic crown that replaces the visible part of the tooth can be seated earlier, allowing patients to regain their normal life sooner.

“It covers the implant with a biodegradable coating that upon contact with the bone dissolves and during this degradation process releases silicon compounds and other bioactive molecules that induce bone generation,” explained Julio José Suay, coordinator of the Polymers and Advanced Materials research group. “This is an innovative line of research, as current implant systems use increasing roughness of the implants to facilitate osseointegration.” After *in vitro* testing with cell cultures of the different biomaterials, the researchers proceeded to the animal evaluation, until they achieved the prototype with the best results. The next phase entails a clinical evaluation in order to obtain a marketable, sterile product within two to three years. The research aims to improve the success rate of dental implants, especially for people with jawbone deficiencies. Not replacing a lost tooth involves a series of biomechanical problems, such as a change in the bite line, malalignment of the teeth and the creation of diastemas. This can ultimately lead to such periodontal diseases as gingivitis and periodontitis that deteriorate the support structures of the jaw and cause the loss of more teeth. This is why it is so important to replace teeth—in addition to the full recovery of masticatory function and normal social relations.

Oestrogen might cause

Gum disease during pregnancy

Researchers have found that hormone levels may determine the extent of gingivitis during pregnancy. In a recent study, they observed that pregnant women with higher levels of oestrogen and dental plaque were at a greater risk of developing gingival inflammation compared with women who had lower levels.

In order to assess the role of oestrogen in gingival inflammation development during pregnancy, researchers from the University of Helsinki measured the salivary oestrogen levels and examined the periodontal health of 30 pregnant women and 24 female controls.

Overall, the researchers found that women with high oestrogen and plaque levels had the highest frequency of preg-

nancy-related gum disease in all trimesters and after giving birth. Those with the highest plaque levels experienced more extensive bleeding gums. In addition, they observed that women whose oestrogen levels and dental plaque scores increased significantly during the second and third trimester were more likely to develop gingivitis than those with high plaque scores alone. The findings thus hold important implications for the improvement of pregnant women’s oral health, the researchers said.

The study was published in the December 2012 issue of the *Journal of Periodontology*.

Link between

Weight problems and tooth loss

Although obesity is a growing public health concern, only limited data is available on the link between tooth loss and obesity. Now, a new study involving 1,720 Brazilian adults has provided new evidence that obesity is associated with the number of teeth. However, it found that the link depended largely on the participants’ age.



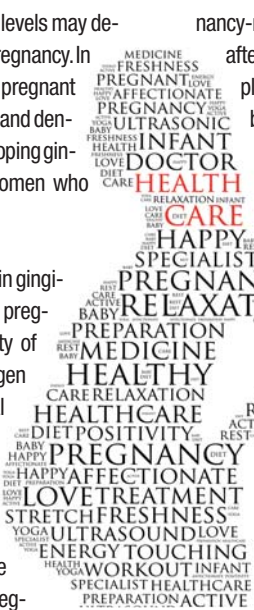The researchers found that the presence of less than ten teeth in at least one arch was positively associated with increased mean BMI and waist circumference. The prevalence of obesity was 50 per cent higher in those with less than ten teeth in at least one arch compared with those with ten or more teeth in both arches.

However, the researchers also found that with increasing age the relationship between tooth loss and obesity became less significant.

“The main explanation for this fact lies in dietary changes with aging and tooth loss. Food-intake pattern changes according to the presence and number of natural teeth,” they said.

In order to promote oral health and early prevention of tooth loss and obesity, further longitudinal studies that involve both urban and rural communities are needed to better understand the complex relationship between the two diseases, they concluded. Currently, the researchers are preparing the second phase of this study to test their formulated hypothesis.

The study was published in the October issue of the *Revista de Saúde Pública journal*.



FDA considers

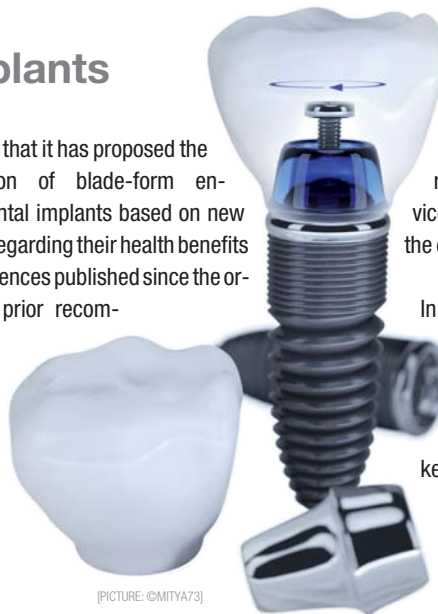
Reclassification of dental implants

The American Food and Drug Administration (FDA) has proposed a reclassification of blade-form endosseous dental implants commonly used in dental restoration from Class III to Class II devices, reducing the regulatory requirements for marketing these implants.

The FDA recognises three classes of medical devices based on the level of control necessary to assure safety and effectiveness. While Class II devices, i.e. medium-risk devices, are subject to general and special controls, Class III devices are highly regulated. Usually, Class III devices support or sustain human life, or are of substantial importance in preventing impairment of human health, but may present a potential, unreasonable risk of illness or injury.

In many cases, premarket approval is required to ensure the safety and effectiveness of these devices.

The FDA said that it has proposed the reclassification of blade-form endosseous dental implants based on new information regarding their health benefits and risk incidences published since the organisation's prior recom-



[PICTURE: ©MITYA73]

mendation. "FDA has been reviewing these devices for many years and their risks are well known. A review of the applicable clinical literature indicates that the device has a high success rate and that few relevant adverse events have been re-

ported in the case of these devices or related devices, suggesting that the device has a high long-term safety profile," the organisation stated.

In addition to complying with general controls, the implants would be subject to special controls, including special labelling requirements, mandatory performance standards and postmarket surveillance.

However, premarket approval would no longer be mandatory to effectively mitigate possible health risks, including infection and adverse tissue reactions.

Electronic or written submissions on the proposal can be submitted by April 15, the organisation stated.

EU health-care sector faces

Serious recruitment problems



[PICTURE: ©VIOLETKAIPA]

The EU health-care sector is facing hard times. With an ageing work-force and insufficient new recruits to replace those who are retiring, the future does not look promising. Owing to demanding working conditions and relatively low pay in some health occupations, recruits are not attracted to the sector. A while ago, the EU member states invited the EC to propose an action plan to assist them in tackling the key challenges facing the health work-force in the medium to longer term. This commission staff working document describes the current status of the sector, among other matters.

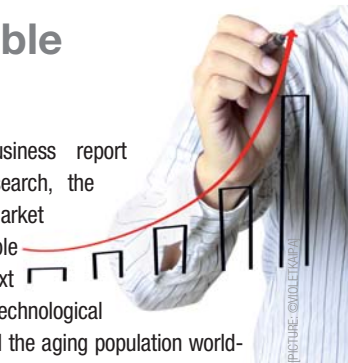The health-care sector comprises workers who primarily deliver health-care services, including health professionals (doctors, nurses, midwives, pharmacists and dentists), allied health professionals, public-health professionals, health management, and administrative and support staff. Some people also

work for the health-care sector indirectly, such as those employed in the health-care industries and support services, pharmaceuticals, medical device industries, health insurance, health research, e-health, occupational health, spa, etc. Most health-care workers are female. More than 13.1 million women were employed in the sector in 2010, making up more than three quarters of the health work-force in the entire EU. Health care is one of the largest sectors in the EU, with around 17.1 million jobs in 2010, which accounts for eight per cent of all jobs in the EU-27. The number of jobs in the sector increased by 21 per cent between 2000 and 2010, creating four million new jobs. According to the EC document, the health-care sector even continued to grow during the economic crisis, with the positive trend reflected in all age groups. Forecasts predict that it will remain a growing sector, even though employment growth will be more modest compared with 2000 to 2010.

Dental implants market

Will double by 2018

According to business report provider GBI Research, the dental implants market is set to almost double in value over the next six years. Owing to technological advancements and the aging population worldwide, the company expects a rapid increase in the use of dental implants in the near future. An analysis of the market for titanium and zirconium dental implants revealed that the global dental implants market is expected to grow at a compound rate of 10 per cent from \$3.4 billion in 2011 to \$6.6 billion in 2018, GBI Research's health care experts said. They found that the market is mainly driven by growing concerns about oral hygiene, increasing life expectancy and the availability of advanced solutions for dental implants based on digital dentistry, which increases procedure efficiency and reduces the incidence of adverse outcomes. Moreover, the investigators observed an increasing preference for dental implants as a treatment option over conventional devices such as crowns, bridges or dentures.



[PICTURE: ©VIOLETKAIPA]

implants
international magazine of oral implantology



Publisher

Torsten R. Oemus
oemus@oemus-media.de

CEO

Ingolf Döbbecke
doebbecke@oemus-media.de

Members of the Board

Jürgen Isbaner
isbaner@oemus-media.de

Lutz V. Hiller

hiller@oemus-media.de

Chief Editorial Manager

Dr Torsten Hartmann (V. i. S. d. P.)
hartmann@dentalnet.de

Editorial Council

Prof Dr Dr Frank Palm
frank.palm@klinikum-konstanz.de

Dr Roland Hille

dr-hille@t-online.de

Prof Dr Dr Kurt Vinzenz

kurt.vinzenz@aon.at

Dr Torsten Hartmann

hartmann@dentalnet.de

Dr Suheil Boutros

sboutros@umich.edu

Editorial Office

Georg Isbaner
g.isbaner@oemus-media.de

Claudia Jahn

c.jahn@oemus-media.de

Executive Producer

Gernot Meyer
meyer@oemus-media.de

Designer

Sarah Fuhrmann
s.fuhrmann@oemus-media.de

Customer Service

Marius Mezger
m.mezger@oemus-media.de

Published by

OEMUS MEDIA AG
Holbeinstraße 29
04229 Leipzig, Germany
Tel.: +49 341 48474-0
Fax: +49 341 48474-290
kontakt@oemus-media.de

Printed by

Silber Druck oHG
Am Waldstrauch 1
34266 Niestetal, Germany

implants

international magazine of oral implantology
is published in cooperation with the German
Association of Dental Implantology (DGZI).

DGZI President

Prof. Dr Dr Frank Palm
DGZI Central Office
Paulusstraße 1, 40237 Düsseldorf, Germany
Tel.: +49 211 16970-77
Fax: +49 211 16970-66
office@dgzi-info.de

www.dgzi.de
www.oemus.com

Copyright Regulations

implants international magazine of oral implantology is published by Oemus Media AG and will appear in 2013 with one issue every quarter. The magazine and all articles and illustrations therein are protected by copyright. Any utilization without the prior consent of editor and publisher is inadmissible and liable to prosecution. This applies in particular to duplicate copies, translations, microfilms, and storage and processing in electronic systems.

Reproductions, including extracts, may only be made with the permission of the publisher. Given no statement to the contrary, any submissions to the editorial department are understood to be in agreement with a full or partial publishing of said submission. The editorial department reserves the right to check all submitted articles for formal errors and factual authority, and to make amendments if necessary. No responsibility shall be taken for unsolicited books and manuscripts. Articles bearing symbols other than that of the editorial department, or which are distinguished by the name of the author, represent the opinion of the afore-mentioned, and do not have to comply with the views of Oemus Media AG. Responsibility for such articles shall be borne by the author. Responsibility for advertisements and other specially labeled items shall not be borne by the editorial department. Likewise, no responsibility shall be assumed for information published about associations, companies and commercial markets. All cases of consequential liability arising from inaccurate or faulty representation are excluded. General terms and conditions apply, legal venue is Leipzig, Germany.

implants

international magazine of oral implantology



Subscribe now!

I would like to subscribe to **implants international magazine of oral implantology** (4 issues per year) for €44 including shipping and VAT for German customers, €46 including shipping and VAT for customers outside Germany, unless a written cancellation is sent within 14 days of the receipt of the trial subscription. The subscription will be renewed automatically every year until a written cancellation is sent to OEMUS MEDIA AG, Holbeinstr. 29, 04229 Leipzig, Germany, six weeks prior to the renewal date.

▶ Reply via Fax +49 341 48474-290 to OEMUS MEDIA AG or per E-mail to grasse@oemus-media.de

You can also subscribe via www.oemus.com/abo

Last Name, First Name

Company

Street

ZIP/City/County

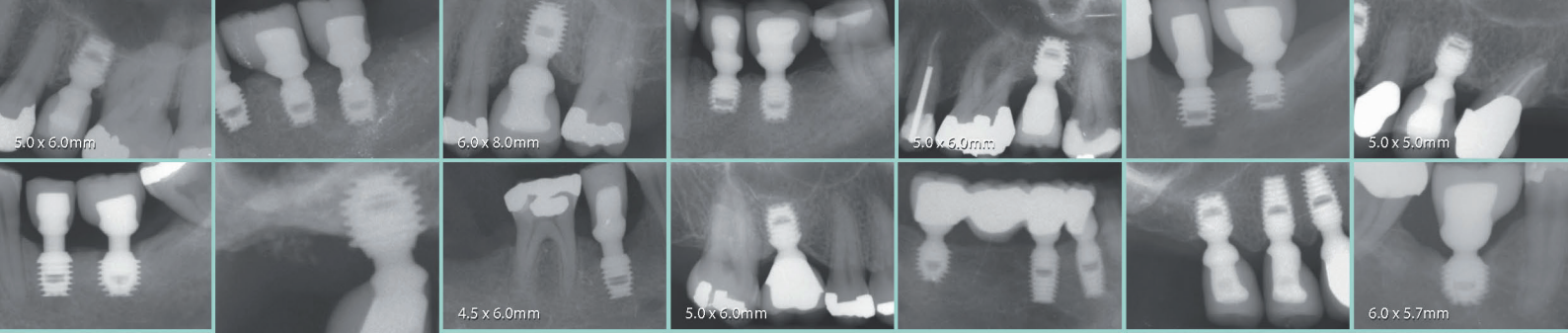
E-mail

Signature

Notice of revocation: I am able to revoke the subscription within 14 days after my order by sending a written cancellation to OEMUS MEDIA AG, Holbeinstr. 29, 04229 Leipzig, Germany.

Signature






6.0 x 5.7mm
14 YEARS

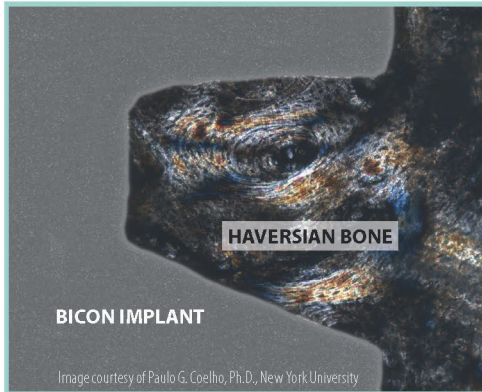


14 YEARS
6.0 x 5.7mm




PLATEAU DESIGN

Bicon's plateau or fin design offers at least 30% more surface area than a screw implant of the same dimensions and allows for the callus formation of mature, cortical-like, haversian bone between the fins of the implant.



THE BICON DESIGN is driven by simplicity. A cornerstone of its simplicity is SHORT® Implants. When the Bicon system was first introduced in 1985, its 8.0mm length implants were considered quite short—most other implants were at least 12–14mm and sometimes 18–20mm long! Since then, the natural progression of Bicon's design philosophy has resulted in 5.0mm, 5.7mm, and 6.0mm SHORT® Implants, all with proven clinical success.



bicon[®]
DENTAL IMPLANTS

**SHORTEST IMPLANTS
LONGEST HISTORY**

SHORT[™]
IMPLANTS

www.bicon.com/shortimplants