


roots

international magazine of endodontology

1 2013



| CE article

A review of bioceramic technology in endodontics

| special

Using hand files to their full capabilities: A new look at an old yet emerging technology

| review

Endodontic irrigants and irrigant delivery systems





Tribune CME

Clinical Masters Program in Aesthetic and Restorative Dentistry

10-14 January 2013 and 24-27 April 2013 in Dubai, for a total 9 days

Dubai, UAE

2 on location sessions with **live patient treatment**
and **hands on** in each session!
+ online live and recorded lectures, **online mentoring**



Didier Dietschi



Francesco Mangani



Panos Bazos

Session I: 10 - 14 January 2013 (5 days)

- Direct/Indirect composite Artistry in the Anterior Segment
- Direct/Indirect composite Artistry in the Posterior Segment
- Photography and shade analysis

Clinical Masters:

Didier Dietschi, Francesco Mangani, Panos Bazos



Mauro Fradeani



Urs Brodbeck

Session II: 24 - 27 April 2013 (4 days)

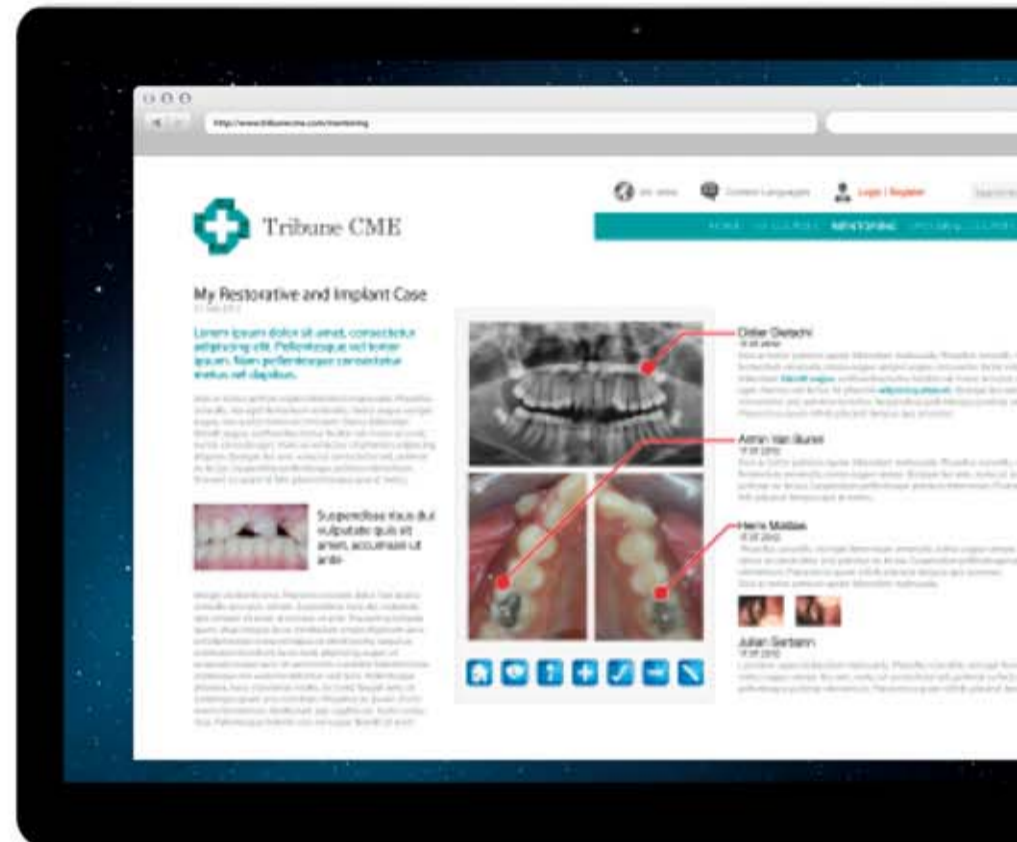
- Full coverage Anterior/Posterior Restoration
- Partial coverage Anterior/Posterior Restoration, Ceramic Restoration

Clinical Masters:

Mauro Fradeani, Urs Brodbeck

ADA CERP® | Continuing Education
Recognition Program

Tribune America LLC is the ADA CERP provider.
ADA CERP is a service of the American Dental Association to assist dental professionals in identifying quality providers of continuing dental education. ADA CERP does not approve or endorse individual courses or instructors, nor does it imply acceptance of credit hours by boards of dentistry.



Full access to our online learning platform:
hours of premium video training and live webinars
collaborate with peers and faculty on **your cases**

Registration info

Course fee: € 8,900

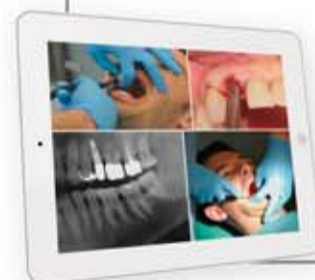Register by the end of October and you
will receive a complimentary iPad
preloaded with premium dental courses

Tribune CME

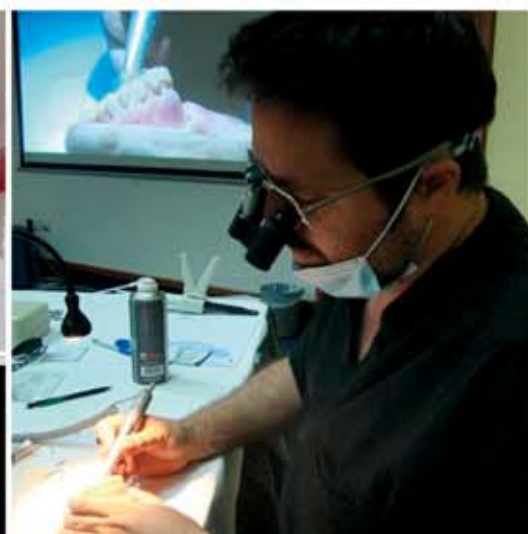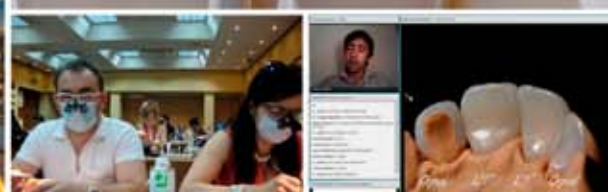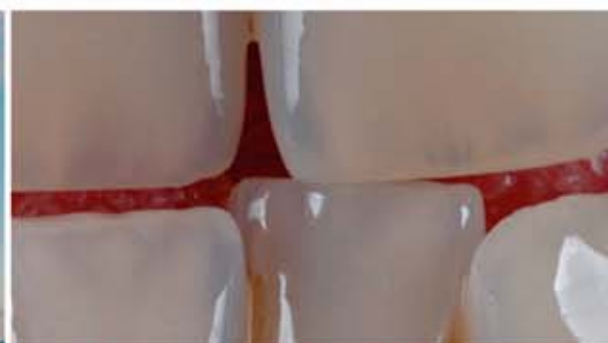Tel.: +49-341-48474-302

email: info@tribunecme.com

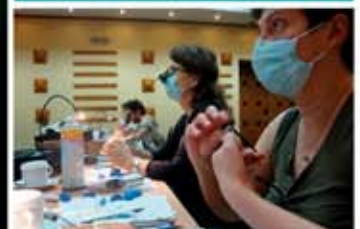www.TribuneCME.com



Discover the Master's secrets and Dubai's superlatives



100
C.E. CREDITS
ADA CERP®



Dear Reader,

_On 5 March, the Root Canal Anatomy Project (<http://rootcanalanatomy.blogspot.com>) will have been online for two years. This project was conceived in the Laboratory of Endodontics of the University of São Paulo, Brazil. During this time, the blog has registered over 210,000 visitors from 161 countries and the videos have been watched more than 50,000 times. Considering that root-canal anatomy is a specific subject in dentistry, we believe that our aim is being achieved.


The original goal of this project was the development and availability of non-commercial educational resources in the endodontic field for educators, scholars, students, clinicians and the general public. The main purpose is to demonstrate the complexity of the root-canal system in different groups of teeth and the limitations of some procedures related to endodontic therapy. In a world where 3-D entertainment rules, it is unthinkable that dentists, dental students and patients are still being educated using only 2-D models such as radiographs and photographs. The project emphasises the importance of animated images of the internal anatomy of the teeth in the educational process.

People have asked me why the content of this project has not yet been commercialised. Basically, there are two reasons for this. The first one is that the technology and training of our staff were only possible because of a government sponsorship. So the government believed in our project and public money was granted in order to develop our idea. It is thus only fair to make the project content available in the form of free educational material.

The second reason has been guided by the following: dividing to multiply. Since the blog first went online, the number of people who appreciate and respect our work has increased exponentially. I have been invited to travel worldwide to talk about this project and had the unique opportunity to experience other cultures and met amazing people I would otherwise not have met. Our images have been used on invitation cards, personal web pages, educational flyers, and even on some covers of **roots**. Amazing! It has been a wonderful experience to be a giver and a receiver at the same time. This is the most beautiful of paradoxes. It is in the very act of giving of ourselves to others that we truly receive all for which we could ever possibly wish.

While this editorial is not full of references to the newest innovations in endodontics or the answers to your deep clinical questions, I am sure that you will be able to find such information in the pages of this marvellous magazine. My purpose here is another one. Considering that this is the first issue of **roots** in 2013, I would like to wish you a year full of new friendships, happiness, peace, and unforgettable moments with your family. I hope that you will keep providing the best of your skills in order to fulfil your patients' needs and use our gift to provide pain release to make this world a better place. Keep giving! Giving is an act of gratitude. Plant the seeds of generosity through your acts of giving, and you will grow the fruits of abundance for yourself and those around you. Thank you for supporting us throughout these years.

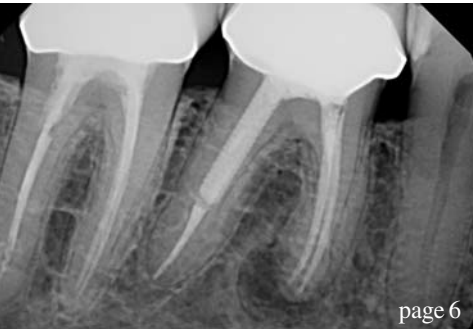My best wishes,



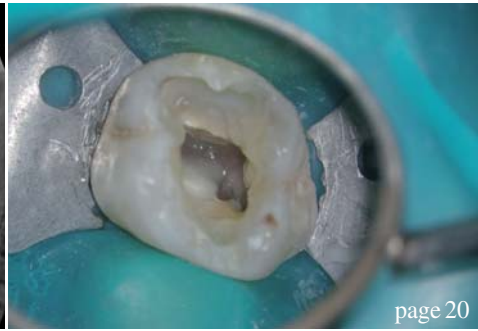
Prof. Marco Versiani, DDS, MS, PhD
Major Dental Officer (Brazilian Military Police)
Specialist in endodontics, didactics and bioethics



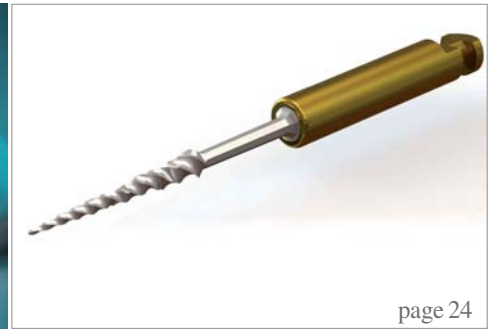Prof. Marco Versiani, DDS, MS, PhD



page 6



page 20



page 24

| editorial

03 Dear Reader | Prof. Marco Versiani

| CE article

06 A review of bioceramic technology in endodontics | Drs Ken Koch, Dennis Brave & Allen Ali Nasseh

| special

14 Using hand files to their full capabilities: A new look at an old yet emerging technology | Dr Rich Mounce

20 Twisted Files changed the world of endodontics | Dr Sorin Sirbu

24 INITIAL®: The beginning of a new era for endodontic instrumentation? | Dr Matthieu Pérard, Dr Justine Le Clerc, Prof. Pierre Colon & Prof. Jean-Marie Vulcain

| review

30 Endodontic irrigants and irrigant delivery systems | Dr Gary Glassman

| industry

38 Stropko Irrigator removes debris, making many procedures easier | Dr John J. Stropko

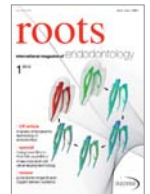39 Produits Dentaires presents PD MTA White

| meetings

40 International Events

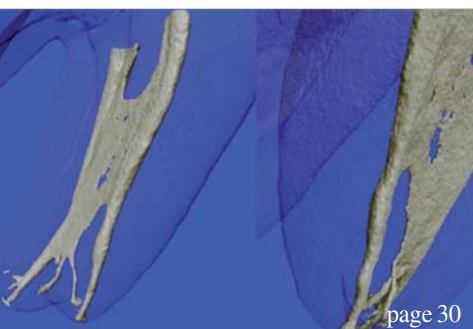
| about the publisher

41 | submission guidelines
42 | imprint



Cover image courtesy of Prof. Marco Versiani

3-D micro-CT models of a mandibular molar showing the changes of the original root-canal anatomy (green) after preparation with a multiple-file rotary system. Each colour represents preparation by one of five instruments. The last image in the sequence represents the root canal after shaping (red) superimposed on the original canal (green), demonstrating that most of the surface area was prepared using the multiple-file system.



page 30



page 38



page 40

FDI 2013 Istanbul Annual World Dental Congress

28 to 31 August 2013 - Istanbul, Turkey

Bridging Continents for Global Oral Health




2013 ISTANBUL

www.fdi2013istanbul.org
congress@fdi2013istanbul.org

A review of bioceramic technology in endodontics

Authors_ Drs Ken Koch, Dennis Brave & Allen Ali Nasseh, USA

_ce credit	roots
	<p>By reading this article and then taking a short online quiz, you can gain ADA CERP CE credits. To take the CE quiz, visit www.dtstudyclub.com. The quiz is free for subscribers, who will be sent an access code. Please write support@dtstudyclub.com if you don't receive it. Non subscribers may take the quiz for a \$20 fee.</p>

Since bioceramic technology was introduced to endodontics, the response has been exceptional. As more and more practitioners have thought through the process, they have been able to see not only the clear benefits of this technology in endodontics, but they are now asking how this technology can be applied to other aspects of dentistry. The application of bioceramic technology has not only changed endodontics both surgically and non surgically, it has also begun to change the way we treatment plan our patients. As a result of bioceramic technology, we now have the ability to save more teeth in a predictable fashion, while, in addition, improving their long-term

prognosis. The option of "saving the natural dentition" is now back on the table.

However, before we investigate specific techniques, we must first ask ourselves is, "What are bioceramics?" Bioceramics are ceramic materials specifically designed for use in medicine and dentistry. They include alumina and zirconia, bioactive glass, glass ceramics, coatings and composites, hydroxyapatite and resorbable calcium phosphates.^{1,2}

There are numerous bioceramics currently in use in both dentistry and medicine, although more so in medicine. Alumina and zirconia are among the bioinert ceramics used for prosthetic devices. Bioactive glasses and glass ceramics are available for use in dentistry under various trade names. Additionally, porous ceramics such as calcium phosphate-based materials have been used for filling bone defects. Even some basic calcium silicates such as ProRoot MTA (DENTSPLY) have been used in dentistry as root repair materials and for apical retrofills.

Although employed in both medical and dental applications, it is important to understand the specific advantages of bioceramics in dentistry and why they have become so popular. Clearly the first answer is related to physical properties. Bioceramics are exceedingly biocompatible, non-toxic, do not shrink, and are chemically stable within the biological environment. Additionally, and this is very important in endodontics, bioceramics will not result in a significant inflammatory response if an over fill occurs during the obturation process or in a root repair. A further advantage of the material itself is its ability (during the setting process) to form hydroxyapatite and ultimately create a bond between dentin and the filling material. A significant component of improving this adaptation to the canal wall is the hydrophilic nature of the material. In essence, it is a bonded restoration. However, to fully appreciate the properties associated with the use of bioceramic technology, we must understand the hydration reactions involved in the setting of the material.

Fig. 1 The particle size of BC Sealer is so fine (less than two microns), it can actually be delivered with a 0.012 capillary tip. (Photos/ Provided by Ken Koch, DMD)

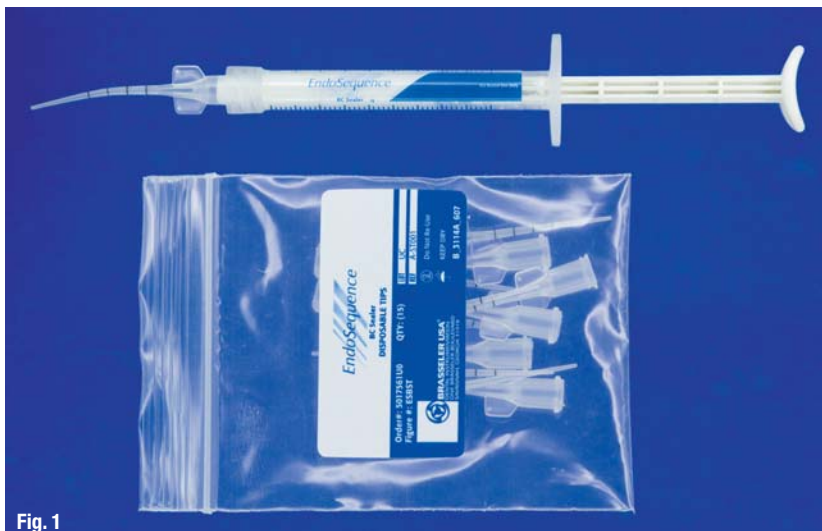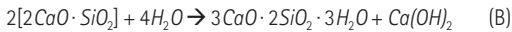
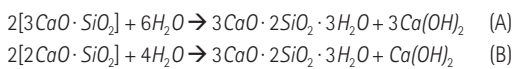


Fig. 1

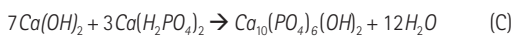
EndoSequence BC sealer setting reactions

The calcium silicates in the powder hydrate to produce a calcium silicate hydrate gel and calcium hydroxide. The calcium hydroxide reacts with the phosphate ions to precipitate hydroxyapatite and water. The water continues to react with the calcium silicates to precipitate additional gel-like calcium silicate hydrate. The water supplied through this reaction is an important factor in controlling the hydration rate and the setting time as following:

The hydration reactions (A, B) of calcium silicates can be approximated as follows:



The precipitation reaction (C) of calcium phosphate apatite is as follows:



For clinical purposes (in endodontics), the advantages of a premixed sealer should be obvious. In addition to a significant saving of time and convenience, one of the major issues associated with the mixing of any cement, or sealer, is an insufficient and non-homogenous mix. Such a mix may ultimately compromise the benefits associated with the material. Keeping this in mind, a new premixed bioceramic sealer has been designed that hardens only when exposed to a moist environment, such as that produced by the dentinal tubules.³

But, what is it specifically about bioceramics that make them so well suited to act as an endodontic sealer? From our perspective as endodontists, some of the advantages are: high pH (12.8) during the initial 24 hours of the setting process (which is strongly anti-bacterial); they are hydrophilic, not hydrophobic; they have enhanced biocompatibility; they do not shrink or resorb (which is critical for a sealer-based technique); they have excellent sealing ability; they set quickly (three to four hours); and they are easy to use (particle size is so small it can be used in a syringe).

The introduction of a bioceramic sealer (EndoSequence BC Sealer, Brasseler) allows us, for the first time, to take advantage of all the benefits associated with bioceramics but to not limit its use to merely root repairs and apical retrofills. This is only possible because of recent nanotechnology developments; the particle size of BC Sealer is so fine (less than two microns), it can actually be delivered with a 0.012 capillary tip (Fig. 1).

This material has been specifically designed as a non-toxic calcium silicate cement that is easy to use as an endodontic sealer. This is a key point. In addition to its excellent physical properties, the purpose of BC Sealer is to improve the convenience and delivery method of an excellent root canal sealer, while simultaneously taking advantage of its bioactive characteristics (it utilizes the water inherent in the dentinal tubules to drive the hydration reaction of the material, thereby shortening the setting time).

As we know, dentin is composed of approximately 20 per cent (by volume) water, and it is this water that initiates the setting of the material and ultimately results in the formation of hydroxyapatite.⁴ Therefore, if any residual moisture remains in the canal after drying, it will not adversely affect the seal established by the bioceramic cement. This is very important in obturation and is a major improvement over previous sealers. Furthermore, its hydrophilicity, small particle size and chemical bonding to the canal walls also contribute to its excellent hydraulics. But there is another aspect to sealer hydraulics. That is the shape of the prepared canal itself.

Actually, it all begins with the file. To be more specific, it all begins with the specific preparation created by the file—a constant taper preparation. When using the EndoSequence technique, we can create either a 0.04 constant taper preparation or a 0.06 taper. The real key is the constant taper preparation, because when accomplished it now gives us the ability to create predictable, reproducible shapes. A variable taper preparation is not recommended because its lack of shaping predictability (and its corresponding lack of reproducibility) will lead to a less than ideal master cone fit. This lack of endodontic synchronicity is why all variable taper preparations are associated with the overly expensive and more time consuming thermoplastic techniques.

Fig. 2a This image shows the excellent adaptation of the bioceramic sealer (and gutta-percha) to the true shape of the prepared canal.

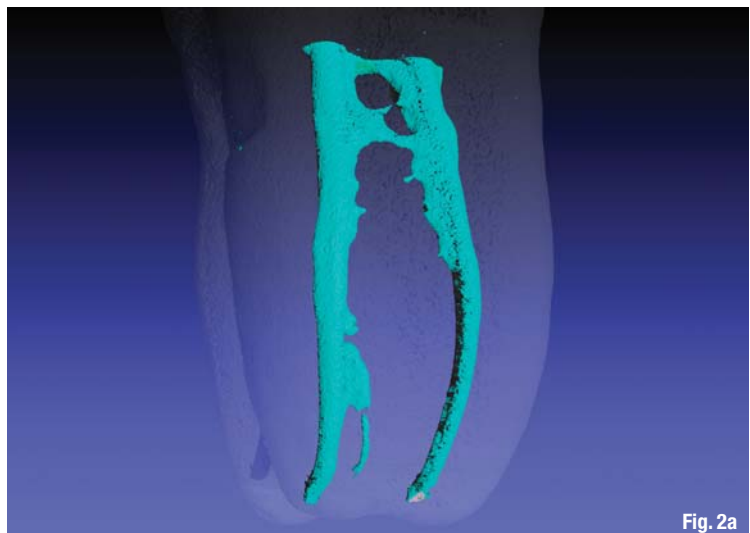


Fig. 2a

Knowing in advance what the final shape (constant taper preparation) will be is a tremendous advantage in creating superior hydraulics. Then add in the feature of laser verified paper points and gutta-percha cones, and we now start to develop a system where everything matches (true endodontic synchronicity).

This concept of having everything match is so important because it allows us, for the first time, to perform rotary endodontics in a truly conservative fashion and to be able to use a hydraulic condensation technique. Furthermore, when used in conjunction with the EndoSequence filing system, this becomes a synchronized hydraulic condensation technique. This

est reported value was in Group IV, which employed ActiV GP sealer in combination with regular gutta-percha cones. The conclusion of this study was that employing a bioceramic sealer (such as BC Sealer) is very promising in terms of strengthening the residual root and increasing the *in vitro* fracture resistance of endodontically treated teeth. This is a very significant finding, especially regarding the long term retention of an endodontically treated tooth.

In this particular study, the bioceramic sealer performed best when combined with ActiV GP cones. In fact, bonding will occur between the bioceramic sealer and the ceramic particles in the ActiV GP cones as well as to the bioceramic particles present in the new bioceramic coated cones (BC cones). The technique of achieving a true bond between the root canal wall and the master cone (as a result of creating endodontic synchronicity and advanced material science) is known as synchronized hydraulic condensation.

Synchronized hydraulic condensation

The technique with this material is quite straightforward. Simply remove the syringe cap from the EndoSequence BC Sealer syringe. Then attach an Intra Canal Tip of your choice to the hub of the syringe. The Intra Canal Tip is flexible and can be bent to facilitate access to the root canal. Also, because the particle size has been milled to such a fine size (less than 2 microns), a capillary tip (such as a 0.012) can be used to place the sealer.

Following this procedure, insert the tip of the syringe into the canal no deeper than the coronal one third. Slowly and smoothly dispense a small amount of EndoSequence BC Sealer into the root canal. Then remove the disposable tip from the syringe and proceed to coat the master gutta-percha cone with a thin layer of sealer. After the cone has been lightly coated, slowly insert it into the canal all the way to the final working length. The synchronized master gutta-percha cone will carry sufficient material to seal the apex.⁶

The precise fit of the EndoSequence gutta-percha master cone (in combination with a constant taper preparation) creates excellent hydraulics and, for that reason, it is recommended that the practitioner use only a small amount of sealer. Furthermore, as with all obturation techniques, it is important to insert the master cone slowly to its final working length. Moreover, the EndoSequence System is now available with bioceramic coated gutta-percha cones. So in essence, what we can now achieve with this technique is a chemical bond to the canal wall, as a result of the hydroxyapatite that is created during the setting reaction of the bioceramic material and we also have a chemical bond between the

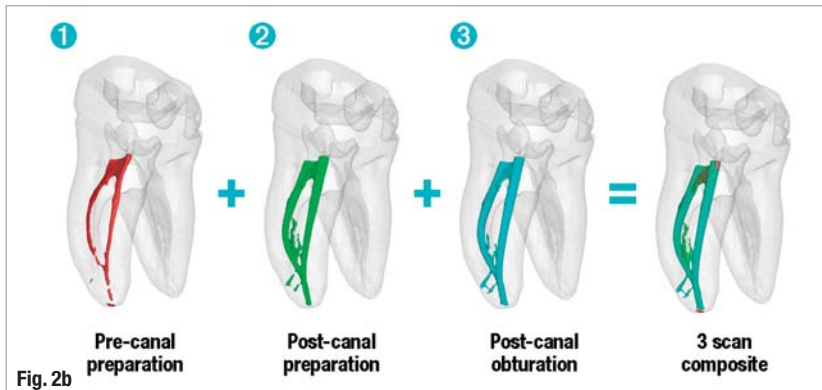


Fig. 2b_A composite image demonstrating the true excellence of the technique.

has tremendous implications for the tooth as evidenced by a recent study published in the Journal of Endodontics.⁵ The purpose of this study was to evaluate and compare the fracture resistance of roots obturated with various contemporary-filling systems. The investigators (Ghoneim, et. al.) instrumented 40 single-canal premolars using 0.06 taper EndoSequence files. The teeth were then obturated using four different techniques. Group I used a bioceramic sealer iRoot SP (iRoot SP is BC Sealer in Europe) in combination with ActiV GP cones (Brasseler) while Group II used the bioceramic sealer with regular gutta-percha. Group III utilized ActiV GP sealer plus ActiV GP cones and Group IV employed ActiV G sealer with conventional gutta-percha cones. All four groups were obturated using a single cone technique. Ten teeth were left unprepared and these acted as a negative control for the study.

Following preparation and obturation, all the teeth were embedded in acrylic molds and then subjected to a fracture resistance test in which a compressive load (0.5 mm/min) was applied until fracture. Subsequently, all data was statistically analyzed using the analysis of variance model and the Turkey post hoc test.

Then results generated were quite remarkable. It was demonstrated that the significantly highest fracture resistance was recorded for both the negative control and Group I (bioceramic sealer/ActiV GP cone) with no statistical difference between them. The low-

IFEA

International Federation of Endodontics Associations

Shaping the Future of Endodontics

The 9th World Endodontic Congress

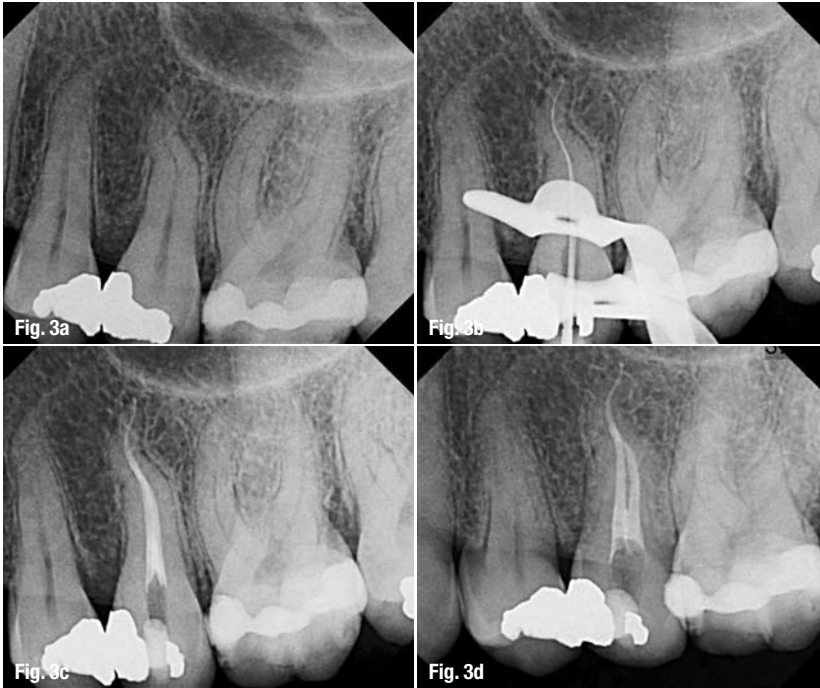May 23 to 26, 2013 Tokyo, Japan



* May 23: Pre-congress Date



www2.convention.co.jp/ifea2013



Figs. 3a–5c_Cases treated with bioceramics. (Clinical X-rays/ Provided by Allen Ali Nasseh, DDS, MMSc)

ceramic particles in the sealer and the ceramic particles on the bioceramic coated cone.

Think about what we have just accomplished. We are now doing root canals in a manner that truly is easier, faster and better. As further evidence of this technique, we asked Dr Adam Lloyd, the chairman of the Department of Endodontics at the University of Tennessee, to share the results of a study recently conducted at the University of Tennessee.⁷

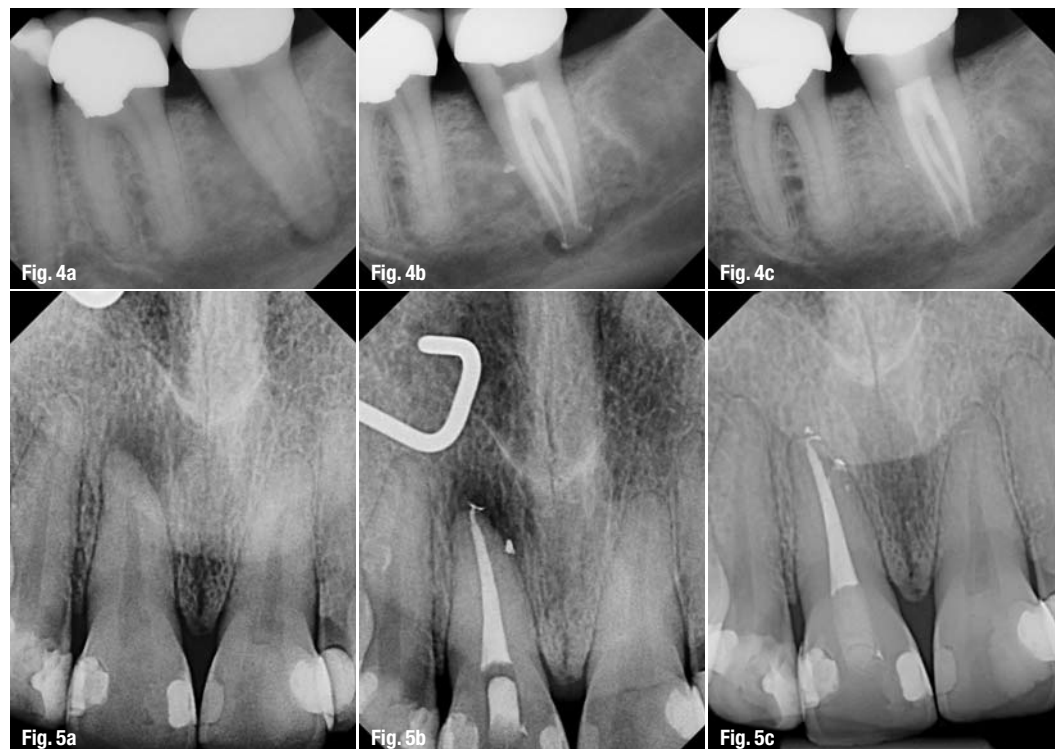Materials and methods

Sixteen recently extracted human molars were mounted on individual stubs and underwent an initial high spatial resolution CT scan prior to any treatment. Following biomechanical crown-down canal preparation to an apical matrix of 35/0.04 and ultrasonic irrigation with 6 per cent sodium hypochlorite, each sample was scanned a second time. Obturation was completed using a single matched gutta-percha cone and EndoSequence BC sealer. The coronal 4 mm of the gutta-percha was thermo-softened and compacted vertically. Subsequent to canal obturation, a third scan was made.

Scanning of the specimens was performed (Actis 150/130, Varian Medical Systems) with a 180-degree rotation around the vertical axis and a single rotation step of 0.9 degree with a cross-sectional pixel size of approximately 24µm. All three backscatter projections were aligned post-processing with sub-voxel accuracy at 92 per cent CI in VG Studio Max 2.1 (Volume Graphics GmbH) and manipulated to create regions of interest for each of the scans.

Results

Analysis of volume occupied by sealer in relation to total original canal volumes was found to be extremely high with a mean of 97 per cent ± 2.8, much higher than reported previously using studies on canal surface area occupancy of material, with 75 per cent of samples occupied at the ≥ 95 per cent level (Figs. 2a, 2b).



While the properties associated with bioceramics make them very attractive to dentistry, in general, what would be their specific advantage if used as an endodontic sealer? From our perspective as endodontists, some of the advantages are: enhanced biocompatibility, possible increased strength of the root following obturation, high pH (12.8) during the setting process which is strongly anti-bacterial, sealing ability related to its hydrophilicity, and ease of use.⁸ Furthermore, the bioceramic sealer does not shrink upon setting (it actually expands 0.002 per cent) and once it is fully set, the material will not resorb.

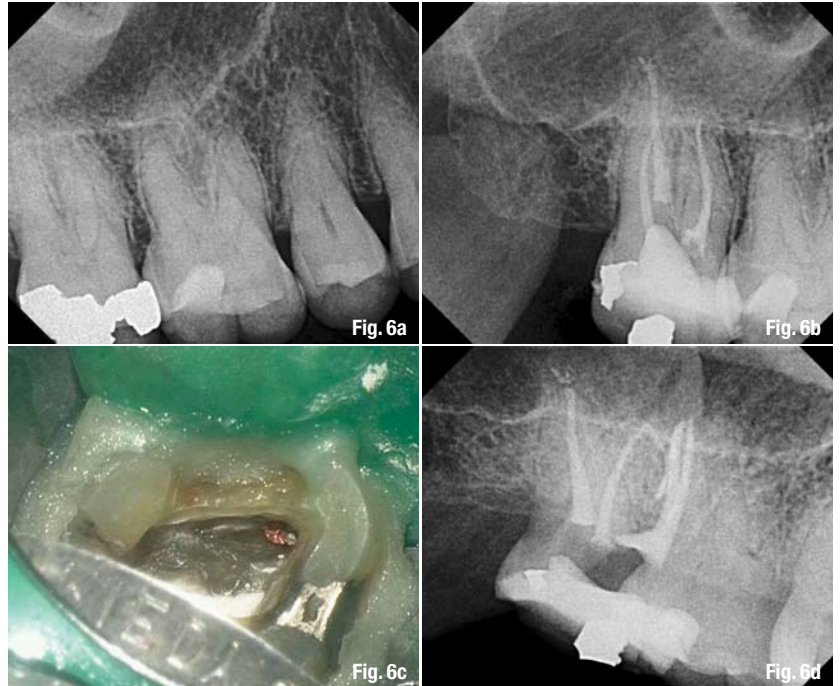The cases pictured in Figs. 3a through 5c demonstrate the excellence of this technique.

Retreatment of bioceramics

Bioceramic sealer cases are definitely retreatable yet the issue of retreating these cases (and all the associated misinformation) is not unlike that of glass ionomer. Historically there has been confusion about retreating glass ionomer endodontic cases (glass ionomer sealer is definitely retreatable when used as a sealer) and, similarly, there has been confusion concerning the retreatability of bioceramics.⁸ The key is using bioceramics as a sealer, not as a complete filler. This is why endodontic synchronicity is so important and again, why the use of constant tapers makes so much sense (it minimizes the amount of endodontic sealer thereby facilitating retreatment).

The technique itself is relatively straightforward. The key in retreating bioceramic cases is to use an ultrasonic with a copious amount of water. This is particularly important at the start of the procedure in the coronal third of the tooth. Work the ultrasonic (with lots of water) down the canal to approximately half its length. At this point, add a solvent to the canal (chloroform or xylol) and switch over to an EndoSequence file (#30 or 35/0.04 taper) run at an increased rate of speed (1,000RPM). Proceed with this file, all the way to the working length, using solvent when indicated. An alternative is to use hand files for the final 2-3 mm and then follow the gutta-percha removal with a rotary file to ensure synchronicity.

The case pictured in Figs. 6a and 6b demonstrates the retreatment of BC Sealer.



Bioceramics as a root repair material

We are all familiar with the success of MTA (mineral trioxide aggregate) as a root repair and apico retrofilling material. Furthermore, we realize that because MTA is a modified Portland cement, it has some limitations in terms of handling characteristics. It does not come premixed (and therefore must be mixed by hand), is difficult to use on retrofills, and has such a large particle size that it cannot be extruded through a small syringe. Yet it has a number of favorable characteristics including a pH of 12.5, which is significantly anti-bacterial. However, in lieu of a Portland cement-based material, we now have available a medical grade bioceramic repair material.

This new repair material is, in fact, the EndoSequence Root Repair material, which comes either premixed in a syringe (just like BC Sealer) or as a premixed putty (Fig. 7). This is a tremendous help not just in terms of assuring a proper mix but also in terms of ease of use. We now have a root repair material with an easy and efficient delivery system. This is a key development and a serious upgrade. This allows many clinicians, not just specialists, to take advantage of its properties.

Figs. 6a–6d A case demonstrating retreatment of BC Sealer. (Clinical X-rays/Provided by Allen Ali Nasseh, DDS MMSc)



Fig. 7

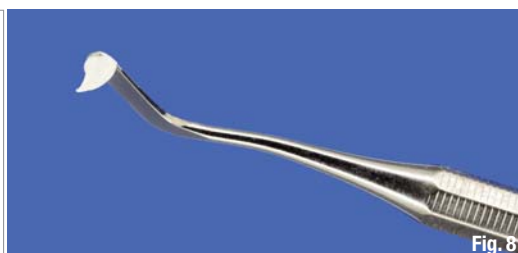
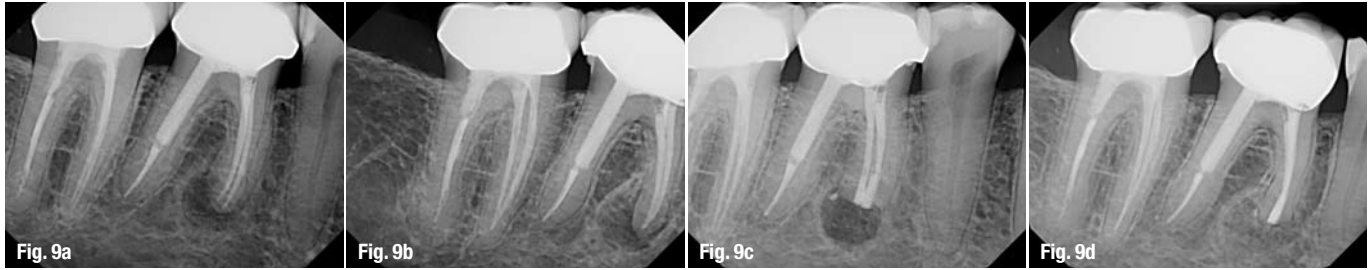
Fig. 8

Fig. 7 EndoSequence Root Repair Material. (Image courtesy of Real World Endo)

Fig. 8 A section of material ready for delivery.



Figs. 9a–10c Cases demonstrate healing and bone fill in less than six months. (Clinical X-rays/Provided by Allen Ali Nasseh, DDS MMSc)

EndoSequence Root Repair material specifically has been created as a white premixed cement for both permanent root canal repairs and apico retrofillings. As a true bioceramic cement, the advantages of this new repair material are its high pH (pH >12.5), high resistance to washout, no-shrinkage during setting, excellent biocompatibility, and superb physical properties. In fact, it has a compressive strength of 50–70 MPa, which is similar to that of current root canal repair materials, ProRoot MTA (DENTSPLY) and BioAggregate (Diadent). However, a significant upgrade with this material is its particle size, which allows the premixed material to be extruded through a syringe rather than inconsistent mixing by hand and then placement with a hand instrument.

The Clinicians Report (November 2011) published findings on EndoSequence Root Repair Material. Some of its noted advantages as a root repair material were:

- _ easier to use and place than previous similar products,
- _ good dispenser (tip/syringe) for easy dispensing,
- _ radiopaque,
- _ multiple uses for a variety of clinical conditions,
- _ no mixing required.

Furthermore, their final conclusion was that 95 per cent of 19 CR Evaluators stated that they would incorporate EndoSequence Root Repair Material into their practice. Ninety-five percent rated it excellent or good and worthy of trial by colleagues.

Another significant piece of research was published in the *Journal of Endodontics*, where a research team investigated the antibacterial activity of EndoSequence Root Repair material against *Enterococcus faecalis*. The aim of this study was to determine whether EndoSequence Root Repair material either in its putty form

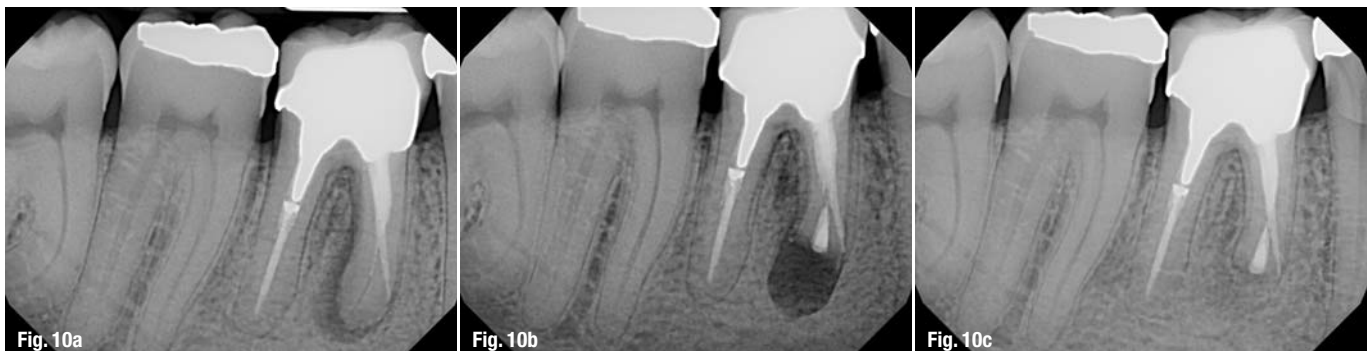
or as a syringeable paste possessed antibacterial properties against a collection of *Enterococcus faecalis* strains. As a standard, they compared the ESRRM to MTA. Their conclusion was, ESRRM, both putty and syringeable forms and white ProRoot MTA demonstrated similar antibacterial efficacy against clinical strains of *E. faecalis*.⁹

This research again validated earlier studies that found ESRRM (Putty) and ESSRM (Paste) displayed similar *in vitro* biocompatibility to MTA. Additionally, other studies found that the ESRRM had cell viability similar to Gray and White MTA in both set and fresh conditions.¹⁰

Even more significant research was published (January 2012) concerning bioceramics in general. In a comparison of endodontic sealers, it was demonstrated that in various moisture conditions within a root canal, iRoot SP (EndoSequence BC Sealer) outperformed all the other sealers. The conclusion of the study was, "Within the experimental conditions of this *in vitro* study, it can be concluded that the bond strength of iRoot SP to root dentin was higher than that of other sealers in all moisture conditions."¹¹

As mentioned previously, the bioceramic material to use in surgical cases is the EndoSequence Root Repair Material (RRM). The ESRRM is available in two different modes. There is a syringeable RRM (very similar to the basic BC Sealer in its mode of delivery) and there is also a RRM putty that is both stronger and malleable. The consistency of the putty is similar to Cavit G. The RRM in a syringe is obviously delivered by a syringe tip but the technique associated with the putty is different.

When using the putty, simply remove a small amount from the room temperature jar and knead it for



a few seconds with a spatula or in your gloved hands. Then start to roll it into a hotdog shape. This is very similar to creating similar shapes with desiccated ZOE or SuperEBA (Bosworth). Once you have created an oblong shape, you can pick up a section of it with a sterile instrument and use this to deliver it where needed (Fig. 8). This is an easy technique for apico retro fills, perforation repairs, and even for resorption defects. After placing the putty into the apical preparation (or defect) simply wipe with a moist cotton ball and finish the procedure.

The cases pictured in Figs. 9a to 10c are evidence of how beautifully this technique works. These cases are so significant because they clearly demonstrate the extraordinary healing capability of bioceramics, when used as a repair material. The X-rays display amazing healing and bone fill in less than six months, in the mandible.

Pulp capping with bioceramics

One of the other significant benefits of having bioceramics come pre-mixed in a syringe (EndoSequence Root Repair Material) is the ability for all dentists to now easily treat young patients in need of pulp caps or other pulpal therapies (e.g., pulpotomies). Previously, many specialists considered MTA to be the ideal material for a direct pulp cap because it did not seem to engender a significant inflammatory response in the pulp. Unfortunately, due to price concerns and the difficulty of placement, this methodology was not universally accepted. However, we now have a true bioceramic material (ESRRM) that not only works well, but is easier to use. It is much easier. Hopefully, this will lead to an increased use of bioceramics in our pediatric patients and help these patients save their teeth. All dentists can benefit from this upgrade in technique.

The technique itself for a direct pulp cap with the bioceramic root repair material is as follows: Isolate the tooth under a rubber dam and disinfect the exposure site with a cotton ball and NaOCl. Apply a small amount of the RRM from the syringe or, take a small amount of the RRM putty from the jar, and place this over the exposure area. Then, cover the bioceramic repair material with a compomer or glass ionomer restoration. Following the placement of this material, proceed with the final restoration, including etching if required. Single visit direct pulp capping is now here.

Future directions and prosthodontic applications

The future promises to be even more exciting in the world of bioceramics. There will be new fast set (8 to 10 minutes) repair materials introduced, as well as a special bioceramic putty for pediatric use (primary teeth). We have also seen the melding of bioceramic technology into the world of prosthodontic cements, with the

introduction of Ceramir Crown & Bridge (Doxa Dental). It is easy to predict that we will see more applications of this technology in different aspects of dental medicine.

In this article, we have introduced a new bioceramic sealer (EndoSequence BC Sealer) that when combined with coated cones offers an exciting new obturation technique (Synchronized Hydraulic Condensation). The properties associated with the new bioceramic sealer also allow us to be more conservative in our endodontic shaping which ultimately leads to the preservation of natural tooth structure. Surgical applications have also been introduced, and cases shown, which demonstrate the remarkable ability of bioceramics. The future is bright for bioceramic technology and even more exciting for dental medicine.

Editorial note: A complete list of references is available from the publisher.

about the authors

roots



Dr Ken Koch, received both his DMD and certificate in endodontics from the University of Pennsylvania School of Dental Medicine. He is the founder and past director of the New Program in Postdoctoral Endodontics at the Harvard School of Dental Medicine. Prior to his endodontic career, Koch spent 10 years in the Air Force and held, among various positions, that of chief of prosthodontics at Osan Air Force Base and chief of prosthodontics at McGuire Air Force Base. In addition to having maintained a private practice, limited to endodontics, Koch has lectured extensively in both the United States and abroad. He is also the author of numerous articles on endodontics. Koch is a co-founder of Real World Endo.



Dr Dennis Brave, a diplomate of the American Board of Endodontics and a member of the College of Diplomates, received his DDS degree from the Baltimore College of Dental Surgery, University of Maryland and his certificate in endodontics from the University of Pennsylvania. In endodontic practice for over 25 years, he has lectured extensively throughout the world and holds multiple patents, including the VisiFrame. Formerly an associate clinical professor at the University of Pennsylvania, Brave currently holds a staff position at The Johns Hopkins Hospital. Along with having authored numerous articles on endodontics, Brave is a co-founder of Real World Endo.



Dr Allen Ali Nasseh, received his MMSc degree and Certificate in Endodontics from the Harvard School of Dental Medicine in 1997. He received his DDS degree in 1994 from Northwestern University Dental School. He maintains a private endodontic practice in Boston (Microsurgicalendo.com) and holds a staff position at the Harvard's postdoctoral endodontic program. Nasseh is the endodontic editor for several dental journals and periodicals and serves as the Alumni Editor of the "Harvard Dental Bulletin." He serves as the Clinical Director of Real World Endo.

The authors may be contacted via their website, www.RealWorldEndo.com, or via email at info@realworldendo.com

Using hand files to their full capabilities: A new look at an old yet emerging technology

Author_Dr Rich Mounce, USA

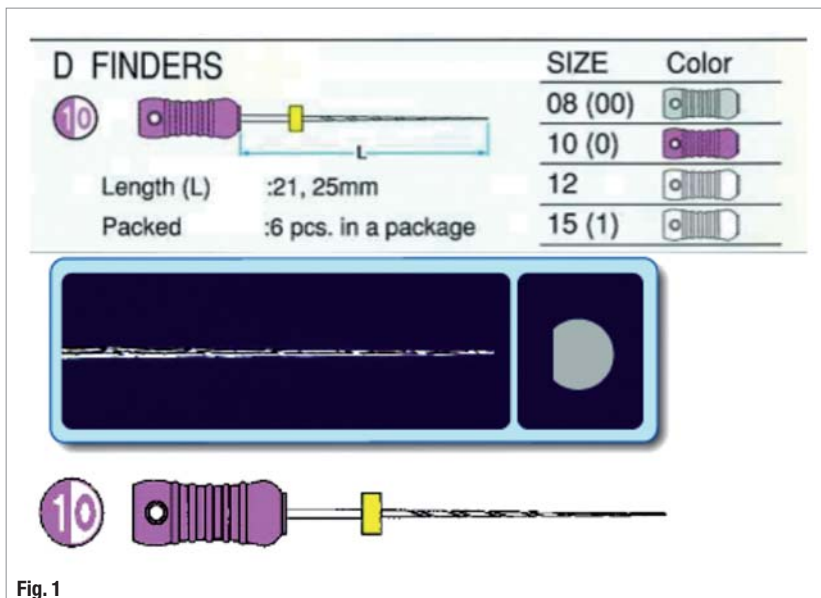


Fig. 1

Fig. 1 Mani D Finders.

(Images provided by Dr Rich Mounce)

Despite wide global acceptance of rotary nickel titanium (RNT) canal enlargement, hand files remain central to endodontic practice. It can be argued persuasively that proper canal negotiation and glide path creation are key ingredients to successful long-term treatment, along with adequate and appropriate irrigation, canal preparation, coronal seal, etc. Simply stated, after the preparatory steps of straight-line access and removal of the cervical dentinal triangle with orifice openers, if the canal is not properly negotiated and a glide path prepared prior to RNT enlargement, cleaning and shaping procedures cannot be optimal.

This article was written primarily for the general dentist. It describes stainless steel (and, to a lesser degree, nickel titanium) hand files, reciprocation and their clinical application. This article is intended to be a clinical "how to" article, not a literature review, hence a lack of extensive references.

The endodontist is encouraged to compare their treatment methods with those described here. The Mani product line of files is described primarily because these files are used daily by the author. Examples of equivalent files are provided alongside of Mani products throughout the article for comparison.

There are myriad hand file designs, applications, materials and manufacturing methods. In recent years, multi axis grinding machines have provided advancements of true clinical consequence, especially with regard to file flexibility and cutting ability. Given the wide diversity of available designs and features, it is impossible to discuss the design, clinical use or precautions required for every hand file on the market. Neither barbed broaches nor balanced force technique will be discussed.¹

Introduction: Appreciating the unseen dimension

Hand files allow the clinician to manually "feel" the unseen dimension in canal anatomy beyond what radiographs alone can illustrate. Specifically, by virtue of hand file resistance to apical advancement, the clinician can, by tactile feel, determine the curvature, calcification, length, the anatomy of the MC, and if iatrogenic events may have occurred. Only cone beam technology comes close to providing the tactile information provided by hand files (Planmeca).

Such tactile information helps determine treatment strategies prior to shaping. Astute RNT use has, as its foundation, intimate canal knowledge first by hand files. Forcing RNT files to length without adequate hand file negotiation and a glide path is the harbinger of file fracture, canal transportation and inadequate cleaning and shaping.




Fig. 2

Hand file applications, differentiation and general use principles

Hand files differ based on the following (among other attributes):

1. Material of manufacture (carbon steel, stainless steel, nickel titanium, among several other less common materials).
2. Taper (0.02 tapered, variable tapered, greater tapered).
3. Initial cross sectional design before manufacture (triangular, square, rhomboid, among other initial shapes).
4. Final cross sectional design.
5. Corrosion resistance.
6. Handle design and material used for the hand file.
7. Tip sizes (of the individual instrument).
8. Progression of tip sizes across the spectrum of a given set of instruments.
9. How the cutting flutes are produced (twisting, grinding, among other manufacturing methods).
10. Tip design (active, non cutting, partially cutting).
11. Whether the file is reciprocated, watch-wound (K files), rotated (K reamers), or used with a pull stroke (H files).
12. Helix angle, rake angle, cutting angle (if different from the rake angle) number of flutes (as well as flute width, depth and number).
13. Possible variability of the cutting angle along the length of the file.
14. Linear length of the cutting flutes.
15. In addition to the attributes above, hand files are designed to be stiff versus flexible, aggressive cutting versus less aggressive, finishing files versus bulk shaping files, among other general classifications.

Principles for maximizing hand file effectiveness

The use of hand files is based on several universal assumptions. These assumptions are:

- a) Optimal visualization of the access preparation, ideally through the surgical microscope (Zeiss, Global Surgical).
- b) Optimal radiographic evaluation of the tooth prior to access preparation including where necessary, cone beam visualization. For those without CBCT technology, having two or optimally three different pre-operative radiographic angles will provide the best possible visualization of canal anatomy short of a CBCT scan.
- c) Straight line access.
- d) Removal of the cervical dentinal triangle prior to hand file exploration.
- e) Copious irrigation at every stage in the procedure, especially rinsing debris from the access preparation before hand files are inserted.
- f) Pre-operative evaluation of the estimated and expected true working length, final taper and master apical diameter.
- g) Curved files negotiate curved canals more effectively than straight ones. The EndoBender pliers (Axis/Sybron) are an effective instrument to place the needed curvature onto hand files. Generally, in canals that have been ledged or transported, placing an acute, 3- to 5-mm curve onto the apical portion of the hand file is beneficial. Multiple insertions of curved hand files to bypass blocked and transported canals (especially ledges) are the rule, not the exception. Alternatively, if no transportation has occurred (the canal is untouched or easily

Fig. 2_Mani K and H Files, and Mani Reamers.




Fig. 3

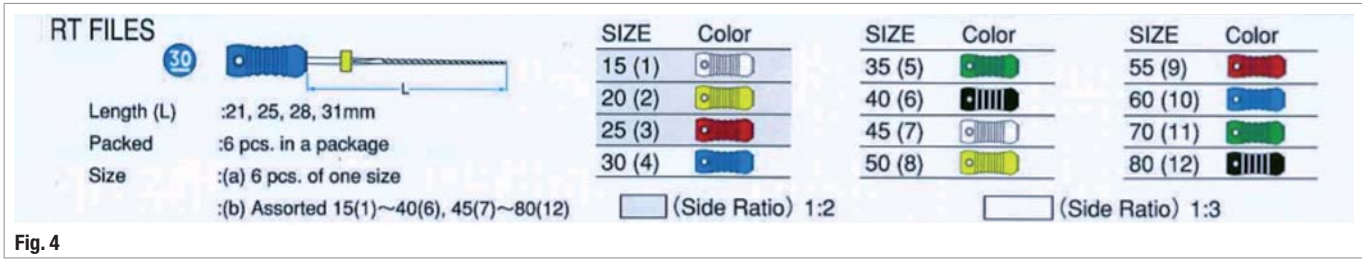


Fig. 4

Fig. 4_Mani RT Files.

- negotiable) the clinician can curve the file in their fingers without an EndoBender.
- h) Canals should always be negotiated with hand files prior to using RNT files. Even if the clinician uses a RNT glide path creator (PathFile, DENTSPLY Tulsa or PreShapers, SpecializedEndo), the canal should be first negotiated by hand to assure patency. Clinician preference dictates whether a glide path should be created by hand files or RNT files.
 - i) In the view of the author, hand files are single use disposable instruments as they dull rapidly during clinical function.
 - j) The use of nickel titanium hand files is a matter of personal preference. While some clinicians desire the flexibility and shape memory of nickel titanium hand files, others do not. It should be noted that nickel titanium hand files are available with controlled memory, a proprietary thermo mechanical process in which nickel titanium hand files lose their shape memory yet retain their flexibility.²⁻⁴
 - k) The principles of canal preparation must be observed, irrespective of the methods utilized to achieve these principles (i.e., hand file canal enlargement and/or RNT enlargement or a combination of these methods). These principles are to:
 - _leave the canal in its original position (simply enlarge it as described here);
 - _leave the minor constriction (MC) of the apical foramen at its original position and size;
 - _create a tapering funnel with narrowing cross sectional diameters from orifice to apex;
 - _create a master apical taper that optimizes irrigation and obturation hydraulics, and yet causes no iatrogenic events (strip perforation, canal transportation unnecessary dentin removal—and does not leave the tooth at risk of long term vertical fracture).

Fig. 5_Mani SEC O K and H Files.

_General classes of hand files

Files primarily designed for canal negotiation

In calcified canals, hand file stiffness is an attribute. Mani D Finder files are representative of this class and are especially useful for early negotiation of calcified canals. The D finders have a D shaped cross section. Some files utilize carbon steel in manufacture and/or possess atypical tip sizes to facilitate negotiation. Stiffness can be attributed to either the files design (Mani D Finders) or the use of carbon steel and/or a combination of carbon steel and a modified design (Pathfinder CS, Axis/SybronEndo) (Fig. 1).

K files

Generally, K files have a three or four-sided configuration with more spirals than a K reamer. Mani K Files are four-sided. Overall, K files are the most "universal" hand files covering the greatest number of clinical indications.

K files are not as flexible as hand files designed specifically for flexibility (such as the Mani Flexile files discussed below) or nickel titanium hand files. K files are used with a watch-winding hand motion and can be reciprocated (as described below). The angle between the cutting flutes and long axis of a K file is generally in the 25- to 40-degree range.⁵ Lexicon K Files are an additional example of another commercially available K file (DENTSPLY Tulsa).

K Reamers

Mani K Reamers are three-sided and contain fewer spirals than K files. Smaller reamers are generally square

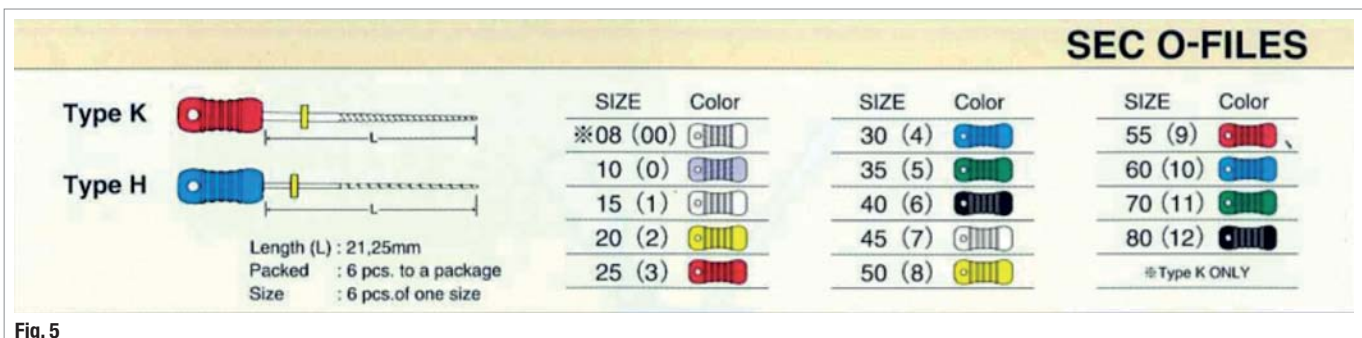


Fig. 5

in cross section. Larger reamer sizes are generally triangular. The angle between the cutting flutes and long axis of a reamer is most often in the 10- to 30-degree range.⁵

Reamers are used in rotation, unlike K files. Hand file rotation is associated with less canal transportation than K file watch winding.

The use of K reamers versus K files is a matter of personal preference. K type instruments of both types (reamers versus K files) should be manipulated carefully when used counterclockwise due to the risk of instrument fracture. Lexicon K Reamers are an additional example of a commercially available K reamer (DENTSPLY Tulsa)—these are triangular in cross section.

H files

H files (Mani H Files as well) have conical spirals ground into them. They are used on the pull stroke for gross removal of canal contents in the coronal third and in retreatment. H files should not be rotated due to fracture risk inherent in their design. The angle between the cutting flutes and long axis of an H file is generally in the 60- to 65-degree range.⁵

It is not advisable to use H files near the MC. The MC can be transported easily if H files are used at or beyond the MC. Clinically, aside from transportation, such an action lead to significant apical bleeding (Fig. 2).

Hand files of accentuated and variable taper

Mani Flare Files are more tapered than standard hand files—0.05 taper compared to 0.02 taper. They are used to prepare tapered canals for doctors who hand file the entire preparation among other more specialized uses such as verifying taper before cone fit.

Accentuated taper is also available with nickel titanium GT Hand Files. ProFile 0.04 Hand Files are 0.04 tapered and come in a variety of tip sizes, again in nickel titanium. ProTaper Universal Hand Files feature the ProTaper variable taper design in shaping and finishing files in various lengths (all of the above are manufactured by DENTSPLY Tulsa).

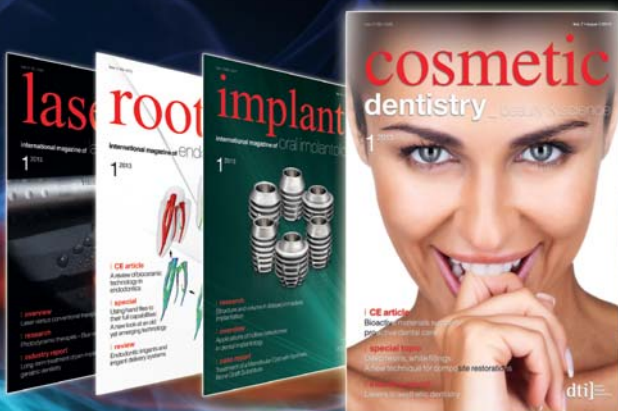Flexible Files

Mani Flexible Files are triangular in cross section. Files with a triangular cross section are more flexible

AD

cosmetic dentistry

_ beauty & science



One issue free of charge!

You can also subscribe via
www.oemus.com/abo

✂ Subscribe now!

- I hereby agree to receive a free trial subscription of **cosmetic dentistry** (4 issues per year). I would like to subscribe to **cosmetic dentistry** for € 44 including shipping and VAT for German customers, € 46 including shipping and VAT for customers outside of Germany, unless a written cancellation is sent within 14 days of the receipt of the trial subscription. The subscription will be renewed automatically every year until a written cancellation is sent to OEMUS MEDIA AG, Holbeinstr. 29, 04229 Leipzig, Germany, six weeks prior to the renewal date.

- ▶ **Reply** via Fax +49 341 48474-290 to OEMUS MEDIA AG or per E-mail to grasse@oemus-media.de

Last Name, First Name

Company

Street

ZIP/City/Country

E-mail

Signature

Notice of revocation: I am able to revoke the subscription within 14 days after my order by sending a written cancellation to OEMUS MEDIA AG, Holbeinstr. 29, 04229 Leipzig, Germany.

Signature

roots 1/13

than those with square cross sections. Flexible stainless steel hand files are generally used in easily negotiated canals. Clinician preference dictates whether to use flexible stainless steel files relative to nickel titanium hand instruments (Fig. 3).

Additional files in this class are Lexicon FlexSSK Files (DENTSPLY Tulsa). These files are also available in medium sizes (12, 17, 22, etc.).

Aggressive cutting files

Mani RT files (possessing a parallelogram cross-section) and a 71-degree cutting angle, making them more aggressive relative to many of the other files included here. RT files would be used primarily by doctors who are hand filing the entire canal in conjunction with other hand files (Fig. 4).

Nickel titanium files

GT Hand Files (made of nickel titanium) are available in various tapers and tip sizes (DENTSPLY Tulsa). Lexicon FlexNTK Files are made of nickel titanium and come in various tip sizes while maintaining a constant taper. As mentioned above, clinician preference dictates whether a flexible stainless steel file is more desirable than a nickel titanium hand file.

Medium sizes, K, H and reamers

Mani provides K Files, H Files and stainless-steel reamers in medium sizes (12, 17, 22, 27, etc.). ProFile Series 29 Stainless Steel 0.02 Hand Files have a constant 29 per cent increase in tip size in 0.02 taper. Use of medium sizes avoids the dramatic increase in tip diameter with increasing tip sizes, especially between a #10 and #15 hand file (a 50 per cent increase in size of the #15 relative to the #10 hand file).

Safe-ended hand files and reciprocation

Mani SEC O files are available in an H and K file variety. Both are "safe-ended," as they do not cut on their tips. The Mani SEC O K File is ideal for reciprocation. SEC O H files (and H files in general) are not reciprocated (Figs. 5 & 6).

Reciprocation is a very safe technique, whereby the clinician can use a reciprocating hand piece attachment to replicate manual hand file watch winding. Clinically, reciprocation is used after the canal has been negotiated to the TWL and reciprocation proceeds with the first file that binds at TWL. In this

article, the terms TWL and MC are synonymous. The purpose of reciprocation is to save time, reduce hand fatigue and prepare a space into which RNT files can subsequently be inserted with minimal torque stresses (prepare a glide path).

Reciprocation is inherently safe. It is difficult to fracture hand files when this technique is used appropriately. Fracture or iatrogenic misadventure generally occurs when the files are inappropriately placed (well beyond the MC), the wrong type of hand file is reciprocated (H) and/or the speed is grossly exaggerated above the recommended levels.

Reciprocating hand piece attachments fit onto an E-type coupling and can be powered at 900 rpm, for example at the 18:1 setting on an electric endodontic motor.

To initiate reciprocation, the file is left in the canal at the TWL and the reciprocating hand piece is placed over the file (the file is inserted into the head of the reciprocating hand piece and is held there while reciprocating). The attachment reciprocates the file clockwise and counter clockwise—for example, with a 30-degree clockwise and 30-degree counterclockwise movement. These attachments do not rotate the file a full 360 degrees—in contrast to how RNT files are powered. Different reciprocating hand pieces may have variations on the degree of clockwise or counterclockwise rotation and possibly include a vertical amplitude.

The Synea W&H-62A is an example of a reciprocating hand piece (MounceEndo) attachment with a 30-degree clockwise and 30-degree counterclockwise motion. Reciprocation is the technique and file motion utilized in the Wave One canal preparation system (DENTSPLY Tulsa).

Clinically, using the SEC O K File as an example, the SEC O K File is placed to the TWL, the attachment placed over the file and reciprocation commences as described above. The file is reciprocated for 15 to 30 seconds, using a 1- to 3-mm vertical amplitude movement. Clinically, the file will become less tightly bound as the canal is enlarged.

If, for example, a #08 SEC O K file is the first file that binds in the canal at TWL this file is reciprocated. Once the #08 SEC O K File is reciprocated, the canal will now accept a #10 SEC O K File to TWL. The #10 SEC O K File is reciprocated. Once reciprocation is complete, the canal will allow a #15 SEC O K File to reach the TWL. Once the canal is enlarged to approximately the size of a #15 or #20 hand file, the canal is ready for RNT enlargement.

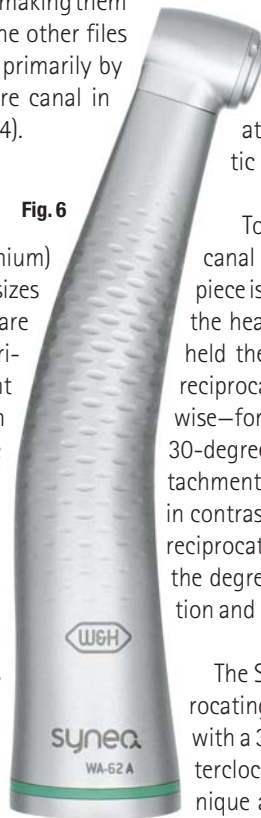


Fig. 6

Fig. 6_ The Synea W&H WA-62. A reciprocating hand piece attachment.



Fig. 7

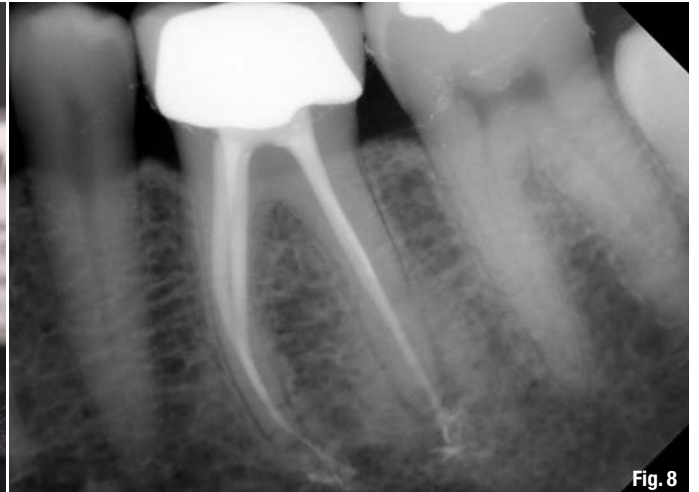

Fig. 8

Aside from glide path creation, this technique is especially helpful in early enlargement of calcified canals, especially the MB2 canal of upper molars. Reciprocation is also valuable for rubbing out iatrogenic ledges. Once the hand file can negotiate around the ledge, it is left in place and reciprocated as suggested above.

It is not advised to place a hand file in a reciprocating handpiece attachment and try to move the file apically while powering the file. While such a motion will work some of the time, it can accentuate ledges and other canal transportations and increase the risk of file fracture.

Integration of the glide path with early RNT shaping

If the clinician is using RNT shaping methods, the decision must be made to move either crown down, step back or possibly use a hybrid of the two strategies. While a comprehensive discussion of such RNT strategies is beyond the scope of this article, it has value to mention that judicious initial removal of restrictive dentin at the point of greatest root curvature (especially in complex cases) is essential to minimize subsequent iatrogenic events. Caution is advised. RNT fracture is a risk when the wrong taper and tip size RNT is inserted into an acute curvature (immediately after glide path creation) with unnecessary force. In essence, a strict crown down sequence may not be indicated.

Anatomically, the aforementioned greatest curvature tends to be in either the middle root third or at the junction of the middle and apical thirds. Clinically, in complex multiplanar curvatures, after glide path preparation, regardless of whether the glide path was made with reciprocation or with a nickel titanium instrument, using a relatively smaller taper and tip size RNT file (for example, a 0.02/20, 0.03/20,

or 0.04/20 file such as the MounceFile CM (controlled memory) can minimize the risk of subsequent fracture that may otherwise result in moving directly to a strict crown down approach around such a curvature. Fracture risk is minimized with the removal of restrictive dentin along the curvature through use of the instruments above (Figs. 7 & 8).

Alternatively, instead of using the MounceFile, the clinician can make an equivalent enlargement through the curvature using a 0.04/25 Twisted File (Axis/Sybron) or similarly sized RNT file.

This article, written for the general dentist, has described common attributes of hand files, their clinical use, reciprocation, and integration of glide path preparation with initial shaping procedures. Emphasis has been placed on interpreting tactile feedback and avoidance of iatrogenic events. Your feedback is welcome.

Editorial note: A complete list of references is available from the publisher.

about the author

roots



Dr Rich Mounce is in full time endodontic practice in Rapid City, SD. He is the owner of MounceEndo LLC and an endodontic supply company marketing the MounceFile in Controlled Memory© and Standard

Nickel Titanium (SNT). MounceEndo is an authorized dealer of Mani Inc. products and W&H reciprocating hand piece attachments in USA. He can be reached at RichardMounce@MounceEndo.com, MounceEndo.com, Twitter: @MounceEndo

Fig. 7 The MounceFile Controlled Memory nickel titanium files.

Fig. 8 Clinical case treated using the reciprocating technique described and the MounceFile in Controlled Memory.

Twisted Files changed the world of endodontics

Case report

Author_ Dr Sorin Sirbu, Romania

Fig. 1_TF 25.12 to 25.04 files.

Fig. 2_The 25.12 file is beginning to untwist near the tip because of overworking. This file must be replaced immediately.

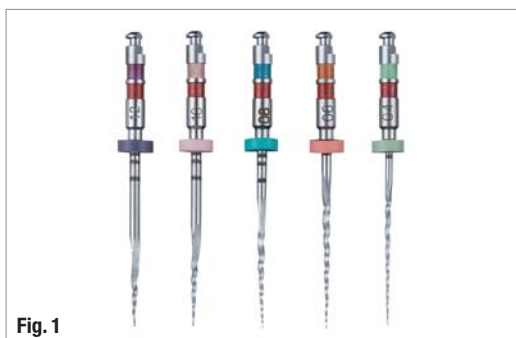

Fig. 1

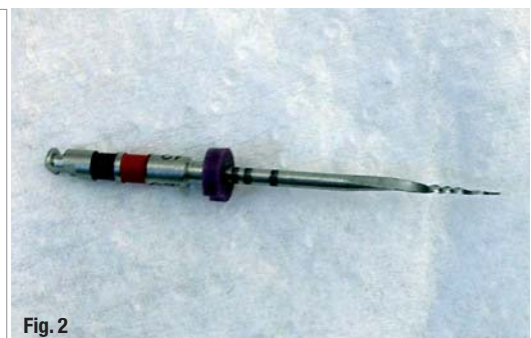

Fig. 2

_Introduction

There are many rotary systems on the dental market at present. All of these systems are relatively similar, except for one. This system is called Twisted Files (TF) and it was introduced to the dental market in 2008. I am glad to have been among the first users of this system, which has changed the endodontic world. How does this system differ from other rotary

systems? Firstly, by its unique machining—which is a SybronEndo patent.

The NiTi wire is brought into a special state (called R-Phase) that allows the twisting of the file. This makes TF distinct from all the other systems, for which the shape of the file is machined by milling, a mechanical process. This unique procedure lends particular resistance to TF, as well as an extraordinary

Fig. 3_Clinical examination of tooth 26 revealed a composite filling.

Fig. 4_The initial radiographic examination showed a massive composite filling.

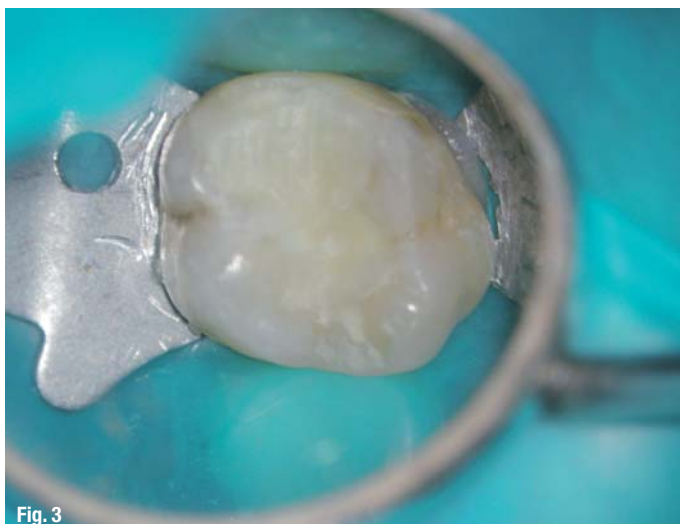

Fig. 3

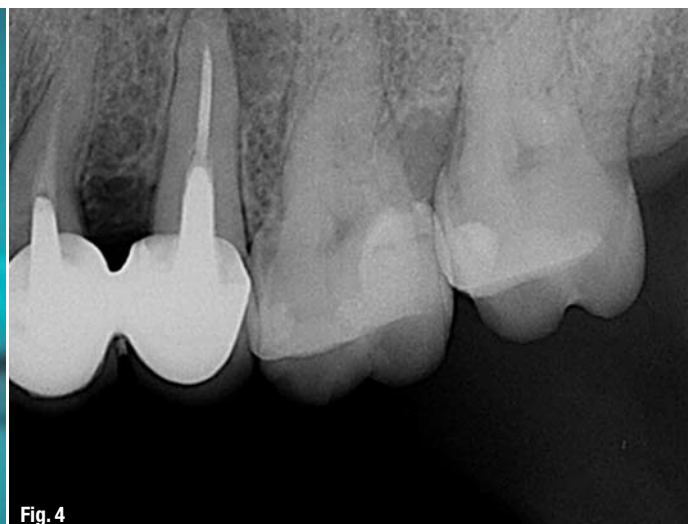

Fig. 4

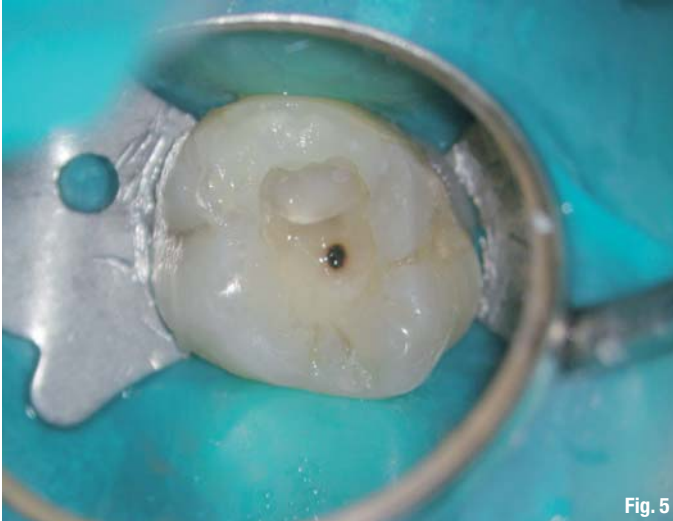

Fig. 5

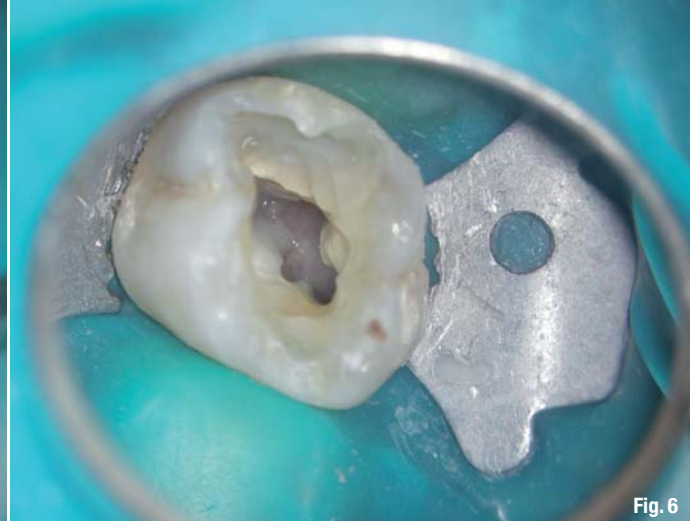

Fig. 6

flexibility. Owing to this manufacturing technique, a TF untwists before breaking, warning the dentist in this way. In addition, being made by twisting and not by polishing/milling, all the microcracks are eliminated, resulting in a more resistant, more robust file. The manufacturing process is completed by applying an advanced surface conditioning treatment that makes the edges active (cutting).

The tip of a TF is inactive, which allows it to follow the route of the canal easily and to minimise canal transportation. The working sequence with this system is terribly easy and consequently working time is reduced.

The files may be recognised and differentiated by the help of the practical system of codification. There are two coloured rings: the lower one (closer to the active part) shows the apical diameter (ISO standard; for example: red = 25) and the upper one shows the taper size (Fig. 1). Two working lengths are available: 23 and 27 mm.

The clinical procedure

In this part, I will describe the TF technique. Treatment with TF always begins by creating a glide path in the canals with #6 to 20 K-files. After opening and access, treatment inside the canal begins. In the absence of adequate access into the canal, there is the risk of overworking the file and its subsequent fracture. By opening the canals with K-files, important information about the anatomy of the root canal is obtained, such as the existence of curves and the diameter of the root canal.

Generally, the first TF that is introduced into the canal is TF 25.08 (the apical diameter is 25 mm and it has a taper of 8%), which in most cases will reach the working length previously detected by means of an apex locator. The endodontic engine must be set at 500 rpm and the torque at 2 Ncm. The file is introduced into the canal in rotation and without pressure applied. It is sufficient to advance 2 to 4 mm when introducing the file into the canal. If the file does not

Fig. 5 After removing the composite filling, a secondary occlusal decay was observed.

Fig. 6 The opening of the pulp chamber in tooth 26 and the identification of the canals.

Fig. 7 The shaped canals ready for endodontic obturation using the warm vertical condensation technique.

Fig. 8 The canals obturated by means of the warm vertical condensation technique.

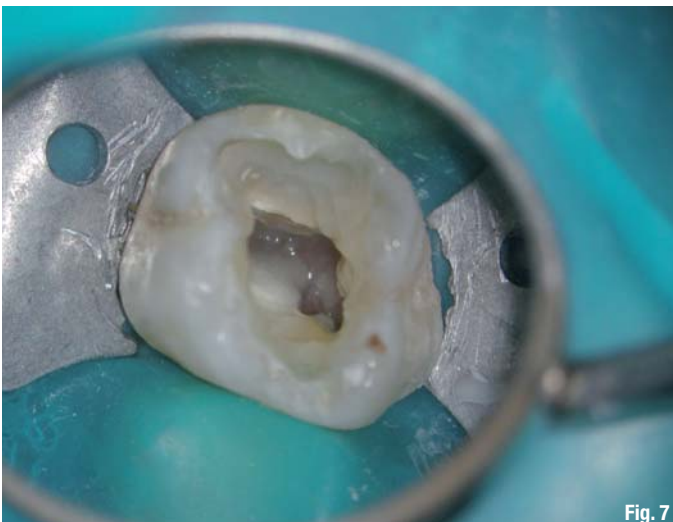

Fig. 7

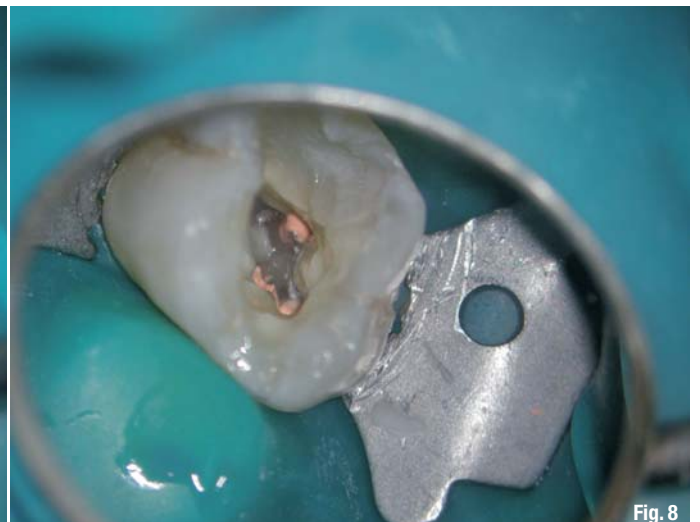

Fig. 8

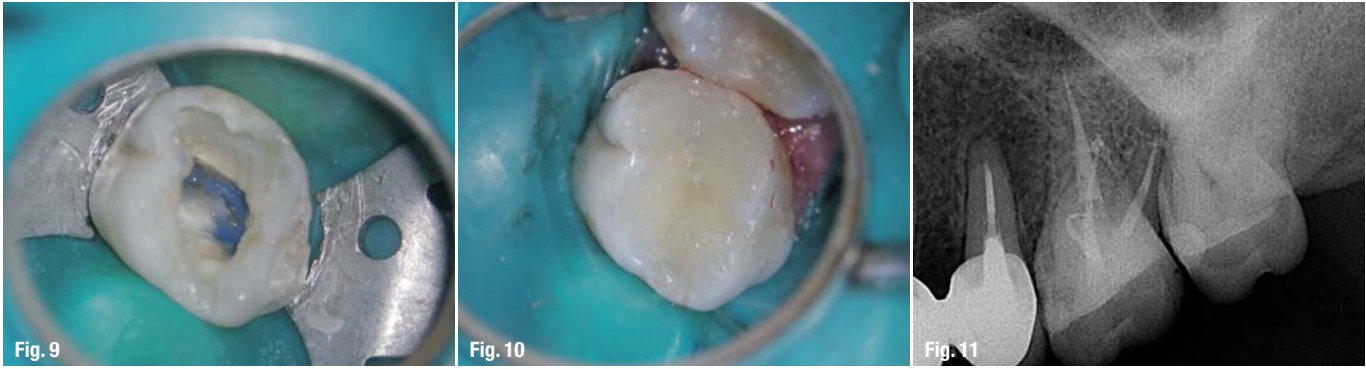


Fig. 9_The sealing of the root canals using RxFlow composite.

Fig. 10_The final composite restoration.

Fig. 11_The final X-ray showing all four obturated canals.

advance, then a file with a smaller taper (TF 25.06) must be used instead to achieve working length.

During preparation, there must be sodium hypochlorite in the root canal at all times. The file is cleaned and examined to detect possible distortion before introduction to the canal and upon withdrawal. If the file exhibits some distortion, it must be replaced (Fig. 2). If TF 25.08 reaches working length easily, then a file with a greater taper can be used (TF 25.10 or 25.12).

After reaching the desired taper, the final apical diameter is prepared. There are many studies in the endodontic literature that have found that apical preparation up to a #25 K-file is insufficient. For this reason, after reaching the taper the TF 30.06 or 35.06 or both are used. If greater apical diameters are desired, TF 40.04 or 50.04 can be used. The greater the apical diameter is, the greater the quantities of irrigation that reach the apex will be and the cleaner the apex will be. It is generally known that apical preparation by means of rotary files with large diameters can create many problems because of the stiffness of the rotary files, such as transportation of the apex and changes to the root-canal anatomy. With TF, however, this does not occur, owing to the unique machining process, which ensures that the files are flexible, even those with large apical diameters.

_Case 1

The patient came to our clinic with acute apical periodontitis around tooth 26. When examined clinically and radiographically, the tooth showed a large composite filling next to the distal pulp horn (Figs. 3 & 4). The periodontal examination did not find any irregularities; however, the tooth was extremely painful in vitality tests. Initially, I intended to replace the composite filling. After removing the old composite filling, I noticed secondary decay that reached up to the pulp chamber (Fig. 5) and I subsequently decided to pursue endodontic treatment.

The treatment was performed in one session. Four canals were identified (MB, MB2, DB and P; Fig. 6). The main problem was in the MB2 canal, which had a 90-degree curvature. The treatment was performed with TF 25.06 in the MB2 canal and with TF 25.08 in the other canals (Fig. 7). As a final irrigant, I used SmearClear (SybronEndo). After obturating the canals with warm vertical condensation using the Elements Obturation Unit (SybronEndo; Fig. 8), the canals were sealed with a coloured composite (RxFlow, Dental Life Sciences; Fig. 9). Finally, the tooth was restored with a composite filling (Fig. 10) and the control X-ray was taken (Fig. 11).

Fig. 12_Tooth 37 at the initial clinic examination.

Fig. 13_The initial radiographic examination of tooth 37.

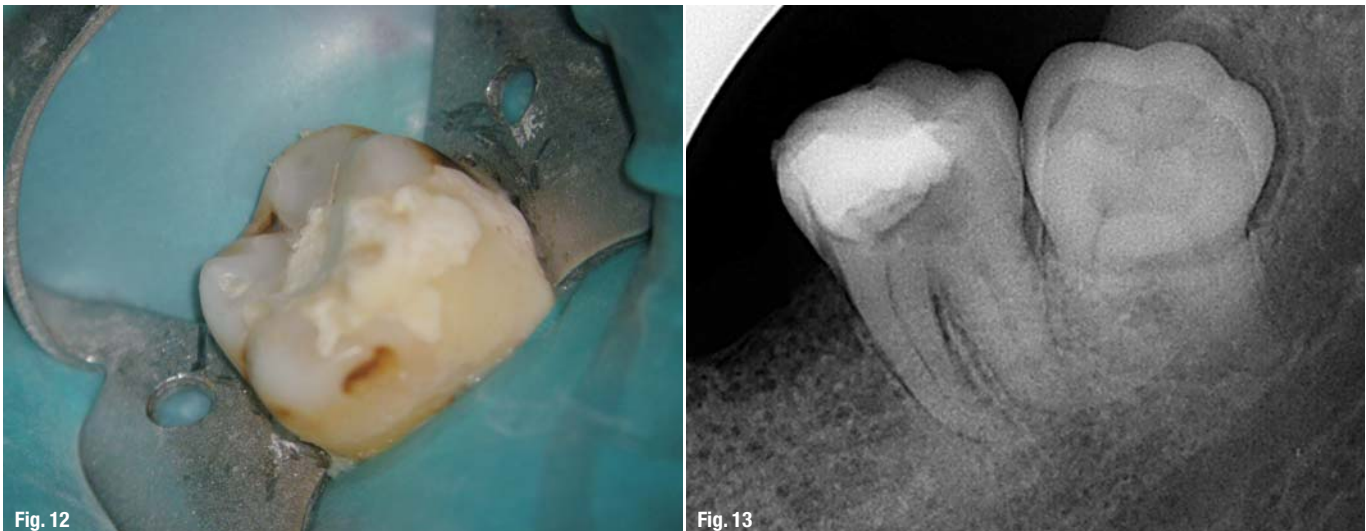

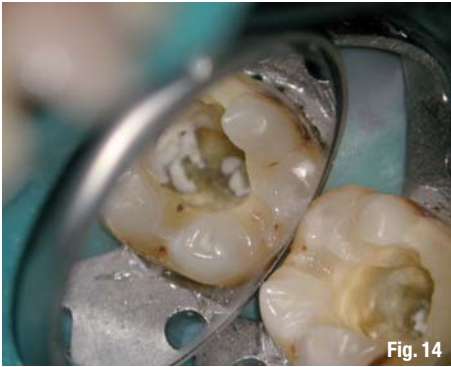


Fig. 14

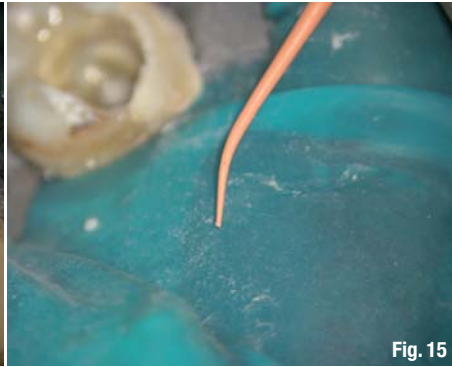


Fig. 15

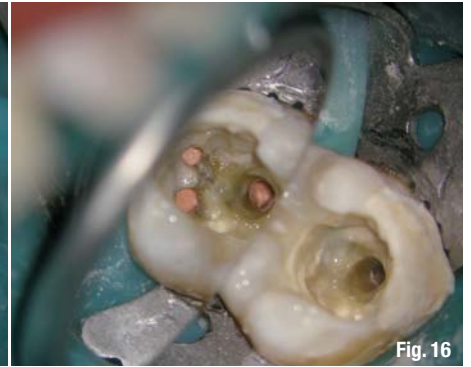

Fig. 16

Case 2

The patient was referred to our clinic by another doctor who had come across difficulties when identifying and working in the canals of tooth 37. The presence of a temporary filling done during previous treatment was observed during the clinical examination (Fig. 12). An initial X-ray was taken to identify any possible associated pathology, the presence of canals, etc. (Fig. 13).

After removing the temporary filling, three root canals were identified, shaped and cleaned (Fig. 14). The treatment was performed with TF 25.10 up to 40.04. The MB and ML canals merged, as shown by the file impression from the MB canal on the gutta-percha cone (Fig. 15). The final irrigation was done with SmearClear. The tooth was obturated with warm vertical condensation using the Elements Obturation Unit (Fig. 16), and finally restored with composite material and a fibreglass post (Fig. 17).

The control X-ray showed that the root canal and numerous accessory canals (Fig. 18) had been properly cleaned and obturated due to working with TF rotary files and negative irrigation with EndoVac (SybronEndo).

Conclusion

TF permits treatment even in the most difficult clinical situations and is essential to the dentist. Using TF, it is possible to widen the apex up to a #50 K-file without the risk of transporting the apex. In addition, owing to its unique machining, TF untwists before separating in the canal, thereby giving the dentist timely warning to replace the file and significantly decreasing the risk of accidents while working with the rotary files. Another major advantage is that this system aids the maintenance of the root-canal anatomy owing to the remarkable flexibility of the files.

Fig. 14 Shaped and cleaned canals.
Fig. 15 The impression left by the file on the gutta-percha cone attested to the merging of the MB and ML canals.
Fig. 16 Final endodontic obturation by means of the warm vertical condensation technique.

_about the author	roots
	<p>Dr Sorin Sirbu graduated from the Carol Davila University of Medicine and Pharmacy in Bucharest in Romania. At present, he works in a private dental practice in Bucharest.</p>

Fig. 17 Tooth 37 restored using composite material and a fibreglass post.
Fig. 18 The final X-ray.

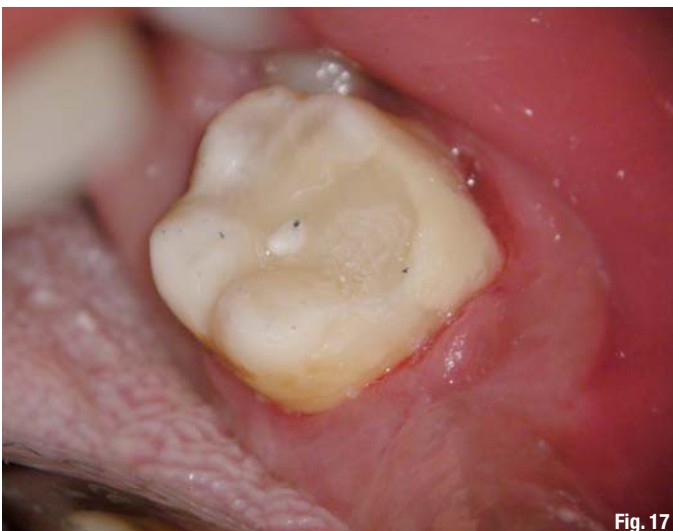

Fig. 17

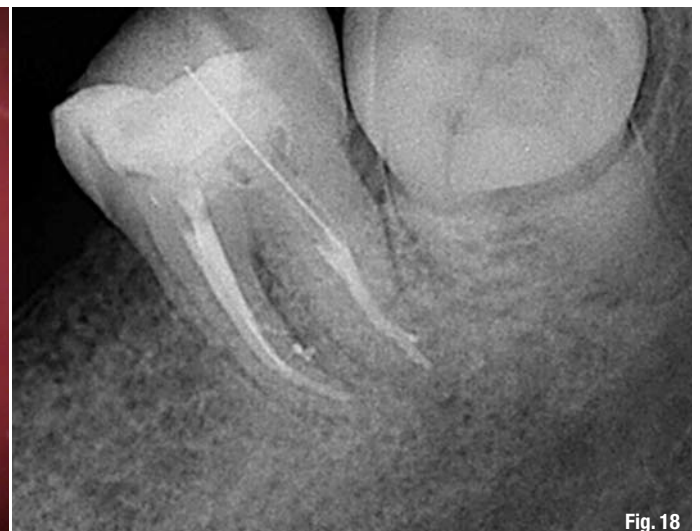

Fig. 18

INITIAL[®]: The beginning of a new era for endodontic instrumentation?

Authors_ Dr Matthieu Pérard, Dr Justine Le Clerc, Prof. Pierre Colon & Prof. Jean-Marie Vulcain, France

_Abstract

In the past three decades, numerous endodontic instruments have been developed to replace traditional steel manual instruments (pulp broaches, K- and H-files), yet sometimes these developments have not offered the clinical benefits expected. The eighties saw the appearance of more sophisticated instruments, still steel, such as the Unifile (DENTSPLY), Canal Master U (BRASSELER), Rispi Sonic and Shaper Sonic (MICRO-MEGA). The nineties and the new century saw an explosion of NiTi instruments; endodontic instrument shapes and methods multiplied to the point that it was sometimes difficult to keep up. Some developments were quickly forgotten, others were widely adopted and remain standards.

_Introduction

During endodontic treatment, after preparation of the access cavity and first shaping of the canals using a #8, 10 or 15/100 manual file, the practitioner seeks to widen the canal entrance. This amounts to preparing the coronal third, which in turn allows instruments to penetrate to the approximate level of the cemento-enamel junction. This facilitates root filling.^{1,2}

Enlarging the canal entrance is performed either with conventional manual or mechanical instruments or with instruments designed for this purpose, such as the ProTaper Universal SX (DENTSPLY Maillefer) or ENDOFLARE (MICRO-MEGA), or with Gates-Glidden or other drills.^{3,4} Numerous studies have shown the importance of this step prior to root-canal preparation.⁵⁻¹¹

INITIAL is a novel instrument for flaring the coronal third of the canal. The instrument is original in its manufacturing process, its geometry and its motion. This universal opener is used prior to specific instruments for canal preparation (Fig. 1). It is made of NiTi and it allows continuous rotation or variable-speed reciprocating motion, acts like an enlarger to a maximum of 10 mm and can be used with a circumferential motion, owing to its blade design.

_Indications

INITIAL is intended to shape the coronal third of a canal, on average a length of 5 mm up to a maximum of 10 mm, depending on the tooth's anatomy. This preliminary preparation using INITIAL facilitates the subsequent passage of any sort of canal preparation instrument down to the apex (Fig. 2). It also allows the elimination of dentinal irregularities at the level of the access cavity and facilitates access to the canal orifice. INITIAL is not intended to reach the apical region but rather is designed to widen and flare the access.



Fig. 1

Fig. 1_The INITIAL endodontic file.

The recently launched Initial (NEOLIX), while on the surface just another new instrument for enlarging canals, deserves close attention because of its innovative manufacturing process, its shape, its functionality and its compatibility with the techniques currently in use. It is an instrument that approaches endodontics differently, perhaps introducing a new era for mechanical endodontic instrumentation.

Characteristics

INITIAL is a Class IIa medical device according to Council Directive 93/42/EEC, with the following characteristics:

It is an endodontic drill made of NiTi consisting of a blade mounted on a 15 mm mandrel, the active portion of which is 10 mm long.

The active part is itself divided into two distinct areas. The first, the apical part, guides the instrument to the canal lumen and is shaped as a square K-file, 2.5 mm long with an apical diameter of 25/100 mm. The second area, the medio-coronal, with a median diameter of 7.5 mm, has a double orientation at the cutting edges of a spiral, one radial (as traditionally found on endodontic instruments) that works tangentially¹² and the other axial, working concomitantly on the canal walls directly. The combined action of these two orientations limits the screwing action and allows the canal entrance to be enlarged safely.

The taper is 12%, as for other enlarging instrument. The inactive portion of the blade has an octagonal cross-section with a diagonal (equivalent to diameter) reduced to 0.90 mm. This increases the flexibility of the upper part of the instrument, provides better visibility, allows access to the cavity and should a file break facilitates grasping the piece with endodontic pliers.

The chuck is 12 mm and a standard diameter of 2.35 mm allows the instrument to be used with all endodontic contra-angle handpieces (Fig. 3).

The combination of the dual orientation of the cutting edge requires either continuous mechanised rotation or reciprocating motion. This is a characteristic of INITIAL, which can be driven by a rotary engine, either Marathon Endo-a-class or Marathon Endo-e-class (NEOLIX), but any other continuous rotation motor with electronic control of speed and torque will suffice (Fig. 4).

In order to exploit the properties of INITIAL optimally, the I-Endo dual (SATELEC ACTEON) motor is recommended because it is programmable and compatible with the characteristics of INITIAL (Fig. 5).

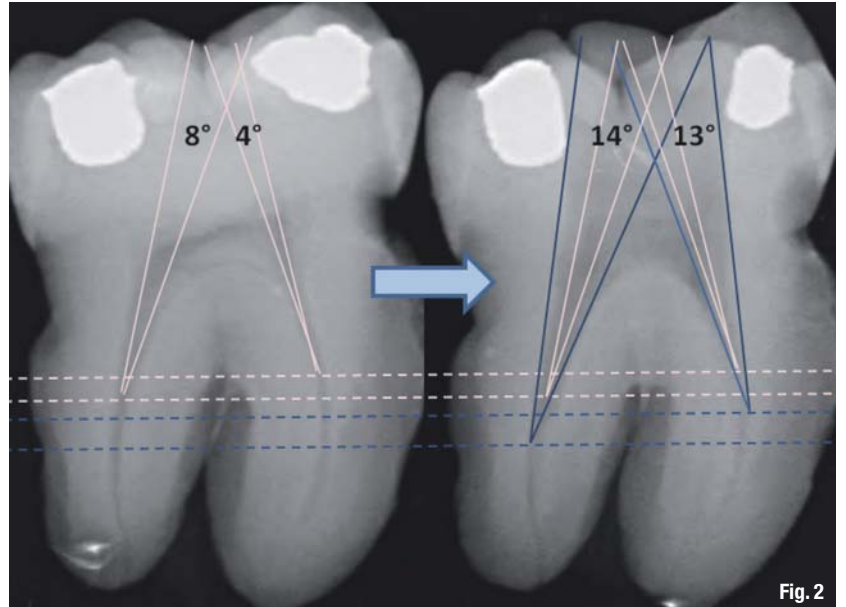


Fig. 2

For smoothing coronal canal walls, it is possible to program, if the operator so wishes, a routine of 360-degree continuous clockwise rotation followed by counter-clockwise rotation limited to 180 or 60 degrees, as helped to define extra-oral trials (Fig. 6).

Fig. 2 Radiograph before and after use of INITIAL (laboratory study): observe the angles of the canal-access passages, which increase significantly after the use of INITIAL.

Recommended speeds vary from 300 to 500 rpm according to the anatomical context. Like any endodontic instrument, INITIAL should have a rotary motion suitable for the clinical situation. It is wise to commence with a slow speed when entering a canal channel, which can be increased once the instrument has freed itself from constraints.¹³

In cases in which penetration is difficult owing to obstruction by secondary dentine (calcification) or in the presence of high curvature, a reciprocating motion can be established.¹⁴ This entails a 360-degree rotation and a clearance movement of 180 to 60 degrees performed by the I-Endo dual engine; during this disengagement movement, tangential force diminishes in favour of the direct motion. This is therefore a period of enlargement without of the instrument progressing into the canal.

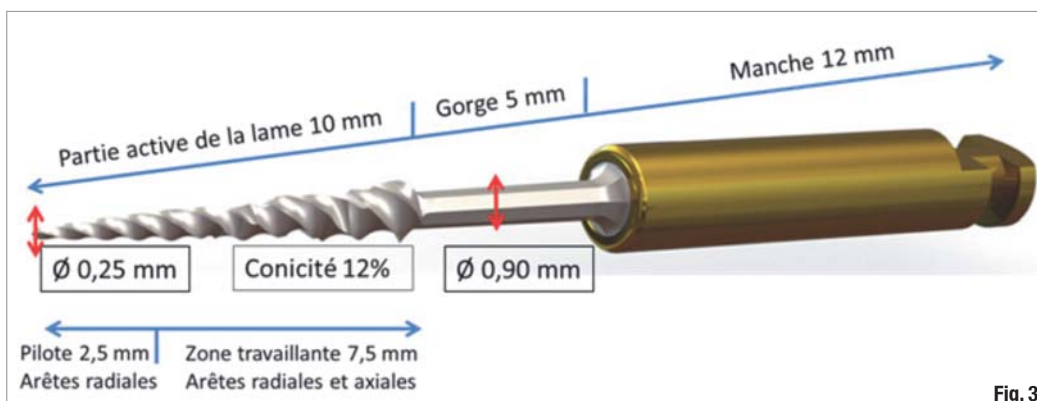


Fig. 3

Fig. 3 Dimensional characteristics of INITIAL.

Characteristics	INITIAL (Neolix)	ENDOFLARE (Micro-Mega)	ProTaper Universal SX (DENTSPLY-Maillefer)
Manufacturing process	WEDM	Micro-grinding	Micro-grinding
Surface treatment	Electro-scouring	Electro-polishing	Electro-polishing
Aspect	Matt	Shiny	Shiny
Penetration capacity (mm)	15	15	20
Active zone (mm)	10	10	14
Apical diameter (mm)	25/100	25/100	19/100
Taper (%)	12	12	Progressive, 3.5 to 8.5
Number of cutting edges	4	3	3
Cross-section active zone	Quadrangular	Triangular	Triangular
Cross-section inactive zone	Octahedral	Circular	Circular
Flutes	Concave	Concave	Reinforced by a convex bar
Cutting edges	Tangential and direct	Tangential	Tangential
Motion type	Continuous rotation or reciprocating	Continuous rotation	Continuous rotation
Speed (rpm)	300 to 500	300 to 600	300
Maximum torque (N cm)	3	3	2
Mandrel standard diameter (mm)	2.35	2.35, or InGet shaft	2.35

Table 1

Table 1 Characteristics of endodontic instruments used to prepare the coronal part of the canal.

Comparative characteristics of INITIAL and two currently used enlarging instruments

The usual reason for using Gates-Glidden, Largo and other enlarging drills, and NiTi enlarging instruments (DENTSPLY Maillefer; MICRO-MEGA) is to prepare the coronal part of the canal while respecting the original anatomy.¹⁵ Every enlarging instruments has different characteristics, as shown in Table 1.

The place of initial in a classical endodontic protocol

1. Take an essential preoperative radiograph to assess the initial root-canal anatomy and the complexity of the canals and to estimate the working length.
2. After placing the rubber dam, open the pulp chamber of the tooth for extirpation.
3. Debride the pulp chamber with ultrasounds and irrigate with an antiseptic.
4. Locate the canal entrances with a DG 16 probe (Hu-Friedy) and evaluate the glide path of the

Fig. 4 Marathon Endo-a-class and Endo-e-class, continuous rotation endodontic motors.

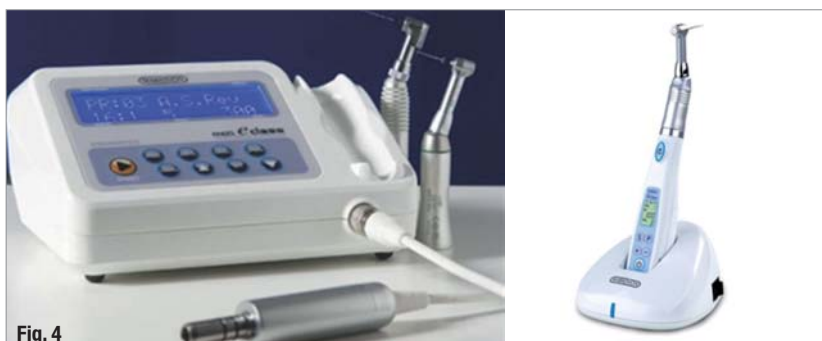

Fig. 4

different canals using #8, 10 or 15 K-files. These preliminary procedures allow the directions of the canals to be determined and the difficulty of the preparation to be assessed.

5. Use INITIAL mounted on an endodontic contra-angle handpiece (16:1 reduction) on a motor with programmable speed (initially 300rpm) and torque limited to a maximum of 3 Ncm. Prepare to a depth of 5 mm, with a circumferential motion, then irrigate thoroughly; the maximum depth should not go beyond the beginning of the first curvature. A depth of 10 mm should be considered the maximum (Fig. 7a).
6. Determine the working length electronically or by preoperative intra-oral radiograph.
7. Continue mechanical preparation, using your preferred instruments. All systems using continuous rotation or reciprocating motion are compatible with INITIAL. Do not neglect irrigation.
8. INITIAL can also be used during preparation to reposition the root-canal entrances (Fig. 7b), possibly using reciprocating motion (Fig. 8).
9. Continue the preparation to the apical cemento-dentinal junction using the technology of your choice.
10. Seal and control.

Discussion

Why focus on this new instrument? Firstly, because the machining technology is entirely innovative; secondly, for its new, variable changing profile; and, finally, for its clinical functionality, safety, comfort in use and universality that make this new approach to endodontics something not to be ignored.

Machining

Most endodontic instruments are machined by micro-grinding.¹⁶ This manufacturing method, in use for many years, is still limited in its ability to produce complex shapes. Indeed, with the micro-grinding method, the cutting tool is the grinding wheel, which has a fixed shape, and it imposes on the object a 3-D inverse profile. Thus, the geometry of the object after micro-grinding is pre-determined by the shape of the grinding wheel. This is why almost all endodontic instruments have tangential cutting edges.¹² Furthermore, wear of the micro-grinding wheel requires constant adjustment to maintain the geometrical and dimensional characteristics of the instrument.

Initial is the first instrument to be machined differently. Its geometry is obtained by wire-cut electrical discharge machining (WEDM).¹⁷ This technique was developed initially in 1943 in the former USSR by Lazarenko¹⁸ and has been improved since then. It entails melting, vaporisation and removal of material within a complex dielectric field.^{19,20} The energy required for the machining is generated by electrical discharges passing between two electrodes and creating an electric arc between the workpiece and the tool (Fig. 9).¹⁷ The advantages of this technology are numerous. Firstly, the precision of the cut can be measured in microns;²¹ secondly, machining by localised microfusion then suppresses any mechanical stress during manufacture, thus avoiding micro-defects and changes in surface properties of the metal by atomic dislocations

(defects in the alignment of atoms); thirdly, the metal remains intact, as if it had not been machined; and, finally, machining parameters remain stable because the cathode wire that conducts electricity is the only piece that suffers wear. This technology can provide an almost total freedom for the production of various geometric designs because there are no constraints due to a grinding tool. In addition, compared with grinding, EDM is more environmentally friendly because it does not require cutting oil, organic solvents or harsh detergents, all of which are toxic to varying degrees.

WEDM is traditionally used in industrial sectors such as aerospace, nuclear, medical, general engineering, automotive, and machine tools to create complex shapes and articles on a small scale because the technology is difficult to implement.²²

This process has recently been modified for the large-scale production of endodontic instruments; it involves a dual-wire electrode, consisting of the instrument being manufactured and a mobile EDM wire, yielding very high machining accuracy, step by step and without physical contact with the workpiece. With this method, the instrument shape is determined by the relative position in space of the EDM wire and the workpiece. The spatial positions of the EDM wire and that of the workpiece can potentially vary independently at any moment, thus allowing variation in the geometry of the part, which is not achievable by conventional machining techniques. Linked to a repetitive mechanism, this technology, innovative in the field of endodontics, differs from the other industrial grinding processes that are conventionally available.

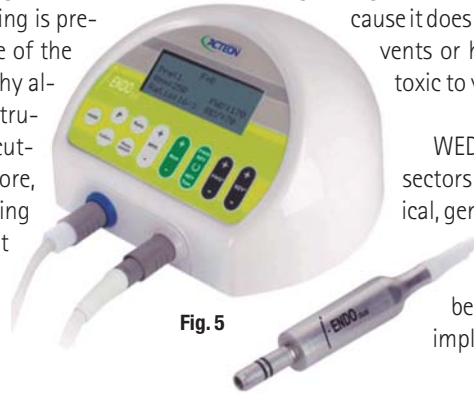

Fig. 5

Fig. 5_I-Endo dual, multifunction endodontic motor that provides a choice of continuous rotation or reciprocating motion.



Fig. 6_Reciprocating-motion sequences of INITIAL.
 Fig. 7a_Illustration of access-cavity flaring.
 Fig. 7b_Illustration of canal-access repositioning.

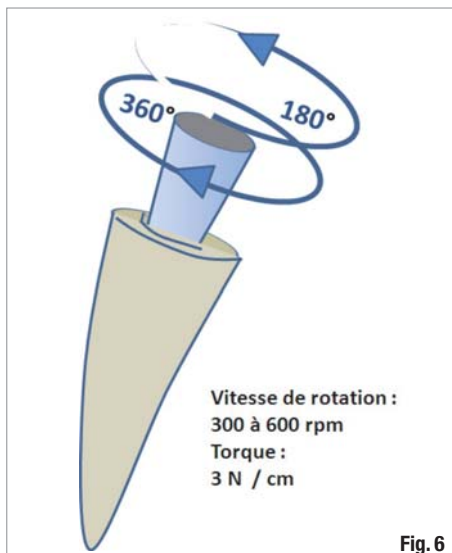


Fig. 6

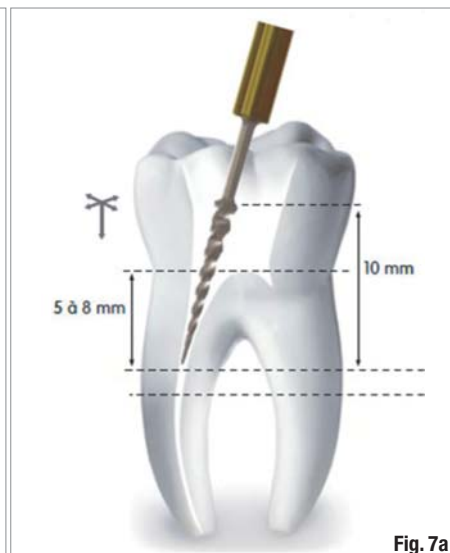


Fig. 7a

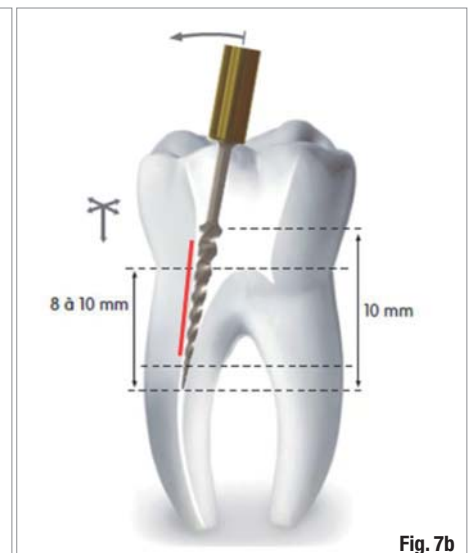


Fig. 7b

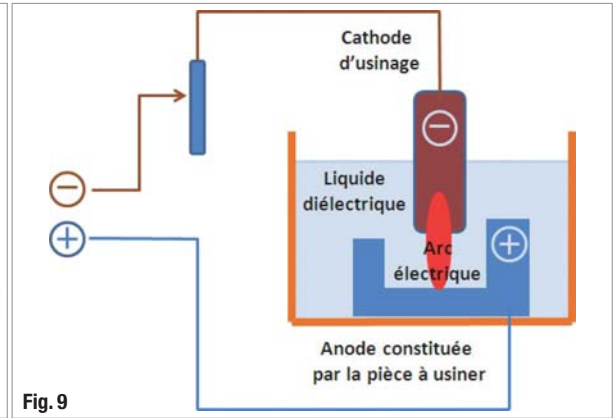
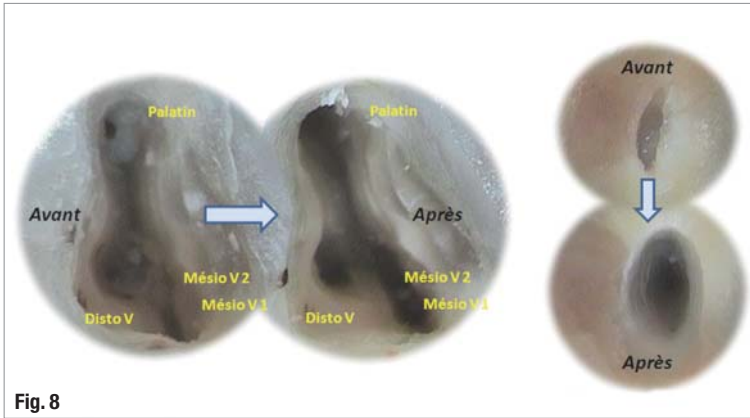


Fig. 8 Intracoronar photographs of preparation before and after INITIAL showing access cavities and canal entrances in teeth 26 and 33 as an example.
Fig. 9 Principle of EDM without contact between the machining tool and the workpiece.

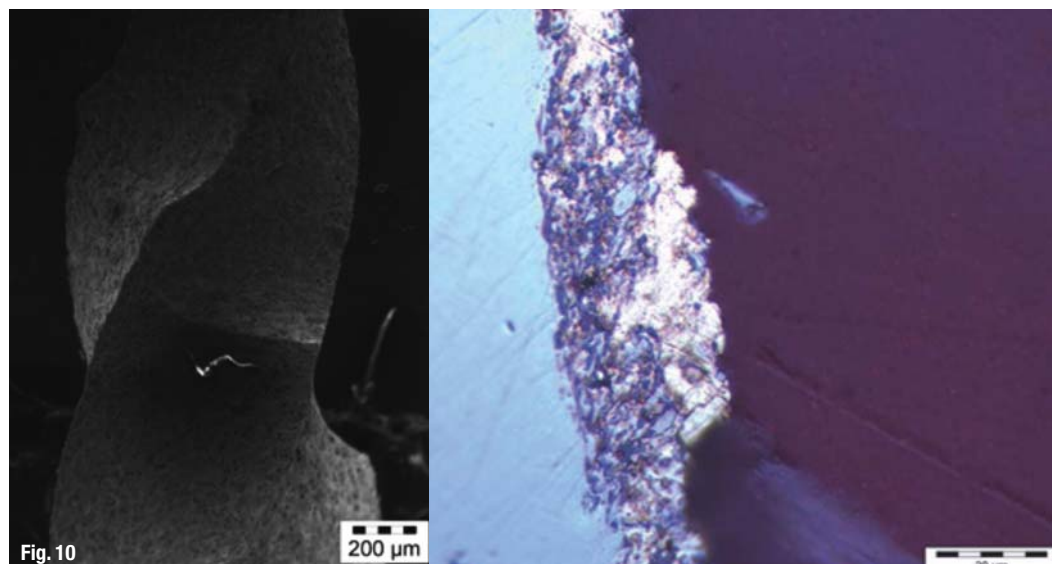
This process, which is applicable only to electrically conductive materials, can change the appearance of machined metal surfaces.¹⁷ In particular, the formation of irregular layers of metal oxides, 20 to 30 μ thick, has been demonstrated (Fig. 10). This condition requires that surfaces be chemically treated following EDM to remove the oxide layers (study of multi-materials and interfaces undertaken by the Laboratoire des Multimatériaux et Interfaces, a research unit of the National Centre for Scientific Research and Université Claude Bernard Lyon 1), while deeper in the material there is an increase in hardness and increased resistance to corrosion and wear.¹⁷ The surface of the instrument remains uneven, and it requires a specific chemical treatment to rid the instrument of these oxide layers while preserving the quality of cut. This treatment helps to strengthen the resistance of the instrument's surface and limits the risk of crack initiation.¹⁷ In order to reduce fatigue to the base value of the material, it is necessary to remove the altered layer entirely (Fig. 11).¹⁷ In the case of INITIAL, measurement of the torsional resistance, 3 mm from the tip in accordance with standardised ISO tests (ref. 3630-1) with a SOMFY-TAC (Metil Industrie) torsion meter, gives values compa-

table to those obtained for the similar NiTi orifice drills such as the ENDOFLARE (335 cN.cm for INITIAL with a standard deviation of 16.3, compared with 322 cN.cm for the ENDOFLARE with a standard deviation of 38.5). Values were almost the same when measuring at 45 degrees of flexion, 3 mm from the tip (126 cN.cm for INITIAL with a standard deviation of 8.3, compared with 134 cN.cm for the ENDOFLARE with a standard deviation of 3.2). Comparison with the SX is more difficult, given the dimensional configuration of the latter, which is more flexible than other enlarging instruments (15 cN.cm with a standard deviation of 2.5), but it has significantly less torsional strength (43 cN.cm with a standard deviation of 2.3). The higher the torque, the more resistant is the instrument, whereas the higher the bending moment, the less flexible is the instrument.

Variable profile

The shape of INITIAL is original because it develops a dual geometry. The active blade has four tangential cutting edges, a pitch of 3.6 mm in the apical portion (0 to 2 mm), 4.5 mm in the median portion (2 to 6 mm) and 6 mm in the coronal portion (6 to 10 mm). The blade

Fig. 10 The layers of metal oxides after WEDM (Laboratoire des Multimatériaux et Interfaces).



also has frontal edges spaced 1.4 to 1.6mm apart, depending on the portion but only on the 7.5mm above the apical portion. These characteristics make INITIAL a very complex instrument with a variable changing profile along the blade's working length. The cutting edges have the ability to work tangentially like any other flaring instrument, but also frontally. This last function, in addition to removing dentine from the canal walls, completes and limits the tangential engagement of the first and allows action restricted to the coronal portion. This also explains why INITIAL behaves and acts differently depending on the working motion.

Furthermore, the inactive blade is octagonal in cross-section, instead of the usual circular cross-section. This characteristic, in itself not important, could be an advantage in case of high fracture of the instrument; in such an event, it would be sufficient to twist the enlarging instrument counter-clockwise with endodontic pliers to remove the instrument from the canal.

If the dimensional characteristics and indications for use are at first glance similar to those of other orifice drills in the market, INITIAL can in no way be compared with them and the instrument performs very differently in clinical use.

Clinical functionality and general usefulness

Continuous rotation allows the instrument to develop a dynamic action, tangential to the canal walls, and to work like a conventional enlarging instrument, that is, to advance towards the apical region while widening the canal, owing to the instrument's 12% taper. All orifice drills have this property. This is why it is recommended that periodical checks be performed for blockage of the cutting edges, frequently observed on all the enlarging instruments, especially on the first few millimetres of the instrument, which serve to guide the penetration into root canals. For this reason, the use of a motor with torque control is recommended. Beyond the first 2.5mm, INITIAL will naturally be restrained in its progress by a direct force that is much more static and therefore opposes the screwing effect.

Using reciprocating motion with the I-Endo dual motor, particularly 360 degrees clockwise and 180 to 60 degrees counter-clockwise, potentiates the forward force and limits tangential dynamic cutting. This allows the canal enlargement to be enhanced and/or monitored without loss of direction.

These two actions, one tangential and dynamic, the other static and forward, make this instrument an all-in-one tool. Its use is indicated regardless of the technique, system or endodontic philosophy preferred by the clinician.

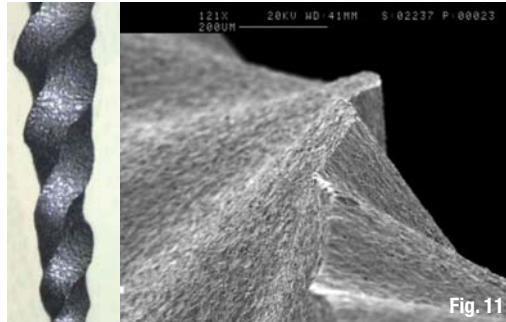


Fig. 11 Aspect of the surface after electro-scouring and electro-polishing under an optical and scanning electron microscope. (Image courtesy of University of Rennes 1.)

Conclusion

INITIAL is the first root-canal instrument to be machined by WEDM. Its geometry is more complex than other orifice drills. It has cutting edges that work tangentially like other endodontic drills and other edges for surface smoothing, with less torsional stress, allowing a more anatomical enlargement of the canal entrance. These simultaneous actions complement each other to limit blockage by debris and help prevent spontaneous instrument fracture, which facilitates the subsequent preparation of access to the apical part of the canal.

It is likely that these advantages of INITIAL will be incorporated into other root-canal instruments, which will thus more easily meet the operative, mechanical and biological requirements of endodontists. In this manner, initial may introduce a new era for endodontic instrumentation.

Editorial note: A complete list of references is available from the publisher.

_contact

roots



Prof. Jean-Marie Vulcain

Pôle d'Odontologie
CHU de Rennes
2 place Pasteur
35000 Rennes
France

Prof. Pierre Colon

PU-PH Faculté d'Odontologie
Université de Paris Diderot—Paris 7
APHP
UMR CNRS 5615 Lyon 1
France

Dr Matthieu Perard & Dr Justine Le Clerc

AHU Faculté d'Odontologie
Université de Rennes 1
CHU de Rennes
France

Endodontic irrigants and irrigant delivery systems

Author_ Dr Gary Glassman, Canada

_Endodontic treatment is a predictable procedure with high success rates. Success depends on a number of factors, including appropriate instrumentation, successful irrigation and decontamination of the root-canal space to the apices and in areas such as isthmuses. These steps must be followed by complete obturation of the root canals, and placement of a coronal seal, prior to restorative treatment.

Several irrigants and irrigant delivery systems are available, all of which behave differently and have relative advantages and disadvantages. Common root-canal irrigants include sodium hypochlorite (NaOCl), chlorhexidine gluconate, alcohol, hydrogen peroxide and ethylenediaminetetraacetic acid (EDTA). In selecting an irrigant and technique, consideration must be given to their efficacy and safety.

With the introduction of modern techniques, success rates of up to 98% are being achieved.¹ The ultimate goal of endodontic treatment per se is the prevention or treatment of apical periodontitis such that there is complete healing and an absence of infection,² while the overall long-term goal is the placement of a definitive, clinically successful restoration and preservation of the tooth. For these to be achieved, appropriate instrumentation, irrigation, decontamination and root-canal obturation must occur, as well as attainment of a coronal seal. There is evidence that apical periodontitis is a biofilm-induced disease.³ A biofilm is an aggregate of microorganisms in which cells adhere to each other and/or to a surface. These adherent cells are frequently embedded within a self-produced matrix of extracellular polymeric substance. The presence of microorganisms embedded in a biofilm and growing in the root-canal system is a key factor for the development of periapical lesions.⁴⁻⁷ Additionally, the root-canal system has a complex anatomy that consists of arborisations, isthmuses and cul-de-sacs that harbour organic tissue and bacterial contaminants (Fig. 1).⁸

The challenge for successful endodontic treatment has always been the removal of vital and necrotic rem-

nants of pulp tissue, debris generated during instrumentation, the dentine smear layer, micro-organisms, and micro-toxins from the root-canal system.⁹

Even with the use of rotary instrumentation, the nickel-titanium instruments currently available only act on the central body of the root canal, resulting in a reliance on irrigation to clean beyond what may be achieved by these instruments.¹⁰ In addition, *Enterococcus faecalis* and *Actinomyces* prevention or treatment of apical periodontitis such as *Actinomyces israelii*—which are both implicated in endodontic infections and in endodontic failure—penetrate deep into dentinal tubules, making their removal through mechanical instrumentation impossible.^{11,12} Finally, *E. faecalis* commonly expresses multidrug resistance,¹³⁻¹⁵ complicating treatment.

Therefore, a suitable irrigant and irrigant delivery system are essential for efficient irrigation and the success of endodontic treatment.¹⁶ Root-canal irrigants must not only be effective for dissolution of the organic of the dental pulp, but also effectively eliminate bacterial contamination and remove the smear layer—the organic and inorganic layer that is created on the wall of the root canal during instrumentation. The ability to deliver irrigants to the root-canal terminus in a safe manner without causing harm to the patient is as important as the efficacy of those irrigants.

Over the years, many irrigating agents have been tried in order to achieve tissue dissolution and bacterial decontamination. The desired attributes of a root-canal irrigant include the ability to dissolve necrotic and pulpal tissue, bacterial decontamination and a broad antimicrobial spectrum, the ability to enter deep into the dentinal tubules, biocompatibility and lack of toxicity, the ability to dissolve inorganic material and remove the smear layer, ease of use, and moderate cost.

As mentioned above, root-canal irrigants currently in use include hydrogen peroxide, NaOCl, EDTA, alcohol and chlorhexidine gluconate. Chlorhexidine

gluconate offers a wide antimicrobial spectrum, the main bacteria associated with endodontic infections (*E. faecalis* and *A. israelii*) are sensitive to it, and it is biocompatible, with no tissue toxicity to the periapical or surrounding tissue.¹⁷ Chlorhexidine gluconate, however, lacks the ability to dissolve necrotic tissue, which limits its usefulness. Hydrogen peroxide as a canal irrigant helps to remove debris by the physical act of irrigation, as well as through effervescing of the solution. However, while an effective anti-bacterial irrigant, hydrogen peroxide does not dissolve necrotic intra-canal tissue and exhibits toxicity to the surrounding tissue. Cases of tissue damage and facial nerve damage have been reported following use of hydrogen peroxide as a root-canal irrigant.¹⁸ Alcohol-based canal irrigants have antimicrobial activity too, but do not dissolve necrotic tissue.

such as NaOCl with EDTA are often used as initial and final rinses to circumvent the shortcomings of a single irrigant.³⁷⁻³⁹ These irrigants must be brought into direct contact with the entire canal-wall surfaces for effective action,^{20,37,40} particularly in the apical portions of small root canals.⁹

The combination of NaOCl and EDTA has been used worldwide for antiseptics of root-canal systems. The concentration of NaOCl used for root-canal irrigation ranges from 2.5 to 6%, depending on the country and local regulations; it has been shown, however, that tissue hydrolysis is greater at the higher end of this range, as demonstrated in a study by Hand et al. comparing 2.5 and 5.25% NaOCl. The higher concentration may also favour superior microbial outcomes.⁴¹ NaOCl has a broad antimicrobial spectrum,²⁰

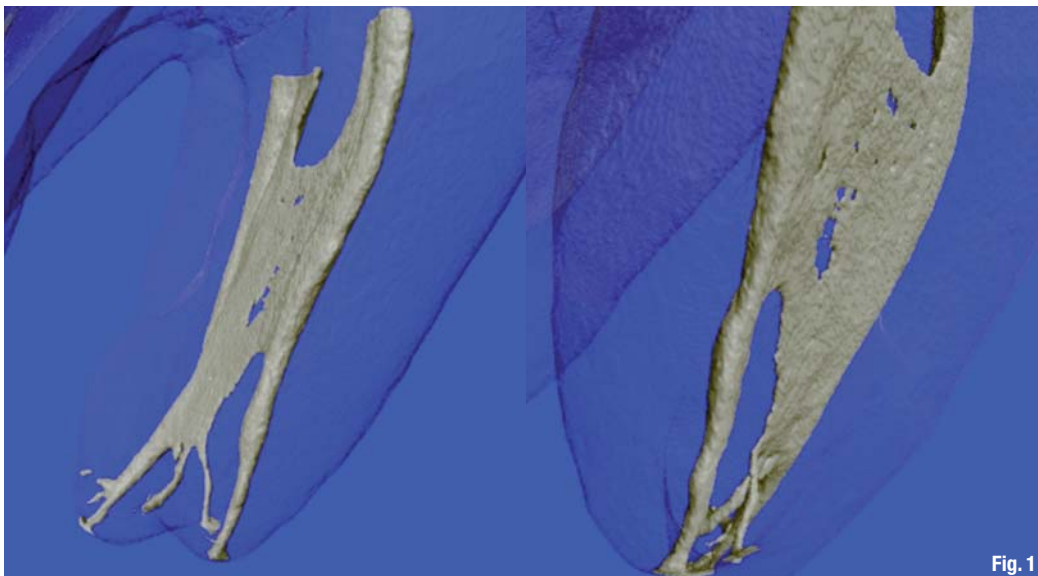


Fig. 1 _ Root-canal complex.
(Image courtesy of Dr Ronald Ordinala Zapata, Brazil.)
<http://www.facebook.com/TheInternalAnatomyOfTheHumanTeeth>

The irrigant that satisfies most of the requirements for a root-canal irrigant is NaOCl.^{19,20} It has the unique ability to dissolve necrotic tissue and the organic components of the smear layer.^{19,21,22} It also kills sessile endodontic pathogens organised in a biofilm.^{23,24} There is no other root-canal irrigant that can meet all these requirements, even with the use of methods such as lowering the pH,²⁵⁻²⁷ increasing the temperature,²⁸⁻³² or adding surfactants to increase the wetting efficacy of the irrigant.^{33,34} However, although NaOCl appears to be the most desirable single endodontic irrigant, it cannot dissolve inorganic dentine particles and thus cannot prevent the formation of a smear layer during instrumentation.³⁵

Calcifications hindering mechanical preparation are frequently encountered in the root-canal system, further complicating treatment. Demineralising agents such as EDTA have therefore been recommended as adjuvants in root-canal therapy.^{20,36} Thus, in contemporary endodontic practice, dual irrigants

including but not limited to *E. faecalis*. NaOCl is superior among irrigating agents that dissolve organic matter. EDTA is a chelating agent that aids in smear layer removal and increases dentine permeability,^{42,43} which will allow further irrigation with NaOCl to penetrate deep into the dentinal tubules.⁴⁴

_General safety precautions

Regardless of which irrigant and irrigation system is employed, and particularly if an irrigant with tissue toxicity is used, there are several general precautions that must be followed. A rubber dam must be used and a good seal obtained to ensure that no irrigant can spill from the pulp chamber into the oral cavity. If deep caries or a fracture is present adjacent to the rubber dam on the tooth being isolated, a temporary sealing material must be used prior to performing the procedure to ensure a good rubber dam seal. It is also important to protect the patient's eyes with safety glasses and protect clothing from irrigant splatter or spill.

It is very important to note that while NaOCl has unique properties that satisfy most requirements for a root-canal irrigant, it also exhibits tissue toxicity that can result in damage to the adjacent tissue, including nerve damage should NaOCl incidents occur during canal irrigation. Furthermore, Salzgeber reported in the 1970s that apical extrusion of an endodontic irrigant routinely occurred *in vivo*.⁴⁵ This highlights the importance of using devices and techniques that minimise or prevent this. NaOCl incidents are discussed later in this article.

_Irrigant delivery systems

Root-canal irrigation systems can be divided into two categories: manual agitation techniques and machine-assisted agitation techniques.⁹ Manual irrigation includes positive-pressure irrigation, which is commonly performed with a syringe and a side-vented needle. Machine-assisted irrigation techniques include sonics and ultrasonics, as well as newer systems such as the EndoVac (SybronEndo), which delivers apical negative-pressure irrigation,⁴⁶ the plastic rotary FFile (Plastic Endo),^{47,48} the Vibringe (Vibringe),⁴⁹ the Rinsendo (Air Techniques),⁹ and the EndoActivator (DENTSPLY Tulsa Dental Specialties).⁹ Two important factors that should be considered during the process of irrigation are whether the irrigation system can deliver the irrigant to the whole extent of the root-canal system, particularly to the apical third, and whether the irrigant is capable of debriding areas that could not be reached with mechanical instrumentation, such as lateral canals and isthmuses. When evaluating irrigation of the apical third, the phenomenon of apical vapour lock should be considered.⁵⁰⁻⁵²

_Apical vapour lock

Since roots are surrounded by the periodontium, and unless the root-canal foramen is open, the root canal behaves like a close-ended channel. This produces an apical vapour lock that resists displacement during instrumentation and final irrigation, thus preventing the flow of irrigant into the apical region and adequate debridement of the root-canal system.^{53,54} Apical vapour lock also results in gas entrapment at the apical third.⁹ During irrigation, NaOCl reacts with organic tissue in the root-canal system, and the resulting hydrolysis liberates abundant quantities of ammonia and carbon dioxide.⁵⁵ This gaseous mixture is trapped in the apical region and quickly forms a column of gas into which further fluid penetration is impossible. Extension of instruments into this vapour lock does not reduce or remove the gas bubble,⁵⁶ just as it does not enable adequate flow of irrigant.

The phenomenon of apical vapour lock has been confirmed in studies in which roots were embedded

in a polyvinylsiloxane impression material to restrict fluid flow through the apical foramen, simulating a close-ended channel. The result in these studies was incomplete debridement of the apical part of the canal walls with the use of a positive-pressure syringe delivery technique.⁵⁷⁻⁶⁰ Micro-CT scanning and histological tests conducted by Tay et al. have also confirmed the presence of apical vapour lock.⁶⁰ In fact, studies conducted without ensuring a close-ended channel cannot be regarded as conclusive on the efficacy of irrigants and the irrigant system.⁶¹⁻⁶³ The apical vapour lock may also explain why in a number of studies investigators were unable to demonstrate a clean apical third in sealed root canals.^{59,64-66}

In a paper published in 1983, based on research Chow determined that traditional positive-pressure irrigation had virtually no effect apical to the orifice of the irrigation needle in a closed root-canal system.⁶⁷ Fluid exchange and debris displacement were minimal. Equally important to his primary findings, Chow set forth an infallible paradigm for endodontic irrigation: "For the solution to be mechanically effective in removing all the particles, it has to: (a) reach the apex; (b) create a current (force); and (c) carry the particles away."⁶⁷ The apical vapour lock and consideration for the patient's safety have always prevented the thorough cleaning of the apical 3 mm. It is critically important to determine which irrigation system will effectively irrigate the apical third, as well as isthmuses and lateral canals,¹⁶ and in a safe manner that prevents the extrusion of irrigant.

_Manual agitation techniques

By far the most common and conventional set of irrigation techniques, manual irrigation involves dispensing of an irrigant into a canal through needles/cannulae of variable gauges, either passively or with agitation by moving the needle up and down the canal space without binding it on the canal walls. This allows good control of needle depth and the volume of irrigant that is flushed through the canal.^{9,63} However, the closer the needle tip is positioned to the apical tissue, the greater the chance of apical extrusion of the irrigant.^{67,68} This must be avoided; were NaOCl to extrude past the apex, a catastrophic accident could occur.⁶⁹

_Manual-dynamic irrigation

Manual-dynamic irrigation involves gently moving a well-fitting gutta-percha master cone up and down in short 2 to 3 mm strokes within an instrumented canal, thereby producing a hydrodynamic effect and significant irrigant exchange.⁷⁰ Recent studies have shown that this irrigation technique is significantly more effective than automated-dynamic irrigation and static irrigation.^{9,71,72}

2 0 1 3



GREATER NEW YORK DENTAL MEETING

SCIENTIFIC MEETING:
Friday, November 29 -
Wednesday, December 4

EXHIBIT DATES:
Sunday, December 1 -
Wednesday, December 4

NO PRE-REGISTRATION FEE

Attend At No Cost
Never a pre-registration fee at the
Greater New York Dental Meeting

Mark Your Calendar
Educational Programs:
Friday through Wednesday,
November 29 - December 4

Exhibits:
Sunday through Wednesday,
December 1 - December 4

More than 600 Exhibitors
Jacob K. Javits Convention Center
11th Avenue between 34-39th Streets (Manhattan)

Headquarters Hotel
New York Marriott Marquis Hotel

Live Dentistry Arena - No Tuition

Latest Dental Technology & Scientific Advances

More Than 350 Scientific Programs
Seminars, Hands-on Workshops, Essays & Scientific
Poster Sessions as well as Specialty and Auxiliary
Programs

Educational Programs in various languages

Social Programs for the Entire Family

**ENJOY NEW YORK CITY AT ITS BEST DURING THE
MOST FESTIVE TIME OF THE YEAR!**

**The Largest Dental Meeting/Exhibition/
Congress in the United States**

89th ANNUAL SESSION



For More Information:
Greater New York Dental Meeting®
570 Seventh Avenue - Suite 800, New York, NY 10018 USA
Tel: (212) 398-6922 / Fax: (212) 398-6934
E-mail: victoria@gnydm.com / Website: www.gnydm.com



WWW.GNYDM.COM

Sponsored by: The New York County Dental Society and The Second District Dental Society

Machine-assisted agitation systems

Sonic irrigation

Sonic activation has been shown to be an effective method for disinfecting root canals, operating at frequencies of 1–6 kHz.^{73,74} There are several sonic irrigation devices on the market. The Vibringe allows delivery and sonic activation of the irrigating solution in one step. It employs a two-piece syringe with a rechargeable battery. The irrigant is sonically activated, as is the needle that attaches to the syringe. The EndoActivator is a more recently introduced sonically driven canal irrigation system.^{9,75} It consists of a portable handpiece and three types of disposable polymer tips of different sizes. The EndoActivator has been reported to effectively clean debris from lateral canals, remove the smear layer, and dislodge clumps of biofilm within the curved canals of molar teeth.⁹

Ultrasonics

Ultrasonic energy produces higher frequencies than sonic energy but low amplitudes, oscillating at frequencies of 25–30 kHz.^{9,76} Two types of ultrasonic irrigation are available. The first type is simultaneous ultrasonic instrumentation and irrigation, and the second type is referred to as passive ultrasonic irrigation operating without simultaneous irrigation (PUI). The literature indicates that it is more advantageous to apply ultrasonics after completion of canal preparation rather than as an alternative to conventional instrumentation.^{9,20,77} PUI irrigation allows energy to

be transmitted from an oscillating file or smooth wire to the irrigant in the root canal by means of ultrasonic waves.⁹ There is consensus that PUI is more effective than syringe needle irrigation at removing pulpal tissue remnants and dentine debris.^{78–80} This may be due to the much higher velocity and volume of irrigant flow that are created in the canal during ultrasonic irrigation.^{9,81} PUI has been shown to remove the smear layer; there is a large body of evidence with different concentrations of NaOCl.^{9,80–84} In addition, numerous investigations have demonstrated that the use of PUI after hand or rotary instrumentation results in a significant reduction in the number of bacteria,^{9,85–87} or achieves significantly better results than syringe needle irrigation.^{9,84,88,89}

Studies have demonstrated that effective delivery of irrigants to the apical third can be enhanced by using ultrasonic and sonic devices that demonstrate acoustic micro-streaming and cavitation.^{79,81,90,91} Acoustic micro-streaming is defined as the movement of fluids along cell membranes, which occurs as a result of the ultrasound energy creating mechanical pressure changes within the tissue. Cavitation is defined as the formation and collapse of gas and vapour-filled bubbles or cavities in a fluid.

The Apical Vapor Lock theory, proven *in vitro* by Tay, has been clinically demonstrated⁹² to also include the middle third by Vera: "The mixture of gases is originally trapped in the apical third, but then it might grow quickly by the nucleation of the smaller bubbles, forming a gas column that might not only impede penetration of the irrigant into the apical third but also push it coronally after it has been delivered into the canal." However, more recently Munoz⁹³ demonstrated that both: passive ultrasonic irrigation (PUI) and EndoVac are more effective than the conventional endodontic needle in delivering irrigant to WL of root canals."

This begs the efficacy question. Two recently published studies examined this issue with both systems by testing their ability to eliminate microorganisms during clinical treatment from infected root canal systems.^{94,95} Paiva found that after a supplementary irrigation procedure using PUI with NaOCl that 23% of the samples produced positive cultures. Cohenca's study examining the clinical efficacy of the EndoVac found no microbial growth either after post instrumentation irrigation or at the one⁹² week obturation appointment.

When questioning these diverse results one must remember that microbial hydrolysis via NaOCl is an equilibrium reaction. Hand demonstrated that a 50% reduction of NaOCl concentration resulted in a 300% reduction in dissolution activity. Accord-

Fig. 2 EndoVac set-up.

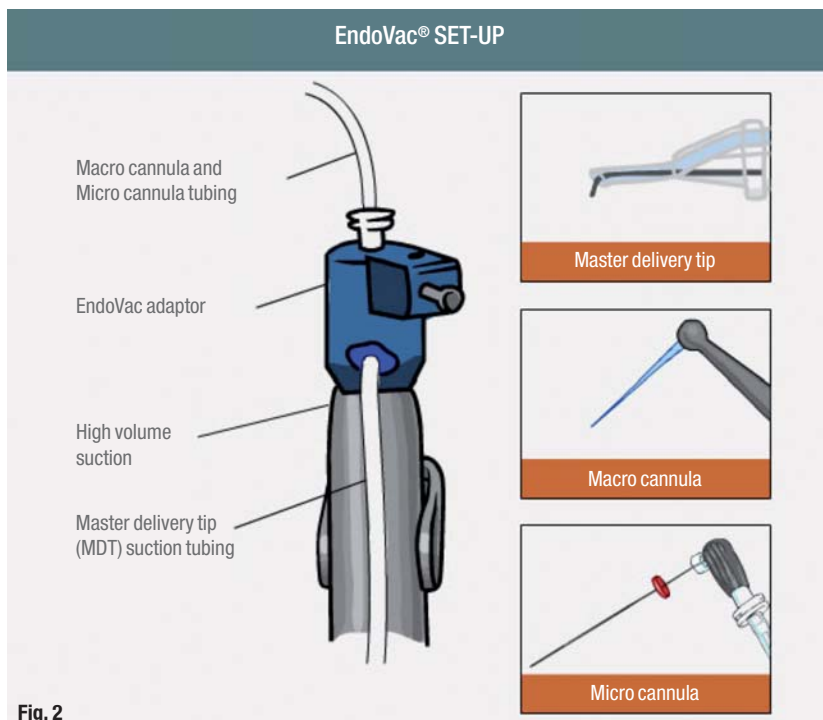


Fig. 2

ingly, one must consider both the delivery of the irrigant to full working length, via PUI or apical negative pressure and the total volume of NaOCl exchanged. The volume of an instrumented root canal 19 mm long shaped to a #35 with a 6% instrument equals .014 cc. Paiva described placement of NaOCl via a NaviTip (ULTRADENT) at WL – 4 mm during instrumentation and discussed using PUI with #15 K-file at WL – 1 mm. Prior to PUI, 2 ml of NaOCl was injected into the canal; however, this could not have filled the apical four millimeters⁹⁵ due to the apical vapor lock. According to Munoz, the canal was most likely immediately filled with ultrasonically activated NaOCl for one minute⁹², but as just described – only about .014cc would have been effectively available for this exchange and activation. In contrast, the Apical Negative Pressure protocol described by Cohenca et al. approximately 2 ml of NaOCl actively passes through the complete WL for one⁹² minute.⁹⁶ The difference in volumetric exchange equals $2/.014 = 14,200\%$ and likely explains the disinfection differential.

_The plastic rotary F File

Although sonic or ultrasonic instrumentation is more effective at removing residual canal debris than rotary endodontic files are,¹⁰⁴ and irrigation solutions are often unable to remove this during endodontic treatment, many clinicians still do not incorporate it into their endodontic instrument armamentarium. The common reasons given for not using sonic or ultrasonic filing are that it can be time-consuming to set up, an unwillingness to incur the cost of the equipment, and lack of awareness of the benefits of this final instrumentation step in endodontic treatment.

It is for these reasons that an endodontic polymer-based rotary finishing file was developed. This new, single-use, plastic rotary file has a unique file design with a diamond abrasive embedded into a non-toxic polymer. The F File will remove dentinal wall debris and agitate the NaOCl without enlarging the canal further.

_Pressure-alternation devices

Rinsendo irrigates the canal by using pressure-suction technology. Its components are a handpiece, a cannula with a 7 mm exit aperture, and a syringe carrying irrigant. The handpiece is powered by a dental air compressor and has an irrigation speed of 6.2 ml/min. Research has shown that it has promising results in cleaning the root-canal system, but more research is required to provide scientific evidence of its efficacy. Periapical extrusion of irrigant has been reported with this device.^{101, 102}

_The EndoVac apical negative-pressure system

The EndoVac apical negative-pressure irrigation system has three components: the Master Delivery Tip, MacroCannula and MicroCannula. The Master Delivery Tip simultaneously delivers and evacuates the irrigant (Fig. 2). The MacroCannula is used to suction irrigant from the chamber to the coronal and middle segments of the canal. The MacroCannula or MicroCannula is connected via tubing to the high-speed suction of a dental unit. The Master Delivery Tip is connected to a syringe of irrigant and the evacuation hood is connected via tubing to the high-speed suction of a dental unit.⁹⁶ The plastic MacroCannula has an open end of ISO size 0.55 mm in diameter with a 0.02 taper and is attached to a handpiece for gross, initial flushing of the coronal and mid-length parts of the root canal. The MicroCannula contains 12 microscopic holes and is capable of evacuating debris to full working length.¹⁰² The ISO size 0.32 mm diameter stainless-steel MicroCannula has four sets of three laser-cut, laterally positioned offset holes adjacent to its closed end, 100 μ in diameter and spaced 100 μ apart. This is attached to a finger piece for irrigation of the apical part of the canal when it is positioned at working length. The MicroCannula can be used in canals that are enlarged with endodontic files to ISO size 35.04 or larger.

During irrigation, the Master Delivery Tip delivers irrigant to the pulp chamber and siphons off the excess irrigant to prevent overflow. Both the MacroCannula and MicroCannula exert negative pressure that pulls fresh irrigant from the chamber, down the canal to the tip of the cannula, into the cannula, and out through the suction hose. Thus, a constant flow of fresh irrigant is delivered by negative pressure to working length. A recent study showed that the volume of irrigant delivered was significantly higher than the volume delivered by conventional syringe needle irrigation within the same period,⁴⁶ and resulted in significantly more debris removal at 1 mm from working length than did needle irrigation. During conventional root-canal irrigation, clinicians must be careful when determining how far an irrigation needle is placed into the canal. Recommendations for avoiding NaOCl incidents include not binding the needle in the canal, not placing the needle close to working length, and using a gentle flow rate when using positive-pressure irrigation.¹⁰³ With the EndoVac, in contrast, irrigant is pulled into the canal at working length and removed by negative pressure. Apical negative pressure has been shown to enable irrigants to reach the apical third and help overcome apical vapour lock.^{46, 104} In addition, with respect to isthmus cleaning, although it is not possible to reach and clean the isthmus area with instruments, it is not impossible to reach and thoroughly clean these

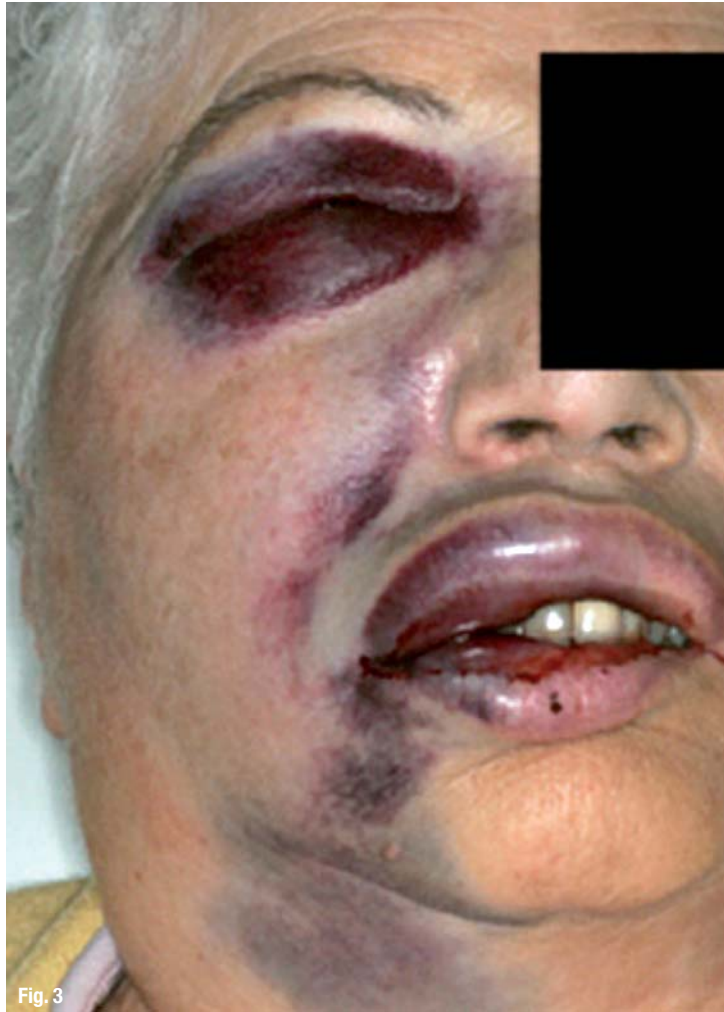

Fig. 3 Irrigation accident with widespread trauma.

areas with NaOCl when the method of irrigation is safe and efficacious. In studies comparing the EndoActivator,¹⁰⁵ passive ultrasonic,¹⁰⁵ the F File,¹⁰⁵ the manual-dynamic Max-i-Probe (DENTSPLY Rinn),^{105, 106} the Pressure Ultrasonic¹¹¹ and the EndoVac,¹⁰⁶ only the EndoVac was capable of cleaning 100% of the isthmus area.

Apart from being able to avoid air entrapment, the EndoVac system is also advantageous in its ability to deliver irrigants safely to working length without causing their undue extrusion into the periapex,^{46, 102} thereby avoiding NaOCl incidents. It is important to note that it is possible to create positive pressure in the pulp canal if the Master Delivery Tip is misused, which would create the risk of a NaOCl incident. The manufacturer's instructions must be followed for correct use of the Master Delivery Tip.

Sodium hypochlorite incidents

Although a devastating endodontic NaOCl incident is rare,¹⁰⁷ the cytotoxic effects of NaOCl on vital tissue are well established.¹⁰⁸ The associated sequen-

lae of NaOCl extrusion have been reported to include life-threatening airway obstructions,¹⁰⁹ facial disfigurement requiring multiple corrective surgical procedures,¹¹⁰ permanent paraesthesia with loss of facial muscle control,⁶⁹ and—the least significant consequence—tooth loss.¹¹¹

Although the exact aetiology of the NaOCl incident is still uncertain, based on the evidence from actual incidents and the location of the associated tissue trauma, it would appear that an intravenous injection may be the cause. The patient shown in Figure 3 demonstrates a widespread area of tissue trauma that is in contrast to the characteristics of NaOCl incident trauma reported by Pashley.^{108, 112} This extensive trauma, and particularly involving the pattern of ecchymosis around the eye, could only have occurred if the NaOCl had been introduced intravenously to a vein close to the root apex through which extrusion of the irrigant occurred and the irrigant then found its way into the venous complex. This would require positive pressure apically that exceeded venous pressure (10 mg of Hg). In one *in vitro* study, which used a positive-pressure needle irrigation technique to mimic clinical conditions and techniques, the apical pressure generated was found to be eight times higher than the normal venous pressure.¹¹³

This does not imply that NaOCl can or should be excluded as an endodontic irrigant; in fact, its use is critical, as has been discussed in this article. What this does imply is that it must be delivered safely.

Safety first

In order to compare the safety of six current intra-canal irrigation delivery devices, an *in vitro* test was conducted using the worst-case scenario of apical extrusion, with neutral atmospheric pressure and an open apex.¹⁰² The study concluded that the EndoVac did not extrude irrigant after deep intra-canal delivery and suctioning of the irrigant from the chamber to full working length, whereas other devices did. The EndoActivator extruded only a very small volume of irrigant, the clinical significance of which is not known.

Mitchell and Baumgartner tested irrigant (NaOCl) extrusion from a root canal sealed with a permeable agarose gel.¹¹⁴ Significantly less extrusion occurred using the EndoVac system compared with positive-pressure needle irrigation. A well-controlled study by Gondim et al. found that patients experienced less post-operative pain, measured objectively and subjectively, when apical negative-pressure irrigation was performed (EndoVac) than with apical positive-pressure irrigation.¹¹⁵

_Efficacy

In vitro and *in vivo* studies have demonstrated greater removal of debris from the apical walls and a statistically cleaner result using apical negative-pressure irrigation in closed root-canal systems with sealed apices. In an *in vivo* study of 22 teeth by Siu and Baumgartner, less debris remained at 1 mm from working length using apical negative pressure compared to use of traditional needle irrigation, while Shin et al. found in an *in vitro* study of 69 teeth comparing traditional needle irrigation with apical negative pressure that these methods both resulted in clean root canals, but that apical negative pressure resulted in less debris remaining at 1.5 and 3.5 mm from working length.^{46, 104, 116} When comparing root-canal debridement using manual-dynamic agitation or the EndoVac for final irrigation in a closed system and an open system, it was found that the presence of a sealed apical foramen adversely affected debridement efficacy when manual-dynamic agitation was used, but did not adversely affect results when the EndoVac was used. Apical negative-pressure irrigation is an effective method to overcome the fluid-dynamic challenges inherent in closed root-canal systems.¹¹⁷

_Microbial control

Hockett et al. tested the ability of apical negative pressure to remove a thick biofilm of *E. Faecalis*, finding that these specimens rendered negative cultures obtained within 48 hours, while those irrigated using traditional positive-pressure irrigation were positive at 48 hours.⁹⁹

One study found that apical negative-pressure irrigation resulted in similar bacterial reduction to use of apical positive-pressure irrigation and a triple antibiotic in immature teeth.¹¹⁸ In a study comparing the use of apical positive-pressure irrigation and a triple antibiotic that has been utilised for pulpal regeneration/revascularisation in teeth with incompletely formed apices (Trimix = Cipro, Minocin, Flagyl) versus use of apical negative-pressure irrigation with NaOCl, it was found that the results were statistically equivalent for mineralised tissue formation and the repair process.¹¹⁹ Using apical negative pressure and NaOCl also avoids the risk of drug resistance, tooth discoloration, and allergic reactions.^{120, 121}

_Conclusion

Since the dawn of contemporary endodontics, dentists have been syringing NaOCl into the root-canal space and then proceeding to place endodontic instruments down the canal in the belief that

they were carrying the irrigant to the apical termination. Biological, scanning electron microscopy, light microscopy, and other studies have proven this belief to be in error. NaOCl reacts with organic material in the root canal and quickly forms micro-bubbles at the apical termination that coalesce into a single large apical vapour bubble with subsequent instrumentation. Since the apical vapour lock cannot be displaced via mechanical means, it prevents further NaOCl flow into the apical area. The safest method yet discovered to provide fresh NaOCl safely to the apical terminus to eliminate the apical vapour lock is to evacuate it via apical negative pressure. This method has also been proven to be safe because it always draws irrigants to the source via suction—down the canal and simultaneously away from the apical tissue in abundant quantities.¹²² When the proper irrigating agents are delivered safely to the full extent of the root-canal terminus, thereby removing 100% of organic tissue and 100% of the microbial contaminants, success in endodontic treatment may be taken to levels never seen before.

Editorial note: A complete list of references is available from the publisher.

This article has been reprinted in part from G. Glassman, Safety and Efficacy Considerations in Endodontic Irrigation (PenWell, January 2011).

_about the author

roots



Dr Gary Glassman graduated from the University of Toronto Faculty of Dentistry in 1984 and graduated from the Endodontology Program at Temple University in 1987, where he received the Louis I. Grossman Study Club Award for

academic and clinical proficiency in endodontics. The author of numerous publications, he lectures globally on endodontics and is on the staff at the University of Toronto Faculty of Dentistry in the Graduate Department of Endodontics. He is a fellow of the Royal College of Dentists of Canada, and the endodontic editor for the Oral Health journal. He maintains a private practice, Endodontic Specialists, in Toronto, Ontario, Canada. He can be reached through his website, www.rootcanals.ca

Stropko Irrigator removes debris, making many procedures easier

Author_ Dr John J. Stropko, USA

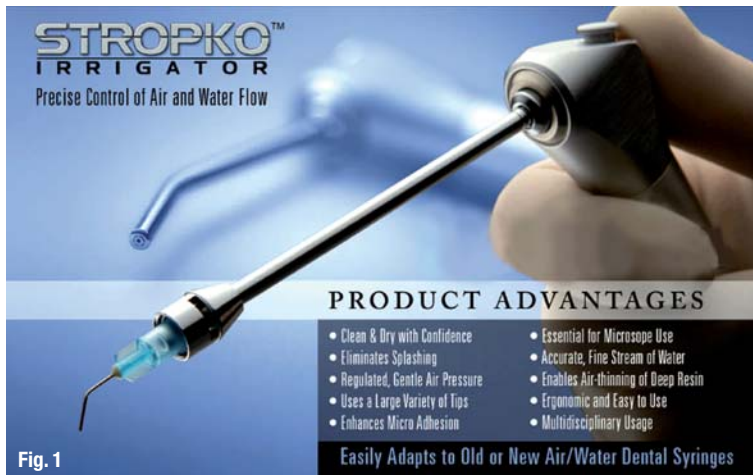

Fig. 1_ The Stropko Irrigator.
(Photographs by Dr. John J. Stropko.)

The innovative Stropko Irrigator has essential uses in any discipline of dentistry: to make restorative, endodontic, periodontal, surgical, and micro-adhesive dentistry, as well as orthodontic and implant procedures, easier by constantly maintaining a clean field with uninterrupted vision. The Stropko Irrigator (Fig. 1) allows numerous advantages over the standard dental tips.

It easily replaces the standard three-way syringe tip and accepts a variety of Luer-lock tips, enabling more precise management of irrigation with air and/or water. The large variety of Luer-lock tips enables direct access to any area of the mouth, during any procedure, whether it is the lingual of an anterior, the distal of a molar, or an apical retro-preparation during surgery.

Using the Stropko Irrigator, cleaning and drying can be done with more precision and control, elimi-

nating all unintentional splashing or contamination of the working area. With standard syringe tips, it is not possible to prevent the dentinal dust from obstructing vision. A good example of vision control can be observed while troughing in search of hidden canals, as demonstrated in Figures 2 and 3.

Figure 2 shows how vision is obstructed by the debris created during instrumentation. In Figure 3, note the vast improvement in vision when the Stropko Irrigator is used. The dentinal debris is eliminated as it is created, thus permitting continuous clear vision.

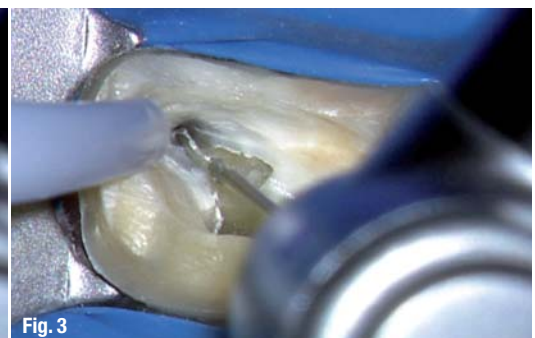
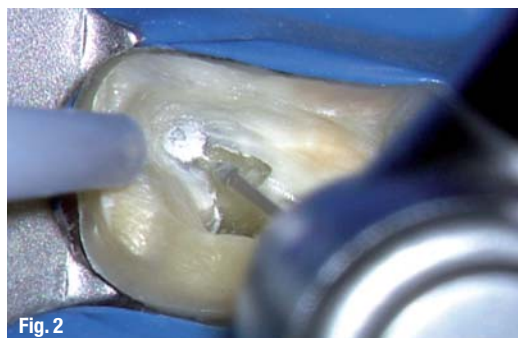
The outcome of any dental procedure is achieved easier, faster, with more predictability and less stress. The advantages of using the Stropko Irrigator are especially appreciated when using a surgical operating microscope during any dental procedure.

The Stropko Irrigator is available in two lengths: the 2.5 in. original length (SI-OL) and the 4 in. extra long (SI-XL). The SI-XL is popular because it allows the operator or the assistant to remain ergonomically comfortable and remain clear of the working site. Using the supplied adapters, the Stropko Irrigator easily replaces the older three-way syringe tips. No adapters are needed for the newer quick-connect three-way syringes.

The Stropko Irrigator is manufactured in the US in accordance with the strictest of quality-control measures, and bears the coveted CE marking. It can be purchased at most dental suppliers in US, or visit www.stropkoirrigator.com for more information.

Fig. 2_ Vision is obstructed by debris created during endodontic instrumentation.

Fig. 3_ When the Stropko Irrigator is used, debris is eliminated as it is created.



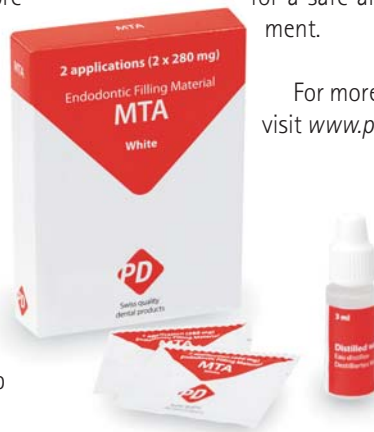Produits Dentaires presents PD MTA White

_PD (Produits Dentaires) Switzerland, developer and manufacturer of MAP System for the precise placement of repair material in the root canal presented at the IDS 2013 for the first time his PD MTA White.

This new endodontic filling material was specially developed to be placed with MAP System but it could be placed with any other technique as well. The PD MTA White offers the following advantages:

- _Optimized particle size;
- _Avoids bacterial migration;
- _Excellent marginal sealing capacity;
- _Stimulates the formation of a dentine layer (pulp capping).

Furthermore the very hygienic packaging in two sachets with 280mg each shows an additional plus for a safe and successful treatment.



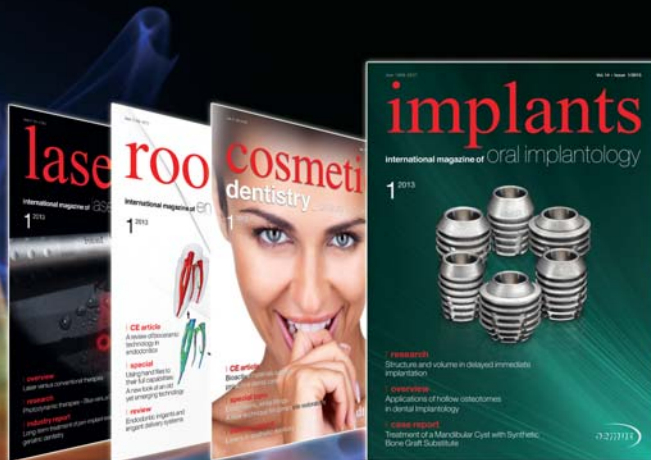For more information please visit www.pdsa.ch

_contact	roots
Produits Dentaires SA Vevey . Switzerland	
Produits Dentaires SA Rue des Bosquets 18 1800 Vevey Switzerland info@pdsa.ch	

AD

implants

international magazine of oral implantology



Subscribe now!

You can also subscribe via www.oemus.com/abo

I would like to subscribe to **implants** for € 44 including shipping and VAT for German customers, € 46 including shipping and VAT for customers outside of Germany, unless a written cancellation is sent within 14 days of the receipt of the trial subscription. The subscription will be renewed automatically every year until a written cancellation is sent to OEMUS MEDIA AG, Holbeinstr. 29, 04229 Leipzig, Germany, six weeks prior to the renewal date.

Reply via Fax +49 341 48474-290 to OEMUS MEDIA AG or per E-mail to grasse@oemus-media.de

Last Name, First Name

Company

Street

ZIP/City/Country

E-mail

Signature

Notice of revocation: I am able to revoke the subscription within 14 days after my order by sending a written cancellation to OEMUS MEDIA AG, Holbeinstr. 29, 04229 Leipzig, Germany.

Signature

roots 1/13



International Events

2013

AAE Annual Session

17–20 April 2013
Hawaii, USA
www.aae.org

35th Asia Pacific Dental Congress

7–12 May 2013
Kuala Lumpur, Malaysia
www.mda.org.my/35th-apdc.htm

CONSEURO Paris 2013

9–11 May 2013
Paris, France
www.paris2013.conseuro.org

IFEA World Endodontic Congress

23–26 May 2013
Tokyo, Japan
www2.convention.co.jp/ifea2013

Sino-Dental

9–12 June 2013
Beijing, China
cnc.sinodent.com.cn/en/index.aspx

20th World Laser Congress

20–22 June 2013
Paris, France

The International Congress of the French Society of Endodontic (FSE)

20–22 June 2013
Aix en Provence, France
www.endodontie.fr

FDI Annual World Dental Congress

28–31 August 2013
Istanbul, Turkey
www.fdiworldental.org

ESE Biennial Congress

12–14 September 2013
Lisbon, Portugal
www.e-s-e.eu

Canadian Academy of Endodontics Annual General Meeting

16–22 September 2013
Ottawa, Ontario, Canada
www.caendo.ca

DGZ & DGET joint meeting

10–12 October 2013
Marburg, Germany
www.dget.de

ADA Annual Session

31 October–3 November 2013
New Orleans, USA
www.ada.org

BAET – Successful Endodontics: Foundations and new Treatment Avenues

8 November 2013
Brussels, Belgium
www.baet.org

Greater New York Dental Meeting

29 November–4 December 2013
New York, USA
www.gnydm.com



submission guidelines:

Please note that all the textual components of your submission must be combined into one MS Word document. Please do not submit multiple files for each of these items:

- _ the complete article;
- _ all the image (tables, charts, photographs, etc.) captions;
- _ the complete list of sources consulted; and
- _ the author or contact information (biographical sketch, mailing address, e-mail address, etc.).

In addition, images must not be embedded into the MS Word document. All images must be submitted separately, and details about such submission follow below under image requirements.

Text length

Article lengths can vary greatly—from 1,500 to 5,500 words—depending on the subject matter. Our approach is that if you need more or less words to do the topic justice, then please make the article as long or as short as necessary.

We can run an unusually long article in multiple parts, but this usually entails a topic for which each part can stand alone because it contains so much information.

In short, we do not want to limit you in terms of article length, so please use the word count above as a general guideline and if you have specific questions, please do not hesitate to contact us.

Text formatting

We also ask that you forego any special formatting beyond the use of italics and boldface. If you would like to emphasise certain words within the text, please only use italics (do not use underlining or a larger font size). Boldface is reserved for article headers. Please do not use underlining.

Please use single spacing and make sure that the text is left justified. Please do not centre text on the page. Do not indent paragraphs, rather place a blank line between paragraphs. Please do not add tab stops.

Should you require a special layout, please let the word processing programme you are using help you do this formatting automatically. Similarly, should you need to make a list, or add footnotes or endnotes, please let the word processing programme do it for you automatically. There are menus in every programme that will enable you to do so. The fact is that no matter how carefully done, errors can creep in when you try to number footnotes yourself.

Any formatting contrary to stated above will require us to remove such formatting before layout, which is very time-consuming. Please consider this when formatting your document.

Image requirements

Please number images consecutively throughout the article by using a new number for each image. If it is imperative that certain images are grouped together, then use lowercase letters to designate these in a group (for example, 2a, 2b, 2c).

Please place image references in your article wherever they are appropriate, whether in the middle or at the end of a sentence. If you do not directly refer to the image, place the reference at the end of the sentence to which it relates enclosed within brackets and before the period.

In addition, please note:

- _ We require images in TIF or JPEG format.
- _ These images must be no smaller than 6x6 cm in size at 300 DPI.
- _ These image files must be no smaller than 80 KB in size (or they will print the size of a postage stamp!).

Larger image files are always better, and those approximately the size of 1 MB are best. Thus, do not size large image files down to meet our requirements but send us the largest files available. (The larger the starting image is in terms of bytes, the more leeway the designer has for resizing the image in order to fill up more space should there be room available.)

Also, please remember that images must not be embedded into the body of the article submitted. Images must be submitted separately to the textual submission.

You may submit images via e-mail, via our FTP server or post a CD containing your images directly to us (please contact us for the mailing address, as this will depend upon the country from which you will be mailing).

Please also send us a head shot of yourself that is in accordance with the requirements stated above so that it can be printed with your article.

Abstracts

An abstract of your article is not required.

Author or contact information

The author's contact information and a head shot of the author are included at the end of every article. Please note the exact information you would like to appear in this section and format it according to the requirements stated above. A short biographical sketch may precede the contact information if you provide us with the necessary information (60 words or less).

Questions?

Magda Wojtkiewicz (Managing Editor)
m.wojtkiewicz@oemus-media.de

roots

international magazine of endodontology

Publisher

Torsten R. Oemus
oemus@oemus-media.de

CEO

Ingolf Döbbecke
doebbecke@oemus-media.de

Members of the Board

Jürgen Isbaner
isbaner@oemus-media.de

Lutz V. Hiller

hiller@oemus-media.de

Managing Editor

Magda Wojtkiewicz
m.wojtkiewicz@oemus-media.de

Executive Producer

Gernot Meyer
meyer@oemus-media.de

Designer

Josephine Ritter
j.ritter@oemus-media.de

Copy Editors

Sabrina Raaff
Hans Motschmann

Published by

Oemus Media AG
Holbeinstraße 29
04229 Leipzig, Germany
Tel.: +49 341 48474-0
Fax: +49 341 48474-290
kontakt@oemus-media.de
www.oemus.com

Printed by

Silber Druck oHG
Am Waldstrauch 1
34266 Niestetal, Germany

Editorial Board

Fernando Goldberg, Argentina
Markus Haapasalo, Canada
Ken Serota, Canada
Clemens Bargholz, Germany
Michael Baumann, Germany
Benjamin Briseno, Germany
Asgeir Sigurdsson, Iceland
Adam Stabholz, Israel
Heike Steffen, Germany
Gary Cheung, Hong Kong
Unni Endal, Norway
Roman Borczyk, Poland
Bartosz Cerkaski, Poland
Esteban Brau, Spain
José Pumarola, Spain
Kishor Gulabivala, United Kingdom
William P. Saunders, United Kingdom
Fred Barnett, USA
L. Stephan Buchanan, USA
Jo Dovgan, USA
Vladimir Gorokhovskiy, USA
James Gutmann, USA
Ben Johnson, USA
Kenneth Koch, USA
Sergio Kuttler, USA
John Nusstein, USA
Ove Peters, USA
Jorge Vera, Mexico



Magda Wojtkiewicz, Managing Editor

roots

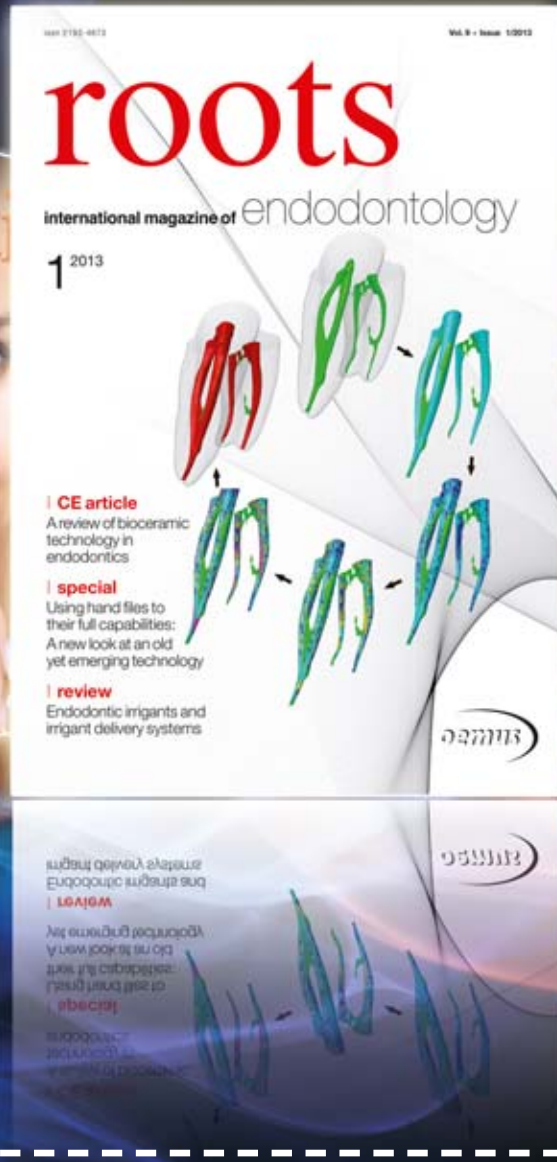
Copyright Regulations

_roots international magazine of endodontology is published by Oemus Media AG and will appear in 2013 with one issue every quarter. The magazine and all articles and illustrations therein are protected by copyright. Any utilisation without the prior consent of editor and publisher is inadmissible and liable to prosecution. This applies in particular to duplicate copies, translations, microfilms, and storage and processing in electronic systems.

Reproductions, including extracts, may only be made with the permission of the publisher. Given no statement to the contrary, any submissions to the editorial department are understood to be in agreement with a full or partial publishing of said submission. The editorial department reserves the right to check all submitted articles for formal errors and factual authority, and to make amendments if necessary. No responsibility shall be taken for unsolicited books and manuscripts. Articles bearing symbols other than that of the editorial department, or which are distinguished by the name of the author, represent the opinion of the afore-mentioned, and do not have to comply with the views of Oemus Media AG. Responsibility for such articles shall be borne by the author. Responsibility for advertisements and other specially labeled items shall not be borne by the editorial department. Likewise, no responsibility shall be assumed for information published about associations, companies and commercial markets. All cases of consequential liability arising from inaccurate or faulty representation are excluded. General terms and conditions apply, legal venue is Leipzig, Germany.

roots

international magazine of endodontology



You can also subscribe via
www.oemus.com/abo

 **Subscribe now!**

I would like to subscribe to **roots** for € 44 including shipping and VAT for German customers, € 46 including shipping and VAT for customers outside Germany, unless a written cancellation is sent within 14 days of the receipt of the trial subscription. The subscription will be renewed automatically every year until a written cancellation is sent to OEMUS MEDIA AG, Holbeinstr. 29, 04229 Leipzig, Germany, six weeks prior to the renewal date.

▶ **Reply** via Fax to +49 341 48474-290 to OEMUS MEDIA AG or via E-mail to grasse@oemus-media.de

Last Name, First Name

Company

Street

ZIP/City/Country

E-mail

Signature

Notice of revocation: I am able to revoke the subscription within 14 days after my order by sending a written cancellation to OEMUS MEDIA AG, Holbeinstr. 29, 04229 Leipzig, Germany.

Signature

*convenient
single cone
technique*



*warm
gutta-percha*

Innovation means combining benefits

**3D root canal filling with an obturator
entirely out of gutta-percha**

- Separation of the handle without additional instruments
- Simplified post space preparation
- Precise placement of the obturator in the root canal with fingers or tweezers

www.vdw-dental.com



with practical
handle for
tweezers

GUTTA FUSION®