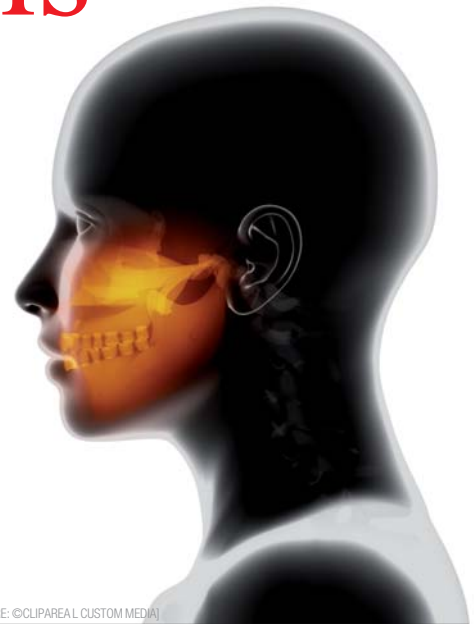

# Bisphosphonate therapy and osteonecrosis of the jaw

**Authors** Johannes D. Bähr, Prof. Dr Dr Peter Stoll & Dr Georg Bach, Germany



(PICTURE: ©CLIPAREA L CUSTOM MEDIA)

## \_Introduction

Osteonecrosis of the jaw due to bisphosphonate was first described in 2003. The disease is called bisphosphonate-related osteonecrosis of the jaw (BRONJ). Dental implants are contraindicated for tumour patients under bisphosphonate therapy. In osteoporosis patients with oral bisphosphonate administration (not exceeding three years), however, the risk of developing osteonecrosis is considered to be very low. The following work provides an overview.

**Fig. 1** Structural formula of pyrophosphate and basic structure of bisphosphonates with the side chains R1 and R2 (Arzneimittelbrief AMB 1998, 32, 41).

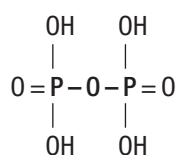
Menschutkin, a German chemist, was the first to achieve the synthesis of bisphosphonates in 1895. In the beginning, bisphosphonates were mainly used in the textile, fertilizer and oil industries thanks to their ability to inhibit the precipitation of calcium carbon-

ate. In the 1960s, they were used as detergent additives by Henkel company.

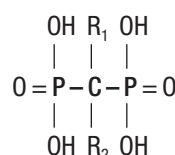
1968 was the year of the first medical application of bisphosphonates. The American orthopaedist Andrew Bassett was in charge of three children whose muscles had calcified in part. One of the three children (16 months old) was in a life-threatening condition, since his respiratory muscles had already been affected. Bassett turned to the Swiss physician Herbert Fleisch who had been dealing intensely with bisphosphonates. The two physicians used the bisphosphonate etidronate for the calcifications. Most of the fresh calcifications disappeared within a few days. Since the 1980s, bisphosphonates have found widespread use in medicine in particular thanks to their bone-strengthening effect.

## \_Chemical principles, mode of action and indication

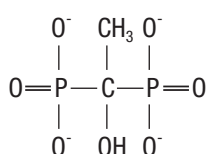
Bisphosphonates are derived from pyrophosphates. On account of their strong affinity to bone, it was assumed that pyrophosphates might be used *in vivo* to prevent bone resorption. However, since they are inactivated quickly *in vivo*, they were not suitable as a drug. In search of substances having a similar, but prolonged effect, scientists came across bisphosphonates. The P-O-P skeleton of the pyrophosphates is replaced by a P-C-P skeleton in the bisphosphonates



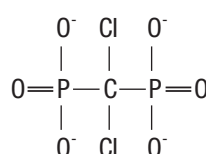
**Pyrophosphate**



**Bisphosphonate**



**Etidronate**



**Clodronate**

# Proven stability, high esthetics

« NobelReplace Conical Connection merges the well-proven implant body of NobelReplace Tapered with a tight internal conical connection. It is a versatile, easy-to-use implant which performs well in soft and hard bone. »



Prof. Alessandro Pozzi  
Rome, Italy

**NEW** Option with  
0.75 mm  
machined collar

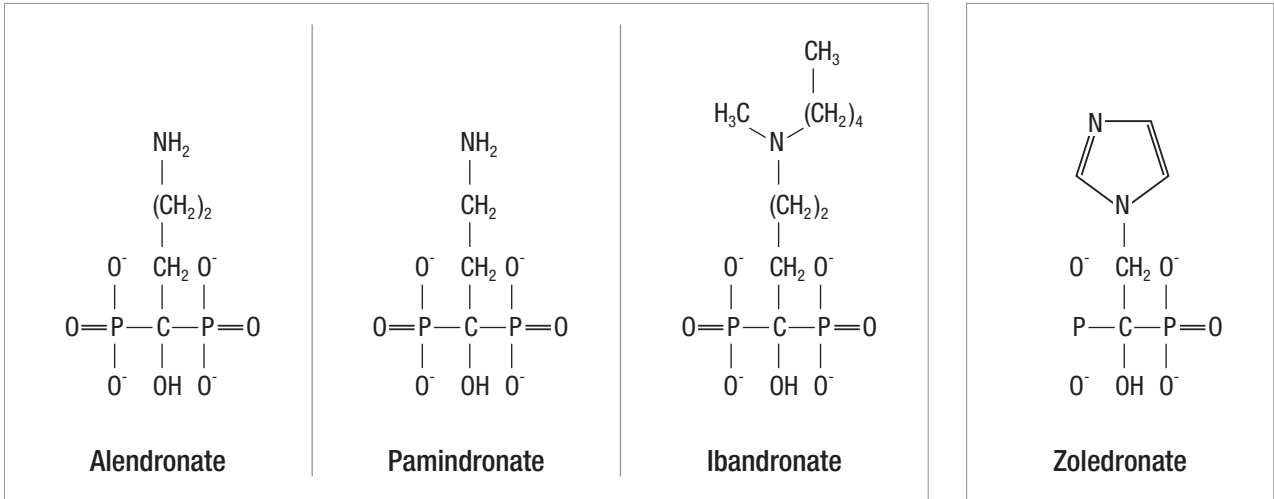
**NobelReplace Conical Connection** combines the original tapered implant body with a sealed conical connection, offering you and your patients an esthetic solution for all indications. The implant body mimics the shape of a natural tooth root, designed for high initial stability with all types of loading protocols including Immediate Function. Developed for restorations in the esthetic region,

NobelReplace Conical Connection offers a strong sealed connection with built-in platform shifting, designed to maximize soft tissue volume for natural looking esthetics. After 45 years as a dental innovator we have the experience to bring you future-proof and reliable technologies for effective patient treatment. **Their smile, your skill, our solutions.**



Visit [nobelbiocare.com/nobelreplace](http://nobelbiocare.com/nobelreplace)





**Fig. 3** Amino bisphosphonates of the second generation (Abu-Id 2010).

**Fig. 4** Amino bisphosphonate of the third generation with nitrogen-containing heterocycle (Abu-Id 2010).

(Fig. 1). The P-C-P group makes the bisphosphonates highly resistant to enzymatic decomposition. A large number of bisphosphonates have been synthesised over the last 30 years. They differ in the two side chains that are bound to the carbon atom. In most bisphosphonates, the first side chain (R1) is an OH group. The second, long side chain (R2) essentially determines the character of the bisphosphonate. Three generations are distinguished according to the R2 side chains:

- The bisphosphonates of the first generation are the so-called non-amino bisphosphonates or alkyl bisphosphonates. They contain an aliphatic R2 side chain such as e.g. etidronate or are substituted by halogen (Fig. 2).
- The bisphosphonates of the second generation are amino bisphosphonates. They contain amino groups in the R2 side chain such as e.g. alendronate, pamidronate or ibandronate (Fig. 3).
- The bisphosphonates of the third generation are amino bisphosphonates as well. They are substituted on the nitrogen atom and have alkaline nitrogen-

containing heterocycles in the R2 side chain such as e.g. zoledronate (Fig. 4).

Some authors do not distinguish between bisphosphonates of the second and of the third generation. These authors subsume all amino bisphosphonates under the group of the second generation. Bisphosphonates act both on the cellular and on the biochemical level. The effects on the biochemical level are based on the side chains. The variability of the side chains determines the differentiation of the different bisphosphonates.

While the R1 side chain of the bisphosphonates is mainly responsible for the binding to the bone, the highly variable R2 side chain has a particular influence on activity. Derivatives with an amino group in the R2 side chain (amino bisphosphonates) are more active than those without such a group (non-amino bisphosphonates). Moreover, the longer the R2 side chain, the greater the activity. Bisphosphonates deposit on the

**Tab. 1** Commonly used bisphosphonates and their relative potency compared to etidronate (Schindler 2009). All bisphosphonates except for clodronate have an OH group at their R1 group. At the R2 group, they have (except for clodronate) an aliphatic chain and/or a nitrogen-containing heterocycle.

Substance	Trade name	R1	R2	Relative potency
Editronate	Didronel®	-OH	CH <sub>3</sub>	1 x
Clodronate	Ostac® Bonefos®	-Cl	-Cl	10 x
Pamidronate	Aredia®	-OH	-CH <sub>2</sub> -CH <sub>2</sub> -NH <sub>2</sub>	100 x
Alendronate	Fosamax®	-OH	-CH <sub>2</sub> -CH <sub>2</sub> -CH <sub>2</sub> -NH <sub>2</sub>	1,000 x
Risedronate	Actonel®	-OH	-CH <sub>2</sub> -	5,000 x
Ibandronate	Bondronat® Bonviva®	-OH -OH	-CH <sub>2</sub> -CH <sub>2</sub> -N(CH <sub>3</sub> )-C <sub>5</sub> H <sub>11</sub>	10,000 x
Zoledronate	Zometa® Aclasta®	-OH	-CH <sub>2</sub> -	20,000 x

2 0 1 3



# GREATER NEW YORK DENTAL MEETING

**SCIENTIFIC MEETING:**  
Friday, November 29 -  
Wednesday, December 4

**EXHIBIT DATES:**  
Sunday, December 1 -  
Wednesday, December 4

**NO PRE-REGISTRATION FEE**

**Attend At No Cost**  
Never a pre-registration fee at the  
Greater New York Dental Meeting

**Mark Your Calendar**  
Educational Programs:  
Friday through Wednesday,  
November 29 - December 4

**Exhibits:**  
Sunday through Wednesday,  
December 1 - December 4

**More than 600 Exhibitors**  
Jacob K. Javits Convention Center  
11th Avenue between 34-39th Streets (Manhattan)

**Headquarters Hotel**  
New York Marriott Marquis Hotel

**Live Dentistry Arena - No Tuition**

Latest Dental Technology & Scientific Advances

More Than 350 Scientific Programs  
Seminars, Hands-on Workshops, Essays & Scientific  
Poster Sessions as well as Specialty and Auxiliary  
Programs

Educational Programs in various languages

Social Programs for the Entire Family

**ENJOY NEW YORK CITY AT ITS BEST DURING THE  
MOST FESTIVE TIME OF THE YEAR!**

**The Largest Dental Meeting/Exhibition/  
Congress in the United States**

**89<sup>th</sup> ANNUAL SESSION**



For More Information:  
Greater New York Dental Meeting®  
570 Seventh Avenue - Suite 800, New York, NY 10018 USA  
Tel: (212) 398-6922 / Fax: (212) 398-6934  
E-mail: victoria@gnydm.com / Website: www.gnydm.com



**WWW.GNYDM.COM**

*Sponsored by: The New York County Dental Society and The Second District Dental Society*



**Fig. 5** First reports on bisphosphonate-related osteonecrosis of the jaw.

- **2003:** Marx (36 cases), Migliorati (5 cases), Carter et al. (3 cases), Wang et al. (3 cases)
- **2004:** Ruggiero et al. (63 cases)  
Communication of the Ärztekommision [Medical Committee]  
Dtsch. Ärzteblatt (Aug. 2004)  
Hoefert et Eufinger (3 cases)  
Information given by Novartis company (3 cases)
- **2005:** Marx (119 cases)

bone surface in the resorption lacunae under the osteoclasts. They are resorbed by osteoclasts and result in cell inactivation and a loss of their ruffled border. Due to the loss of their ruffled border, the cell surface of the osteoblasts diminishes and they thus lose their ability to resorb bone. In addition, an increased apoptosis of osteoclasts occurs at higher doses. Besides the inhibition of osteoclasts, osteoblasts are inhibited as well.

The therapeutic effect of bisphosphonates consists in the fact that the inhibition of osteoclasts exceeds the inhibition of osteoblasts. This results in a positive balance in bone remodelling in favour of bone formation and in a reduction of the bone remodelling rate. The most common clinical indication for bisphosphonates is the treatment of osteoporosis. They are highly effective in this field. They effect an increase in bone density and a reduction in bone loss both in postmenopausal and in steroid-induced osteoporosis. The field of application of bisphosphonates for malignant

diseases includes osteolytic bone metastases and multiple myeloma. The bisphosphonates contribute to reduce the risk of skeleton-related events in patients. They have positive effects on a series of complications such as acute hypercalcaemia, new bone metastases, diffuse bone pain and protect against pathological fractures. Osteoporosis treatment is usually carried out using tablets. Intravenous administration of bisphosphonates is common in particular in oncology. The dosing for the treatment of osteoporosis is many times lower than for the treatment in oncology.

The activity of a bisphosphonate is defined by the amount of substance that is necessary in order to effectively inhibit bone resorption. The higher the activity, the greater is the potency of the bisphosphonate. The relative potency of bisphosphonates is related to the potency of the non-amino bisphosphonate etidronate. Etidronate is the oldest bisphosphonate available for clinical use. Table 1 shows a selection of therapeutically proven bisphosphonates. Only 1–10 per cent of orally administered bisphosphonates are resorbed. They bind to albumin in the blood and have a very high affinity to hydroxylic apatite of the bone. The half-life period in bone ranges from years to decades. Accumulation occurs in case of repeated application. Elimination takes place via the renal route. Bisphosphonates have side effects. The most important side effects are: gastrointestinal problems, acute phase reaction, renal lesions and osteonecrosis of the jaw.

**Fig. 6** Therapy recommendations for BRONJ depending on the stage of the disease (AAOMS, Ruggiero et al. 2009).

<b>Stage 0</b> <ul style="list-style-type: none"> <li>• unspecific symptoms</li> <li>• no bone necrosis</li> </ul>	<ul style="list-style-type: none"> <li>• symptomatic pain therapy</li> <li>• if necessary, antibiotic therapy</li> </ul>
<b>Stage 1</b> <ul style="list-style-type: none"> <li>• exposed necrotic bone</li> <li>• asymptomatic patients</li> <li>• no evidence of infection</li> </ul>	<div style="display: flex; flex-direction: column; align-items: center;"> <div style="border: 1px solid black; padding: 2px;"> <ul style="list-style-type: none"> <li>• frequent recalls</li> <li>• patient instruction</li> </ul> </div> <div style="border: 1px solid black; padding: 2px; margin: 2px;">antibacterial mouthwash solution (CHX 0,2%)</div> <div style="border: 1px solid black; padding: 2px; margin: 2px;">Antibiotic therapy</div> <div style="border: 1px solid black; padding: 2px; margin: 2px;">Pain therapy</div> <div style="border: 1px solid black; padding: 2px; margin: 2px;">Surgical debridement</div> </div>
<b>Stage 2</b> <ul style="list-style-type: none"> <li>• exposed necrotic bone</li> <li>• symptomatic patients</li> <li>• clinical evidence of infection</li> </ul>	
<b>Stage 3</b> <ul style="list-style-type: none"> <li>• exposed necrotic bone</li> <li>• symptomatic patients with pain and evidence of infection</li> <li>• evidence at least one of the following complications                             <ol style="list-style-type: none"> <li>1. pathological fracture</li> <li>2. extraoral fistula</li> <li>3. oral-antral communication</li> <li>4. extended osteolyses</li> </ol> </li> </ul>	

### Bisphosphonate-related osteonecrosis of the jaw (BRONJ)

Bisphosphonate-related osteonecrosis of the jaw was described for the first time in 2003. Early reports are listed in Figure 5. More than 400 case series were published in the years that followed. The great increase in the number of case reports might also be because of the increased use of bisphosphonates in the treatment of osteoporosis and tumours. With respect to the definition of osteonecrosis of the jaw under therapy with bisphosphonates, there is no agreement in literature regarding nomenclature and inclusion criteria. The suggestion of the American Association of Oral and Maxillofacial Surgeons (AAOMS) is quoted most frequently. According to that, the disease is called bisphosphonate-related osteonecrosis of the jaw (BRONJ). The criteria for the presence of BRONJ are:

- current or earlier treatment with bisphosphonate
- uncovered, necrotic bone in the jaw for more than eight weeks
- no history of radiotherapy in the gnathofacial region.

Up to now, there is no satisfactory pathogenetic explanation for which mechanisms are responsible for causing osteonecrosis due to bisphosphonates in the end. Only hypotheses serve as approaches to explain

the occurrence of the disease. For example, in particular the inhibition of bone remodelling through bisphosphonates and the bisphosphonate-induced anti-angiogenesis are discussed as causes. It has not been established yet why bisphosphonate-related osteonecrosis only occurs in the jaw. The following particular features of the jaw are discussed as possible causes:

1. desmale ossification of the jaw
2. contamination of the jaw via the teeth
3. prominent points of the jaw with thin mucosal cover and
4. often secondary wound healing (e. g. dental extraction).

Risk factors for the occurrence of BRONJ include:

1. type and duration of treatment with bisphosphonates (the higher the dose and the longer the therapy, the greater the risk)
2. dento-alveolar operations
3. dento-alveolar infections and
4. demographic factors (risk increasing with age, lower in black population than in white).

A large number of associations and expert committees have published recommendations for the prevention and therapy of BRONJ:

- American Academy of Oral Medicine (AAOM) 2005 (Migliorati et al. 2005)
- Deutsche Gesellschaft für Zahn-, Mund- und Kieferheilkunde (DGZMK) [German Society of Dentistry, Oral Medicine and Orthodontics], Arbeitsgemeinschaft (AG) Kieferchirurgie [Working Group for Maxillary Surgery] and Deutsche Gesellschaft für

Mund-, Kiefer- und Gesichtschirurgie (DGMKG) [German Association for Oral and Maxillofacial Surgery] 2006 (Grötz and Kreuzsch 2006)

- Spanish Expert Panel Oncology, Hematology, Urology and Stomatology 2007 (Bagán et al. 2007)
- American Society for Bone and Mineral Research (ASBMR) 2007 (Khosla et al. 2007)
- American Dental Association (ADA) 2006, 2008 (updated) (Edwards et al. 2008)
- American Association of Oral and Maxillofacial Surgeons (AAOMS) 2007, 2009 (updated) (Ruggiero et al. 2009)
- French Expert Panel 2009 (Tubiana-Hulin et al. 2009).

Not all recommendations include strategies depending on defined stages of the disease in order to ensure that the treatment is initiated in a suitable manner according to the severity of the disease. And there are no randomised clinical studies that assess the effectiveness of these recommendations. The recommendations for prevention before treatment with bisphosphonates listed below correspond to the recommendation of the joint scientific statement of Deutsche Gesellschaft für Zahn-, Mund- und Kieferheilkunde (DGZMK) [German Society of Dentistry, Oral Medicine and Orthodontics], the Arbeitsgemeinschaft (AG) Kieferchirurgie [Working Group for Maxillary Surgery] and Deutsche Gesellschaft für Mund-, Kiefer- und Gesichtschirurgie (DGMKG) [German Association for Oral and Maxillofacial Surgery]:

- advice and information on the risk of necrosis of the jaw
- sanitation of all potential focuses of infection in the jaw

**Tab. 2** Authors with publications on the treatment of BRONJ.

Authors	Patients treated (n)	Type of study	Type of therapy	Patients recovered (n)
Nocini et al. (2008)	7	retrospective	antib./surg.	6
Ferran et al. (2008)	1	case report	antib./surg.	1
Engroff & Coletti (2008)	1	case report	antib./surg.	1
Carlson & Basile (2009)	74	retrospective	antib./surg.	66
Stanton & Balasarian (2009)	33	retrospective	antib./surg.	28
Wongchuensoontorn et al. (2009)	3	retrospective	antib./surg.	3
Saussez et al. (2009)	20	retrospective	antib./surg.	4
Williamson (2010)	40	prospective	antib./surg.	40
Abu-Id (2010)	98	retrospective	antib./surg.	93
Nicolatou-Galitis et al. (2011)	67	prospective	antibiotic	10
Wilde et al. (2011)	24	prospective	antib./surg.	20
Hoefert & Eufinger (2011)	46	retrospective	antib./surg.	34

**Tab. 3** Authors with publications on implant insertion with oral bisphosphonate therapy.

Authors	Patients	Implants	Losses	BRONJ
Jeffcoat (2006)	25	63	0	none
Fugazzoto et al. (2007)	61	169	0	none
Brooks et al. (2007)	2	11	0	none
Bell et al. (2007)	42	101	5	none
Grant et al. (2007)	115	468	2	none
Shabestari et al. (2007)	21	46	0	none
Torres et al. (2007)	1	6	0	none

- smoothing of sharp edges of bone
- sanitation of conservable teeth
- checking dental prostheses for pressure sore
- continual recall.

The therapy recommendations in Figure 6 show the recommendations of the American Association of Oral and Maxillofacial Surgeons (AAOMS), updated in 2009. Most publications and guidelines have recourse to these recommendations. The therapy recommendations are presented depending on the stage of BRONJ.

In general, it must be concluded that the use of oral antimicrobial mouthwash solutions combined with oral systemic antibiotic therapy is recommended in early stages. Superficial debridement is occasionally indicated as well. Extensive surgical treatment is mainly reserved for patients in more advanced stages. The treatments performed on BRONJ patients according to literature cannot be classified according to clinical staging, since most publications do not consistently describe the criteria for diagnosis, staging and choice of therapy. In most of the cases described, the treatment of BRONJ consists of a combination of antibiotic therapy and surgical intervention. Many studies, however, are retrospective studies. More and more prospective studies have been published recently. The combined antibiotic/ surgical treatment seems to be superior to pure antibiotic treatment. Table 2 shows a selection of authors who treated BRONJ patients and published this in studies.

The problem about literature evaluation is the poor comparability. Criteria for making the diagnosis, duration of bisphosphonate treatment, extension of the necrotic bone and/or description of the exact surgical procedure are absent in many cases. The treatment of BRONJ is complex and has not been investigated sufficiently. In many cases, the conservative approach does not result in recovery. While most of the treatment options suggested were investigated in a small

number of patients only, they offer new solutions for the future. In all cases, the surgical and non-surgical therapy depends on the extension of the lesions, but also on the patient's general state of health and their life expectancy.

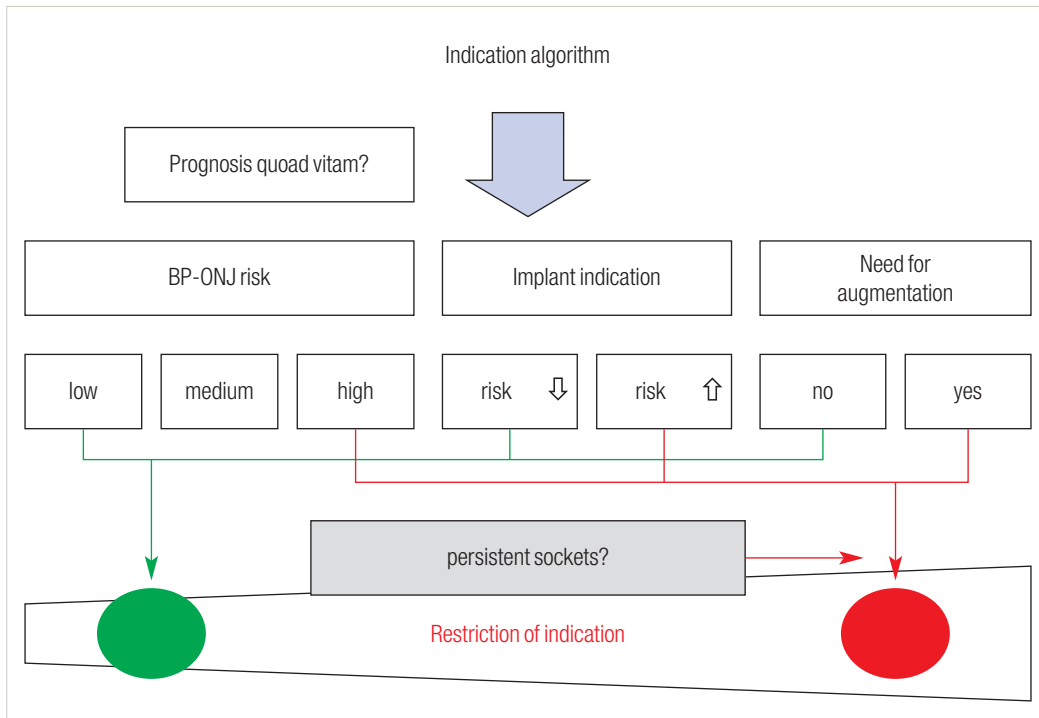
### Special implantologic aspects

Only very isolated reports on the integration of dental implants in tumour patients associated with intravenous bisphosphonate therapy can be found in literature. These reports agree that implant insertions should be refrained from in tumour patients with intravenous bisphosphonate therapy. These patients are considered to be at an excessive risk of developing BRONJ in the context of a dento-alveolar procedure. However, there is a certain number of reports on dental implants in patients under prolonged oral bisphosphonate therapy in literature. Table 3 shows a selection of authors who inserted implants in patients with oral bisphosphonate therapy and published this in studies.

The published cases suggest that the occurrence of BRONJ after implant insertion is rather rare under oral bisphosphonate therapy. Since implant insertion, however, constitutes a dento-alveolar procedure, implant insertion is associated with the risks of a dento-alveolar procedure under bisphosphonate administration, such as the risk of developing BRONJ, but to a much lesser extent than in tumour patients who were treated with bisphosphonates by comparison.

Grötz et al. (2010) recommend the preparation of an individual risk profile for potential implant patients that should include the following three criteria:

1. the patient's individual BRONJ risk,
2. the issue of increase or decrease in the risk of developing BRONJ due to the implantation, and
3. the issue of the necessity of augmentative measures. The diagram shown in Figure 7 helps to illustrate the indication algorithm. The diagram may be



**Fig. 7** Diagram for determining the indication for an implantation in case of bisphosphonate medication (Grötz et al. 2010).

useful in particular for patients who have been treated with bisphosphonates over a long period of time before implantation.

run the greatest risk of developing osteonecrosis of the jaw. Osteoporosis patients with oral bisphosphonate therapy of less than three years are less at risk.

Reports in literature agree that implant insertion in patients with oral bisphosphonate therapy of less than three years constitutes virtually no risk factor for BRONJ. However, implant follow-up should be particularly intensive in these patients as well since the area through which the implant was inserted constitutes an area at particular risk. The same applies to patients who had already received dental implants before a scheduled oral bisphosphonate therapy.

A dental-surgical procedure precedes the onset of the disease in most of the patients. A large number of associations publish recommendations regarding the prevention and therapy of the disease. The use of oral antimicrobial mouthwash solutions combined with oral systemic antibiotic therapy is recommended in early stages. Superficial debridement is indicated as well in some cases. An extended surgical treatment is mainly reserved to patients in more advanced stages.

**\_Prospects**

Although longitudinal prospective studies are being carried out at present, most knowledge on BRONJ originates from the experience of treating physicians, from retrospective studies of patient records and from assumed conclusions of bone physiology and pharmaceutical research. Until long-term prospective studies confirm or correct the current procedures and therapies, we will be on uncertain ground when treating bisphosphonate patients. This problem might be present in particular regarding oncology patients with intravenous bisphosphonate therapy.

Dental implants are contraindicated in tumour patients under bisphosphonate therapy. In osteoporosis patients with oral administration of bisphosphonates (not exceeding three years), however, the risk of developing osteonecrosis is considered to be very low.

*Editorial note: A list of references is available from the publisher.*

**\_Summary**

Osteonecrosis of the jaw is an undesired side effect of bisphosphonate therapy first described in 2003. Patients with multiple myeloma and skeletal metastases who are treated with intravenous bisphosphonates

<b>_contact</b>	<b>implants</b>
<p><b>Johannes Daniel Bähr</b>                  Wilhelmstraße 3                  79098 Freiburg/Breisgau                  Germany</p> <p>johannes.d.baehr@web.de</p>	