

Implant-supported rehabilitation after radiation therapy

Authors_Dr Umut Baysal, Dr Arzu Tuna & Dr Rainer Valentin, Germany

Introduction

The restoration of the masticatory function after therapy of malign tumours of the head and neck is of great importance for the social reintegration of oncological patients. Especially their localisation in the head-and-neck area poses high psychological and psychosocial demands on the patient. The following article gives insight into latest therapeutic successes as well as a patient case from the author's practice.

Practicing dentists play an important role the prevention and early detection of carcinoma of the oral cavity, but they are equally central in masticatory functional rehabilitation post radiationem.¹

In the majority, these are squamous cell carcinomas of varying localisation. Malign tumours of the salivary glands are less frequent (adenoid-cystic carcinomas, mucoepidermoid, adeno and salivary duct carcinomas), lymphoepitheliomas and sarkomas.² Adverse therapy effects often result from combined radio(chemo)therapeutical and surgical treatment, often affecting the physiological anatomy and function. However, both radiation and chemotherapy are integral aspects of the treatment, in addition to the tumour surgery itself. Head-and-neck radiation is performed in squamous cell carcinoma of the oral cavity and the oropharynx as well as malign tumours of the salivary glands and malign lymph nodes.¹

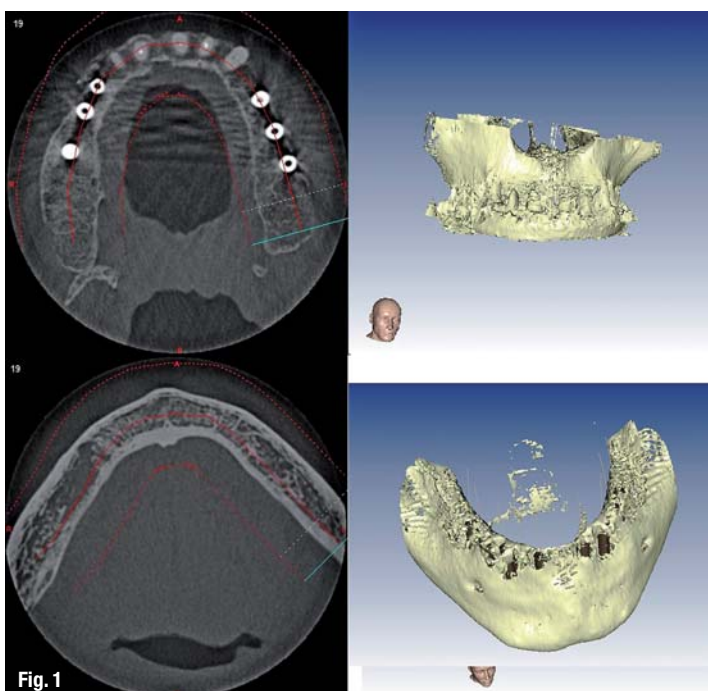
Therapeutic effects

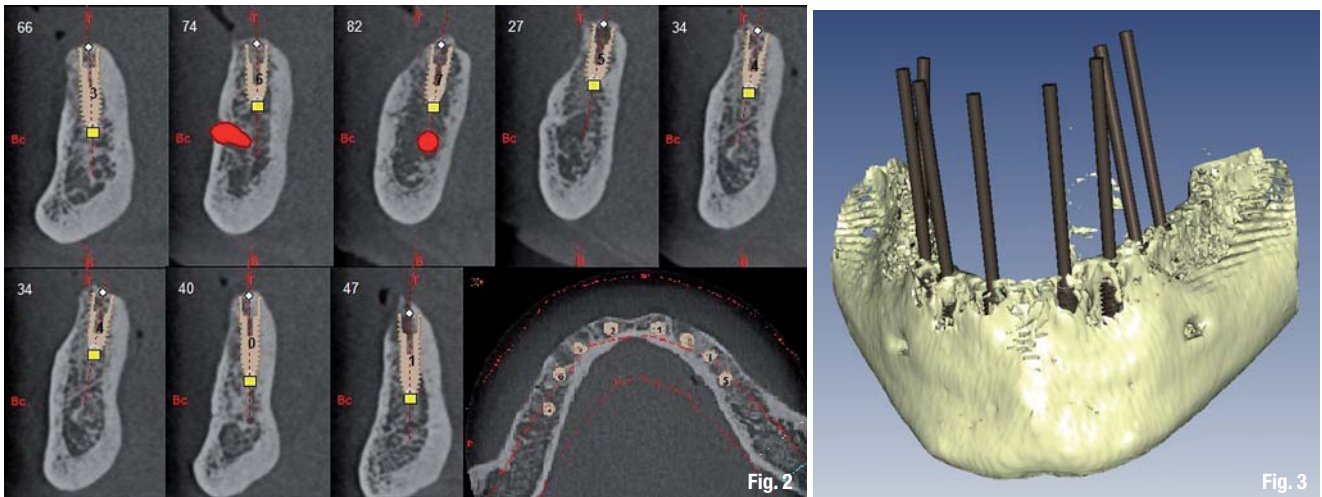
Early, mostly reversible therapy effects (mucositis) are differentiated from late, mostly permanent therapy effects (radioxerostomy, radiation caries, radiation fibrosis, risk of infected osteoradionecrosis (IORN)).²⁻⁵

Infected osteoradionecrosis (IORN) is the most severe local complication. Progressive osteolysis often can only be treated by partial resections of the jaw and they usually demand subsequent elaborate surgical rehabilitation.² IORN is often triggered by operations of the jaw or prosthesis pressure marks. In more than 60 % of IORN cases, infection stems from the dental area, which is increased by the factor three in cases of lacking periradiotherapeutic care.⁶

The extent of the extraction has been discussed controversially, but a selective diagnosis is recom-

Fig. 1_Preoperative condition: circular hybrid bridge in regio 16–26 with abutment teeth 12–23 and implants in regio 16, 14, 13, 24, 25, 26 and an edentulous mandible.





mended in radical extractions.² Further unwanted therapy effects are radiation caries, radio-induced xerostomia and radiation fibrosis. Radiation caries and conventional caries differ drastically in their incidence and course. An early rehabilitation of enamel and dentine lesions as well as therapy via fluoridation splints are significant aspects.^{7,8} Patients, however, see the greatest limitation in their quality of life in radio-induced xerostomia. In its process, many important functions of the saliva are lost. A lack in mucosa lubrication (physiological moistening of the mucosa) will only allow a limited adaptation of the gingivally-supported prosthesis, thus leading to an increase in the prevalence of prosthesis pressure marks. In addition, the remineralisation of enamel and the overall immune defence can be affected.⁹ Conventional prosthetic restorations will reach their lim-

its, consequently raising the demand to resort to implant-supported prostheses.

Implantation

Endosseous implants show five-year survival rates of 72 to 92%.¹ Loss rates are therefore above those of a non-irradiated jaw, but distinctly below those of natural, pre-radiotherapeutic healthy teeth of radiation therapy patients.² While data on titanium implants are available exclusively, there has been no scientific research on ceramics. Implants which have been inserted before radiation do not show any special features. However, peri-implant inflammation should be treated before radiation. While implantation is a significant aspect of tumour surgery¹⁰, implantation post radiationem occurs most frequently.²⁸ Usually, im-

Fig. 2_Virtual implant planning via IMPLA 3D, oro-vestibular cross section with Nervus alveolaris inf. (red).

Fig. 3_Virtual implant planning, depicting the axes.

Fig. 4_Intraoral situation before operation.

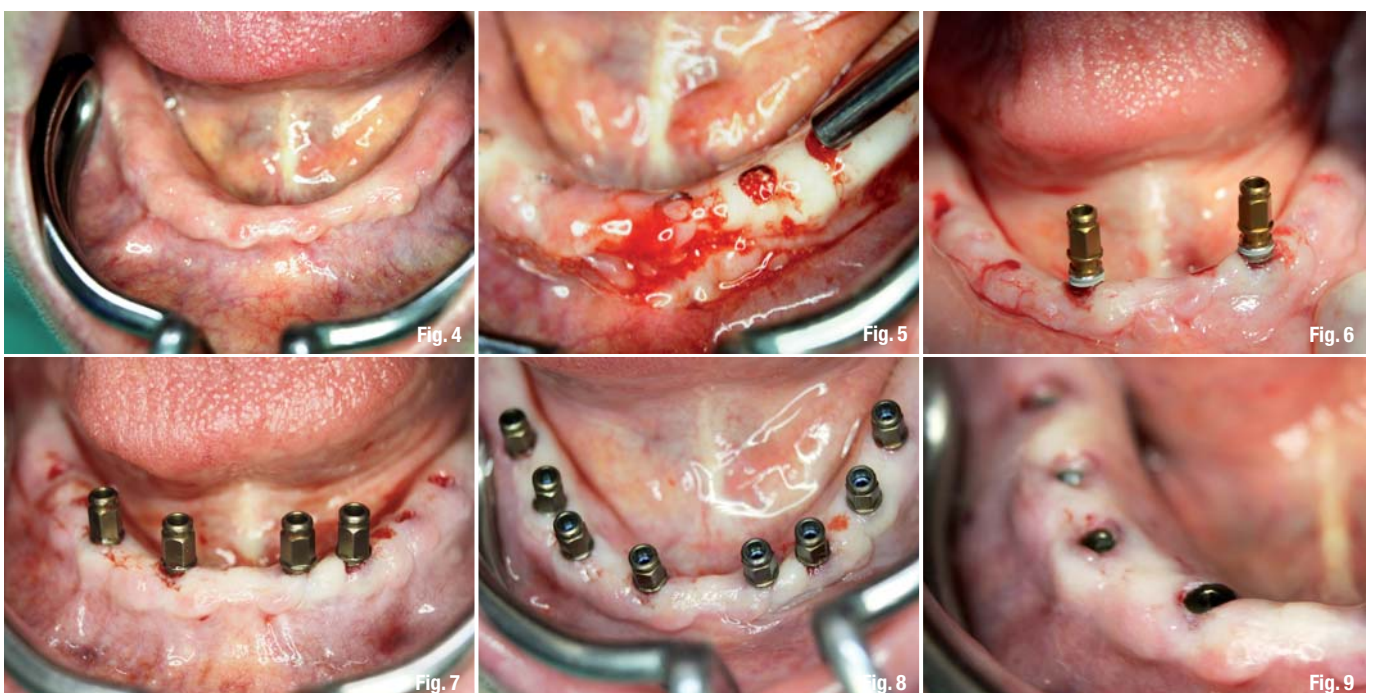
Fig. 5_Template positioned, with pilot drills in regio 33 und 34.

Fig. 6_Implants inserted in regio 33 and 34.

Fig. 7_Further insertion in regio 32 and 42.

Fig. 8_Condition after the planned insertion of eight implants.

Fig. 9_Condition after Insertion of the cover screws in the fourth quadrant.



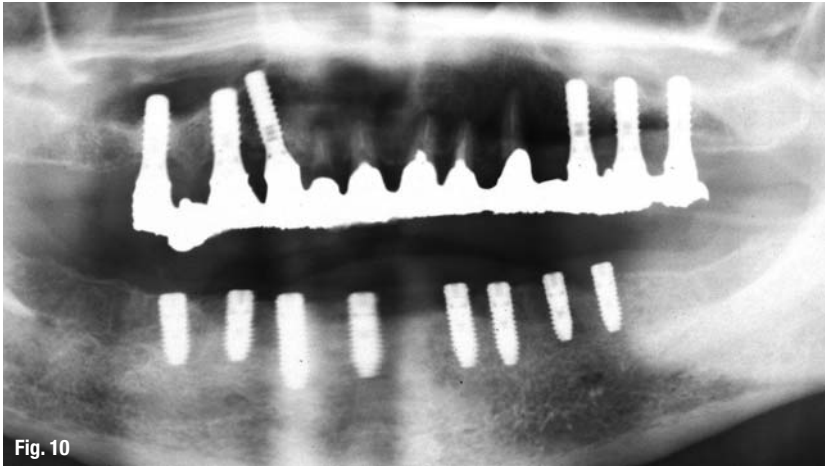


Fig. 10

Fig. 10 Postoperative OPG.

plantation is conducted six to twelve months after radiation, although the temporal interval between radiation and implantation has not been shown to have any influence on the prognosis of the implant.¹¹ The amount of time taken by the healing process is a different story. Here, a period of up to six months is average. Principally, bone augmentation after radiation therapy must be avoided.¹ Resulting from the necessity to minimise risks, three-dimensionally planned implant insertion is indicated, making flapless implantation and avoiding augmentation possible. Special local conditions often lead to an increase in the implant number in comparison to non-radiated patients.

Clinical case

A 70-year-old female patient presented with a circular hybrid bridge in regio 16–26 with abutment teeth 12–23 and implants in regio 16, 14, 13, 24, 25, 26 (Fig. 1). The mandible was edentulous and a removable prosthesis for teeth 36–46 was installed. The patient wished to have a fixed prosthesis for her lower jaw. She was diagnosed with a malign tumour of the salivary glands in 2009. As part of the pre-radiotherapeutic measures, all teeth were extracted from the mandible. Oncological treatment followed as a combination of radiation and surgical therapy. The tumour was removed in toto and no relapses occurred during the frequent recall sessions. Individual risk analysis and therapy planning were conducted in our practice. This included: identification of the radiation date, dose and the dose distribution in the head. Judging from the overall oncological prognosis of the patient, this allows for establishing an individual risk profile. For an absolute risk minimisation, template-guided implantation based on three-dimensional data (CBCT) was indicated. We aimed at making flapless operation without denudation of the radiated bone by template-guided implanta-

tion. Virtual implant planning (IMPLA 3D, Schütz Dental GmbH, Germany) gave the additional benefit of using the pre-existent bone material in total, with the aim of avoiding augmentative procedures (Fig. 2). With regard to the implant prognosis of radiated patients and the target of avoiding gingiva-based support, eight implants were planned in regio 36–46 for a conditionally removable bridge. OPG was used as a postoperative imaging procedure (Fig. 10).

Surgical procedure

As an adjuvant preoperative measure, the oral cavity was treated antiseptically (chlorhexidine 0.2%). Perioperatively, a systemic antibiotics was conducted (amoxicillin, 24 hours before surgery). After local anaesthesia, the template was positioned (Fig. 5), and eight pilot drills were performed. Expansion drills were done according to the manufacturer's protocol. After careful inspection of the drills via button probe, eight implants (IMPLA Cylindrical, Schütz Dental GmbH, Germany) were inserted (Fig. 8). By avoiding any incisions, sutures became dispensable. Punched areas were left to heal by themselves, based on granulation tissue formation (Fig. 9).

Conclusions

Positive long-term results prove the good prognosis for endosseous implants in the radiated jaw, which have a five-year survival rate of 72–92%.¹ However, it must be pointed out that these positive research outcomes were only achieved taking strict perioperative precautions and by close monitoring of the patient (implant recall).² An individual risk analysis and precise planning will support psychosocial integration by implant-supported rehabilitation of the masticatory function with predictable results.

Editorial note: A list of references is available from the publisher.

_contact

implants

Dr Umut Baysal

Dr Rainer Valentin
Deutzer Freiheit 95–97
50679 Cologne, Germany

u.baysal@gmx.de



Tribune CME



6 Months Clinical Masters Program in **Implant** Dentistry

2 May 2013 to 10 November 2013, a total of 12 days
in **Heidelberg (DE), Como (IT), Maspalomas (ES)**



Live surgery and hands-on with the masters
in their own institutes plus online mentoring and
on-demand learning at your own pace and location.

Learn from the Masters of Implant Dentistry:



Dr. Tiziano Testori



Dr. Hom-Lay Wang



Dr. Scott D. Ganz



Dr. Jose Navarro



Dr. Philippe Russe



Dr. Stavros Pelekanos



Dr. Marius Steigmann

Registration information:

2 May 2013 to 10 November 2013, a total of 12 days
in Heidelberg (DE), Como (IT), Maspalomas (ES)

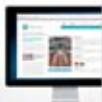Find out more on www.TribuneCME.com

Curriculum fee: € 11,900

contact us at: tel.: **+49-341-48474-302** / email: info@tribunecme.com

Collaborate
on your cases

and access hours of
premium video training
and live webinars



University
of the Pacific

you will receive a certificate
from the University of the
Pacific



Latest iPad
with courses

all early birds will receive
an iPad fully loaded with
premium dental courses



100 ADA CERP
C.E. CREDITS

ADA CERP® | Continuing Education
Recognition Program

Tribune Group GmbH is the ADA CERP provider. ADA CERP is a service of the American Dental Association to assist dental professionals
in identifying quality providers of continuing dental education. ADA CERP does not approve or endorse individual courses or instructors,
nor does it imply acceptance of credit hours by boards of dentistry.