

cosmetic dentistry _ beauty & science

1 2013

| CE article

Bioactive materials support
proactive dental care

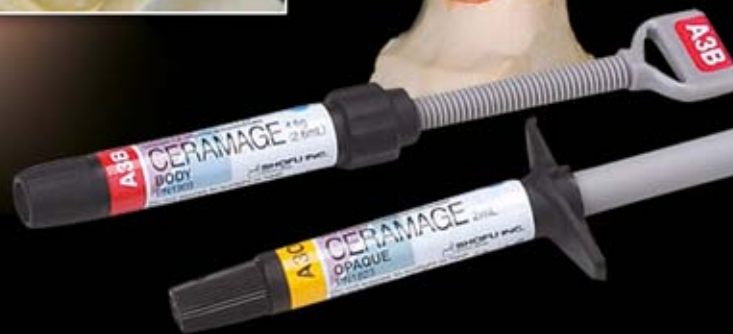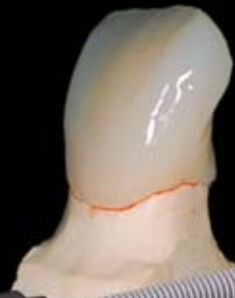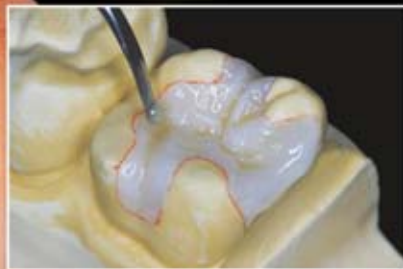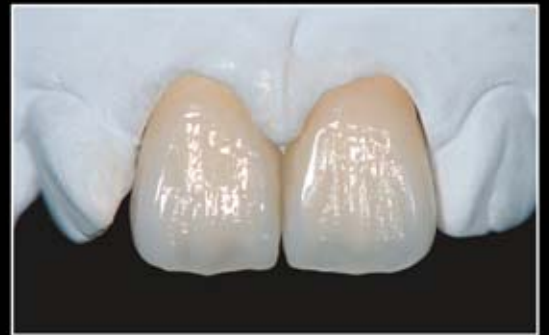| special topic

Deep resins, white fillings:
A new technique for composite restorations

| industry report

Lasers in aesthetic dentistry

Aesthetics of Your Choice



CERAMAGE ...

*A superior Indirect Composite
with Ceramic-Like aesthetics for
Anterior & Posterior Restorations.*

For more information, please contact your
nearest SHOFU dealer.



Official Partner



Minimally Invasive
Cosmetic Dentistry

SHOFU INC. SINGAPORE BRANCH

Tel (65) 6377 2722 Fax (65) 6377 1121

eMail mailbx@shofu.com.sg website www.shofu.com.sg

Dear Reader,

Happy New Year for 2013! May you always have health and happiness in your life.

2012 was very busy for the MICD team. We travelled to various places in Asia to promote the MICD concept and slogan, "Enhancing smiles with minimal biological cost". Our team was invited to many countries to deliver lectures and to conduct hands-on training. It is very gratifying for me to observe that the take-up of the MICD concept around the world has increased rapidly.

I have applied the MICD concept to the majority of worn smile redesign cases that I have treated. Worn smiles may have a negative impact on patients' psychology, health, function and aesthetics. I have noticed in my practice that the demand for treatment of worn smiles has increased dramatically over the past decade, and I think that other dentists have probably observed this too. A combination of factors such as chemical erosion, abrasion, para-functional habits and occlusal prematurities are major causes of worn smiles. Redesign of worn smiles is one of the most complex clinical situations in dentistry and requires detailed examination and evaluation of the patient's diet, history, eating disorders, behavioural factors, para-functional habits, and complete analysis of teeth, muscle, joint and airway (TMJA) harmony, and meticulous treatment planning to achieve the desired function and aesthetics with minimal biological cost.

There are various clinical techniques in oral rehabilitation. Conventional methods use full-coverage crowns that require aggressive tooth preparation and generally have high biological, financial and time costs. However, with the advancement of science and technology in adhesive restorative materials and the availability of digital occlusal analysis technology that can measure precisely different clinical parameters of the underlying force components in a dynamic state, clinicians can treat even complex oral rehabilitation in non or minimally invasive ways so that the biological cost of the treatment can be drastically reduced.

In my practice, I use resin composites in the majority of worn smile redesign cases and I follow the MICD full-mouth rehabilitation protocol, which has four logical clinical steps: 1. develop anterior aesthetics and guidance; 2. establish posterior teeth supports; 3. customise case finishing (aesthetic and force finishing); and 4. recheck para-functional habits.

Once I have restored the smile aesthetics and built up the posterior teeth supports, I customise case finishing. First, I perform the necessary aesthetic finishing, as it is visible to others and can be most appreciated by the patient, then in order to harmonise the occlusal force component I perform digital occlusal analysis and the force finishing of the case. The final step entails rechecking for the absence or presence of para-functional habits (bruxism and clenching) by asking the patient to wear a BruxChecker for three to four nights. After this period, if grinding patterns are visible on the BruxChecker, I always suggest wearing a thin night guard to the patient. I think the reader will find these simple clinical steps for redesigning worn smiles with minimal biological cost useful.

In this new issue of **cosmetic dentistry**, we have gathered a variety of quality clinical articles. I hope you will enjoy reading them.

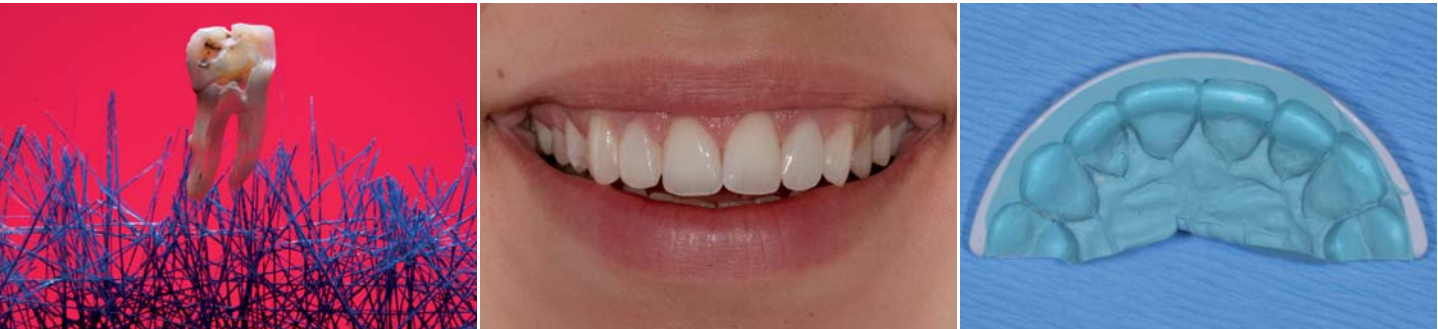Yours faithfully,



Dr Sushil Koirala
Editor-in-Chief
President Vedic Institute of Smile Aesthetics (VISA)
Kathmandu, Nepal



Dr Sushil Koirala
Editor-in-Chief



| **editorial**

03 **Dear Reader**
| Dr Sushil Koirala, Editor-in-Chief

| **CE article**

06 **Bioactive materials** support proactive dental care
| Dr John C. Comisi

| **special topic**

12 **Deep resins, white fillings:**
A new technique for composite restorations
| Dr Irfan Ahmad

19 **Conservative smile enhancement:** Direct composite
resin restoration of conoid lateral incisors
| Dr Monika Marciniak

| **industry report**

22 **Improving success with your cosmetic cases**
using the TMJ QuickSplint
| Dr John F. Weston

26 **Restoration of orofacial aesthetics:**
A new multidisciplinary concept
| Drs Hermes Pretel, Jackson Lins & Ismael Drigo Cação

30 **Lasers in aesthetic dentistry**
| Drs Ilay Maden, Zafer Kazak & Özge Erbil Maden

34 **Stop hurting your patients!**
| Dr Steven G. Goldberg

36 **What constitutes new technology?**
Water flossing revisited
| Deborah M. Lyle

| **industry news**

40 **Kuraray Noritake Dental** proudly presents
world-first innovations in dentistry at IDS 2013
| Kuraray

| **news**

42 **ESCD tenth anniversary** international meeting
| Dr Luca Dalloca

| **meetings**

44 **The annual conference of the**
Society for Color and Appearance in Dentistry
| Dr So Ran Kwon

46 **International Osteology Symposium** in Monaco
| Interview with Prof. Niklaus P. Lang & Prof. Massimo Simion,
congress chairmen

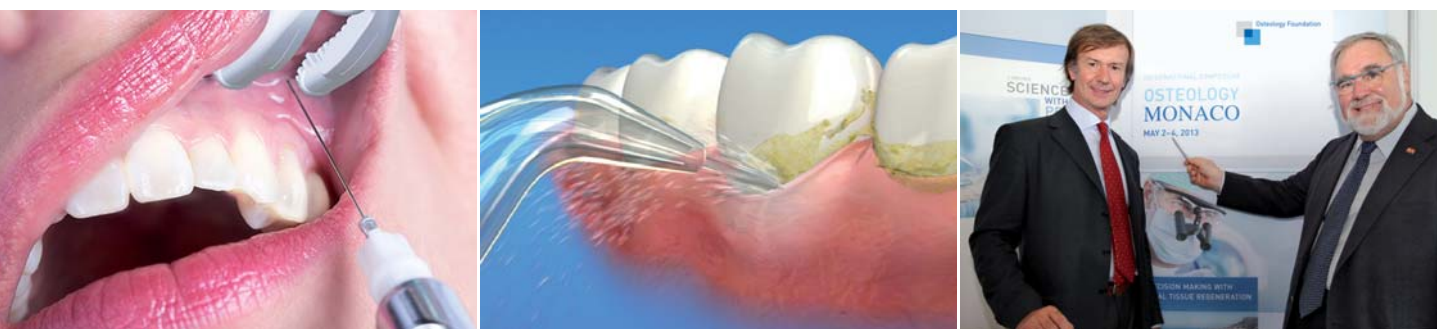40 **International Events**

| **about the publisher**

41 | submission guidelines
42 | imprint



Cover image courtesy of Yuri Arcurs



kuraray

Noritake

**Come and try our
new product at IDS!**

Hall 11.3 · Booth D 010

**Just
blend in!**

CLEARFIL MAJESTY™ ES-2

You'll just be amazed by the blending effects every time you use this intuitive composite concept.

Start working with the new universal CLEARFIL MAJESTY™ ES-2 and something surprising will happen. We re-engineered the color system to make it simply intuitive. Just pick your VITA™ approved colors and start designing nature. To create the perfect adaption to the tooth, we further optimized the consistency. This will give you great confidence during layering. Especially when using our new Premium Enamel and

Dentin colors to naturally layer your restoration. After finishing you will just be amazed by the blending effect.

To create this unique restorative workflow, we used the latest pioneering technologies to make your restorations better, more predictable and longer lasting.



For more information +49 (0) 69-305 35833 or www.kuraray-dental.eu

SCIENCE.KNOWLEDGE.SUPPORT.

Bioactive materials support proactive dental care

Author_Dr John C. Comisi, USA

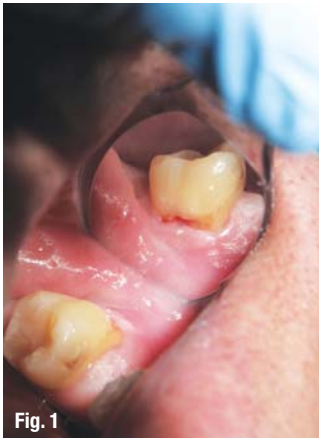

Fig. 1

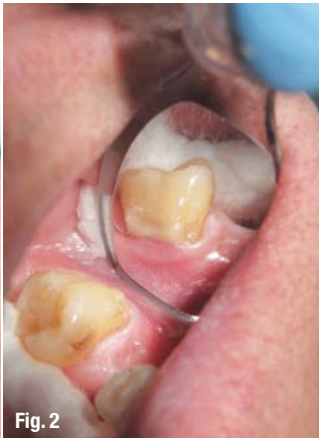

Fig. 2

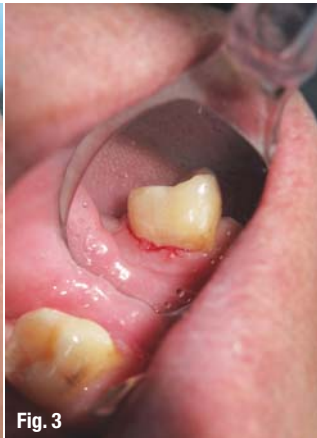

Fig. 3

(Photos/Provided by Dr John C. Comisi unless noted otherwise)

_Resin bonding of the human dentition has become a "standard" in the United States and Canada. There are more than 80 different bonding systems on the market today. We have seen them evolve through multiple generations in an attempt to "simplify" the bonding process. Yet, as these agents have simplified, many in our profession have seen many challenges arise.

A significant number of reports in the literature have been showing that the "immediate bonding effectiveness of contemporary adhesives are quite favorable, regardless of the approach used (however) in the long term, the bonding effectiveness of some adhesives drops dramatically."¹ The hydrophilicity that both etch-and-rinse and self-etch bonding agents offer initially in the dentin-bonding process becomes a significant disadvantage in terms of longterm durability.²

It is this hydrophilicity of simplified adhesive systems combined with other operator-induced challenges that contribute to these failures. Tay, Carvalho, Pashley, et al. have reported repeatedly in the literature of this problem.^{3,4} They continue to report that these bonding agents do not coagulate the plasma proteins in the dentinal fluid enough to reduce this permeability. The fluid droplets contribute to the incompatibility of these simpli-

fied adhesives and dual-/auto-cured composites in direct restorations and the use of resin cements for luting of indirect restorations.

The term "water-tree" formation has been coined to describe this process, which originated from the tree-like deterioration patterns that were found within polyethylene insulation of underground electrical cables. It is now being applied to the water blisters formed by the transfer of dentinal fluid across the dentin-bonding interface. These "water blisters...

act as stress raisers and form initial flaws that cause subsequent catastrophic failure along the adhesive composite interfaces."

The previously mentioned plasma proteins are released by the dentin when subjected to acids and cause hydrolytic and enzymatic breakdown of the dentin and resin bonding agent interface.⁵ These enzymes are called matrix metalloproteinases (MMPs).

Currently, there are only three methods of reducing these MMPs: 2 per cent chlorhexidine solutions that are used prior to application of bonding agents; etchants containing benzalkonium chloride, otherwise known as BAC (i.e., Bisco's Uni-etch products); and polyvinylphosphonic-acid-producing products (glass ionomer and resin-modified glass ionomers).

Due to the short efficacy of these chlorhexidine solutions being used before bonding, this methodology has come into question as of late.⁶ Etchants with BAC have been shown to be valuable in the reduction of MMPs and should be considered in all bonding processes.⁷ However, the most intriguing methodology of reducing MMPs and remineralizing tooth structure is with the use of glass ionomer cements (GIC) and resin-modified glass ionomers (RMGIC).

_ce credit **cosmetic dentistry**

By reading this article and then taking a short online quiz, you can gain ADA CERP CE credits. To take the CE quiz, visit www.dtstudyclub.com. The quiz is free for subscribers, who will be sent an access code. Please write support@dtstudyclub.com if you don't receive it. Non-subscribers may take the quiz for a \$20 fee.

Glass ionomers and resin-modified glass ionomers

Glass ionomer cements have long been used as a direct restorative material. Their early formulations made the material difficult to handle, and the break down of the material made it an undesirable solution in dental restoration. However, these materials, especially in today's formulations and pre-encapsulated presentations, have many properties that make them very important in the restorative process.

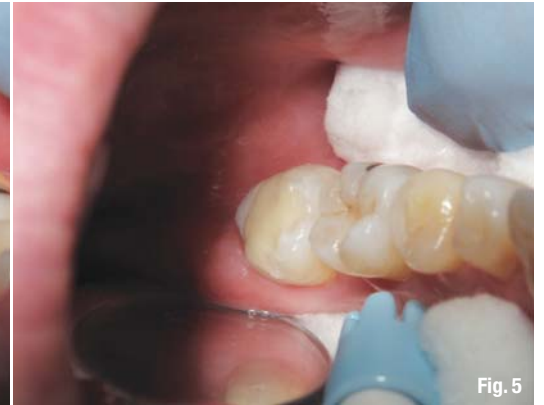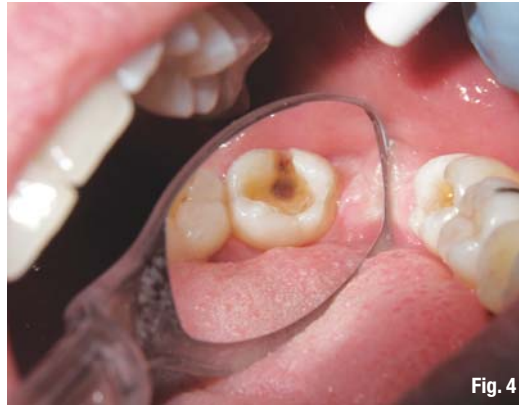The work at companies such as SDI North America (Riva product line), GC America (Fuji product line) and VOCO (Iono product line) have continued to make great strides in improving these products for easier and longer-lasting use of GIC and RMGIC products.

First, these materials are bioactive, and up until recently, they were the only materials with this property; that is they have the capacity to interact with living tissue or systems. Glass ionomers release and recharge with ions from the oral cavity.

This transfer of calcium phosphate, fluoride, strontium and other minerals into the tooth structure helps the dentition deal with the constant assault of the acidic nature of day-to-day ingestion of food and beverages and encourages remineralization; and the incorporation of phosphorous into the acid in today's GICs creates polyvinylphosphonic acid.⁸

This property of GICs makes them a major agent in the reduction of MMP formation, and thereby minimizing if not eliminating the collagen breakdown commonly found in many resin-dentin bonding procedures.⁹

Second, they bond and ultimately form a union with the dentition by chemically fusing to the tooth. The combination of the polyacrylic acid and the calcium fluoroaluminosilicate glass typically found in GICs reacts with the tooth surface, which releases calcium and phosphate ions that then combine into the surface layer of the



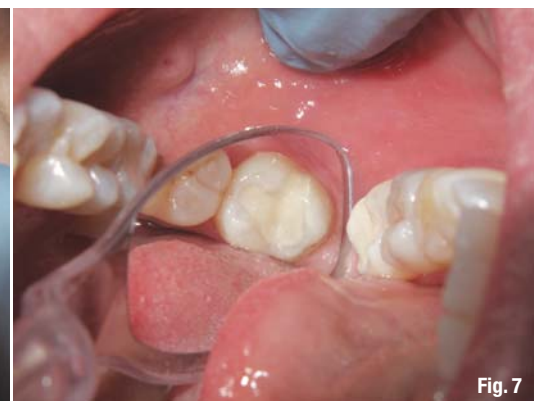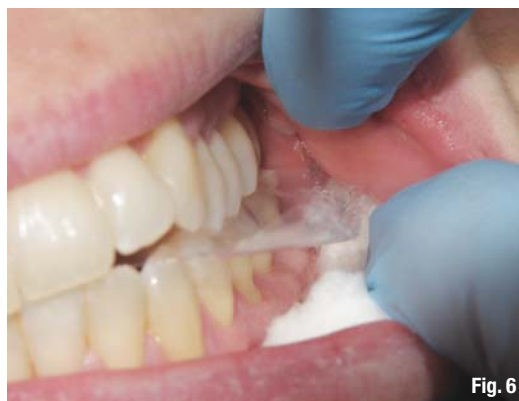GIC and forms an intermediate layer called the "interdiffusion zone."¹⁰

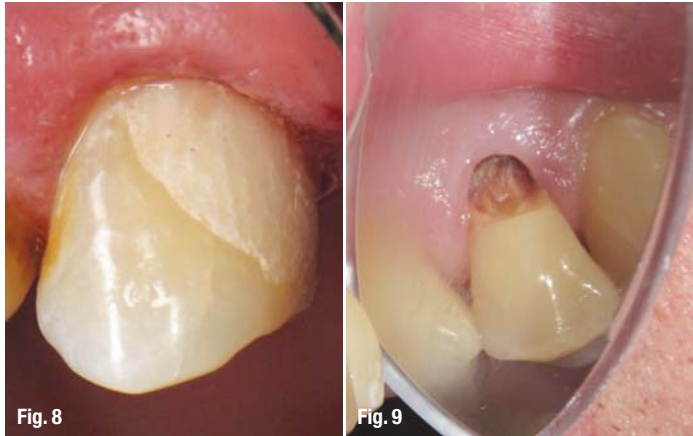
No resin bonding agents are required due to this chemical fusing to the tooth structure. This ion release helps inhibit plaque formation and provides an acid buffering capability that helps to create a neutralization effect intraorally. In addition, these GICs have very good marginal integrity with better cavity-sealing properties, have better internal adaption and resistance to microleakage over extended periods of time, have no free monomers, can be bulk filled and offer excellent biocompatibility.¹¹

Another important consideration is that GICs are moisture-loving materials, which makes them very sensible for use in the intraoral cavity.

The transfer of dentinal fluid from the tooth to the GIC essentially creates a "self-toughening mechanism of glass ionomer based materials... serves to deflect or blunt any cracks that attempt to propagate through the matrix [and]... plays an adjunctive role by obliterating porosities [which] delay the growth of inherent cracks in the GIC under loading."⁴

The intermediate layer of the GIC provides flexibility during functional loading and acts as





a stress absorber at the interface of the restoration and the tooth.¹²

Resin-modified glass ionomers (RMGIC), which are a hybrid of traditional glass ionomer cements with a small addition of light-curing resin, exhibit properties intermediate of the two materials.¹³ This material has been shown to have properties similar to GIC, but with better esthetics and immediate light cure. RMGICs have been shown to undergo slight internal fracturing from polymerization shrinkage, yet have an inherent ability to renew broken bonds and reshape to enforce new forms.¹²

Application of RMGIC to all cut dentin in Class II composite restorations has been shown to "significantly reduce micro-leakage along (the) axial wall" of the restoration,¹⁴ and helps prevent bacterial invasion of the restored tooth. RMGIC bio-materials are multifunctional molecules that can adhere to both tooth structure and composite resin, thus providing an improved sealing ability by chemical or micromechanical adhesion to enamel, dentin, cementum and composite resin.

They, like GICs, can be bulk filled to reduce the amount of composite necessary to restore the cavity preparation and act as dentin substitutes in the restoration.¹⁵

The use of GIC and RMGIC in the restoration of posterior Class V restorations and conservative Class I restorations provides many benefits. They are easy to place and reasonably forgiving, even in a slightly moist environment. They should be placed in a moist but not wet environment, so familiarity with technique is imperative as it is with all dental restorations. I will often use Riva SC (SDI) or Fuji 9 GP Extra (GC America) in posterior Class I and V restorations (Figs. 1–7).

Polishing and shaping of the materials must be done with water spray and fine/ultra fine composite finishing burs and polishers so as not to destroy the surface of the material (Fig. 8). The use of RMGIC products, such as Riva LC or Fuji II LC, is great in bicuspid and anterior Class V restorations, especially in high caries prone patients (Figs. 9–12).

Class II restorations, however, have always presented a challenge to the clinician. If the operator wanted to use GIC or RMGIC, there was no easy way to do this that appeared to provide satisfactory results. It is with this in mind that the "sandwich technique" was developed.

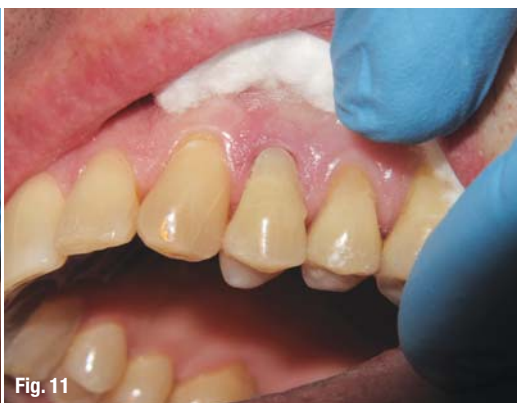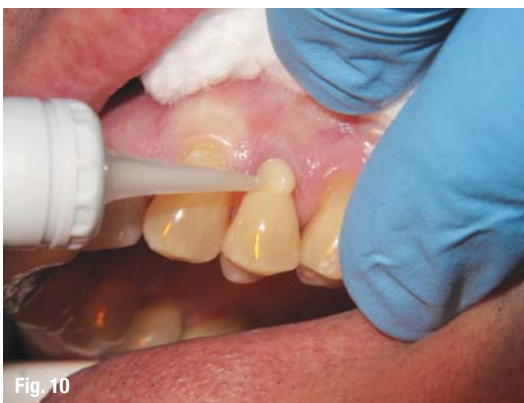It was thought that using the properties of GIC to bond to the tooth and then applying resin-bonding agents and composite to the set GIC could help reduce sensitivity and bond failures typically seen in many resin-bonded composite (RBC) techniques.

Typically, the GIC is placed in the preparation, allowed to set, cut back to ideal form and then bonded to with an RBC technique. However, the inability of RBCs to adhere to the set GIC often creates many failures. The materials by themselves are incompatible over the long term.

The modified sandwich technique evolved as a means to overcome this problem. Placing RMGIC over set GIC—and then adding a RBC to that—provided a better solution, but was as laborious and time consuming to do, as is the sandwich technique.

The 'Co-Cure Technique'

In 2006, an article was published¹⁶ that, in my opinion, has revolutionized the way I approach direct posterior restorations and direct restorations as a whole. The article presented a radical approach to direct posterior



restorations, called the Co-Cure Technique. This technique is defined as the simultaneous photo-polymerization of two different lightactivated materials that involves "the sequential layering of GIC, RMGIC and composite resin prior to photo-polymerization and before the initial set of the GIC [which] enables an efficient single-visit placement of a [direct] restoration..."¹⁶

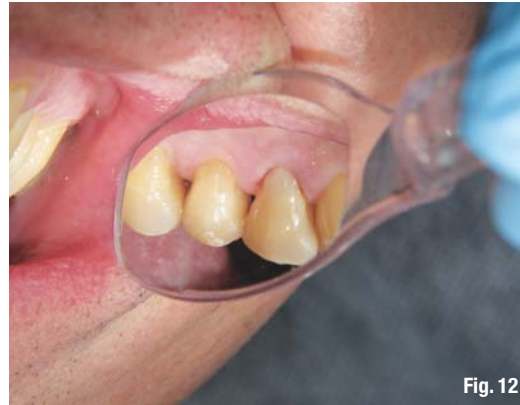

Fig. 12

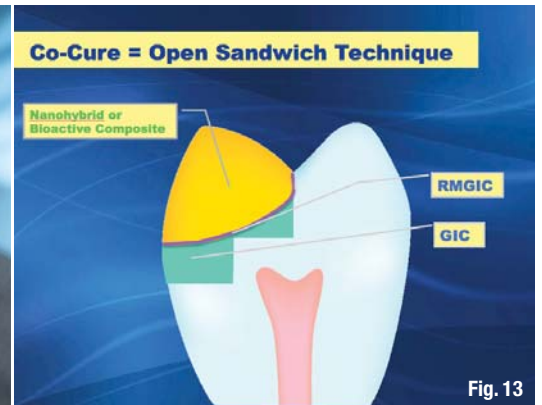


Fig. 13

In the Co-Cure Technique, the composite restoration does not require a bonding agent because the bonding agent is essentially the RMGIC. The RMGIC acts as the interface between the GIC and the composite material. It combines the GIC, RMGIC and composite in a way to form what can best be described as a "monolithic biomimetic restoration."

This restoration is an "open sandwich" type of sandwich technique. That is, the GIC component is exposed to the oral environment (Fig. 13) at the gingival portion of the restoration. It is quickly and efficiently accomplished and has significantly reduced postoperative sensitivity compared with typical direct RBC techniques. I have been placing these types of direct posterior restorations since 2008. They have become the cornerstone of my practice.

Technique procedure (Fig. 14)

After placement of an appropriate dental matrix, the technique incorporates the use of 37 per cent phosphoric acid to prepare the tooth for restoration. The acid is essentially "flooded" into the preparation in a similar manner to doing a "total-etch" RBC. It is, however, washed off after five seconds of placement. The tooth is then dried but not desiccated. The area remains slightly moist because the GIC that will be placed next is hydrophilic.

Fill the preparation with the triturated GIC material up to the level of the DEJ, then immediately place the triturated RMGIC in a very thin layer to cover the GIC and walls of the preparation. Finally, place the composite over the previous materials to slightly overfill the preparation. With a large round burnisher dipped in an unfilled resin material (i.e., Riva Coat by SDI or G-Coat by GC), wipe away the excess GIC and composite restoration material to create your margins and prevent ditching and white lines.

The occlusal table of the restoration can then be compressed gently with a plastic occlusal matrix by either having the patient bite or by the operator pressing gently with his thumb or forefinger to improve the coalescence of the three materials. This can help reduce the time involved in creating the final occlusion of the restoration by creating a functional occlusal table.

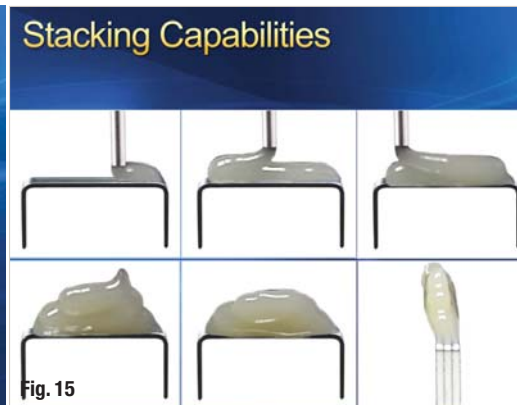
The restoration is then cured for 30 to 40 seconds with an LED curing light that generates at least 1,500 mW/cm². Appropriate light output is critical for all direct cured restorations, and assurance that appropriate output is provided by the curing light is needed for complete cure of any direct restoration.

The restoration is evaluated for complete cure and then a layer of an unfilled resin is placed on the exposed GIC/RMGIC/composite complex and cured for an additional 10 seconds. The matrix band is removed and the restoration is trimmed and polished as any typical RBC restoration would be.

I have found that an entire three-surface posterior restoration can be accomplished in less than three minutes once the matrix has been placed. Typically, finishing the restoration can also be done in less than three minutes. This makes the direct posterior restoration quite efficient and beneficial to the clinician and the patient because we are providing a restoration that will help enhance healing of the dentition and reduce recurrent decay and restorative failure.

— Nanotechnology in dental materials

Nanotechnology involves the production of functional materials and structures in the range of 0.1 to 100 nanometers by various physical or chemical methods. Today, the development of nanotechnology has become one of the most highly energized disciplines in science and technology because it can stimulate the creation of many new



No other composite material has this property to date. I use these giomers instead of traditional nano-hybrid composites in my restorations because of these properties. They complete the entire biomimetic and bioactive nature of all the co-cure procedures that I create.

The Beautiful Flow Plus product line has also expanded the way that I create

restorations due to their unique viscosities. These materials can be stacked (Fig. 15) and used in a restorative process I call the "modified resin cone technique" (Fig. 16).

They can also be applied to create direct composite veneers that can be easily placed, sculpted and highly polished (Fig 17). Easy placement, the ability to stack and maintain position and shape, plus their bioactive nature, make these materials a "game changer."

Several studies^{17,18} have shown that the inclusion of these types of nano-fillers and nano-fibers into the dental materials (dental composites and bonding agents) can improve the physical properties by increasing the strength, polishability, wear resistance, esthetics and bond strengths in many dental applications.

It is also envisioned that the incorporation and utilization of these nanoparticles in the form of nanorods, nanofibers, nanospheres, nanotubes and ormocers (organically modified ceramics) into dental restorative and bonding agents can create more biomimetic (life-like) restorations. This will not only enable these materials to mimic the physical characteristics of the tooth structure, but will also be able to facilitate the remineralization of that structure.

_Giomers

As Saunders states in his conclusion, "such nanorestorative biomaterials could very credibly be the next transformative clinical leap" in restorative dentistry.

In that vein, an exciting advancement in bioactive materials is the development of giomer products (SHOFU Dental, Beautiful II, and Beautiful Flow Plus). These giomers are resin-based composites that contain pre-reacted glass ionomer particles (S-PRG). These particles are made of fluorosilicate glass reacted with polyacrylic acid (just like a GIC), just before being incorporated into the resin. This creates a new type of bioactive material.

These giomer products display properties in a manner similar to GICs¹⁹: They release ions and recharge with ions from the oral cavity, inhibit plaque formation and neutralize and buffer the acids of the mouth.²⁰

Another advancement that I have been working with is a product that is a resin-modified, light-cured bonding agent (SDI, North America: Riva Bond LC). This product is a specially formulated liquid RMGIC that can be used to bond composite restorations in the traditional sense, used in traditional sandwich and modified sandwich techniques and, of course, used in the Co-Cure Technique.

This concept is especially appealing in light of the research that indicates RMGICs provide quite good marginal seal when used as a bonding agent on cut dentin surfaces.¹⁴ I especially like to use it with the Co-Cure Technique and when doing anterior restorations.

_Resin-modified, light-cured bonding agents

Using this technique I am able to get a completely biomimetic, bioactive restoration in both situations because of the bioactive nature of the materials used.

The technique for use of this RMGIC bonding agent with composite is as follows:

- 1) Etch with 37 per cent phosphoric acid for five seconds.
- 2) Wash and dry but do not desiccate.
- 3) Triturate and apply the RMGIC bonding agent

with a micro-brush and cure for 20 seconds.

- 4) Place composite to fill the preparation and cure as appropriate.

When I use this material in the Co-Cure Technique, I just substitute it for the traditional RMGIC material that I would have used otherwise.

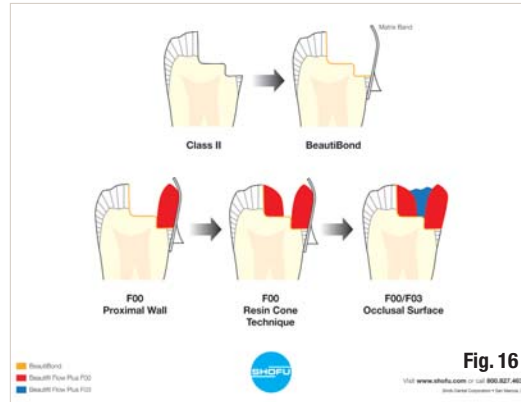


Fig. 16

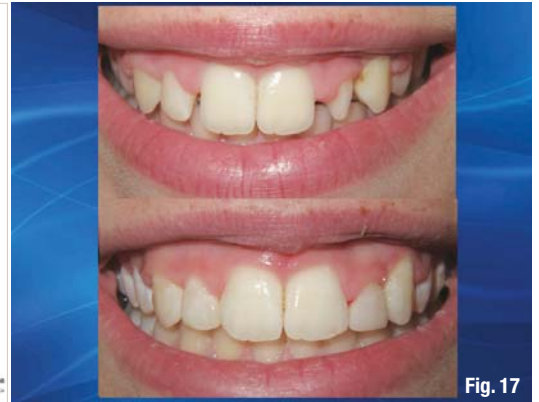

Fig. 17

Resin-modified calcium silicates

Another recent interesting product release is from Bisco and is called TheraCal LC. This light-cured bioactive material is used to seal and protect the dentin-pulp complex. It is the first of a new class of internal pulpal protectant materials known as resinmodified calcium silicates (RMCS).

It acts as a pulp capping and liner material. Calcium hydroxide (CH) has been the "gold" standard for pulp capping for many years. However, it has always had difficulties in use as a liner under RBC adhesives. In fact, despite their frequent use, the success of CH based therapies is only 30 to 50 per cent.²¹

It has also been shown that traditional resin-based light-cured liners have been cytotoxic to cultured odontoblast-like cells, while light-cured resinbased MTA cements presented the lowest cytopathic effects.²² Based on this, the creation of light-cured RMCS is a logical step in developing a solution for direct pulpal protection. Calcium has been shown to be crucial to the formation of apatite, dentin bridge formation and re-apatite potential of affected dentin.

Additionally, alkalinity also seems to be contributory toward this goal. This combination in the RMCS material appears to form good, hard and thick dentin bridges and stimulates dentin pulp cells to turn into odontoblastic dentin cells.²³

This type of material represents a promising new direction in direct pulp-capping clinical procedures with its ability to form apatite and further contribute to the formation of new dentin.

Conclusion

It is my belief that using bioactive materials in the provision of care for my patients has been

paramount to the success of the care I have been providing. In this way, I have provided ways to heal the dentition, enhance the restoration and improve the health of my patients.

I believe we are on the threshold of further bioactive material advancements and that learning and incorporating these restorative materials into the day-to-day provision of care will continue to help our patients, our practices and our profession.

Editorial note: A complete list of references is available from the publisher.

about the author

cosmetic
dentistry



Dr John C. Comisi, DDS, MAGD, has been in private practice in Ithaca, NY, since 1983. He is a graduate of Northwestern University Dental School and received his Bachelor of Science in biology at Fordham University.

He is a member of the American Dental Association and its tripartite organizations, the Academy of General Dentistry, the American Equilibration Society, the International and American Association of Dental Research, a research associate at New York University Dental School and an editorial board member of Dental Products Shopper Magazine. Comisi is a Master of the Academy of General Dentistry, and holds fellowships in the Academy of Dentistry International, the American College of Dentistry, the Pierre Fauchard Academy and the International College of Dentistry. He may be contacted at jcomisi@jcomisi.com.

Deep resins, white fillings: A new technique for composite restorations

Author _ Dr Irfan Ahmad, UK

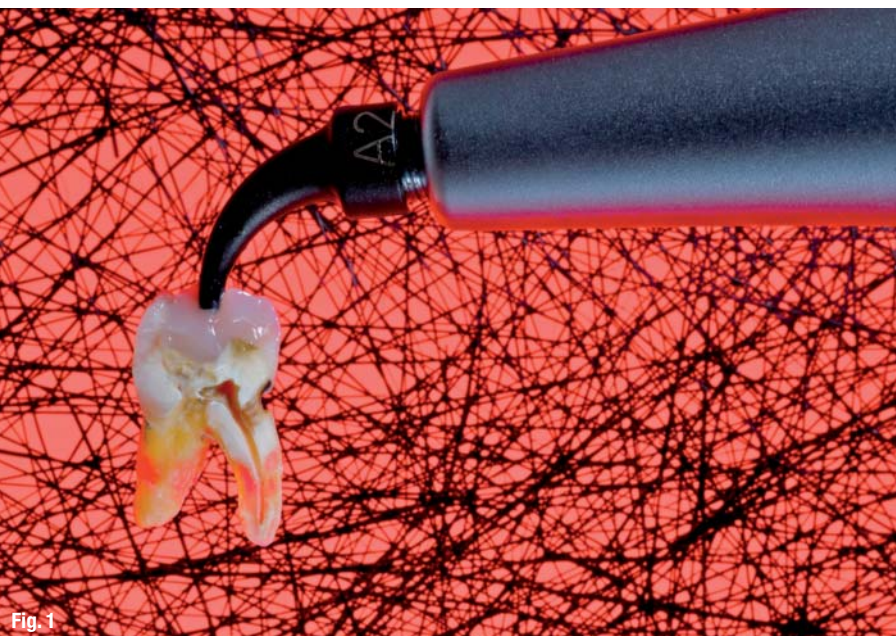

Fig. 1

Fig. 1 _The SonicFill system consist of a handpiece for delivering sonic energy to a dispensing tip containing a specially formulated resin-based composite.

Fig. 2 _Pre-operative lower left mandibular molar showing rampant occlusal decay.

Fig. 3 _A round bur is used for judicial decay excavation, leaving deeper decay *in-situ* to avoid accidental pulpal exposure.

Fig. 4 _Completed cavity preparation following decay removal, with 90 degrees cavo-surface angles.

Fig. 5 _A periodontal probe confirms the cavity depth for ensuring that a single increment of 5 mm of the resin is sufficient to fill the cavity.

_Abstract

This article describes a new bulk-fill resin, or deep resin composite, SonicFill (Kerr Corp., USA), possessing fluctuating viscosity by the application of sonic energy. The rationale for the system is explained, together with concerns and the benefits in clinical practice. Deep

resins are primarily indicated for white fillings in posterior teeth, but the unique varying viscosity of the SonicFill concept offers other useful clinical applications. Numerous case studies are presented for a variety of clinical situations including replacing defective posterior fillings; core build-ups and retaining fixed orthodontic brackets and retainers.

_Introduction

The use of amalgam for posterior restorations has declined considerably in the last two decades, and continues to do so. The reasons are twofold, first, scientific advances in the development of superior, alternative restorative materials and second, patient wishes.

One of the major concerns about amalgam restorations is cavity preparation, which is both invasive and extensive, undermining the remaining tooth substrate already ravished by disease. Furthermore, placing amalgam restorations without a dentine-bonding agent fails to seal the margins, and is therefore potentially detrimental.

From the patients' perspective, grey fillings are unsightly, especially in mandibular teeth, and usually shunned in favour of tooth coloured "white" restorations. However, the clinical time and cost of these

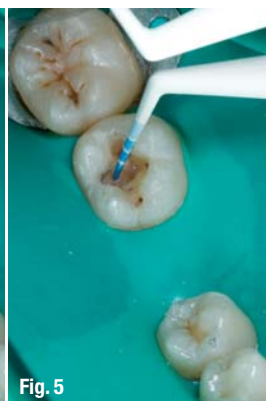
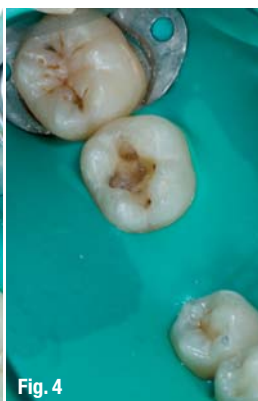
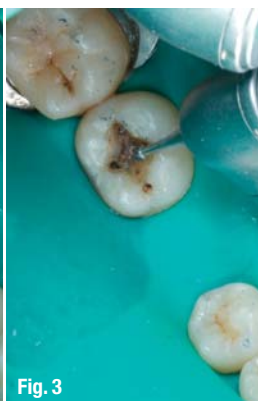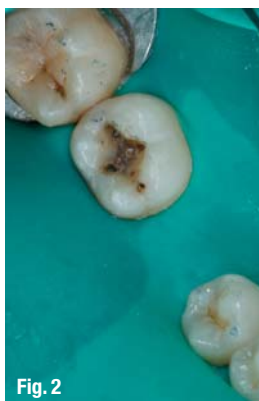Fig. 2

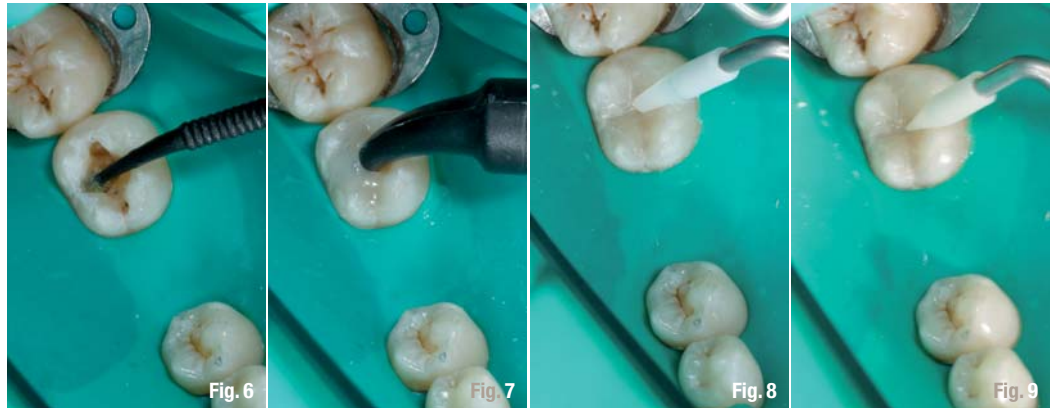
Fig. 3

Fig. 4

Fig. 5

aesthetic white restorations is far greater than the single-step amalgam fillings.

The launch of bulk-fill composites, or deep resins, a few years ago is a sign of the times. The epicurean and prosperous lifestyles of the last two decades are being traded for austerity and frugal constraints. Hence, the introduction of these restorative materials is both timely and fortuitous.



Both patients and dentists are forgoing their hedonistic demeanour for asceticism, seeking ways to reduce expenditure while striving to maintain standards. Patients are declining treatment plans that they may have considered prior to the credit crunch, in favour of simpler and cost effective methods for restoring dental health. In addition, dentists are no longer complacent about elaborate treatment plan acceptance, and instead are offering less expensive, timesaving alternatives for achieving health and function, without the opulence of superlative aesthetics. Thus, the bulk-fill deep resins, which offer expediency and reduced treatment cost, are catering for the current economic volatile market.

_Incremental vs. bulk-fill

Currently, the options for placing direct tooth coloured restorations are either by the incremental or bulk-fill approach. The rationale for incremental layering is that most universal hybrid composites can only be cured to a depth of 2 mm, and hence consecutive layers are necessary to fill the cavity.¹ Furthermore, successive layers reduce the cavity configuration factor (C-factor) for lowering pulpal deflection² and mitigating bond failure³ following polymerisation shrinkage. In addition, superior aesthetics can be achieved by mimicking the natural dentine and enamel layers with corresponding increments of the RBC and incorporating specific tints and stains. Hence, highly aesthetic restorations with superior anatomical form are possible. However, with contemporary universal hybrid composites possessing low-shrinkage & low-stress,⁴ the C-factor and microleakage are less of a concern.⁵ The disadvantages of incremental layering is the onerous process with greater probability for introducing porosity between the layers, and the protracted treatment session is reflected by a higher cost for the patient. Furthermore, the initial flowable stress relieving lining is ineffective for reducing cuspal deflection,⁶ further questioning the validity of this procedure.

Unquestionably, the incremental approach is ideally suited for anterior restorations where aesthetics are a prime concern, but is it also necessary for posterior

restorations? In a recent article, Smales et al.⁷ stated that "...clinical technique is the determining factor for success and longevity of composites", and added there has been "...little improvement in the last 30 years!" Therefore, any procedure that simplifies the taxing clinical technique of composite placement is likely to improve predictability and durability of restorations. Consequently, introduction of bulk-fill resins endeavour to expedite direct composite restorations in posterior teeth. The rationale of the bulk-fill resins is reducing clinical steps by a filling the cavity in a "single" increment, thereby simplifying the existing incremental technique. This also ensures reduced porosity and uniform consistency restoration, with reduce clinical time and cost for the patient.

At present three types of bulk-fill resins are available, distinguished primarily by their viscosity, which is low, medium or fluctuating. The low viscosity variety offers superior adaptability, while the medium viscosity type is better for carving and sculptability (see schematic representation on the illustration below).

_A utopian composite?


Contemporary resin-based composite filling materials can arbitrarily be categorised as flowable and universal composites. Each variety has unique chemical,

Fig. 6 The bonding agent, OptiBond XTR primer, followed by the adhesive, is copiously applied to both enamel and dentine, according to the manufacture's instructions.

Fig. 7 The appropriate shade of SonicFill deep resin is dispensed into the cavity using the handpiece, ensuring that the Unidose tip is totally submerged in the material to avoid entrapment of air.

Fig. 8 After the tip is removed, the SonicFill resin regains its high viscosity to allow sculpting, in this instance, a flat shape CompoRoller carving tip is used for creating cuspal inclines.

Fig. 9 A conical shaped CompoRoller carving tip is used for refining occlusal fissures.



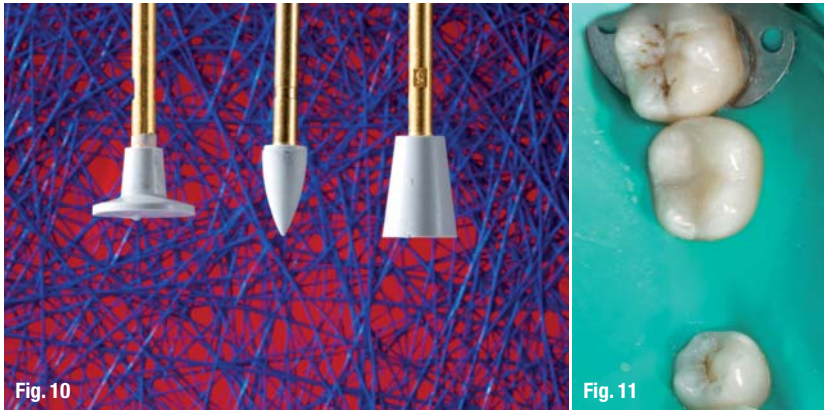


Fig. 10

Fig. 11

Fig. 10 Finishing and polishing is accomplished by using various shapes of Opti1Step polishing tips.

Fig. 11 The post-operative result shows the polished SonicFill deep resin: white filling displaying acceptable aesthetics.

physical, mechanical and optical properties, but the disguising feature between the two composites is their handling properties.

Flowables are low viscosity, offering improved wettability for better adaptation to cavity floors and walls, while the universal composites offer high viscosity allowing optimal sculptability and carving for creating correct anatomical morphology. Hence, the clinician is faced with a catch-22, ideally adaptability is essential, but the slumping sticky flowables are not conducive for shaping.

Conversely, the high resistance to flow of universal composites are ideal for contouring but may create voids within the restoration or the cavo-surface margins due to reduced fluidity. A utopian composite should possess the handling characteristics of a flowable for adaptation, as well as having high viscosity for facilitating sculpting. The SonicFill system resolves this dichotomy.

The SonicFill system

The SonicFill system consists of a handpiece that dispenses a resin-based composite filling material. The handpiece, designed by KaVo (Biberach), delivers sonic energy at varying intensities, which is adjusted on the shank from low to high (1 to 5) to control rate of composite extrusion. The handpiece fits onto the KaVo MULTIflex coupling and is operated by the universal foot control. The specially formulated deep resin is manufactured by Kerr (Kerr Corp., USA), which incorporates

modifiers that react to sonic vibrations to alter the viscosity of the material. The Unidose capsules have smaller diameter 1.5 mm tips for accessing deep cavities, compared to the conventional larger 2.5 mm pre-loaded tips (PLT). The resin dispensing tips screw directly onto the handpiece head and deliver the composite when activated by the foot control. The sonic energy reduces the viscosity of the resin by 87 % allowing adaptation in deep cavities, up to 5 mm, in a single increment (Fig.1). After the foot control is released the sonic energy ceases, and the resin returns to its high viscosity state, facilitating sculpting and carving to the desired anatomical form. Another defining feature of this unique deep resin is that it can be light cured to depths of 5 mm (20 seconds for LED units with an output of 800 mW/cm²) in a single layer. Additional 10 seconds curing from both buccal and lingual sides are also recommended. The final stage is polishing the white filling, which is achieved with appropriate rotary instruments such as OptiDisc & Opti1Step (Kerr, Switzerland)—see case study in Figs. 2–11. Furthermore, the SonicFill resin has greater radiopacity than enamel, allowing easy detection of secondary caries.

The concerns

As with any new product, there is a degree of scepticism, and inertia for adopting to a new technique and material. Some of the questions asked about the SonicFill system include the following:

Does bulk filling increase polymerisation shrinkage and associated stresses?

A low shrinkage composite is defined as having less than 2% polymerisation shrinkage.⁸ In addition, the stresses associated with volumetric contraction are more significant since they should be lower than the shear bond strength of the dentine adhesive to prevent bond failure and formation of voids at the tooth-resin interfaces.

Some of the older "condensable" composites exhibited excessive stresses during the polymerisation phase causing detachment of the filling material from the cavity walls, resulting in marginal discrepancies and post-

Fig. 12 A molar tooth showing a deep tortuous cavity, ideally suited for restoring with a bulk-fill deep resin, up to a depth of 5 mm with a single increment.

Fig. 13 The erratic terrain of amorphous shaped cavities are best filled a low viscosity composite for superior adaptation, which can be achieved by temperature or applying sonic energy to a resin-based composite to improve flowability.

Fig. 14 A Class I cavity with undercuts at its floor for retaining an amalgam filling.



Fig. 12

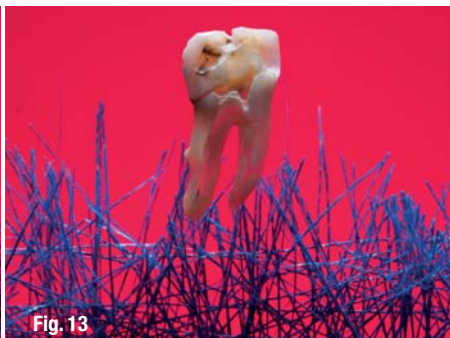
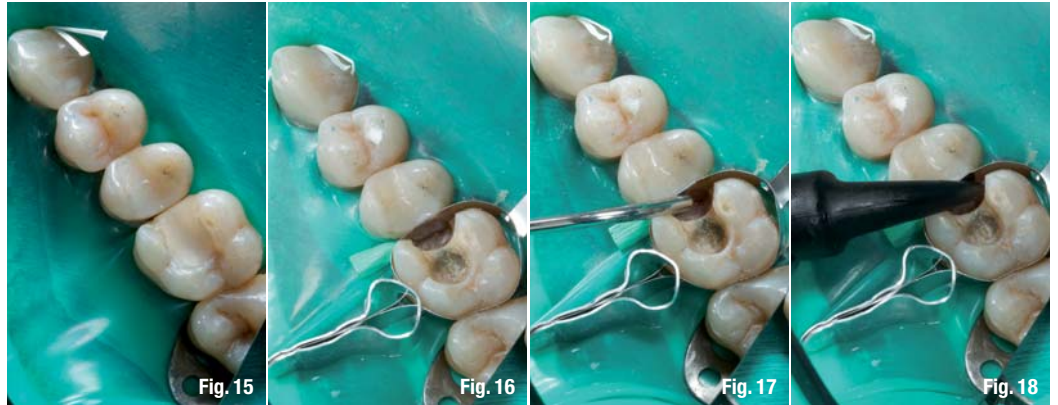
Fig. 13



Fig. 14

operative sensitivity. Numerous newer low shrinkage resins offer <2% contraction, and the highly filled (>83% by weight) SonicFill resin has shrinkage of only 1.6%. Furthermore, the associated reduced stresses of 3 MPa are lower compared to many universal composites, which translates to the positive assumption that gap-free restorations are possible with bulk-fill deep resins.⁹



Is a "flowable" composite strong enough to resist occlusal forces?

Flowable composites, by definition, are weaker materials due to reduced filler content for lowering the viscosity of the material, and are therefore unsuitable for occlusal load bearing surfaces. Class I, II, and VI cavities require high strength and high wear resistant composites to maintain occlusal morphology.

Research has confirmed that universal composites function adequately under normal occlusal forces.¹⁰ Although SonicFill transiently becomes flowable by applying sonic energy, it is essentially a high viscosity, highly filled composite with a compressive strength of 254 MPa, great than several universal composites.¹¹ In addition, it displays a bottom to top Rockwell hardness ratio of 86% making it ideal for resisting occlusal forces.

Can a 5 mm increment be completely polymerised to its full depth?

The maximum thickness recommended for most universal and flowable composites is 2 mm for ensuring adequate bottom to top polymerisation of the resin. The conversion of the monomer matrix to a polymer is primarily dictated by the formulation of the resin material. Nevertheless, many studies have concluded that the depth of conversion of bulk-fill composites is a viable possibility.¹²⁻¹⁴

The greater amount of photoinitiators in the SonicFill composite resin allow a high degree of conversion ratio, more than 86%, to a full depth of 5 mm (Fig.12). Therefore, the proverbial 2 mm layer thickness is an antiquated guideline for bulk-fill, deep resins.

Are aesthetics compromised using a single monochromatic layer?

Although aesthetics are paramount for the anterior region of the mouth, and indeed, success is often judged by the appearance of the restoration, posterior restorations are not assessed with the same critique. Innumerable clinicians, including the author, have published articles showing beautifully carved posterior composite fillings with intricate fissure patterns and staining that impeccably mingle with the surrounding tooth substrate. From an aesthetic perspective, these immaculate fillings are unquestionably flawless.

However, others frown at such "perfection", stating that it is an exercise in self-indulgence, adding little functional or health benefits, to which a patient is totally indifferent. This is further elaborated by pointing out that patients do not notice this meticulous work or the effort required for achieving these highly aesthetic restorations (especially in maxillary molars). Further criticism is that patients are unlikely to photograph their posterior teeth, enlarge the images, and neither scrutinise nor appreciate the arduous effort for creating such 'masterpieces'.

Fig. 15 A pre-operative defective mesio-occlusal composite restoration in maxillary right molar showing marginal breakdown, ditching and poor occlusal anatomy.

Fig. 16 After removing the filling, a MetaFix (Kerr, Switzerland) matrix band and wooden wedge are placed to shape the filling and obtain a tight proximal contact point, respectively

Fig. 17 A burnisher or LM-Arte Condensa (LM-Instruments Oy, Parainen) is used to adapt the mesial aspect of the matrix band to the distal aspect of the anterior second premolar.

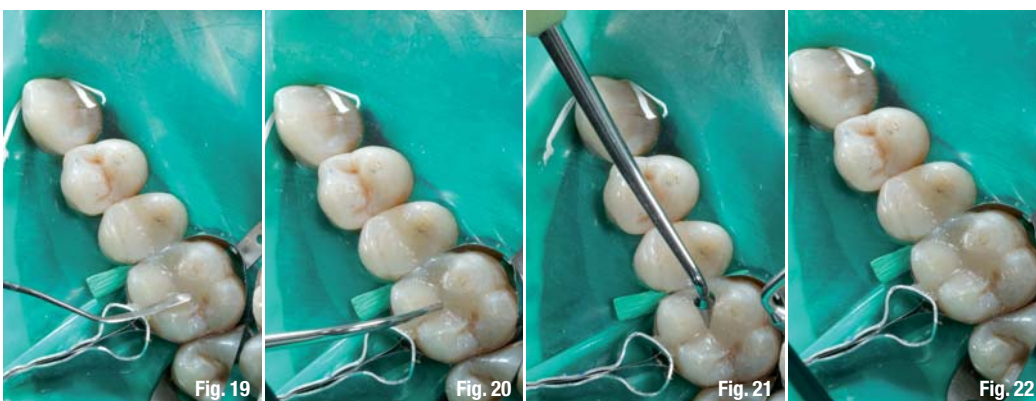Fig. 18 After applying the bonding agent, the SonicFill deep resin is dispensed into the cavity.

Fig. 19 Once the SonicFill tip is removed, the resin returns to a high viscosity state that is ideal for contouring the resin with a variety of hand instruments. A flat-plastic or LM-Arte Applica (LM-Instruments Oy, Parainen) is used for creating cuspal inclines.

Fig. 20 A LM-Arte Fissura (LM-Instruments Oy, Parainen) is used for defining fissures.

Fig. 21 A carver or LM-Arte Fissura (LM-Instruments Oy, Parainen) is used for shaping the marginal ridge.

Fig. 22 Having sculpted and contoured the resin, the restoration is light cured and ready for finishing and polishing.



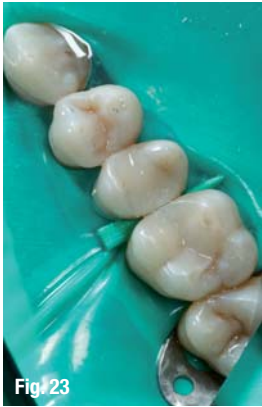

Fig. 23

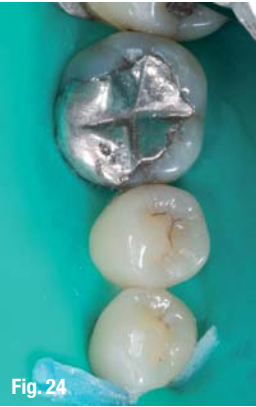

Fig. 24

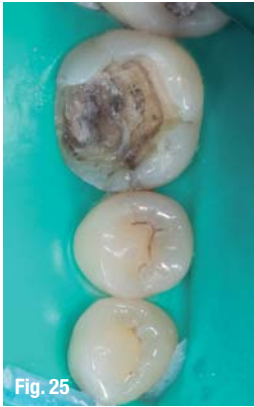

Fig. 25

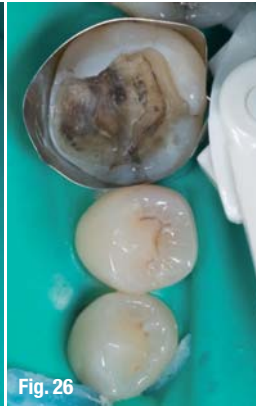

Fig. 26

Fig. 23_ The post-operative white fillings after shaping with OptiDisc aluminium discs and polishing with Opti1Step silicone tips.

Fig. 24_ A large defective amalgam restorations in the right mandibular molar requiring replacement.

Fig. 25_ After removing the amalgam filling, extensive decay is precariously close to the pulp, which requires monitoring before proceeding to a definitive indirect restoration.

Fig. 26_ A steel matrix bank is placed, and dentine bonding agent applied.

Fig. 27_ A coronal build-up using SonicFill resin to review and monitor the endodontic status prior to providing a definitive indirect restoration.

Fig. 28_ Two months later the tooth was symptomless, and the SonicFill core is trimmed back for an indirect ceramic inlay.

Fig. 29_ An impression is taken using a polyvinyl siloxane impression material Take1 (Kerr Corp., USA) and forwarded to the dental laboratory for fabricating a ceramic inlay.

Furthermore, many object to stained fissures, which are perceived as dirty teeth. In reality, patients only desire clean, "white", functioning fillings to alleviate their symptoms. From a clinical standpoint, posterior fillings should possess a hermetic marginal seal to prevent breakdown, and correct anatomical form to restore occlusion.

After all, amalgam fillings, which are blatantly obvious and unaesthetic, have routinely been placed in posterior teeth for over a century without causing a massive revolt from the population. Therefore, offering patients white fillings that are functional and resilient at a fraction of the cost compared to layered restorations is an attractive option, especially in the current economic debacle; and the SonicFill system caters for this niche in the market.

Benefits

For reasons mentioned above, the dental marketplace has recently been flooded with bulk-fill composites for direct restorations in posterior teeth. However, not all the deep resins for white fillings are identical. The defining features of the SonicFill system are fluctuating viscosity for adaptability and sculptability, single increment bulk-fill & bulk-cure up to 5 mm for expediency, high wear resistance for durability, and a reduced translucency for acceptable aesthetics. These key characteristics result in fewer clinical steps, saving time,

reducing cost, improving efficiency, predictability, and longevity of direct posterior composite restorations.

Fluctuating viscosity

Most bulk-fill composites have a fixed, unchangeable viscosity that ranges from medium (e.g. Tetric EvoCeram Bulk Fill, Ivoclar Vivadent, Liechtenstein), to low or flowable (e.g. Surefill SDR Flow, DENTSPLY Caulk, Germany, Venus Bulk Fill, Heraeus, Germany).

A major drawback of universal composites is that their consistency is thick, not conducive for spreading and achieving tight adaptation to cavity walls and floors. Methods such as applying external sonic vibrations and temperature improve fluidity and therefore helps manipulating the composite to "fit" the erratic terrain of cavities (Fig.13). There are numerous external handheld sonic devices for applying vibrations for modelling resins, e.g. Compothixo (Kerr, Switzerland). Whilst these are efficacious for reducing viscosity of a resin, an extra step is added to the already onerous clinical procedure. Lowering viscosity is also possible by thermal means, e.g. heating resin to around 60 °C. However, the time to transfer the composite from the heating apparatus and adapting it to the cavity may cool the material, and hence negate the potential benefit. This is because heat is rapidly dissipated when the resin is placed in a tooth that acts as a heat sink at body temperature of 37 °C, thus reverting the composite viscosity to its unheated state. The SonicFill system overcomes the above two difficulties by lowering the viscosity at the point of delivery by applying internal vibrations to the resin, without the need for heat or external handheld sonic devices.

Another advantage of fluctuation viscosity is that an initial lining, or a capping occlusal layer is obviated. The difference in viscosities of a material, off course, improves its handling characteristics, but it also affects the physical and mechanical properties of the resin. Unalterable, low viscosity bulk-fill resins (e.g. Surefil SDR Flow, Venus Bulk Fill) have lower filler content to confer flowability, which in turn makes the material weaker, requiring a capping occlusal layer with a universal composite to resist occlusal forces. Conversely, with medium viscosity materials (Tetric EvoCeram Bulk Fill), an initial flowable composite layer is necessary as a lining for better adaptation to the cavity walls. Similar to stratification with a universal composite, applying an initial low viscosity layer may introduce incremental voids and therefore compromise the integrity of the restoration.

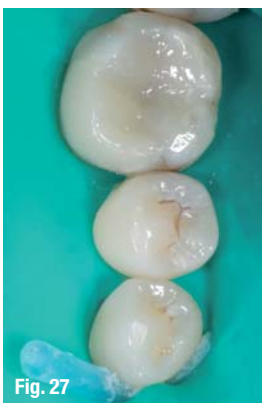

Fig. 27

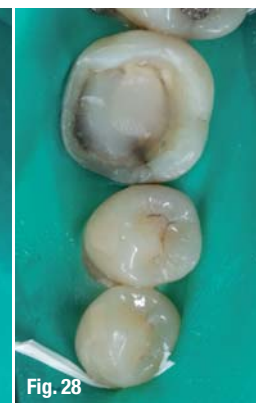

Fig. 28

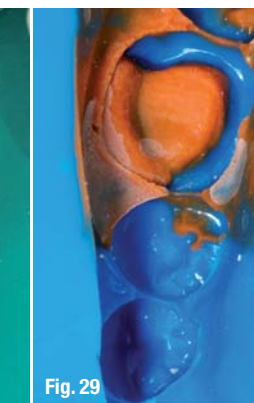
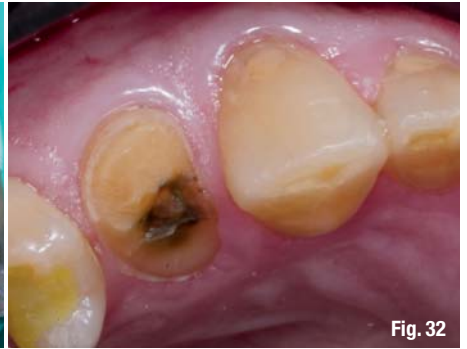
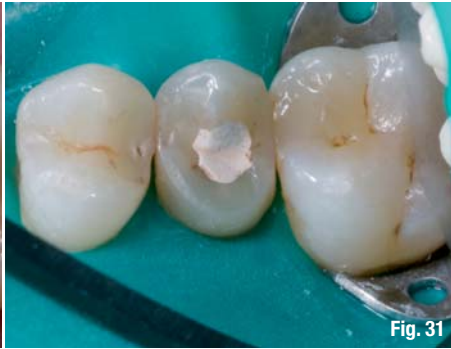
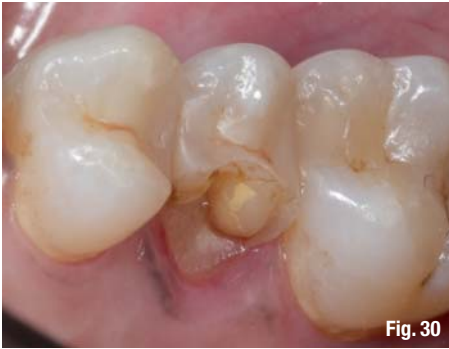Fig. 29



Bulk-cure

Bulk-fill, fixed viscosity composites such as Quixx and Surefil SDR Flow, Tetric EvoCeram Bulk Fill, Venus Bulk Fill, and x-Tra Fil (VOCO) offer a depth of cure of only 4 mm. In contrast, SonicFill is a true bulk-fill resin with a higher depth of cure up to 5 mm, compared to analogous products.

Strength and longevity

The survival of a composite, especially in the posterior regions, is determined by its ability to resist occlusal loads and maintain its anatomical form. Another advantage of the SonicFill resin is that due to its favourable strength, a capping occlusal layer is obviated, and research has confirmed that the high flexural strength (186 MPa) and compressive strength (254 MPa) of the SonicFill composite is comparable, or even great than several conventional universal composites.¹⁵

Reduced translucency

In order to achieve a greater depth of cure, many bulk-fill deep resins are highly translucent to allow the curing light to sufficiently penetrate to the bottom of a single incremental layer. Unfortunately, the increased inherent translucency of materials such as QuiXFil compromises aesthetics by having a greyish appearance due to low value, which is unsightly and readily noticeable. On the other hand, the SonicFill resin is relatively opaque and available in a variety of VITA shades, A1, A2, A3 and B1 and when appropriately polished, yields acceptable aesthetics.

_Clinical applications

The salient feature of the SonicFill system is fluctuating viscosity, and in clinical practice, varying viscosities offer vast versatility. In addition, the expediency for the provision of posterior white fillings is particularly beneficial for patients with limited compliance, such

as the elderly or medically infirm who cannot endure protracted sessions for incremental layering, fissure staining and are satisfied with mediocre aesthetics. The clinical applications of SonicFill include posterior white fillings, coronal or core build-up, and cementing orthodontic brackets and fixed retainers.

Posterior fillings

The obvious use of a bulk-fill deep resin is resorting Class I, II and VI cavities in posterior teeth. These can either be new fillings or those that require replacement due to defective margins, marginal ditching, wear, poor morphology or bulk fractures, which applies to both failing amalgam and composite restorations. In order to retain an amalgam filling, creating undercuts are necessary (Fig. 14). However, after removing the offending amalgam filling, the remaining undercuts require obliterating to seal the cavity floor. This can be accomplished by reduction of the axial walls to remove the unsupported enamel, which is destructive and unnecessarily. An alternative method for obliterating the undercuts is sealing them by exploiting the initial low viscosity of the SonicFill resin, which flows into the undermined areas to preserve existing tooth substrate.

All composite resin fillings are particularly susceptible to hydrolytic degradation over time. This causes ditching, microleakage, loss of contours or even catastrophic fracture, which can result in sensitivity, secondary caries or endodontic complications. Replacement of old defective composite fillings with SonicFill is effortless and straightforward to restore occlusal form, provide

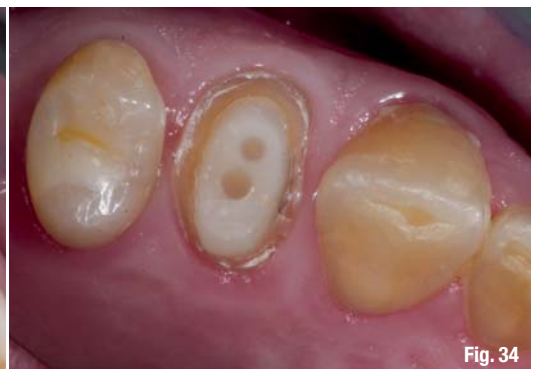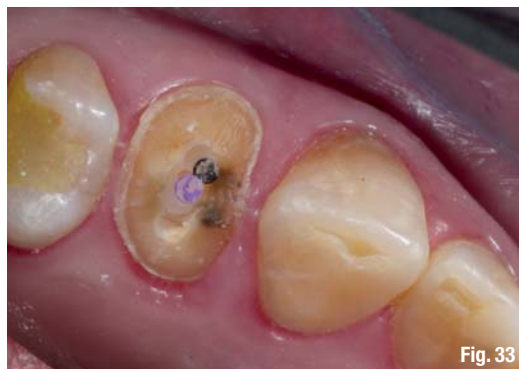Fig. 30_A palatal cusp fracture on a maxillary premolar with endodontic involvement.

Fig. 31_The lost palatal cusp is built-up with SonicFill resin to isolate the tooth from oral fluids before preparing an access cavity for root canal therapy.

Fig. 32_A fractured maxillary first premolar at the level of the gingival margin.

Fig. 33_Following root canal therapy, two fibre posts are placed to retain a core build-up.

Fig. 34_A core build-up using OptiBond XTR with SonicFill resin for supporting a definitive crown.



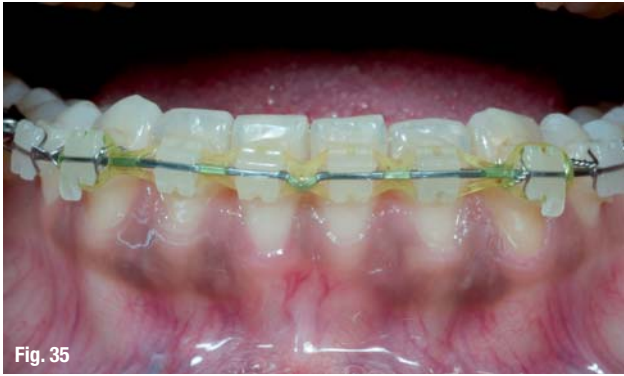

Fig. 35

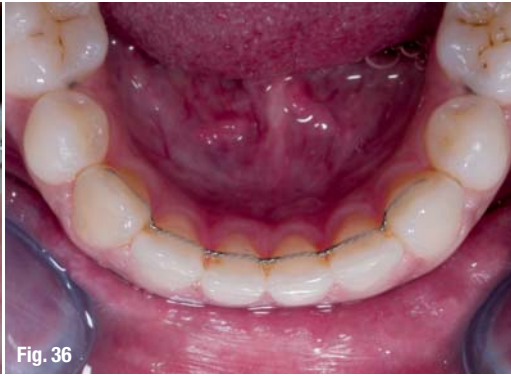

Fig. 36

Fig. 35 Fixed orthodontic brackets can be accurately located and precisely cemented with SonicFill resin.

Fig. 36 Lingual orthodontic wire retained by correctly contoured (non-bulbous) resin, without impingement of the gingival margins for improved oral hygiene and periodontal health.

a hermetic seal to alleviate symptoms, and prevent future complex treatment (see case study in Figs. 15–23).

Coronal or core build-up

A gross loss of dentine and enamel is usually due to caries, tooth wear or trauma. In each of these circumstances, the objectives are building up the lost coronal substrate for restoring structural integrity, a foundation for a subsequent definitive restoration and preventing ingress of bacteria and oral fluids. The SonicFill resin, possessing high flexural strength, compressive strength, hardness, and reduced volumetric contractions together with a profound depth of cure is proficient for achieving these objectives.

For vital teeth that have extensive failing or fractured restorations, a coronal reconstruction serves as a long-term restoration, possibly for reviewing endodontic status and monitoring tooth vitality before the provision of a final restoration (Figs. 24–29). In addition, acute traumas causing cuspal fractures with pulpal exposure, necessitating root canal therapy, a core build-up acts to retain a rubber dam clamps for isolation during endodontic therapy (Figs. 30 & 31). Finally, for root treated teeth, intra-radicular posts can be used for building up a core with SonicFill resin for supporting an eventual crown (Figs. 32–34).

Retaining orthodontic brackets and fixed retainers

Fixed orthodontic therapy involves cementing orthodontic brackets with a resin cement or flowable composite. Because the latter possesses low viscosity, this presents a challenge for accurate location of the brackets. Furthermore, the inherent low viscosity of cements and flowables reduces thixotropic properties and makes removal of excess unset material a tedious chore. Although this is not officially included in the indications recommended by the company, the SonicFill resin resolved these problems since its dispensing tip delivers a small amount of material exactly where needed.

In addition, the initial low viscosity of the resin allows precise adaptation to the enamel surface, and when its viscosity increases, the brackets can be accurately po-

sitioned and excess material removed with ease before light curing. This substantially reduces clinical time, and avoids inadvertent damage to the surrounding enamel by scraping with hand or rotary instruments, or laceration of the gingival tissues during removal of excess

set cement or flowable composite (Fig. 35).

Similarly, fixed orthodontic retainer wires can be accurately positioned on the lingual or palatal surfaces, and the highly viscous SonicFill unset excess resin removed prior to light curing. This avoids the frequently encountered lingual or palatal bulbosity associated with surplus composite around retainer wires (Fig. 36). Finally, since the SonicFill resin is precisely adapted to the retainer wire, inadvertent impingement of the gingival margin is mitigated, thus improving access for oral hygiene procedures, and preventing inflammation of the gingival margins.

_ Conclusion

Bulk-fill, deep resins, provide an expedient and cost effective solution for posterior direct restorations where aesthetics are not a paramount concern. The SonicFill system offers the best of both worlds; adaptability of a flowable and the sculptability of a universal composite with the added benefit of 5 mm depth of cure in a single increment. Deep resins: white fillings, delivered with simplicity and efficiency. In addition, the favourable mechanical properties of the SonicFill resin and its fluctuating viscosity allow other clinical applications such as core build-ups and retaining orthodontic fixed brackets and appliances. Finally, it is not inconceivable that future varieties of bulk-fill deep resins may incorporate self-etching bonding agents that would obviate the need for a prior bonding protocol, and thereby further simplifying and reducing clinical steps.

Editorial note: A complete list of references is available from the publisher.

_contact	cosmetic dentistry
<p>Dr Irfan Ahmad The Ridgeway Dental Surgery 173 The Ridgeway, North Harrow Middlesex, HA2 7DF, UK</p> <p>iahmadbds@aol.com www.irfanahmadtrds.co.uk</p>	

Conservative smile enhancement: Direct composite resin restoration of conoid lateral incisors

Author_Dr Monika Marciniak, Poland

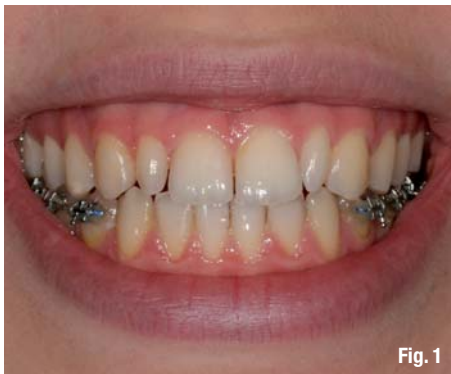

Fig. 1

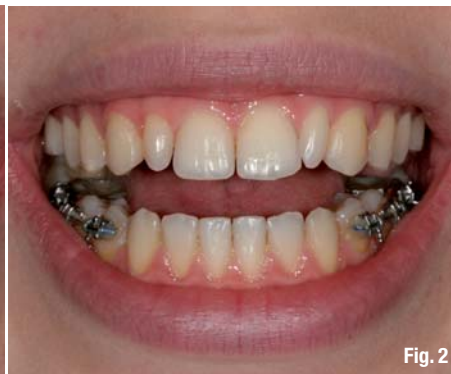

Fig. 2

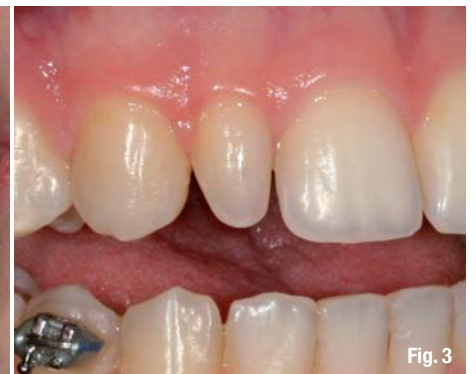

Fig. 3

_Minimally invasive treatments restore form, function and aesthetics with minimal removal of sound tooth structure. Understandably, the restorations age with the patient. Eventually, teeth that have been restored will break down and patients will need to have those restorations replaced.

Fortunately, restorative materials and procedures evolve constantly. If an initial restoration was created using minimally invasive procedures, there should be more tooth structure to work

with when a second restoration is needed. The following case report demonstrates such a conservative approach.

_Case report

After orthodontic treatment, a 19-year-old female patient was dissatisfied with the unpleasant, disproportional appearance of her conoid maxillary lateral incisors. A direct composite technique was selected for smile enhancement at the initial appointment (Figs. 1–4).

Figs. 1–4 Pre-op view following orthodontic bracket removal. Conoid maxillary lateral incisors make the smile unpleasant and disproportional.

Fig. 5 Prepared right conoid lateral incisor with fixed celluloid strip and retraction cord inserted.

Fig. 6 Etching with 37% phosphoric acid for 30 seconds prior to application of a fifth-generation bond.

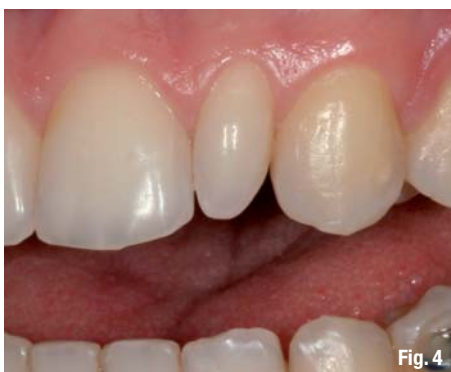

Fig. 4

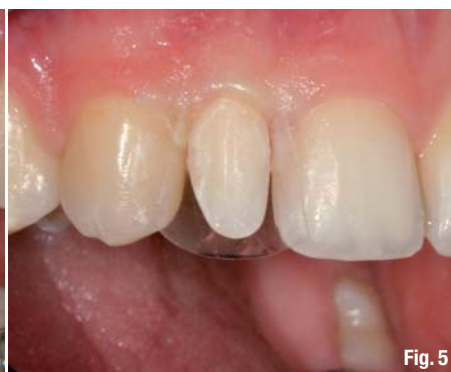

Fig. 5

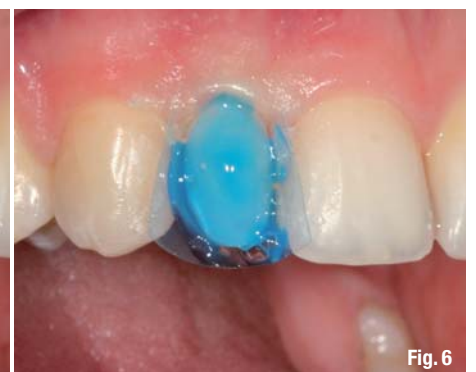

Fig. 6

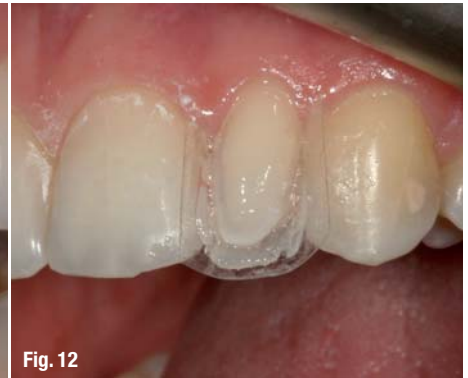
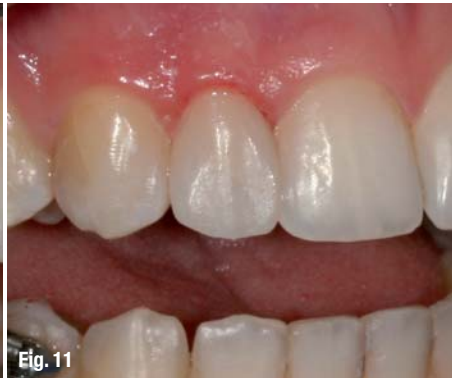
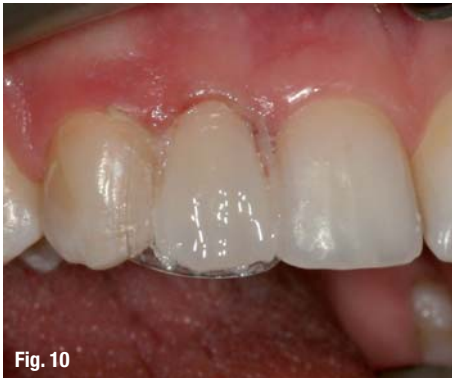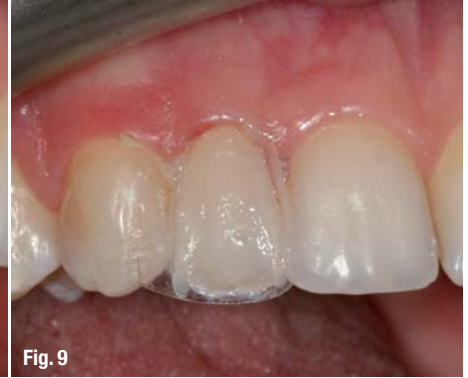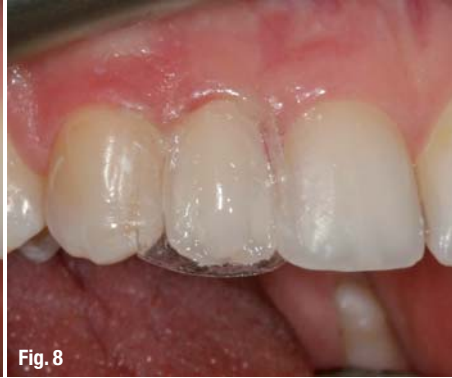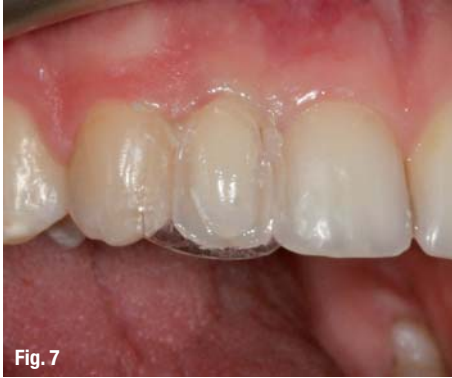Fig. 7_ Completed palatal and two lateral enamel walls. The lingual shelf leaves room for the dentine layering.

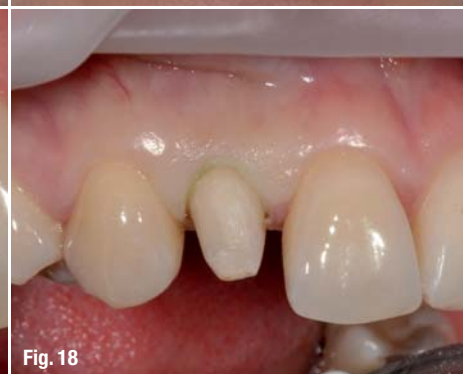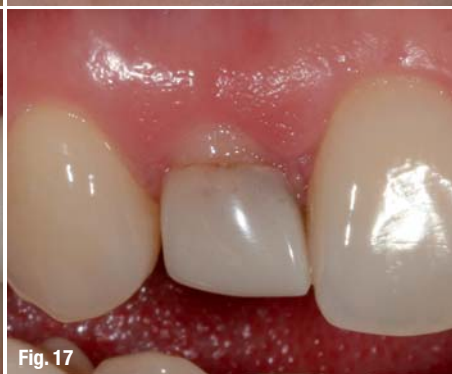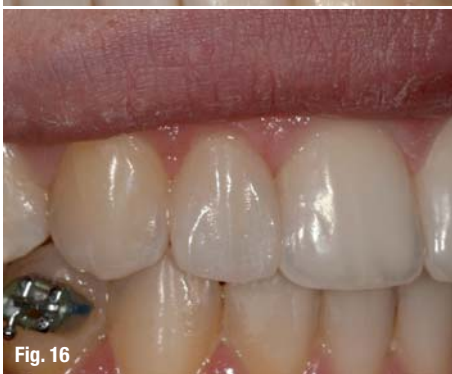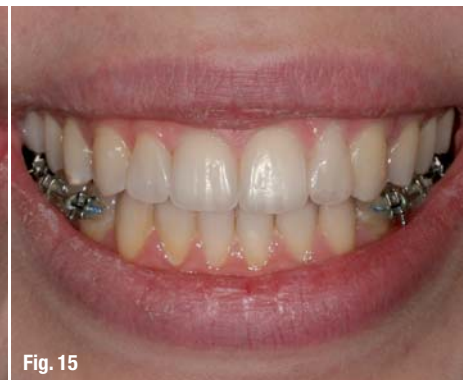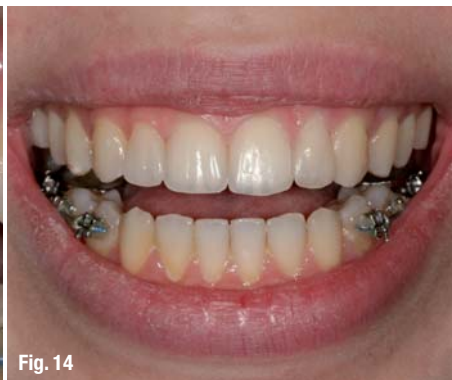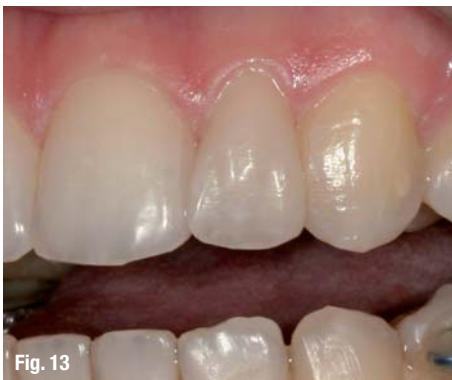Fig. 8_ Distal and mesial lobes created with increments of dentine-shade resin.

Fig. 9_ Darker-shade dentine on the cervical third. White tint

Following enamel-preserving preparation using a tapered, round-ended fine diamond bur and sand-blasting, a celluloid strip was placed subgingivally and fixed using flowable composite. This helped to create the desired emergence profile and contact points. Next, a retraction cord was inserted into the labial part of the gingival sulcus (Fig. 5).

After isolation of the operative field, the preparation was etched with 37 % phosphoric acid for 30 seconds, then thoroughly rinsed and dried. Subsequently, a fifth-generation bonding agent was applied and light cured (Fig. 6).

The next step entailed creating palatal and two lateral enamel walls that were completed using



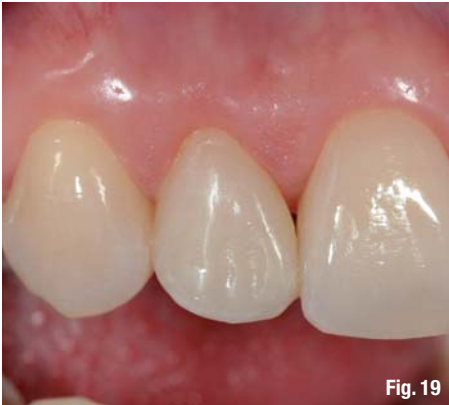

Fig. 19

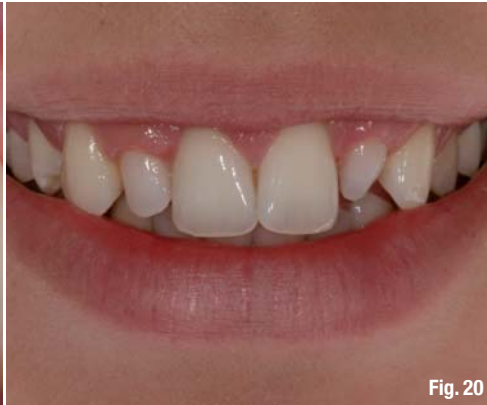

Fig. 20

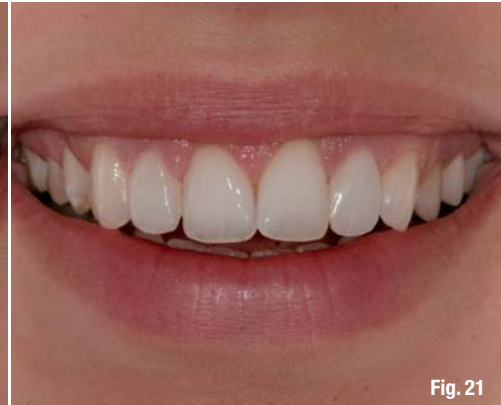

Fig. 21

increments of enamel-shade resin. Creating a lingual shelf in this manner left room for the subsequent dentine layering (Fig. 7).

The appropriate dentine-shade resin was then applied in order to create distal and mesial lobes. These were light cured for ten seconds (Fig. 8). Dentine in a darker shade was placed onto the cervical third. Prior to light curing, the white strip was painted horizontally along the incisal edge of the enamel shelf using a white tint and smooth brush (Fig. 9). Finally, an enamel resin layer was placed, contoured, smoothed with a brush and light cured (Fig. 10).

After completion of composite applications and polymerisation, fine flame-tipped finishing diamond burs and Sof-Lex discs (3M ESPE) were used for gross contouring and creating texture. The final polish was achieved using rubber finishers, a brush, a felt wheel and a paste kit (Fig. 11).

The same procedures were followed during reconstruction of the left lateral incisor (Figs. 12 & 13). Figures 14 to 16 show the situation 30 days post-operatively. The lateral incisors show favourable integration of form and colour as achieved through the direct composite resin restoration procedure. Adequate contours and proportions create a smile with harmonious symmetry and a natural appearance.

Some cases present with conoid lateral incisors displaying a lack of gingival harmony, as were the cases with those patients (Figs. 17 & 20). This usually manifests as the translocation of the gingival contour coronal to the zenith of the canine and the central incisor. Such a clinical situation requires gingival recontouring before direct restoration.

In presented cases, the recontouring procedure was carried out using a Soft Tissue Trimmer

(Edenta). Modifications were limited by the patients biologic width. As observed at four-week follow-up visits, there was a very good gingival response to the polished restorations (Figs. 19 & 21).

_ Conclusion

Conoid lateral incisors are not uncommon. They may be found unilaterally or bilaterally. Their poor appearance can spoil an otherwise attractive smile. The case presented describes a minimally invasive way of addressing this problem using direct composite bonding.

The step-by-step images illustrate how dentists can solve this cosmetic issue without using aggressive techniques and with the advantage of being in full control of shade matching and characterisation.

placed horizontally along the incisal edge of the enamel shelf.

Fig. 10_The final enamel resin layer contoured and smoothed with a brush.

Fig. 11_Completed composite restoration immediately after finishing and polishing.

Figs. 12 & 13_The same steps followed during reconstruction of the left lateral incisor.

Figs. 14–16_Post-op view after 30 days demonstrating favourable integration of the form and colour of the restored teeth.

Figs. 17 & 20_Gingival contour of conoid lateral incisors translocated coronal to the zenith of the canine and central incisor.

Fig. 18_Recontoured gingiva with retraction cord inserted.

Figs. 19 & 21_Very good gingival response to the polished restorations at four-week follow-up visits.

_ about the author

cosmetic
dentistry



Dr Monika Marciniak

graduated from the Medical University of Białystok in Poland in 1992, and runs a private practice with her husband. She has been publishing articles on direct composite restorations

since 2007. She is a member of the European Society of Cosmetic Dentistry.

Dr Monika Marciniak
Ul. Staffa 20 A
18-400 Łomża
Poland

dentystamarciniak@dentonet.pl

Improving success with your cosmetic cases using the TMJ QuickSplint

Author_Dr John F. Weston, USA

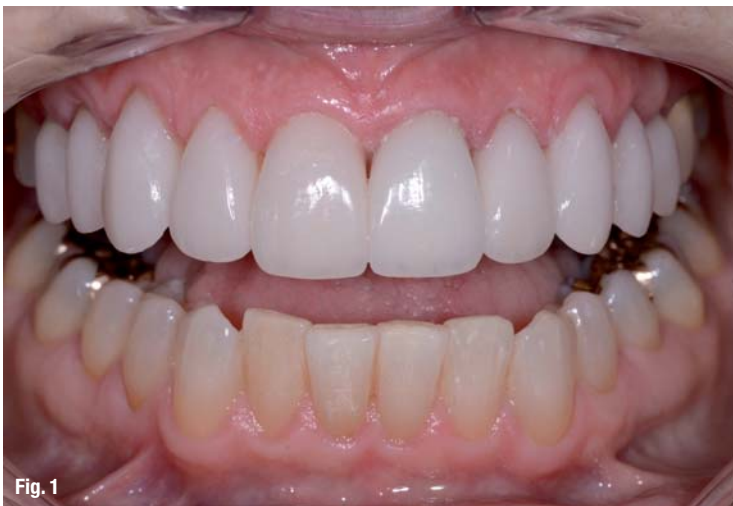

Fig. 1_Immediately post-delivery of ten restorations.

Fig. 2_The TMJ QuickSplint device before use.

Fig. 3_The TMJ QuickSplint with impression and trimming.

_Any clinician who practises aesthetic or reconstructive dentistry knows the challenges of predictably executing multi-unit anterior dental cases. From acquiring proper and repeatable bite records to protecting provisional and final restorations, anterior bite plane devices (depro-

grammers) are a useful tool when integrated into your protocol.

Research has shown that when posterior teeth are prevented from contact, the overall mastication forces are reduced by up to 70 per cent. This protective feedback mechanism is both beneficial to teeth and can relieve uncomfortable muscle pain resulting from overuse and spasms caused by excessive contraction.

For this reason, some providers regard anterior bite plane devices as the perfect first-line treatment for acute temporomandibular joint (TMJ) pain and dysfunction.

Most of the time, patients present for anterior reconstruction due to worn anterior incisal edges and/or abraded posterior dentition. This condition is most commonly associated with nighttime bruxing habits (sleep bruxism). Over time, sleep bruxism can cause aesthetically displeasing results, with loss of anterior guidance, occlusal



Fig. 2

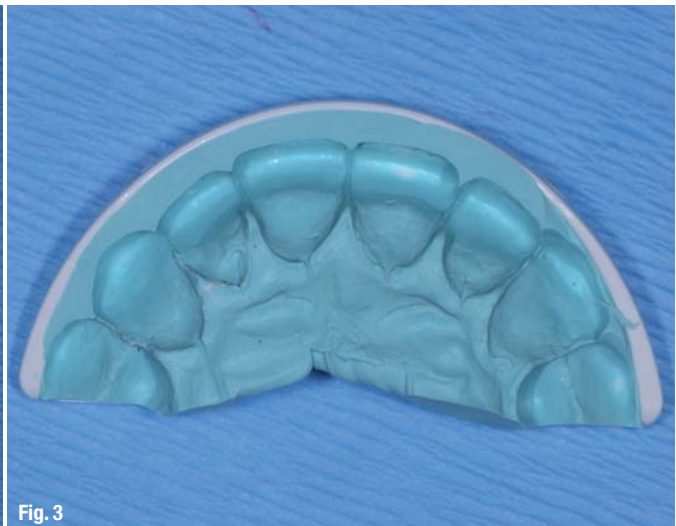


Fig. 3



22–23 May 2013, Multikino, Złote Tarasy, Warsaw
TWO–DAY SPECIAL SESSION
with John Kois – Treatment Planning and Occlusion

XII. SCIENTIFIC CONFERENCE

Polish Academy of Estetic Dentistry & ART ORAL

“back to the roots – looking for the future”

20–22 June 2013, SOPOT, Hotel Sheraton

Gerd Körner (Germany), Marco Degidi (Italy), Bart Beekmans (Netherland), Michel Magne (USA), Christian Coachman (Brasil), Arndt Happe (German), Klaus Mütterthies (Germany), Sam Lee (USA), Urs Brodbeck (Switzerland), Tal Morr (USA), Martijn Moolenaar (Netherland), Fernando Rojas Viscaya (Spain), Enrico Steger (Italy), Ed McLaren (USA), Toni Rotondo (Australia) and Pascal Magne (USA) confirmed their participation.

Great practical workshops, inspiring Pascal Magne session, the June weather and great Gala Party on the seashore.

**We have obtained special terms from Hotel Sheraton for those attending the Conference (www.pase2013.pl).
The official language of the Conference and the Session is English.**

REGISTRATION FEE:

Full ATTENDANCE: Conference (two days) + KOIS Session (two days)
From: 2590 PLN (about 600 euro)

JOHN KOIS Special Session:

From: 1890 PLN (about 440 euro)

PASE Conference:

From: 1490 PLN (about 350 euro)

WORKSHOPS:

HAND ON: 690 PLN (about 160 euro)

SEMINARY: 450 PLN (about 100–110 euro)

Pascal Magne Seminary Session: 550 PLN (about 130 euro)

DISCOUNT FEE for FOREIGN GROUPS:

Organized groups numbering more than 20 people and registering before May 10, 2013 we offer special rates.

ART Oral / PASE Conference 21–22 June, Sopot,
Group registration: 990 PLN (about 230 euro)

John Kois' Special Session – 22–23 May, Warsaw,
Group registration: 1190 PLN (about 280 euro)

After May 10th, only regular price.

Please sent an information on email:
szkolenia@pracowniapz.pl

Please contact us if there is a need to organize interpreter in other language.

REGISTRATION AND INFORMATION: www.pase2013.pl

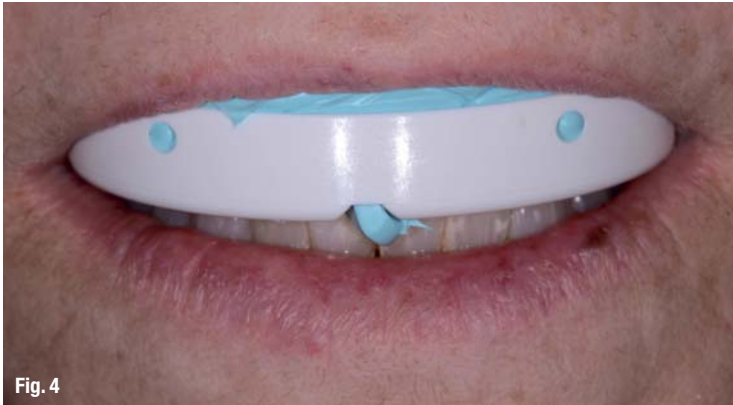

Fig. 4

Fig. 4_Intra-oral realignment, patient wearing the TMJ QuickSplint.

disharmony and overall destabilisation of the bite. Sleep bruxism, like many other oral conditions, is often painless but without intervention leads to more tooth wear and can result in TMJ pain and pathology.

Moreover, studies have shown that more than half the patients who grind their teeth due to para-functional habits are not aware of the behaviour, which can interfere with treatment needs and case acceptance. With time, sleep bruxism can result in firm and enlarged muscles of mastication. Enlarged muscles can increase the challenges of case aesthetics and often make it difficult to obtain a passive centric relation occlusal bite record.

In my practice, anterior deprogrammers have been used successfully for many years. These devices can help relax overused or hyperactive muscles. They allow the joints to seat passively in their anatomically ideal location through a protective pathway once the patient's occlusion is disengaged. Used as a diagnostic tool, as a first line of treatment or as a step in treatment,

Fig. 5_The take-home package for same-day night-time wear.

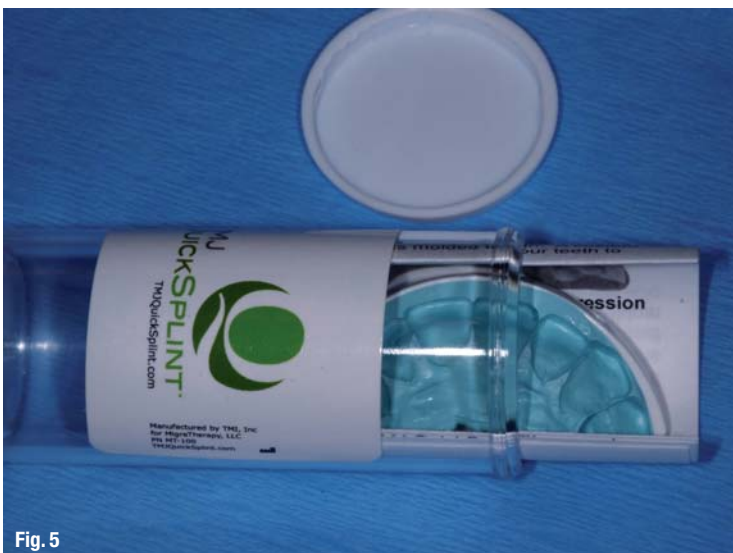

Fig. 5

anterior deprogramming devices are a valuable treatment tool.

The TMJ QuickSplint is a semi-custom anterior bite plane (deprogrammer) that was developed for immediate placement with minimal demand on the provider regarding time, cost or treatment expertise. Although other methods currently exist, I have found the TMJ QuickSplint to be especially useful in the following two areas in aesthetic dental care.

Achieving accurate open-bite centric relation records

A simple technique that can be used to achieve accurate bite records involves using the TMJ QuickSplint as a night-time appliance for one week prior to record making. The design of the TMJ Quick Splint shell and recommended fabrication technique provide a simple, consistent, reliable and fast method to deliver this device chairside. The TMJ QuickSplint used as a deprogrammer will relax the patient's muscles of mastication and help provide a repeatable, accurate centric relation record. The TMJ QuickSplint is designed for maxillary or mandibular arch use, based on maximum contact, occlusal stability, operator preference or patient comfort.

The procedure is simple. After using the device for seven to ten days, the patient returns for records to be made. With the TMJ QuickSplint in place, the patient is asked to bite on the anterior plate (of the TMJ QuickSplint), slide forward and backward a few times and then while the jaw is in the most retruded position to firmly bite down on the TMJ QuickSplint and to hold and squeeze the jaw to stabilise the position.

Bite record material is then injected between the posterior teeth and allowed to set. The TMJ QuickSplint is then removed and the patient is asked to bite into the freshly made posterior sections that provide stability while new material is injected onto the anterior region, providing an accurate full-arch open-bite centric relation record.

Protecting provisionals and final restorations

Another common and significant problem is keeping provisionals in place while waiting for laboratory-fabricated restorations to be completed. It is not practical to fabricate any permanent bite protection for patients in provisionals and most systems on the market involve rigid acrylic liners that could potentially damage and

or loosen the restorations. Provisionals need to be luted to the preparations in such a way that the patient can visualise the end-result and have some functional benefit. Essentially, they need to be cemented well enough to function but easily removed without damaging the preparations.

Since the cause of the patient's original tooth wear is still present and active, this is not always easy and often leads to broken provisionals and upset patients and clinicians. Failure or unexpected events in aesthetic dental care can have negative consequences on patient perception, which is essential to building a strong cosmetic dental practice.

The TMJ QuickSplint is best fabricated using Blu-Mousse (Parkell) or your choice of similar fast-set bite registration material. This allows for rapid, accurate and careful placement over the top of the provisionals. The patient uses the TMJ QuickSplint at night to prevent damage to the provisionals during removal or placement, with the added benefit of reducing overall force and stresses on the interim restorations. After final delivery, we relign the TMJ QuickSplint to fit the final restorations. This can be worn until a defin-

itive device is fabricated and delivered. In my practice, the patient is advised to keep the TMJ QuickSplint as an emergency device in the event of a symptomatic muscle flare-up or if the current appliance is misplaced or damaged.

TMJ QuickSplint™ is a registered trademark of Migratherapy LLC.

_about the author

cosmetic
dentistry



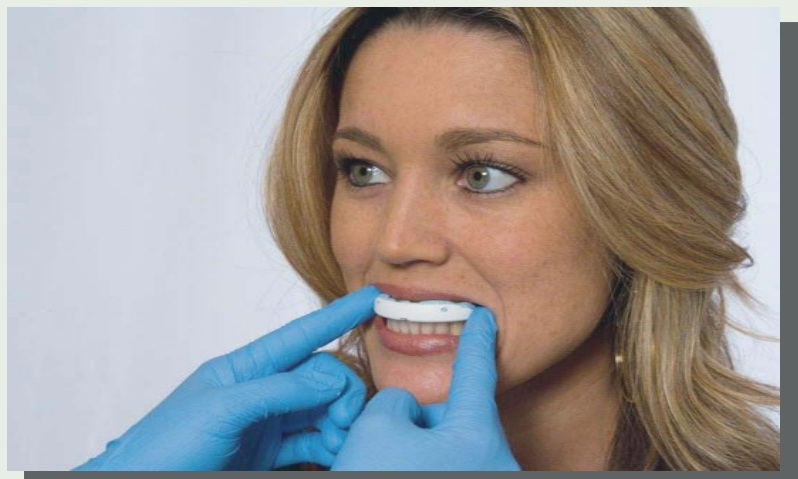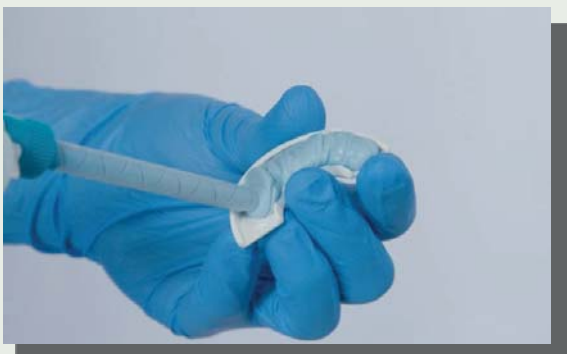Dr John Weston is an accredited fellow of the American Academy of Cosmetic Dentistry and an examiner for the American Board of Cosmetic Dentistry. He lectures nationally and internationally, publishes articles, conducts clinical research, and evaluates new and emerging dental technology and products for major dental companies. He is director and owner of Scripps Center for Dental Care, a multi-specialty practice located at Scripps Memorial Hospital in La Jolla, California. Information on other articles he has published can be found at www.scrippsdentalcare.com.

AD



Easy, chairside fabrication

- Protects provisionals and final restorations
- Addresses acute pain today
- Confirms bruxing to patients



Easy to Use • Quick Results

Inexpensive short-term solution and reimburseable

Coming to Europe soon

www.TMJQuickSplint.com

1-800-760-0526

FDA Approved

Patented

Restoration of orofacial aesthetics: A new multidisciplinary concept

Authors_Drs Hermes Pretel, Jackson Lins & Ismael Drigo Cação, Brazil

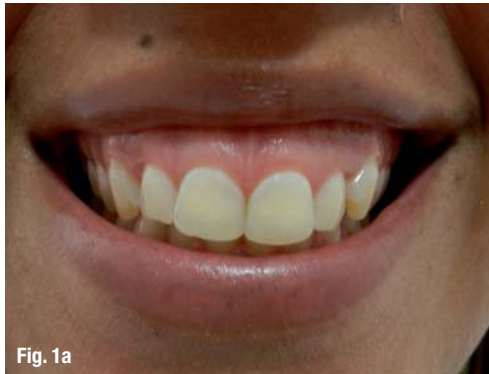

Fig. 1a

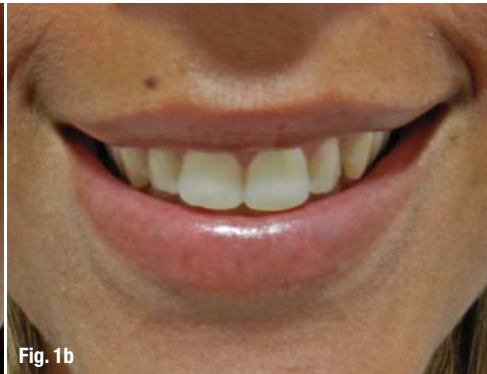

Fig. 1b

Figs. 1a & b _Case 1: gummy smile (a) – treatment with application of botulinum toxin on the levator labii superioris muscle. Result obtained one week after treatment (b).

_Introduction

Since ancient times, humanity seems to focus on the characterization of aesthetics standards which modulate the individuals and make them being noted and appreciated by the society in which they live. For this reason, trends in aesthetics are always established by standards determined by society as a whole. In dentistry, this applies too, hence the pursuit of oral aesthetics using the best technological and human resources in the various specialties. Nowadays, any oral restoration procedure is initiated from a detailed plan, which aims to satisfy the patient's wishes. In general, the intended result of treatment is healthy, well-aligned, whitened teeth with an ideal occlusion and with a harmonious integration of orofacial aesthetics.

Figs. 2a & b _Before (a) and one week after (b) treatment of a gummy smile (Case 2).

The time when the work of a dental surgeon entailed only exodontia, aggravated by the fear caused by the noise coming from the high-rotation system,

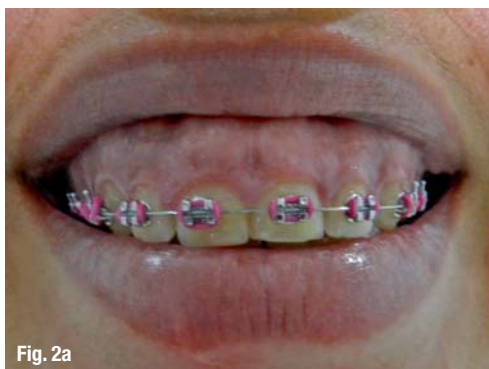

Fig. 2a

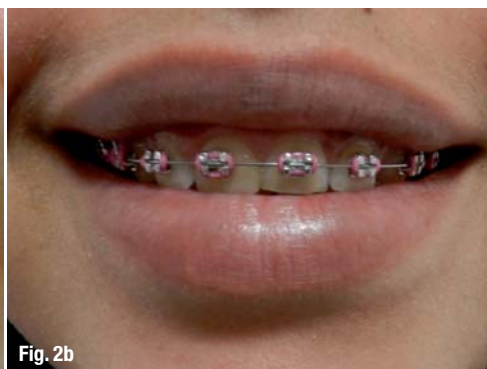

Fig. 2b

belongs to past. Fortunately, whether owing to the evolution of the materials we use or formation improvement, today we are recognised for the excellence of our work, which unites science and art to provide safe and comfortable treatments, combining function and aesthetics in one of the regions of the body that most requires care, the face.

In the new area of orofacial aesthetics, as with other areas of dentistry, diagnosis and planning are indispensable for excellent dentofacial aesthetics. For the feasibility of these treatments, a multidisciplinary approach, employing new techniques such as botulinum toxin, filling materials and phototherapy, is an essential therapeutic approach for treating many dysfunctions. Therefore, in addition to dental procedures, new and efficient procedures, which are aimed at not only oral restoration but also orofacial restoration, are used for treating a gummy smile, dystonia, mandibular spasms, temporomandibular joint dysfunction syndrome, hypertrophy of the masseter, orofacial pain, loss of support of the lips, short interdental papillae or black space between the teeth, and other epidermal dysfunctions.

The aim of this article is to present new concepts in orofacial dentistry in order to promote new supporting therapies in the pursuit of multidisciplinary treatment. Using botulinum toxin for therapeutic purposes, filling dynamic wrinkles resulting from facial expressions with filling materials, and the application of phototherapy to orofacial aesthetics will be considered.

_Discussion

The botulinum toxin commercialised in Brazil by different pharmaceutical companies originates from a Gram-positive bacterium called *Clostridium botulinum*. There have been many reports on the action of

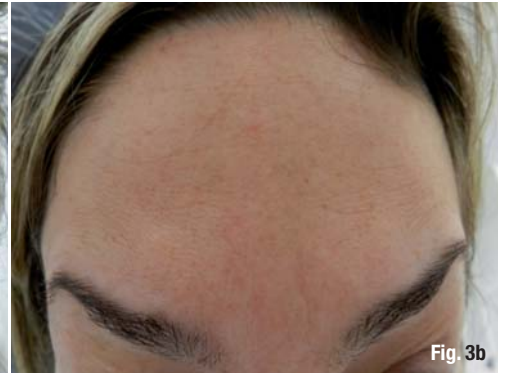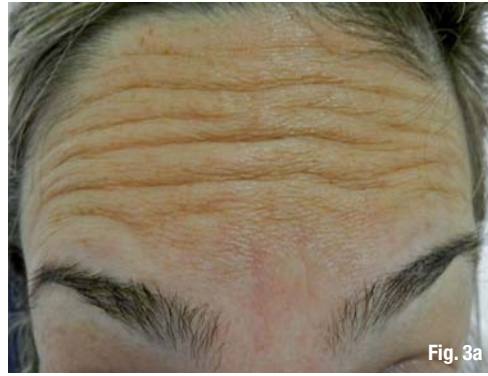botulinum toxin since the middle of 18th century, when Justin Kerner described it as "sausage poison" because of the effects in patients after eating contaminated sausage. Only in 1949, did Arnold Burgen report the discovery of the blocking action of botulinum toxin on neuromuscular transmission. Since then, many studies have been conducted on the therapeutic and cosmetic uses of botulinum toxin. It was first used for therapeutic purposes with the approval of health regulatory agencies in 1989 in ophthalmology to treat strabismus, blepharospasm and hemifacial spasms.

From 2000, botulinum toxin Type A began to be widely used in muscular and cosmetic therapies but without indication of use, that is off label.¹

When it is injected into muscle, botulinum toxin Type A paralyzes muscular movement. The mechanism of action of botulinum is the inhibition of acetylcholine, the neurotransmitter released by the action of nerve impulses at neuromuscular junctions, thus preventing muscular contraction. Consequently, temporomandibular joint dysfunction syndrome, muscular hypertonia (trismus), migraines and gummy smiles, among others, are dysfunctions that may benefit from the use of the toxin (Figs. 1a–3b).²

Botulinum toxin is contra-indicated in lactating and pregnant women, people with autoimmune diseases, neurological diseases and diseases that affect the muscles, people allergic to egg protein and people using medicines derived from aminoglycosides.

Among the major risks of botulinum toxin is overdosing and application to incorrect regions, which may result in asymmetry. In terms of health, it could affect the movements necessary for good function such as blinking, chewing and swallowing.³



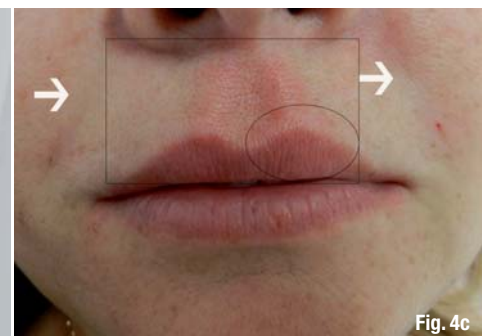
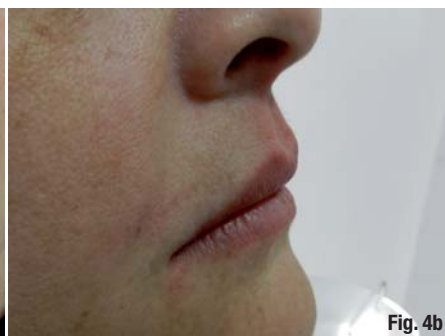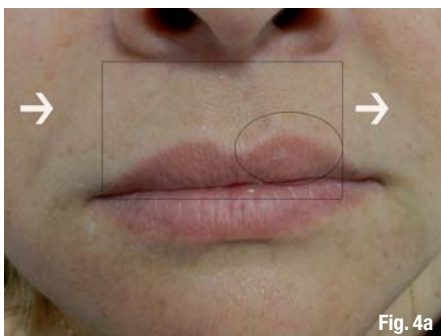Botulinum toxin has a temporary effect, thus its treatments must be seen as palliative and not definitive. For this reason, if treatment is satisfactory, it will have to be repeated to maintain the results. There is not a rule, each person has a singular reaction, but the applications are generally done every six to eight months, always by a skilled professional. The possibility of developing resistance and thus requiring increasingly higher dosages and shorter intervals between treatments is a matter of debate. Some studies show that over time the patient may develop resistance to the toxin, indeed requiring higher dosages in future applications. This dosage excess may cause an insensitivity of the patient to the effects. Other studies however show that over time the need for the toxin is reduced, which implies that lower dosages are required. After some time the relaxed muscle shows a decrease of conditioning spontaneous of activity, as an atrophy, thus explaining the decrease in need of toxin.^{4,5}

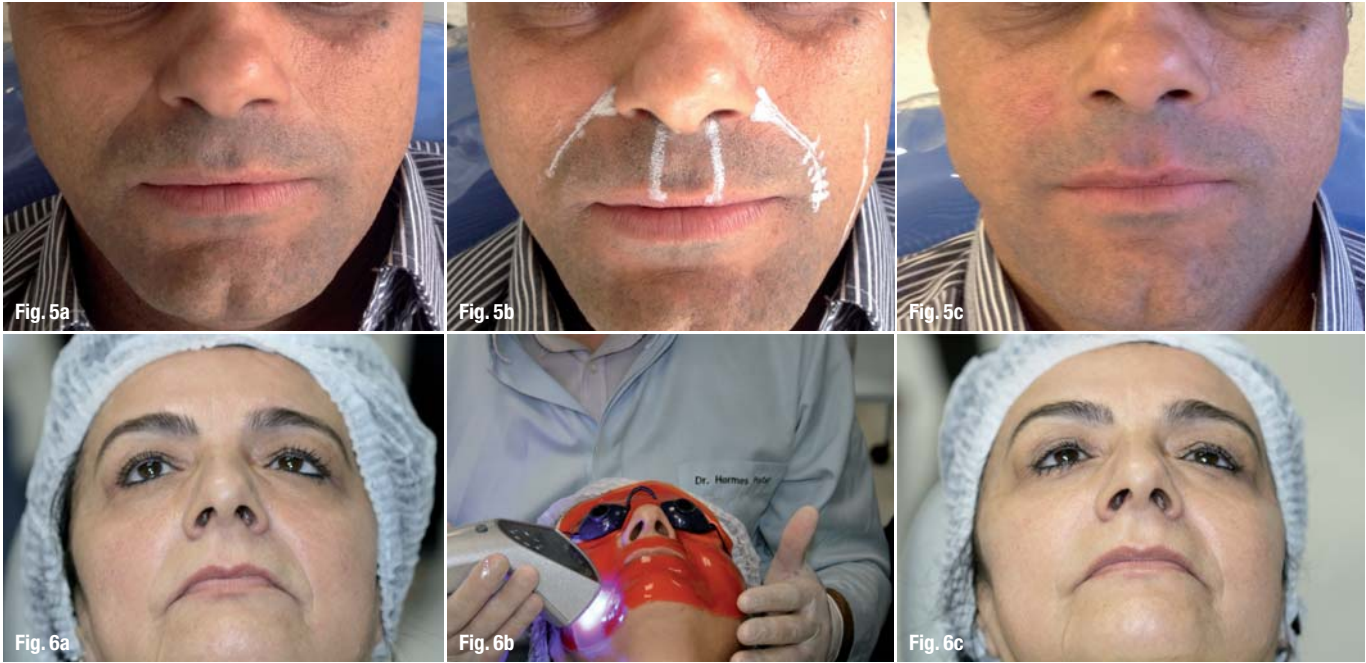Figs. 3a & b Before (a) and one week after treatment (b) of chronic migraine (Case 3) by reduction of tension in the temporal and frontal muscles.

Filling materials are widely used in medicine. In orofacial dentistry, filling materials such as polyamide, hyaluronic acid and hydroxyapatite are employed to fill nasolabial folds, the lips, the barcode lines of the upper lip and short interdental papillae, also known as black triangles or black spaces, and to sculpt the Cupid's bow and model the philtrum, the vertical groove in the center of the upper lip. (Figs. 4a–5c).^{6,7}

Therapeutic procedures to restore function are combined with procedures to restore aesthetics in

Figs. 4a–c Case 4: Filling of nasolabial folds (arrow), Cupid's bow (oval) and philtrum (rectangle) with a filling material made of polyamide (Aqualift).





Figs. 5a-c_ Immediate post-op photograph of Case 5 (a), filling of nasolabial folds, upper lip, Cupid's bow and philtrum using Aqualift (c). During the procedure, the points requiring filling were marked (b).

Figs. 6a-c_ Case 6 treated to effect facial hydration and lighting using facial phototherapy biophotonics, showing photoactivation of collagen mask with blue LED (Elite, DMC) during the procedure (b).

orofacial dentistry. For this reason, it is very important to define the concepts of facial and dental aesthetics for the integration of the procedures.⁸ Phototherapy combines function and aesthetics. Therapeutic lasers have been used for over 50 years in diverse medical specialties. The effects of phototherapy are based on the absorption of the electromagnetic energy and its conversion into chemical energy in the cell. This photo-biostimulation promotes the acceleration of scarring processes, as well as bio-modulation of pain and tissue remodeling.⁹

Associated with dental treatment, orofacial aesthetics provides the link between the mouth and face. Phototherapy for aesthetic purposes thus assumes an important role in multidisciplinary treatment. Different wavelengths are used to treat facial dysfunctions that affect aesthetics. The most studied wavelengths are red, infra-red, amber and blue. The red wavelength acts directly on the mitochondria, increasing cell metabolism and, consequently, tissue repair. The infra-red wavelength acts on the cell membrane, modifying its permeability, controlling the input and output of ions, and modulating the propagation of nerve impulses in controlling pain. The amber wavelength interacts with the ribosomes responsible for amino acid synthesis. Finally, the blue wavelength increases the quantity of intracellular fluid, promoting hydration and cell swelling (Figs. 6a-c).^{10, 11}

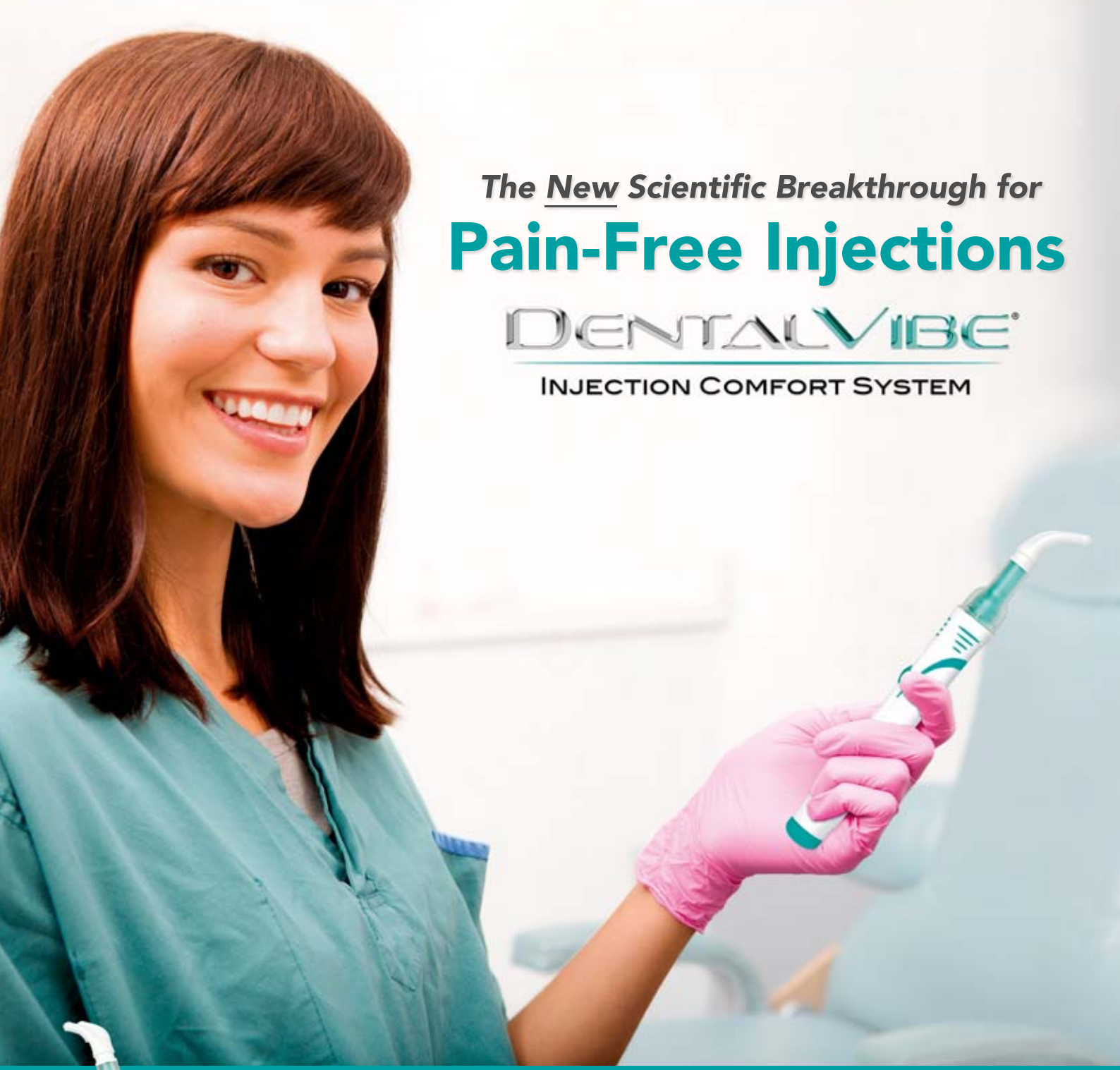In orofacial aesthetics, phototherapy, among other therapies, is used to effect an increase in collagen, tissue swelling and whitening, cell biostimulation and lymphatic drainage.

_ Conclusion

Therefore, orofacial dentistry offers dental surgeons a multidisciplinary approach, combining oral and facial treatment, providing minimally invasive, integrated treatment with effective results in the dental practice. New treatments and therapies are constantly being integrated into modern dentistry. For this reason, continuing education is essential for the development of orofacial aesthetics.

Editorial note: A complete list of references is available from the publisher.

_ about the authors	cosmetic dentistry
<p>Dr Hermes Pretel, DDS., MsC., PhD, is a dental surgeon, a master and doctoral degree in Dentistry Sciences by Faculdade de Odontologia de Araraquara – FOAr – UNESP; Researcher of Grupo Biomateriais, Laser and Led in bone and dental repair of FOAr – UNESP, Scientific Director of Núcleo de Pesquisa e Ensino de Fototerapia nas Ciências da Saúde – Nupen (Research and Teaching Center of Phototherapy in Health Sciences) – Brazil. He can be contacted at hpretel@hotmail.com.</p> <p>Dr Jackson Lins is a dental surgeon and a lawyer. He works at a private dental practice in Iguaba Grande, Brazil.</p> <p>Dr Ismael Drigo Cação is a dental surgeon, a master and a expert in facial phototherapy. Habilitation in laser by Conselho Federal de Odontologia (Dentistry Federal Council) – CFO – Brazil.</p>	



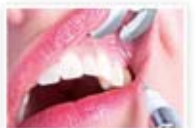The New Scientific Breakthrough for **Pain-Free Injections**

DENTALVIBE® INJECTION COMFORT SYSTEM

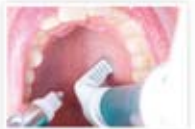

DentalVibe® is a patented, **award-winning** multipurpose clinical instrument designed to alleviate intra-oral injection pain. It is a cordless, rechargeable, hand held device that delivers soothing, pulsed, percussive micro-oscillations to the site where an injection is being administered. Its proprietary VibraPulse Technology gently stimulates the sensory receptors at the injection site, effectively closing the neural pain gate, **blocking the pain of injections.**

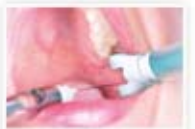**To learn more: Call 877-503-VIBE (8423)
or Visit www.DentalVibe.com**



INFILTRATIONS

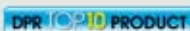

PALATAL



BLOCK

DentalVibe is used in more than 25 countries around the world.
Manufactured in the USA.



Lasers in aesthetic dentistry

Authors_Drs Ilay Maden, Zafer Kazak & Özge Erbil Maden, Turkey

Figs. 1a & b_Crown lengthening before treatment (a).
Crown lengthening 6 months after treatment (b).

Figs. 2a & b_Gingival depigmentation before treatment (a).
Gingival depigmentation 7 days after treatment (b).

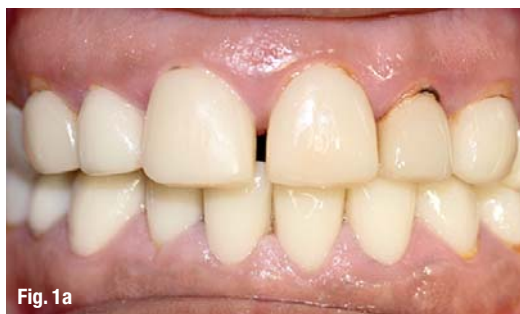

Fig. 1a

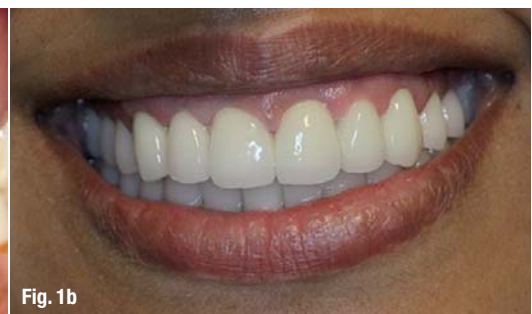

Fig. 1b

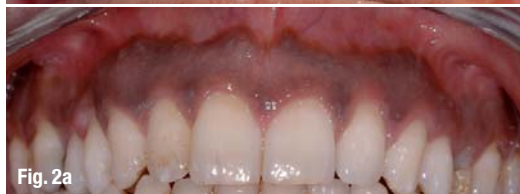

Fig. 2a

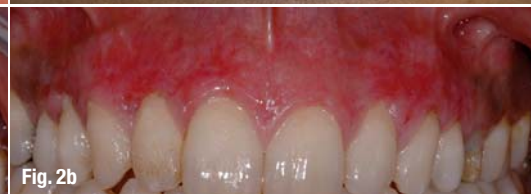

Fig. 2b

The exciting possibilities offered by the world of aesthetic dentistry are being experienced by an increasing number of dentists and patients worldwide as new materials, techniques and tools become widely available.

One such example is the laser, of which there are many for use in dentistry. To appreciate laser dentistry to its fullest, however, it is necessary to gain accurate information from unbiased sources, firstly about laser safety and the physics of laser-tissue interaction, and secondly about the specific uses of lasers in practice.

The most commonly used laser types in dentistry are erbium lasers (with two variants: 2,940 nm Er:YAG and 2,780 nm Er,Cr:YSGG), neodymium lasers (1,064 nm Nd:YAG) and diode lasers (810, 940 or 980 nm). Each type of laser has a different wavelength, and each wavelength has a different interaction with the specific body tissue being treated.

Crown lengthening or gingival levelling (Figs. 1a & b) is a routine procedure for laser-assisted aesthetic interventions. All lasers can be used for

this procedure; however, there are two main advantages of using erbium lasers in crown lengthening. First of all, they can be used without anaesthesia, as they do not cause thermal damage to the tissue. This results in a stable gingival height after the procedure.

Since diode and Nd:YAG lasers work in a more thermal manner, a longer healing time should be expected for the tissue to settle. A prerequisite for success in crown lengthening is, of course, to respect biologic width. If there is less than 3 mm between the desired gingival level and the bone, the bone level must be decreased. While this is possible to do with erbium lasers (even flapless), neither diode nor Nd:YAG lasers are suitable for this, since they are only capable of removing soft tissue.

The same conditions are applicable for uncovering implants with erbium lasers, so it is possible to take the impressions for prosthetic procedures on the same day or within a short period. If it is necessary to remove bone or soft tissue for either indication, erbium lasers with adjustable pulse duration (referred to as VSP technology in

Fotona lasers, for example) are the only option without raising a flap.

Tooth preparation for crowns and bridges with lasers is not yet as efficient as one might like it to be; however, new research and technological improvements are ongoing. A diode or Nd:YAG laser can still be helpful during prosthetic work for troughing before taking impressions or desensitising prepared teeth if required. It is also possible to reduce or eliminate dentine hypersensitivity due to periodontal treatment or gingival recession by either modulating the nerve endings or blocking the dentinal tubules using a laser.

Another aesthetic treatment is gingival depigmentation (Figs. 2a & b), which can also be performed by using long pulses of erbium or diode lasers. It is possible to de-epithelialise the surface, as the pigmentation is usually in the basal layer.

Erbium lasers are safer, since they do not penetrate the tissue. The effect is only superficial, and this is exactly where the pigmentation is.

Diode lasers penetrate more deeply, especially if one is not careful and tries to remove tissue that is lighter in colour. As with other treatments, erbium lasers allow the tissue to heal faster; however, there can be mild bleeding during the operation.

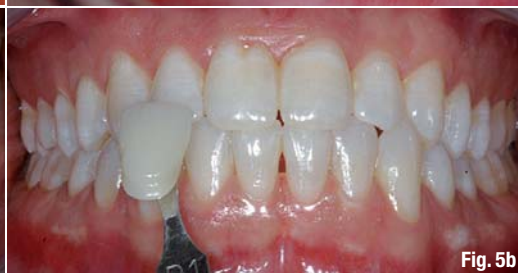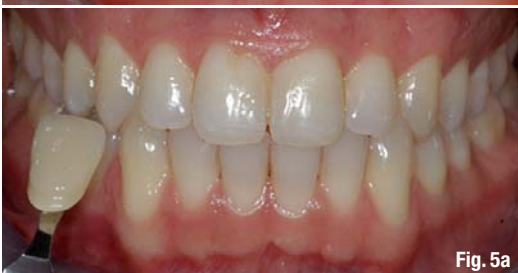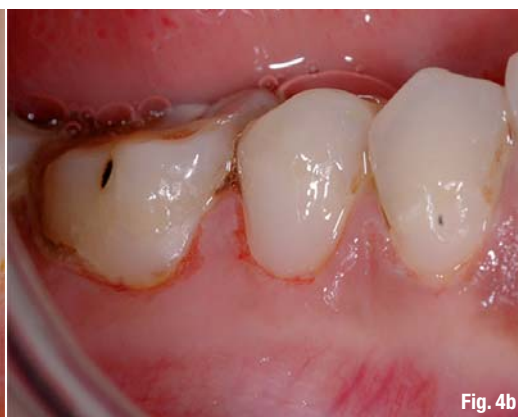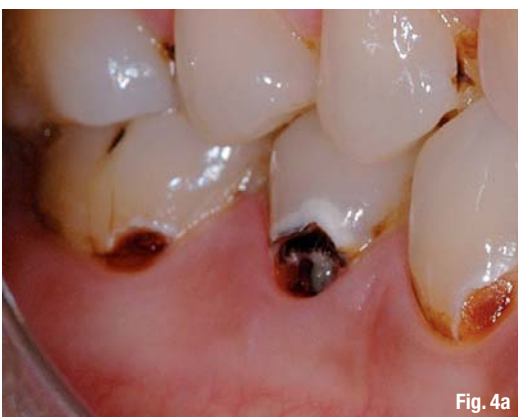Class V caries removal for composite fillings can easily be performed with an erbium laser, quickly, painlessly, and without any thermal side-



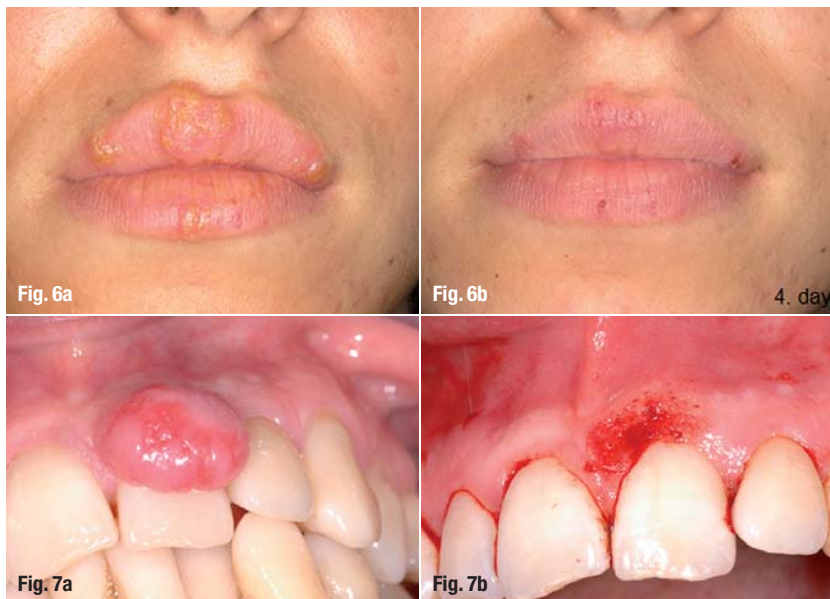
Fig. 3 SEM image of hard dental tissue after ablation with an erbium laser.

effects, especially if the pulse durations are short enough—typically between 50 and 100 microseconds (Fig. 3). The shorter the pulse duration is, the more effective the laser energy will be at removing hard tissue. The margins of the cavity can even be bevelled for better aesthetic appearance and long-term colour stability if the laser is efficient enough to remove small amounts of sound enamel when needed.

Lasers also work selectively to only remove carious tissue, which has more water content than sound hard dental tissue. Surface modification can also be done with the erbium laser after cavity preparation for repairing composite fillings, or even for restoration cementation. One big advantage is that anaesthesia is not generally required when bloodless gingivectomy is used to uncover the borders of the carious lesion with an erbium laser using pulse durations of between 600 and 1,000 microseconds (Figs. 4a & b).



Figs. 4a & b Clinical case before treatment (a). Immediately after gingivectomy and carious lesion removal (b). **Figs. 5a & b** Before (a) and after TouchWhite procedure (b).



Figs. 6a & b Before (a) and four days after treatment of herpetic lesions (b).
Figs. 7a & b Before removal of overgrown tissues (a) and immediately after the removal with an erbium laser (b).

For tooth whitening, lasers can also be used for activation of the bleaching gel (Figs. 5a & b), which decreases the treatment time as well as post-operative sensitivity. As the laser is absorbed by the appropriate gel, the heat is only superficial and the contact time is decreased, leading to less or no sensitivity.

The Er:YAG laser beam is uniquely absorbed in the water molecules that are contained in all gels. The more water content (the more the gel is "soft" and a bit runny), the better the resulting bleaching interaction (known as the TouchWhite procedure, patented by Fotona). The colour is not of importance for this interaction, unlike with Nd:YAG and diode lasers, which are absorbed more efficiently in pigments and therefore require specially coloured gels to be effective.

Nd:YAG and diode lasers have very specific indications, such as the treatment of herpetic lesions (Figs. 6a & b) and non-invasive haemangioma, which can present aesthetic problems too. The advantages of treating a herpetic lesion by laser are that the pain is relieved shortly after lasing, the lesion heals faster and reoccurrence is less frequent in the treated area.

For haemangioma treatment, the lesion is coagulated by the strong absorption of the laser energy in haemoglobin, after which it is either left to be removed by mast cells or ablated.

The bio-modulation effect of these lasers is also advantageous, helping to increase cell turnover and blood circulation (with an anti-inflammatory effect), eliminate pain, improve nerve transmission, promote myo-relaxation, stimulate

the release of growth hormones, and improve many more aspects of healing.

Other procedures like frenectomy or removal of overgrown tissue (lasers can be used to safely and easily remove tissues, like overgrowth, pigmentation, etc. but it is essential to be certain about the nature of the tissue that is being removed) can be carried out for aesthetic reasons in the anterior region (Figs. 7a & b).

Erbium lasers are preferred for soft-tissue surgeries like these because they are fast, require minimum anaesthesia and do not cause a delay in healing. It is important, however, to be able to modify the parameters: if the pulse duration can be increased above 600 microseconds, preferably up to 1,000 microseconds, the quantity of heat delivered will rise—still without damaging the tissue—and cause haemostasis. If this cannot be achieved with the particular Er:YAG laser system, then a second wavelength must also be employed, such as diode or Nd:YAG in order to effect haemostasis.

Diode and Nd:YAG lasers can be used from start to finish for all soft-tissue interventions to yield blood-free surgery; however, this requires more anaesthesia and a longer healing time.

All of these benefits and many more increase the comfort of the patient and give dentists more reasons to enjoy their profession. For achieving a full and successful integration of laser technology into a clinician's treatment offering, and to make effective use of the investment made, as well as to ensure the health and safety of patients, it is necessary to obtain an adequate education in both the biophysical interactions underlying these treatment protocols and the specific properties of each laser device.

All procedures presented in this article were performed using a LightWalker AT dental laser system (Fotona).

_contact	cosmetic dentistry
<p>Dr İlay Maden PhD, MSc, BDS Mühürdar Caddesi 69 34710 Istanbul Turkey</p> <p>ilaymaden@gmail.com</p>	



The New Scientific Breakthrough for **Pain-Free Injections**

DENTALVIBE®

INJECTION COMFORT SYSTEM



DentalVibe® is a patented, **award-winning** multipurpose clinical instrument designed to alleviate intra-oral injection pain. It is a cordless, rechargeable, hand held device that delivers soothing, pulsed, percussive micro-oscillations to the site where an injection is being administered. Its proprietary VibraPulse Technology gently stimulates the sensory receptors at the injection site, effectively closing the neural pain gate, **blocking the pain of injections.**

**To learn more: Call 877-503-VIBE (8423)
or Visit www.DentalVibe.com**



INFILTRATIONS

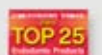

PALATAL



BLOCK

DentalVibe is used in more than 25 countries around the world.
Manufactured in the USA.



Stop hurting your patients!

Deliver the “WOW experience” and watch your practice grow

Author_Dr Steven G. Goldberg, USA

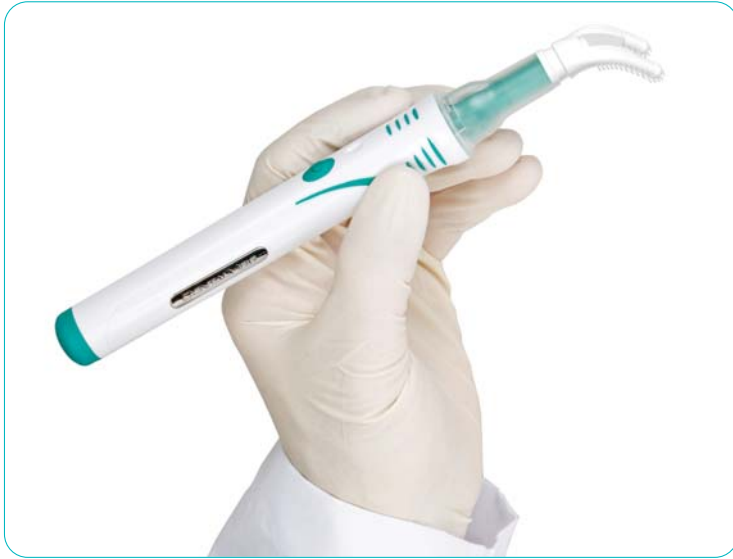

Fig. 1_ DentalVibe Injection Comfort System.

Every dentist is looking to grow his or her practice, and we are all looking to bring in as many new patients as we can. Numerous excellent articles have been written by many highly successful clinicians and marketing gurus on a myriad of ways to grow your practice.

According to Dr Joe Blaes, editor of *Dental Economics*, speaking of the DentalVibe Injection Comfort System in his column “Pearls for your practice” (January 2011), “The best WOW experience that we can give in dental practices is to *not hurt* our patients. You will get more referrals from patients if you have a pain-free practice than any other

marketing tool you can use. [...] DentalVibe's synchronized percussive vibration provides an ideal way to administer anesthetic injections, anywhere in the mouth, without discomfort. DentalVibe is cordless, portable, and easily affordable for every office.”

The fact is that as dentists we are so focused on our technical skills while we are performing our craft that we lose sight of one of the most important issues on the business side of dentistry: the patients' perspective. They are desperately afraid that we are going to hurt them. Many people are so afraid of pain that they avoid going to the dentist altogether. According to worldental.org, studies by the Dental Fears Research Clinic in Seattle, Washington, report that upwards of 40 million Americans avoid going to the dentist because of this fear. This is quite alarming when you consider the negative health effects directly related to poor oral health.

Consider the following scenario. You spend half an hour with a new patient, treating tooth 14 with an MOD composite bonded filling. You carefully excavate the decay, skilfully prepare the tooth with perfect cavosurface margins, etch, prime, place adhesive and composite, and cure for the appropriate period. You spend a great deal of time creating a beautifully artistic representation of occlusal anatomy, and even place secondary grooves in the marginal ridges. Then you polish like you have never polished before. You are proud of the artistic piece that you have created and you have provided a tremendous service to your patient.

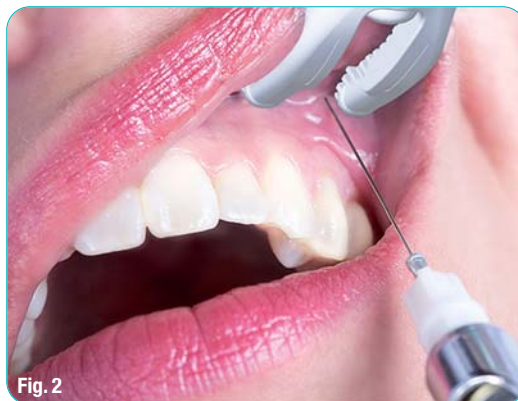
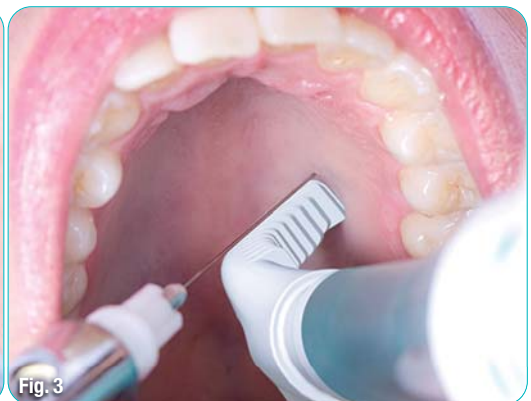
Fig. 2_ Infiltration shot.
Fig. 3_ Palatal shot.



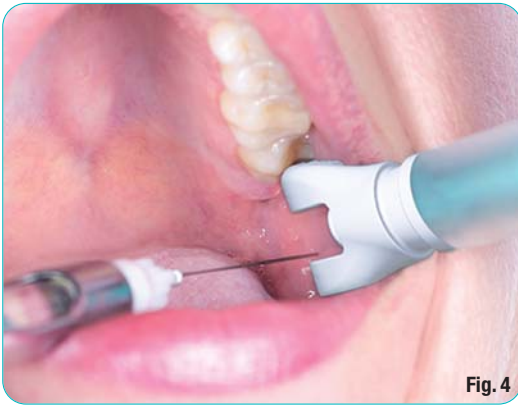

Fig. 4

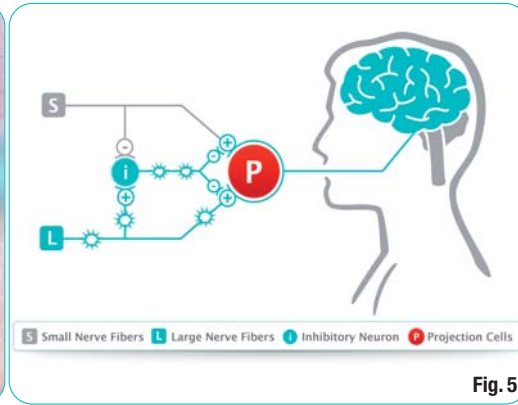


Fig. 5

Fig. 4_ Block shot.

Fig. 5_ Gate control graphic.

However, when your patient goes home and reports back to his or her family and friends about his or her dental experience, is the patient going to tell them how wonderful your secondary grooves are? More likely, what the patient will say is whether you hurt him or her.

What patients remember is the very beginning of the appointment, the dreaded dental injection. If you anesthetise your patients painlessly, you will be considered a painless dentist. After all, dentistry does not hurt. A filling does not hurt, an extraction does not hurt, and even a root canal does not hurt, because once your patient is anesthetised, you are practising painless dentistry. But if you hurt your patients during the injection process, you are no longer considered a painless dentist.

With the use of the DentalVibe Injection Comfort System (Fig. 1), now in its second generation, as an adjunct to the injection process, you no longer have to hurt your patients to help them. This patented, award-winning device utilises revolutionary Vibra-Pulse technology to send soothing, pulsed, percussive vibrations deep into the oral mucosa during the delivery of an injection. This stimulation is perceived by the submucosal sensory receptors, sending a message to the brain, effectively closing the neural pain "gate", allowing for the comfortable administration of intra-oral injections. Adults and children have reported painless injections and dentists report less stress during the injection process. The device is cordless, portable, non-threatening, easily affordable, has been receiving rave reviews all around the world from key opinion leaders in dentistry, and has been featured on all of the TV news networks.

DentalVibe is based on the Gate Control Theory of Pain, proposed by Drs Ronald Melzack and Patrick Wall of McGill University, and published in the Science journal in 1965. According to this theory, there is a gating mechanism located in the dorsal horn of the spinal cord. This gating mechanism either permits or prevents the sensation of pain from travelling up the

spinothalamic tract to the brain. When the DentalVibe is used simultaneously during the administration of an injection, the pulsed vibratory impulses generated by the device travel along thick myelinated A beta nerve fibres 37.5 times faster to the brain than the sensation of pain from the injection, which travels along thin unmyelinated C nerve fibres. As the vibration sensation reaches the brain first, a signal is sent to a synapse in the spinal cord, activating inhibitory interneurons that prevent the action of projection neurons, thereby shutting a gate, blocking the pain from the injection.

This is one dental product that holds universal appeal to consumers. Nobody wants to feel pain and these days patients are no longer willing to accept it, as they may have in years gone by. Therefore, Bing Innovations, the developer of DentalVibe, has launched a multimillion-dollar patient-awareness campaign, including TV commercials, print advertisements, cinema advertising, Internet banner advertisements and a web-based dentist locator. This tremendous effort is effectively educating tens of millions of consumers on the wonderful benefits of DentalVibe for virtually painless injections and driving patients to those dentists who use it.

Give your patients the "WOW experience" with DentalVibe, so that both you and your patients can enjoy our wonderful profession a little bit more. _

_contact

cosmetic
dentistry



Dr Steven G. Goldberg,
DDS, fellow of the
International Academy
for Dental-Facial Esthetics,
Inventor of DentalVibe,
Founder and spokesperson
of Bing Innovations

drstevengoldberg@dentalvibe.com
www.dentalvibe.com

What constitutes new technology? Water flossing revisited

Author _ Deborah M. Lyle, USA



Fig. 1



Fig. 2

Fig. 1 _ Original Waterpik oral irrigator introduced to the dental profession in 1962.

Fig. 2 _ Waterpik Ultra Water Flosser with ten pressure settings and six tip designs.

_Dental school graduates from the 1960s, 1970s and 1980s have probably heard of the Waterpik Water Flosser, but ask them to tell you what it does or whether it is effective, and they generally either do not know or else believe that it is not very effective at removing plaque. Graduates after 2000 may not even know what this technology is or what it does.

The hydrodynamic therapy action of an oral irrigator is not a new concept to the dental profession. The innovations lie in our improved understanding of the pathogenesis of oral disease, the role of plaque as a biofilm, and applying clinical evidence to make clinical decisions. Recent and ongoing research and applications have shown how the oral irrigator is a self-care product that warrants attention in the 21st century.

The original oral irrigator (known as a dental water jet, and more recently a water flosser) was developed by Dr Gerald Moyer, a Fort Collins, Colorado, dentist, and Dr John Mattingly, a hydraulic engineer at Colorado State University (Figs. 1 & 2). Moyer was looking for a product that could clean areas of the oral cavity that are not readily assessable by traditional methods such as toothbrushing and dental flossing. Together they designed a device that provided a controllable pulsating water stream for the targeted delivery of a solution and the self-cleansing of inaccessible areas by the patient. The current terminology, "water flosser", will be used throughout this article.

The water flosser delivers a pulsating stream of water or other solution that results in successive com-

pression and decompression phases of the gingival tissue (Fig. 3).¹ The solution strikes the tooth at the gingival margin, the *impact zone*, and is deflected subgingivally and interdentally, the *flushing zone* (Fig. 4). It was anecdotally believed that the water flosser was simply flushing out debris without removing plaque or having a positive impact on oral health. However, as early as 1969, studies were reporting significant plaque

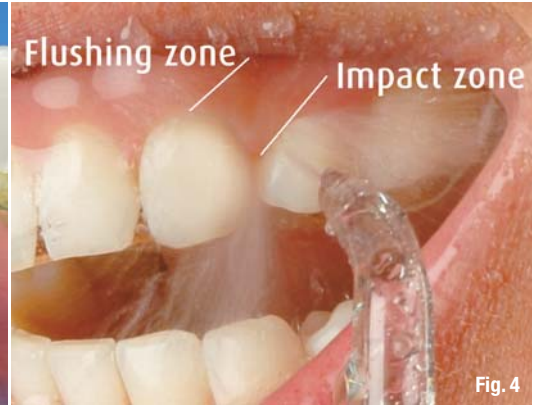
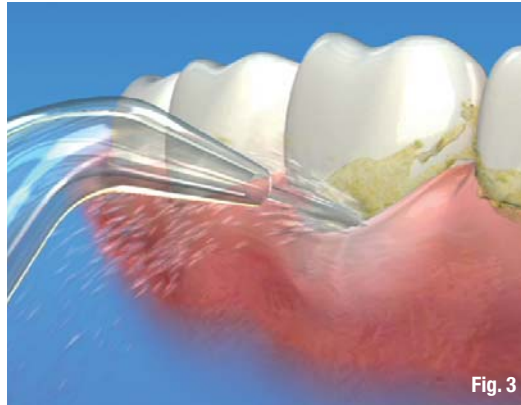
and calculus reduction in groups using the water flosser.^{2,3} More recently, significant plaque reduction has been demonstrated in studies with subjects with mild to moderate gingivitis,⁴ periodontitis,⁵ orthodontic appliances⁶ and diabetes.⁷

The above studies used the traditional validated plaque indices, which provide a 1-D perspective; the presence of plaque is determined by disclosing solution. In 2009, Dr Bill Costerton and his team took this a step further to evaluate the removal of biofilm from the tooth surfaces using a water flosser. This *ex vivo* study utilised periodontally involved teeth that were extracted and inoculated with saliva to grow new biofilm over existing deposits. The teeth were treated with a water flosser for three seconds at medium pressure and then prepared and viewed under a scanning electron microscope (SEM). The removal of biofilm was evident as seen in Figures 5a & b, with almost 100 per cent removal from treated areas.⁸

_Self-care technology

Brushing is considered the first line of defence for maintaining good oral hygiene. Some power brushes are quite sophisticated; they help the user know when to change quadrants, when the two-minute brushing time is reached, and how the user is doing. They offer power selections that include cleaning action, massaging action or a gentle stroke for sensitive areas. There are different bristle configurations, brush-head sizes and designs, and angles and contours for cleaning the line angles, pits, fissures and posterior regions.

Careful analysis determines the individual recommendation of the right toothbrush for each patient. Toothbrushing targets only supragingival plaque, however. Numerous studies have indicated that significant plaque can remain after brushing.⁹ And all toothbrushing, whether power or manual, fails to clean interdentally, an area that the patient must address separately. It can be argued that interdental cleaning should be the first step, since that is the area where the risk of periodontal disease and infection is higher.



While dental floss is not a state-of-the-art technology, it is still considered the first choice for interdental cleaning among dental professionals. A major problem is that patients do not like to floss,^{10, 11} tend to avoid the practice, and often demonstrate a technique that is less than adequate.¹² Dentists and dental hygienists need to find alternative methods to accomplish interdental cleaning.

There are many products available that are designed or marketed to clean between the teeth and to motivate individuals to perform this task; how effective are they, and can they be used easily by most individuals? Interdental brushes have been shown to reduce plaque and gingivitis,¹³ but require a large enough embrasure space for access. Even the smallest designs may not fit into all interdental spaces or effectively clean the proximal surface concavities of the teeth. Floss holders are designed to make it easier to use floss, but do not eliminate all the dexterity challenges that patients face. Wooden sticks,¹⁴ rubber tips and toothpicks are not interdental cleaners.

The recent advent of "water flosser" as a descriptor is based on clinical findings from three studies (Table 1). The first study in this group was published in 2005, and demonstrated that the water flosser with a classic jet tip and either a power toothbrush or a manual toothbrush were significantly better at reducing bleeding and gingivitis when compared with a manual toothbrush and string floss.¹⁵ This was followed by a 2008 study that compared the efficacy of a water flosser with an orthodontic tip and a manual toothbrush to a manual toothbrush and string floss in 11- to 17-year-olds with fixed orthodontics.¹⁶ The water

flosser group had significantly reduced plaque and bleeding over four weeks compared with the string floss group. The most recent study published in 2011 found that the water flosser with either the classic jet tip or a tip with individual bristle tufts was up to twice as effective as dental floss in as little as two weeks. The differences between the tips and floss were even more dramatic at four weeks.¹⁷

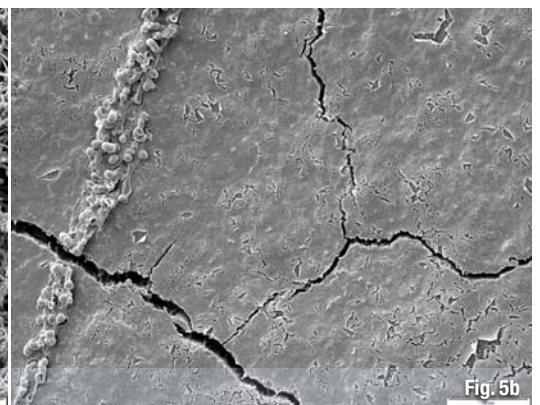

How does a water flosser stand out from other self-care products?

The documented research on water flossers is extensive, spanning over 50 years. These studies were designed to address new developments in dentistry. The link between periodontal disease and systemic disease has been studied extensively and reported in the literature; some associations are very strong while others are less conclusive. It is well known that people living with diabetes have an increased risk of periodontal disease that starts earlier and leads to more severe complications in both children and adults. Controlling oral inflammation is important and may be more difficult to accomplish than in non-diabetic individuals. A water flosser was compared with traditional oral hygiene in a cohort of Type 1 or Type 2 diabetic subjects over three months. The group that used the water flosser has significantly better improvements in gingivitis, plaque, and bleeding on probing compared with the group that continued with traditional oral hygiene methods.⁷

Fig. 3 Decompression phase where the tissue is extended from the tooth, allowing access to the subgingival area.

Fig. 4 The impact zone is where the solution hits the tooth and the flushing zone encompasses the subgingival and interdental areas around the tooth.

Figs. 5a & b Before and after using a water flosser on medium pressure for three seconds: biofilm on tooth under SEM (a); 99.9% removal of biofilm from tooth surface under SEM (b).



Reference	Title	Design	No. of subjects	Products used	Groups
Barnes et al.	Comparison of irrigation to floss as an adjunct to toothbrushing: Effect on bleeding, gingivitis, and supragingival plaque	RCT Parallel Examiner Blind 4 weeks	105 (10 subjects across the groups had to be dismissed owing to illness, antibiotic use or corticosteroid use)	Waterpik Water Flosser (WP-60) with traditional jet tip and water (WF); Oral-B 35 manual toothbrush (Procter and Gamble, MT); Waterpik Sensonic Toothbrush (SR-700, PT); Reach floss, unflavoured, waxed (Johnson and Johnson, FL); Crest Cavity Control toothpaste (Procter and Gamble, MT)	MT + FL MT + WF PT + WF
Sharma et al.	Effect of a dental water jet with orthodontic tip on plaque and bleeding in adolescent patients with fixed orthodontic appliances	RCT Parallel Examiner Blind 4 weeks	106 (1 subject withdrew because he did not want to floss)	Waterpik Ultra Water Flosser (WP-100) with orthodontic tip and water; Oral-B 35 manual toothbrush; Reach floss, unflavoured, waxed; GUM Eez-Thru floss threaders (Sunstar Americas); Crest Cavity Control toothpaste	MT + FL MT + WF MT only
Rosema et al.	The effect of different interdental cleaning devices on gingival bleeding	RCT Parallel Examiner Blind 4 weeks	108 (2 subjects withdrew because of scheduling conflicts, 1 moved and 1 withdrew for personal reasons)	Waterpik Ultra Water Flosser (WP-100) with standard jet tip (S) or prototype tip (P) with 3 bristle tufts; Reach floss, unflavoured, waxed; Oral-B Indicator 35 manual toothbrush; Everclean fluoride toothpaste (HEMA, Netherlands)	MT + WF (S) MT + WF (P) MT + FL

Table 1

Table 1 Overview of studies comparing water flosser to string floss. (Reprinted with permission from the *Compendium of Continuing Education in Dentistry*.)

Studies between 1990 and 2000 continued to show the benefits of a water flosser in reducing bleeding, gingivitis and plaque.¹⁸⁻²¹ Some of the researchers proposed that the significant results from using a water flosser were associated with a change in the host response. With a new focus on host inflammatory modulation, a randomised controlled study was conducted comparing routine oral hygiene with routine oral hygiene plus a water flosser.⁵ The investigators used traditional bleeding, gingivitis and plaque indices, but also measured pro-inflammatory mediator interleukin-1B (IL-1B) and prostaglandin E₂, anti-inflammatory mediator interleukin-10, and interferon-gamma, a cytokine key in killing bacteria. The study results demonstrated that the water flosser group had a significant reduction in plaque, bleeding and gingivitis indices plus probing depth compared with the control group. The cytokine profile was changed in the water flosser group, showing a decrease in the pro-inflammatory mediators and an increase in the anti-inflammatory mediators. Since the measurements were taken from gingival crevicular fluid, the researchers prevented a dilution effect by waiting eight hours after the subjects had used the water flosser. Key findings include:

Both groups had reduced plaque biofilm compared with baseline, but only the water flosser group had decreased inflammatory mediator IL-1B.

The reduction of bleeding on probing correlated with the reduction of IL-1B not the reduction of plaque.

The selective reduction of pro-inflammatory mediators demonstrates a modulation effect

In the diabetes study mentioned above, the investigators measured the serum cytokine profile of the subjects. Over the three months of the study, the

test group that used the water flosser showed significant reductions in IL-1B and prostaglandin E₂.⁷


Conclusion

The water flosser has an extensive body of evidence that demonstrates its safety and efficacy with multiple patients and different oral care needs, for example gingivitis, orthodontics, implants, crowns and bridges, individuals in periodontal maintenance programmes, and particularly those with good oral health. Studies in the past decade have addressed new areas such as host response, impact on systemic health, and the effect on biofilm at the microscopic level. The water flosser has the ability to provide individuals with an easy and effective way to maintain good oral health by accessing the areas that are not readily reachable and cleansable by traditional methods. Not all oral irrigators, dental water jets or water flossers have the same combination of pulsations and pressure. The overwhelming majority of studies have been done using the Waterpik Water Flosser. Dental professionals need to evaluate the evidence for each specific product, as studies are not transferable between technologies and manufacturers.

Editorial note: A complete list of references is available from the publisher. Photographs courtesy of Water Pik, Inc.

_contact

cosmetic
dentistry

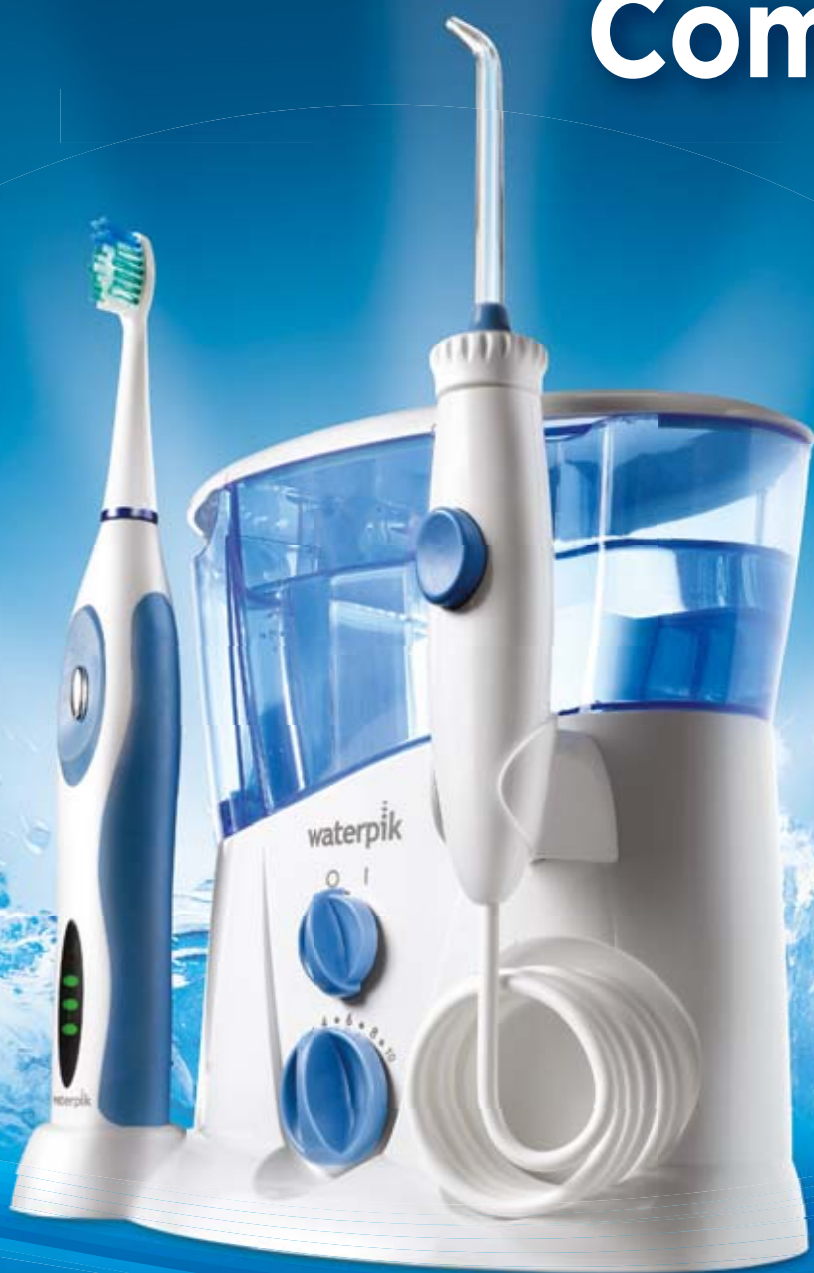

Deborah M. Lyle
RDH, MS
New Jersey
USA

dlyle@waterpik.com

NEW!

Nothing Beats Complete Care



waterpik®
COMPLETE CARE

Best

Up To

159%

More Effective
vs. Manual
Brushing¹

Up To

70%

More Effective
vs. A Leading
Sonic Toothbrush¹

1. Clinical research
study, for details go
to Waterpik.com

**SONIC
BRUSH
Better**

**MANUAL
BRUSH**

Good

©2013 Water Pik, Inc.

The superior combination of Water Flossing and Sonic Brushing.

Waterpik® has taken Water Flosser technology to the next level by combining a more effective way to floss with a more effective Sonic Toothbrush. Now your patients can get all their brushing and flossing needs in one convenient and clinically-proven product. Compared to even the world's leading sonic toothbrush brand, Waterpik® Complete Care is significantly more effective for plaque removal, bleeding reduction, and improved gingival health. Give your patients a healthy smile for life - recommend Waterpik® Complete Care.

See our 8-minute presentation and
receive a free Water Flosser!

2013 International Dental Show
Waterpik® Booth
Hall 11.3, Stand J040 K049



A product for
every patient need.

waterpik®

COMPLETE CARE

**waterflosser +
sonic toothbrush**

Kuraray Noritake Dental proudly presents world-first innovations in dentistry at IDS 2013

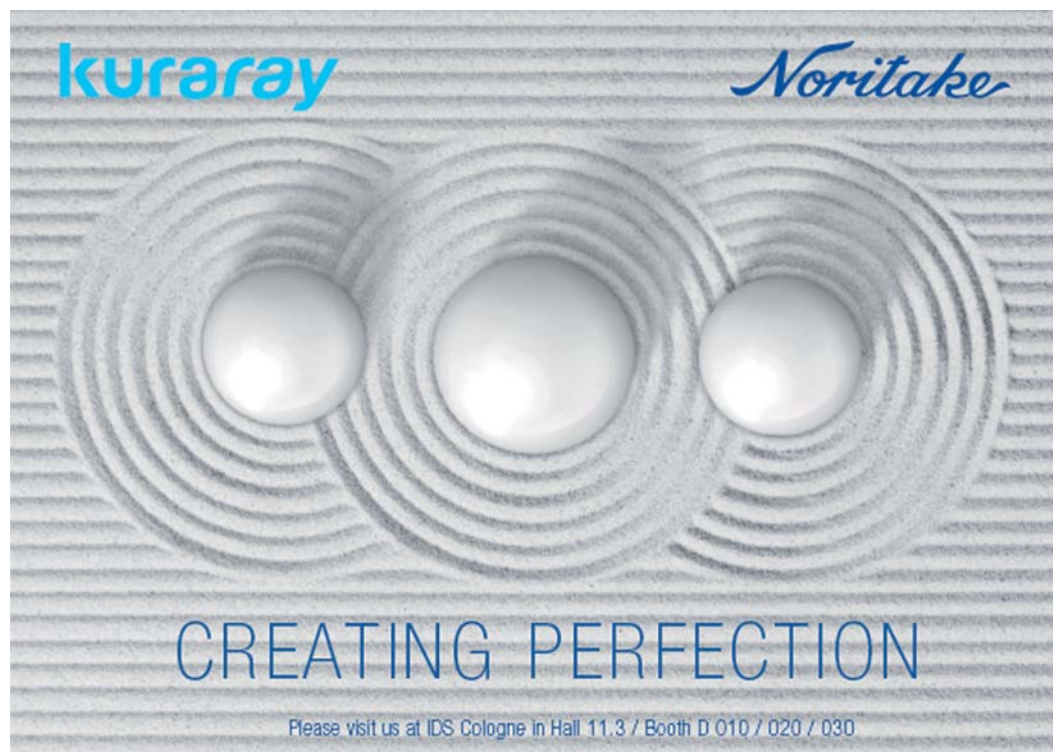_Noritake Dental Supply Company and Kuraray Medical merged to form a new company called Kuraray Noritake Dental, which has continued to develop Kuraray and Noritake dental products, which represent highly aesthetic restorations in dental technology.

Kuraray Noritake Dental will be exhibiting its successful innovations at IDS 2013, and is proud to offer products developed through the combined, valuable experience of the original companies in the field of ceramic technology.

World-first products will be launched during the IDS and demonstrated during hands-on presentations by internationally well-known dental technicians.

Visitors can attend "Behind the scenes: Rule the opacity, gain ultimate control over porcelain" by **Hiroki Goto** and "Internal stain: World for reproduction of natural teeth" by **Alek Aronin**.

Be the first to visit us at our booth: Hall 11.3, Booth D 010/020/030. _



Organiser:

Society of Esthetic
Dentistry in Romania



Dedicated to excellence in esthetic dentistry

International Congress of Esthetic Dentistry

16-18 May 2013 Bucharest

» Info

SSER · Dr. Leonte Street · no.8
District 5 · Bucharest · Romania

Phone: 0040.21.317.58.64
Email: contact@sser.ro
Web: www.sser.ro

FREE ATTENDANCE

REGISTER NOW

www.sser.ro

■ Speakers

- Dr. Orlando Alvarez - Chile
- Prof. Dr. David Cottrell - USA
- Dr. George Freedman - Canada
- Dr. Pablo Galindo Moreno - Spain
- Dr. Scott Ganz - USA
- Dr. Jordi Gargallo - Spain
- Dr. Fay Goldstep - Canada
- Prof. Dr. Samuel Kratchman - USA
- Prof. Dr. Ivo Krejci - Switzerland
- Dr. Francesco Maggiore - Italy
- Prof. Dr. Angelo Putignano - Italy
- Dr. Roberto Rossi - Italy
- Dr. Gadi Schneider - Israel
- Prof. Dr. Massimo Simion - Italy
- Prof. Dr. Philippe Sleiman - Lebanon
- Prof. Dr. Marius Steigmann - Germany
- Prof. Dr. Hom Lay Wang - USA
- Prof. Dr. Ervin Weiss - Israel

www.sser.ro

ESCD tenth anniversary international meeting

Turin, 3–5 October 2013.



Dear ESCD members, friends,

First of all, I would like to wish everybody a marvellous 2013. It feels like only yesterday when we had our congress in Bucharest last May and I was elected president. Now we are already in the middle of the organisation of our tenth anniversary congress in Turin in October.

I would like to thank all our members for your confidence and esteem during the last ten years and to give my assurances that it will be my task to reward your contribution. We value your membership in these poor economic times more than ever. Your help will allow us to excel in our services. The European Society of Cosmetic Dentistry (ESCD) is made up of all of us and without the contribution of all our members from all over the world who believe in our society and in the development of aesthetic and cosmetic dentistry, the society would not exist.

The society and its board are working very hard and making great progress. We have a brand new user-friendly website (www.escdonline.eu) with helpful information for ESCD members and for the public. The English version of the **cosmetic dentistry** magazine has become the official journal of the ESCD and it will be distributed free to all members who have paid their annual subscription fee. We are working with the editors of **cosmetic dentistry** throughout Europe to be able to translate and distribute the journal in local languages. We are launching country study clubs for each nation in which we have a country chairman. These are aimed at educating and enabling members to share their professional experiences, and building camaraderie and pride in belonging to our association.

The Italian board is working on the organisation of our congress in October, which is themed "Esthetic truffles", and we promise you fireworks in terms of both the scientific programme and the social events. Those familiar with our society are well aware of the great atmosphere and friendship that distinguish our gatherings. For the ESCD and friends evening, we have scheduled tasting of Piedmont regional wines and dishes based on truffles, and of course there will be music and dancing. This year, we have drawn up a scientific programme that is relevant to the whole dental team: dentists, dental technicians, hygienists, nurses and secretaries. For the support staff, we will have a full-day lecture by Dr Alessandro Magnanensi, an expert in human resources, on the role of personnel in helping overcome the difficult economical situation that many of our offices are experiencing. For dentists and technicians, practical hands-on sessions will be held on Thursday, while Friday and Saturday will offer presentations by well-known speakers in aesthetic dentistry and technology. Just to give you a taste: C. Orr, I. Loi, D. Winkler, M. Nicastro, F. Ferretti, B. Lesage, T. Quereshi, N. Perakis, R. Bonfiglioli, V. Muttoni, A. DiFelice, G. Paolone, E. Manca and many others.

I warmly invite you to reserve 3 to 5 October 2013 and to bring all your staff with you for the tenth ESCD international congress in Turin. You won't regret it, I promise!

With my very best wishes to all of you,

Luca Dalloca, President of the ESCD

Join the ESCD and you'll get:

A regular newsletter

Featuring the latest in cosmetic dentistry, upcoming events, news from members and much more. Got an interesting article you'd like published? News you think other members would like to hear about? Send it to us and we'll almost certainly include it!

Study clubs

Starting in 2013, we'll be arranging regional meetings all over Europe. An ideal place to meet other members from your district, obtain a little education and enjoy the company of like-minded professionals.

Special offers when attending our superb annual meeting, featuring internationally acclaimed speakers and fabulous social events

ESCD meetings are legendary! Consistently excellent speakers from all over the world offering top-class education to what many people agree is the friendliest dental society!

Your personal membership certificate

Hang it proudly on your wall. Membership of the ESCD demonstrates that you're serious about dental education and do everything to provide your patients with excellent service.

Listing on our website

Patients looking for a cosmetic dentist will find your details on our website. If you hold certification by the ESCD, they will have the confidence of knowing your work has been approved by your peers and is of a high standard.

The opportunity to obtain the valued ESCD Certificate in Cosmetic Dentistry

Certification by the ESCD demonstrates that you've completed a number of clinical cases to a very high standard and

have been examined on your knowledge of cosmetic dentistry. The opportunity to obtain certification is a valuable one, and all members should aim for certification. It provides great professional satisfaction and can help develop your practice.

The opportunity to meet dentists from all over the world and share in their professional experience

ESCD members love meeting each other! Exchanging views and comparing working practices in different countries is one of the most valuable benefits of membership. On top of that, everyone has a wonderful time!

Special subscription rates for your assistants, hygienists and other staff

We all work better as a team. That's why the ESCD encourages all members of the practice to join. Attending lectures with team members greatly improves the implementation of new ideas when you return to work.

Membership of a truly international group that always places members' interests first

The ESCD does everything it can to support its members. If you have questions about clinical dentistry, practice management or any other dental issue, ask our team and we'll find someone to help. Send your questions to info@escd.info. We're always open to suggestions about how we can improve the society and always try to act on our members' comments.

Superb value! Annual individual membership of the ESCD costs only €190.00 for dentists and €95.00 for dental team members! **The ESCD** really is for everyone. We're passionate about cosmetic dentistry. We know it's what more and more of our patients are asking for, so we're determined for our members to get the best possible support and education to be able to offer excellent services to the public. Whether you're completely new to cosmetic dentistry or whether you're already an experienced practitioner, the ESCD is for you. Join now at www.escdonline.eu!

10th ANNIVERSARY MEETING

TORINO CINEMA LUX

Italy, October 3rd - 5th, 2013



INVITED SPEAKERS:

★ PERAKIS - BONFIGLIOLI



★ IAFRATE - LESAGE



★ BUDA - MUTONE



★ LASSERRE



★ MINTRONE



★ WINKLER



★ CSILLAG



★ HALLEY



★ TAMIR



★ ORR



PONGIONE - DELLA NEVE ★



CANULLO - MARINOTTI ★



NICASTRO - FERRETTI ★



LOI - DI FELICE ★



MAGNANENSI ★



SARACINELLI ★



FREEDMAN ★



QURESHI ★



MANCA ★



ESTHETIC "TRUFFLES"

The Gold Standard in 2013

The annual conference of the Society for Color and Appearance in Dentistry

Author_Dr So Ran Kwon, USA



Fig. 1

Fig. 1_Dr Rade Paravina, Executive Director of SCAD (left); Dr Joe Ontiveros, board member (middle); and Dr Stephen Chu, President of SCAD (2011–2012; right).

From 28 to 29 September 2012, the long-awaited fourth annual conference of the Society for Color and Appearance in Dentistry (SCAD) was held at the W Chicago City Center hotel.

The event was opened by Dr Stephen Chu, then SCAD president (2011–2012), followed by a warm

welcome message from Dr Ronald E. Goldstein, the pioneer of aesthetic dentistry. The scientific meeting featured high-quality, evidence-based presentations on colour-related issues in dentistry by well-known speakers in dentistry attended by leading clinicians, researchers, specialists, dental technicians and general dentists worldwide.

The topics covered the wide field of aesthetic dentistry with a special emphasis on the theme, "White and pink—Emulating nature and beyond".

The challenge of colour matching with composite resins was spectacularly demonstrated by Dr Newton Fahl (Brazil), Dr Jack L. Ferracane (USA) and Dr Didier Dietschi (Switzerland).

Clinical techniques and safety issues in state-of-the-art tooth whitening were well explained by Dr Linda Greenwall (UK) and Dr Yiming Li (USA). Special attention was given to obtaining credible results in monitoring tooth whitening using the newly introduced VITA Bleachedguide 3D-Master, with the inclusion of interpolated shade-guide



Fig. 2



Fig. 3



Fig. 4



Fig. 5

units, in the presentation by Dr Rade D. Paravina (USA), Executive Director of SCAD.

Overcoming everyday challenges associated with different ceramic systems was discussed by Dr John O. Burgess (USA), Dr Michael Tholey (Germany), Dr Kenneth A. Malament (USA) and Prof. Edward A. McLaren (USA).

Bone and tissue interaction at the implant and abutment interface, creating the critical pink interface in aesthetic implant dentistry, was the topic of the presentations by Dr Dennis P. Tarnow (USA), Dr Maurice A. Salama (USA), Dr David A. Garber (USA) and Dr Aris-Petros Tripodakis (Greece).

The presentations on digital developments and their influence on general dentistry and dental laboratories by Dr Brian LeSage (USA), Aki Yoshida (USA), Michael Bergler (USA) and Claude Sieber (Switzerland) were very well received by the audience.

Colour science in general and a new form of precision in risk assessment were discussed in depth by Dr Stephen C. Bayne and Dr Sherilyn G. Sheets (both USA), and in a joint lecture by Drs Shigemi Nagai and Stephen Chu (both USA).

Besides the high-calibre poster sessions with a variety of first-rate research presentations and very well-attended lunch and learn sessions, the convivial atmosphere during the social programme, acknowledging and appreciating the diversity of the members, encouraged lively conversation with colleagues in a most comfortable environment.

The academy was very pleased to announce the first recipients of the newly established SCAD VITA Award for excellence in research related to colour and appearance in aesthetic dentistry.

The award serves to acknowledge the successful professional collaboration with and the long-term support of VITA Zahnfabrik. The ultimate purpose of the award is to promote meaningful research related to colour and appearance in aesthetic dentistry.

Save the date for the fifth annual SCAD conference, which will be held from 3 to 5 October 2013 at the five-diamond Ritz-Carlton Hotel in Denver, Colorado. The list of confirmed presenters includes Pinhas Adar, Luiz Narciso Baratieri, Lawrence E. Brecht, Theodore P. Croll, Krikor Derbabian, Sillas Duarte, Charles J. Goodacre, Jens Fischer, So Ran Kwon, Ernesto A. Lee, Tall Mor, Dan Nathanson, Jacinthe M. Paquette, Stefan Paul, Wolfgang Rauh, Irena Sailer, Herbert Scheller, Thomas Sing, Edward J. Swift, Van P. Thompson and Marcos Vargas, and there are more to come (www.scadent.org).

SCAD was founded in 2008 as a consortium of dental professionals and colour experts interested in the area of aesthetic dentistry specifically related to the scientific investigation and the application of colour and appearance in dentistry.

Fig. 2_Dr Stephen Chu presents the SCAD VITA Award for excellence in research to Dr So Ran Kwon (left). **Fig. 3**_Convivial atmosphere during the President's Dinner, with Dr Stephen Chu (second from right). **Fig. 4**_Convivial atmosphere during the President's Dinner, with Dr Rade Paravina (second from right). **Fig. 5**_During the President's Dinner, with Dr Dan Nathanson, SCAD secretary (second from right), and Dr John Powers, SCAD treasurer, holding the E.B. Clark Award. Photographs courtesy of Stephen R. Snow.

_contact

cosmetic
dentistry



Dr So Ran Kwon

Department of
Restorative Dentistry
Center for Dental Research
Loma Linda University School
of Dentistry
24876 Taylor St.
Loma Linda
CA 92350, USA

sorankwon@llu.edu

International Osteology Symposium in Monaco

Possibly making regeneration easier?

Author_Verena Vermeulen, Switzerland

Some of the most critical issues concerning oral regeneration are going to be discussed at the International Osteology Symposium from 2 to 4 May 2013 in Monaco. The major challenges are making regenerative therapies easier and less invasive, and combating the serious issue of peri-implantitis. Both congress chairmen Niklaus P. Lang, Switzerland, and Massimo Simion, Italy, provide a unique insight into the programme.

Verena Vermeulen: The theme of the congress is "Decision-making with oral tissue regeneration". Why is the focus on decisions?

Niklaus P. Lang: In dental practice, it is always a matter of having to make decisions. For instance, do you extract a tooth or do you retain it? By what criteria should you decide? Practitioners often choose a strategy for therapy intuitively, based on their familiarity with certain procedures, but the scientific evidence for one therapy option or another actually ought to take centre stage. That is what we want to communicate.

Massimo Simion: At the same time, there is still a lack of high-quality data for specific clinical situations. For this reason, meta-analyses frequently draw the conclusion that further studies are needed. Notwithstanding, we need to treat our patients and make decisions. In unclear situations, the views of experts are sought after—they are familiar with the literature on the one hand and possess a great deal of clinical experience on the other. This benefits congress attendees greatly because it provides them with a point of reference.

Most indications for oral regeneration are covered in the programme. Which ones are especially important to you?

Lang: The whole of Saturday is dedicated to the topic of peri-implantitis. Dentists often prefer to place an implant rather than to preserve a peri-



odontally compromised tooth. This might then give rise to peri-implant complications in some cases. At the symposium, we will concern ourselves with the problem of these infections in relation to the oral cavity as a whole and consequently the need for holistic treatment.

Simion: Apart from bacteria, the manner in which an implant is placed and the implant surface appear to play a role, although it has not yet been possible to demonstrate the latter conclusively. There are also patient factors that have an impact, such as smoking or specific diseases. It is key for dentists and oral surgeons to be aware of all these factors and learn how to diagnose and treat peri-implantitis early. The answers to many questions are already close at hand. That is why we have devoted so much space to the topic at the congress.

_And bone regeneration? Can we now assume that everyone knows all there is to know about this subject?

Simion: We perform guided bone regeneration (GBR) procedures on an almost daily basis—to enhance aesthetics, to treat angular bone defects and so on. But how can GBR be made easier and less invasive? When, for instance, is it possible to dispense with autologous bone or a non-absorbable membrane that is difficult to handle? Or how can you prevent bone resorption directly after a tooth has been extracted and so facilitate subsequent implant placement? Current questions for daily practice, like these, will be discussed at the congress.

_One session will address patient-reported outcome measures. What does that involve?

Lang: To assess therapy success, we often only gauge objective parameters such as implant survival rate or bone level, but it is also important to establish whether the patient is satisfied with the function and the aesthetics or whether the patient experienced a lot of pain or swelling post-operatively. For a long time, such subjective parameters were neglected in implantology.

_Is soft tissue a significant factor in aesthetics?

Simion: The quality and quantity of soft tissue is vital for aesthetics, but for function too. For example, the amount of keratinised gingiva around an implant seems to have an effect on recession development and the risk of peri-implantitis.

Dentists may be hesitant to harvest a graft from the palate because the procedure is invasive and painful. Soft-tissue substitute products are such an interesting alternative for this reason. At the congress, we will be taking a close look at when they can



be used. They are very well suited to some indications but not to others.

Prof. Massimo Simion (left) and Prof. Niklaus P. Lang (right).

_Can you list three key reasons your colleagues should attend the Osteology Symposium in Monaco?

Lang: At this time of the year, Monaco is beautiful and the programme speaks for itself. It is well balanced, featuring both young and established colleagues. Some focus on empirical practice, others on the science. This mix is essential for us, for they go hand in hand. And last but not least, the Osteology Foundation will be celebrating its tenth anniversary in Monaco. Nobody should miss this.

_Thank you very much for this interview.

Further information: www.osteology-monaco.org

_info

cosmetic
dentistry

Prof. Massimo Simion is Professor for Periodontology and Co-Chairman of the Department of Periodontics and Dental Implant Rehabilitation of the Dental Clinic of the University of Milan. His chief interest lies in Guided Bone Regeneration and Osseo-integration. He is a member of the Osteology Foundation Board.

Prof. Niklaus P. Lang is Professor of Periodontology and the holder of numerous prizes. At over 500 publications, he is one of the most prominent international periodontists. He is Editor-in-Chief of various international journals, such as *Clinical Oral Implants Research* and a member of the Osteology Foundation Board.

International Events

2013

International Dental Show

12–16 March 2013
Cologne, Germany
www.ids-cologne.de

AACD Annual Meeting

24–27 April 2013
Seattle, USA
www.aacd.com

DGKZ Annual Meeting

26 & 27 April 2013
Berlin, Germany
www.dgkz.com

8th CAD/CAM & Digital Dentistry

International Conference
2 & 3 May 2013
Dubai, UAE
www.cappmea.com

International Osteology Symposium

2–4 May 2013
Monaco
www.osteology.org

SSER Annual Meeting

16–18 May 2013
Bucharest, Romania
www.sser.ro

EAED Spring Meeting

30 May–1 June 2013
Crete, Greece
www.eaed.org

MIS' 2nd Global Conference

6–9 June 2013
Cannes, France
www.mis-implants.com

Nobel Biocare Global Symposium

20–23 June 2013
New York, USA
www.nobelbiocare.com

IACA 2012

1–3 August 2013
Calgary, Canada
www.theiaca.com

AAED Annual Meeting

7–10 August 2013
Washington, USA
www.estheticacademy.org

FDI Annual World Dental Congress

28–31 August 2013
Istanbul, Turkey
www.fdiworldental.org

ESCD annual meeting

3–5 October 2013
Turin, Italy
www.escdonline.eu

BACD Annual Conference

7–9 November 2013
London, UK
www.bacd.com



submission guidelines:

Please note that all the textual components of your submission must be combined into one MS Word document. Please do not submit multiple files for each of these items:

- _ the complete article;
- _ all the image (tables, charts, photographs, etc.) captions;
- _ the complete list of sources consulted; and
- _ the author or contact information (biographical sketch, mailing address, e-mail address, etc.).

In addition, images must not be embedded into the MS Word document. All images must be submitted separately, and details about such submission follow below under image requirements.

Text length

Article lengths can vary greatly—from 1,500 to 5,500 words—depending on the subject matter. Our approach is that if you need more or less words to do the topic justice, then please make the article as long or as short as necessary.

We can run an unusually long article in multiple parts, but this usually entails a topic for which each part can stand alone because it contains so much information.

In short, we do not want to limit you in terms of article length, so please use the word count above as a general guideline and if you have specific questions, please do not hesitate to contact us.

Text formatting

We also ask that you forego any special formatting beyond the use of italics and boldface. If you would like to emphasise certain words within the text, please only use italics (do not use underlining or a larger font size). Boldface is reserved for article headers. Please do not use underlining.

Please use single spacing and make sure that the text is left justified. Please do not centre text on the page. Do not indent paragraphs, rather place a blank line between paragraphs. Please do not add tab stops.

Should you require a special layout, please let the word processing programme you are using help you do this formatting automatically. Similarly, should you need to make a list, or add footnotes or endnotes, please let the word processing programme do it for you automatically. There are menus in every programme that will enable you to do so. The fact is that no matter how carefully done, errors can creep in when you try to number footnotes yourself.

Any formatting contrary to stated above will require us to remove such formatting before layout, which is very time-consuming. Please consider this when formatting your document.

Image requirements

Please number images consecutively throughout the article by using a new number for each image. If it is imperative that certain images are grouped together, then use lowercase letters to designate these in a group (for example, 2a, 2b, 2c).

Please place image references in your article wherever they are appropriate, whether in the middle or at the end of a sentence. If you do not directly refer to the image, place the reference at the end of the sentence to which it relates enclosed within brackets and before the period.

In addition, please note:

- _ We require images in TIF or JPEG format.
- _ These images must be no smaller than 6x6 cm in size at 300 DPI.
- _ These image files must be no smaller than 80 KB in size (or they will print the size of a postage stamp!).

Larger image files are always better, and those approximately the size of 1 MB are best. Thus, do not size large image files down to meet our requirements but send us the largest files available. (The larger the starting image is in terms of bytes, the more leeway the designer has for resizing the image in order to fill up more space should there be room available.)

Also, please remember that images must not be embedded into the body of the article submitted. Images must be submitted separately to the textual submission.

You may submit images via e-mail, via our FTP server or post a CD containing your images directly to us (please contact us for the mailing address, as this will depend upon the country from which you will be mailing).

Please also send us a head shot of yourself that is in accordance with the requirements stated above so that it can be printed with your article.

Abstracts

An abstract of your article is not required.

Author or contact information

The author's contact information and a head shot of the author are included at the end of every article. Please note the exact information you would like to appear in this section and format it according to the requirements stated above. A short biographical sketch may precede the contact information if you provide us with the necessary information (60 words or less).

Questions?

Magda Wojtkiewicz (Managing Editor)
m.wojtkiewicz@oemus-media.de

cosmetic dentistry

_ beauty & science

asia pacific edition

dti Dental
Tribune
International

Publisher

Torsten R. Oemus
t.oemus@dental-tribune.com

Managing Editor

Magda Wojtkiewicz
m.wojtkiewicz@dental-tribune.com

Executive Producer

Gernot Meyer
g.meyer@dental-tribune.com

Designer

Franziska Dachsel
f.dachsel@dental-tribune.com

Copy Editors

Sabrina Raaff
Hans Motschmann

International Administration Marketing & Sales

Esther Wodarski
e.wodarski@dental-tribune.com

Executive Vice President

Finance
Dan Wunderlich
d.wunderlich@dental-tribune.com

Printed by

Löhnert Druck
Handelsstraße 12
04420 Markranstädt, Germany

International Media Sales

Matthias Diessner
m.diessner@dental-tribune.com

Europe

Melissa Brown
m.brown@dental-tribune.com

Asia Pacific

Peter Witteczek
p.witteczek@dental-tribune.com

The Americas

Jan M. Agostaro
j.agostaro@dental-tribune.com

International Offices

Europe

Dental Tribune International GmbH
Contact: Esther Wodarski
Holbeinstr. 29, 04229 Leipzig, Germany
Tel.: +49 341 48474-302
Fax: +49 341 48474-173

Asia Pacific

Dental Tribune Asia Pacific Ltd.
Contact: Tony Lo
Room A, 26/F, 389 King's Road
North Point, Hong Kong
Tel.: +852 3113 6177
Fax: +852 3113 6199

The Americas

Dental Tribune America, LLC
Contact: Anna Wlodarczyk
116 West 23rd Street, Suite 500
NY 10011, New York, USA
Tel.: +1 212 244 7181
Fax: +1 212 244 7185

Advisory Board

Dr Michael Miller, USA
Dr Seok-Hoon Ko, Korea

Editorial Board

Dr Anthony Au, Australia
Dr Bao Baicheng, China
Dr Helena Lee, Singapore
Dr Hisashi Hisamitsu, Japan
Dr Jiraporn Charudilaka, Thailand
Dr Mostaque H. Sattar, Bangladesh
Dr Ratnadeep Patil, India
Dr Sim Tang Eng, Malaysia
Dr Suhit Raj Adhikari, Nepal
Dr Takashi Nakamura, Japan
Dr Vijayaratnam Vijayakumaran, Sri Lanka

cosmetic
dentistry _ beauty & science
is the official publication of:



www.dental-tribune.com

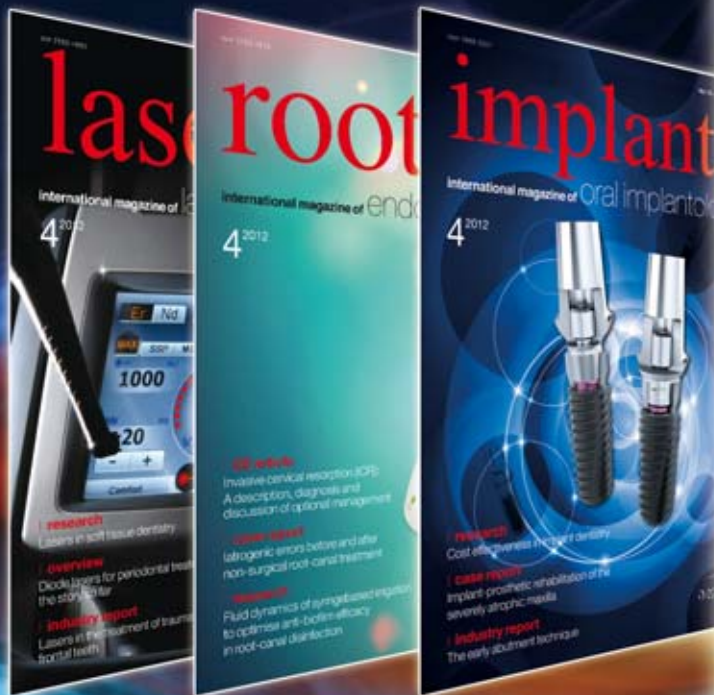Copyright Regulations

cosmetic dentistry beauty & science is published by Dental Tribune Asia Pacific Ltd. and will appear in 2013 with four issues. The magazine and all articles and illustrations therein are protected by copyright. Any utilisation without the prior consent of editor and publisher is inadmissible and liable to prosecution. This applies in particular to duplicate copies, translations, microfilms, and storage and processing in electronic systems.

Reproductions, including extracts, may only be made with the permission of the publisher. Given no statement to the contrary, any submissions to the editorial department are understood to be in agreement with a full or partial publishing of said submission. The editorial department reserves the right to check all submitted articles for formal errors and factual authority, and to make amendments if necessary. No responsibility shall be taken for unsolicited books and manuscripts. Articles bearing symbols other than that of the editorial department, or which are distinguished by the name of the author, represent the opinion of the afore-mentioned, and do not have to comply with the views of Dental Tribune Asia Pacific Ltd. Responsibility for such articles shall be borne by the author. Responsibility for advertisements and other specially labeled items shall not be borne by the editorial department. Likewise, no responsibility shall be assumed for information published about associations, companies and commercial markets. All cases of consequential liability arising from inaccurate or faulty representation are excluded. General terms and conditions apply, legal venue is North Point, Hong Kong.

cosmetic

dentistry _ beauty & science



You can also subscribe via
www.oemus.com/abo

One issue free of charge!

 **Subscribe now!**

I hereby agree to receive a free trial subscription of **cosmetic dentistry** _ beauty & science (4 issues per year).

I would like to subscribe to **cosmetic dentistry** for € 44 including shipping and VAT for German customers; € 46 including shipping and VAT for customers outside of Germany unless a written cancellation is sent within 14 days of the receipt of the trial subscription. The subscription will be renewed automatically every year until a written cancellation is sent to OEMUS MEDIA AG, Holbeinstr. 29, 04229 Leipzig, Germany, six weeks prior to the renewal date.

▶ Reply via Fax to +49 341 48474-290 to OEMUS MEDIA AG or via E-mail to grasse@oemus-media.de

Last Name, First Name	
Company	
Street	
ZIP/City/County	
E-mail	Signature

Notice of revocation: I am able to revoke the subscription within 14 days after my order by sending a written cancellation to OEMUS MEDIA AG, Holbeinstr. 29, 04229 Leipzig, Germany.

Signature

After endodontic laser treatment there is no smear layer around the opening of the lateral canal.

The universe at your fingertips.

LightWalker®

Introducing the highest technology dental laser system

Supreme clinical results in:

- TwinLight™ Perio Treatments (TPT)
- TwinLight™ Endo Treatments (TET)
- Effective oral implant surgery
- Gentle TouchWhite™ bleaching
- Patient-friendly conservative dentistry

Unmatched simplicity of use:

- Pre-sets for over 40 applications
- Intuitive user navigation
- Balanced and weightless OPTOflex arm
- Nd:YAG handpiece detection system
- Er:YAG scanner ready

Journey into a new dental experience with speed, precision and great results.
Visit www.lightwalkerlaser.com today!

