

# cosmetic dentistry \_ beauty & science

2<sup>2013</sup>

| **review**

Ceramics: Rationale for material selection

| **case report**

Changing grey-white back to red-white

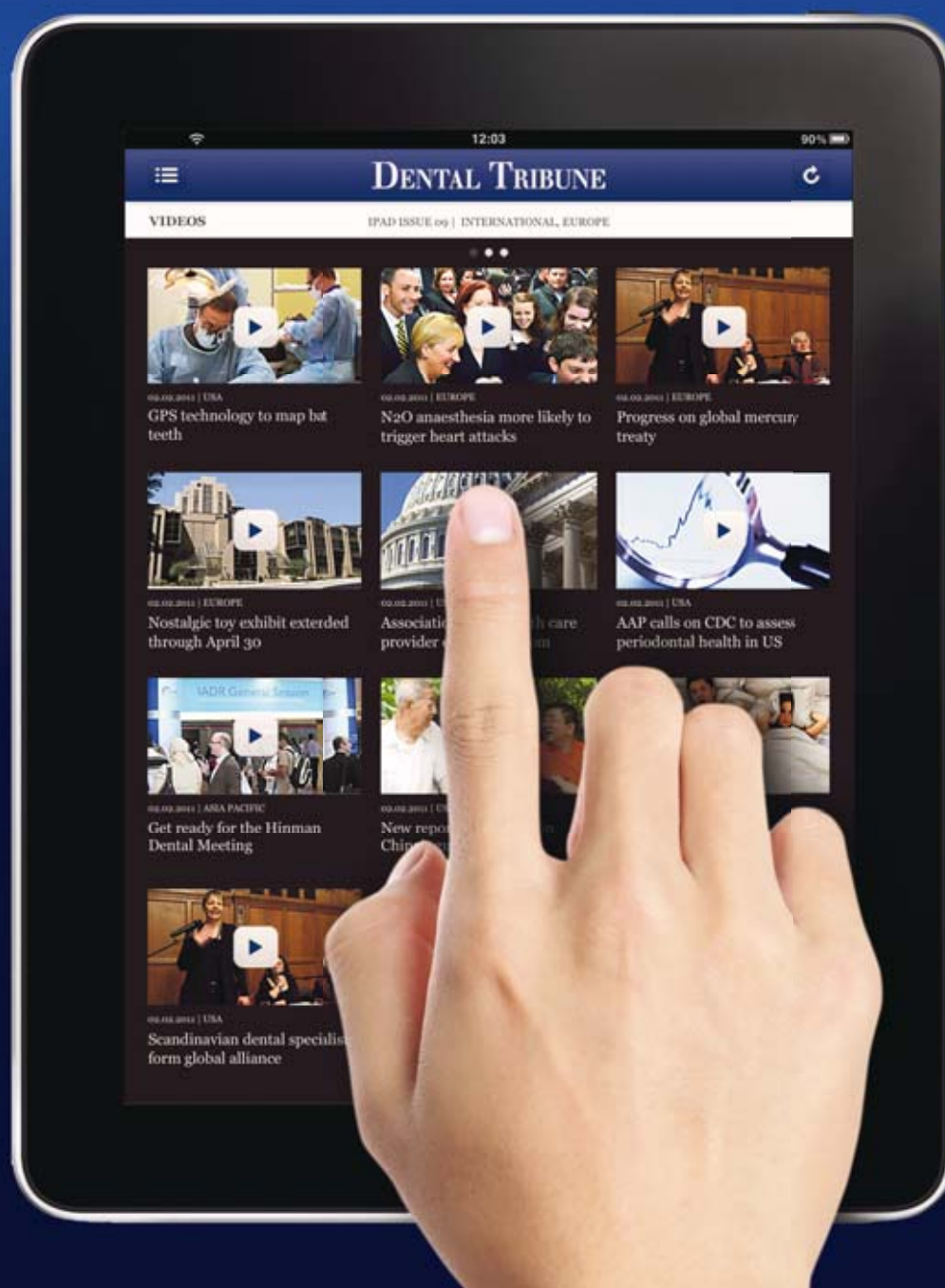| **technique**

The perimeter preparation

# Dental Tribune for iPad – Your weekly news selection

Our editors select the best articles and videos from around the world for you every week. Create your personal edition in your preferred language.

[ipad.dental-tribune.com](http://ipad.dental-tribune.com)



**DENTAL TRIBUNE**

— The World's Dental Newspaper —

# Dear Reader,

\_Colour measurement of human teeth and restorative materials has become an integral component of both clinical practice and dental research. This importance is reflected in the immense growth of the Society for Color and Appearance in Dentistry (SCAD), founded in 2008 as a consortium of dental professionals and other experts interested in the area of aesthetic dentistry specially related to scientific investigation and the relationship between colour and appearance.

Colour matching has always been a challenge, especially in the anterior region, regardless of the restorative materials used. Although many regard ceramics as the restorative material of choice for ensuring increased longevity and superior aesthetics, composite materials have been gaining favour because of their minimally invasive nature, excellent aesthetic potential, and relatively low cost. Restoration using composite has evolved dramatically with the development of new resin composite materials with excellent optical properties emulating dentine and enamel. Proper application of the natural layering technique, which seeks to imitate the optical and anatomical characteristics of natural teeth, using these new composite materials can provide solutions to overcome the aesthetic challenges faced in so many clinical situations.

With the increased development and evolution of digitally created restorations, the rationale for material selection in ceramic restorations has changed significantly. However, even with the introduction of high-technology devices, there is still a need for proper interpretation of shade information in creating the ceramic build-up and the illusion of a natural tooth by ceramic layering techniques.

Special emphasis in colour matching has been placed on the critical pink interface. The underlying titanium implant may shine through delicate peri-implant mucosa, resulting in the greyish appearance of the gingival cuff. Optical evaluation of the gingival colour and a multidisciplinary approach to the interface planning will simplify treatment and provide predictable aesthetic outcomes.

In this issue of **cosmetic dentistry**, we have included beautifully illustrated and well-documented articles that report on restorations with resin composites and ceramics. I hope you will enjoy this edition and successfully apply your new knowledge to your daily practice.

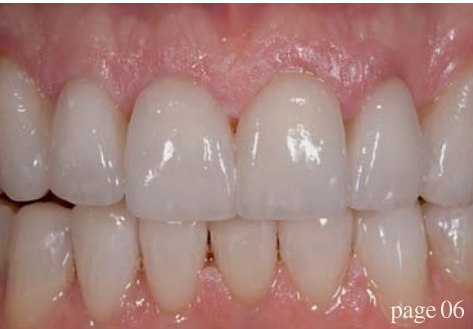Yours faithfully,



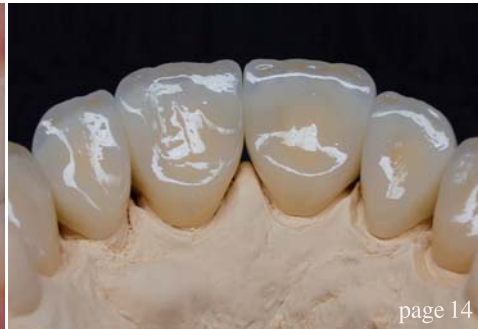Dr So Ran Kwon  
Co-Editor-in-Chief  
President, Korean Bleaching Society  
Seoul, Korea



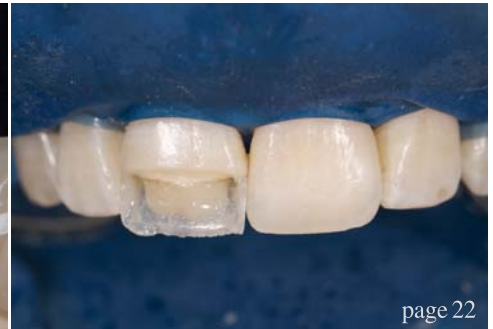Dr So Ran Kwon  
Co-Editor-in-Chief



page 06



page 14



page 22

| editorial

03 Dear Reader

| Dr So Ran Kwon, Co-Editor-in-Chief

| review

06 Ceramics: Rationale for material selection

| Prof. Edward A. McLaren & Yair Y. Whiteman, USA

30 Silane coupling agents and surface conditioning in dentistry

| Dr Christie Ying Kei Lung & Dr Jukka Pekka Matinlinna, Hong Kong

| case report

14 Changing grey–white back to red–white

| Jost P. Prestin, Germany

18 Ceramic and composite resin integration for custom smile design

| Prof. Rony Hidalgo, Drs Rafael Barrantes & Roberto Tello, Peru

22 Extending the boundaries of feasibility in direct restorative procedures

| Dr Gauthier Weisrock, France

| technique

26 The perimeter preparation

| Dr Fay Goldstep, Canada

| feature

34 A biological approach to implantology

| An interview with Dr Eduardo Anitua, Scientific Director of the BTI Biotechnology Institute

| meetings

36 Concepts in implant therapy discussed

| Osteology Foundation celebrates anniversary meeting in Monaco

40 International Events

| industry news

38 CLEARFIL MAJESTY ES-2

—The new universal composite

| Kuraray

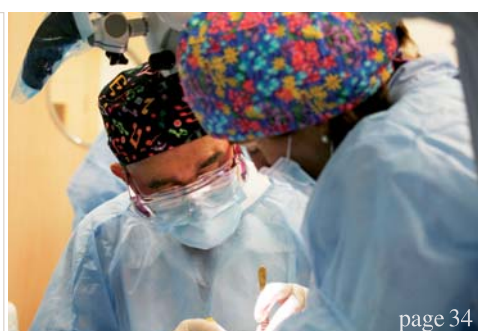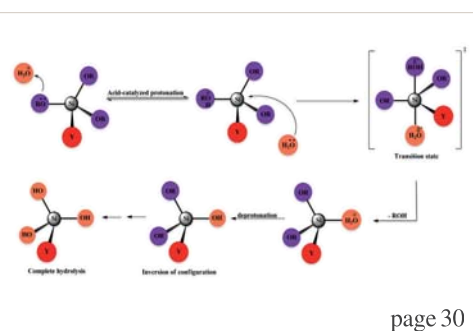
| about the publisher

41 | submission guidelines

42 | imprint



Cover image courtesy of Rido



page 34



page 36

**kuraray**

*Noritake*



**Just  
blend in!**

## **CLEARFIL MAJESTY™ ES-2**

**You'll just be amazed by the blending effects every time you use this intuitive composite concept.**

Start working with the new universal CLEARFIL MAJESTY™ ES-2 and something surprising will happen. We re-engineered the color system to make it simply intuitive. Just pick your VITA™ approved colors and start designing nature. To create the perfect adaption to the tooth, we further optimized the consistency. This will give you great confidence during layering. Especially when using our new Premium Enamel and



Dentin colors to naturally layer your restoration. After finishing you will just be amazed by the blending effect.

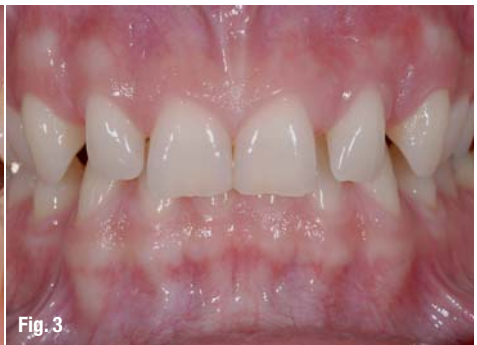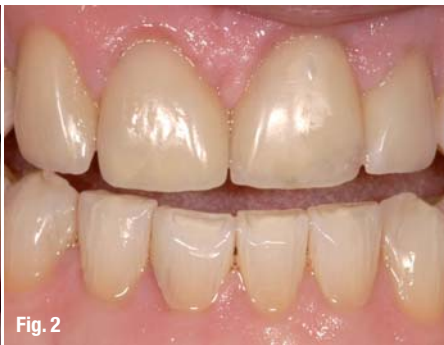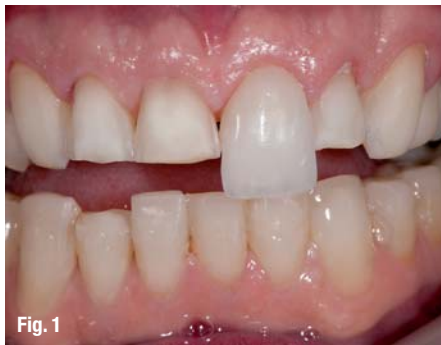To create this unique restorative workflow, we used the latest pioneering technologies to make your restorations better, more predictable and longer lasting.

For more information +49 (0) 69-305 85981 or [www.kuraray-dental.eu](http://www.kuraray-dental.eu)

**SCIENCE.KNOWLEDGE.SUPPORT.**

# Ceramics: Rationale for material selection

**Authors**\_Prof. Edward A. McLaren & Yair Y. Whiteman, USA



**Fig. 1** \_Image of prepared tooth: Significant dentine is exposed along the proposed length, flexure and tensile stress risk is at least medium, and the restoration thickness would be at least 0.9 mm.

This was noted in the chart.

**Fig. 2** \_Image demonstrating excessive enamel crazing, leakage, and staining. Flexure, tensile, and shear shear risk would be medium to high. The substrate would depend on preparation.

**Fig. 3** \_Image demonstrating deep overbite in which shear and tensile stresses would be at least medium.

Bonded porcelain would require maintenance of enamel and an occlusal strategy to reduce leverage on the teeth.

## \_Abstract

All imaginable types of materials and techniques, from very conservative ceramic restorations to very complex restorations of either metal or high-strength crystalline ceramics veneered with porcelain, have been introduced and tried over the years, with varying levels of success. Unfortunately, there is considerable misinformation, and a general lack of published rational treatment planning guidelines, about when to use the ceramics available in dentistry. This article provides readers with a systematic process for treatment planning with ceramic materials. Specific guidelines are outlined for the appropriate clinical conditions for using the various ceramic materials available.

## \_Introduction

Many types of ceramic materials and processing techniques have been introduced throughout the years. As early as 1903, Charles Land patented all-ceramic restorations, using fired porcelains for inlays, onlays and crowns.<sup>1</sup> Insufficient understanding of material requirements for survival in the oral environment, poor ceramic processing techniques, and the inability of adhesive cementation led to early catastrophic failure. Since then, all imaginable varieties of materials and techniques, from very conservative ceramic restorations to very complex porcelain veneered of either metal or high-strength crystalline ceramics, have

been introduced and tried with varying levels of success.<sup>2</sup> The authors have previously published two detailed descriptions of, or classification systems for, ceramics used in dentistry, one based on the microstructure of the material and the second on the way in which the material is processed.<sup>3</sup>

There is considerable misinformation and a general lack of rational treatment planning guidelines published regarding the use of different ceramics in dentistry. The literature is replete with various accounts of clinical success and failures of all types of dental treatments. Sadowsky<sup>4</sup> published a review of the literature covering treatment considerations using aesthetic materials, for example whether to use amalgam or composite and the success rates of different treatments. No recent literature could be found presenting a thorough discussion of when to use the various ceramics, for example when feldspathic porcelains should be used, when either pressed or machined glass-ceramics are appropriate, when different types of glass-ceramics should be employed, when a high-strength all-ceramic crown system of either alumina or zirconia is ideal, and when metal ceramics are suitable.

This article provides a systematic stepwise process for treatment planning with ceramic materials and presents specific guidelines for the appropriate clinical conditions for applications of the various systems.

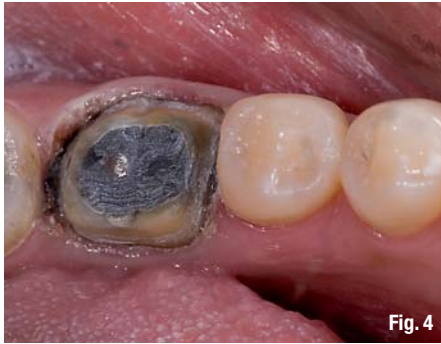

Fig. 4

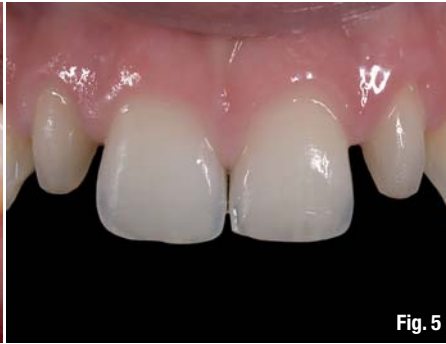

Fig. 5

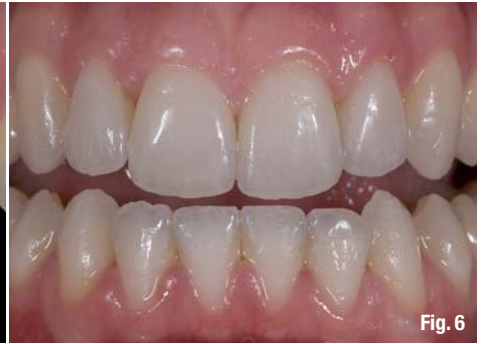

Fig. 6

## \_Treatment philosophy

A treatment philosophy based on current standards of care that consider the patient's aesthetic requirements is a prerequisite to making any decision regarding the use of a material or technique. More importantly, this philosophy should be aimed at maintaining the long-term biological and structural health of the patient in the least destructive way.

Restorative or aesthetic dentistry should be practised as conservatively as possible. The use of adhesive technologies makes it possible to preserve as much tooth structure as feasible while satisfying the patient's restorative needs and aesthetic desires.<sup>5</sup> The philosophy today is not to remove any healthy tooth structure unless absolutely necessary. This will reduce dentists' frustration when orthodontics would have been the ideal treatment. With restorations, clinicians should choose a material and technique that allows the most conservative treatment in order to satisfy the patient's aesthetic, structural, and biological requirements, and that meets the mechanical requirements to provide clinical durability. Each of these requirements could be the topics of individual articles.

There are four broad categories or types of ceramic systems:

1. powder/liquid feldspathic porcelains;
2. pressed or machined glass-ceramics;
3. high-strength crystalline ceramics; and
4. metal ceramics.

### Category 1

Porcelains—the most translucent—can be used the most conservatively, but are the weakest.<sup>3,6</sup>

### Category 2

Glass-ceramics can be very translucent too but require slightly thicker dimensions for workability and aesthetics than porcelains do.

### Categories 3 and 4

High-strength crystalline ceramics and metal ceramics, although demonstrating progressively higher fracture resistance, are more opaque and, therefore, require additional tooth reduction and are thus a less conservative alternative.

Based on the treatment goal of being as conservative as possible, the first choice will always be porcelains, then glass-ceramics, followed by high-strength ceramics or metal ceramics. The decision will be based on satisfying all the treatment requirements, that is, if the more-conservative material meets all the treatment requirements then that is the ideal choice. The article will identify the clinical conditions in which treatment requirements dictate the use of a specific category of ceramics.

## \_Space required for aesthetics

The first consideration is the final 3-D position of the teeth, that is, smile design. There are several resources available for smile design.<sup>7,8</sup> The second consideration is the colour change desired from the substrate (tooth), since this will dictate the restoration thickness. In general with porcelains, a porcelain thickness of 0.2–0.3 mm is required for each shade change (A2 to A1 or 2M1 to 1M1). For example, A3 to A0 would require a veneer of 0.6–0.9 mm in thickness.

Glass-ceramics have the same space requirements as porcelain for effective shade change; however, the authors find it difficult to work with this category and produce the best aesthetic results when the material is less than 0.8 mm in thickness. High-strength all-ceramic crowns require a thickness of 1.2–1.5 mm, depending on the substrate colour, and metal ceramics need a thickness of at least 1.5 mm to create lifelike aesthetics. With that in mind, a diagnosis based on tooth position and colour change will direct treatment planning, as well as the final decision regarding tooth preparation design (i.e. total tooth structure reduction)

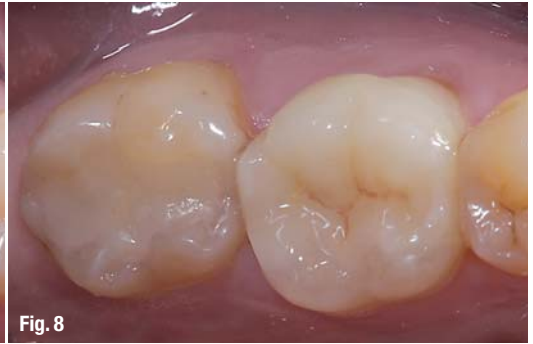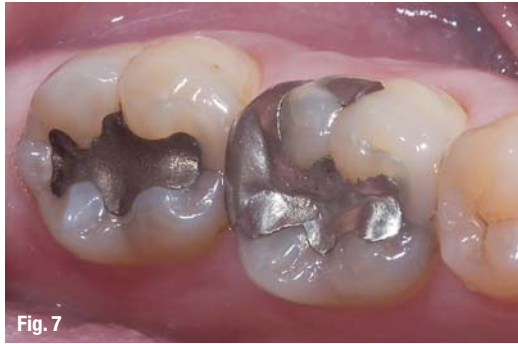**Fig. 4** Image of preparation with poor substrate and subgingival margins where maintaining seal would be difficult. High-strength ceramics or metal ceramics would be indicated.

**Fig. 5** Image of minimal preparations prior to receiving bonded porcelain.

**Fig. 6** Two-year post-op image of very conservative Category 1 bonded porcelain restorations, using VITA VM porcelains.

**Fig. 7**\_Pre-op image of a case for an inlay in tooth 18 and onlay in tooth 19.

**Fig. 8**\_Post-op image using non-layer IPS e.max HT.



and whether orthodontic treatment is required to facilitate a more conservative and aesthetic outcome.

### Clinical parameters to evaluate

Once the 3-D smile design has been completed, colour change assessed, and adjunctive therapy finished to create an environment that will allow the least removal of healthy tooth structure, an evaluation of each tooth is needed for ascertaining which ceramic system and technique are most suitable. The evaluation of individual teeth for specific material selection involves assessing four environmental conditions in which the restoration will function.

#### *Substrate*

The first consideration is evaluating the substrate to which the material will be attached (Fig. 1). Is it enamel? How much of the bonded surface will be enamel? How much enamel is on the tooth? Is it dentine? How much of the bonded surface will be dentine? What type of dentine will the restoration be bonded to (tertiary or sclerotic dentine exhibits a very poor bond strength, and bonding to this type of dentine should be avoided when possible)? Is it a restorative material (e.g. composite, alloy)? These questions should be addressed for each tooth to be restored, since this will be a major parameter for material selection.

It is generally understood and accepted that a predictable and high bond strength is achieved when restorations are bonded to enamel, given the fact that the stiffness of enamel supports and resists the stresses placed on the materials in function. However, it is equally understood that bonding to dentine surfaces, as well as composite substrates, is less predictable given the flexibility of these substrates. The more stress placed on the bonds between dentine and composite substrates and the restoration, the more damage to the restoration and underlying tooth structure is likely to occur. Therefore, because enamel is significantly

stiffer than either dentine or composite and much more predictable for bonding, it is the ideal substrate for bonded porcelain restorations.

#### *Flexure risk assessment*

Next is the flexure risk assessment. Each tooth and existing restorations are evaluated for signs of past overt tooth flexure. Signs of excessive tooth flexure can be excessive enamel crazing (Fig. 2), tooth and restoration wear, tooth and restoration fracture, micro-leakage at restoration margins, recession, and abfraction lesions. Often, the aetiology is multifactorial and controversial. However, if several of these conditions exist, there is an increased risk of flexure on the restorations that are placed, which may overload weaker materials. Evaluation of this possibility is also based on the amount of remaining tooth structure. The more intact the enamel is, the less potential there is for flexure.

The amount of tooth preparation can directly affect tooth flexure and stress concentration. There is much potential subjectivity in any observational assessment of clinical conditions; however, an assessment of flexure potential for each tooth to be restored is needed. A subjective assignment of low, medium, or high risk for flexure is based on the evaluated parameters, as outlined below:

Low risk for clinical situations in which there is low wear; minimal to no fractures or lesions in the mouth; and the patient's oral condition is reasonably healthy.

Medium risk when signs of occlusal trauma are present; mild to moderate gingival recession exists, along with inflammation; bonding mostly to enamel is still possible; and there are no excessive fractures.

High risk when there is evidence of occlusal trauma from parafunction; more than 50 % of dentine exposure exists; there is significant loss of enamel due to wear of 50% or more; and porcelain must be built up by more than 2 mm.



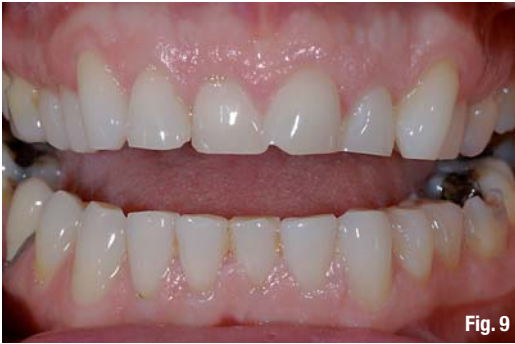

Fig. 9

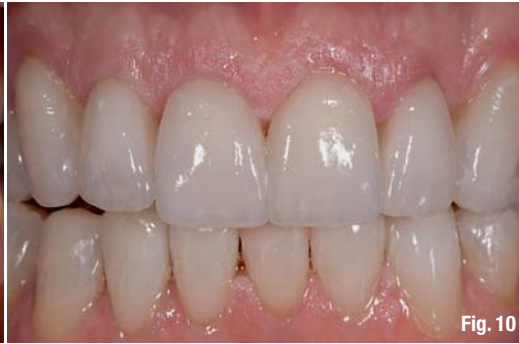

Fig. 10

**Fig. 9** Pre-op image of case requiring significant lengthening. There is at least a medium risk of flexure and unfavourable stress, and some of the substrate would be dentine. Thus, Category 1 materials were eliminated as a choice.

**Fig. 10** Post-op image of the same case using Category 2 materials, in this case VITABLOCS Mark II with minimal porcelain layering in the incisal one-third.

### *Excessive shear and tensile stress risk assessment*

The third parameter is the risk (or amount) of ongoing shear and tensile stresses that the restoration will undergo, since the prognosis is more guarded for specific materials. All types of ceramics (especially porcelains) are weak in tensile and shear stresses.<sup>9</sup> Ceramic materials perform best under compressive stress. If the stresses can be controlled, then weaker ceramics can be used, for example bonded porcelain to the tooth. The same parameters are evaluated, similar to flexure risk, for example deep overbites and potentially large areas where the ceramic would be cantilevered (Fig. 3).

If a high-stress field is anticipated, stronger and tougher ceramics are needed; if porcelain is used as the aesthetic material, the restoration design should be engineered with such support (usually a high-strength core system) that it will redirect shear and tensile stress patterns to compression. In order to achieve that, the substructure should reinforce the veneering porcelain by utilising the reinforced-porcelain system technique, which is generally accepted in the literature as a metal-ceramic concept.<sup>10</sup> The practitioner can assess and categorise low, medium, or high risk for tensile and shear stresses based on the parameters and symptoms mentioned above.

### *Bond/seal maintenance risk assessment*

The fourth parameter is the risk of losing the bond or seal of the restoration to the tooth over time. Glass-matrix materials, which consist of the weaker powder/liquid porcelains, and the tougher pressed or machined glass-ceramics, require maintenance of the bond and seal for clinical durability.<sup>11, 12</sup> Owing to the nature of the glass-matrix materials and the absence of a core material, the veneering porcelains are much more susceptible to fracture under mechanical stresses and, therefore, a good bond in combination with a stiffer tooth substructure (e.g. enamel) is essential for reinforcing the restoration. If the bond and seal cannot be maintained, then high-strength ceramics or metal

ceramics are the most suitable, since these materials can be placed using conventional cementation techniques.

Clinical situations in which the risk of bond failure is higher are

- \_ moisture control problems;
- \_ higher shear and tensile stresses on bonded interfaces;
- \_ variable bonding interfaces (e.g. different types of dentine);
- \_ material and technique selection of bonding agents (i.e. as dictated by such clinical situations as inability to achieve proper isolation for moisture control to enable use of adhesive technology); and
- \_ the experience of the operator (Fig. 4).

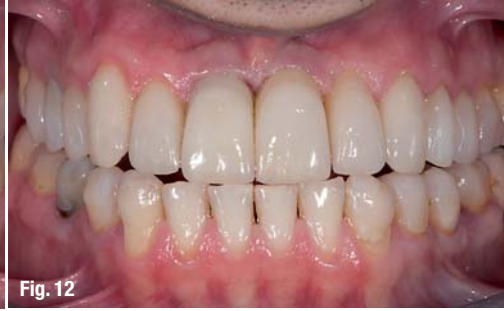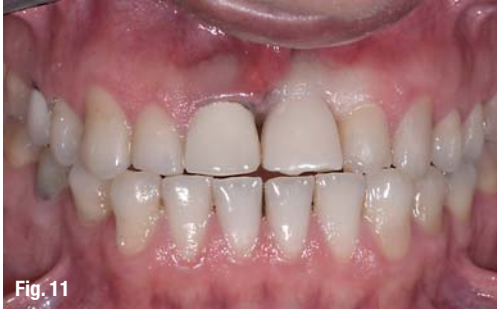An assignment of low, medium, or high risk for bond and seal failure is based on the evaluated parameters.

## **\_Category 1: Powder/liquid porcelains**

### *Guidelines*

Bonded pure-porcelain restorations are ideal as the most-conservative choice but are the weakest material and require specific clinical parameters to be successful.<sup>13</sup> Many good materials and techniques are available for bonded porcelain (e.g. Creation, Jensen Dental; Ceramco 3, DENTSPLY; EX-3, Noritake). However, VITA VM 13 (VITA Zahnfabrik) is recommended by the authors when 3D-Master shades are taken, and Vintage Halo (SHOFU) when classic shades are taken.

When following clinical parameters and guidelines at the University of California, Los Angeles's Center for Esthetic Dentistry (UCLA Center for Esthetic Dentistry), these materials have been used with similar success rates compared with porcelain fused to metal (i.e. less than a 1 % fracture rate if all parameters are followed, unpublished data; Figs. 5 & 6).



**Fig. 11** Pre-op image of a case in which the patient refused surgery and orthodontics. The treatment goal was to perform minimal preparation and use a tough material due to general medium to high risk in every area, other than seal maintenance.

**Fig. 12** Post-op image with bonded full-contour restorations on posterior teeth and incisally layered anterior teeth. All performed with IPS e.max HT.

*Aesthetic factors*

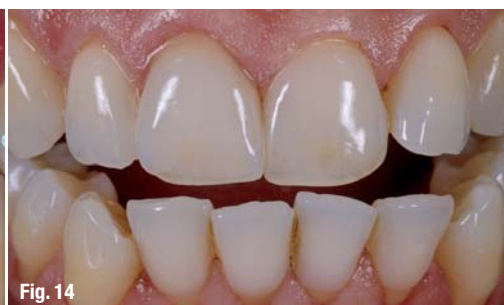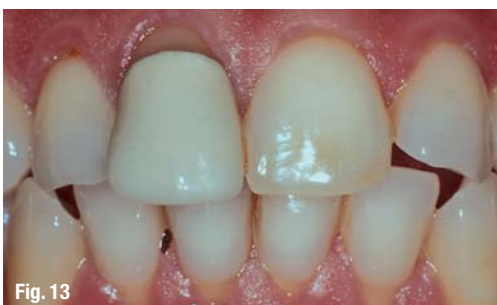Space requirements for shade change: 0.2–0.3 mm is required for each shade change.

*Environmental factors*

1. Substrate condition: There is 50 % or more remaining enamel on the tooth, 50 % or more of the bonded substrate is enamel, 70 % or more of the margin is in enamel. It is important to note that these percentages are subjective assessments based on an overall evaluation of all parameters affecting the teeth to be restored and which may influence material selection. If bonding to some dentine substrate, the dentine should be mostly unaffected and superficial, since sclerotic dentine exhibits a very poor bond strength.
2. Flexure risk assessment: There is a higher risk and a more guarded prognosis when bonding to dentine. Owing to dentine's flexible nature, it is recommended that restorations with low fracture resistance materials be avoided and, therefore, the presence of a higher percentage (i.e. at least 70 % in high-stress areas such as the margins) of enamel is recommended when restoring using powder/liquid (Category 1) materials. By increasing the presence of enamel, the prognosis is improved and, depending on the dentine/enamel ratio, the risk can be assessed as low to moderate.
3. Tensile and shear stress risk assessment: There is a low to low/moderate risk. Large areas of unsupported porcelain, deep overbite or overlap of teeth, bonding to more-flexible substrates (e.g. dentine and composite), bruxing, and more

**Fig. 13** Pre-op image of old un-aesthetic PFM.

**Fig. 14** Post-op of high-alumina crown system, veneered with VITA VM 7 (SPINELL, VITA Zahnfabrik).



distally placed restorations increase the risk of exposure to shear and tensile stresses.  
4. Bond/seal maintenance risk assessment: There is an absolute low risk of bond/seal failure.

*Summary*

Porcelains are generally indicated for anterior teeth. Occasional bicuspid use and rare molar use would be acceptable only with all parameters at the least-risk level.

Category 1 materials are ideal in cases with significant enamel on the tooth, and generally with low flexure and stress risk assessment. These materials require long-term bond maintenance for success.

**Category 2: Glass-based pressed or machinable materials**

*Guidelines*

Glass-ceramic pressable materials, for example IPS Empress (Ivoclar Vivadent) and Authentic (Jenson) and the higher-strength IPS e.max materials (Ivoclar Vivadent), can be used in any of the same clinical situations as Category 1 materials. Machinable versions of glass-ceramic material, for example VITABLOCS Mark II (VITA Zahnfabrik), IPS Empress CAD (Ivoclar Vivadent), and IPS e.max CAD, can be used interchangeably with the pressed versions. Monolithic IPS e.max, owing to its high strength and fracture toughness, has shown promise as a full-contour, full-crown alternative, even on molars.<sup>14</sup>

Glass-ceramics can also be used in clinical situations when higher risk factors are involved. Other than certain risk factors (see below) that would limit their use, these materials can be difficult to use when there is less than 0.8 mm in thickness, except at marginal areas. They can gradually thin to a margin of approximately 0.3 mm.

All things being equal, if the restoration is still a Category 1 clinical situation and there is more than 0.8 mm of working space, glass-ceramics should be considered owing to their increased strength and toughness, and the presence of sufficient room to achieve the desired aesthetics.

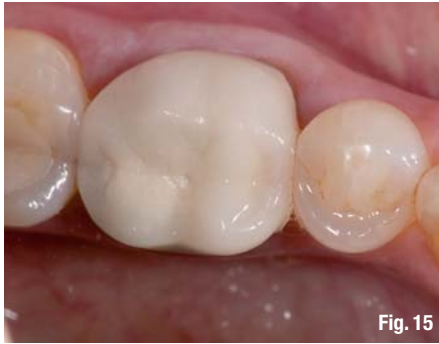

Fig. 15

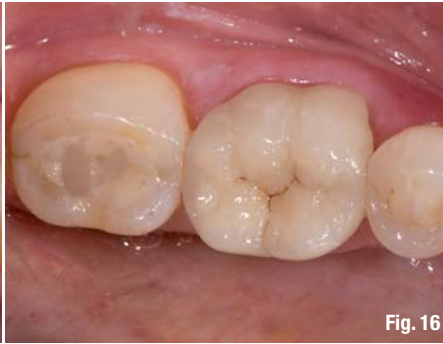

Fig. 16

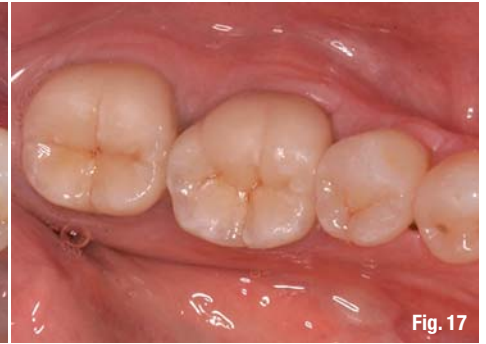

Fig. 17

### Aesthetic factors

Space requirements for workability and shade change: A minimum working thickness of 0.8 mm and 0.2–0.3 mm for each shade change is required.

### Environmental factors

1. Substrate condition: There is less than 50 % of the enamel on the tooth, less than 50 % of the bonded substrate is enamel, and 30 % or more of the margin is in dentine.
2. Flexure risk assessment: The risk is medium for Empress, VITABLOCS Mark II and Authentic-type glass-ceramics, and layered IPS e.max. In cases in which flexure risk is medium to high (and full-crown preparation is not desirable), the authors have found in their clinical trials that monolithic IPS e.max has been 100 % successful for as long as 30 months in service. All glass-ceramic restorations, including IPS e.max, were adhesively bonded in their samples.
3. Tensile and shear stress risk assessment: The risk is medium for Empress, VITABLOCS Mark II and Authentic-type glass-ceramics, and layered IPS e.max. It is medium to medium/high for bonded monolithic IPS e.max.
4. Bond/seal maintenance risk assessment: There is a low risk of bond/seal failure for Empress, VITABLOCS Mark II and Authentic-type glass-ceramics, and layered IPS e.max. It is medium for monolithic IPS e.max.

### Summary

Pressed or machined glass-ceramic materials, such as Empress, VITABLOCS Mark II and Authentic, are indicated for thicker veneers, anterior crowns, and posterior inlay and onlays (Figs. 7 & 8) in which medium or less flexure, and shear and tensile stress risk is documented (Figs. 9 & 10). Also, they are only indicated in clinical situations in which long-term bond and seal can be maintained. IPS e.max (Figs. 11 & 12), which is a different type of glass-ceramic that has higher toughness, is also indicated for the same clinical situations as the

other glass-ceramics, but can be extended for single-teeth use in higher-stress situations (as in molar crowns). This is provided it is used in a full-contour monolithic form and cemented with a resin cement.

### Category 3: High-strength crystalline ceramics

#### Guidelines

Mostly (e.g. VITA In-Ceram, VITA Zahnfabrik) all-crystalline materials are used for core systems to replace metal that would then be veneered with porcelain. Alumina-based systems, for example In-Ceram and NobelProcera (Nobel Biocare), were first on the market but are now generally being replaced with zirconia systems. Alumina systems have shown to be very clinically successful for single units, with a slightly increased risk in the molar region.<sup>15, 16</sup> They can be recommended for any single-unit anterior or bicuspid crown (Figs. 13 & 14).

The authors have observed a slight increase in failure with conventional cements. For example, after using alumina restorations for many years at the UCLA Center for Esthetic Dentistry, the authors observed that at between eight and ten years, the failure rate doubled to approximately 2 %, with those failures being core fractures necessitating replacement (unpublished data). Their suggestion for alumina-core restorations is either a resin-modified glass ionomer luting cement (e.g. RelyX, 3M ESPE) or a resin cement. For zirconia-core systems (e.g. LAVA, 3M ESPE), the authors have not experienced core fracture but have seen problems with chipping of porcelain.

White and McLaren<sup>17</sup> found that a special slow-cool thermal cycle minimises the stress in the porcelain and at the porcelain/zirconia interface. Clinically, since the authors of this current article have been using the altered firing schedules, their replacement rate for chipping has been reduced by less than 1 %.

**Fig. 15** Pre-op image of old PFM. The patient was unhappy with the opacity and metal display at margin. Category 3 or 4 material is required for this case.

**Fig. 16** Post-op image of a LAVA coping with the new LAVA Digital Veneering System (3M ESPE).

**Fig. 17** Post-op image of teeth 18 and 20 in a case with subgingival margins and poor bonding. Metal ceramics with a coping (CAPTEK).

*Aesthetic factors*

Space requirements for workability and maximum aesthetics: A minimum working thickness of 1.2 mm is required, and 1.5 mm is ideal if masking.

*Environmental factors*

1. Substrate condition: Substrate is not critical, since a high-strength core supports veneering material.
2. Flexure risk assessment: The risk is high or below. For high-risk situations, core design and structural support for porcelain become more critical.
3. Tensile and shear stress risk assessment: The risk is high or below. Note that for high-risk situations, core design and structural support for porcelain become more critical. Preparations should allow for a 0.5 mm core plus 1 mm of porcelain to ensure the best aesthetic results. Additionally, there should not be more than 2 mm of unsupported occlusal or incisal porcelain; the restoration core should be built out to support marginal ridges. For higher-risk molar regions, it is better to use zirconia cores rather than alumina cores, provided the current firing parameters are followed. Full-contour zirconia restorations (e.g. BruxZir, Glidewell Laboratories) have been recommended for high-risk molar situations. Failure of these restorations is not likely to be an issue; some preliminary concern involves wear of the opposing dentition with full-contour zirconia.<sup>18</sup> No clinical data could be found to confirm or refute this. Clinically, only full-contour zirconia against full-contour zirconia in the molar region should be considered when no other clinical option is viable.
4. Bond/seal maintenance risk assessment: If the risk of obtaining or losing the bond or seal is high, then zirconia is the ideal all-ceramic to use.

*Summary*

A high-strength ceramic (specifically zirconia) is indicated when significant tooth structure is missing, unfavourable risk for flexure and stress distribution is present, and it is impossible to obtain and maintain bond and seal (e.g. most posterior full-crown situations with subgingival margins; Figs. 15 & 16).

**\_Category 4: Metal ceramics**

*Guidelines*

For almost half a century, metal ceramics have been the standard for aesthetic full-crown restorations. Generally, they have the same indications as Category 3 zirconia-based restorations. With metal ceramics, manufacturers have eliminated the complications throughout the years; these

materials do not have the same thermal firing sensitivity as zirconia does. However, anterior teeth metal ceramics need to be approximately 0.3 mm thicker to have the same aesthetics as properly designed zirconia/porcelain crowns. When porcelain-fused-to-metal restorations are indicated, the CAPTEK (Precious Chemicals USA) system has been the material of choice at the UCLA Center for Esthetic Dentistry owing to its superior aesthetic properties.

*Aesthetic factors*

1. Space requirements for workability: 1.5–1.7 mm is required for maximum aesthetics.
2. Substrate condition: The substrate is not as critical, since the metal core supports the veneering material.
3. Flexure risk assessment: The risk is high or below. For high-risk situations, core design and structural support for porcelain become more critical.
4. Tensile and shear stress risk assessment: The risk is high or below. For high-risk situations, core design and structural support for porcelain become more critical.
5. Bond/seal maintenance risk assessment: If the risk of obtaining or losing the bond or seal is high, then metal ceramics are an ideal choice for a full-crown restoration.

*Summary*

Metal ceramics are indicated in all full-crown situations, esp. when all risk factors are high (Fig. 17).

**\_Conclusion**

This article has presented a systematic process of clinical evaluation and rationale for material selection. The most important point is that the most-conservative restoration should be done if the clinical criteria are met; for example, a full-coverage crown or deep-cut glass-ceramic restoration should not be performed when a more conservative porcelain restoration is indicated.

*Editorial note: A complete list of references is available from the publisher.*

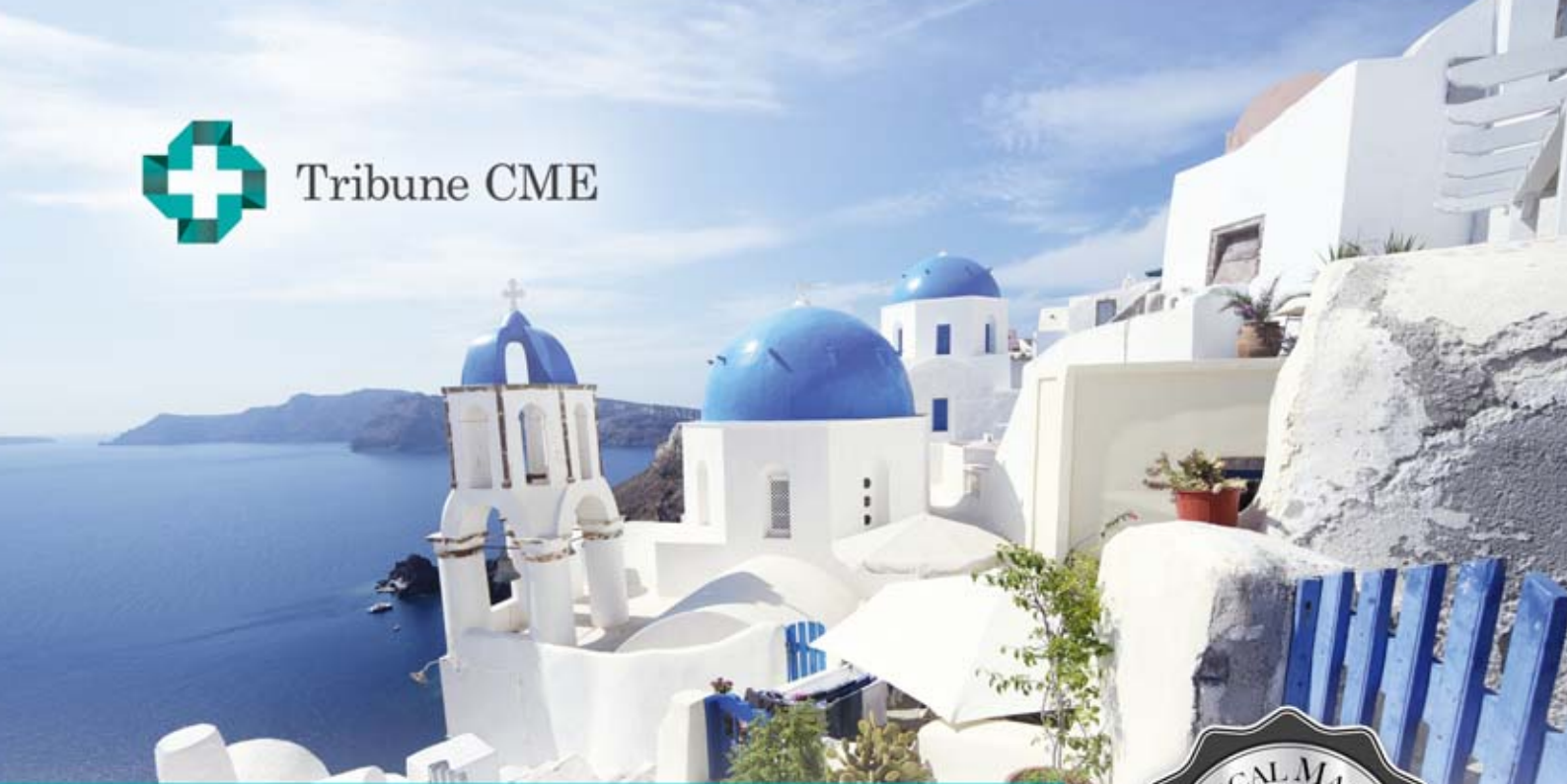**\_about the authors** **cosmetic**  
dentistry

**Prof. Edward A. McLaren, DDS, MDC,** is the founder and director of UCLA postgraduate aesthetics, and Director of the UCLA Center for Esthetic Dentistry in Los Angeles, California.

**Yair Y. Whiteman, DMD,** is a full-time faculty member at the UCLA Center for Esthetic Dentistry.



Tribune CME



# 1 Year Clinical Masters Program in Aesthetic and Restorative Dentistry

17 June 2013 - 8 Feb 2014

in **Santorini** (Greece), **Geneva** (Switzerland), **Pesaro** (Italy)



Three on location sessions with **live patient treatment, hands-on practice** plus online learning and online mentoring under the Masters' supervision.

Learn from the **Masters** of Aesthetic and Restorative Dentistry:



### Registration information:

17 June 2013 - 8 Feb 2014  
in **Santorini** (Greece), **Geneva** (Switzerland), **Pesaro** (Italy)

Find out more on [www.TribuneCME.com/128](http://www.TribuneCME.com/128)

Curriculum fee: € 9,900

contact us at: tel.: **+49-341-48474-302** / email: [request@tribunecme.com](mailto:request@tribunecme.com)

Collaborate on your cases and access hours of premium video training and live webinars.

University of the Pacific  
you will receive a certificate from the University of the Pacific.

Latest iPad with courses  
all early birds will receive an iPad fully loaded with premium clinical courses

**150** ADA CERP C.E. CREDITS

**ADA C.E.R.P.** Continuing Education Recognition Program

Tribune Group GmbH is the ADA CERP provider. ADA CERP is a service of the American Dental Association to assist dental professionals in identifying quality providers of continuing dental education. ADA CERP does not approve or endorse individual courses or instructors, nor does it imply acceptance of credit hours by boards of dentistry.

# Changing grey–white back to red–white

Author\_Jost P. Prestin, Germany

**Fig. 1** Old PFM crowns *in situ* with surrounding grey-coloured gingiva.

**Fig. 2** Old PFM crowns, slightly exposed tooth necks of teeth 12–22 and an open margin on the crown on tooth 22.

**Fig. 3** View of the grey-coloured occlusal soft tissue around the anterior PFM crowns and around the PFM molars.

**Figs. 4a–d** Schematic diagram of the incidence of light. The cross-section of a tooth with a PFM crown shows that the light passes through the ceramic and is blocked by the more opaque surface of the metal coping and scattered back into the ceramic (a & b). The cross-section of a natural tooth shows that the light passes into the tooth and the mineral tooth structure scatters it in all directions (c & d). Owing to the thin alveolar bone and the thin soft tissue, the entire area around the tooth is lit up from the inside.<sup>1</sup>

**Fig. 5** Occlusal view of the preparation with packed retraction cords.

**Fig. 6** The preparation with the same stump shade on all stumps.

**Figs. 7 & 8** Provisional *in situ* with cleared papillary areas.

**Fig. 9** The impression, taken with Aquasil Ultra.

**Fig. 10** Close-up image of the control model.

**Fig. 11** Occlusal checking on the model to ensure adequate space for the crowns.

**Fig. 12** The finished IPS e.max copings on the control model.

**Fig. 13** Close-up image of the coping margins.

**Figs. 14 & 15** Ready for the try-in.

**Fig. 16** Close-up image of

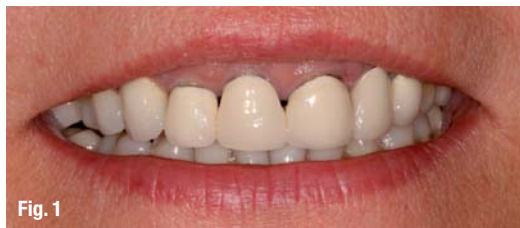

Fig. 1

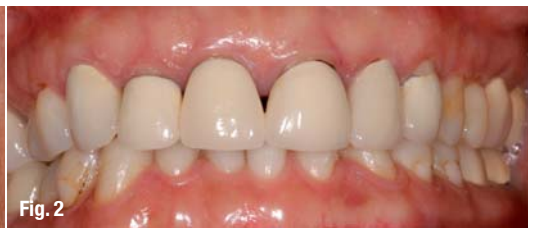

Fig. 2

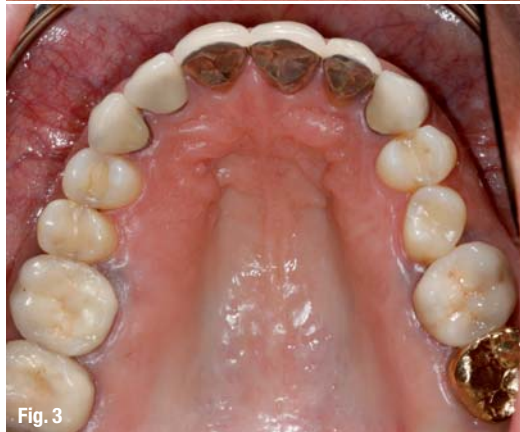

Fig. 3

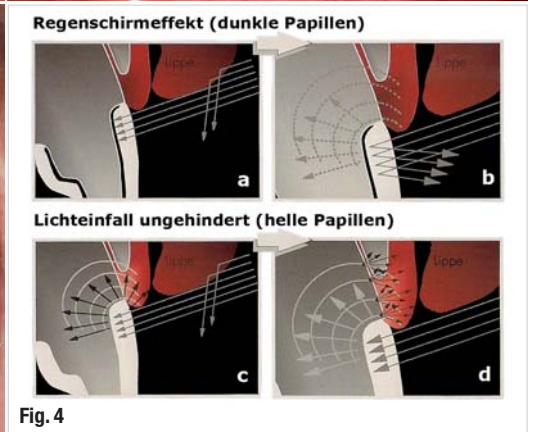


Fig. 4

When meeting someone for the first time, a dental technician or dentist automatically glances at the person's mouth and teeth. Generally, the unnatural grey- or purple-coloured gingiva attracts more attention than the quality of the crowns. As detailed in the following case report, anterior porcelain-fused-to-metal (PFM) crowns

or bridges are the main reason for this unsightly gingiva.

## Case report

A female patient came to our office in February 2012 complaining about pain in the region of teeth

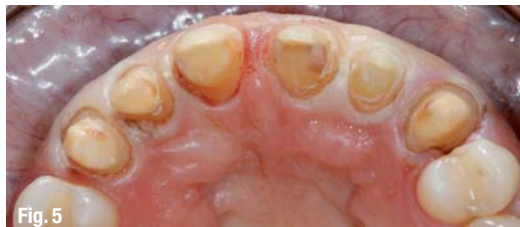

Fig. 5

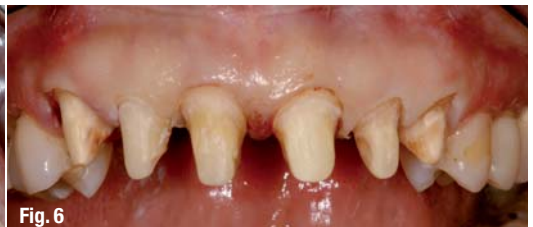

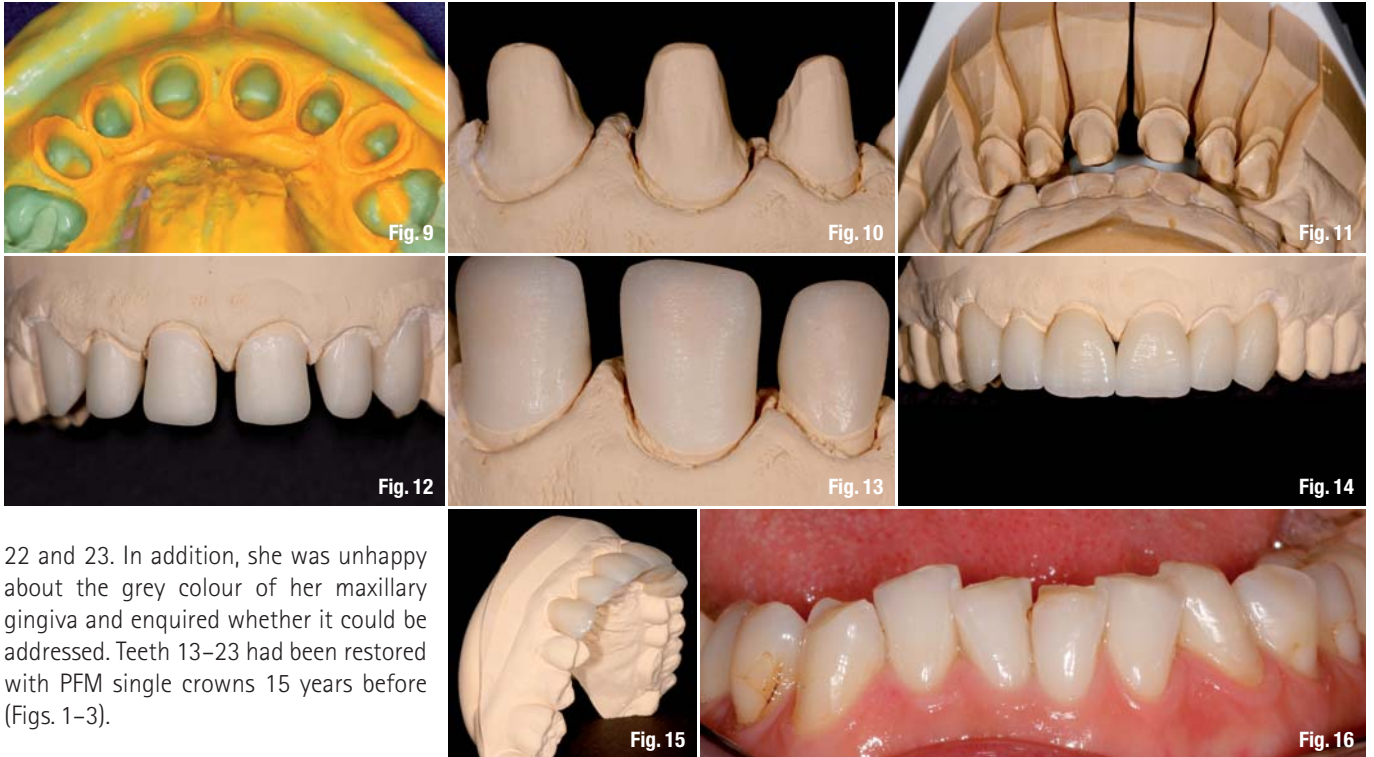
Fig. 6

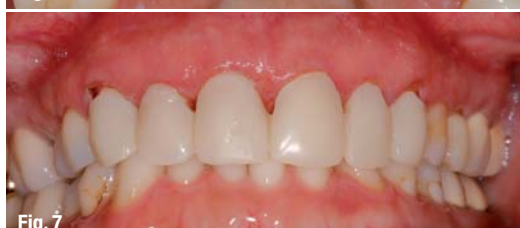

Fig. 7

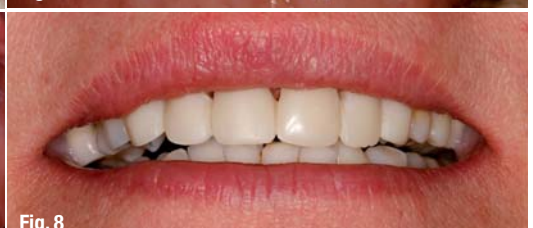

Fig. 8



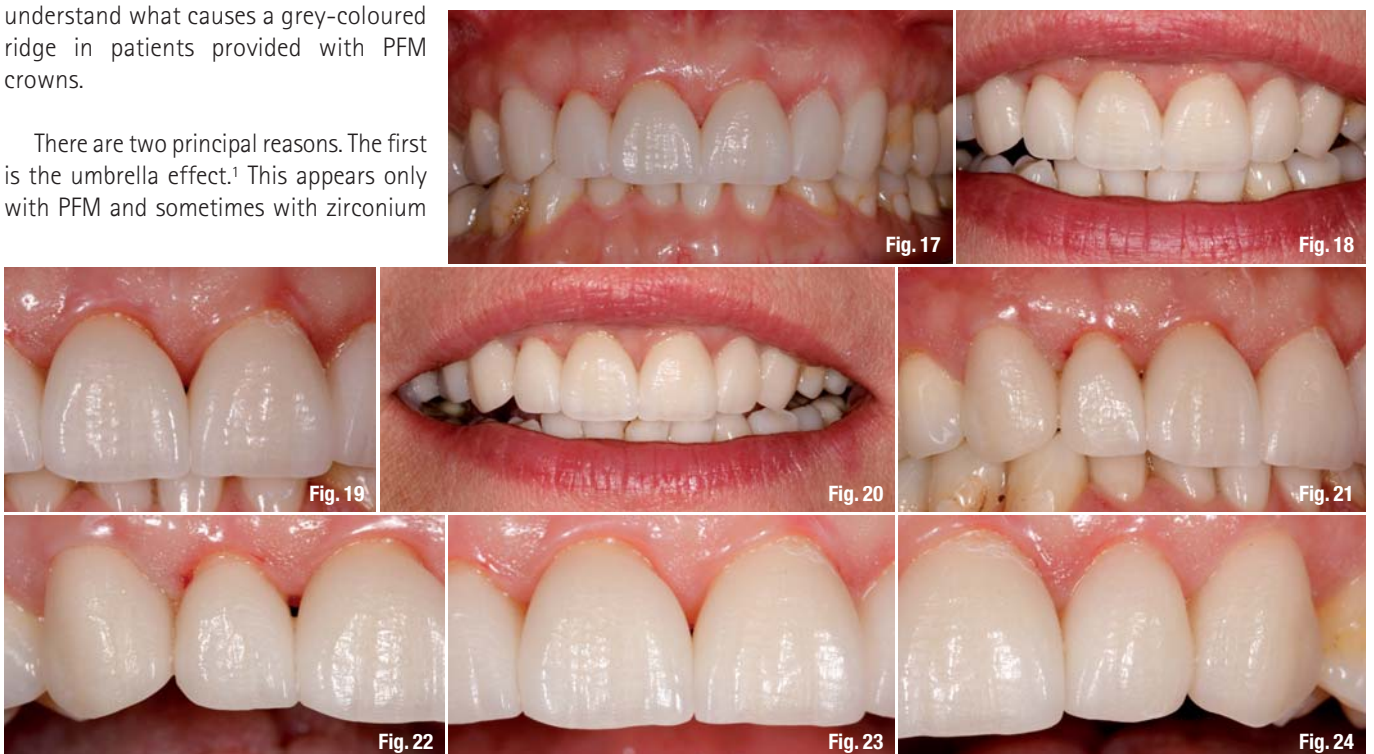
22 and 23. In addition, she was unhappy about the grey colour of her maxillary gingiva and enquired whether it could be addressed. Teeth 13–23 had been restored with PFM single crowns 15 years before (Figs. 1–3).

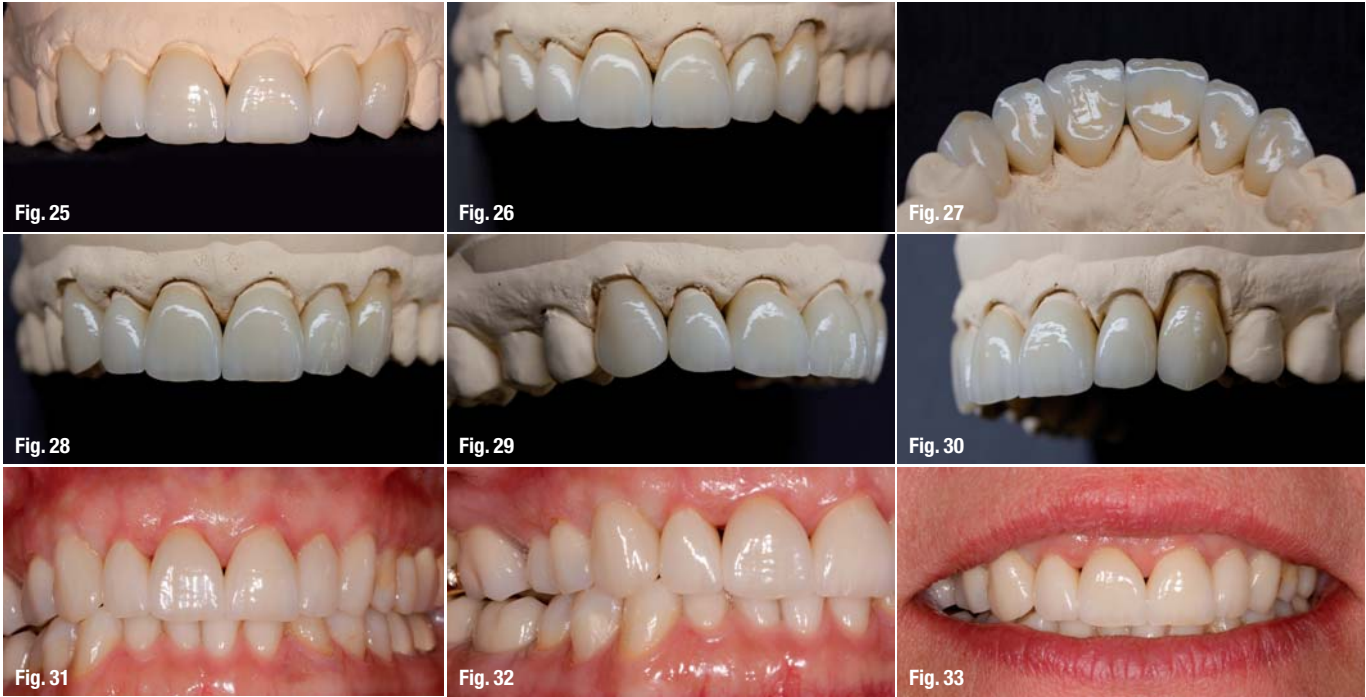
After a detailed discussion of the state of the art in anterior aesthetics, we decided to renew all six PFM crowns and replace them with IPS e.max crowns (Ivoclar Vivadent). For all anterior cases, IPS e.max is our first choice of material. Not even all ceramic is all ceramic. Zirconium has nearly the same light transmission as PFM—almost nothing. Of course development goes on, and the first translucent zirconia products have been made available. It is first necessary to understand what causes a grey-coloured ridge in patients provided with PFM crowns.

There are two principal reasons. The first is the umbrella effect.<sup>1</sup> This appears only with PFM and sometimes with zirconium

crowns. The opaque copings block the light (Figs. 4a & b) so the root is not able to transmit the light and brighten up the papilla from the inside. Lithium disilicate glass-ceramic (except for the MO and HO ingots) is able to mimic the natural tooth. Owing to the mineral (crystalline) structure of the tooth substance and the natural light transmission of the IPS e.max restoration, the light is scattered in all

the mandibular anterior teeth for the ceramic build-up. **Figs. 17–19** IPS e.max crowns *in situ* at the try-in. **Fig. 20** Controlling the shade, including the lips. **Figs. 21–24** Controlling the approximal areas.





**Figs. 25–30**\_An overview of the finished crowns on the control model.

**Figs. 31–33**\_Close-up image of the papillae directly after seating of the new crowns.

directions inside the tooth, lighting up the gingiva from the inside (Figs. 4c & d). The second reason for grey gingiva underneath PFM crowns is metal oxides diffusing into the soft tissue. The possibility of dark gingiva is increased by crowns with a higher ignoble metal content.

### Treatment plan

After preparing all the necessary paperwork and discussing the treatment plan again, we began removing the old crowns and finished the supragingival preparation in the middle of April. The stump shade of all six teeth was the same, allowing us to press the copings all at once in the same shade (IPS e.max Press LT A2; Figs. 5 & 6). The provisional was directly prepared in the office. It is important to leave enough space for the papillae so that they are not pushed away (Figs. 7 & 8).

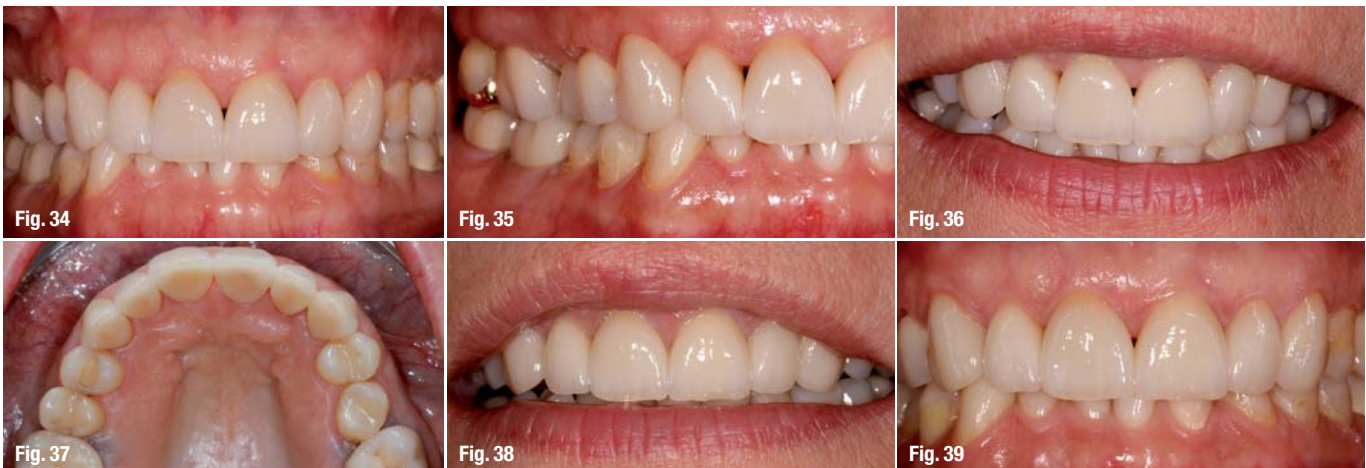
After taking the impressions using Aquasil Ultra (DENTSPLY; Fig. 9), the model work was performed (Figs. 10 & 11) and the IPS e.max copings were prepared (Fig. 12). For the pressing process, we used Vario Press 300.e (Zubler). The extremely short pressing time results in a very thin reaction layer. There is therefore no need to etch the item in hydrofluoric acid. The advantage is the perfect fit achieved because the thin margins of the copings are not rounded by etching (Fig. 13).

Afterwards, we applied layers of IPS e.max Ceram (Ivoclar Vivadent). The layering technique is not part of this article (Figs. 14 & 15). The shade and appearance of the tooth texture were copied from the mandibular anterior teeth (Fig. 16). For the first try-in, the crowns were in their final form and size (Figs. 17–19). The patient was more than satisfied with the result so far. We did not have to

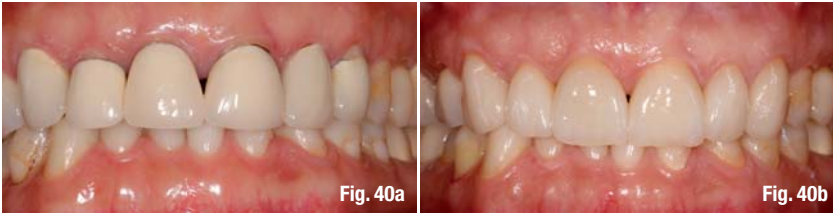
**Figs. 34–37**\_Final check-up one week after seating.

**Fig. 38**\_The situation five months after seating.

**Fig. 39**\_A small black triangle appeared between the central incisors when the saliva was blown away.





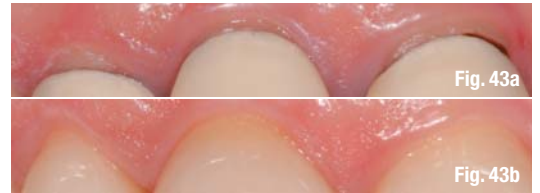

change anything. Even the colour was a perfect match (Fig. 20).

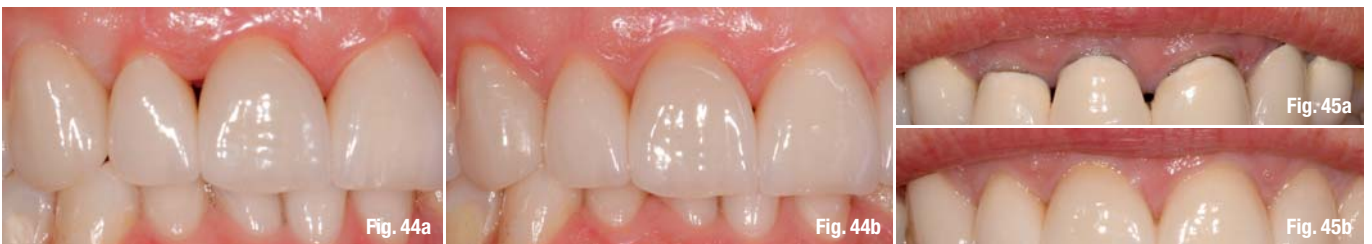Sufficient space was left in the approximal areas to allow the papillae to regenerate (Figs. 21–23). We dislike long areas of contact that make the teeth appear square. On the maxillary left side, the papillae were almost perfect at the try-in (Fig. 24).

After that, we adjusted the surface texture and performed the glaze firing using Glaze Paste FLUO (Ivoclar Vivadent). Finally, the crowns were polished by hand with a diamond paste to obtain the highest plaque resistance possible. For the finishing, photographs are a great help. Today, capturing photographs of the teeth should be common practice

Owing to the extraordinary translucency of the IPS e.max crowns, the roots receive the same amount of light that would pass through a natural tooth (Figs. 43a & b). The soft tissue is then lit up naturally and the grey gingiva is completely gone. Also, it is interesting how well the papillae are able to regenerate (Figs. 44a & b). It may even appear that the gingival margin on PFM crowns is moving by itself to escape the metal-ion infiltration. The appearance of the papillae was improved after the all-ceramic crowns had been seated (Figs. 45a & b).



**Fig. 40a & b** Close-up image pre- and post-treatment.  
**Fig. 41** The patient with the old PFM crowns before the treatment.  
**Fig. 42** The patient after restoration seating.



because, especially for a case like this, no patient has the time to sit in the laboratory for hours (Figs. 25–30).

About three weeks after preparation, the crowns were seated with Syntac and Tetric Flow in shade A2 (both Ivoclar Vivadent). Little black triangles were still visible between teeth 11 and 12, and 11 and 21 (Figs. 31–33). One week later, we performed the final fit (Figs. 34–37), and we rechecked the situation five months later (in October). The patient showed a grey-free smile with perfectly formed papillae in all approximal areas (Fig. 38). At a recent follow-up, a small black triangle appeared between the central incisors when the saliva was blown away (Fig. 39).

### \_Final result

Six months after the start of treatment, our patient was more than satisfied with the final result (Figs. 40–42). Her request for a healthy-looking gingiva and natural-looking crowns had been fulfilled. It is almost impossible to detect artificial dentition in her new smile, even for a dentist or dental technician.

Finally, it could be said that because of the drawbacks of PFM and even zirconia we should consider using true all-ceramic crowns for such cases.

### \_Reference

- 1 P. Magne & U. Belsler, Adhäsiv befestigte Keramikrestaurationen (Berlin: Quintessenz, 2002).

**cosmetic**  
dentistry

**\_contact**

**Jost P. Prestin, MDT**  
André di Mauro, DDS

Die Zahnärzte am alten Park  
Hegaustraße 3  
78315 Radolfzell  
Germany

prestin@dzaap.de  
www.dzaap.de  
www.jostprestin.com

**Figs. 43a & b** Close-up image of the gingival margin, showing the dark tooth necks due to blocked light (a), and the correct shade and translucency of the restorations (b). This result would not have been possible with zirconia crowns, for which subgingival preparation would have been required (no bleaching was involved).  
**Figs. 44a & b** Regeneration of the approximal papillae immediately (a) and five months after seating of the new restorations (b).  
**Figs. 45a & b** Gingiva before treatment (a) and five months after restoration (b).

# Ceramic and composite resin integration for custom smile design

**Authors**\_Prof. Rony Hidalgo, Prof. Rafael Barrantes, Dr Joanna Dávila, Paola Chinchay, Peru

It is widely accepted that in order to obtain highly aesthetic results, detailed treatment planning is mandatory in order to schedule the various stages of the restorative treatment to achieve the best possible outcome. Time too is a very important factor in terms of complying with dental principles concerning biology, function and aesthetics because of the need to wait for a favourable biological response, to test occlusal function and to achieve the biopsychosocial acceptance of the patient.

These dental principles have to be considered in close communication with the laboratory technician to treat each case using the ideal material

and fulfilling the expectations of the patient. The present case report demonstrates the importance of handling high-tech dental materials to achieve integration between dental aesthetics and nature.

In certain clinical situations, it is necessary to use dental ceramics and composite resins, whether due to specific indications, biologic reasons, budget, etc. The dentist nowadays must be able to achieve optimum aesthetics with appropriate handling of dental materials. One of the challenges in this regard is that there is no correlation in colour selection and brightness between ceramics and composite resins.

We understand that integration of a restorative material with the surrounding natural dentition must be an essential triad of individual aesthetics: form (surface and periphery), colour and brightness.

Creating an organised system of the entire range of ceramics, ceromer, and now direct restorative materials (in this case IPS Empress Direct, Ivoclar Vivadent) allow the latter to be compatible with the color of indirect restorative materials (ceromer and ceramics) or even be used in urgent situations for the repair of indirect restorations intra- or extra-orally.

Considering patients' demand for highly aesthetic results and that many clinical situations require adequate handling of ceramics and composites, it is evident that the integration of indirect and direct restorative dentistry is crucial, as is good communication with the laboratory technician, as well as good management of the clinical steps, in order to achieve the best possible

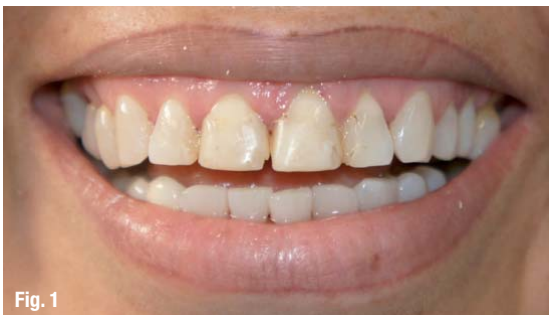

Fig. 1

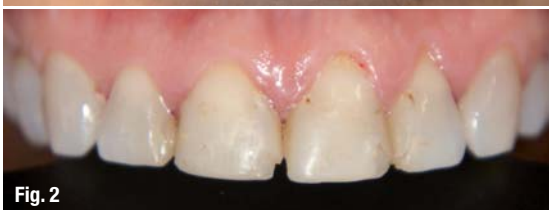

Fig. 2

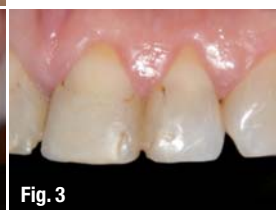

Fig. 3

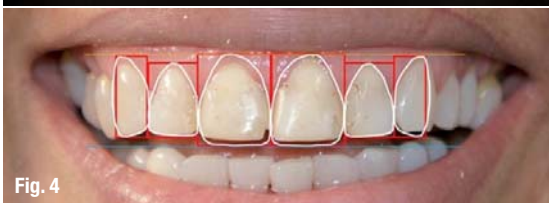

Fig. 4

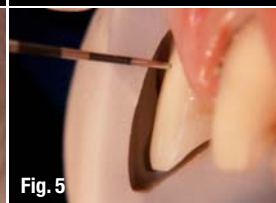

Fig. 5

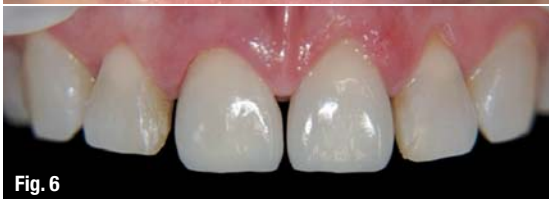

Fig. 6

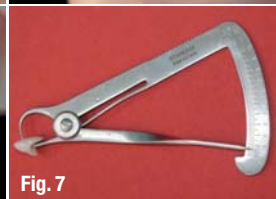

Fig. 7

results. The following case report is a clear example of this kind of management.

### Case report

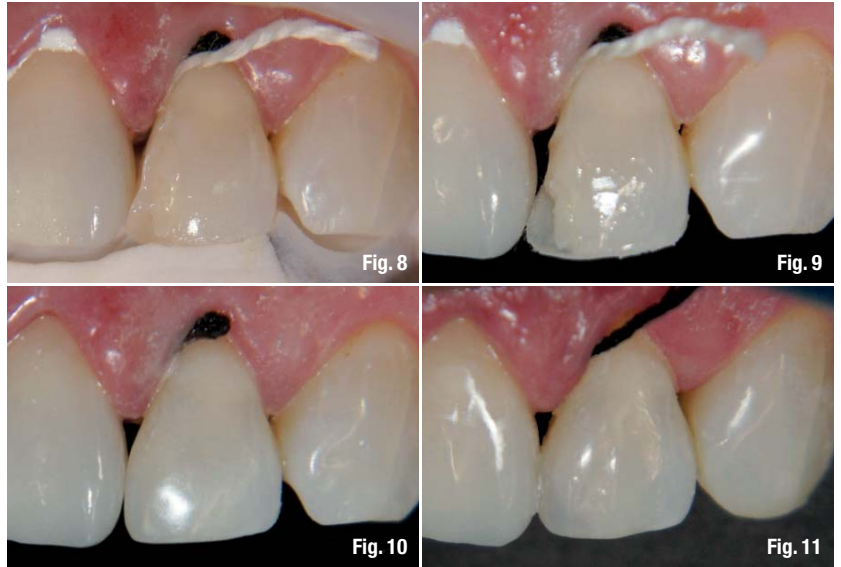
A female patient presented to the office wishing to improve the health and aesthetics of her maxillary anterior teeth, and had only 15 days in town before returning to her home country. She presented with several defective composite restorations in the maxillary incisors, a slight diastema between the central incisors, with excessive material at the mesial, distal and vestibular surfaces. The patient also wanted her teeth to be whiter. They were greyish, with significant opacity and saturation at the cervical area (Fig. 3).

The first appointment entailed determining the patient's expectations regarding her anterior teeth, making study models, capturing photographs (intra- and extra-orally, used for the digital smile design; Fig. 4), and performing a thorough prophylaxis accompanied by oral hygiene instruction.

At the second appointment, we restored the cervical non-carious lesions in the molars and premolars, restored occlusal equilibration to stabilise the occlusion, and noted the need to increment the cusps of the maxillary canines, which was originally planned in the digital design. The design was presented to the patient, but she did not like the size of the central incisors, desiring smaller ones. We took impressions, and manufactured models and duplicates of the models for fabricating the whitening trays, the digital design of the smile had to be customized. We saw that as in this case the mathematical proportions were not always pleasant to patients.

At the third appointment, the teeth were prepared using polyvinyl siloxane rigid patterns to perform as minimal tooth preparation as possible because the teeth were all vital. Use of IPS e.max Press (Ivoclar Vivadent) was indicated using high-translucency ingots in shade BL4 owing to the appropriate colour of the vital preparation of the central incisors, which showed a significant buccal flare (Fig. 5).

Based on the distal half of the natural lateral incisors, we chose to use shade 110 (Chromascop) to perform a cut-back and stratification with IPS e.max Ceram (Ivoclar Vivadent) following the marginal seal and try-in. We had to finish the tooth whitening while fabricating the full-coverage crowns. We took the final impressions and provisionalised with bis-acrylic temporary crowns.



At the fourth appointment, five days later, the whitening was almost complete, the ceramic copings of the pressed crowns were tried in, the marginal seal was verified, as were the primary anatomy details, and the application of in-office whitening was continued. Colour selection was performed again and this time we achieved a colour that was more transparent than 110. The teeth showed a definitive greyish aspect, which was very challenging to replicate. Working closely with the laboratory technician was crucial. His coming to the office to meet the patient to assess the details needed to mimic the natural dentition was decisive for the final outcome.

Following wash preparation cook, IPS e.max Ceram Glaze in shade A1 was applied to saturate the cervical area and lightly applied to the proximal surface. Then the deep dentinal mass structures were powdered with IPS e.max Ceram in shade A2. At the stratification, Deep Dentin shade A2 was used for the cervical area, shade 110 for the body, transparent blue for the incisal halo, and grey for the incisal edge. Transparent neutral was used to finish it owing to the low value of the teeth, which explains the greyish final aspect.

Five days after we had received the glazed crowns, the bleached teeth presented a different surface lustre, so it was necessary to touch up that aspect. We were able to both replicate the size the patient had in mind and satisfy the occlusal and anterior guide requirements; however, the diastema between the central incisors required that space be redistributed towards the mesial surfaces of the lateral incisors, where we needed to replace defective composite restorations (Fig. 6).

We proceeded with the resin composites in the lateral incisors and canines, all of which should free

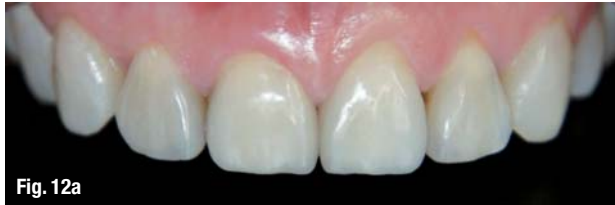

Fig. 12a

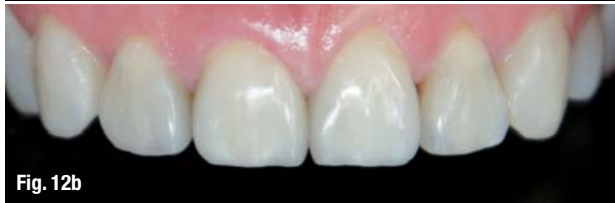

Fig. 12b



Fig. 13a



Fig. 13b

the occlusion during lateral excursions of the mandible. We had the advantage of postponing the cementation of the crowns until the composite resins had been completely finished, and the integration of colour and specific characteristics of the anatomy had been verified against the natural dentition of the patient, and copied in the crowns, with uniform thickness of 0.5–0.6 mm in the buccal and palatal aspects.

We used IPS Empress Direct to restore the lateral incisors and canines in the following sequence: shade A1E on the palatal surfaces, using the rigid silicone pattern obtained from the diagnostic wax-up, shades A2D and A1D in progressive transition, then Trans Opal for the grey halo effect, and shade A1E and Trans Opal for the final layer. At this session, preliminary finishing was performed with the Astrobrush and Politip polishing systems (both Ivoclar Vivadent). Final occlusion was achieved for all restorations, direct and indirect, and final photographs were taken and submitted to the laboratory technician to allow him to replicate the manual polishing and mimic the natural dentition.

The crowns were cemented with Multilink N in the Translucent shade (Ivoclar Vivadent) because the teeth were all vital and we did not want to perform an acid etch on the prepared dentine. Multilink N is self-etching and polymerisation occurs upon contact.

The final result was very natural looking: the customised bright and glazing integrated the IPS e.max Press restorations with IPS Empress Direct very naturally owing to their colour qualities. It was crucial to determine the precise thickness of the translucent mass to obtain the final translucent effect of both the IPS e.max Ceram and the natural dentition.

### Conclusion

Mimicking nature generally involves replicating specific details of the dentition, combining

conservative treatments such as teeth whitening with re-establishing a proper occlusal relationship, such as anterior occlusal guide, using direct and indirect restorative materials and using the least biologically invasive method possible.

Clinical integration of such restorative materials, requiring comprehensive knowledge of them and their systematisation, helps clinicians achieve homogenous and highly aesthetic results.

The importance of digital design is a preview of the final result, however, within the possibilities of smile design approach (mathematical and psychological), the most important thing is to meet aesthetic expectations of the patient.

It is accepted that nowadays aesthetic results depend on the dentist, his or her clinical skills and working technique, and on the experience of the laboratory technician, but achieving aesthetic results is facilitated by suitable dental materials, whose improved optical and mechanical properties match the aesthetic need, and adapting different working protocols to the various clinical situations.

The present clinical case exemplifies the optimum integration of IPS e.max Press, IPS e.max Ceram and IPS Empress Direct, fulfilling the patient's expectations in a short period.

### \_contact

cosmetic  
dentistry



**Prof. Rony Hidalgo**  
Alameda del Crepúsculo #195  
Alborada – Lima 33  
Peru  
esteticadentalperu@hotmail.com

2 0 1 3



# GREATER NEW YORK DENTAL MEETING

**SCIENTIFIC MEETING:**  
Friday, November 29 -  
Wednesday, December 4

**EXHIBIT DATES:**  
Sunday, December 1 -  
Wednesday, December 4

**NO PRE-REGISTRATION FEE**

**Attend At No Cost**  
Never a pre-registration fee at the  
Greater New York Dental Meeting

**Mark Your Calendar**  
Educational Programs:  
Friday through Wednesday,  
November 29 - December 4

**Exhibits:**  
Sunday through Wednesday,  
December 1 - December 4

**More than 600 Exhibitors**  
Jacob K. Javits Convention Center  
11th Avenue between 34-39th Streets (Manhattan)

**Headquarters Hotel**  
New York Marriott Marquis Hotel

**Live Dentistry Arena - No Tuition**

Latest Dental Technology & Scientific Advances

More Than 350 Scientific Programs  
Seminars, Hands-on Workshops, Essays & Scientific  
Poster Sessions as well as Specialty and Auxiliary  
Programs

Educational Programs in various languages

Social Programs for the Entire Family

**ENJOY NEW YORK CITY AT ITS BEST DURING THE  
MOST FESTIVE TIME OF THE YEAR!**

**The Largest Dental Meeting/Exhibition/  
Congress in the United States**

**89<sup>th</sup> ANNUAL SESSION**



For More Information:  
Greater New York Dental Meeting®  
570 Seventh Avenue - Suite 800, New York, NY 10018 USA  
Tel: (212) 398-6922 / Fax: (212) 398-6934  
E-mail: victoria@gnydm.com / Website: www.gnydm.com



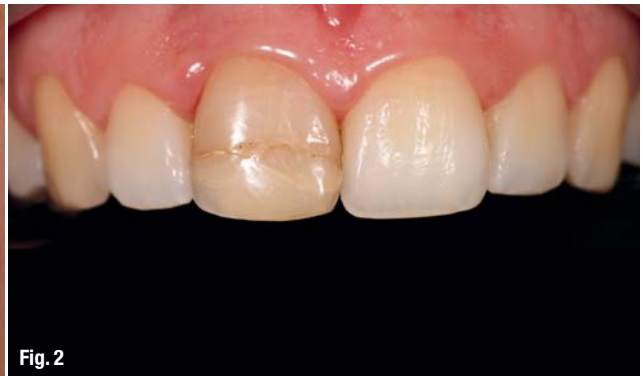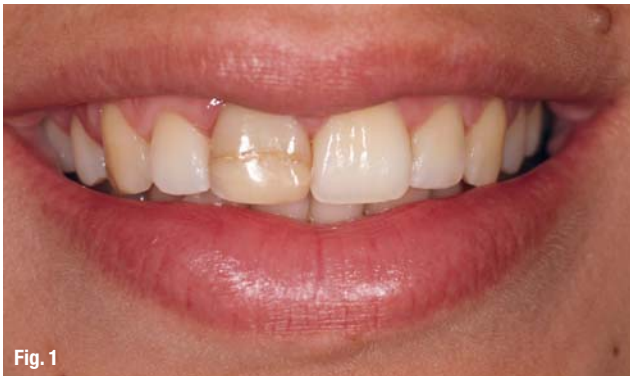**WWW.GNYDM.COM**

*Sponsored by: The New York County Dental Society and The Second District Dental Society*

# Extending the boundaries of feasibility in **direct restorative procedures**

## A clinical case combining a high-performance material and clearly defined protocol

Author\_Dr Gauthier Weisrock, France



**Fig. 1** \_Severely discoloured tooth#11.

**Fig. 2** \_The shape of tooth #11 appeared to be harmonious with tooth #21. The substance loss amounted to somewhat less than half of the tooth.

**Fig. 3** \_After the bleaching procedure, the shade of tooth #11 was optimal.

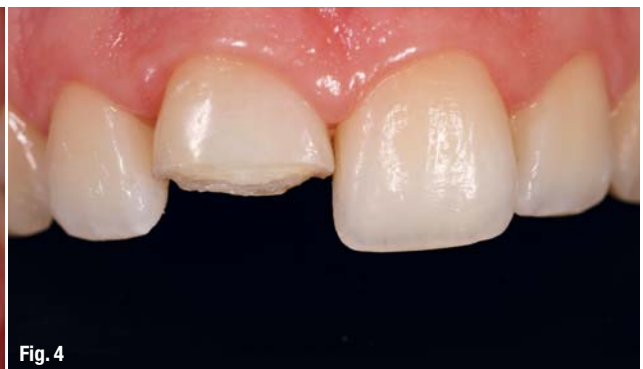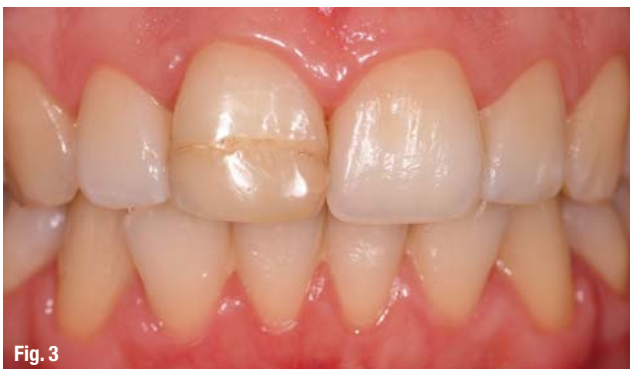**Fig. 4** \_Prepared tooth #11 with vestibular chamfer and straight, right-angle palatal margin.

\_Modern high-performance composite materials and standardised treatment protocols have led to more direct composite restorations being fabricated in the anterior region than ever. Even extremely challenging cases may now be treated chairside with predictable results and minimal loss of tooth structure.

A 24-year-old female patient presented at our practice with a request regarding aesthetics. She disliked the appearance of tooth #11, which showed

severe discoloration after endodontic treatment. A clinical examination revealed that the root had been extirpated after an accident and that a fractured piece had been reattached with a composite material (Figs. 1 & 2). Upon radiological examination, it was found that the root-canal treatment had been performed correctly. However, a post had not been used.

Owing to the fact that approximately half of the original tooth structure had been lost, we opted



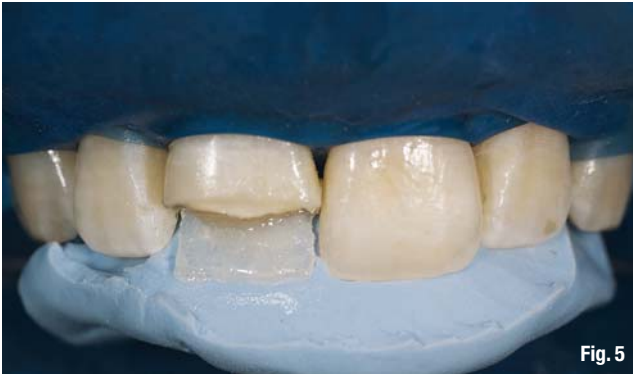

Fig. 5

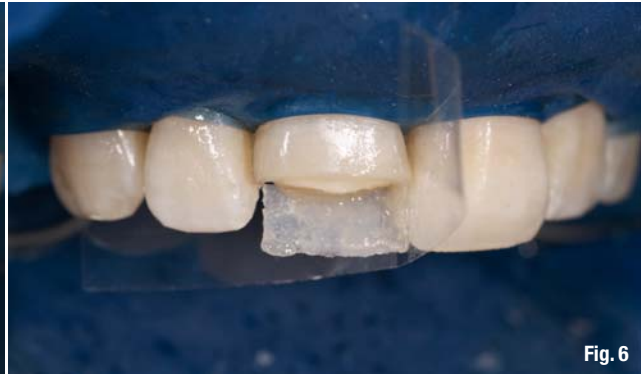

Fig. 6

for a direct composite restoration, provided that a tooth-whitening procedure could be successfully completed. Along the spectrum of possible treatments, this approach is located between "conventional" composite restoration and ceramic veneering and, therefore, appeared to be clinically appropriate.

The patient, whose primary concerns were a natural tooth shade and minimal loss of tooth structure, agreed to the recommended procedure. We decided to use the nano-hybrid composite IPS Empress Direct (Ivoclar Vivadent) to fabricate the restorations. In addition to dentine and enamel materials, this product is also available in an opalescent material version.

### Preliminary treatment

First, internal bleaching was performed on the tooth, on which the success of treatment would depend. Access to the endodontic chamber was created through the old restoration. The gutta-percha increment was removed up to 3 mm below the cemento-dentinal junction. At the bottom of the cavity, a plug with a thickness of 2 mm made of glass ionomer cement was inserted to prevent the bleaching agent from accessing the sensitive areas. We used a mixture of sodium perborate and distilled water for the bleaching procedure. The access to the cavity was then sealed with a temporary material.

Since the desired tooth shade was not achieved upon initial bleaching, the entire procedure had to be repeated after one week. After another week, the result was finally optimal (Fig. 3). In order to neutralise the bleaching agent, calcium hydroxide was placed into the cavity and left in place for at least one week. (An adhesive may only be applied 15 days after conclusion of the bleaching procedure, in order to ensure optimum adhesion and stable shade.)

### Aesthetic diagnosis and shade determination

After tooth-shape analysis, we concluded that the proportions were harmonious compared with tooth #21. In order to avoid a misinterpretation of the shade owing to dry adjacent teeth, the tooth shade was determined prior to any intervention and in daylight. The IPS Empress Direct shade guide was used for the determination of the enamel and dentine materials. We determined the dentine shade based on the cervical third and the enamel material based on the incisal third of the adjacent tooth. Particular attention was paid to the anatomical structure of the adjacent tooth and the various opalescent reflections visible on the incisal surface, since it was our aim to imitate these features.

A layering diagram detailing all the materials that we planned to use was prepared. In this case, only four shades were used: A3/A2 Dentine, A2 Enamel and Trans Opal.

**Fig. 5** Creating the palatal wall with enamel material (A2 Enamel).  
**Fig. 6** Designing the proximal area and the transition lines.

**Fig. 7** Building up the palatal and proximal areas, or transforming a complex preparation into a simple one.  
**Fig. 8** Application of dentine material in shade A3.

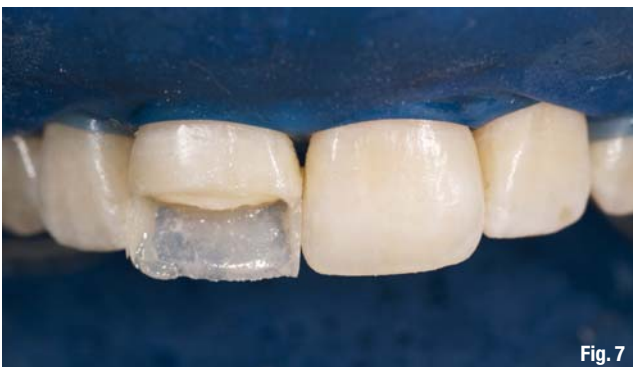

Fig. 7

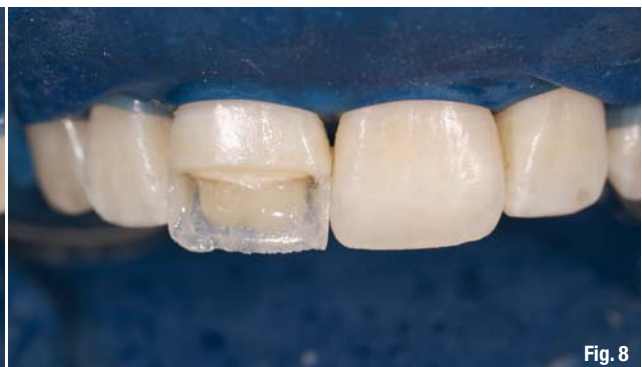
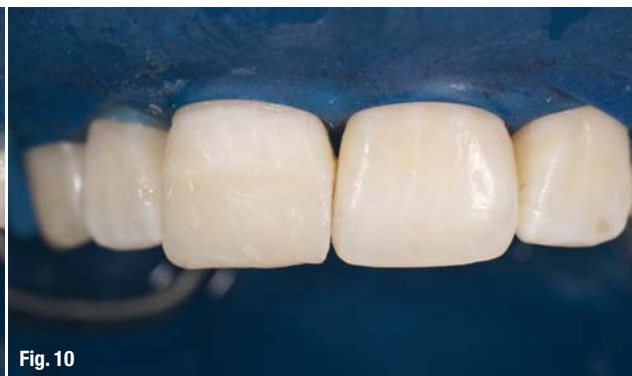
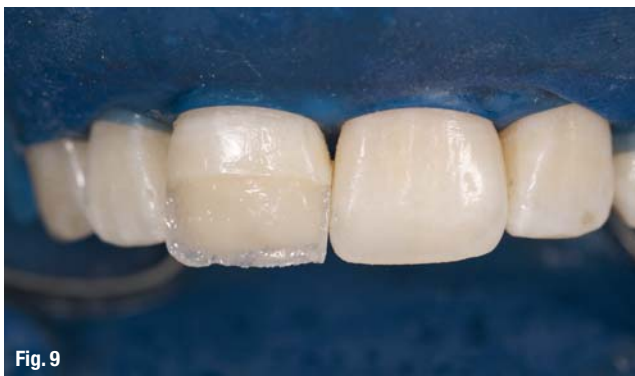Fig. 8



**Fig. 9** Application of dentine material in shade A2. The previous layer was entirely covered with this material.

**Fig. 10** Application of a covering layer of enamel material in shade A2.

Subsequently, we created a palatal silicone key on tooth # 11 with the appropriate shape and occlusion. Once in place intra-orally, this key helped to create the palatal wall of the restoration in one step. The key included the teeth adjacent to the tooth that needed to be restored and covered the incisal area.

### Preparation and application of the adhesive

The existing restoration was removed with the help of both rotary and ultrasonic instruments and with care to prevent any damage to the adjacent teeth. During the preparation of the tooth, the mechanical properties of the material used and the aesthetic integration needed to be taken into account. In the case of IPS Empress Direct, the ideal preparation design involved a vestibular chamfer and a straight, right-angle proximal and palatal margin (Fig. 4).

Before proceeding with the adhesive cementation, it was necessary to protect the operatory field from saliva or blood in the oral cavity. Therefore, we isolated the anterior teeth, including the canines, with a rubber dam. The expanded treatment area allowed us to assess the incisal line, and the size and shape of the adjacent teeth.

We checked whether the silicone key could be positioned exactly. (If required, interfering areas can be adjusted using a scalpel until a precise fit is achieved.) The enamel areas were etched for 30 seconds and the dentine for 15 seconds. Both were then thoroughly rinsed and dried.

Subsequently, the adhesive was applied, while the adjacent teeth were protected with a metal matrix. We used the ExcITE F total-etch adhesive (Ivoclar Vivadent) for this step. Owing to the non-retentive preparation design and the fact that most of the restoration would be created on enamel, this type of adhesive proved superior to self-etching products. In order to facilitate penetration into the dentine tubules, the adhesive was gently massaged

into the cavity walls. (After the adhesive has dried, the cavity must exhibit a glossy appearance. If this is not the case, the procedure needs to be repeated.)

The adhesive was then light-cured for 10 seconds with a bluephase curing light (Ivoclar Vivadent).

### Building up the palatal and proximal walls

As a first step, the palatal enamel was built up. A thin layer of enamel material (shade A2) of less than 0.5 mm was applied to the palatal key and smoothed out with a brush. Then the key loaded with composite material was placed in the mouth and the fit was checked again. If necessary, the material may be modified before it is polymerised for 10 seconds.

The palatal wall created in the process showed the exact desired shade and did not touch the adjacent teeth (Fig. 5).

Applying a thin layer of enamel material (A2) to the proximal walls changed the complex cavity into a simple one. In order to create the thin layer, we fixed a transparent matrix in place with a wooden wedge, which allowed us to create the transition lines (the convex area that separates the proximal from the vestibular area)—the restorative outcome is influenced by the successful design of these transitional areas because it is not possible to design them with rotary instruments. We then applied composite material from the distal side of tooth #11, while tightening the matrix from the opposite side and polymerising the material in this position (Fig. 6). Thus, sufficient composite material could be added until the desired transition area was achieved. The mesial side was built up in the same manner (Fig. 7).

### Building up the dentine core

Using dentine materials, a restoration is created that shows decreasing saturation from the cervical



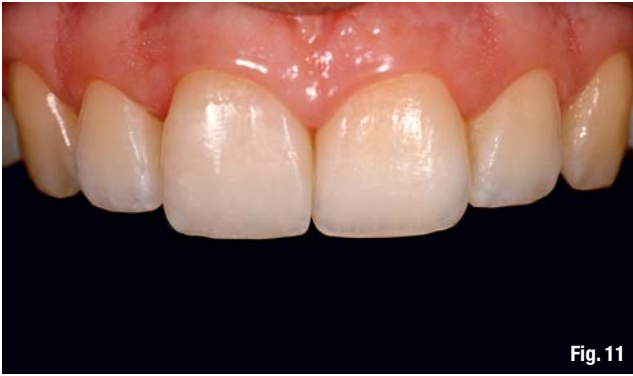

Fig. 11

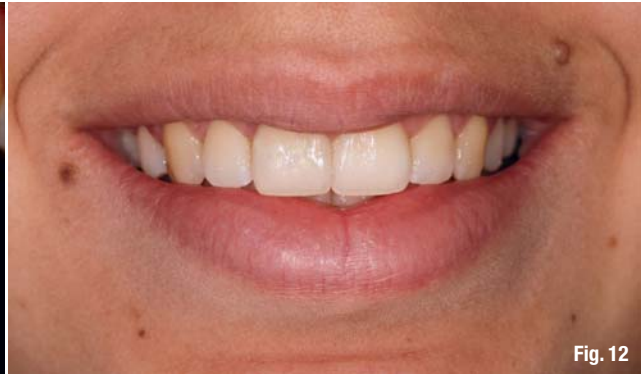

Fig. 12

to the incisal and from the palatal to the vestibular area. In order to achieve this, a 3-D layering technique is applied, using materials with different levels of saturation. In our case, a material with a saturation one degree higher than the desired final tooth shade was applied. Therefore, dentine material in shade A3 was used in the area of the cervical margin.

The layer was applied to the palatal wall using a flat spatula suitable for composite resins (Fig. 8). Subsequently, a layer consisting of dentine material with a lower saturation was applied (shade A2). A pointed silicone instrument was used to design a slightly wavy margin covering half of the chamfer up to 1 mm below the incisal edge (Fig. 9). (If this technique is applied, the translucency of the enamel material becomes visible in the area of the incisal edge and the transition from tooth structure to composite material is masked.)

Each layer was polymerised with the bluephase curing light for ten seconds.

### \_ Designing the enamel portion

The opalescence effect was enhanced by applying a thin layer of Trans Opal material in the area of the incisal edge. Since the visible effect of this material is very intense, only a small amount could be used. An enamel layer (shade A2) was applied in several steps to the vestibular area, then contoured with brushes and cured for ten seconds. This enamel material covered the entire restoration (Fig. 10).

### \_ Finishing and polishing

The patient's teeth exhibited a very pronounced macro- and microtexture (vertical pits and horizontal streaks, respectively). Imitating these features to achieve a lifelike reflection on the restorative surfaces was a challenging task.

This step was similarly important to determining the appropriate shade. We imitated the surface

texture with fine-grain diamond-coated burs, using flame- and lens-shaped instruments (first with the red and then with the yellow colour code). The burs were used in the red handpiece without water irrigation.

Another important step was the finishing of the transition lines and the interproximal areas. It is advisable to use abrasive strips for this purpose because rotary instruments may produce flat areas that cause inappropriate reflections. OptraPol Next Generation polishers (Ivoclar Vivadent) with water irrigation were used for the polishing process. We always take great care to polish restorations perfectly whilst avoiding any damage to the surface texture we design. The polishing was greatly facilitated as a result of the extraordinary polishability of this composite material (Figs. 11 & 12).

### \_ Conclusion

Owing to high-performance materials such as IPS Empress Direct, which are consistently improving, and a clearly defined approach, we may use direct restorations for more indications than ever before, thus constantly extending the boundaries of feasibility. The advantage of direct restoration procedures is that they are time saving and conservative. Nevertheless, it may happen that directly restored teeth show discolouration again in spite of the perfect aesthetic outcome. In this case, another treatment is inevitable.

**Figs. 11 & 12** The restored tooth #11 exhibits a harmonious appearance, achieved with a minimal loss of tooth structure.

### \_ about the author

**cosmetic**  
dentistry



#### **Dr Gauthier Weisrock**

is a dental surgeon from Marseille in France. He can be contacted at [gauthier.weisrock@gmail.com](mailto:gauthier.weisrock@gmail.com).

# The perimeter preparation

Author\_Dr Fay Goldstep, Canada




Fig. 1

**Fig. 1** The Fissurotomy bur (SS White) is designed to conservatively remove incipient decay in enamel.

The composite restoration is the basic foundation of the general dental practice. Countless composites are placed by dentists every day. Through the science of adhesive dentistry, these restorations can be conservative and provide long-term service. With time and function some breakdown may occur, usually at the margin of the restoration, the interface between the tooth structure and composite resin. In many cases, while the margin shows localised breakdown, the rest of the restoration remains intact. The dentist is then faced with the decision of replacing or repairing the restoration.

In the days before adhesive dentistry, when an amalgam margin began to break down, the entire restoration was soon compromised. There was no tooth–amalgam bond or seal to prevent the leakage and percolation of saliva, bacteria and bacterial products into the area under the amalgam and the adjacent tooth structure. This environment allowed bacteria to thrive, creating further breakdown and secondary caries.

**Fig. 2** Beautiful Flow Plus (SHOFU) combines the “healing” of giomer science with the handling and adaptability of flowable composites.

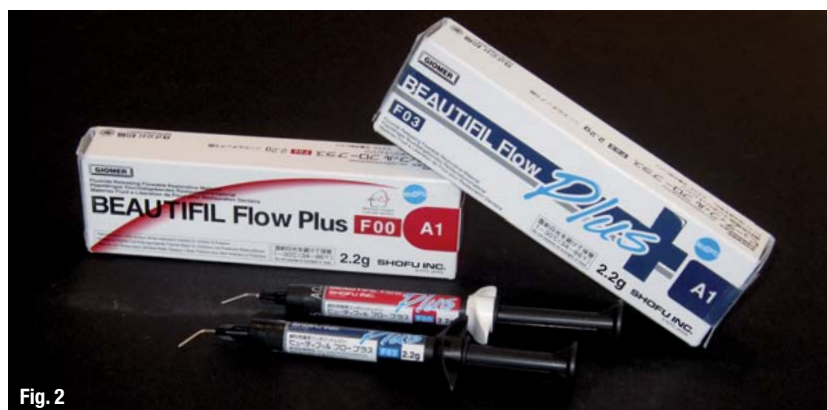

Fig. 2

With the advent of adhesive dentistry, leakage is no longer a major concern. Even in situations where the restorative margin has become defective, the bulk of the restoration is still sealed against bacterial challenge. It is, however, important not to leave these margins open over the long term. With time, there can be further marginal breakdown and secondary decay around the perimeter of the restoration. The dentist should not leave the restoration until it becomes unsalvageable and must be replaced entirely. With today’s technology and materials, there are tools to address the situation proactively at an early stage, before more extensive treatment becomes necessary. This approach is the perimeter preparation.

## The ultimate wish list

What tools are needed to repair and restore the defective margins of a composite resin restoration? First, there must be an excisional instrument (bur) that is conservative and minimally invasive. This bur should access marginal decay with minimal tooth removal. Second, the restorative material must flow easily into all the irregularities of the perimeter preparation. The typical preparation is very narrow. It may also be long and convoluted, following the defects at the margins of the restoration and the surrounding tooth. The dental material of choice is a flowable composite resin, which can easily penetrate the intricate geometry of the narrow preparation without bubbles or gaps. The ideal material should have strength and wear resistance to withstand all oral forces. It must be radiopaque to allow for monitoring of treated sites. Additional features to this ultimate wish list are plaque resistance and remineralising properties, to prevent future perimeter breakdown. The ultimate wish list is no longer dental science fiction. These tools, materials and techniques are available, as discussed below.

## Fissurotomy Bur

The Fissurotomy Bur system (SS White Burs) was developed to detect and remove incipient decay in enamel proactively (Fig. 1). The shape and size of the Fissurotomy Bur are designed specifically for treating early pit and fissure lesions. The head length is 2.5 mm, allowing the dentist to control the bur tip to cut just below the amelodentinal junction and

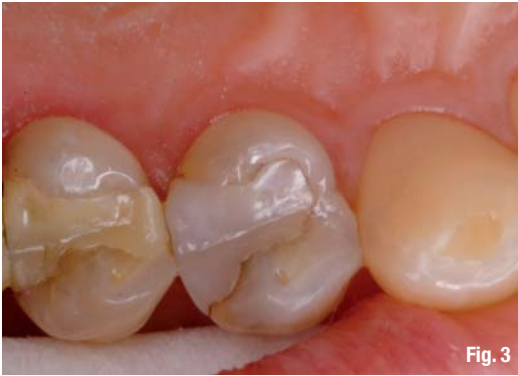

Fig. 3

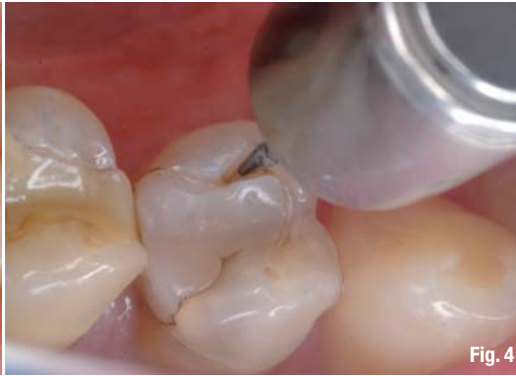

Fig. 4

**Fig. 3** The occlusal margins of a composite restoration have begun to break down.

**Fig. 4** A Fissurotomy bur (SS White) removes all decay and questionable tooth material.

no further. The tapered shape of the bur allows the cutting tip to encounter very few dentinal tubules, and to minimise heat build-up and vibration. This has the added advantage of decreasing patient discomfort and the need for local aesthetic. Traditional cutting burs remove far more enamel at any depth of cut and are far more invasive.

The Fissurotomy Bur is the ideal excisional tool for the perimeter preparation. It is conservative and minimally invasive. It can access decay with little tooth removal. The Fissurotomy Bur is the proactive tool for the repair of defective composite restoration margins.

### Giomers flowable restorative materials

Giomers (Beautifil II and Beautifil Flow Plus, both SHOFU) are the latest category of hybrid restorative materials. Giomer technology represents the true

integration of glass ionomers and composite resins with the benefits of both. Giomers provide the fluoride release and recharge of glass ionomers, and the aesthetics, physical properties and handling of composite resins.<sup>1</sup>

Studies have demonstrated that dentine remineralisation occurs at the preparation surface adjacent to the giomer.<sup>2</sup> Furthermore, giomer restorations take up the extra fluoride ions released by fluoride toothpastes, rinses and varnishes in oral fluids. The giomer restorations then function as reservoirs when fluoride is needed in the oral cavity.<sup>3,4</sup>

Giomers resist plaque formation owing to a film that forms on the restorative surface when it contacts saliva. This film consists of aluminium, silica, strontium and other ions that originate from the giomer fillers and act to inhibit bacterial adhesion.<sup>5</sup>

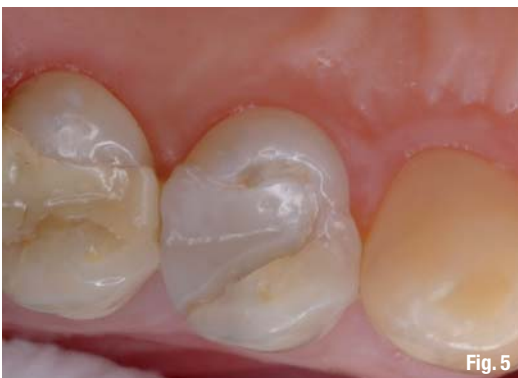

Fig. 5

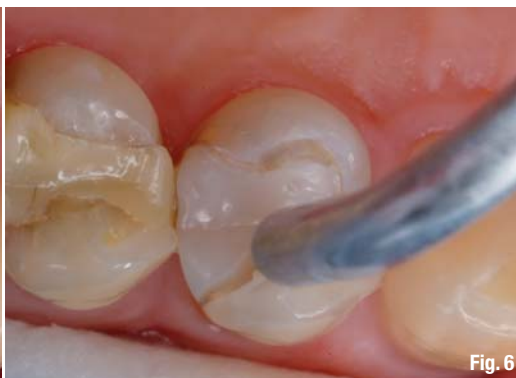

Fig. 6

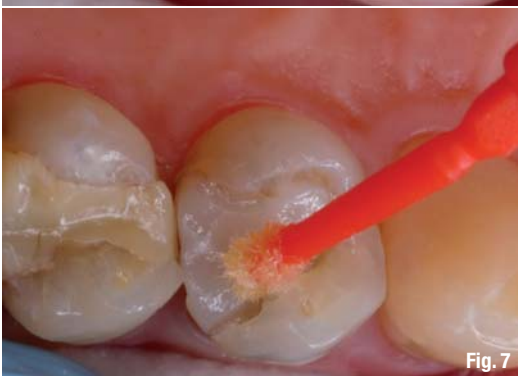

Fig. 7

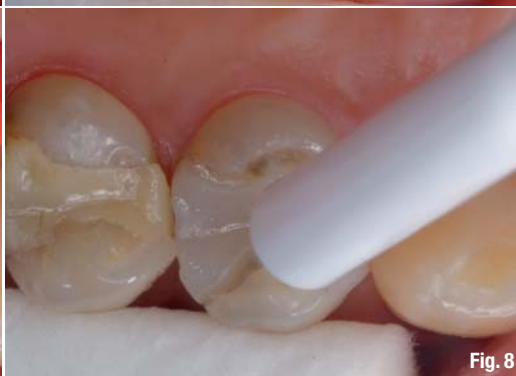

Fig. 8

**Fig. 5** The Perimeter Preparation is examined for any remaining decay.

**Fig. 6** Microabrasion is used to improve bondability of the preparation.

**Fig. 7** Beautibond (SHOFU) 7<sup>th</sup> generation adhesive is applied to the cavity preparation.

**Fig. 8** The adhesive is thoroughly air-dried.

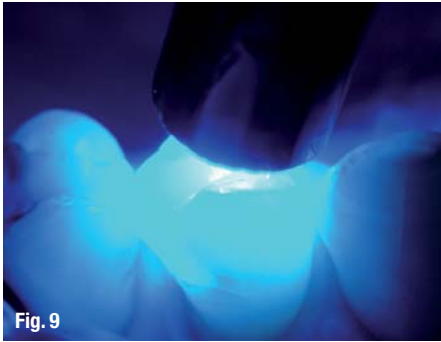


Fig. 9

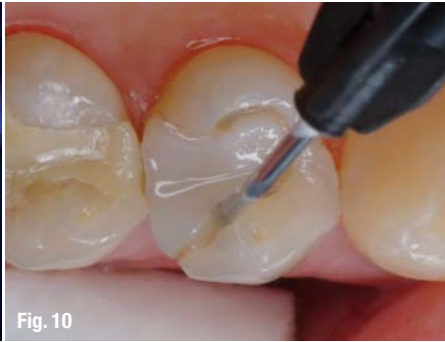

Fig. 10

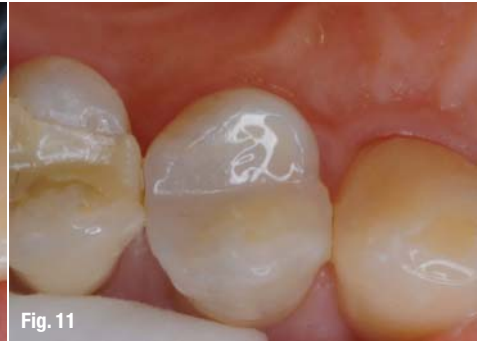

Fig. 11

**Fig. 9\_**The adhesive is light cured.

**Fig. 10\_** Beautifil Flow Plus (SHOFU) is placed in the Perimeter Preparation and light cured.

**Fig. 11\_** The completed Perimeter Restoration will now serve the patient effectively for many years.

A giomer flowable (Beautifil Flow Plus) has recently been introduced (Fig. 2). It combines all the healing advantages of giomer science with the ease of use, handling and adaptability of flowable composites. The physical performance (compressive strength, wear resistance, etc.) of Beautifil Flow Plus has been tested against leading hybrid composites and has been found to be equal or better. In addition, Beautifil Flow Plus is radiopaque.

Beautifil Flow Plus is the ideal restorative material for the perimeter preparation. It fulfils all the necessary criteria: a flowable composite resin that easily conforms to the intricate geometry of the narrow preparation without creating voids, has strength and wear resistance to withstand oral forces, is bacteriostatic and remineralising to prevent secondary caries, and is radiopaque. The tools and materials for the perimeter preparation are now readily available and so is the simple technique that can be incorporated into daily dental practice.

### **\_The perimeter preparation technique**

1. The occlusal margins of a composite restoration have begun to break down. There is no radiographic evidence that decay has spread far beyond the surface (Fig. 3).
2. All decay and questionable tooth material are removed with the Fissurotomy Bur (Fig. 4).
3. The perimeter preparation is examined for any remaining decay (Fig. 5).
4. Micro-abrasion can be used to increase the surface roughness and bondability of the preparation (Fig. 6).
5. Shofu BeautiBond the seventh-generation adhesive is applied to the cavity preparation (Fig. 7).
6. The adhesive is thoroughly air dried (Fig. 8).
7. A brief three to five seconds of LED light curing is all that is required for the adhesive (Fig. 9).
8. Beautifil Flow Plus is placed in the perimeter preparation and light cured (Fig. 10).

The completed perimeter preparation technique offers a restoration that will serve the patient effectively for many years (Fig. 11).

The perimeter preparation is an effective treatment option for proactive intervention dentistry. The dentist has the tools, materials and techniques to manage restorative marginal breakdown at an early stage, before more extensive treatment becomes necessary. This is simpler and more predictable for the dentist, as well as more comfortable and less invasive for the patient. \_

*Editorial note: A complete list of references is available from the publisher.*

### **\_about the author**

**cosmetic  
dentistry**



**Dr Fay Goldstep** (FACD, FADI, FADFE) has been an ADA Seminar Series Speaker, and has lectured at the ADA, Yankee, AACD, AGD, and the Big Apple dental conferences. She has lectured nationally and internationally on Proactive

Intervention Dentistry, Minimally Invasive Dentistry, soft tissue lasers, electronic caries detection and magnification. Dr. Goldstep has served on the teaching faculties of the Post-graduate Programs in Esthetic Dentistry at SUNY Buffalo, Universities of Florida (Gainesville), Minnesota (Minneapolis) and UMKC (Kansas City). Dr Goldstep sits on the Editorial Boards of Oral Health Magazine (Healing/Preventive Dentistry) and Dental Tribune (US Edition) as well as the Advisory Board of Dental Asia. She is a Fellow of the American College of Dentists, American Society for Dental Aesthetics, International Academy of Dental-Facial Esthetics and the Academy of Dentistry International. Dr Goldstep has been a contributing author to 4 textbooks and has published over 60 articles. She has been listed as one of the leaders in Continuing Education by Dentistry Today since 2002. Dr Goldstep is a consultant to a number of dental companies and maintains a private practice in Toronto, Canada. She can be contacted at [epdot@rogers.com](mailto:epdot@rogers.com).

# FDI 2013 Istanbul Annual World Dental Congress

28 to 31 August 2013 - Istanbul, Turkey

Bridging Continents for Global Oral Health



**2013 ISTANBUL**

[www.fdi2013istanbul.org](http://www.fdi2013istanbul.org)  
[congress@fdi2013istanbul.org](mailto:congress@fdi2013istanbul.org)

# Silane coupling agents and surface conditioning in dentistry

Authors\_Drs Christie Ying Kei Lung & Jukka Pekka Matinlinna, Hong Kong

In dental restorations, it is desirable to have durable and strong bonding between resin composite and dental restorative materials. Weak bonding at the interface can be dramatically enhanced with a coupling agent.

This review will discuss surface-conditioning methods and some new surface-conditioning techniques, silane chemistry, silane application in dentistry, and the limitations of silanes in adhesion promotion.

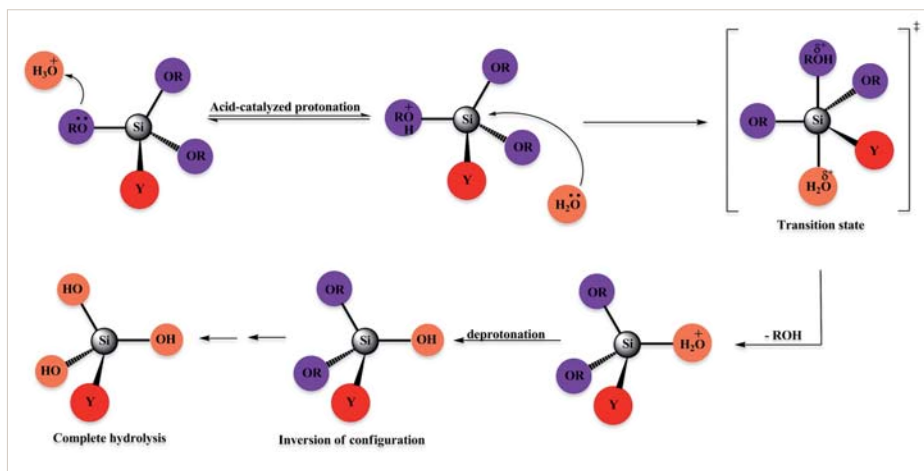


Fig. 1\_The silane hydrolysis mechanism.

Silane coupling agents, which are synthetic hybrid inorganic-organic compounds, are used to promote adhesion between dissimilar materials. They are good at promoting adhesion in silica-based materials such as porcelain. However, adhesion in non-silica-based restorative materials such as zirconia, metals and metal alloys is not satisfactory.

A solution to this problem may be surface conditioning of the restorative materials. Currently, a widely used surface-conditioning method in dentistry is tribochemical silica coating. After this treatment, a silica layer is formed on the surface so that the silane coupling agent can react chemically to form a durable bond with non-silica-based materials. Moreover, this treatment increases surface roughness, which will enhance micromechanical interlocking for bonding.

The silane monomer most commonly used in clinical commercial products is 3-methacryloxypropyltrimethoxysilane. This is pre-hydrolysed in a solvent mixture usually consisting of ethanol and water that is acidified with acetic acid.

The shelf life for a single-bottle silane solution is relatively short. The solution will turn cloudy over time and cannot be used for adhesion. Two-bottle silane systems have been developed to offer a more stable system. One bottle contains an unhydrolysed silane in ethanol and the other one contains an aqueous acetic acid solution.<sup>1</sup> The two solutions are mixed

for silane hydrolysis before use.

## Surface-conditioning methods

The surface conditioning of restorative materials is an important preliminary step in clinical practice to modify surface properties for durable and hydrolytically stable adhesion. The surface pretreatment methods widely used in dental technology are grit blasting, tribochemical silica coating and hydrofluoric acid etching, which will be discussed briefly in the following section.

### *Grit blasting*

The surface of materials such as metals, alloys and some ceramics is sand-blasted with alumina particles of 110 μm in size at a perpendicular dis-

tance of 10 mm under an air pressure of 380 kPa for ten to 15 seconds.<sup>2</sup> This process is intended to increase the surface roughness of the materials. It also enhances micromechanical retention for bonding.<sup>3</sup>

#### *Pyrochemical silica coating*

Over the years, several silica-coating systems have been used in dental laboratories. Briefly, they are Silicoater Classical, Silicoater MD and Siloc (all Heraeus Kulzer) and PyrosilPen (SURA Instruments).<sup>2</sup> In these systems, a tetraethoxysilane solution is injected into a flame and burned with butane in oxygen. The silane decomposes and forms reactive SiO<sub>x</sub>-C fragments, which are deposited on the substrate surface. A glass-like silica layer is thereby formed on the surface.<sup>4</sup> The use of this surface treatment is not popular in clinical practice.

#### *Tribochemical silica coating*

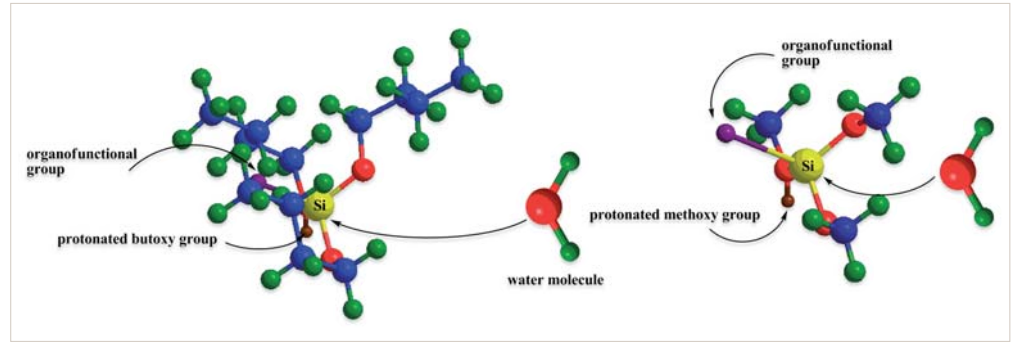
The tribochemical Rocatec system (3M ESPE) that uses silica-coated alumina particles was introduced in 1989. It is indicated for silica coating of ceramic and metal surfaces.<sup>5</sup> It enhances the adhesion of a silane coupling agent to a silica-coated material by forming a durable siloxane Si-O-Si bond. This surface treatment also increases the surface roughness that provides micromechanical retention for resin bonding, that is, for the resin to penetrate pores on the surface.<sup>6,7</sup>

#### *Hydrofluoric acid etching*

Hydrofluoric acid is normally used to etch porcelain veneers and for intra-oral repair of fractured porcelain restorations before cementation.<sup>1</sup> Low concentrations of 4 to 10 % hydrofluoric acid are used in clinical practice. When a porcelain surface is etched with hydrofluoric acid etching gel, the acid dissolves the glassy matrix of the porcelain. A microscopically porous and micro-retentive surface is thus produced and micromechanical interlocking for resin bonding is enhanced.<sup>9</sup>

### **\_New surface-conditioning methods**

The quest for enhanced and durable bonding continues. Several new surface-conditioning methods are currently under investigation globally. These include laser surface treatment<sup>9,10</sup>, selective infiltration etching<sup>11</sup>, nanostructured alumina coating<sup>12</sup>, internal coating<sup>14</sup>, chemical vapour deposition<sup>14</sup> and plasma fluorination.<sup>16</sup>



**Fig. 2** The steric effect of alkoxy groups on silane hydrolysis using ball-and-stick models between butoxysilane and methoxysilane.

#### *Laser surface treatment*

Laser stands for light amplification by stimulated emission of radiation and the technology was introduced in the 1950s. Er:YAG, Nd:YAG, and CO<sub>2</sub> lasers are used in dentistry for soft-tissue surgery and hard-tissue treatment and surface treatment.<sup>10</sup> Laser irradiation of a ceramic surface produces irregularities on the surface, which increase the surface roughness for mechanical retention.<sup>16</sup> The main problem, however, of this surface treatment method is the formation of surface cracks owing to thermal effects of laser irradiation at high power settings.<sup>10,16</sup> Therefore, appropriate laser settings for different ceramic surfaces is important to prevent formation of surface cracks.

#### *Selective infiltration etching*

In this method, a thin layer of a glass conditioning agent is coated onto the zirconia surface and is then heated to above the glass transition temperature. The molten glass particles may infiltrate between the surface grains. After this process, the specimens are allowed to cool at room temperature. The conditioning agent is then removed by applying hydrofluoric acid and rinsing it off. This creates a new retentive surface for resin-zirconia bonding.<sup>17</sup>

#### *Nanostructured alumina coating*

In this coating method, the zirconia is immersed in a suspension of aluminium nitride. Aluminium nitride undergoes hydrolysis to form boehmite, which is deposited onto the zirconia surface. A heat treatment at 900 °C is carried out. Boehmite undergoes a phase transition to  $\alpha$ -alumina. Through this treatment, a micro-retentive surface area is created that may increase mechanical interlocking for resin bonding.<sup>13</sup>

#### *Internal coating with porcelain*

The zirconia surface is sand-blasted with alumina particles of 70  $\mu$ m in size. Then, the surface is coated with high fusing porcelain, which is prepared by stirring the porcelain powder into an excess amount of distilled water. The porcelain is fired at

a high temperature in a vacuum. After the firing process, the surface is sand blasted again. A silica-containing layer forms on the zirconia surface. This enhances adhesion with a silane coupling agent, that is, siloxane linkage formation.<sup>14</sup>

#### *Chemical vapour deposition*

In a chemical vapour deposition system, the zirconia surface is exposed to a vapour mixture of tetrachlorosilane and water. The silane hydrolyses and a  $\text{SiO}_2$  seed layer is deposited as a coating on the surface. The thickness of the seed layer is controlled by deposition time. This silica seed layer provides the reactive sites for the silane coupling agent.<sup>15</sup>

#### *Plasma fluorination*

In a plasma reactor, the zirconia surface is exposed to sulphur hexafluoride plasma. An oxyfluoride layer is formed on the surface. This layer may increase the reactivity of zirconia towards a silane coupling agent. However, the exact mechanism of the bonding formation between the zirconium oxyfluoride layer with silane is still unclear.<sup>15</sup>

## Silane chemistry

#### *Functional and non-functional silanes*

Functional silanes contain two different functional groups that can react with inorganic matrices, for example ceramics, and organic materials, for example resins. Therefore, they can be used as coupling agents to connect dissimilar materials.

There is also a group of silanes called the non-functional silanes. They contain one reactive functional group that can react with inorganic materials. They are widely used for some specific surface modification of materials. In addition, there are bis-functional/cross-linking/dipodal silanes that possess two silicon atoms with three hydrolysable alkoxy groups. Cross-linking silanes are used in the steel and tyre industries.<sup>18</sup> Such silane is also incorporated with functional silane to increase the bonding and hydrolytic stability of resin composite to titanium.<sup>19</sup>

#### *Silane activation mechanism*

Silanes can create a bond between inorganic and organic materials. A general formula for a functional silane coupling agent is  $\text{Z}-(\text{CH}_2)_n-\text{Si}-(\text{OR})_3$ . Z is an organo-functional group that reacts with organic resin,  $(\text{CH}_2)_n$  is a linker group, and OR is an alkoxy group. The alkoxy groups are activated by hydrolysis ( $[\text{SiOR}] \rightarrow [\text{SiOH}]$ ) before they react with the surface hydroxyl groups of the substrate.<sup>20</sup>

The first step of silane hydrolysis is the fast and reversible protonation of the alkoxy group at a low pH (3–5). Next, a bimolecular nucleophilic substitution ( $\text{S}_{\text{N}}2$ ) reaction at the silicon atom takes place. A nucleophile, a water molecule, attacks backside to the silicon atom, an electrophile, to form a penta-coordinate transition state. A new bond is formed between the silicon and the nucleophile, and a bond is cleaved between the silicon and the leaving group, alcohol. This yields the product with an inversion of the configuration.<sup>21</sup> A suggested mechanism for silane hydrolysis is shown in Figure 1.

The silane hydrolysis rate depends on the steric (size) and inductive (electronic) effects of alkoxy groups on the silane. The steric effect is the dominant factor that affects the silane hydrolysis rate.<sup>22</sup> This effect is best illustrated using a ball-and-stick model (Fig. 2).

As shown in Figure 2, the steric repulsion increases when the size of the alkoxy group is changed from a methoxy to butoxy group. The approach of a water molecule, a nucleophile, to the silicon atom is more difficult for the bulky butoxy groups. This may explain why ethoxysilanes are employed in commercial dental products because of fast hydrolysis of small ethoxy groups. Methoxysilanes are not used, as the by-product methanol is very toxic.

The organo-functional groups of silane coupling agents consist of, for example,  $>\text{C}=\text{C}<$ , a vinyl double bond that can react with the functional groups of resin composite consisting of  $>\text{C}=\text{C}<$  bonds. The reaction is initiated by the initiators in the resin composite, which are decomposed by visible blue light to form free radicals. These free radicals react with the  $>\text{C}=\text{C}<$  bond in the resin composite monomer or in the silane molecule to generate another free radical species. The reaction of these free radicals with resin composite monomers and silane molecules forms new C–C single bonds. Therefore, the silane coupling agents connect the resin composite and the inorganic substrate surface.<sup>23</sup>

## Application of silanes in dentistry

#### *Ceramic restorations and repairs*

Silane coupling agents are used in dental restoration, such as ceramic repairs of onlays, inlays, crowns and bridges. For most patients, repair is more economical and time-saving than the fabrication of new restorations, unless damage due to a fracture is beyond repair. The clinical procedure for repairing ceramic restoration usually involves the following steps: roughening the surface with diamond burs, sand-blasting the surface, acid etching, silanisation and finally bonding to resin composite.<sup>24</sup>



### *Glass fibre-reinforced composites*

A relatively new group of dental biomaterials, the glass fibre-reinforced composites, is used in fixed partial dentures, removable prosthodontics, periodontal splints and retention splints.<sup>25</sup> The adhesion between the glass fibre and resin composite is improved by adding a silane coupling agent. The silane forms siloxane linkages with the surface hydroxyl groups of glass fibre. The organo-functional groups of silane react with the functional group in the resin composite. Thus, the bonding strength is increased between resin composite and glass fibre.<sup>27</sup>

### *Resin composite filling materials*

Nowadays, dental resin composites are composed of a resin matrix that contains monomers and cross-linking monomers, as well as a free-radical initiator, an inhibitor, colouring pigments, filler materials such as barium glass, silica, apatite and a silane coupling agent.<sup>27,28</sup> The latter enhances the bonding between the filler particles and the resin matrix.<sup>29</sup> The filler particles added to the resin matrix also improve the physical and mechanical properties of the resin composite. Moreover, the addition of fillers reduces volume shrinkage after polymerisation, and improves the aesthetic appearance and radiopacity.<sup>30</sup>

### *Titanium, noble metal and base metal alloys*

Titanium, noble metals and cobalt-chromium (base metal) alloys are commonly used for removable partial and complete dentures with a metal frame incorporated and metal-resin cement restorations.<sup>31,32</sup> For these metal and metal alloys, surface conditioning by sand-blasting using silica-coated alumina particles produces a silica-coated layer on the surface. Application of a silane coupling agent to the silica-coated surfaces forms a durable siloxane linkage. This is followed by cementation.

## **\_ Limitations of silanes as adhesion promoters**

Silanes are good at promoting adhesion between resin composites and dental restorative materials but there are some limitations to silane coupling agents.

The adhesion of silane coupling agents and non-silica-based restorative materials such as alumina, zirconia or metals is weaker than the silica coating of these materials.<sup>33,34</sup> Therefore, a surface pretreatment with silica coating is required so that durable bonds (siloxane bonds) are formed between silane and silica-coated restorative materials. For noble metals or noble metal alloys, thione or thiol-based coupling agents are used to promote adhesion.<sup>35</sup>

These coupling agents have different bonding mechanisms with various dental restorative materials.

## **\_ Current trends and future development of coupling agents in dentistry**

Nowadays, other coupling agents (such as phosphate ester) are added to self-adhesive resin cements and adhesive primers, metal and alloy primers, and carboxylic acid primers used in dental restoration.<sup>36,37</sup> Phosphate esters can bond directly to non-silica-based ceramics such as zirconia.<sup>38</sup> It has been reported that using this phosphate ester can enhance the hydrolytic stability of bonding more than using silane coupling agents can.<sup>39</sup>

The main problem of resin composites bonded to silica-coated restorative materials with the application of commercial silane coupling agents is the bond degradation over time under artificial ageing.<sup>40,41</sup> In order to increase the hydrolytic stability of the bonding at the interfacial layer, novel surface treatments of restorative materials and the design of novel silane monomers can solve this problem. Silane coupling agents with long hydrocarbon chains are more hydrophobic than those with short hydrocarbon chains. The bonding at the interfacial layer is more resistance to water ageing. These two approaches could resolve the problem.

It could be said that silane coupling agents can fulfil the clinical requirements for dental restorations. Nowadays, a standard laboratory protocol for dental restorations entails surface conditioning of dental materials, silanisation and cementation. The problem of hydrolytic stability of the siloxane linkage formed from silane coupling agents with resin composites and dental restorative materials is currently being addressed. It is not an exaggeration to claim that silane coupling agents have wide application in industry, dentistry and medicine and will play an important role in biomaterials science.

*This review is based on the article "Aspects of silane coupling agents and surface conditioning in dentistry: An overview", Dental Materials, 28 (2012): 467-77. A complete list of references is available from the publisher.*

### **\_ about the author**

**cosmetic**  
dentistry



#### **Dr Christie Lung Ying Kei**

is a postdoctoral fellow in Dental Materials Science at the Faculty of Dentistry at the University of Hong Kong. He can be contacted at [cyklung@hku.hk](mailto:cyklung@hku.hk).

# A biological approach to implantology

An interview with Dr Eduardo Anitua, Scientific Director of the BTI Biotechnology Institute and owner of an ultra-modern training centre and private practice in Vitoria, Spain

Author\_Magda Wojtkiewicz



Dr. Eduardo Anitua.  
(Photos courtesy of  
BTI Biotechnology Institute S.L.)

*Magda Wojtkiewicz: Reconstruction of the atrophic maxilla presents unique challenges and often requires major surgical intervention, however you are known for treating atrophic maxilla with minimally invasive clinical techniques using plasma rich in growth factors. Could you please explain the main points of your surgical protocols to our readers?*

**Dr Eduardo Anitua:** The aim of our technique is to be able to offer specific, customised solutions to every situation in the treatment of atrophic maxilla without having to resort to much more-invasive and less-predictable surgery techniques, regardless of whether the resorption is transverse or vertical.

In this regard, for cases of transverse atrophy, BTI has developed Tiny implants and transitional expanders, which are the ideal solution both for inserting narrow implants when there is no other option and for gaining the bone substrate volume required for placing definitive implants.

To treat vertical atrophy, BTI recommends short and extra short implants for cases with insufficient bone substrate in both the superior maxilla, avoiding elevation of the sinus, and the inferior maxilla, when the distance to the dental nerve is not sufficient.

*What qualifications are needed to perform such procedures? Are they performed only by specialists or GPs as well?*

BTI offers specialised courses in atrophic maxilla treatment. This programme on advanced techniques is aimed at two types of professionals: specialists with experience in implantology and specialists with no experience in implantology. Regarding the first group, the advanced course refreshes their knowledge of minimally invasive techniques. Specialists with no experience in implantology (but with a knowledge of oral implantology—editorial note) can benefit from this advanced



BTI Training centre,  
Tuition Classroom.

training because it is designed to be a continuation of the intensive five-day course that aids professionals in developing their knowledge of oral implantology, from the most basic level to the most advanced surgical techniques.

*Is it possible to obtain these qualifications at your training centre?*

Of course, with a course combining theory and practical work, the professional may learn the latest techniques for the treatment of large-scale atrophy from a biological perspective.

*Please could you explain the course briefly. You mentioned that it includes both theory and practice.*

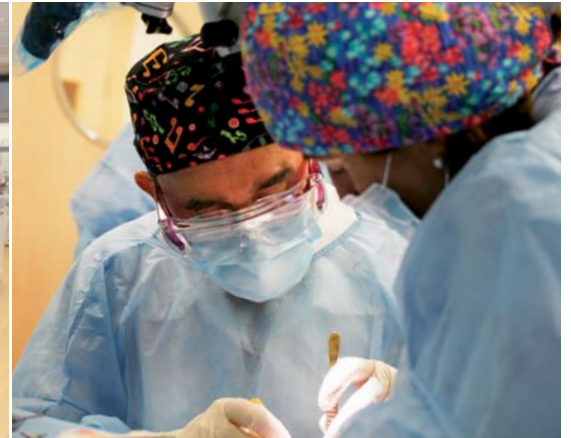This training course, like our other courses, is taught with a biological focus, showing how the development of less-invasive techniques is slowly going to replace those traditionally well established, and concentrates on treatment from a prosthodontic-surgical point of view as opposed to a surgical-prosthodontic one. This type of minimally invasive treatment results in a significant improvement in the patient's overall quality of life owing to the speed of recovery and excellent aesthetic finish. And, of course, the programme includes plenty of practical work.

*Apart from the atrophic maxilla courses, what is the educational offering at the BTI's postgraduate and training centre?*

Training is one of the basic pillars of BTI and for this reason we devote many of our resources to it, which allows us to offer multidisciplinary training to the entire clinical team with the aim of reinforcing and refreshing the knowledge of professionals in different areas of medicine.

BTI offers a wide range of courses and colloquia, made up of ongoing training programmes, specialised courses, internships, expertise sessions and classes, among others. In addition, our training is international, as it is also offered in the other countries where we are represented, such as Italy, Germany, the UK, Portugal, the US and Mexico, thanks to collaboration with the most prominent universities in these countries.

We already have 25 years of experience in training, having developed the first postgraduate course in the area of oral implantology in Spain.



One of the topics most in demand over the last two years has been training in PRGF-Endoret technology, both in the area of oral surgery and in other specialisations, which is a significant part of our training.

The main objective is to be close to professionals, helping them to achieve excellence in their daily practice, which has a direct influence on the well-being and health of patients.

*What is BTI's philosophy?*

BTI has been engaged in ongoing research and development activities for more than 15 years, and it is necessary to disseminate the knowledge gained. Therefore, in addition to publishing scientific articles in the most prestigious international journals and participating in the main scientific forums and conferences, we share the knowledge gained with professionals through training, helping them to achieve excellence in their daily practice, which has a direct influence on the well-being and health of patients.

The centre has an area exclusively dedicated to scientific research and innovation, a clinical floor and another for training and scientific dissemination. Using the synergies between these areas and having equipped the training and postgraduate centre with the most-advanced medical and audiovisual technology, it has become a European leader in this field. However, this achievement would not have been possible without our excellent multidisciplinary team of professionals with extensive clinical and teaching experience.

But, more importantly, it is the patients who are the focus of our commitment to innovation and the reason for our ongoing motivation. For BTI, people continue to be the origin of science and our *raison d'être*.

*Thank you very much for this interview.*

**Left** R & D Lab of BTI Biotechnology Institute.  
**Right** Dr. Eduardo Anitua at operating theatre.

# Concepts in implant therapy discussed

Osteology Foundation celebrates anniversary meeting in Monaco



All photos courtesy of Osteology Foundation, Switzerland.

**\_Immediate implantation in combination** with biomaterials can effectively prevent bone resorption after tooth extraction. This was one of the key findings presented at the tenth International Osteology Symposium in the principality of Monaco last month.

Well-known periodontologist Prof. Jan Lindhe from Sweden told event participants in a keynote


lecture that although bone resorption in the mesiodistal dimension can be prevented through immediate implant placement pre-clinical studies have shown that ridge preservation procedures with biomaterials are usually required to preserve the buccopalatal dimension too, a discovery also confirmed by fellow presenter Dr Dietmar Weng from Germany.

Presentations on other important aspects of dental implant therapy included soft-tissue management and peri-implantitis, the frequency of which, according to presenter Björn Klinge from the

Department of Dental Medicine at the Karolinska Institutet in Stockholm, Sweden, remains difficult to assess owing to contradictory scientific data and differences regarding its definition. While the prevalence of the condition itself remains a matter of debate, there was general agreement that primary contributing factors include inadequate bone volume, as well as the distance between and the position of the implants.



In addition, new clinical evidence was presented that supports the assumption that sufficiently keratinised mucosa around implants can prevent peri-implantitis. Biomaterials offer significant advantages over connective tissue grafts or free gingival grafts in this regard because their use has demonstrated greater patient satisfaction owing to the reduction in operating time and post-operative pain, according to US periodontist Todd Scheyer.



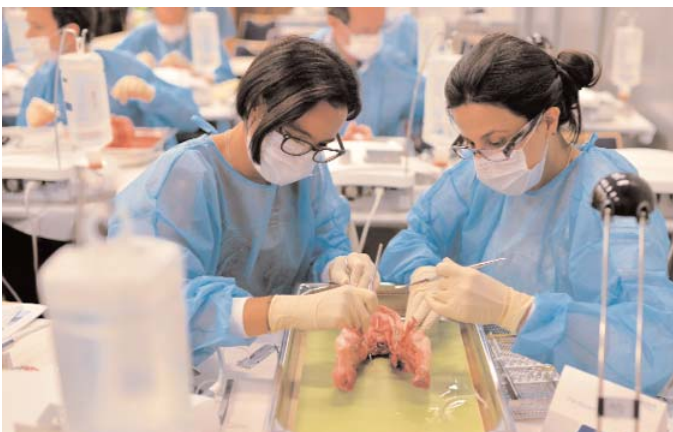This year was the second time that the Osteology Foundation held its scientific symposium in Monaco. Established through a partnership between Dr Peter Geistlich, founder and former CEO of the company with the same name, Dr Philip Boyne from the Loma Linda University and Harvard professor Myron Spector a decade ago, the foundation based in Switzerland has become a leading platform for research on regenerative therapies for oral tissue.

Since 2003, it has spent CHF0.5 million annually for funding scientific studies on the topics of regenerative dentistry and dental-tissue engineering, according to its figures, among them a recent paper by a clinical team from the Faculty of Dentistry at the Complutense University of Madrid that evaluated

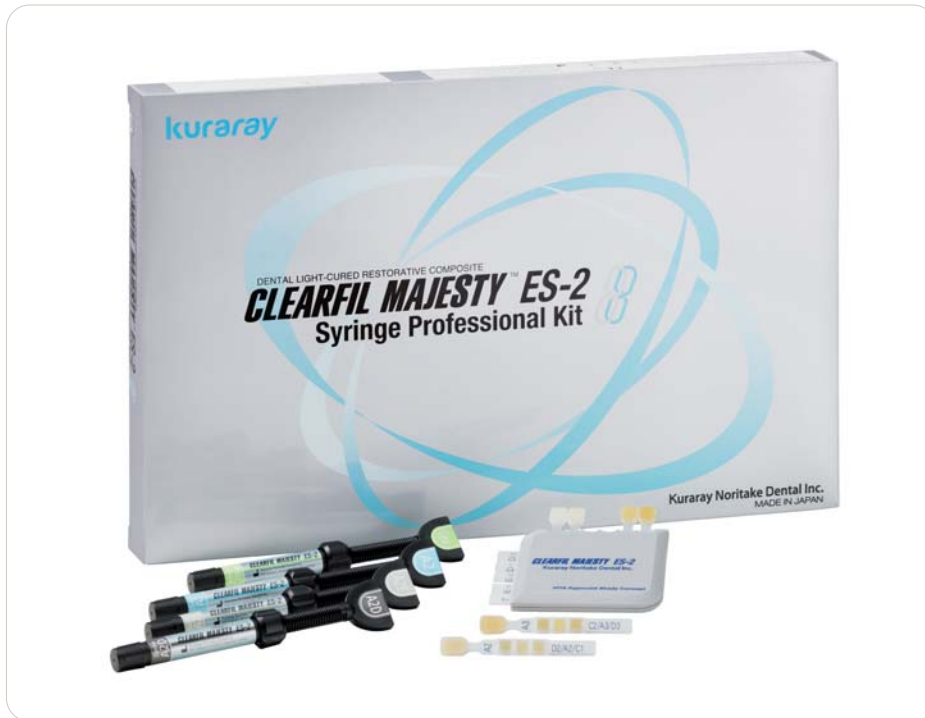a novel flapless technique for cleft-palate repair by injection of a BMP-2-containing hydrogel.

Overall, more than 40 studies conducted by researchers around the world have been financially supported this way over the last ten years, the foundation said. This year's Osteology Research Prize was awarded to clinicians from Spain and Italy.

It also holds regular scientific symposia to educate practitioners on the subject of regenerative dentistry. This year's edition drew 2,700 participants to Monaco. Besides 60 scientific presentations, the event offered pre-congress hands-on workshops, a research forum, a poster exhibition and an industry showcase. The next edition is to be held in 2016.



# CLEARFIL MAJESTY ES-2— The new universal composite



Also, layering difficulties are an issue of the past. Only nature's enamel and dentin layers need to be copied with a Premium enamel and dentin shade. When time is limited, a one layer Classic shade may be chosen. To create the perfect adaption to the tooth, the company further optimized the paste consistency. This gives the dentist great confidence during layering and leads to a remarkable blending effect. The new credo is: "Do what you love to do and create beautiful restorations."

Kuraray Noritake's new composite concept is based on revealing novelties. The dentist is able to cover three VITA classical shades with

With the new universal composite CLEARFIL MAJESTY ES-2, which was presented at the IDS 2013, Kuraray Europe is introducing a universal composite that sets new standards.

During the complete re-engineering of the product over the last seven years, the goal was to develop a composite that makes restorations more beautiful, more predictable and longer lasting. The result of Kuraray Noritake's effort was to create the first composite concept with an amazing blending effect with the natural tooth. But not only the restorative results, also the work flow was positively affected.

With CLEARFIL MAJESTY ES-2, Kuraray Noritake has developed a composite concept that makes the work process surprisingly intuitive, and the results simply impressive. The dentist may start immediately without having to pay attention to difficult colour schemes or complicated instructions. Choosing the right colour has never been more intuitive and precise at the same time. The dentist just picks a VITA approved colour and starts designing nature.

only one Premium shade combination. Now astounding results can be created with less shades. According to the company and dentists involved in testing the product, any visible enamel-composite border simply vanishes. With the components of CLEARFIL MAJESTY ES-2 (one-layer Classic shades, multi-layer Premium shades and the new supportive shade guide) almost any restorative case may be covered in daily practice.

## \_contact

cosmetic  
dentistry

### Kuraray Europe GmbH

BU Medical Products  
Philipp-Reis-Str. 4  
65795 Hattersheim am Main  
Germany

Tel.: +49 69 305 35833

dental@kuraray.eu  
www.kuraray-dental.eu



The congress will be held at the spectacular Palazzo della Gran Guardia\*

ESTHETICS  
MEETS  
AESTHETICS



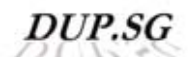# VERONA

ITALY • May 31- June 1, 2013

\*Venue subject to change

save the date

In Cooperation With



# International Events

## 2013

### Esthetic Dentistry & Periodontics Main Conference

1–5 July 2013  
Hawaii, USA  
[www.uclahawaii.com](http://www.uclahawaii.com)

### IACA 2012

1–3 August 2013  
Calgary, AB, Canada  
[www.theiaca.com](http://www.theiaca.com)

### AAED Annual Meeting

7–10 August 2013  
Washington, USA  
[www.estheticacademy.org](http://www.estheticacademy.org)

### FDI Annual World Dental Congress

28–31 August 2013  
Istanbul, Turkey  
[www.fdiworldental.org](http://www.fdiworldental.org)

### IFED 8<sup>th</sup> World Congress

18–21 September 2013  
Munich, Germany  
[www.ifed-2013.com](http://www.ifed-2013.com)

### ESCD annual meeting

3–5 October 2013  
Turin, Italy  
[www.escdonline.eu](http://www.escdonline.eu)

### 2<sup>nd</sup> Asia–Pacific Edition 9<sup>th</sup> CAD/CAM & Digital Dentistry International Conference

5 & 6 October 2013  
Singapore  
[www.cappmea.com](http://www.cappmea.com)

### EAO 2013

16–19 October 2013  
Dublin, Ireland  
[www.eao.org](http://www.eao.org)

### BACD Annual Conference

7–9 November 2013  
London, UK  
[www.bacd.com](http://www.bacd.com)

### 5<sup>th</sup> Dental–Facial Cosmetic International Conference

8–9 November 2013  
Dubai, UAE  
[www.cappmea.com/aesthetic2013](http://www.cappmea.com/aesthetic2013)

### ADF Annual Dental Meeting

26–30 November 2013  
Paris, France  
[www.adf.asso.fr](http://www.adf.asso.fr)

### Greater New York Dental Meeting

29 November–4 December 2013  
New York, USA  
[www.gnydm.com](http://www.gnydm.com)



Hawaii. Photo: tomas del amo



## submission guidelines:

Please note that all the textual components of your submission must be combined into one MS Word document. Please do not submit multiple files for each of these items:

- \_ the complete article;
- \_ all the image (tables, charts, photographs, etc.) captions;
- \_ the complete list of sources consulted; and
- \_ the author or contact information (biographical sketch, mailing address, e-mail address, etc.).

In addition, images must not be embedded into the MS Word document. All images must be submitted separately, and details about such submission follow below under image requirements.

### Text length

Article lengths can vary greatly—from 1,500 to 5,500 words—depending on the subject matter. Our approach is that if you need more or less words to do the topic justice, then please make the article as long or as short as necessary.

We can run an unusually long article in multiple parts, but this usually entails a topic for which each part can stand alone because it contains so much information.

In short, we do not want to limit you in terms of article length, so please use the word count above as a general guideline and if you have specific questions, please do not hesitate to contact us.

### Text formatting

We also ask that you forego any special formatting beyond the use of italics and boldface. If you would like to emphasise certain words within the text, please only use italics (do not use underlining or a larger font size). Boldface is reserved for article headers. Please do not use underlining.

Please use single spacing and make sure that the text is left justified. Please do not centre text on the page. Do not indent paragraphs, rather place a blank line between paragraphs. Please do not add tab stops.

Should you require a special layout, please let the word processing programme you are using help you do this formatting automatically. Similarly, should you need to make a list, or add footnotes or endnotes, please let the word processing programme do it for you automatically. There are menus in every programme that will enable you to do so. The fact is that no matter how carefully done, errors can creep in when you try to number footnotes yourself.

Any formatting contrary to stated above will require us to remove such formatting before layout, which is very time-consuming. Please consider this when formatting your document.

### Image requirements

Please number images consecutively throughout the article by using a new number for each image. If it is imperative that certain images are grouped together, then use lowercase letters to designate these in a group (for example, 2a, 2b, 2c).

Please place image references in your article wherever they are appropriate, whether in the middle or at the end of a sentence. If you do not directly refer to the image, place the reference at the end of the sentence to which it relates enclosed within brackets and before the period.

In addition, please note:

- \_ We require images in TIF or JPEG format.
- \_ These images must be no smaller than 6x6 cm in size at 300 DPI.
- \_ These image files must be no smaller than 80 KB in size (or they will print the size of a postage stamp!).

Larger image files are always better, and those approximately the size of 1 MB are best. Thus, do not size large image files down to meet our requirements but send us the largest files available. (The larger the starting image is in terms of bytes, the more leeway the designer has for resizing the image in order to fill up more space should there be room available.)

Also, please remember that images must not be embedded into the body of the article submitted. Images must be submitted separately to the textual submission.

You may submit images via e-mail, via our FTP server or post a CD containing your images directly to us (please contact us for the mailing address, as this will depend upon the country from which you will be mailing).

Please also send us a head shot of yourself that is in accordance with the requirements stated above so that it can be printed with your article.

### Abstracts

An abstract of your article is not required.

### Author or contact information

The author's contact information and a head shot of the author are included at the end of every article. Please note the exact information you would like to appear in this section and format it according to the requirements stated above. A short biographical sketch may precede the contact information if you provide us with the necessary information (60 words or less).

### Questions?

Magda Wojtkiewicz (Managing Editor)  
[m.wojtkiewicz@dental-tribune.com](mailto:m.wojtkiewicz@dental-tribune.com)

# cosmetic dentistry

\_ beauty & science

asia pacific edition

## Publisher

Torsten R. Oemus  
t.oemus@dental-tribune.com

## Managing Editor

Magda Wojtkiewicz  
m.wojtkiewicz@dental-tribune.com

## Executive Producer

Gernot Meyer  
g.meyer@dental-tribune.com

## Designer

Franziska Dachsel  
f.dachsel@dental-tribune.com

## Copy Editors

Sabrina Raaff  
Hans Motschmann

## International Administration Marketing & Sales

Esther Wodarski  
e.wodarski@dental-tribune.com

## Executive Vice President

**Finance**  
Dan Wunderlich  
d.wunderlich@dental-tribune.com

## Printed by

Löhnert Druck  
Handelsstraße 12  
04420 Markranstädt, Germany

## International Media Sales

Matthias Diessner  
m.diessner@dental-tribune.com

### Europe

Melissa Brown  
m.brown@dental-tribune.com

### Asia Pacific

Peter Witteczek  
p.witteczek@dental-tribune.com

### The Americas

Jan M. Agostaro  
j.agostaro@dental-tribune.com

## International Offices

### Europe

Dental Tribune International GmbH  
Contact: Esther Wodarski  
Holbeinstr. 29, 04229 Leipzig, Germany  
Tel.: +49 341 48474-302  
Fax: +49 341 48474-173

### Asia Pacific

Dental Tribune Asia Pacific Ltd.  
Contact: Tony Lo  
Room A, 26/F, 389 King's Road  
North Point, Hong Kong  
Tel.: +852 3113 6177  
Fax: +852 3113 6199

### The Americas

Dental Tribune America, LLC  
Contact: Anna Wlodarczyk  
116 West 23<sup>rd</sup> Street, Suite 500  
NY 10011, New York, USA  
Tel.: +1 212 244 7181  
Fax: +1 212 244 7185

dti] Dental  
Tribune  
International

## Advisory Board

Dr Michael Miller, USA  
Dr Seok-Hoon Ko, Korea

## Editorial Board

Dr Anthony Au, Australia  
Dr Bao Baicheng, China  
Dr Helena Lee, Singapore  
Dr Hisashi Hisamitsu, Japan  
Dr Jiraporn Charudilaka, Thailand  
Dr Mostaque H. Sattar, Bangladesh  
Dr Ratnadeep Patil, India  
Dr Suhit Raj Adhikari, Nepal  
Dr Takashi Nakamura, Japan  
Dr Vijayaratnam Vijayakumaran, Sri Lanka

cosmetic  
dentistry \_ beauty & science  
is the official publication of:



www.dental-tribune.com

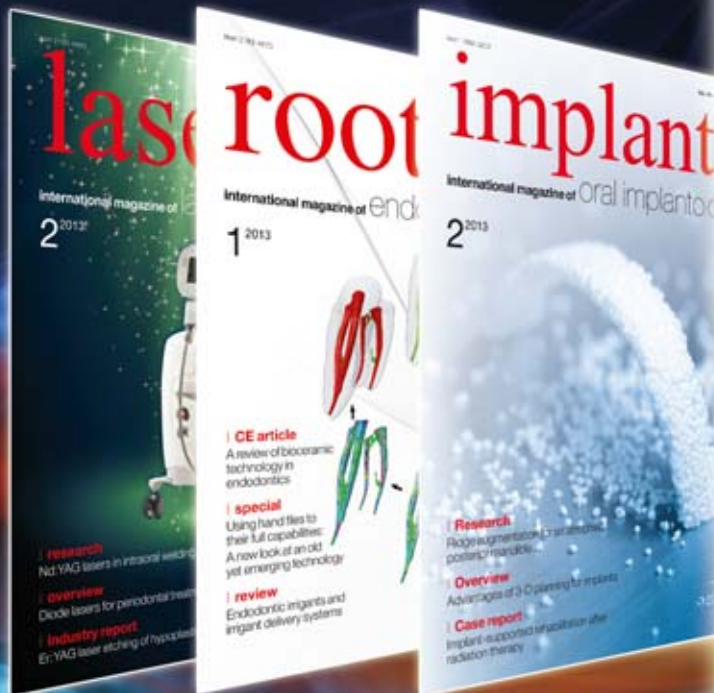## Copyright Regulations

\_cosmetic dentistry\_ beauty & science is published by Dental Tribune Asia Pacific Ltd. and will appear in 2013 with four issues. The magazine and all articles and illustrations therein are protected by copyright. Any utilisation without the prior consent of editor and publisher is inadmissible and liable to prosecution. This applies in particular to duplicate copies, translations, microfilms, and storage and processing in electronic systems.

Reproductions, including extracts, may only be made with the permission of the publisher. Given no statement to the contrary, any submissions to the editorial department are understood to be in agreement with a full or partial publishing of said submission. The editorial department reserves the right to check all submitted articles for formal errors and factual authority, and to make amendments if necessary. No responsibility shall be taken for unsolicited books and manuscripts. Articles bearing symbols other than that of the editorial department, or which are distinguished by the name of the author, represent the opinion of the afore-mentioned, and do not have to comply with the views of Dental Tribune Asia Pacific Ltd. Responsibility for such articles shall be borne by the author. Responsibility for advertisements and other specially labeled items shall not be borne by the editorial department. Likewise, no responsibility shall be assumed for information published about associations, companies and commercial markets. All cases of consequential liability arising from inaccurate or faulty representation are excluded. General terms and conditions apply, legal venue is North Point, Hong Kong.

# cosmetic

## dentistry \_ beauty & science



You can also subscribe via  
[www.oemus.com/abo](http://www.oemus.com/abo)

 **Subscribe now!**

I would like to subscribe to **cosmetic dentistry** for € 44 including shipping and VAT for German customers, € 46 including shipping and VAT for customers outside Germany, unless a written cancellation is sent within 14 days of the receipt of the trial subscription. The subscription will be renewed automatically every year until a written cancellation is sent to OEMUS MEDIA AG, Holbeinstr. 29, 04229 Leipzig, Germany, six weeks prior to the renewal date.

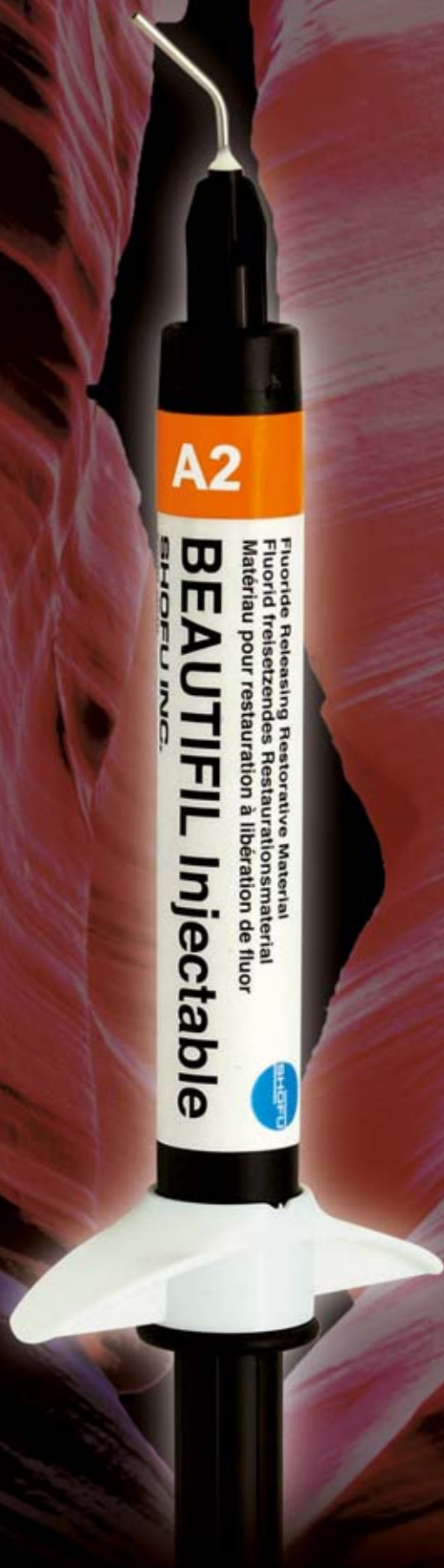▶ **Reply** via Fax +49 341 48474-290 to OEMUS MEDIA AG or via E-mail to [grasse@oemus-media.de](mailto:grasse@oemus-media.de)

Last Name, First Name	
Company	
Street	
ZIP/City/County	
E-mail	Signature

Notice of revocation: I am able to revoke the subscription within 14 days after my order by sending a written cancellation to OEMUS MEDIA AG, Holbeinstr. 29, 04229 Leipzig, Germany.

Signature
-----------

# In a LEAGUE of its own ...



Inject Beauty & Strength as you directly stack and shape Beautifil Injectable into life-like aesthetic restorations that exhibit superior endurance to occlusal load, sustained fluoride protection and unique anti-plaque effect.

SHOFU DENTAL ASIA-PACIFIC PTE. LTD.

Tel (65) 6377 2722 Fax (65) 6377 1121

mailbx@shofu.com.sg website www.shofu.com.sg

Official Partner



Minimally Invasive  
Cosmetic Dentistry