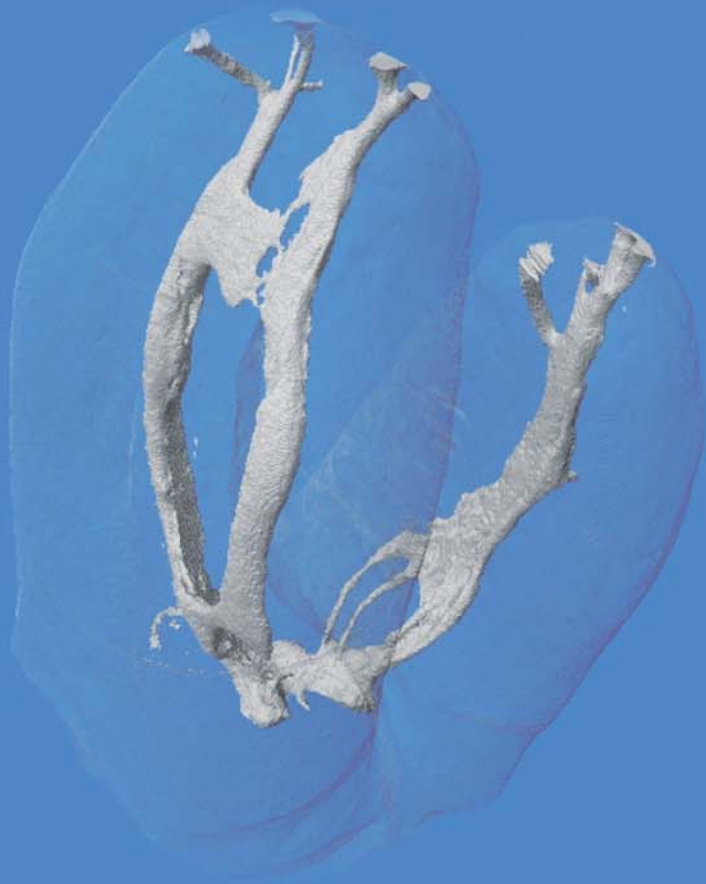

roots

international magazine of endodontology

2²⁰¹³



| **CE article**

Predictable Endo 102:
Why warm and soft is so good

| **opinion**

Raising the bar for endodontic success:
Where we were, where we are and
where we are going

| **research**

Accuracy and consistency of four electronic
apex locators in the presence of different irrigants



*convenient
single cone
technique*



*warm
gutta-percha*

Innovation means combining benefits

**3D root canal filling with an obturator
entirely out of gutta-percha**

- Separation of the handle without additional instruments
- Simplified post space preparation
- Precise placement of the obturator in the root canal with fingers or tweezers

www.vdw-dental.com



with practical
handle for
tweezers

GUTTA FUSION®

Dear friends and colleagues,



Dr John J. Stropko

What a great honour to have this opportunity to share over half a century of my private practice experience with all of you! My prayer, since the beginning of my dental career, was to know when it was time to put the handpiece down. In December 2011, I finished a treatment with an excellent result, but it took me twice as much time and effort to do it. I realised then that my hand-eye co-ordination was not what it used to be. That was not fair to me, nor to the patient, so I decided that the time had come. I may have put the handpiece down, but I have replaced it with a pen, and I am eager to share some of my sincere convictions and experiences with you, in the hope that your path to excellence can be made smoother and with more commitment.

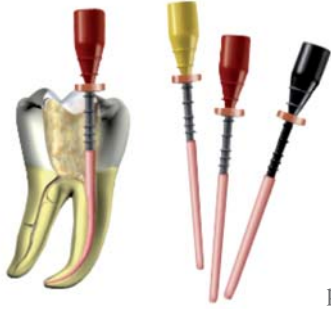I believe what I heard so long ago: "In any profession, or walk of life, there are 2 per cent masters. They are put on earth, by God, to show how the task is to be done. Then there are 8 per cent who have a 'God-given gift' for what they do. They are honest, conscientious, hardworking and continuous students. Then there are 36 per cent who have an average, or so, ability. They too are honest, conscientious, hardworking and continuous students. But then there are the remaining 54 per cent who 'don't give a damn!' They are doing what they are doing for all the wrong reasons: be it family pressure, peer pressure, money, recognition, power, etc., but not committed to their everyday task in life. It really does not make any difference what the person's task in life (job) is. He or she could be a plumber, a barber or a dentist."

Continuing education permits us to view achievements of the past, appreciate the current potential of patient care, and create a more predictable treatment result in the future. It is essential to seek out and listen to those who have already experienced the incredible and increasingly rapid advancement of technology that has occurred in recent years. We all stand on the shoulders of the giants who preceded us. Today, the range of and convenient access to communication permit anyone to attain current knowledge, to pave a path for better results. Continuing education is the map for our journey to excellence and provides the fuel necessary to get there. If you embrace the concept of continuing education as essential to performing your task in life at a higher level, this issue of **roots** is just another small channel for achievement.

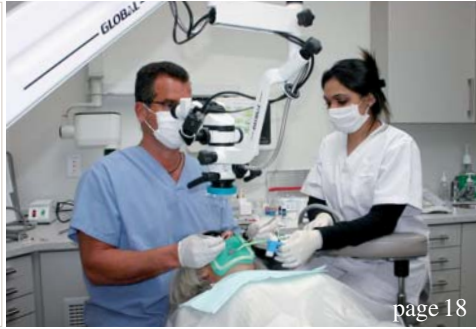In the pursuit of perfection, be willing to accept excellence. Look at any failures as lessons for improvement, not failures. In today's wonderful world of technology and communication, it is all there for the taking, if you want it!

John J. Stropko, D.D.S.

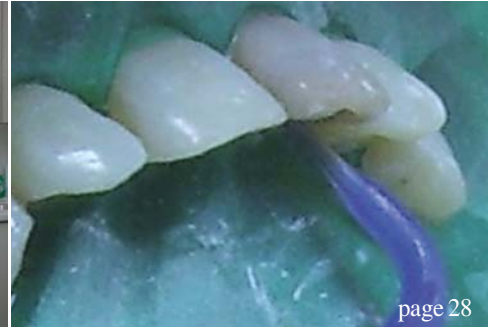Dr John J. Stropko



page 6



page 18



page 28

| editorial

03 Dear friends and colleagues
| Dr John J. Stropko

| CE article

06 Predictable Endo 102: Why warm and soft is so good
| Dr John J. Stropko

| opinion

18 Raising the bar for endodontic success: Where we were, where we are and where we are going
| Dr Gary Glassman

| research

22 Accuracy and consistency of four electronic apex locators in the presence of different irrigants
| Dr Jorge Paredes Veyra, Dr Javier Jimenez Enriquez & Fernando Calleja Casillas

| case report

28 Single-visit apexification with MTA following ozone disinfection
| Prof. Georgi Tomov & Prof. Elka Popova

32 Root-end resection or trephination
A therapy comparison out of the dental practice
| Dr Robert Teeuwen

| feature

38 “The ninth WEC helped to elevate the technical and scientific standards of endodontic research, practice and teaching”
| An interview with IFEA congress president Prof. Hideaki Suda

| meetings

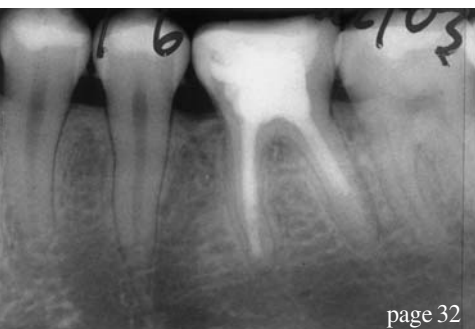40 International Events

| about the publisher

41 | submission guidelines
42 | imprint



Cover image courtesy of Dr Ronald Ordinola Zapata (blog: <http://www.facebook.com/TheInternalAnatomyOfTheHumanTeeth> and iBook: <https://itunes.apple.com/es/book/internal-anatomy-human-teeth./id534097316?mt=11>)



page 32



page 38



page 40



16TH CONGRESS OF THE EUROPEAN SOCIETY OF ENDODONTOLOGY

MAIN TOPICS

Pulp regeneration

Endodontic surgery

Retreatments

Updates on clinical techniques

Education

**REGISTRATIONS & ABSTRACT SUBMISSION
OPEN FROM 1 JANUARY 2013!**

For information please visit the congress website:

<http://www.e-s-e.eu/ese-biennial-congress/lisbon2013/>



AIM GROUP INTERNATIONAL - Lisbon Office

Av. Liberdade, 258 – 6º

1250-149 Lisboa

Tel. +351 21 3245054

Fax +351 21 3245051

eselisbon2013@aimgroup.eu

Diamond Sponsor


DENTSPLY

MAILLEFER

Predictable Endo 102: Why warm and soft is so good

System 'S' for injectable or carrier-based GP

Author_ Dr John J. Stropko, USA

_ce credit	roots
	<p>By reading this article and then taking a short online quiz, you can gain ADA CERP CE credits. To take the CE quiz, visit www.dtstudyclub.com. The quiz is free for subscribers, who will be sent an access code. Please write support@dtstudyclub.com if you don't receive it. Non subscribers may take the quiz for a \$20 fee.</p>

Abstract

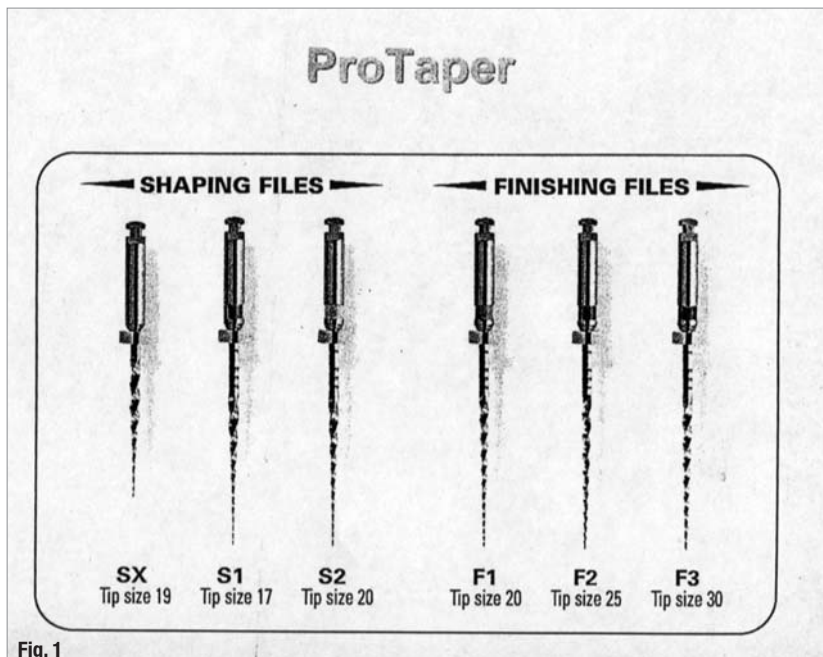
The author has been in private practice and a continuing student for the past 50 years. The first half was spent practicing restorative dentistry, and the second half in a specialty practice limited to endodontics. On the road to predictability, it became apparent there was a definite relationship present between root canal treatment, periodontal status, prosthetics and/or subsequent restorative procedures. Each operator has to decide what steps for a more predictable outcome they are willing to trust another to do. This article is an attempt to share some "secrets of success" and perhaps serve as a checklist for a system that works in the attempt to achieve predictability of endodontic treatments.

"There's a difference between interest and commitment. When you're interested in something, you do it when it's convenient. When you're committed to something, you accept no excuses, only results."

—Ken Blanchard

Fig. 1 Typical rotaries, one of several popular brands.

(Photos/Provided by John J. Stropko, DDS, unless otherwise noted)



During the earlier years of the past century, several techniques were devised for the obturation of the canal system after removal of the diseased pulp, or necrotic tissue. Some of the most popular were silver points, lateral condensation of gutta-percha (GP), Sargenti paste and chloropercha. Currently there are seven techniques that utilize gutta-percha as the obturation material of choice:

- 1) Single cone
- 2) Lateral condensation
- 3) Chloropercha technique
- 4) Vertical compaction of warm GP (Schilder, continuous wave, System "B", McSpadden, System "A")
- 5) Carrier-based (Thermafil)
- 6) Injection of thermo-plasticized GP (often referred to as "squirting" using a Calamus or Obtura unit)
- 7) Mechanically assisted compaction (Pac Mac).

In 1967, Dr Herb Schilder, often referred to as "the father of modern endodontics," introduced the concept of filling the root canals in three dimensions.¹ The Schilder Technique involved a new and different approach for obturation of the canal system and resulted in much controversy. Evidently, the controversy did create interest from some doctors, because

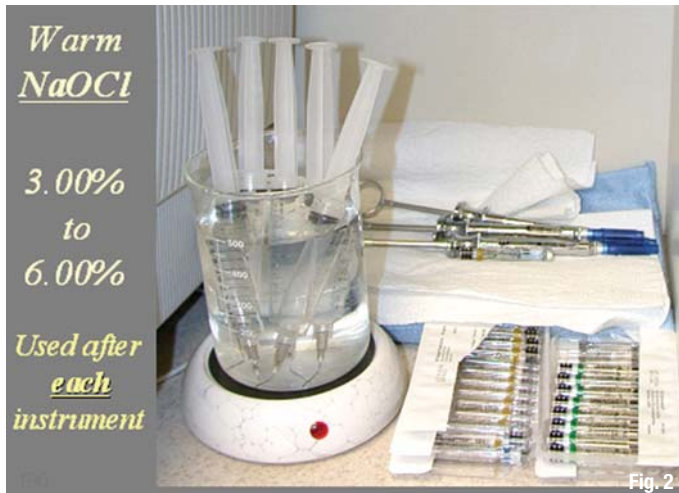


Fig. 2

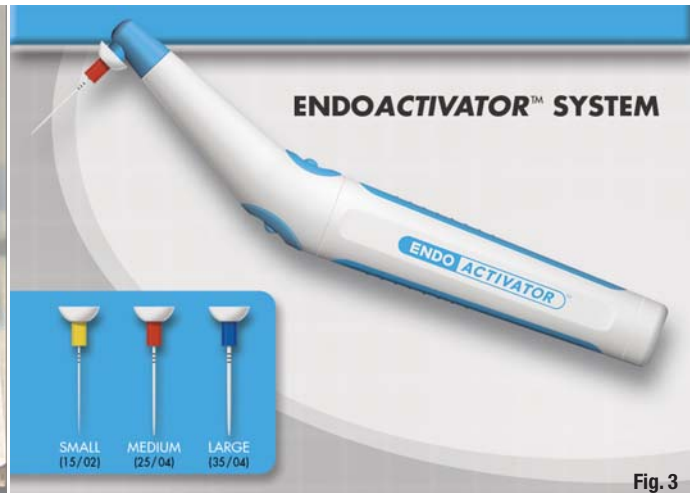

Fig. 3

in the mid 1970s new ideas and techniques evolved that became most of what are the currently accepted concepts of modern endodontic principles and techniques. Today, the numerous clinical reports, published research and the rapid advancements in technology have significantly changed the operator's obturation preferences. Ease of communication, along with modern marketing, has become a very important determinant when making a choice of techniques. More recent studies have discounted some previous obturation materials that were popular, but some form of GP still remains the most acceptable and widely used. The purpose of this article is to share a simple, six-step protocol (System "S") in a straightforward manner, to achieve predictability of endodontic treatment for the benefit of the patient.

There are six important components to the System "S" protocol:

- 1) Proper shaping with patency.
- 2) Adequate cleaning, disinfection and drying.
- 3) Delivery of pre-warmed GP to apex (Calamus/Obtura).
- 4) Coronal seal for the rest of the system.
- 5) Respect for the endo-pros relationship.
- 6) Use of the surgical operating microscope (SOM) for the entire endodontic treatment.

The author believes that as long as the gutta-percha is introduced to the apical third of the canal system, pre-warmed and pre-softened, the deformation and adaptation to the canal walls is more predictable, resulting in a better seal that is significantly less "sealer-dependent". It has been shown that the pre-warmed techniques (Obtura and Thermafil) produce a better seal than lateral condensation.² Due to the lack of deformity inherent at room temperature, the techniques utilizing non-softened GP are more "sealer-dependent". The two most popular thermoplastic obturation techniques are the "carrier-based" (e.g., Thermafil) and "direct injection" (e.g., Calamus/Obtura). The pros and

cons of each will be discussed, but regardless of the technique used, the "shape" of the prepared canal system is of utmost importance and must be discussed.

Access and shaping the canal system

In the early '70s, Schilder clearly stated the requirements for the proper shape using GP to achieve three-dimensional obturation of the canal system:

- 1) The root canal preparation should develop a continuously tapering cone shape.
- 2) It should have decreasing cross-sectional diameters at every point apically and increasing at each point as the access cavity is approached.
- 3) It should have multiple planes, which introduces the concept of "flow".
- 4) The foramen should not be transported.
- 5) The apical opening should be kept as small as practical in all cases.

There were several other requirements more clinically definitive. Following are a few of them: After placement of the rubber dam, an appropriate access is made. Unless the access is large enough for adequate vision, appropriate instrumentation may be compromised and canals missed. A perfect example is a maxillary first molar; if the access is made as though there was an MB2, it is amazing how many times an MB2 is found. A general rule of thumb is, if you access for it, you are more likely to find it. A proper access will also facilitate the creation of the continuously tapering shape of the canal, necessary for the warm GP technique. Occasionally after caries or old restorations are removed, a "pre-endodontic" restoration may be required to control and maintain a sterile environment until the endodontic treatment is complete. This can usually be accomplished using a bonded composite technique.

Shaping should be confined to the anatomy of canal system, following the natural curvatures. Instrumen-

Fig. 2 NaOCl irrigating syringes can be warmed in a beaker on a coffee warmer. Note the anesthetic syringes on a heating pad in the background.

Fig. 3 The Endo Activator is used for the 'tsunami effect' for cleaning canals.




Fig. 4a The canal system can be very complicated.
Fig. 4b The Walter Hess studies with vulcanite clearly demonstrated the complexity of canal systems.
Fig. 5 Set of three Stropko Irrigators with various 27-gauge tips bent for use. Arrow points to the dedicated 'air-only', single-button DCI syringe.
Fig. 6 When drying canals with air, needles must be notched or side-vented (arrows).

tation beyond the apex is unnecessary and may needlessly enlarge and deform the apical foramen.³ Using the Schilder protocol to achieve the desired shape of the canal system was a time-consuming process. It involved the tedious use of pre-curved files and reamers to follow the anatomical curvatures of the canal. Other requirements that caused some controversy then (and still does), besides the size of the access opening, was the need to keep the apical foramen as small as possible, and to maintain patency throughout the entire process. The majority of more recent published research and clinical studies have confirmed the rationale for an appropriate access and correct shaping.

In the early 1990s, technology brought about the introduction of rotary instruments, relieving the operator of considerable time spent creating an acceptable shape. The ProFile rotary bur (Tulsa Dental) with 0.04 and 0.06 taper, was introduced to the profession. Creating the shape necessary for the successful use of the warm obturation techniques was made easier and faster. By the beginning of this century, numerous designs gradually evolved utilizing varying tapers, active or passive cutting blades, etc. (Fig. 1). At first, the biggest problem with the rotary files was breakage during use. But modern nickel titanium (NiTi) metallurgy technology has developed more, and more dependable, rotary files. As a result, today the separation of a rotary instrument during use is of virtually little or no concern.

It has also been shown that proper shape permits more thorough irrigation and the removal of significantly more debris from the prepared canal system. Disinfecting irrigation should be used between each instrument during the entire shaping process and patency continually maintained with a #10 file. Note: The quantity of irritants used is not as important as the frequency of use. The irrigation protocol, instruments, fluids, etc., are in constant evolution and becoming more effective. However, a clean and sterile environment of the canal system prior to obturation is still the objective.

Irrigation for cleaning the canal system

After shaping is completed, final cleaning can be effectively accomplished by the alternative use of:

- 1) Warm 3- to 6-per cent NaOCl.
- 2) 17 per cent aqueous EDTA for approximately 30 seconds (smear layer removal).
- 3) Warm 3- to 6-per cent NaOCl (further disinfect and stop action of the EDTA).

The NaOCl can be effectively warmed by placing the irrigating syringes in a beaker of water set on a small coffee warmer (Fig. 2). The canal(s) are completely flooded with the desired solution; an Endo Activator (DENTSPLY) is appropriately used for the "tsunami effect", then re-irrigated with the same solution for flushing of debris (Fig. 3). The NaOCl is then effectively removed with a capillary tip (Ultradent) attached to a high-speed evacuator. Other solutions (hydrogen peroxide, chlorhexidine, 17 per cent aqueous EDTA, MTAD, etc.) can also be used alternately, depending on operator preference.

Close observation with an SOM will clearly indicate complete cleaning of the canal system when no debris is flushed out during the irrigation process. During the evacuation with the capillary tip, it becomes apparent if there is a joining of the canal systems within the root. For example, if using the SOM as the MB1 canal is being evacuated and it is noted that fluid is simultaneously being drawn from the MB2 canal, there is a good indication that the system is complicated and does join at some point (Figs. 4a & b). There are occasions, especially in lower molars, where the mesial root canal system unexpectedly joins with the distal root canal system. On occasion, the maxillary canal system will have the DB or MB canal system connected to the palatal system. These "surprises" are important to be aware of, before obturation of the canal system, especially when using either carriers or injectable GP.

_Drying canals with F•I•R•E

The canal(s) are **F**looded with 95 per cent ethanol (Everclear, available at local liquor store), agitation of the fluids are **I**nitiated with an activator for the tsunami effect, then **R**e-irrigated with the 95 per cent ethanol, and then **E**vacuated with the capillary tip. The canal(s) are then best dried by using a Stropko Irrigator on a dedicated, air-only syringe (DCI), but if a three-way syringe is used, be sure to express all water from the line first (Fig. 5). Next, with a 27- or 30-gauge notched or side-vented needle (Monoject), fitted to the tip of the Stropko Irrigator and bent as necessary, to easily dry the canal system (Fig. 6). Important note: It is essential to regulate the air pressure to the syringe at 1 to 3 psi and use a side-vented or notched needle, to prevent any possibility of inadvertently forcing air through the apical foramen. This is easily achieved with an in-line regulator, the Chapman-Huffman Regulator & Gauge, Part #17-050-00 (Fig. 7).

As dentists, we are accustomed to a "blast" of air while using the usual air/water syringe tip and high air pressure to the A/W syringes. With a properly regulated Stropko Irrigator fitted with an appropriate small gauge needle, only a "kiss" of air is necessary to create the flow necessary for thorough air drying of the canal. On occasion, one has to direct the air to a sensitive area on himself or herself to be sure the air is even flowing. Just watching the evaporation that occurs within the canal, while using the SOM, is enough to convince any operator that there is indeed a flow of air. There is enough physiologic back pressure of the apical environment (1.5 mm Hg) to prevent movement of the air past the terminus in the correctly shaped canal. In almost 20 years, with many different doctors using the Stropko Irrigator to "air dry" canals, the author has only heard of one unfavorable incident. In that one case, the doctor did not use a side-vented needle and did not regulate the air pressure to the air syringe. To repeat, when the Stropko Irrigator is used with the properly regulated air pressure (1 to 3 psi) and the appropriate 27- to 30-gauge, side-vented/notched needle is used, there is no fear of forcing air into apical tissues.

_Sealer application

To the SOM user, the ineffectiveness of drying the canal with a paper point is soon realized. It is also easy to observe how differently the Kerr Pulp Canal Sealer EWT (SybronEndo) acts when the canal is in fact dry, not just blotted. After blotting with a paper point, the sealer tends to act like a drop of oil when placed on the canal wall. But when the surface is dried, using alcohol and air as described above, the sealer readily spreads onto the canal wall, much like a coat of paint.

The complete dryness of the canal to the desired working length is checked with a clean absorbent point that fits to length. This also gives the operator an excellent chance to recheck the working length and dryness of the canal. Any sealer (Kerr EWT, Roth, AH Plus, etc.) can be used as long as the heat of the warm GP does not cause a "flash set." The end 3 mm of a sterile paper point is coated with the sealer of choice and placed into the canal to the working length. The author uses Kerr Pulp Canal Sealer EWT, mixed per usual directions, but a little "on the thin side". Using short, rapid apical-coronal movements, the walls of the canal are completely coated with sealer. The use of the SOM is a great aid for observing when the coating of the canal wall by the sealer is complete. Then, a sterile absorbent point is used, in the same manner, to remove any excess sealer that may remain. Depending on the amount of sealer placed at the beginning, more than one absorbent point may be necessary to get the "blotchy appearance" on the final point (Fig. 8). Only a thin coat of sealer is necessary for lubrication, so very little remains on the walls of the canal (Fig. 9). One of the most common mistakes, made at first, is using too much sealer. When this happens, the excess sealer will be extruded back into the chamber, or apically when the warm GP is placed. In some cases, the GP may be prevented from completing the desired "flow" apically. Typically, only one or two points are normally needed once the operator achieves proficiency at applying the correct amount of sealer to begin with. Thermoplastic GP techniques are not sealer-dependent and depend more on the sealer as a lubricant and facilitate the flow of the thermoplastic GP.



Fig. 7

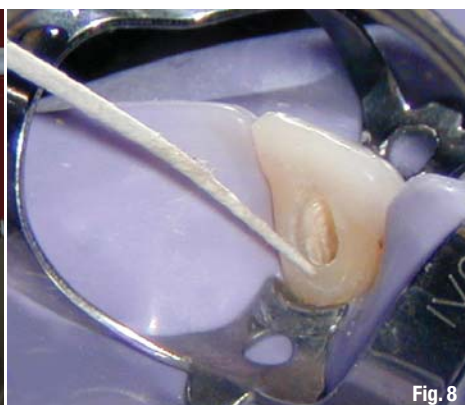

Fig. 8



Fig. 9

Fig. 7_ The Chapman Huffman in-line air regulator and 0-15 psi gauge works well.

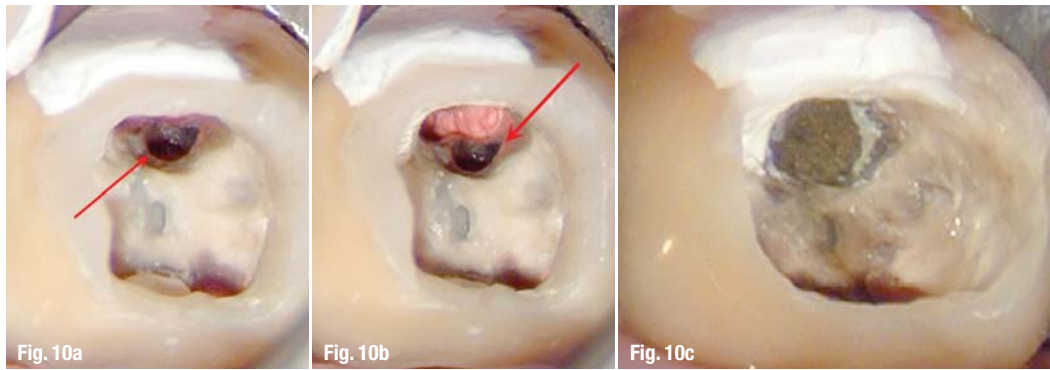
Fig. 8_ Fresh absorbent points are used to remove excess sealer until 'blotchy'.

Fig. 9_ Only a very thin layer of sealer needs to coat the walls for lubrication. (Photo/Courtesy of Bob Sharp, Sacramento, CA)

Fig. 10a_A furcal perforation in the distal root of a mandibular first molar.

Fig. 10b_ Canal filled just apical to furcal perforation.

Fig. 10c_MTA placed to repair the perforation.



Important consideration between using injection or carrier-based obturation

Essentially, there is one very significant difference between the two techniques. The injection technique fills the canal system from the apical to the coronal, whereas the carrier-based techniques fill from coronal to the apical. This is important to take into account, especially in cases the operator does not want to fill the canal to the orifice or needs to control the "depth" of the fill. A good example would be in the case of treatment of a perforation repair. Using injection, the "fill" can be accomplished rather easily, and both the sealer and GP can be confined apical to the perforation. MTA can then be added to the repair in a very controlled manner (Figs. 10a–c). When a post space is required, the GP can be injected to any level in the canal, but it is better to obturate the entire canal first, so unknown anatomy more coronally in the canal won't be missed.

Obturation by injection of thermo-plasticized GP with a Calamus or Obtura

After using the Obtura for over a decade for thermo-plasticized GP obturation, the author switched to the Calamus when it was first introduced many years ago. After thousands of canals were obturated using both of them, several advantages were noted when comparing the two units (Table 1).

Both units are available as a single unit, or a dual unit combined with a thermal handpiece for convenience (Figs. 11a&b). The consistent flow of the Calamus unit does make the learning curve quicker and easier to master than the Obtura, because the relatively large muscle action of squeezing the trigger could vary from patient to patient, or day to day. The much smaller muscle action of using a finger to press the collar of the Calamus is significantly less, and the resulting flow of the GP can be pre-set for consistency.

The size of the needle used in the Calamus or Obtura (20 vs. 23 gauge) is generally a matter of preference and can also depend on what the canal wants. It does not make any difference, in the scheme of things, how far apically into the canal the needle is placed, as long as it is non-binding.⁴ For example, straighter and larger canal will take a larger needle. On some occasions, the 20-gauge needle will not be far enough apical to the orifice of the canal before binding. If the canal preparation is narrower, this is an indication to use the smaller, 23-gauge needle. As long as it is not binding and the canal has the correct shape, the GP will flow to the apex. Note: If the canal is parallel in shape, the canal then becomes an extension of the needle and apical control is severely handicapped. Shape is of the utmost importance, especially in these techniques.

The settings on the Calamus are checked to assure the desired set temperature has been achieved (the author uses 160°C), and the flow rate is set correctly (the author prefers 100 per cent). When the unit reaches the set temperature, it will stop blinking. Note: As a safety feature, until the unit has achieved the pre-set parameters, the motorized plunger will not initiate and GP is not ejected. When all is ready, the collar is pressed until the initial GP is extruded and then the collar is released. The slight amount of GP at the tip is removed. The needle is then placed into the canal apically, just short of binding, and the collar is pressed to reactivate the plunger and initiate the flow of GP. It is good practice to barely move the tip, in a very slight apical-coronal direction as the GP is flowing. The moment there is a sensation of pushback, a momentary, very slight apical resistance can be exerted, then

CALAMUS	OBTURA
Flow is consistent and can be preset	Flow dependent on operator's "squeeze"
GP & needles in single packaging	GP pellets delivered several in a box
Single needle use the norm	Multiple needle use the norm
Barrier protection easy to place	Barrier protection more involved
Less patient discomfort upon injection	Patient often felt a "flash of warmth"
Easier to relate/teach proper use	Proper "squeeze" a longer learning curve
Can easily be rotated for ergonomics	Unit difficult to turn to different angle
No hand fatigue during use	Hand fatigue can occur
No patient response during obturation	Patients often felt apical pressure
Generally, very clean to use	More time consuming to clean

Table 1

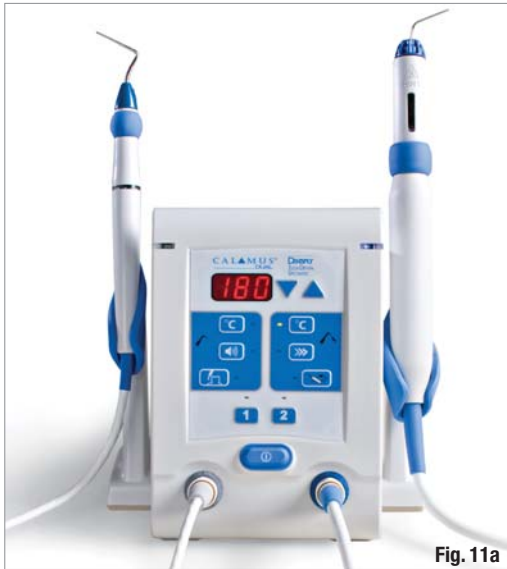

Fig. 11a

Obturation with carrier-based GP (Thermafil)

Carrier-based GP (Thermafil) was first conceived by Dr Ben Johnson of Tulsa, OK, USA, in 1975; published in 1978; and made commercially available to the dental profession in 1988 (Tulsa Dental).⁵ It has become one of the most popular and respected techniques in the world. Today there are many forms of the Thermafil concept on the market that conform to the design of various rotary burs (DENTSPLY Tulsa) (Fig. 13). The technique saves the operator a significant amount of time during the obturation process, and excellent results have been supported by numerous studies over the years.

After shaping, cleaning and disinfection is complete and the canal is still filled with fluid (NaOCl, CHOH, etc.), a NiTi verifier the same size as the maximum apical file (MAF) is selected. Using just the fingers, it is spun into the canal to working length. The verifier has to be passive when doing this step. Depending on the canal anatomy (straight vs. curved), if there is significant resistance with the selected verifier, such as traversing a curve of sufficiently sharp radius, then the carrier of the same size will meet the same resistance when it is placed. Therefore, you would then drop down one size, test-spin that verifier to length, and it should encounter less resistance. This then would be the correct size carrier to choose, regardless of what the final apical size was that you machined. Note: The verifier is not verifying the apical size of the preparation, but it is a dress rehearsal for how the carrier is going to behave when it is inserted into the space. It is verifying the ease of insertion of the eventual carrier core.

For example, if you instrumented to a MAF size 30/0.06 in a significantly curved canal (less than 25 degrees), a #30 size verifier may not spin easily to

Fig. 11a_The Calamus Dual unit with a thermal handpiece.

(Photo/Courtesy of DENTSPLY Tulsa Dental Specialties)

Fig. 11b_An Obtura III Max Pack Dual also has the thermal handpiece.

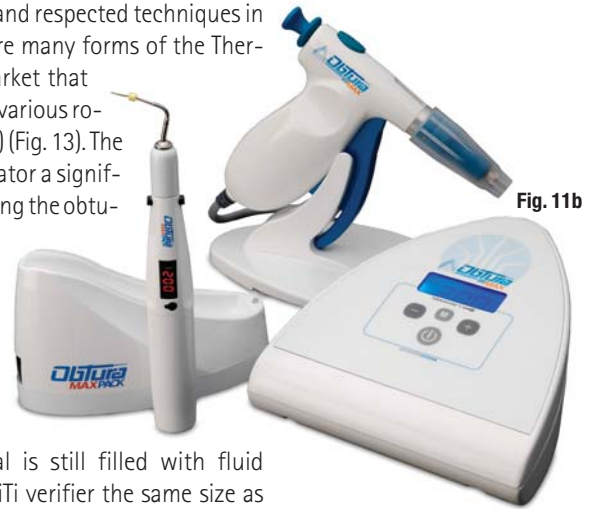

Fig. 11b

begin to slowly withdraw the needle until the GP fills the canal to the orifice. Using an SOM, this is easily observed and gives the operator confidence.

If there are two or more canals in the same root, they must be injected in a special manner, especially if they join or are connected by any variation in the canal system (an isthmus, for example). Obturation is accomplished by filling both of the canals in rapid succession to the desired level in the orifice. Then immediately proceed to the first canal with a pre-measured plugger to create more hydraulics (deep pack) and start the compaction process. The GP will remain soft for enough time so the operator can accomplish the shepherding process in two or more canals if done in a timely manner.

To insure complete adaptation to the walls of the canal, the warm GP needs to be compacted as it cools to overcome any shrinkage that will normally occur. Since the softness of the GP is mass-dependent, the GP at the orifice level has the greatest mass and will stay softest for the longest time in the canal, regardless of which technique is utilized. Using the Calamus, a pre-fitted Schilder #9 plugger, well short of binding, is then used to compact the GP to the pre-measured depth (Fig. 12). The plugger is firmly pushed into the soft GP and held at the measured depth for just a few seconds to achieve compaction of the GP in the apical third. The plugger is now used to "shepherd" the GP from the walls of the canal into a "wad" and further compact the GP. The operator works toward the orifice in approximately 2-mm steps as the plugger creates "new wads" in the process. The shepherding of the GP is continued until the desired depth in the orifice is reached. The mistake often made when working with warm GP is the tendency to "bounce" off the GP while compacting, instead of giving the GP time to compact. Just a few seconds are needed for the newly compacted "wad" to cool.

Fig. 12_The plugger is pre-fit, short of binding, to avoid unnecessary contact with the canal walls during deep compaction of the softened GP.

(Image/Courtesy of Arnaldo Castellucci, Florence, Italy)

Fig. 13_The GuttaCore carriers are just one of many popular products for carrier-based GP. (Photo/Courtesy of DENTSPLY Tulsa Dental Specialties)

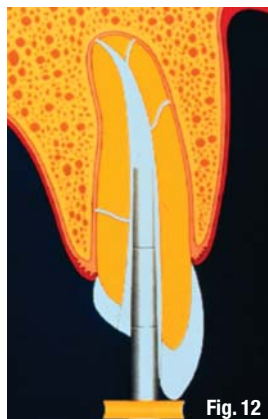


Fig. 12

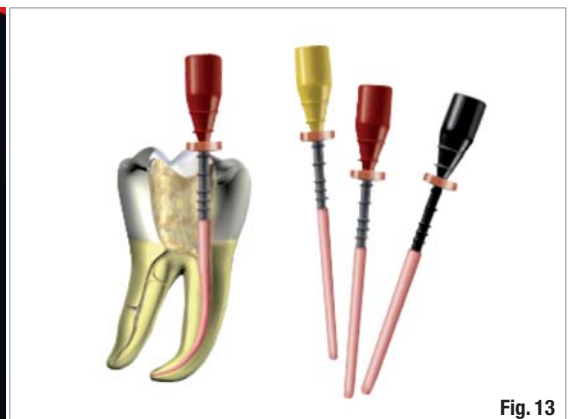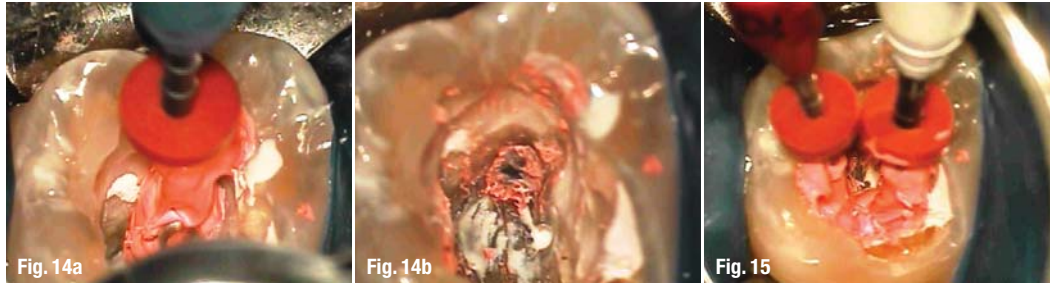


Fig. 13

Fig. 14a_A Prepi bur (DENTSPLY) is used to sever the handle of the carrier at level of the orifice. (Photo/Courtesy of Stephen P. Niemczyk, Drexel Hill, PA)

Fig. 14b_Carrier shaft and GP are severed at the orifice of the canal. (Photo/Courtesy of Stephen P. Niemczyk, Drexel Hill, PA)

Fig. 15_A second carrier is inserted alongside the first carrier to enhance compaction. (Photo/Courtesy of Stephen P. Niemczyk, Drexel Hill, PA)



length; you would try a #25 size verifier instead. In all likelihood, the #25 will go to length without significant resistance. The resistance it encounters is a function of the file/carrier being distorted by the curvature of the canal space; the greater the curvature, the greater the distortion and resistance (and the greater the chance of contacting the carrier on two opposing sides during insertion, possibly stripping the GP from the core). Dropping down one size eases that impingement without compromising the carrier's ability to transport the softened gutta-percha to length. The use of the size verifier is critical to the successful placement of the eventual carrier, but is often done improperly, or not at all.

Once the appropriate carriers are chosen, the canal spaces are dried completely with paper points, the "FIRE technique," etc. A small amount of sealer is applied to the canal walls with a paper point (pin-head drop) into the shaped canal. If the canal is not dry, the excess moisture will prematurely cool the advancing wave of GP, resulting in a "pig-tail" of GP extruded into the PA area. The same will occur with excess sealer, and it will extrude along with the GP.

The carriers are placed singly into the oven, the correct time chosen, and the cores allowed to heat to the proper temperature. The small plastic, and all Gutta-Core carriers, are heated on the first setting (20 to 22 seconds); size 30 to 60 Thermafil Plus heated with the second setting (40 to 42 seconds); and size 70 or larger, the third setting (44 to 46 seconds). The carriers can be reheated, if necessary, and the time setting for the larger carriers is not critical, as long as they are heated for at least 40 seconds.

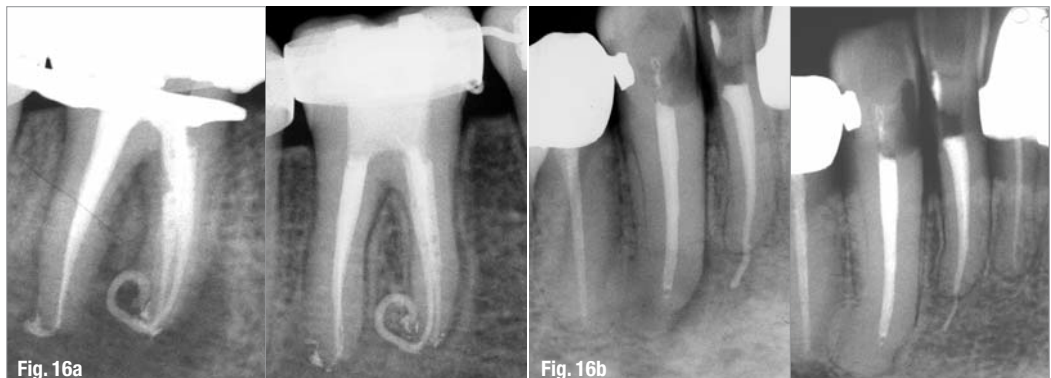
Insertion of the heated carrier is slow and deliberate; you need to allow the excess material to be vented coronally. Insertion rates are 2 to 3 mm per second, which would translate to an average time of seven to 10 seconds for most canals from orifice to working length. With the larger carriers, you may experience a "rebound" effect after the carrier is inserted a few millimeters into the canal. Release the carrier and it will "rise" slightly from the canal space. This is the GP venting and pushing the carrier back out of the canal slightly as it vents. Once the rebound is stopped, you can continue the insertion, stopping every few millimeters to check for rebound until the carrier is inserted to length. Pushing through the rebound and not allowing the GP to vent coronally will precipitate significant extrusions.

Depending on which type of carrier is used, the handle is cut at the orifice level using either a Prepi bur, or a thermal tip (Figs. 14a&b). Removal of the handle is essential when placing more than one carrier in the access, as multiple handles in the access will obscure the view for the succeeding placements. A radiograph is taken to confirm placement, and any adjustments are easily made by engaging the core with a file and removing from the canal. Using a high-speed round bur, the remaining carrier "stubs" are trimmed to the desired level. If a post space is desired, it can be prepared immediately with an end-cutting ProPost drill (DENTSPLY) that will not displace the carrier.

Compaction of warm GP using Thermafil for carrier-based obturation is slightly different. A simple technique is to segment a GP cone into approximately 5 mm sections prior to the obturation process. Imme-

Fig. 16a_A PAX of the immediate post-op (left) and two-year post-op (right).

Fig. 16b_A PAX of the immediate post-op (left) and four-year post-op (right).



diately after the Thermafil carrier is separated with a Prepi bur (DENTSPLY), the GP at the orifice is still soft and can be readily compacted. To facilitate thorough adaptation, a small and lubricated plugger (about a size 8 to 8.5 Schilder) can be used to apically compact the warm GP alongside the carrier. Push apically to a predetermined distance, hold briefly and remove the plugger. Then, using one of the pre-cut segments of GP, place it into the void created by the plugger, and compact it into place. More segments of GP may be necessary depending on the size of the canal. In cases when the canal may be ribbon-shaped and large in the M-D or B-L direction, the apical third of the canal is obturated in the conventional manner. Then an accessory carrier can be inserted alongside the initial carrier (Fig. 15). The second core of the second carrier functions as a gentle spreader to assist in the lateral compaction and spread of the softened GP. The warm GP from the first and second carriers fuse together so any voids are eliminated.

_Excess filling material

Historically, any time a case was obturated, there was much concern when anything was extruded beyond the apical terminus. Many endodontic failures were blamed on vertical over-extension, but in reality the culprit was an "under-filled" canal system. As Schilder stated, "You can only fill a canal 100 per cent." If the canal is filled 100 per cent, any excess material extruded would be of no consequence. In fact, if the author obturated a canal system and there was no excess filling material, the GP would be routinely removed and re-obturated until there was. The point was, "How else could you be sure the canal system was obturated 100 per cent unless there was some excess filling material present at the apex?" Cases that have a significant amount of excess filling material but are properly shaped, cleaned and packed do heal. Over time, the excess material will slowly be resorbed (Figs. 16a & b).

The biggest fear of the new user of injection or carrier-based GP is, "There will be a great amount of excess filling material at the terminus." The opposite is generally true. At first, the most common problem for the new user was the inability to get to the terminus and completely fill/obturate the canal system. The usual reason for this was either an improper shape, the absence of patency or fear of the operator to use enough pressure during the injection and compaction process.

A good way to imagine what is happening, while using thermo-plasticized GP in a properly shaped and patent canal, is to envision everyone in a theater rushing to get out the same door in a big hurry. The GP molecules are relatively large and warm, so the continually tapering shape is, in itself, a limiting factor for

the amount of sealer, or filling material, that will be extruded beyond the apex. If the apical terminus of the canal is kept as small as practical, about the size of a 20KF, it is hard to obtain more than a small "puff" at the apex, no matter how hard the operator compacts the thermo-plasticized GP (Figs. 17a & b). However, it makes sense that the larger the apical opening, the larger the amount of excess material might be extruded. In a short period the operator develops the necessary "feel" to be very predictable with the obturation and compaction.

This is the essence of the learning curve when beginning to use a thermo-plasticized technique. Also, since the softness of thermo-plasticized GP is maintained for a longer time in a larger mass size (volume), the apical extent is the first to become solid since it has the smallest volume of mass. These techniques are easy, fast and predictable for achieving excellent obturation, if all is done as described.

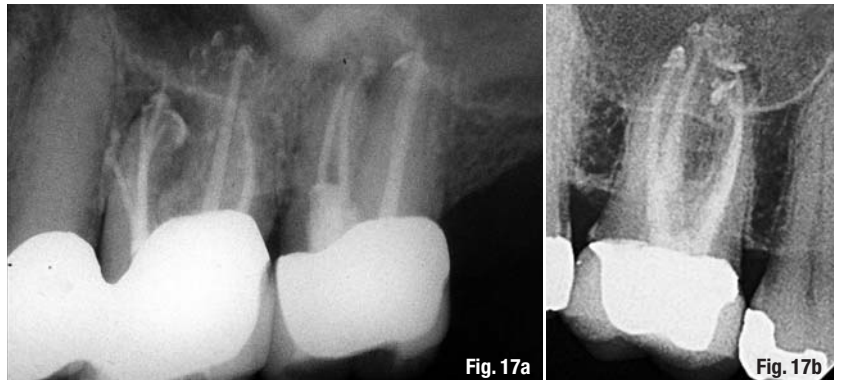


Fig. 17a_Teeth #14 & 15 obturated with Thermafil Plus. (Photo/Courtesy of Stephen P. Niemczyk, Drexel Hill, PA)

Fig. 17b_Tooth #3 after being obturated using the Calamus.

_Now for the rest of the seal

The final step of the System "S" protocol is to fill the entire canal system. It is self-defeating to do a beautiful job in the apical half of the canal system and turn the case over to another person to complete the coronal half of the obturation. As endodontists, we are generally concerned with "the fill" and forget the importance of sealing "the rest of the system."⁶ To illustrate this concept, look at the four cases depicted in Figure 18, and then decide which one would have the most predictable chance of success. They all have well-done endodontic treatment, but only one case has had the entire canal system sealed.

A survey taken not too long ago showed that 95 per cent of general/restorative dentists did not use a rubber dam while placing a foundation restoration in an endodontically treated tooth. To maximize the predictability of success and avoid possible post-op complications, the "endo-doer" must be responsible for the seal of the entire canal system. Here are just a few reasons to do the foundation restoration at the same visit:

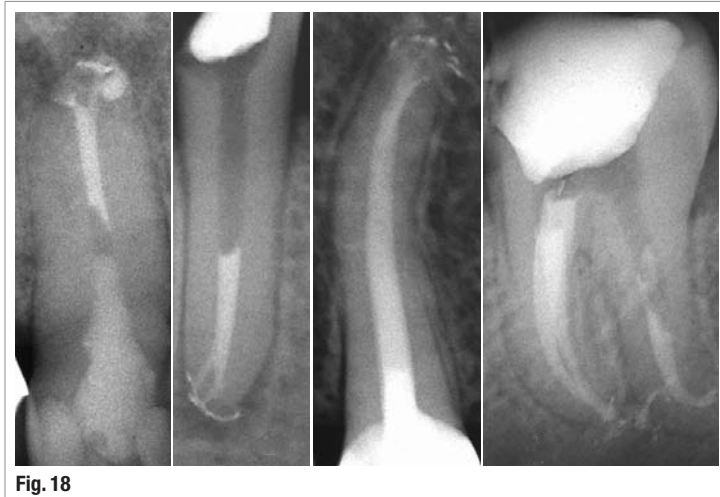

Fig. 18

Fig. 18—These four cases all have excellent root canal treatment, but only the third from left had the entire canal system filled at the final endodontic visit. Which one would you bet on for predictability?

- 1) Patient is "in the chair."
- 2) Patient is anesthetized.
- 3) Rubber dam is in place.
- 4) Access is sterile for placement of the foundation restoration.
- 5) All previous restorative materials are easily removed.
- 6) The "endo-doer" has microscopically enhanced vision.
- 7) The "endo-doer" knows correct angle, size and depth of the canal system.
- 8) There is no chance of contamination of the canal system.
- 9) Inadvertent perforations are eliminated.
- 10) The tooth can be "roughed prepped" with dam in place.
- 11) The patient has more time to plan the final restoration.
- 12) After RCT, doctor knows, within two minutes, the time to schedule for crown prep.
- 13) On anterior teeth, appointments can be coordinated for placement of a provisional.

It has been shown that coronal leakage is the major cause of root canal treatment failure.⁷ Therefore, it behooves us to do all that is possible to prevent it. If multiple visits are required, the doctor should not rely

on "cotton and Cavit" to maintain the sterility of the system. With the current bonding and composite technology, the temporary placed between visits should be a bonded composite. A good example of an easy-to-use temporary is auto-cure Tenure Uni-Bond and Core Paste (Denmat). CaOH (Ultracal by Ultradent) is injected into the canal system and covered with a sterile cotton pellet. Then Tenure Uni-Bond is used to condition the access opening, lightly air dried and Core Paste is injected to fill the opening. After just a few minutes, the auto cure Core Paste is set completely, the occlusion is ready for any adjustments to make sure there are no interferences left to irritate the tooth. On occasion, a patient is unable to keep the appointed return visit and may have to delay his or her return visit for weeks or months (Fig. 19). There may be an important change of events in his or her life, or the doctor may also have to change the scheduled visit. If a temporary is placed, such as Cavit, IRM or Tempit, all control of the bacterial environment in the canal system is lost in a relatively short period if the patient does not return in a timely fashion. Who would be better to control the coronal aspect of the tooth following endodontic obturation than the "endo-doer," while the case isolated with a rubber dam in place? As Dr Denny Southard of Tulsa commented almost 15 years ago, "When we slap in Cavit and turn our heads, the case is destined for contamination or worse (perforation, for example)." However, if a more definitive seal is maintained, that part of the equation becomes a non-issue.⁶

An easy foundation restoration technique

After the obturation of all canals, the gutta-percha is removed to the proper depth in the orifice as required for retention. This is quickly and easily done using a Muncie Bur at approximately 5,000 rpm. If a post space is required using carrier-based GP, a ProPost drill can be used to remove a little GP at a time, until the desired depth is reached. Using the co-observer tube of the SOM and a precise flow of air from the Stropko Irrigator, the chairside assistant can aid in the removal of all bits of sealer and GP to maintain vision while final cleaning of the access/post space is done.

Figs. 19a-c—A bonded temporary that has been in place for three months without leakage.

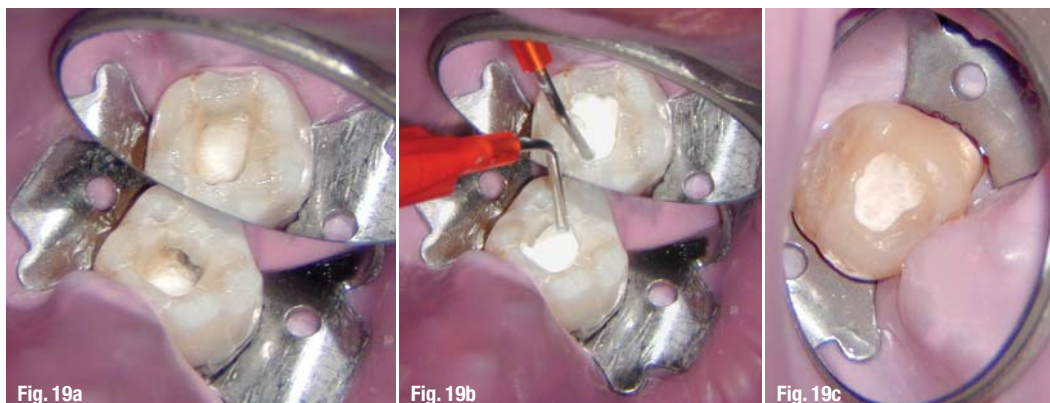



Fig. 19a

Fig. 19b

Fig. 19c

After the mechanical cleansing of the access is accomplished, it is flooded with 95 per cent ethanol to remove any remaining sealer and scrubbed with a micro-applicator (SybronEndo). Another application may be necessary to achieve a clean surface. If there is a post space, it can be cleaned the same way, but after flooding the space with 95 per cent ethanol, use a Versa-brush (Vista) turning at approximately 500 rpm to be assured of getting the post space walls free of sealer. After this step, the post used can be tried in to be sure it fits passively. The FibreKor post kit (Pentron) has a very good selection of sizes (Fig. 20). The 1.125 mm (lavender colored lid on tube) fits most of the post spaces passively. If the fit of the post is not passive but is the desired size, a very fine, tapered diamond is used to taper the apical end until it does fit passively into the space. Note: A post space should never be enlarged to fit the post. The post should always be adjusted to fit the post space. A post should only be used for retention of the core buildup and does not strengthen the tooth.



Rinse and air dry the access, and then flood it with 37 per cent phosphoric acid gel (Ultradent), letting it remain for approximately 20 seconds to accomplish the proper etch of the walls. Rinse very thoroughly and air dry, being careful not to desiccate the dentinal surface. Apply two coats of Tenure A&B (Den Mat) for conditioning of the dentin, air drying between each and inject Core Paste (Den Mat) to fill the access completely. If needed, the FibreKor post can be cemented with the initial application of Core Paste. It is a good idea to also coat the fiber post with the Tenure A&B before insertion into the newly injected, soft Core Paste. Note: Do not use the Tenure Uni-Bond for this step, as it is thicker in consistency and may affect the passive fit of the post.

Core Paste is one of the most forgiving and easy-to-use materials. It is auto-cure, has adequate working time and can be "stacked" or added onto, so enough bulk is easy to achieve for the desired buildup, and it always sets up in two to three minutes. The tooth can then be rough prepped and returned to the referring doctor (Figs. 21a-c). At any rate, the endodontically treated tooth is ready for the final crown prep and impression if the doctor wishes to do it at the same appointment.

Respect for the endo-pros relationship

Current technology has allowed endodontic treatment to achieve a very high degree of success when the coronal seal has been accomplished. Weine has stated that more endodontically treated teeth are lost due to improper restoration than to endodontic failure.⁸ More recently, it was shown that in 1.5 million people over an eight-year period, there was a 97 per cent success rate for endodontically treated teeth. Of the 3 per cent that failed, 85 per cent of those had no coronal coverage.⁹ It is necessary to appreciate some basic restorative/prosthetic principles to establish a degree of predictability we want to achieve with the System "S" protocol of treatment.

It has been shown that teeth do flex during normal function. The less radicular structure present, the weaker the tooth will be. And the weaker the tooth, the more it flexes. The more it flexes, the more micro leakage occurs and it becomes only a matter of time before the tooth fails. The canal system can be contaminated due to micro leakage, by fracture due to lack of radicular strength, or the crown/post/core can break or come out. If a restoration is placed, entirely based on the retention of the foundation restoration, it is not an issue of whether the restoration will fail; it is a matter of when it will fail.¹⁰

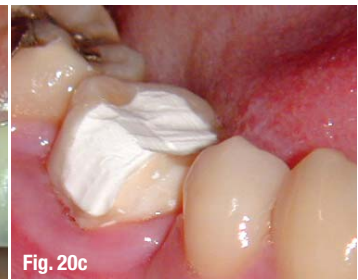
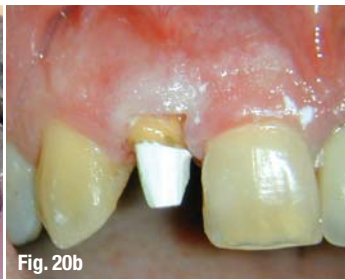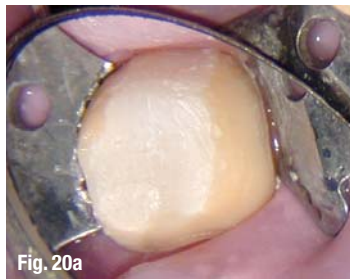
It is critical that a minimal circumferential ferrule of 1 to 2 mm be established for retention of the restoration. A biological width of approximately 2 to 3 mm is required between the osseous crest and the cervical margin of the restoration.¹¹ Therefore, a minimum total of 3.5 mm is necessary between the intended cervical margin of the restoration and the osseous crest.

Another important consideration for conserving root structure is the necessity of a post for retention. It is worth repeating, "A post is only indicated if retention of the core is inadequate without it. Posts are only indicated when needed for retention. The post space must never be shaped to fit the post. Instead, the post must be shaped to fit the existing post space." The more radicular substance removed, the weaker the tooth. Posts never strengthen a tooth.

Conservation of the radicular structure also needs to be considered when accessing and shaping the canal system. Only enough tooth substance should be removed to achieve vision and desired shape needed to completely disinfect, clean and obturate the entire canal system. If the access is compromised, the correct shape may be difficult if not impossible to achieve. Likewise, if we compromise the shape, the cleaning and obturation will also not be as complete as desired for predictability. The author is amused by anyone willing to compromise access and shaping in the name of

Fig. 20 The FibreKor posts have a wide selection of posts with good retention and are easy to use.

Figs. 21a–c—The canal systems have been filled 100 per cent and are ready for restorations without any concern for micro-leakage until they are more permanently restored.



tooth conservation. What good does all that tooth structure do if the tooth is lost to disease?

Once the referring doctors are made aware of the favorable benefits that will be derived, it becomes difficult for a conscientious person to object to this concept of eliminating untoward possibilities that can lead to failure of treatment.

Conclusion

The System “S” protocol demands thoroughness in treatment of the entire canal system. The author uses a Calamus for obturation, but carrier-based techniques of using warm GP can be used with the same degree of success, as long as they are done correctly. System “S” requires a commitment to complete all six steps to avoid the many pitfalls that present themselves during treatment of the entire endodontic canal system.

A survey of endodontists taken about nine years ago stated that 38 per cent always used an SOM, 30 per cent sometimes used it, and 32 per cent never used it.¹² Hopefully, things have changed. The use of an

SOM is essential for us, as “endo-doers,” to achieve the high level of predictability our current technology allows us to deliver. We only know what we see, and if we don’t see it we don’t know it. A good example is the high percentage of fourth canals (93 per cent) that can be found in the maxillary molar segment. The clinical use of the SOM significantly increased the number of canals that were discovered.¹³ If these canals are not found, and the operator doesn’t take the time to locate and treat them, the predictability of success will be far less. It behooves all of us to do everything humanly possible to give our patients dental treatment that will create the health they expect from our profession.

In general, our current endodontic vision has been directed to treatment of the apical half of the root canal system. It should not be a problem integrating the basic principles of bonding technology, restorative principles and post core placement into our normal endodontic treatment protocol. We, as a specialty, should be thinking in terms of being responsible for the entire canal system and doing everything humanly possible to increase the predictability of our treatment. When endodontic treatment fails, it seems like everyone “stands around in a circle and points at one another.” Adhering to proven principles eliminates the probability of contamination of the canal system by providing a solid foundation for the restorative aspect of the patient treatment.

Obviously, those who are so concerned with the endodontic lack of respect for radicular structure have not witnessed what often happens to that same tooth when preparing it for a crown. It is imperative for the endodontic and restorative to be a team, working together for predictability, in the interest of the patient.

Our job as “endo-doers” is to learn, become teachers and educate the patients, staff and doctors we work with, so we can achieve dental health as a team. Let’s not “cave into” the demands of public convenience or political pressure, but rather be governed by proven dental principles, so we can achieve predictable endodontic success, saving the teeth our patients are born with. Isn’t that what endodontics is all about?_

Editorial note: A complete list of references is available from the publisher.

Acknowledgements

As with any article, there is always the support and background help that nobody ever sees. I wish to thank my wife, Barbara, for her support while working on this article. Also, sincere appreciation to Dr William “Ben” Johnson, Dr Stephen P. Niemczyk and Dr Clifford J. Ruddle for always being there to give advice and help when I needed it.

about the author

roots



John J. Stropko received his DDS from Indiana University in 1964. For the next 24 years he practiced general and restorative dentistry. In 1989, he received a certificate for endodontics from Boston University and has recently retired from his private practice limited to microendodontics in Scottsdale, Arizona. Stropko is an internationally recognized authority on microendodontics and has performed numerous live microendodontic and microsurgical demonstrations. He has been a visiting clinical instructor at the Pacific Endodontic Research Foundation (PERF); an adjunct assistant professor at Boston University; an assistant professor of graduate clinical endodontics at Loma Linda University; a member of the endodontic faculty at the Scottsdale Center for Dentistry in Scottsdale, Arizona, as an instructor of microsurgery; and is a co-founder of Clinical Endodontic Seminars. His research on in-vivo root canal morphology has been published in the *Journal of Endodontics*. He has published in several journals and texts, is the inventor of the Stropko Irrigator, and is an internationally known speaker. Stropko and his wife, Barbara, currently reside in Prescott, Arizona. Contact him at docstropko@gmail.com

Disclosure: Dr Stropko is a distributor of the Stropko Irrigator and receives royalties from Dentsply International.

2 0 1 3



GREATER NEW YORK DENTAL MEETING

SCIENTIFIC MEETING:
Friday, November 29 -
Wednesday, December 4

EXHIBIT DATES:
Sunday, December 1 -
Wednesday, December 4

NO PRE-REGISTRATION FEE

Attend At No Cost
Never a pre-registration fee at the
Greater New York Dental Meeting

Mark Your Calendar
Educational Programs:
Friday through Wednesday,
November 29 - December 4

Exhibits:
Sunday through Wednesday,
December 1 - December 4

More than 600 Exhibitors
Jacob K. Javits Convention Center
11th Avenue between 34-39th Streets (Manhattan)

Headquarters Hotel
New York Marriott Marquis Hotel

Live Dentistry Arena - No Tuition

Latest Dental Technology & Scientific Advances

More Than 350 Scientific Programs
Seminars, Hands-on Workshops, Essays & Scientific
Poster Sessions as well as Specialty and Auxiliary
Programs

Educational Programs in various languages

Social Programs for the Entire Family

**ENJOY NEW YORK CITY AT ITS BEST DURING THE
MOST FESTIVE TIME OF THE YEAR!**

**The Largest Dental Meeting/Exhibition/
Congress in the United States**

89th ANNUAL SESSION



For More Information:
Greater New York Dental Meeting®
570 Seventh Avenue - Suite 800, New York, NY 10018 USA
Tel: (212) 398-6922 / Fax: (212) 398-6934
E-mail: victoria@gnydm.com / Website: www.gnydm.com



WWW.GNYDM.COM

Sponsored by: The New York County Dental Society and The Second District Dental Society

Raising the bar for endodontic success: Where we were, where we are and where we are going

Author_ Dr Gary Glassman, Canada

_Vince Lombardi so eloquently stated, "Practice does not make perfect. Only perfect practice makes perfect." In other words, we can perform a procedure repeatedly over and over again and not obtain the expected outcome for success. We must continually advance in all disciplines of dentistry in order to provide our patients with the most predictable treatment regimens possible, understanding the greatest variable that stands in our way is the human variable. Elevating the standards of endodontic care is inextricably tied to an important dynamic in our armamentaria.^{48,50}

The objective of endodontic treatment has continue to be a constant since root canal treatment was first performed; the prevention or treatment of apical periodontitis such that there is complete healing and an absence of infection,¹ while the overall long-term goal is the placement of a definitive, clinically successful restoration and preservation of the tooth. After all, the main objective in dentistry is to retain what nature has created!

From about 1985 to 1995 there was more change in clinical endodontics than in perhaps the previous 100 years combined. In these 10 years, clinical endodontics changed forever with the emergence and development of four very important technologies: the dental operating microscope (DOM), ultrasonics, nickel-titanium rotary file systems and mineral trioxide aggregate (MTA).^{2,3,50}

_Where We Were

The Dental Operating Microscope

Superior vision became attainable with the integration of the dental operating microscope (DOM). Diagnostically, the operating microscope is an indispensable aid in locating cracks and tracking vertically fractured teeth.^{2,4} It allows a more detailed view of root canal intricacies, enabling the operator to more

efficiently examine, clean and shape complex anatomy.⁵ It provides superior resolution, thereby aiding the removal or bypassing of separated canals.⁶ A microscope provides an improved surgical technique allowing for smaller osteotomies, shallower bevels and the location of isthmi and other canal irregularities,⁷ thereby allowing unprecedented success rates of up to 96.8 per cent.⁸ A DOM has significantly shown to improve the probability of locating a second mesial buccal canal in maxillary molars. Baldassari-Cruz et al.⁹ showed that the MB-2 canal was located in 90 per cent of maxillary molars with the operating microscope but only 52 per cent with unaided vision.⁵⁰

Sonics

Piezoelectric ultrasonic energy, in conjunction with the DOM, drove microsonic (sonic and ultrasonic) instrumentation techniques that are minimally invasive, efficient and precise.² Refinement of access openings in a controlled and predictable manner, locating calcified canals with a reduced risk of perforation, removal of attached pulp stones, removal of intracanal obstructions (separated instruments, root canal posts, silver points and posts) and removal of the smear layer, biofilm and remaining debris are just some of the many uses that microsonics are capable of doing.^{2,10,11}

In surgical endodontics, specially designed retro tips are used ultrasonically for superior root-end cavity preparation. This allows minimal removal of root structure down the long access of the root canal without the creation of a bevel for surgical access. This subsequently reduces the number of exposed dentinal tubules and minimizes apical leakage.^{10,50}

Nickel Titanium Instruments

Canal preparation procedures became more predictably successful with the emergence of nickel titanium files (NiTi) files.² This super-elastic alloy has

shape memory, allowing for better maintenance of the original canal anatomy. These files produce less extrusion of debris, allow greater cutting efficiency and reduce the time for canal shaping compared to stainless-steel files. They are biocompatible, anti-corrosive and do not weaken following sterilization.^{12,13} Although full rotary has been the mainstay for nickel-titanium systems for years, reciprocating motors have taken the market by storm by allowing less debris extrusion and quicker negotiation to the apices and less file fatigue.

Mineral Trioxide Aggregate

This decade of extraordinary change concluded with the introduction of mineral trioxide aggregate (MTA).² This remarkable and biocompatible restorative material has become the standard for pulp capping and has salvaged countless teeth that previously had been considered hopeless.² In vital pulp therapy, when MTA is used as a direct pulp cap to maintain pulp vitality, studies have shown that these areas were free of inflammation and all of them had calcified bridge formation after five months.⁴⁹

MTA has proved to be the ideal pulpotomy agent in terms of dentin bridge formation and preserving normal pulpal architecture.⁴⁹ MTA produces favourable results when it is used as a root-end filling material in terms of lack of inflammation, presence of cementum and hard-tissue formation.⁴⁹ It is used to repair both furcal and lateral perforations with a relatively high degree of success and to seal both internal and external resorptive defects from an orthograde and retrograde approach.⁴⁹

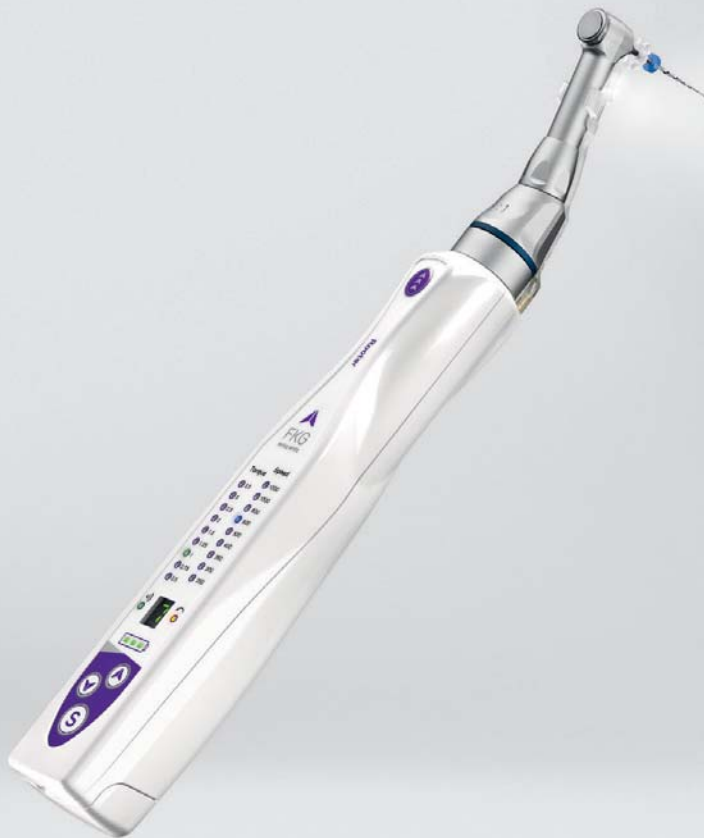The treatment of teeth with open apices and necrotic pulps has always been a challenge for the dental practitioner. MTA can effectively be used as an apical barrier in teeth with necrotic pulps and open apices.^{49,50}

_Where We Are

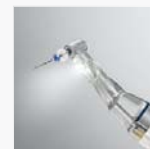Irrigants and Irrigant Delivery Systems

Perhaps the greatest international attention in recent years has focused on methods to improve endodontic disinfection in the root canal system.²

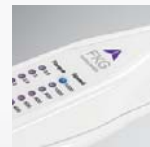AD



► **Rooter**, light up your work



LED
Ergonomic
and light



250 – 1200 rpm



Auto-reverse
disengage mode
10 presetable
torque/speed
programmes

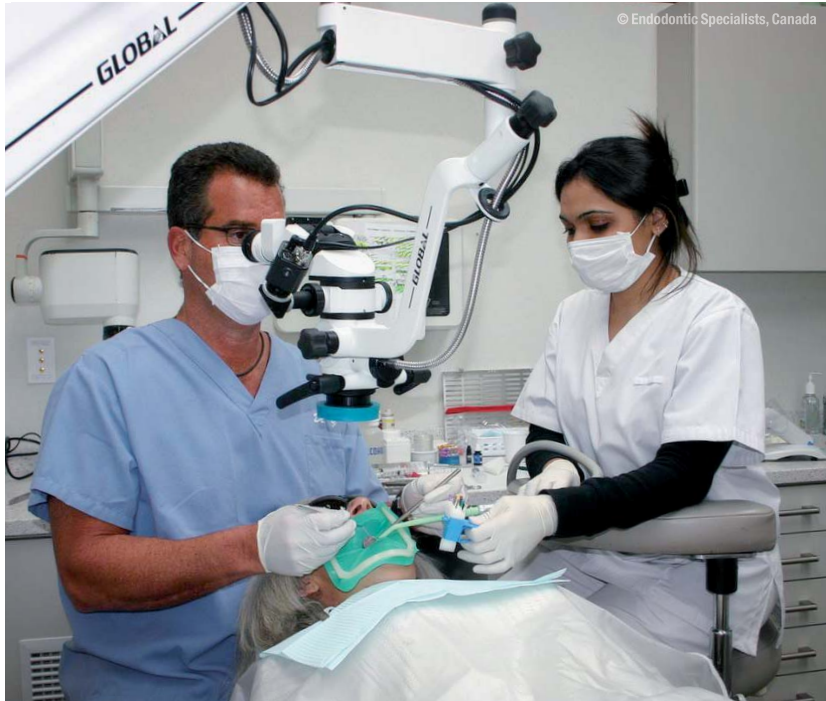

Fig. 1 The operating microscope has become an indispensable aid in the field.

The desired attributes of a root canal irrigant include the ability to dissolve necrotic and pulpal tissue, bacterial decontamination with a broad antimicrobial spectrum, the ability to enter deep into the dentinal tubules, biocompatibility and lack of toxicity, the ability to dissolve inorganic material and remove the smear layer, ease of use and moderate cost. The combination of sodium hypochlorite and EDTA has been used worldwide for antiseptics of root canal systems.¹⁵ Sodium hypochlorite has the unique ability to dissolve necrotic tissue and the organic components of the smear layer.¹⁶⁻¹⁸ It also kills sessile endodontic pathogens organised in a biofilm.^{19,20} There is no other root canal irrigant that can meet all these requirements, even with the use of methods such as increasing the temperature²¹⁻²⁵ or adding surfactants to increase the wetting efficacy of the irrigant.^{26,27}

Deminerizing agents such as EDTA have therefore been recommended as adjuvants in root canal therapy in combination with sodium hypochlorite^{20,28} as they dissolve inorganic dentin particles and aid in the removal of the smear layer during instrumentation.²⁹ It is very important to note that while sodium hypochlorite has unique properties that satisfy most requirements for a root canal irrigant, it also exhibits tissue toxicity that can result in damage to the adjacent tissues, including nerve damage should sodium hypochlorite incidents occur during canal irrigation.¹⁵ It is therefore very important that irrigant delivery devices are used that not only allow voluminous exchange right to the apex but also deliver them in a safe and effective manner without apical extrusion.

Root canal irrigation systems can be divided into two categories: manual agitation techniques and machine-assisted agitation techniques.¹¹ Manual irrigation includes positive pressure irrigation, which is commonly performed with a syringe and a side-vented needle. Machine-assisted irrigation techniques include sonics and ultrasonics, as well as newer systems such as the EndoVac (SybronEndo, USA), which delivers apical negative pressure (ANP) irrigation,³⁰ the plastic rotary F File (Plastic Endo, Lincolnshire, IL, USA),^{31,32} the Vibringe (Vibringe BV, The Netherlands),³³ the RinsEndo (Air Techniques Inc., USA),⁹ and the Endo-Activator (DENTSPLY Tulsa Dental Specialties, USA). Of all the techniques listed, only the Endo Vac has repeatedly shown to break the apical vapour lock (the column of gas that is formed at the apical 3 mm of the root canal formed by the hydrolysis of organic tissue by sodium hypochlorite), produce a current of irrigant, remove debris and deliver voluminous amounts of irrigant to the apex without the risk of apical extrusion.^{15,50}

Lasers

The integration of lasers is a viable addition to the endodontic armamentarium and has the potential to overcome some of the challenges to successful root canal therapy.⁵¹ Of particular benefit is the ability to avoid vibration pain upon access, even in "hot" teeth that are difficult to anaesthetise, and the three-dimensional ability to remove pulpal tissue, bacteria, smear layers and dentin from canal walls via laser energy and hydrophobic activity. Of particular significance is the ability of laser light to penetrate 1,000 microns into the dentinal tubules.⁵² Bacterial infiltration into dentinal tubules has been reported to be 400 microns⁵³ and chemical rinses have a penetration depth of only 100 microns.⁵⁴ This results in the possibility of bacterial entombment and microleakage. The resulting disinfection and reduction of bacteria in the dentinal tubules is significant with respect to providing unparalleled levels of endodontic success.⁵⁰

Digital Radiography

Digital radiography has significantly reduced treatment time for endodontic procedures with far less exposure compared to conventional film. High-resolution digital images are instantaneously generated and easily manipulated for enhanced diagnostic performance. Digital storage of images is simple, allowing quick transfer and communication.^{34,35,50}

Cone-Beam Computed Tomography (CBCT)

What digital radiography has provided us for imaging in the present, CBCT (cone-beam computed

tomography) will carry us into the future. CBCT technology has been around since the 1980s, however, only recently has it become a viable option for the endodontic office.³⁶ Cone-beam technology uses a cone-shaped beam of radiation to acquire a volume in a single 360-degree rotation, similar to panoramic radiography.³⁶ It has advantages over conventional medical CT, including increased accuracy, higher resolution, scan-time reduction and dose reduction.³⁶ Endodontic uses include but are not limited to diagnosis of odontogenic and non-odontogenic cysts, cysts vs. granulomas,³⁷ location of untreated canals and the diagnosis of certain root fractures. The extent of internal, external and cervical resorption can be accurately mapped and the presurgical evaluation of anatomic landmarks can be precisely surveyed.^{36,50}

Regenerative Endodontics

Regenerative endodontics has become an exciting possibility, allowing stem cells found in the dental pulp to regenerate and replace diseased tissue with healthy tissue and revitalize a tooth.³⁸ The vascularisation of necrotic teeth with immature apices can be a significant challenge to the clinician. In the past, apexification procedures have allowed root length to continue, but the walls of the roots remained thin, allowing the high risk and probability of fracture. Revascularization techniques provide such a tooth the ability to not only continue linear root growth, but also to allow increased thickness of dentin on the root canal walls, which will ultimately allow retention of the natural tooth, obviating the need for extraction and implant replacement.³⁹ The technique is uncomplicated and easy to learn. Through the use of a specialized tri-antibiotic mixture, blood clot inducement and its coronal sealing with MTA, many necrotic and immaturely developed teeth that would otherwise be extracted can now be retained.^{40,50}

Endodontics vs. Implants

With the advent of implants, patients were able to maintain their occlusion and health in those functional areas that were missing teeth. Unfortunately implants are also being used to replace viable teeth.⁴¹

If a tooth is sound from both a restorative and periodontal aspect, then endodontic therapy should be the treatment of choice. However, if a tooth is compromised from a restorative or periodontal perspective, then an implant may be considered.⁴² Both root canal therapy and orthograde retreatment as a first and second line of intervention are more cost-effective compared to implant therapy. Current cost structures indicate that implants are limited to a third line of intervention.⁴³

Confidence and embracing the advances in the science and art of endodontics is imperative if we are to continue to achieve and improve the successes that we have achieved. There are numerous studies that support the excellent clinical results of endodontic treatment.⁴⁴ Kim and Iqbal conducted a review of the relative success rates of endodontic treatment and implants. The literature review found equal survival rates of single-tooth implants and endodontically restored teeth. Both therapies had overall survival rates of 94 per cent, thus providing predictable outcomes.^{45,46} However, implants have a longer mean and median time to function, and have a higher frequency of postoperative complications requiring additional treatment intervention.^{47,50}

Where We Are Going

Science and research will elevate the specialty of endodontics to its rightful pinnacle.⁴⁸ The cornerstone of our specialty's integrity and relevance must be built on a strong foundation of randomized clinical trials and evidenced-based endodontics.⁴⁸ The future of endodontics is bright as we continue to develop new techniques and technologies that will allow us to perform endodontic treatment painlessly and predictably, and continue to satisfy one of the main objectives in dentistry, that being to retain the natural dentition.^{14,50}

Editorial note: A complete list of references is available from the publisher.

about the author

roots



Gary D. Glassman, DDS, FRCD(C) graduated from the University of Toronto, Faculty of Dentistry in 1984 and was awarded the James B. Willmott Scholarship, the Mosby Scholarship and the George Hare Endodontic Scholarship for proficiency in Endodontics. A graduate of the Endodontology Program at Temple University in 1987, he received the Louis I. Grossman Study Club Award for academic and

clinical proficiency in Endodontics.

The author of numerous publications, Gary is on staff at the University of Toronto, Faculty of Dentistry in the graduate department of endodontics and Adjunct professor of dentistry and director of endodontic programming at UTech in Kingston, Jamaica.

Dr Gary Glassman maintains a private practice in Toronto.

www.rootcanals.ca

Accuracy and consistency of four electronic apex locators in the presence of different irrigants

Author | Dr Jorge Paredes Vieyra, Dr Javier Jimenez Enriquez & Fernando Calleja Casillas, USA

Abstract

Introduction

The aim of this study was to examine the accuracy and consistency of four electronic apex locators (EALs) in the presence of various intra-canal irrigants used in non-surgical endodontic therapy in an *in vivo* model. The null hypothesis is that the irrigants evaluated largely did not have an effect on the accuracy and consistency of the EALs.




Fig. 1

Fig. 2

Fig. 1 Apical view of tooth 41 under 20x magnification.

Fig. 2 Apical view of tooth 12 under 20x magnification.

Methods

The working length (WL) was determined electronically of 390 teeth (248 maxillary and 142 mandibular teeth), which had a total of 1,095 root canals and completely formed apices, with a #15 K-file as the measuring file. Measurements were taken in sequence once the canals had been irrigated with 5 ml of 2.5% NaOCl, 2% CHX, and 17% EDTA, respectively, with an endodontic syringe and a 30-gauge needle. The data was analysed using Student's t-test, and significance was set at $p < 0.05$.

Results

The statistical analysis revealed no significant differences in the accuracy of the four EALs in determining the WL when 2.5% NaOCl, 2% CHX, and 17% EDTA were used as irrigants ($p = 0.05$). For anterior

teeth and premolars, the Root ZX, Elements, PAL and Ray-pex 5 EALs located the apical constriction 95.29% of the time in CHX, 95.29% in NaOCl, 95.88% in CHX, and 94.11% in CHX, respectively. For molars, Root ZX, Elements, PAL and Ray-pex 5 located the apical constriction 95.34%, 95.34%, 92.38% and 98.63% of the time in EDTA, respectively.

Conclusion

The results showed that no statistically significant differences in accuracy and consistency were found between the four EALs.

Correct determination of WL is a key factor that can influence the outcome of root-canal treatment.¹ Failure to determine the correct WL might result in overfilling or underfilling, and has the potential to increase the failure probability of root-canal treatment within a ten-year observation period from around 10% to around 50% as shown in a retrospective clinical study.²

Anatomically, the apical constriction (AC)³ is a logical location for WL because it often coincides with the narrowest diameter of the root canal.⁴ However, locating the AC clinically is problematic. Dummer et al.⁵ concluded that it is impossible to locate the AC clinically with certainty because of its position and topography.

The cemento-dentinal junction (CDJ) is thought of as the ideal limit for endodontic instrumentation because of the small diameter of the root canal at that point. Moreover, it has been established that endodontic procedures must take place inside the root canal and should not affect the cementum, thereby preserving the remaining apical periodontal tissue.⁶⁻⁹

The CDJ has also been suggested as the ideal place for WL determination because it represents the transition between pulpal and periodontal tissue.¹⁰ The

location of the CDJ is widely accepted as being 0.5–0.75 mm coronal to the apical foramen¹¹ but, as with the AC, the exact location of the CDJ is impossible to identify clinically. In general, the CDJ is considered to be co-located with the minor foramen;¹² however, this is not always the case.⁵

The consistency of a device describes the regularity of its function. A measuring device that is able to give a reading each time used is considered to function consistently, regardless of the quality of the performance. The dysfunction (inconsistency) may be recognised when the scale bars on the display of EALS are either unstable (jump from one point to the other) or do not appear at all.

The quality of the performance or measurements can be described in terms of reliability, which is the probability that a device will perform a required function (e.g. high accuracy, repeatability, and reproducibility)¹³ under stated conditions (e.g. on patients) for a stated period of time. The reliability of apex locators in terms of accuracy and repeatability is well studied,^{14–18} but there is little data on the consistency or regularity of the function of EALS.

As far as we know, the clinical consistency of the function of EALS has not been studied. A limited number of *ex vivo* studies have described the inconsistent function of EALS as a secondary finding.^{8,19} Furthermore, the clinical factors influencing the function of EALS need to be studied.

To date, no study has been published on the effects of irrigants on the accuracy and consistency of EALS. The purpose of this study was to examine the accuracy and consistency of four EALS in the presence of various intra-canal irrigants used in non-surgical endodontic therapy in an *in vivo* model.

Materials and methods

This study took place at the faculty of dentistry of the Autonomous University of Baja California in Tijuana, Mexico. The subjects review committee approved the study and all the participants were treated in accordance with the Declaration of Helsinki.

Calculation of sample size by setting the power of the study to 90%, standard deviation of the outcome to 1 mm based on earlier studies,²⁰ and the minimum detectable difference to 0.5 mm yielded a minimum number of 1,095 root canals for this study. Consequently, 390 teeth (248 maxillary and 142 mandibular teeth), which had a total of 1,095 root canals and completely formed apices, were selected (Table 1). All selected teeth had mature apices with no radiographic signs of root resorption. Exclusion criteria

	Number of canals		
	Number	Maxillary	Mandibular
Central incisor	44	21	13
Lateral incisor	54	37	7
Canine	27	21	6
1 st premolar	27	18 (36)	9 (18)
2 nd premolar	18	11 (22)	7 (14)
1 st molar	142	98 (392)	44 (176)
2 nd molar	78	41 (164)	37 (148)
Total	390	248 (694)	123 (382)

Table 1 Distribution of 390 teeth (1,095 root canals).

were previous endodontic treatment, non-restorable teeth, internal or external root resorption, intra-canal calcification, active systemic disease, and physical or mental disability. The selected teeth had been scheduled for extraction due to periodontal disease or for orthodontic reasons from adult patients (between 21 and 65 years old).

All teeth responded positively to hot and cold sensitivity tests, and clinically all pulps were confirmed to be vital on entry into the pulp chamber. Informed consent was obtained in writing from each patient in accordance with the approval of the study by the ethics board of the faculty of dentistry of the Autonomous University of Baja California. All clinical procedures and measurements were performed by the author.

A standardised periapical radiograph was taken for each tooth in buccolingual projection to allow proper selection. After local anaesthetic had been administered using 2% lidocaine with 1:100,000 epinephrine (Septodont) and rubber dam isolation, the tooth was disinfected with 5.25% NaOCl (Ultra bleach).

The cusps or the incisal edges of the teeth were flattened with a diamond bur (DENTSPLY Maillefer) to obtain a stable reference point for all measurements. All caries and existing metal restorations were removed, and endodontic access cavities made with sterile high-speed #331 carbide (SS White) and Zekrya Endo burs (DENTSPLY Maillefer). After identification of the root canals, the cervical third of each canal was flared with an SX file and S1 ProTaper file (DENTSPLY Maillefer).

Measurements were taken in sequence after the canals had been irrigated with 5 ml of 2.5% NaOCl, 2% CHX (Vista Dental), and 17% EDTA (Vista Dental), respectively, with an endodontic syringe and a 30-gauge needle. Excess fluid was removed, but no attempt was made to dry the canal. Between meas-

EAL	-1 mm			-0.5 mm			AC			+0.5 mm			+1 mm		
	n = 170			n = 170			n = 170			n = 170			n = 170		
	NaOC	CHX	EDTA	NaOC	CHX	EDTA	NaOC	CHX	EDTA	NaOC	CHX	EDTA	NaOC	CHX	EDTA
Root ZX	-	-	-	8	8	12	158	162	158	4	-	-	-	-	-
Elements	-	-	1	8	8	11	162	158	155	-	4	-	-	-	-
PAL	-	-	1	10	7	11	156	160	156	4	3	-	-	-	-
Ray-plex 5	-	-	0	8	7	12	159	163	158	3	-	-	-	-	-

P = 0.05
 AC = apical constriction
 (+) and (-) values indicate file tip beyond (+) or short (-) of the AC

Table II

Table 2 Distance of file tip from the apical constriction determined by Root ZX, Elements, PAL, Ray-plex 5 and a radiograph (anterior teeth and premolars).

measurements, the canals were irrigated with 10 ml of distilled water and dried with paper points before application of the next irrigant. A computerised method of randomisation selected the order in which the irrigants and the EALs were used.

Each EAL was used in accordance with the manufacturer's instructions. The AC of each tooth and double stoppers were used to reduce the possibility of stopper movement during measurements. Measurements were considered to be valid if the reading remained stable for at least 5–10 seconds.

For Root ZX (Morita),²¹ the buccal clip was attached to the patient's lip, and the probe was connected to a #15 stainless-steel K-file. The file was advanced within the root canal to a point just beyond the major foramen, as indicated by the flashing APEX bar on the liquid crystal display of the EAL. When the file was in position, the LCD display showed a flashing bar between APEX and 1.

The AC was located with Elements (SybronEndo) by advancing the same size K-file in the canal until the locator indicated that the AC had been reached.²² The two silicone stoppers on the file were positioned at the reference point and the insertion length measured. The sequence of testing alternated between the two locators.

For PAL (NSK),²³ the AC was located at the 0.0 mark, at which point the EAL produced a constant audible tone.

For Ray-plex 5 (DENTSPLY), the reading was recorded when all three green bars lit up. The file was advanced within the root canal to the major foramen (red light) and retracted until the flashing green bars appeared.

For determining consistency, an EAL was considered inconsistent if the WL determination in one or more of the root canals was inconsistent. The EAL was considered consistent when all root-canal measure-

ments within a tooth were consistent. The consistency of the EALs was determined by calculating the number of consistent measurements and the 99% confidence interval. The significance of these results^{13,14,18} regarding the consistency of the EALs was calculated by performing a regression analysis. The unit of further analysis was the root canal and not the tooth. The percentage of acceptable long and short measurements and the corresponding 99% confidence interval were calculated. The function of the EAL was recorded as consistent when the scale bars of the EAL were stable and their movement corresponded with the movement of the measuring file in the root canal.

The AC was located radiographically by advancing the #15 K file until its tip was 1 mm from the radiographic apex (determined from a pretreatment parallel technique radiograph). A radiograph was exposed, and if the file tip was seen not to be 1 mm from the radiographic apex the file was repositioned and another radiograph taken to ensure that it was. The distance from the stop to the tip was the insertion length. The file was then reinserted to the insertion length (1 mm from the radiographic apex) and cemented in place with GC Fuji II LC dual-cure glass ionomer cement (GC Corporation). The file handle was sectioned with a high-speed bur, and the tooth was extracted without disturbing the file by an experienced oral surgeon, immersed in 2.5% NaOCl for 30 minutes to remove any residual organic tissue from the root, and then kept in a 1% thymol solution in a numbered specimen cup.

The apical 5 mm of the root was clipped in a longitudinal direction using a fine, flat cylinder diamond bur (Brasseler) under a stereomicroscope (Zeiss Stemi 2000-C, Carl Zeiss) at 16x magnification to expose the file tip.

The remaining tooth structure was removed carefully until the file tip and the root canal were both visible. A digital photograph was taken and stored in Adobe Photoshop 5.5 (Adobe Systems), and the distance from the file tip to the minor foramen was

EAL	-1 mm			-0.5 mm			AC			+0.5 mm			+1 mm		
	n = 880			n = 880			n = 880			n = 880			n = 880		
	NaOC	CHX	EDTA	NaOC	CHX	EDTA	NaOC	CHX	EDTA	NaOC	CHX	EDTA	NaOC	CHX	EDTA
Root ZX	-	-	-	31	42	41	836	817	839	13	21	-	-	-	-
Elements	-	-	-	41	42	41	817	817	838	22	21	-	-	-	-
PAL	-	-	-	35	41	38	795	789	813	21	21	-	-	-	-
Ray-plex 5	1	-	-	34	42	41	853	846	868	21	21	-	-	-	-

P = 0.05
 AC = apical constriction
 (+) and (-) values indicate file tip beyond (+) or short (-) of the AC

Table III

measured using Image Tool 3.1 software (University of Tennessee Health Science Center).

The distance from the file tip to the AC was measured. This distance was recorded as being (a) -1 mm from the AC; (b) -0.5 mm from the AC; (c) at the AC; (d) +0.5 mm from the AC; and (e) +1 mm from the AC. A minus symbol (-) indicated a file short of the AC, and a plus symbol (+) indicated that it was beyond the AC.

The position of the file tip in each root canal was evaluated by two examiners. If the two examiners disagreed, a third previously calibrated researcher was asked to make the final decision. The final WL was established to be 0.5 mm coronal to the major foramen.²⁴ Once the actual length to the AC had been measured visually, the distance from the AC determined by the four EALs was also calculated (-1 mm from the AC, -0.5 mm from the AC, etc.), by comparing their insertion lengths to the actual length (i.e. distance to the AC; Tables 2 & 3).

The measurements obtained (accuracy and consistency) by the four EALs and radiographs relative to the actual location of the AC with three different irrigants were compared using a paired samples t-test, chi-squared test and repeated measures ANOVA conducted at the 0.05 level of significance.

_Results

The statistical analysis revealed no significant differences in the accuracy of the four EALs in determining the WL when 2.5% NaOCl, 2% CHX, and 17% EDTA were used as irrigants (*p* = 0.05). For anterior teeth and premolars, Root ZX, Elements, PAL and Ray-plex 5 located the AC 95.29% of the time in CHX, 95.29% in NaOCl, 95.88% in CHX, and 94.11% in CHX, respectively. For molars, Root ZX, Elements, PAL and Ray-plex 5 located the AC 95.34%, 95.34%, 92.38% and 98.63% of the time in EDTA, respectively. There were no statistically significant differences between the four EALs, but there was a difference between the EALs and radiographs (Tables 2 & 3).

For anterior teeth and premolars, two of the measurements were 1 mm short of the AC. For anterior teeth and premolars, 18 of the measurements were 0.5 mm beyond the AC. For molars, 1.47%, 2.5%, 2.3% and 2.3% of the measurements using Root ZX, Elements, PAL and Ray-plex 5, respectively, were 0.5 mm beyond the AC (Tables 2 & 3).

No EAL measurements were 1 mm beyond the AC for anterior teeth, premolars or molars. There were no statistically significant differences between the four EALs.

The statistical analysis revealed no significant differences in the consistency of the four EALs in determining the WL when 2.5% NaOCl, 2% CHX, and 17% EDTA were used as irrigants (Table 3).

_Discussion

The present study was performed to examine the accuracy and consistency of four EALs in the presence of various intra-canal irrigants used in non-surgical endodontic therapy in an *in vivo* model. Earlier studies have demonstrated that EALs often yield inaccurate readings in the presence of fluids.^{25,26} However, the use of irrigants and their benefits in endodontics have been demonstrated, and most clinicians use the irrigants that were used in this study for their antimicrobial and tissue-dissolving abilities. Our results showed that the irrigants evaluated largely did not have an effect on the accuracy of the EALs.

The use of electronic devices to determine WL has gained popularity. When using them, an important consideration is being aware of the possible sources of error, such as metallic restorations, salivary contamination, dehydration, etc. However, as shown in this and other studies, the accuracy of EALs is superior to radiographs.^{19,27,28}

One of the reasons that a radiographically determined WL lacks accuracy is that it is based on the radiographic apex rather than the apical foramen (the end of the canal). WL is obtained with a radiograph by

Table 3 Distance of file tip from the apical constriction determined by Root ZX, Elements, PAL, Ray-plex 5 and a radiograph (220 molars, 880 canals).

Figs. 3a & b Position of the K-file in the canal.



positioning the tip of a file a certain distance (usually 1 mm) from the radiographic apex. However, WL should be based on the location of the AC rather than that of the radiographic apex because the apical foramen frequently is not at the radiographic apex.²⁹ The measurements of the present study were attained in a target interval of ± 0.5 mm to the minor diameter of the AC, using ImageTool 3.1. This clinical tolerance of ± 0.5 mm is considered to be the strictest tolerance. Measurements within this minimal tolerance are very accurate.³⁰

In this study, Root ZX and Elements correctly located the AC in anterior teeth and premolars 95.29% and 95.29% of the time, respectively, whereas the PAL and Ray-plex 5 achieved this 95.88% and 94.11% of the time, respectively. An *in vivo* study by Shabhang²⁶ reported that Root ZX was within 0.5 mm of the AC 96% of the time, a value similar to the present findings. In general, this study also corroborates the findings of other studies³¹ that EALs are more accurate than radiographs are and greatly reduce the risk of instrumenting and filling short of or beyond the canal terminus.

A matter of debate in endodontics is the apical limit of root-canal treatment and obturation. Traditionally, the apical point of termination has been 1 mm from the radiographic apex. Kuttler³ found the average distance between the apical foramen and the AC to be 0.5–0.75 mm and that this distance increases with age because of cementum deposition.

In this study, Root ZX and Elements correctly located the AC in molars 95.34% and 95.34% of the time, respectively, whereas the PAL and Ray-plex 5 achieved this 92.38% and 98.63% of the time, respectively.

The Root ZX and Ray-plex 5 devices showed better scores in consistency in CHX and EDTA because of their superior repeatability,¹⁴ although the consistency of Ray-plex 5 in EDTA was statistically significantly higher than that of Root ZX. Clinically, this difference is not significant (Table 3).

Chapman³¹ found that the AC was located 0.5–1 mm from the apical foramen in 92% of observed teeth. Another study documented the average distance between the AC and the apical foramen to be 0.9 mm and found that 95% of the constrictions were between 0.5 and 1 mm from the apical foramen.⁵ Hassanien³² identified the AC to be at an average distance of 1.2 mm from the apical foramen. In light of these studies, it seems that there is ample reason to establish WL 1 mm short of the radiographic apex and use this reference point as a target for comparison of EALs in terms of measurement accuracy or at least near accuracy.

Our results are in relative agreement with other studies that reported the accuracy to be 73%,³³ 75–91.7%,³⁴ 90%,³⁵ and 89–100%.^{36,37} The different results obtained in previous studies could be explained partly by the nature of the teeth and irrigants used in those studies.

In the present study, significant differences were observed between the measurements obtained using the four EALs. For example, greater accuracy of Ray-plex 5 was observed in the presence of either 2% CHX or 17% EDTA, compared with the accuracy of Root ZX, Elements and PAL. However, the irrigant used did not influence the accuracy of the EAL.

Conclusion

Under clinical conditions, the EALs identified the AC with a high degree of accuracy and consistency. EALs were accurate and consistent to a high degree, with the potential to reduce the risk of instrumenting and filling beyond the apical foramen greatly.

Within the limitations of this study, the results showed that there were no statistically significant differences in accuracy and consistency between the four EALs. All tested EALs achieved an acceptable determination of the root canal WL.

Editorial note: A complete list of references is available from the publisher.

_contact	roots
<p>Dr Jorge Paredes Vieyra #1513 Suite A 710 E. San Ysidro Blvd. San Ysidro California 92173 USA</p> <p>jorgitoparedesvieyra@ hotmail.com</p>	

FDI 2013 Istanbul Annual World Dental Congress

28 to 31 August 2013 - Istanbul, Turkey

Bridging Continents for Global Oral Health



2013 ISTANBUL

www.fdi2013istanbul.org
congress@fdi2013istanbul.org

Single-visit apexification with MTA following ozone disinfection

A case report

Authors_ Prof. Georgi Tomov & Prof. Elka Popova, Bulgaria

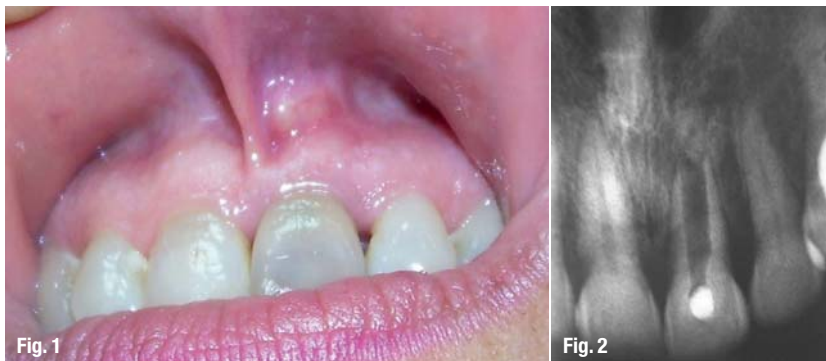

Fig. 1 Pre-op photograph showing discoloured crown of tooth 21, with mild swelling of the periapical zone and a discharging sinus tract.

Fig. 2 Pre-op digital radiograph showing under-formed apex and lesion of endodontic origin following pulp necrosis.

_Abstract

Introduction

Immature teeth with necrotic pulp and large periapical lesions are difficult to treat using conventional endodontic therapy. Materials such as mineral trioxide aggregate (MTA) are indispensable. However, disinfection is still problematic and alternatives such as ozone are under consideration. This case report demonstrates successful healing after single-visit apexification using MTA following ozone disinfection.

Methods

The case report presents a case of traumatised maxillary anterior tooth. The radiographic evaluation revealed an open apex with a very wide canal. The canal was cleaned using intra-canal instrumentation and 0.5% NaOCl and final irrigation with 15% EDTA. In order to ensure sufficient canal disinfection, the canal was treated with ozone for 72 seconds. Subse-

quently, a 4 mm apical barrier (plug) was created with MTA and allowed to set. The root canal was then obturated with thermo-plasticised gutta-percha. The access cavity was sealed with a composite resin restoration.

Results

A one-year follow-up demonstrated a clinically asymptomatic and adequately functional tooth with radiological signs of healing. The positive clinical resolution of this case is encouraging for the use of ozone and white MTA as an apical plug in immature teeth with open apices.

Conclusion

The combination of ozone disinfection and MTA appears to be a valid option for single-visit apexification, with its main advantage being the speed at which the treatment can be completed. Apexification in one visit using ozone and an apical plug of MTA can be considered a predictable treatment and may be an alternative to long-term calcium hydroxide apexification.

_Case report

A 50-year-old female patient presented to the Faculty of Dental Medicine at the Medical University of Plovdiv with a discoloured maxillary left central incisor and sinus tract discharging pus (Fig. 1). The patient gave a history of trauma about 43 years ago. After the acute period, amputation paste was applied to the same tooth by a local dentist. There was no history of severe pain and swelling, or any other symptom, except occasional pus discharge from the sinus

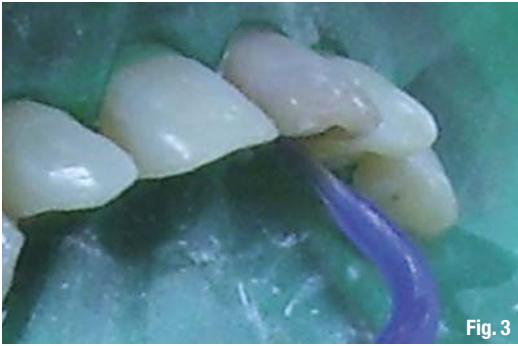

Fig. 3

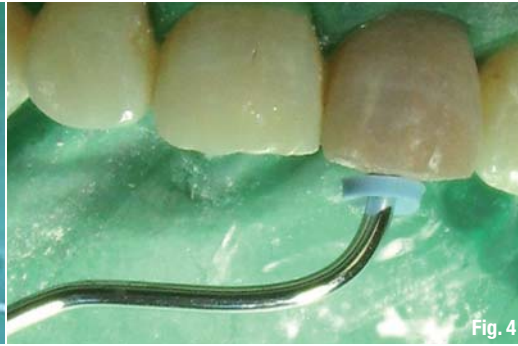

Fig. 4

Fig. 3 _Ozone was generated by Prozone and introduced into the canal via a plastic cannula for 72 seconds (corresponding to 0.672 mg of ozone).

Fig. 4 _MTA apical plug positioning using an endodontic plugger.

tract and moderate discomfort during mastication. Recently, the crown involved had become markedly discoloured, owing to which the patient's facial appearance had become highly unaesthetic. The radiographic examination of the tooth showed a wide canal with an open apex and periapical lesion (Fig. 2). Electric pulp testing was performed on teeth in the area of trauma, that is, from the maxillary left canine to the maxillary right canine. All the teeth gave a positive pulpal response, indicating their vitality, except the involved maxillary left central incisor.

Treatment protocol

Regarding the current clinical guidelines, it was decided to treat the case non-surgically by placing an MTA apical barrier.¹ Adequate isolation was achieved with the use of cofferdam. Once the working length had been determined, the canal was cleaned using a size 80 H-file and gentle but copious irrigation with 0.5% sodium hypochlorite and 15% EDTA as final irrigation. After final drying of the canal prior to obturation, ozone gas produced by the Prozone generator (W&H) was introduced directly into the root canal to within 3 mm of the apex using a slow in-and-out movement of the flexible cannula for 72 seconds, as recommended by the manufacturer (Fig. 3). We used ozone to eliminate any residual bacteria in inaccessible anatomical areas or within the dentinal tubules. White MTA (ProRoot MTA, DENTSPLY Tulsa Dental Specialties) was mixed to a paste consistency with sterile water and delivered to the canal using a Dovan carrier. An endodontic plugger of a suitable size was used to condense the MTA at the apex to about 4 mm in thickness (Fig. 4). A radiograph was taken to confirm its position (Fig. 5). A moist cotton pellet was sealed inside for setting of the MTA. The patient was recalled the next day and the hard set of the MTA was verified with an endodontic file. The remaining portion of the root canals was then closed with thermoplastic gutta-percha and a radiograph was taken (Fig. 6). Intracoronary bleaching was also performed. The sinus tract disappeared two weeks after the treatment (Fig. 7). The 12-month follow-up found an asymptomatic and adequately functioning tooth with radiological signs of healing (Fig. 8).

_Discussion

Until a relatively short time ago, calcium hydroxide has been used to establish an apical hard-tissue barrier in immature open apices.² The time interval for calcium hydroxide apexification has been reported to vary from 12 to 24 months.² This presents possible problems regarding patient compliance and the risk of reinfection if the temporary restoration fails, and predisposes the tooth to fracture.² Moreover, calcium hydroxide is a strong alkali and could irritate periodontal tissue. The barrier produced by calcium hydroxide apexification has been reported to be more porous and weak, and can allow apical micro-leakage.²

MTA has been widely recommended for closure of open apices. It demonstrates good apical seal, biocompatibility, and pulpal and periodontal regeneration capabilities.^{1,3-6} White MTA was preferred over the grey MTA, as it has shown significantly less micro-leakage.⁷

When single-visit apexification with MTA is the preferred treatment protocol, the major problem is ensuring sufficient canal disinfection with respect to the exposed periapical tissue. A low-concentra-

Fig. 5 _Radiograph showing MTA apical barrier.

Fig. 6 _Radiograph showing final root-canal filling.

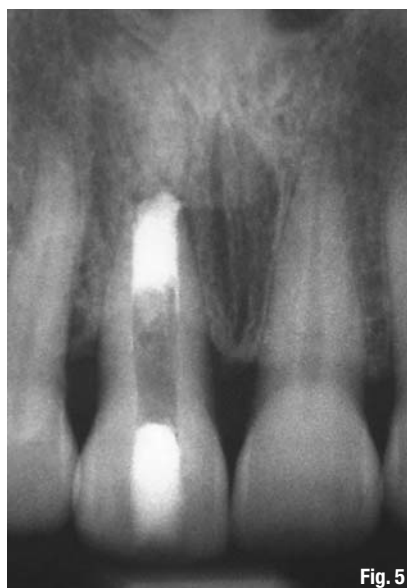


Fig. 5

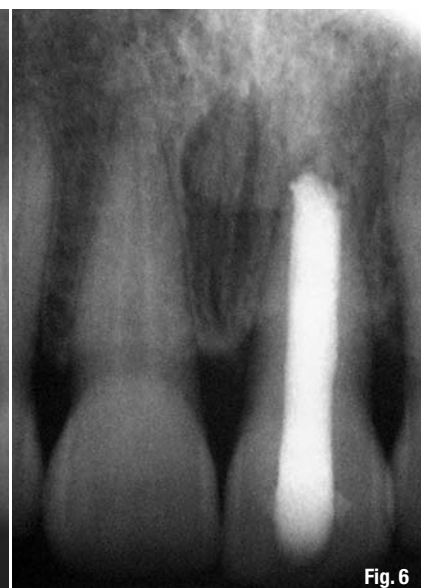

Fig. 6

Fig. 7_ The sinus tract disappeared two weeks after the treatment.

Fig. 8_ The 12-month follow-up found an asymptomatic and adequately functioning tooth with radiological signs of healing.

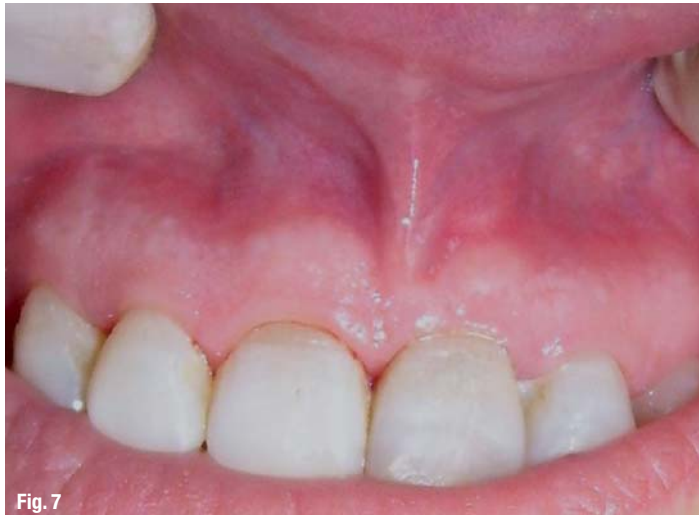

Fig. 7

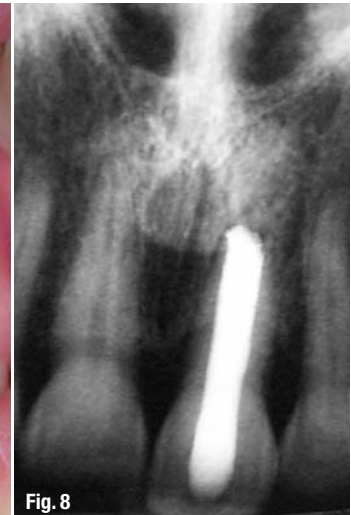

Fig. 8

tion sodium hypochlorite (0.5%) was selected in this case for irrigation owing to the open apex. Higher concentrations with more cytotoxicity that extrude even slightly beyond the apex can cause severe damage to the periapical tissue and irritation, with the resultant pain and swelling.^{8,9} Copious irrigation was used during instrumentation to compensate for the low concentration used.⁸ EDTA was used to remove the smear layer after instrumentation but its toxicity compared with NaOCl seems to be insignificant.¹⁰ Conventional irrigation has some limitations however. The high surface tension of the chemical solutions (even with ultrasonic activation) plays a role in the incomplete cleaning of dentinal tubules, whereas there is no such restriction when using a gas such as ozone, which will flow into any available spaces.^{8,11} Ozone is also responsible for immune modulation, anti-inflammatory effects, accelerating biosynthesis (activation of the metabolism) when is used in medicine. Other effects reported are bioenergetic, antihypoxic, analgesic and haemostatic.^{8,11-13} Ozone has great potential for use as an antimicrobial in endodontics. It is one of the most powerful antimicrobial agents with enormous capacity to reduce the number of micro-organisms (planktonic and organised in biofilm) in the root canal.¹² Ozone is effective when prescribed in sufficient concentration, used for an adequate time and delivered correctly into root canals after the customary cleaning, shaping and irrigation have been completed.^{8,11} Studies have proved the potential use of ozone gas and ozonated water (or irrigants) in endodontic therapy.^{8,11-13}

The rapid healing within 12 months reported in this case was attributed to the stimulation of the local immune response by the ozone, which releases free oxygen radicals, as well as the potent bactericidal and fungicidal action of the ozone.

_Conclusion

Single-visit apexification with MTA was ideal for this case. It entails the non-surgical compaction of a biocompatible material into the apical end of the root canal, thus creating an apical plug and enabling immediate filling of the root canal. Disinfection with ozone was chosen to avoid using high concentrations of NaOCl. Intra-canal disinfection using ozone and the use of MTA as an apical plug achieved a positive initial clinical outcome for the immature tooth. The 12-month follow-up found clinical and radiological signs of healing.

The above-mentioned technique saves a great deal of time compared with calcium hydroxide apexification and achieves a predictable apical barrier in a single visit. Long-term follow-up is however necessary to ensure success.

Editorial note: A complete list of references is available from the publisher.

_contact	roots
	
<p>Prof. Georgi Tomov Department of Oral Pathology Faculty of Dental Medicine Medical University of Plovdiv Hristo Botev Blvd. 4000 Plovdiv Bulgaria</p>	

Root-end resection or trephination

A therapy comparison out of the dental practice

Author_ Dr Robert Teeuwen, Germany

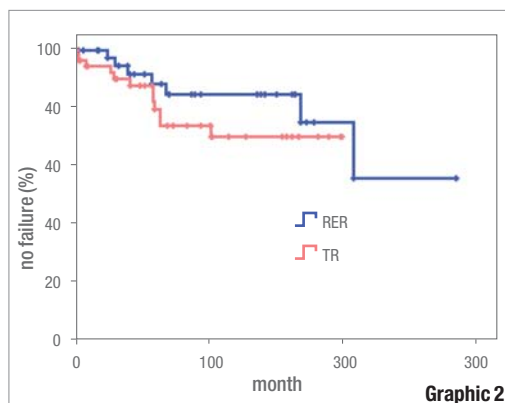
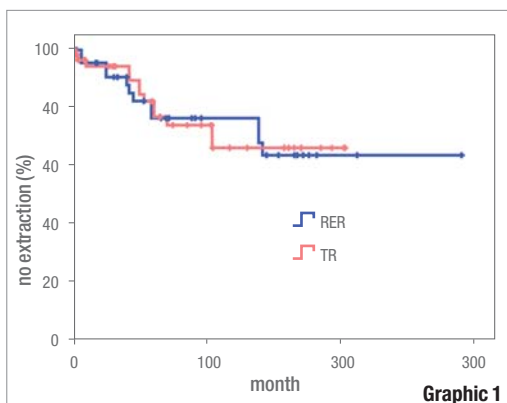
_Abstract

The aim of the present study was to evaluate the treatment success of root-end resection compared with that of trephination directly after orthograde root-canal filling of non-vital molars. The survival time, considering extractions and clinical/radiographic success, was tested in 79 teeth with 118 treated roots with a median control time of 58 months. The age of the patient, type of molar and number of appointments were not relevant to the result. The study found that 81% of the trephined roots and 86.5% of the resected roots were successful. The success difference was not statistically significant ($p=0.239$). Regarding failure, both therapies achieved a statistical significance in apical periodontitis lesions of greater than 5 mm in diameter at the beginning of treatment ($p=0.003$ for root-end resection; $p=0.043$ for trephination). A statistically significant difference was found between the failure of trephined roots treated by the dental assistants and the failure of those roots treated by the practice owner ($p=0.044$), possibly because they had less experience than the practice owner did. Overfilled trephined roots showed a tendency to an increased failure rate, but no statistical significance was observed.

_Introduction

The European Society of Endodontology¹ quality guidelines describe the aims of root-end resection (RER) and periapical curettage (PC). RER involves the removal of unfilled root portions and simplifies retrograde RF. With the aid of PC, diseased tissue or foreign bodies are removed from the periapex. The ESE¹ only accepts these two treatments as isolated measures when prior root-canal filling (RF) has been satisfactory. Trephination (TR) of cortical bone after gaining access to the root canal is regarded as an adjuvant treatment to regular endodontic treatment (root-canal therapy—RCT) in case of pain and a blocked root canal. According to several authors various synonyms for bone TR include trepanation, artificial fistulation and aeration (the term "Schröder Lüftung" is used in Germany). According to several authors TR is indicated for emergencies only.²⁻⁸

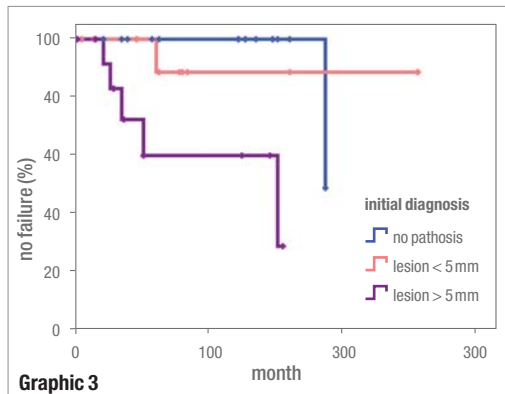
Supporters of PC prior to or after RF for systematic treatment of teeth with necrotic pulp can be found in the literature.⁹⁻²² Luebke²³ does not regard removal of the periapical granulation tissue as necessary. According to Lin et al.,²⁴ partial curettage is adequate because the cause of the granuloma lies in the root canal to be treated. Morse²⁵ suggests that removal of the pe-



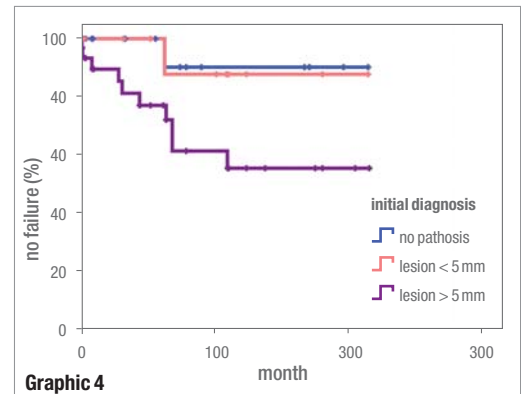
Graphic 1_Kaplan-Meier-Analysis: Survival without extraction root-end-resection vs. trephination.

Graphic 2_Kaplan-Meier-Analysis: Success root-end-resection vs. trephination.

Graphic 3 Kaplan-Meier-Analysis:
Root-end-resection success
dependent on initial diagnosis.



Graphic 4 Kaplan-Meier-Analysis:
Trephination success dependent on
initial diagnosis.



riapical granulation tissue is not necessary for healing. However, he proposes that healing may be accelerated by curettage because the granulation tissue has to be resorbed prior to healing. In Ørstavik's²⁶ opinion too, removal of the apical lesion does not influence healing. This problem could be resolved with an optimal RCT. According to Velvart,²⁷ PC is not necessarily essential because the periapical granulation tissue is a response to the canal infection to be treated.

Frank²⁸ regards PC as being the more extensive treatment compared with TR, but both treatments are nearly symptom-free postoperatively. In cases of persistent pain after RCT, Bender et al.²⁹ performed PC in anterior teeth and TR in posterior teeth. Trauner³⁰ performed 64 TRs as the final treatment measure within half a year, and 30 TRs later followed by RER. For Bence,³¹ TR is the more conservative method compared with RER. Harrison³² states: "If definite therapy requires surgery (root-end resection, etc.) there may be a temptation to substitute the definite surgical procedure for the emergency trephination procedure". Already in 1921, Faulhaber and Neumann³³ raised the controversial question of whether to per-

form RER for endodontic therapy. Sommer et al.³⁴ too raises the question of whether RER is necessary in the case of apical periodontitis (AP). According to Siskin,³⁵ resection of a part of the root has no or only a minor influence on the prognosis of the case. In cases of orthograde RF for RCT of a pulp necrosis, Telander³⁶ and Sargenti³⁷ almost completely replaced RER with TR with as few appointments as possible.

Materials and method

Data was collected in the author's practice on RCTs of non-vital molars (necrosis, revision), which were treated by RER or TR following orthograde RF between 1987 and 1999 with the final check-up concluded by 16 March 2012. RCT was executed according to the principles of the simplified Sargenti^{37,38} technique. Canal preparation was performed using a reamer with the crown-down technique and no canal rinsing, and the formaldehyde-containing N2 was applied with a lentulo. No gutta-percha point was needed. Contrary to Sargenti, a rubber dam was not used for manual RCT. Isolation with cotton rolls was sufficient.

Apart from one TR case, only the buccal roots were subject to surgical intervention in the maxilla. As with RER, TR was performed by flap. RER was accompanied by PC, but TR was not. In TR, an interradicular bone perforation of the periapex was performed using a turbine drill (Brasseler H1 014). All cases were immediately provided with a filling in both the RER and TR treatment. The basis of evaluation was entries in record cards and single-tooth radiographs.

Roots were grouped as follows based on pre-RCT radiographs:

1. no pathological abnormality detected (NAD) at the apex;
2. apical lesion \leq 5 mm in diameter; or
3. apical lesion > 5 mm in diameter.

Follow-up x-ray check (min. 1 year post RCT) included diagnostics according to strict criteria with the following differentiation:

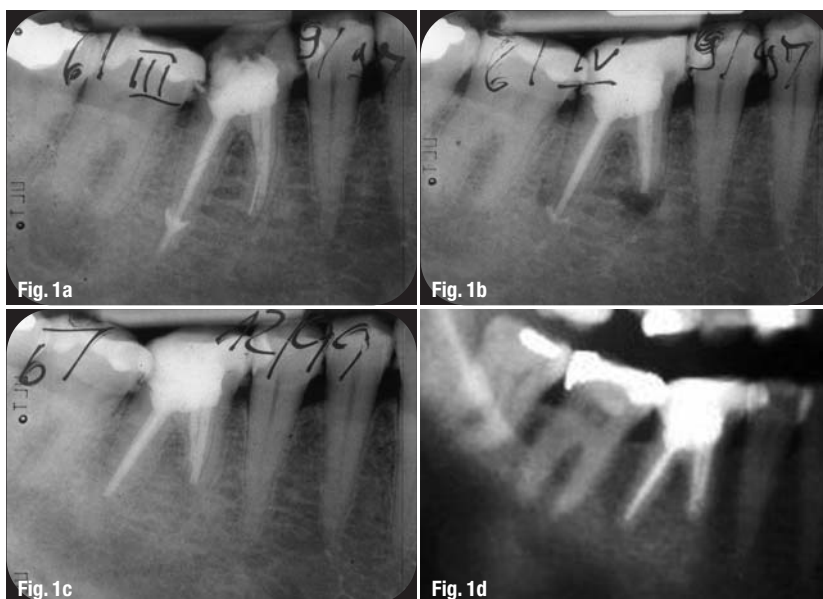
Case 1

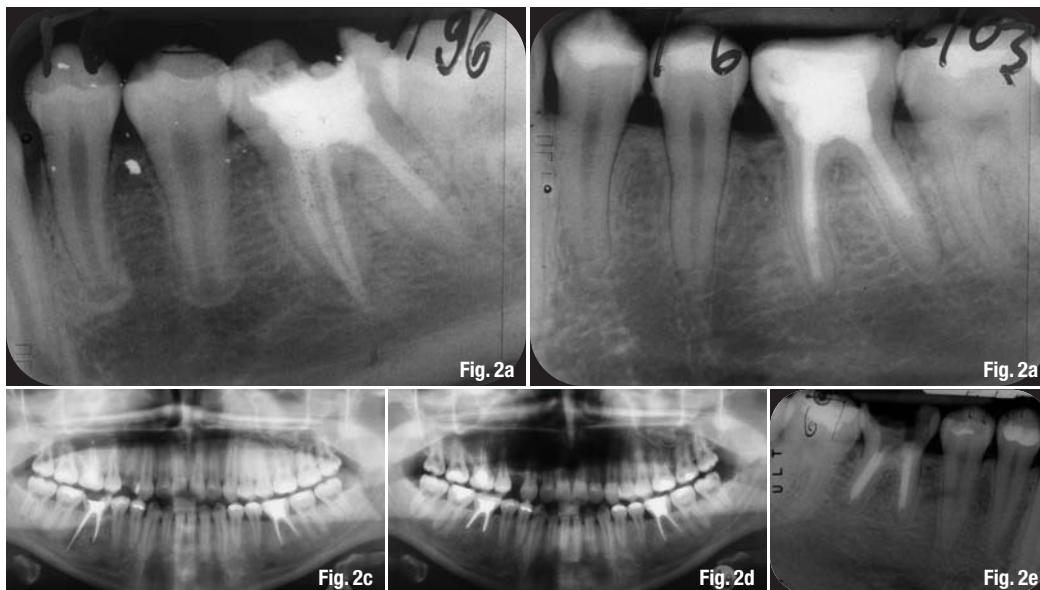
Fig. 1a 46 root-canal-treatment in one session: mesial root fracture of reamer: root-end-resection distal root root-canal-filling extruded: trephination (23.09.1997).

Fig. 1b X-ray post root-end-resection and trephination (23.09.1997).

Fig. 1c A follow-up (21.12.1999).

Fig. 1d A follow-up (16.03.2012).





_Case 2

Fig. 2a_RCT was performed in one session in tooth 36. Both roots had been overfilled and were treated with TR (29.01.1996).
Fig. 2b_A follow-up (09.12.2003).
Fig. 2c_36 follow-up 46 root-canal-treatment in 1 session. Both roots with lesion, distal root tremendous overfill, both roots root-end-resection (09.04.2002).
Fig. 2d_A follow-up showing teeth 36 and 46 healed (09.03.2004).
Fig. 2e_A follow-up of tooth 46 (29.04.2011).

1. NAD at the apex;
2. problematic/apex doubtful; or
3. pathological apex: persistent, reduced, or newly developed lesion.

The instruments used for diagnosis were 2 magnifying glasses, one with 2x and one with 7x (incl. mm scale) magnification. Diagnosis was performed by the author (40 years of practical experience) and separately by a colleague (30 years of practical experience) with significant experience as a court-appointed expert who had never before worked according to the a.m. RCT method. If the respective radiographic diagnoses did not correspond, the worst was chosen for evaluation. In case of a discrepancy between diagnosis 1 and diagnosis 3, a mid-way diagnosis 2 was made.

The last patient appointment in the practice without reintervention at the tooth, root or RF was used for the end of the survival time. So the date of a reintervention, such as a tooth extraction or RER, was considered the last day in function.

Statistical analysis was performed in SPSS (version 19.0, SPSS). The data was analysed using the chi-squared test and the Fisher exact test. A two-page significance check was performed for all tests based on a statistically significant p-value of < 0.05. Determination of survival times was done using the Kaplan–Meier estimate. The log-rank test was used to compare the survival times.

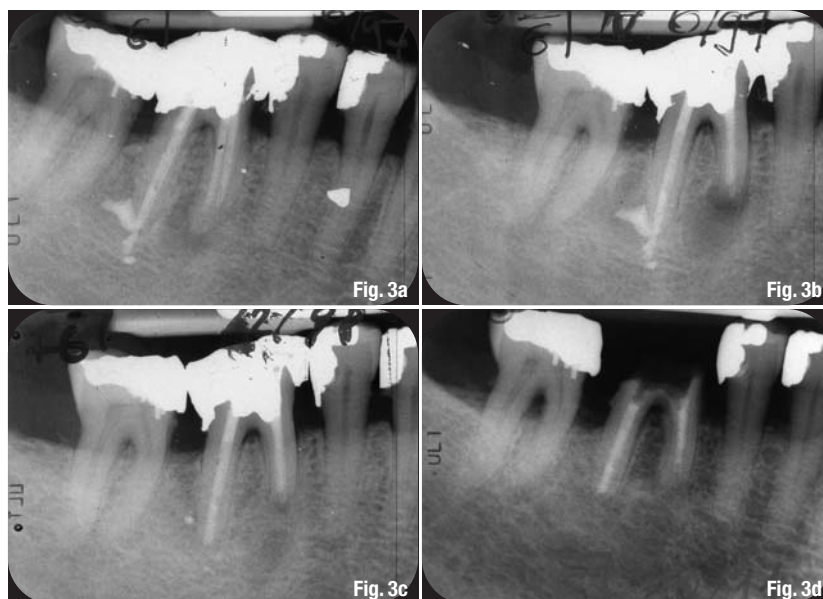
_Results

The median age of the patients was 27.39 years. The mean value was 30.99 years (min. 11, max. 63 years). The treatment of 79 teeth was finished in one appointment for 70.9%—among these, 13 teeth

were pretreated alio loco. Treatments that needed more than one appointment were finished within 21 days. The median follow-up time of the treated roots amounted to 58.43 months, and the mean follow-up time was 77.45 months. All treated teeth were available for clinical follow-up for a maximum of 290 months in the case of RER and for a maximum of 199 months in the case of TR. Two molars with altogether three TR roots did not undergo follow-up. RER was done in 34 non-vital molars (necrosis, revision) with 52 roots—22 (64.7%) maxillary first molars, nine (26.5%) mandibular first molars and three (8.82%) mandibular second molars. TR was performed in 45 molars with 66 roots—25 (56%) mandibular first molars, 12 (27%) maxillary first molars, five (11.11%) mandibular second molars, two (4.44%) mandibular third molars, and one (2.22%) maxillary second molar.

_Case 3

Fig. 3a_RCT was performed in one session in tooth 46. RER was performed in the mesial root and TR in the distal root (13.06.1997).
Fig. 3b_A radiograph post-RER and TR (13.06.1997).
Fig. 3c_A follow-up (18.12.1998).
Fig. 3d_A follow-up (13.12.2011).

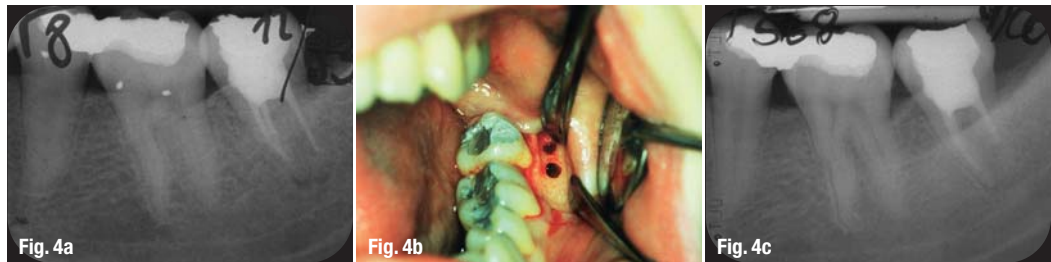

_Case 4

Fig. 4a Tooth 38 was treated conservatively in one session with RF (02.12.1993).

Fig. 4b Pain: trephination (03.12.1993).

Fig. 4c A follow-up (20.09.2000).



RER was most frequently performed in the mesiobuccal root of the maxillary first molars, with 19 cases (37%), and TR was most frequently performed in the distal root of the mandibular first molars, with 23 cases (35%). Six teeth were treated with RER or TR at different roots during the same appointment: five mandibular first molars with RER of the mesial root and TR of the distal root (four with RF +3, one with RF -1), as well as one maxillary first molar with RER of the mesial root and TR of the distobuccal root. In one maxillary first molar, the mesiobuccal root was hemisected and the poorly filled distobuccal root was resected. Hemisection of the distobuccal root of another maxillary first molar was performed with TR of the palatal root through the alveolus of the removed root.

the case of other diagnoses, 89.6% and 85.4% of the teeth survived after five and ten years, respectively.

A fractured instrument led to immediate RER six times. Despite RER, the fractured file remained in the canal for another five and 12 years, respectively, without disadvantage in these cases. In the TR roots, an instrument had fractured in the overfilled mesial root of a mandibular first molar and the tooth was extracted after four years with NAD at the apex clinically or radiographically. Three TR roots (two teeth) had to be resected seven and 58 months post-TR, respectively, owing to failure. Per definitionem, the RER data meant the end of the survival time although the respective teeth fulfilled their function for another 13 respectively 10 years.

_Case 5

Fig. 5a RCT was performed in one session in tooth 46. Both roots had lesions pre-RCT.

Fig. 5b The mesial root was underfilled and the distal root was overfilled post-RF. RER was performed with N2 in the mesial root post-RF and TR was performed in the distal root.

Fig. 5c Flap, mesial root already resected, distal root trephined.

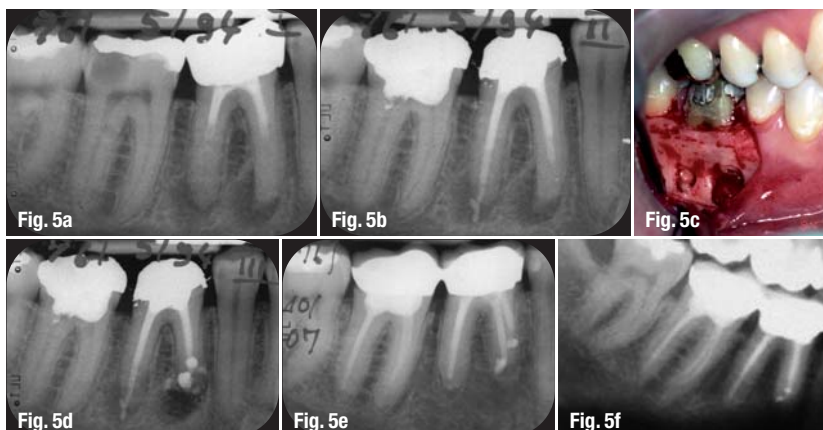
Fig. 5d Post root-end-resection and post trephination (Figs. 5a-d: 15.05.1994).

Fig. 5e A follow-up (20.10.2007).

Fig. 5f A follow-up (17.11.2011).

During the follow-up period, eight RER teeth (23.5%) with 12 roots (23.1%) were extracted—three of which exhibited radiographic failure—as well as ten TR teeth (23.3%) with 13 roots (20.6%)—two of which exhibited radiographic failure and one extraction due to acute exacerbation. Thus, 76.9% of the RER roots and 80.3% of the TR roots survived the follow-up period without extraction. Survival development is shown in Figure 1. The survival difference of $p=0.981$ was not statistically significant. However, a statistically significant difference between RER and TR of $p=0.005$ regarding extraction frequency of teeth was found in relation to the initial diagnosis of an AP lesion > 5 mm versus all other diagnoses. Of teeth diagnosed with this more progressed apical lesion, 58% survived after five years and 52.2% after ten years. In

Half of the follow-up radiographs dated from more than 49 months post-RER and more than 62 months post-TR. The two radiograph evaluators made the same diagnoses, 65% in RER and 59% in TR. Forty-three (36.4%) of the 118 treated roots were diagnosed as NAD at the apex radiographically. Aside from one case, AP as initial diagnosis was proved to result in later radiographic failure. A differentiation of RER and TR showed seven roots each as radiographic failures, that is, 17.1% in RER and 15.9% in TR. Another TR tooth with two treated roots with a radiographic diagnosis of a problematic/insecure apex was added to the failures. This was a mandibular molar whose roots had been resected 58 months after TR without RF revision. Acute exacerbations were not observed after RER, but were observed three times after TR in teeth with an initial large AP lesion and anamnestic pathology. One of these teeth was extracted after six days, a second one resected after 21 days, and the third one underwent RER with retrograde RF after seven months. A mandibular first molar that had to be re-trephined after 16 days owing to persistent pain was not classified as a failure but as a complication of TR. This tooth remained under control without any symptoms for another six years. Taking the two TR patients who did not return for treatment into account, TR had a total failure rate (radiographically and clinically) of 23.3% in 43 treated teeth with ten failures and 19% in treated roots with 12 failures. Thus, after a post-operative control phase, successful treatments were as follows: 27 teeth

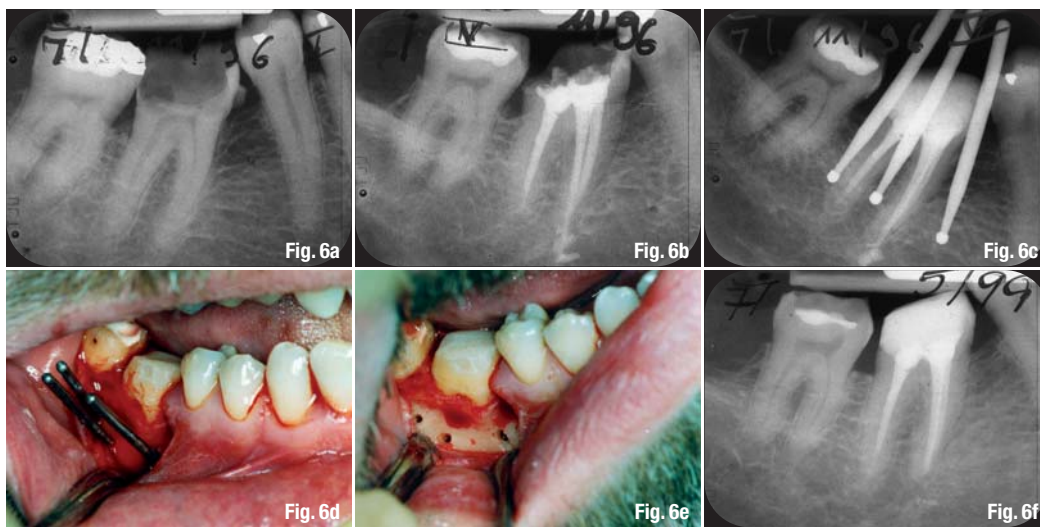


(79.4%) with 45 roots (86.5%) for RER, and 33 teeth (76.7%) with 51 roots (81%) for TR. A statistically significant difference in success between both therapy forms was not found ($p=0.239$; Fig. 2). Such a difference between RER and TR was only found in relation to the initial diagnosis. During the follow-up phase a therapy success rate of 70.6% after RER for an AP lesion > 5mm was achieved compared with 94.3% for smaller lesions or NAD at the apex ($p=0.003$), and of 67.7% compared with 93.8% after TR ($p=0.043$; Figs. 3 & 4).

The results showed no statistically significant preference of a post-operative AP lesion for certain tooth locations when comparing the most frequently

Discussion

Regarding treatment success, the present study combined the follow-up X-ray pictures to be interpreted with the clinical situation, which may lead to a less positive result compared with evaluation of radiographs only.³⁹ The individually treated roots were evaluated radiographically, which showed better results than evaluation of tooth units.³⁹ This finding corroborates that of Swartz et al.,⁴⁰ whose study of 1,007 teeth with 1,770 canals found a failure rate of 12.21% of teeth and 10.43% of roots after one–ten years. In this study, the development of the tooth units excluding reinterventions (extraction, RER) resp. last check-up was followed in parallel to healing success. Ulti-



Case 6

Fig. 6a 47 root-canal-treatment in one session ante root-canal-treatment.

Fig. 6b TR performed post RF.

Fig. 6c TR drill *in situ*.

Fig. 6d TR drill *in situ*.

Fig. 6e Three TR holes

(Figs. 6a–e: 22.11.1996).

Fig. 6f A follow-up (27.05.1999).

treated tooth locations—16/26 in RER and 36/46 in TR—with the sum of the remaining treated tooth locations ($p=0.44$ for RER compared with $p=0.746$ for TR). There was also no statistically significant difference of failures depending on the patient's age based on a median age of 27.39 years ($p=0.497$ for RER compared with $p=0.705$ for TR). Five of the seven RER failures and nine of the ten TR failures were ascribed to an anamnestic pathology. The number of appointments—one appointment versus more than one appointment—had no statistically significant influence on the failure rate ($p=0.779$ for RER compared with $p=0.672$ for TR). Nine of the 39 overfilled roots of the TR group led to failure (23.1%), compared with three of the 24 non-overfilled roots (12.5%). This difference ($p=0.371$) was not statistically significant. The 14 poorly filled RER roots and the ten insufficiently filled TR roots had two failures each. In revision treatments, there was only one failure in a TR case. A statistically significant difference in failure of $p=0.044$ was observed regarding personnel involved in treating trephinated teeth (13.5% for the author compared with 26.9% for the assistants). The results are shown in Tables 1 and 2.

mately, it is essential for the patient that a root-treated tooth remain in function in the mouth and asymptomatic for as long as possible.⁴¹ Torabinejad et al.⁴¹ report a healing success rate of 75% in their systematic RER review. The authors noticed a functional success rate of 84.4%. Friedman and Mor⁴² determined a highly variable healing rate of teeth with AP after RER of 37–85% (average of 70%), as well as a functional success rate of 86–92%. Based on their meta-analysis, Ng et al.⁴³ concluded that with reference to extractions survival rates exceed healing rates. Furthermore, they state that no studies thus far have analysed the survival and healing rates for the same patient. The present study has attempted to do so.

A disadvantage of this study is the low number of cases (79 molars with 118 treated roots), which relativises the statistical relevance of the results. This low number of cases means that only significant percentage differences indicate statistical significance. According to Trope et al.,⁴⁴ a minimum of 350 cases is needed to render a 10% difference between two subjects statistically relevant. Lewsey et al.⁴⁵ concluded from their meta-analysis that studies with a higher

		RER		TR	
		n	%	n	%
Treated teeth		34	100	45	100
Patient	Male	17	50	26	57.8
	Female	17	50	19	42.2
Treatment	Author	24	70.6	26	57.8
	Assistant	10	29.4	19	42.2
Symptomatic pre-RCT		26	76.5	37	82.2
Sessions	1	21	61.8	35	77.8
	>1	13	38.2	10	22.2
Treated roots		52	100	66	100
Necrosis		48	92.3	59	89.4
Retreatment		4	7.7	7	10.6
Location	17/27	0	0	1	1.5
	16/26	36	69.2	17	25.8
	36/46	11	21.1	36	54.5
	37/47	5	9.6	9	13.6
	38/48	0	0	3	4.5
AP lesion pre-RCT	None	19	36.5	24	36.4
	< 5 mm	16	30.8	11	16.7
	≥ 5 mm	17	32.7	31	47
RF length	Short of apex	25	48.1	13	19.7
	-1	10	19.2	13	19.7
	Overfilled	17	32.7	40	60.6
RF quality	Well condensed	38	73.1	56	84.8
	Poorly condensed	14	26.9	10	15.2
Radiograph more than one year later		41	78.8	44	66.7
Radiographic failure	Sure	7	17.1	7	15.9
	Sure + questionable	7	17.1	9	20.5
	16/26	6		1	
	36/46	1		6	
Table 1	37/47	0		2	

Table 1 Comparison of RER vs. TR in non-vital molars.

number of participants report more success rates than those with a lower number of participants do. The requirement of Mühlemanns⁴⁶ for a minimum of 90% follow-up examinations of the originally treated cases was exceeded though, as 100% of the RER and 95.5% of the TR teeth were rechecked.

One critical point is that the simplified Sargenti technique^{37,38} was used for RCT. This technique entails the use of formaldehyde-containing N2, which is a matter of significant debate. Regarding the absence of canal irrigation, as postulated by Sargenti, Byström and Sundqvist⁴⁸ state that a significant reduction in the number of micro-organisms can be achieved without disinfecting irrigants. Baugh and Wallace⁴⁹ and Sjögren et al.⁵⁰ recommend a strong canal preparation to reduce canal infection.⁵⁰ According to Wu et al.,⁵¹ reduction of AP to a histologically acceptable level cannot be achieved. Nair et al.⁵¹ performed one-stage RCT in 18 teeth with AP. Thereafter, the root ends were resected and examined. Persistent micro-organisms were found in 16 (88%) resections.

In response to the perception that only the conservative endodontic method can achieve a reduction of bacteria, Sargenti developed N2, which produces formaldehyde-containing gases that enter otherwise inaccessible side canals and tubules. Ørstavik et al.⁵³ concede that the sealer used is significant to the result of an endodontic treatment. The focus of the current study was the systematic use of TR after orthograde RF using N2, a procedure that Sargenti proposed for the reduction of appointments for RCT of necrotic teeth, compared with RER—which Sargenti considered obsolete.

Sargenti^{37,38} supported PC with TR only for the removal of filling material in cases of massive overfilling. In the present study, PC was omitted in all TR cases. Periapical granulation tissue was left to heal without PC. From the point of view of numerous authors,²³⁻²⁷ removal of the granulation tissue is not necessary.

This study was based on the hypothesis that RER and TR lead to the same success results regarding the healing process (clinically, radiographically) and survival rate independent of the x-rays. When starting treatment, AP was present in an equal number of the respective teeth subjected to each therapy (63.5%). A differentiation regarding the size of the apical lesions clearly revealed that wider translucencies predominate in TR cases. Only the presence of a large lesion had an influence on the success result. At the end of treatment, 17 (32.7%) RER roots exhibited a larger apical lesion. During the subsequent control phase, radiographic failure was diagnosed in five cases (29.4%). The situation was similar for TR cases: 31 cases (47%) of an initial larger periapical translucency were later followed by eight radiographic failures (25.8%) and two clinical failures (acute exacerbations). These results are similar to the findings of Kojima et al.⁵⁴ In their study of 5,839 non-vital teeth, they report 71.5% successful treatments after RCT of teeth with AP and 82% without AP.

The initial periapical situation was of equal importance to failure in RER and TR. A statistical significance of $p=0.003$ in RER and of $p=0.043$ in TR was demonstrated for an AP lesion > 5 mm. The statistically significantly higher failure rate of TR treatment by assistants might be ascribed to the fact that all seven assistant failures for TR featured a large apical lesion at the beginning of treatment, whereas only three of the five failures for TRs performed by the practice owner had such a lesion. However, the literature mentions that the RCT success rate also depends on the practitioner's qualification. According to the systematic review by Ng et al.,⁵⁵ general dentists scored the worst, with a success rate of 65.7%. The success rate of students was 74.8% and 84.8% for specialists.

Treatment	RER				TR						
Control	Post-RER		n = 52		Control	Post-TR		n = 63			
	Treated		Failed		p-value	Treated		p-value			
Factor	n	%	n	%		Factor	n	%	n	%	
Treatment by					0.435	Treatment by					0.044
Author	37	71.2	5	13.5		Author	37	58.7	5	13.5	
Assistant	15	28.8	2	13.3		Assistant	26	41.3	7	26.9	
Age of patients					0.497	Age of patients					0.705
≤ 27	25	41.1	4	16.0		≤ 27	32	50.8	5	15.6	
28+	27	51.9	3	11.1		28+	31	49.2	7	22.6	
Sessions					0.779	Sessions					0.833
1	33	63.5	3	9.1		1	47	74.6	9	19.1	
> 1	19	36.5	4	21.1		> 1	16	25.4	3	18.7	
Location					0.440	Location					0.746
16/26	36	69.2	6	16.7		36/46	34	54	7	20.6	
Others	16	30.8	1	6.2		Others	29	46	5	17.2	
Initial diagnosis					0.003	Initial diagnosis					0.043
NAD at the apex	19	36.5	1	5.3		NAD at the apex	21	33.3	1	4.8	
Lesion < 5 mm	16	30.8	1	6.2		Lesion < 5 mm	11	17.5	1	9.1	
Lesion ≥ 5 mm	17	32.7	5	29.4		Lesion ≥ 5 mm	31	49.2	10	32.3	Table 2

Table 2 Failure of roots in relation to factors.

The importance of AP prior to RCT can be measured radiographically, but is also expressed in the survival rate. Dammaschke et al.⁵⁶ report that 64.1% of teeth with initial AP survived 11 years after conservative RCT versus 83.6% for teeth with no AP. In the present study, 52.2% of the teeth with an AP lesion > 5 mm survived after 11 years regarding extraction frequency and 85.4% of teeth with a different initial diagnosis. A similar difference was observed in the radiographic failure rate, which was diagnosed in 31.25% of the 48 cases with an AP lesion > 5 mm after 11 years, whereas a therapy failure of 6% was recorded for 67 teeth with a different initial diagnosis.

Teeth with necrotic pulp can be treated effectively in one appointment, as this study has proved—this applies also to teeth with pathology and AP: 26 (83.9%) of the 31 TR cases with a larger lesion and ten (58.8%) of the 17 corresponding RER cases were treated in one appointment only. In 1999, 34.4% of participating US endodontists⁵⁷ stated in a poll that they treated necrotic teeth in one appointment. In a poll of German dentists⁵⁸ in 2010, only 7.34% reported performing RF during the appointment for initial preparation. Ng et al.⁵⁹ proved that RCTs performed during one or several appointments result in nearly identical success, namely 77.2% and 77.4%, respectively, with strict stipulations, and 89.5% and 85.5%, respectively with less-strict stipulations.

While the periapex was curetted for all RER cases, this was not the case for TR, which is why the effect of overfilling on failure in TR cases compared with other RF levels could be investigated. Including the

three acute cases, nine of the 12 failures were due to the 39 overfilled roots, the other three to the remaining 24 followed-up roots. Despite the high failure percentage of 23.1% in overfilled roots compared with 12.5% in non-overfilled roots, a statistically significant distance was not found ($p=0.371$). This however suggests that a disadvantage of overfilling might be found in larger samples. Kojima et al.⁵⁴ found a success rate of 70.8% after overfilling, and Ng et al.⁵⁹ report a success of 65.8% according to strict criteria and of 74.5% according to less-strict criteria. The latter concluded from a literature review that for RCT the mandibular molars had the lowest treatment success rates compared with all tooth types, whereas the maxillary molars had average success rates. Only molars were considered in the present study. Differences in the success of RCT in maxillary and mandibular molars could not be verified.

Conclusion for the practice

For the practitioner, TR is technically easier and more time-saving than RER is because access to the periapex is sufficient. Both therapy alternatives have identical treatment successes and survival rates. PC performed with TR or RER is optional in cases of massive overfilling and can be disregarded for cases of slight overfilling. RER after orthograde RF of non-vital teeth is only indicated for a problem in the apical root section, such as too short RF or in case of "ferrum alienum".

Editorial note: A complete list of references is available from the publisher.

Acknowledgements

Dr Ernst Goffart acted as second advisor for radiology diagnostics. Dr Tanja Kottmann performed the statistical analysis. I wish to thank both of them for their contributions.

_contact	roots
<p>Dr Robert Teeuwen Berliner Ring 100 52511 Geilenkirchen Germany</p> <p>robteeuwen@t-online.de</p>	



“The ninth WEC will help to elevate the **technical and scientific standards of endodontic research, practice and teaching**”

An interview with IFEA congress president Prof. Hideaki Suda

The World Endodontic Congress (WEC) in Athens, Greece, in 2010 was one of the most successful events the International Federation of Endodontic Associations (IFEA) has ever organised in its 27-year history. This year's edition was held in Tokyo in Japan from 23 to 26 May 2013 and attracted even more interest from specialists around the world, according to the organisation. **roots** magazine had the opportunity to speak with congress president and Tokyo Medical and Dental University professor Hideaki Suda.

_roots: IFEA's ninth WEC was held in Japan for the first time. What has the organisation been like, and what were your expectations for the event?

Prof. Hideaki Suda: The selection of the Japan Endodontic Association to host the congress in 2013 was a decision made by the IFEA general assembly in Vancouver, Canada, six years ago. Since then, the local organising committee and its five subcommittees have had over 30 meetings concerning the preparations for the congress. Each subcommittee has also

held its own meetings. We expect that the ninth WEC will help to elevate the technical and scientific standards of endodontic research, practice and teaching, as well as disseminate them throughout the world in order to improve the dental care standards in many nations.

“...a large part of the **profession** is very keen on **learning** about the latest **scientific** and **technological** **developments**.”

_In what regard this congress was different from that in Athens?

Looking back at the previous congress, one has to admit that it was not only extremely well organised but also very successful both at an academic and social level. At this point, we can already say that the ninth WEC was much larger in size and participation numbers, as we had over 1,100 registrations from 41 member and non-member countries. Almost 300 research papers have been accepted and was presented in Tokyo. Furthermore, there were nine symposia and 17 table clinic presentations, where the newest scientific methods and technologies were on display.

Owing to Japan's unique hospitality, I hope that participants enjoyed their stay throughout the event.

_Japan is the country where the apex locator was developed, among other things. How would you describe the level of endodontic treatment and research in the country?

Another Japanese development was the application of adhesive dentistry principles to endodontic treatment. As you may also know, Prof. Shinya Yamanaka from the Kyoto University was awarded the Nobel prize last year for inducing pluripotent stem cells. Tissue engineering of the dental pulp has become one of the hottest topics for research in Japan and we may see the regeneration of the pulp become a reality in the near future owing to this development.

Unfortunately, there are still only a few general practitioners who are specialised in endodontic procedures, most of which are performed under the Japanese health insurance service. Therefore, the country has tended to be behind other markets regarding the introduction of the latest instruments and materials to daily practice. It is encouraging to see however that endodontic seminars and hands-on courses for general dental practitioners here are always well attended, demonstrating that a large part of the profession is very keen on learning about the latest scientific and technological developments.

_The theme of this year's congress was "Shaping the future of endodontics". Was the programme primarily focused on new techniques and treatment methods?

New techniques and treatment methods such as CBCT and the use of lasers and microscopes in endodontics were topics with which many of the papers are concerned.

Other topics included pain control, the newest apex locators, MTA, novel root-canal irrigation methods, the management of tooth fractures, as well as root-canal preparation and filling. Single-file preparation methods in particular were demonstrated during the pre-congress courses by four world-famous endodontists.

_Which presentations were you looking forward to most?

Highlights were definitely the plenary and keynote lectures, where the latest information on regeneration of the dental pulp, re- and auto-transplantation of teeth, biofilms in endodontics, treatment outcomes, and retreatment were presented. In addition, we were looking forward to the country representative speakers session, where the current trends in endodontic treatment in each member country were discussed.

_The general assembly met again during the congress. What will be discussed at this gathering?

Besides reports from officers and representatives from different regions, the general assembly meeting on Sunday, 26 May, selected the location of the 12th WEC in 2019 which will be announced soon. Last time, it was decided that the next congress (in 2016) will be held in Cape Town in South Africa. Future concepts concerning science and business were also discussed. Through those activities, we hope to foster international professional relationships and the exchange of information in endodontics.

Thank you very much for this interview.



Prof. Hideaki Suda

International Events

2013

FDI Annual World Dental Congress

28–31 August 2013
Istanbul, Turkey
www.fdiworldental.org

ESMD Autumn School

6–7 September 2013
Louvain la Neuve, Belgium
www.esmd.info

ESE Biennial Congress

12–14 September 2013
Lisbon, Portugal
www.e-s-e.eu

Canadian Academy of Endodontics Annual General Meeting

16–22 September 2013
Ottawa, Ontario, Canada
www.caendo.ca

AMED Annual Meeting & Scientific Session

3–5 October 2013
Orlando, Florida
www.microscopdentistry.com

DGZ & DGET joint meeting

10–12 October 2013
Marburg, Germany
www.dget.de

The Uruguayan Endodontic Congress

15–18 October 2013
Montevideo, Uruguay
www.endodonciauruguay.com

ADA Annual Session

31 October–3 November 2013
New Orleans, USA
www.ada.org

BAET – Successful Endodontics: Foundations and new Treatment Avenues

8 November 2013
Brussels, Belgium
www.baet.org

AAE Fall Conference

14–16 November 2013
Las Vegas, USA
www.aae.org

ADF Annual Dental Meeting

26–30 November 2013
Paris, France
www.adf.asso.fr

3rd Pan Arab endodontic congress

28–30 November 2013
Beirut, Lebanon
www.paec2013.org

Hellenic Society of Endodontology 1st International Congress of Endodontics

29 November–1 December 2013
Athens, Greece
www.endodontics2013.gr

Greater New York Dental Meeting

29 November–4 December 2013
New York, USA
www.gnydm.com



submission guidelines:

Please note that all the textual components of your submission must be combined into one MS Word document. Please do not submit multiple files for each of these items:

- _ the complete article;
- _ all the image (tables, charts, photographs, etc.) captions;
- _ the complete list of sources consulted; and
- _ the author or contact information (biographical sketch, mailing address, e-mail address, etc.).

In addition, images must not be embedded into the MS Word document. All images must be submitted separately, and details about such submission follow below under image requirements.

Text length

Article lengths can vary greatly—from 1,500 to 5,500 words—depending on the subject matter. Our approach is that if you need more or less words to do the topic justice, then please make the article as long or as short as necessary.

We can run an unusually long article in multiple parts, but this usually entails a topic for which each part can stand alone because it contains so much information.

In short, we do not want to limit you in terms of article length, so please use the word count above as a general guideline and if you have specific questions, please do not hesitate to contact us.

Text formatting

We also ask that you forego any special formatting beyond the use of italics and boldface. If you would like to emphasise certain words within the text, please only use italics (do not use underlining or a larger font size). Boldface is reserved for article headers. Please do not use underlining.

Please use single spacing and make sure that the text is left justified. Please do not centre text on the page. Do not indent paragraphs, rather place a blank line between paragraphs. Please do not add tab stops.

Should you require a special layout, please let the word processing programme you are using help you do this formatting automatically. Similarly, should you need to make a list, or add footnotes or endnotes, please let the word processing programme do it for you automatically. There are menus in every programme that will enable you to do so. The fact is that no matter how carefully done, errors can creep in when you try to number footnotes yourself.

Any formatting contrary to stated above will require us to remove such formatting before layout, which is very time-consuming. Please consider this when formatting your document.

Image requirements

Please number images consecutively throughout the article by using a new number for each image. If it is imperative that certain images are grouped together, then use lowercase letters to designate these in a group (for example, 2a, 2b, 2c).

Please place image references in your article wherever they are appropriate, whether in the middle or at the end of a sentence. If you do not directly refer to the image, place the reference at the end of the sentence to which it relates enclosed within brackets and before the period.

In addition, please note:

- _ We require images in TIF or JPEG format.
- _ These images must be no smaller than 6x6 cm in size at 300 DPI.
- _ These image files must be no smaller than 80 KB in size (or they will print the size of a postage stamp!).

Larger image files are always better, and those approximately the size of 1 MB are best. Thus, do not size large image files down to meet our requirements but send us the largest files available. (The larger the starting image is in terms of bytes, the more leeway the designer has for resizing the image in order to fill up more space should there be room available.)

Also, please remember that images must not be embedded into the body of the article submitted. Images must be submitted separately to the textual submission.

You may submit images via e-mail, via our FTP server or post a CD containing your images directly to us (please contact us for the mailing address, as this will depend upon the country from which you will be mailing).

Please also send us a head shot of yourself that is in accordance with the requirements stated above so that it can be printed with your article.

Abstracts

An abstract of your article is not required.

Author or contact information

The author's contact information and a head shot of the author are included at the end of every article. Please note the exact information you would like to appear in this section and format it according to the requirements stated above. A short biographical sketch may precede the contact information if you provide us with the necessary information (60 words or less).

Questions?

Magda Wojtkiewicz (Managing Editor)
m.wojtkiewicz@oemus-media.de

roots

international magazine of endodontology

Publisher

Torsten R. Oemus
oemus@oemus-media.de

CEO

Ingolf Döbbecke
doebbecke@oemus-media.de

Members of the Board

Jürgen Isbaner
isbaner@oemus-media.de

Lutz V. Hiller

hiller@oemus-media.de

Managing Editor

Magda Wojtkiewicz
m.wojtkiewicz@oemus-media.de

Executive Producer

Gernot Meyer
meyer@oemus-media.de

Designer

Josephine Ritter
j.ritter@oemus-media.de

Copy Editors

Sabrina Raaff
Hans Motschmann

Published by

Oemus Media AG
Holbeinstraße 29
04229 Leipzig, Germany
Tel.: +49 341 48474-0
Fax: +49 341 48474-290
kontakt@oemus-media.de
www.oemus.com

Printed by

Silber Druck oHG
Am Waldstrauch 1
34266 Niestetal, Germany

Editorial Board

Fernando Goldberg, Argentina
Markus Haapasalo, Canada
Ken Serota, Canada
Clemens Bargholz, Germany
Michael Baumann, Germany
Benjamin Briseno, Germany
Asgeir Sigurdsson, Iceland
Adam Stabholz, Israel
Heike Steffen, Germany
Gary Cheung, Hong Kong
Unni Endal, Norway
Roman Borczyk, Poland
Bartosz Cerkaski, Poland
Esteban Brau, Spain
José Pumarola, Spain
Kishor Gulabivala, United Kingdom
William P. Saunders, United Kingdom
Fred Barnett, USA
L. Stephan Buchanan, USA
Jo Dovgan, USA
Vladimir Gorokhovskiy, USA
James Gutmann, USA
Ben Johnson, USA
Kenneth Koch, USA
Sergio Kuttler, USA
John Nusstein, USA
Ove Peters, USA
Jorge Vera, Mexico



Magda Wojtkiewicz, Managing Editor

roots

Copyright Regulations

_roots international magazine of endodontology is published by Oemus Media AG and will appear in 2013 with one issue every quarter. The magazine and all articles and illustrations therein are protected by copyright. Any utilisation without the prior consent of editor and publisher is inadmissible and liable to prosecution. This applies in particular to duplicate copies, translations, microfilms, and storage and processing in electronic systems.

Reproductions, including extracts, may only be made with the permission of the publisher. Given no statement to the contrary, any submissions to the editorial department are understood to be in agreement with a full or partial publishing of said submission. The editorial department reserves the right to check all submitted articles for formal errors and factual authority, and to make amendments if necessary. No responsibility shall be taken for unsolicited books and manuscripts. Articles bearing symbols other than that of the editorial department, or which are distinguished by the name of the author, represent the opinion of the afore-mentioned, and do not have to comply with the views of Oemus Media AG. Responsibility for such articles shall be borne by the author. Responsibility for advertisements and other specially labeled items shall not be borne by the editorial department. Likewise, no responsibility shall be assumed for information published about associations, companies and commercial markets. All cases of consequential liability arising from inaccurate or faulty representation are excluded. General terms and conditions apply, legal venue is Leipzig, Germany.

roots

international magazine of endodontology



You can also subscribe via
www.oemus.com/abo

 **Subscribe now!**

I would like to subscribe to **roots** for € 44 including shipping and VAT for German customers, € 46 including shipping and VAT for customers outside Germany, unless a written cancellation is sent within 14 days of the receipt of the trial subscription. The subscription will be renewed automatically every year until a written cancellation is sent to OEMUS MEDIA AG, Holbeinstr. 29, 04229 Leipzig, Germany, six weeks prior to the renewal date.

▶ Reply via Fax to +49 341 48474-290 to OEMUS MEDIA AG or via E-mail to grasse@oemus-media.de

Last Name, First Name	
Company	
Street	
ZIP/City/Country	
E-mail	Signature

Notice of revocation: I am able to revoke the subscription within 14 days after my order by sending a written cancellation to OEMUS MEDIA AG, Holbeinstr. 29, 04229 Leipzig, Germany.

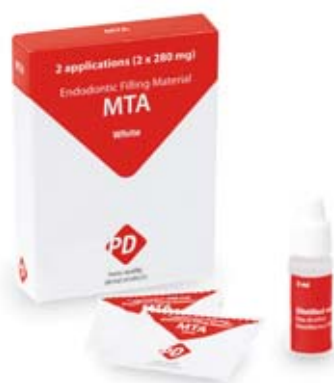Signature

PD MTA White

Load your MAP System

PD MTA White

- Optimized particle size
- Avoids bacterial migration
- Excellent marginal sealing capacity
- Stimulates the formation of a dentine layer (pulp capping)
- 2 sachets with 280 mg each



Swiss quality
dental products