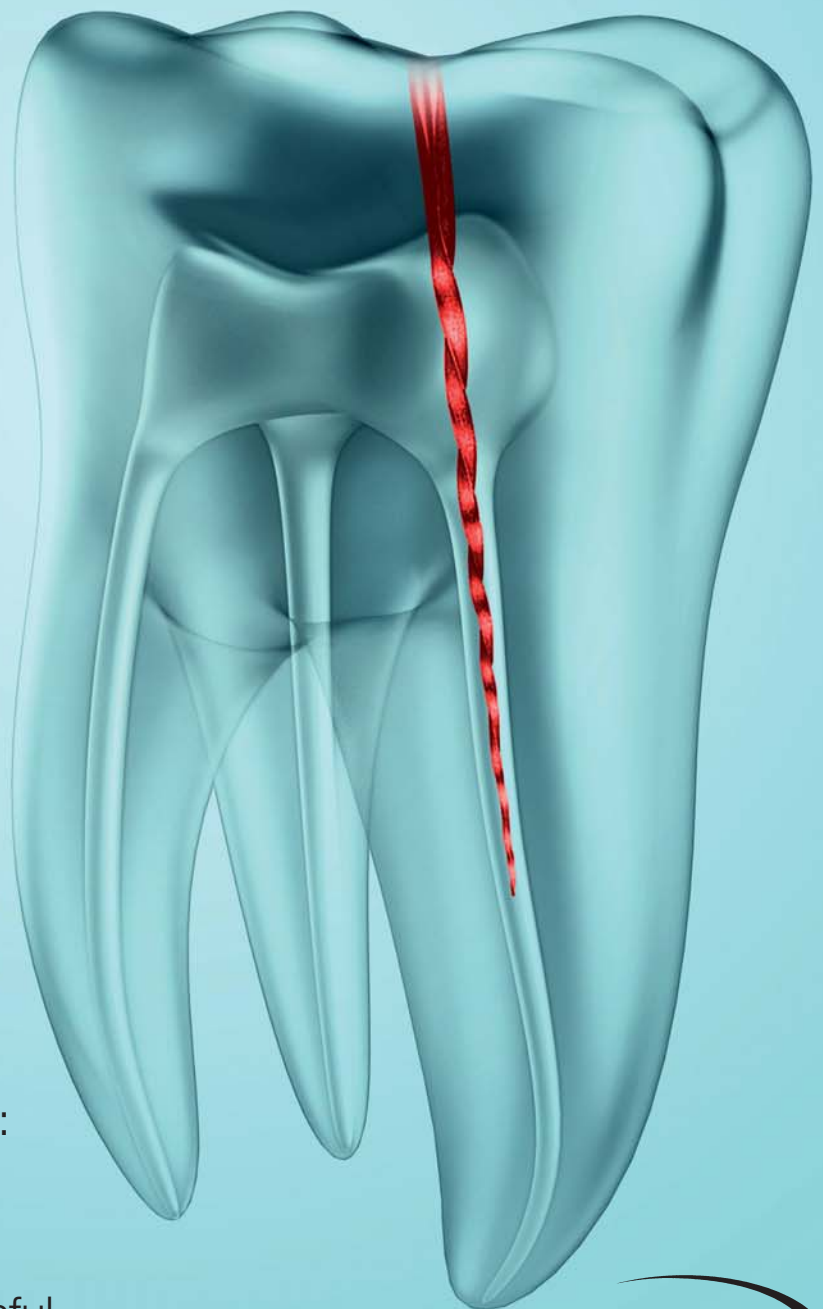


roots

international magazine of endodontology

3²⁰¹³



| **CE article**

Endodontic retreatment and adhesive restoration of structurally compromised second premolar

| **research**

In vitro analysis of efficiency and safety of a new motion for endodontic instrumentation: TF Adaptive

| **case report**

Eight-year follow-up of successful intentional replantation

037113



RECIPROCATE and SMILE



"My experience with RECIPROC® has been nothing short of amazing. This presents a paradigm shift in the way mechanical root canal preparation can be achieved to provide every practitioner a markedly better opportunity to produce consistent, predictable results. RECIPROC® provides the safest and easiest method for shaping the canals compared to any system. If this doesn't get you more excited about endodontics nothing will!"

Dr. Bjørn Besserman-Svendsen, Frederiksberg Copenhagen, Denmark



www.vdw-dental.com



RECIPROC®
one file endo

Dear friends and colleagues,



Dr Hakki Sunay

It is with great honour and pleasure that I write the editorial for this year's third issue of the **roots** magazine. Throughout my career, I have always believed in the importance of collaboration between dental practitioners and specialists, and it is undeniable that dental journals offer an indispensable means of fostering interaction and communication between dental professionals. I also strongly feel that endodontic specialists should be continuously involved in collaborative activities, and the delivery of up-to-date information by means of journals is a very efficient means of sharing one's experience and knowledge. Endodontic specialists, and all other dental practitioners, should also be encouraged to participate in symposiums and conferences pertaining to the field and subscription to a specialty journal can be a very efficient means of creating and maintaining a scientifically based professional foundation.

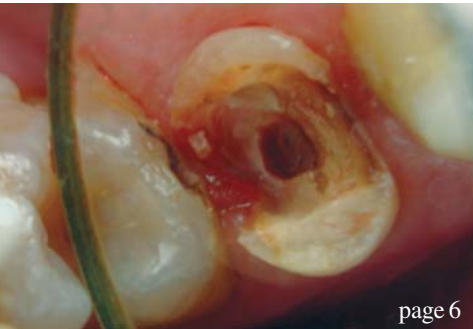It is amazing how rapidly the specialty of endodontics has developed and evolved, especially in the last decade, with new approaches and methodologies regularly being unveiled, as well as paradigm shifts that might alter our conventional methodologies through the introduction of innovative and productive devices. Instrumentation has always been a challenge for endodontists and we are living in an era in which rapid delivery of quality dental service is expected. New methodologies and instrumentation systems are continuously being launched to facilitate endodontic patients' comfort and to ease the practitioner's work. This issue of the magazine contains the most recent information concerning new shaping strategies; readers are introduced to new options and encouraged to make comparisons with their routine methodologies.

Imaging and magnification are considered very important steps in state-of-the-art endodontic care, and it is indisputable that one is enabled to perform sensitive procedures in endodontic treatment when good visualisation is rendered possible. You will find in this issue information on visual data and imaging that will enhance the quality of your endodontic treatments. Case reports are a good means of sharing one's experience with others, and through commentary on and analysis of unique cases dental practitioners can be provided with sufficient information on cases they might encounter in their practices. In this issue, in the belief that such information is very helpful for enhancing the vision of a dental practitioner, interesting cases with efficient treatment modalities and sufficient follow-up periods are presented.

Finally, the European Society of Endodontology congress is soon to be held in Lisbon in Portugal, and we are expecting to enjoy a lively scientific programme with mutual discussions, the exchange of ideas and the enhancement of existing knowledge. I wish all participants a pleasant and productive congress, and I hope that the upcoming event will serve as a successful means of supporting our endeavours in striving to offer the best service in our patients' best interest.

My best wishes to all readers and colleagues,

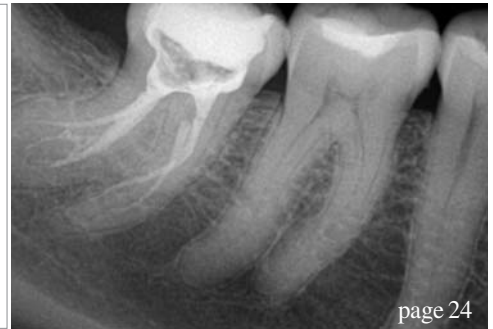Dr Hakki Sunay
Associate Professor, Faculty of Dentistry, Yeditepe University



page 6



page 16



page 24

| editorial

03 **Dear friends and colleagues**
| Dr Hakkı Sunay

| CE article

06 **Endodontic retreatment and adhesive restoration of structurally compromised second premolar**
| Drs Stela Nicheva, Lyubomir St. Vangelov & Ivan Filipov, Bulgaria

| research

12 **In vitro analysis of efficiency and safety of a new motion for endodontic instrumentation: TF Adaptive**
| Prof. Gianluca Gambarini, Italy & Dr Gary Glassman, Canada

| industry report

16 **MounceFiles: A safe, economical and efficient option for canal preparation**
| Dr Rich Mounce, USA

| technique

22 **Hands on with the new reciprocating motion file system**
| Dr Thomas Jovicich, USA

| case report

24 **Adapting to the anatomy, guided by the canal**
| Dr Philippe Sleiman, Lebanon

28 **Eight-year follow-up of successful intentional replantation**
| Dr Muhamad Abu-Hussein, Greece; Dr Sarafianou Aspasia, Greece; & Dr Abdulgani Azzaldeen, Israel

| opinion

32 **Visual information and imaging technology in endodontics**
| Prof. Hideaki Suda & Dr Toshihiko Yoshioka, Japan

| industry news

34 **Produits Dentaires presents PD MTA White**
| Produits Dentaires

34 **RECIPROC—also efficient in retreatment**
| VDW

36 **Axis | SybronEndo: Rotary Meets Endo**
| Perry Lowe, USA (Axis | SybronEndo)

38 **A new manufacturing process for new NiTi rotary files**
| Dr Arnaud Stanurski, France (NEOLIX)

| meetings

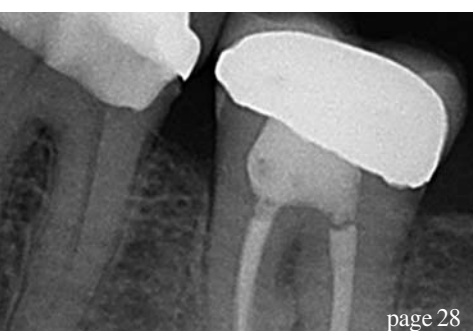40 **International Events**

| about the publisher

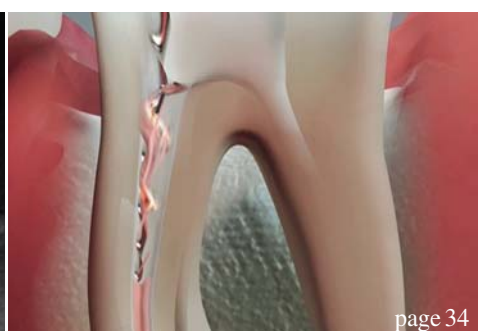41 | submission guidelines
42 | imprint



Cover image courtesy of SybronEndo



page 28



page 34



page 40

BE SAFE!

neoniti new nickel titanium rotary file is manufactured by Electric Discharge Machining (EDM) combined with an appropriate heat-treatment. This exclusive process allows **sharp cutting edges**, **built-in abrasive properties**, **variable changing profiles**, and a **progressive flexibility**.

Key advantages of **neoniti** are:

- no screwing in effect
- a high resistance to fatigue
- an effective removal of debris
- an enhanced cutting speed

neoniti is a *safe* rotary file, even in complex cases, and is appropriate for all practitioners.




NEOLIX SAS - 11, avenue Raoul Vadepiéd
53600 Châtres-la-Forêt (France)
Tel: +33-2-5374-5007 - Fax: +33-2-5368-2005
Email: neolix@neolix.eu - Web: www.neolix.eu

NEOLIX 
Creative dental instruments

Endodontic **retreatment** and adhesive restoration of structurally compromised second premolar

Authors_ Drs Stela Nicheva, Lyubomir St. Vangelov & Ivan Filipov, Bulgaria

_ce credit	roots
	<p>By reading this article and then taking a short online quiz, you can gain ADA CERP CE credits. To take the CE quiz, visit www.dtstudyclub.com. The quiz is free for subscribers, who will be sent an access code. Please write support@dtstudyclub.com if you don't receive it. Non subscribers may take the quiz for a \$20 fee.</p>

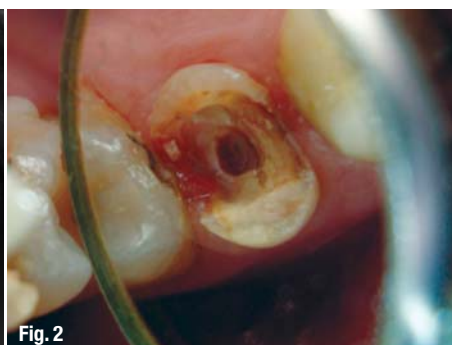vious restoration. The endodontic retreatment in such cases is a challenge concerning the isolation, overcoming different obstructions, perforation management (if they exist) and final restoration. The success rate for teeth that exhibit one or more technical problems, such as transportation, stripping, perforation or internal resorption, is reported to be 47 per cent.² Perforations have the most negative influence.³

_In light of the scientific literature concerning the outcome of the endodontic treatment, it doesn't sound inappropriate that the restoration of the endo-coronal complex has to be completed by the endodontist.¹ In this context the following report presents a complete rehabilitation of a second premolar, including retreatment and definitive restoration.

One of the factors that influence the outcome following non-surgical retreatment is the final restoration. Though some authors question the importance of the coronal restoration for the longevity of endodontically treated teeth,^{4,5} it is well accepted that the final restoration is as important for the outcome of the endodontic treatment as the quality of the treatment itself.⁶ Still, restoration of endodontically treated teeth remains a controversial issue. In the context of the increasing relevance of biomimetics,^{7,8} adhesively inserted indirect partial tooth-colored restorations are gaining more and more attention. The restoration or mimicking of the biomechanical, structural and aesthetic in-

(Photos/Provided by Dr Stela Nicheva)

Teeth that need retreatment are most often grossly decayed due to caries, fracture and/or pre-

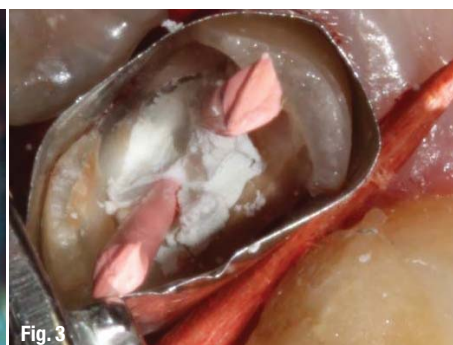
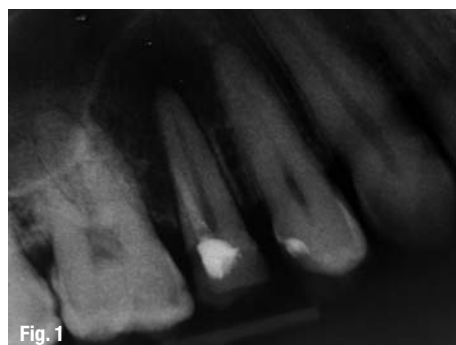
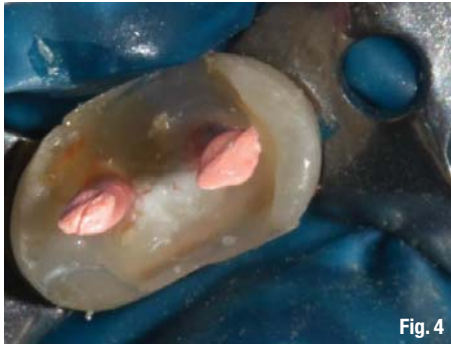



Fig. 4

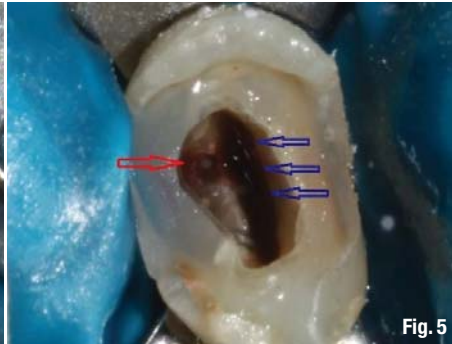

Fig. 5

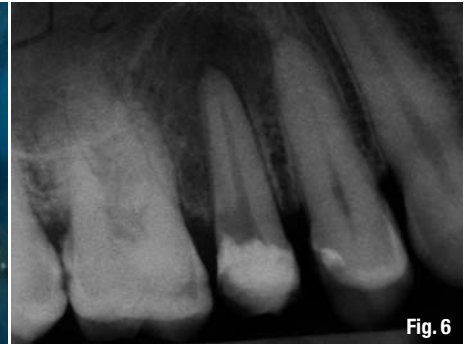


Fig. 6

tegrity of the teeth in a conservative manner is an advantage that must be used and preferred whenever possible. Still, these types of restorations are an underutilized restorative modality, particularly on endodontically treated teeth compared to crowns.⁹ This may be because clinicians and dental technicians are more familiar with crown restorations, the results of which are predictable, and insecure about the adhesive protocol for bonded partial restorations.

Once the decision for tooth-coloured partial restoration is made, the operator must choose between two materials—composite or ceramics. The benefits of the former (less abrasiveness and brittleness, lower costs, easy to polish and repair, user friendly) encounter the strength, inertness and biocompatibility of the latter. While some studies indicate that ceramic and composite inlays provide similar fracture resistance on endodontically treated premolars,¹⁰ other suggest that when cuspal coverage is required composite resin may be more beneficial in endodontically treated posterior teeth compared to ceramics pertaining to its greater survival rate, fatigue resistance and more favorable failures.¹¹ This can be explained with the more friendly stress distribution of composite resin onlays, confined above the cemento-enamel junction.¹²

The present report describes the microscopic retreatment and the definitive restoration of a grossly decayed perforated maxillary premolar. The reasons for the applied treatment are discussed.

_Case report

A 34-year-old male patient reported to the department of Operative Dentistry and Endodontics, complaining of symptoms from another tooth. The radiographic examination (Fig. 1) revealed inadequate endodontic treatment and perforation with radiolucent area at the apex of tooth 15. The tooth was endodontically treated four years ago.

Medical history was non-contributory. Probing was within normal limits. Local anesthesia with Ubistesine DS was administered. After the removal of the old restoration (Fig. 2) and cleaning up the decay, a pre-endodontic buildup was accomplished. Undercuts were not removed but were blocked out with the composite resin. The operative field was isolated with retraction cord immersed in AlCl_3 and Matrix band (Fig. 3). While keeping the orifice and perforation open with gutta-percha points and Cavit, a total etch technique was performed. Enamel and dentin were covered with adhesive (Prime & Bond NT, DENTSPLY) and polymerized for 10 seconds. Bulk-fill flowable composite was applied (SDR, DENTSPLY) and polymerized for 40 seconds in order to create a reservoir for the irrigants during endodontic retreatment (Fig. 4). After the removal of gutta-percha points and Cavit, the real canal (blue arrows) and the perforation (red arrow) were easily accessible (Fig. 5).

Since the artificial canal was previously obturated with a paste, cleaning with a combination of hand files, ultrasonics (Pro Ultra 5 and 6) and irrigation with citric acid was used. To confirm the effectiveness of

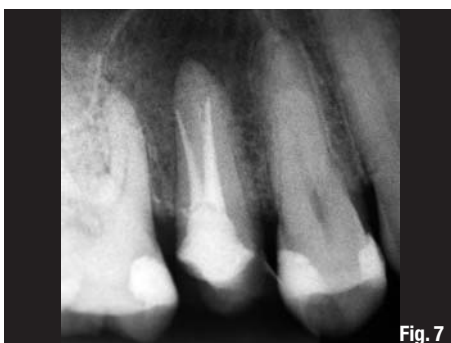

Fig. 7

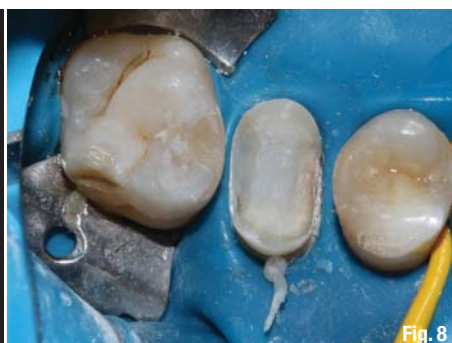

Fig. 8

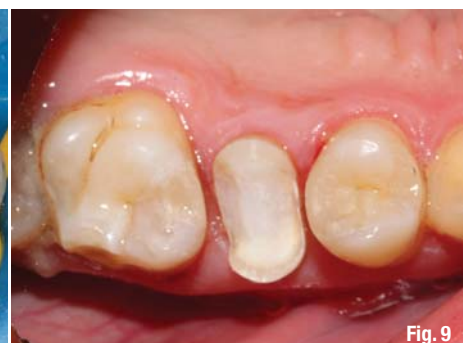

Fig. 9

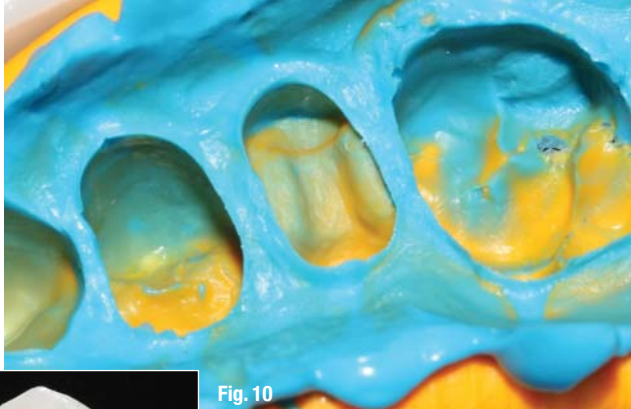


Fig. 10

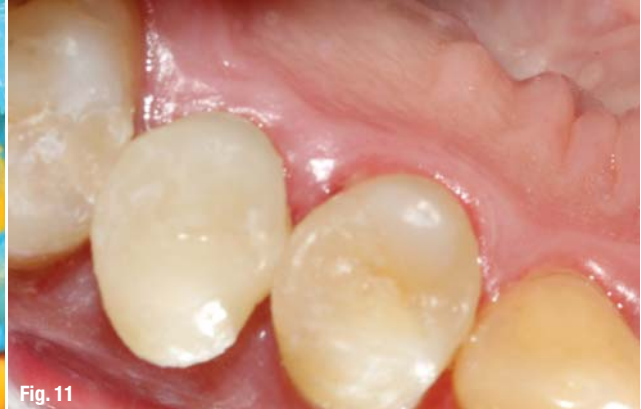

Fig. 11

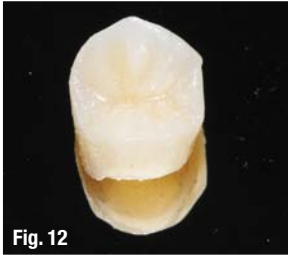

Fig. 12

the cleaning procedure, an intra-operative X-ray was done (Fig. 6). Because of the different angulation of the beam, it seems as if the perforation is on the level of the crestal bone, which is not the real case.

For cleaning and shaping of the real root canal, the following protocol was used:

1. Glide path was established using SS K-files 08, 10, and Path Files 013, 016, 019, (DENTSPLY Maillefer).
2. The upper two-thirds was prepared using S1 and S2 files from Pro Taper system (DENTSPLY Maillefer).
3. The apical third—20 (04) GTX file (DENTSPLY Maillefer).

Throughout the whole procedure, irrigation with Citric acid (40%, Cerkamed, Poland) and NaOCl (2%, Cerkamed, Poland) was used.

We preferred S1 and S2 files because of their ability to brush against the canal wall, which is very useful in cases with oval cross sections, where it is of paramount importance to clean all aspects of the root canal spaces. For the apical one third we choose landed GTX file, because the canal was very narrow and we wanted to eliminate the possibility to transport the apical foramen. Both artificial and true canal were obturated using warm vertical compaction of gutta-percha and MTA-based sealer (FillApex, Angelus, Brazil). On the post-op radiograph, the preparation and obturation seem short, but this was the reading we repeatedly got with our apex locator (RayPex5, VDW, Germany) (Fig. 7).

After the completion of the endodontic retreatment, the pre-endodontic buildup was left at place and the endodontic access was restored again with SDR, creating a core, on which an onlay preparation with diamond burs (Mani Inc.) was performed (Figs. 8 & 9). The enamel margins were exposed and unsupported enamel prisms were removed using fine-grit diamond points. The remaining tooth structure was prepared to create a butt-joint with the restoration margins. Internal line angles were rounded and the walls provided 5- to 15-degree path of divergence. The proximal boxes

preparations extended to the existing composite, since they were located in the dentin.

The dimensions of the preparation provided at least 2 mm interocclusal clearance, which could be verified on the impression. A condensable silicone impression was taken (Fig. 10). A custom made provisional restoration was created using direct technique and temporarily cemented with a non-eugenol luting agent (Temp-Bond NE) (Fig. 11). The fitting aspect of the restoration was sandblasted by the dental technician.

At the second appointment after assessment of the prepared restoration, removal of the provisional and cleaning of the preparation the fit and aesthetics of the onlay were evaluated. Rubber dam was placed and the preparation was cleaned with acetone, etched with 37 per cent phosphoric acid for 15 seconds, rinsed and dried. The fitting aspect of the restoration was also cleaned with acetone prior to cementation. A dual-cure self-adhesive luting resin (SmartCem2, DENTSPLY) was applied to the walls of the preparation and the restoration was placed with firm pressure until fully seated. The excess cement was removed with an explorer, a #12 scalpel blade and dental floss in the interproximal area after five-second polymerization that brought the cement to a "rubbery" stage (Figs. 12 & 13). The restoration was covered with glycerin and finally cured for 60 seconds from each side (Figs. 14 & 15). The minimal occlusal adjustments were done with fine diamond burs under water coolant. Finishing and polishing were accomplished with the Enhance system (DENTSPLY) (Fig. 16).

Once finishing and polishing was done, a 37 percent phosphoric acid gel was applied for 15 seconds to clean the surface of the restoration and to acid etch the marginal enamel. After washing and drying, the nanofilled adhesive (Prime&BondNT, DENTSPLY) was applied and permitted to rest for 10 seconds to permeate the surface and margin fissures created by the finishing process. The adhesive was then thinned with air and polymerized for 40 seconds (Fig. 17). At the six-month recall, the tooth was asymptomatic and the patient was completely satisfied (Figs. 18, 19).

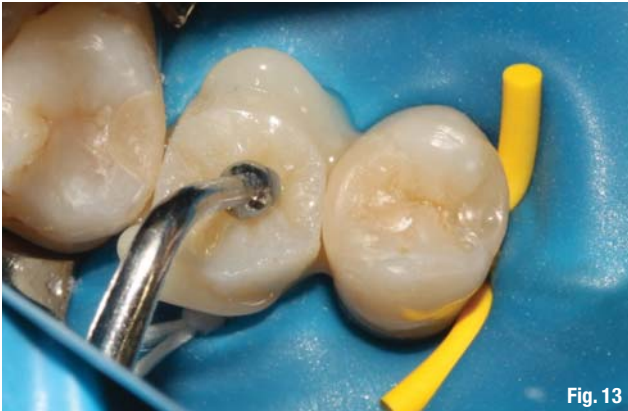

Fig. 13

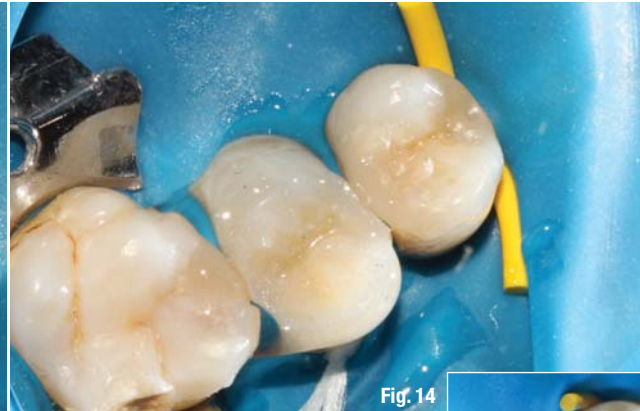


Fig. 14

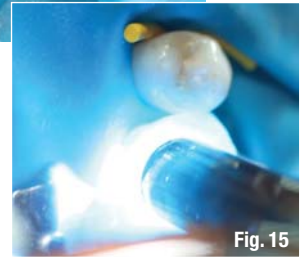


Fig. 15

Discussion

This case report demonstrates endodontic retreatment and composite onlay as definitive restoration for a compromised tooth with minimal coronal tooth structure.

The two most important factors in terms of prognosis of treatment of perforations are the age of the lesion and degree of bacterial contamination.¹³ In our case, the previous endodontic treatment was done four years ago. The long period of time is not favourable for the prognosis, but since the perforation is in the apical third the likelihood of bacterial contamination is low. After the patient has been informed, he chooses orthograde endodontic retreatment as a treatment modality.

The material of choice for perforation repair is MTA (mineral trioxide aggregate). Because of the small size and apical position of the lesion, we decided to treat it like a second canal and to obturate with gutta-percha and MTA based sealer. The absence of worsening of the periapical conditions in the six months post-op X-ray (Fig. 19) supports this approach, and the patient is still under observation.

Although still debatable, recent comprehensive meta-analysis by Gillen et al.⁶ demonstrates that a

well-fitting, bacteria-proof final restoration has the same importance for the long-term prognosis of the endodontically treated tooth as does the well-performed endodontic therapy. Besides the prevention of coronal microleakage, a key factor for the long-term survival of an endodontically retreated tooth appears to be the amount of remaining tooth substance,¹⁴ which is determined by the dimensions of the final restoration. So an ideal treatment option for an endodontically retreated tooth seems to be adhesively bonded restoration that preserves as much of the tooth structure as possible.

An endodontically treated posterior tooth presenting with extensive decay is most frequently restored with a post and a crown. That is intelligible, because crowns are a well-established and known, clinically proven restorative modality, and still a considerable amount of research is being performed in this direction.¹⁵ On the other hand, partial tooth-coloured restorations are recognized as valuable alternatives to full coverage crowns, and questions are raised if intracanal posts are necessary at all for an endodontically treated tooth.

Since their introduction in 1980,¹⁶ indirect laboratory processed composites are being continuously improved in their physical and mechanical properties. Now this restorative option offers ad-

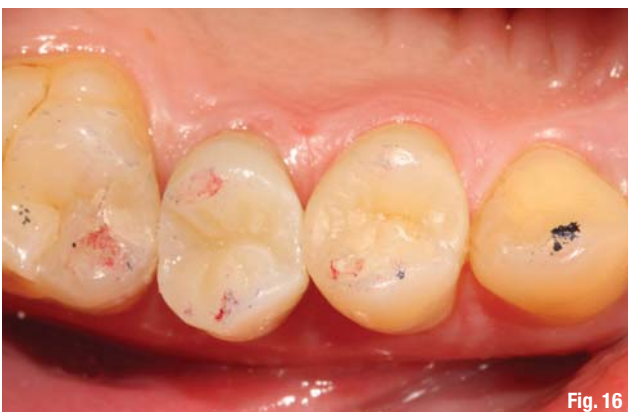

Fig. 16

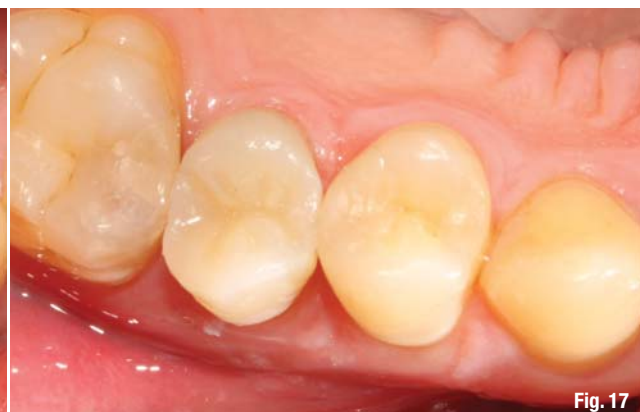

Fig. 17

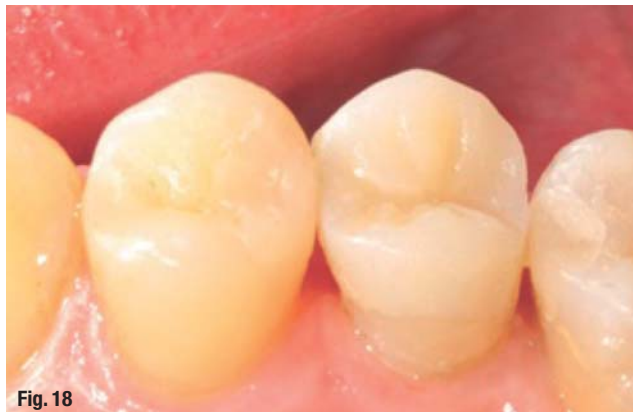

Fig. 18

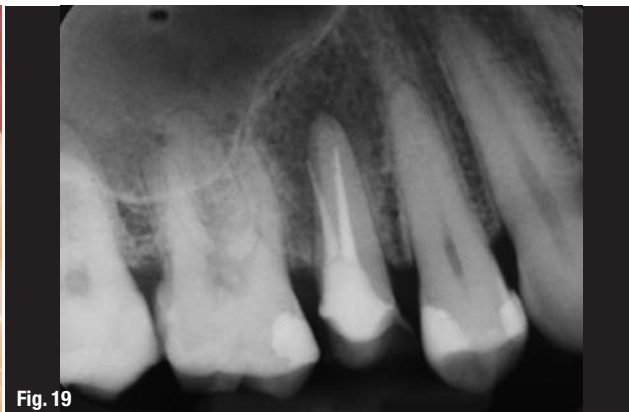


Fig. 19

hesive, biomimetic approach far less aggressive than crowns and far less technique sensitive than ceramics.

Achieving a perfect marginal quality with composite onlays, when gingival margins are located in the dentin, continues to be critical even when new adhesive techniques and systems are used.¹⁷ The application of a composite base underneath indirect composite restorations represents a feasible non-invasive alternative to surgical crown lengthening to relocate cavity margins from an intra-crevicular to a supra-gingival position. This also permits the placement of rubber dam for absolute isolation. Surgical crown lengthening may also compromise the periodontal tissue support of neighbouring teeth.¹⁸ We did this relocation simultaneously with the pre-endodontic build up with SDR. This material has the intimate wetting ability of low viscosity composite and in the same time polymerization shrinkage stress similar to regular viscosity composite.

To simplify the procedures for bonding indirect restorations, resin cements have been introduced recently that are promoted as self-adhesive—i.e., do not require a separate adhesive application step. Manufacturers claim that these cements are hydrophilic when mixed (acidic phase) but become hydrophobic (neutral pH) upon reaction with the tooth structure. The bond strengths to the tooth structure are questioned. In our case we decided to additionally etch the enamel margins of the preparation, although not recommended by the manufacturer, because the procedure is simple and, as Duarte et al.¹⁹ and de Andrade et al.²⁰ demonstrated, improves the bond strength of the restoration.

We preferred condensation-type silicone impression material for its better ability to reproduce the surface characteristics of low viscosity resin reported by Takano et al.²¹

The surface and margins of the restoration were sealed with filled adhesive. This treatment improves the marginal adaptation,²² and it could be demonstrated that adhesives are superior to specially designed resin coating materials.

Editorial note: A complete list of references is available from the publisher.

_about the authors

roots



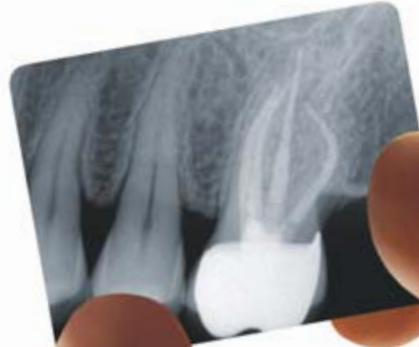
Stela Nicheva, DMD, graduated in dentistry from Medical University, Plovdiv, Bulgaria, in 2010. Currently she is taking a PhD position at the Department of Operative Dentistry and Endodontics, Faculty of Dental

Medicine, Plovdiv, Bulgaria. She may be contacted at stelanicheva@gmail.com.

Lyubomir Vangelov, DMD, is an assistant professor at Faculty of dental medicine, Department of Operative Dentistry and Endodontics, Plovdiv-Bulgaria. Simultaneously he maintains his private practice in Dental Center “Avangard,” limited to endodontics and esthetic restorations.

Ivan Filipov, DMD, PhD, is associate professor at Faculty of Dental Medicine, Department of Operative Dentistry and Endodontics, Plovdiv, Bulgaria, and maintains his private practice in Dental Center “Avangard.”

Confidence in your hands.



You're in control > TF Adaptive is designed to work with our Elements™ Adaptive Motion Technology, which allows the TF Adaptive file to self-adjust to intra-canal torsional forces. In other words — **rotary when you want it and reciprocation when you need it.**

Keep it simple > An intuitive, color-coded system designed for efficiency and ease of use.

Peace of mind > TF Adaptive is built on the success of the Classic TF design and includes the same advanced Twisted File technology.

Radiograph courtesy of Dr. Gary Glassman.

Trusted by

Gary Glassman, D.D.S.
Endodontist
Toronto, Canada



In vitro analysis of efficiency and safety of a new motion for endodontic instrumentation: TF Adaptive

Authors_ Prof. Gianluca Gambarini, Italy & Dr Gary Glassman, Canada

_Introduction

The introduction of the nickel-titanium (NiTi) alloy in endodontics was a significant improvement, allowing good results in terms of cleaning and shaping of root canals, while reducing operative time and minimising iatrogenic errors.^{1,2} Owing to the superior mechanical properties of the NiTi alloy, it was possible to use endodontic instruments of greater tapers in continuous rotation to increase the effectiveness and rapidity of the cutting.³ However, several studies reported a significant risk of intracanal separation of NiTi rotary instruments.⁴⁻⁷ Although multiple factors contribute to file separation, cyclic fatigue has been proven to be one of the leading causes.⁸ Fatigue failure usually begins with the formation of microcrack at the surface of the file that arises from surface irregularities. During each loading cycle, microcracks develop, deepening until complete separation of the file occurs.⁹ All endodontic files show some irregularities on the surface and inner defects as a consequence of the manufacturing process, and the distribution of these defects influences fracture strength of the endodontic instruments.^{10,11}

NiTi instruments have traditionally been used with a continuous motion, but in recent years a new approach to the use of NiTi instruments in a reciprocating motion has been introduced.¹² In Yared's study,¹² only one F2 ProTaper NiTi rotary instrument Dentsply (York, PA) was used for canal preparation in a clockwise (CW) and counter-clockwise (CCW) movement. The CW and the CCW rotations used by Yared were four-tenths and two-tenths of a circle, respectively, and the rotational speed was 400 rpm.¹² The concept of using a single NiTi instrument to pre-

pare the entire root canal is interesting, and it is possible because reciprocating motion is thought to reduce instrumentation stress, and new instruments have recently been introduced based on these concepts (e.g. WaveOne, DENTSPLY Tulsa Dental Specialties). Literature data has demonstrated that reciprocating motion can extend cyclic fatigue resistance of NiTi instruments compared with continuous rotation.¹³⁻¹⁵ Moreover these positive results have been an initial step for further studies because many different reciprocating movements and many different instrument designs can be used in clinical practice, thus affecting the overall results.

More recently, a new instrumentation technique (TF Adaptive) has been developed by Axis | SybronEndo, aimed at combining the advantages of both continuous rotation and reciprocation. More precisely TF Adaptive uses Adaptive Motion, a patented, undisclosed motion provided by a new endodontic motor, the Elements Motor (Axis | SybronEndo, Coppell, TX) that automatically adapts to instrumentation stress (Fig. 1). When the TF Adaptive instrument is not (or very lightly) stressed, the movement can be described as an interrupted continuous rotation, allowing optimal cutting efficiency and removal of debris, since cross-sectional and flute designs are meant to perform at their best in a CW motion. On the contrary, while negotiating the canal, owing to increased instrumentation stress and metal fatigue, the motion of the TF Adaptive instrument changes into reciprocation with specifically designed CW and CCW angles. Moreover, these angles are not constant, but vary depending on the anatomical complexities and the intra-canal stress. This adaptive motion is therefore meant to reduce the risk of intra-canal failure without affecting performance,

by the Elements Motor automatically selecting the best movement for each clinical situation.

The TF Adaptive technique is a three-file technique designed for all canals, with differences between small, difficult canals and large, easy ones, allowing in both cases an adequate taper and an increased apical preparation size. The number of instruments in the sequence may vary, depending on the canal anatomy. An instrument is used only when apical enlargement is needed due to a larger original canal dimension and/or enhanced final irrigation techniques are required (Fig. 2). More precisely, TF Adaptive is an intuitive system designed for efficiency and ease of use. The colour-coded system is based on a traffic light: start with green, continue or stop with yellow, and stop with red. Once straight-line coronal access has been achieved, apical patency and a glide path are established using a #8 hand file, followed by a #10 hand file and continued up to a #15 hand file at least.

Based on tactile perception, if the clinician finds it difficult to take a #15 K-file to working length, then the canal size is deemed to be small and the small pack (single colour band) and its instrument sequence is used. If it is loose then the medium/large pack (double colour bands) is used. TF Adaptive files are used with the Adaptive Motion mode in the Elements Motor and are slowly advanced in the canal with a single controlled motion until the file engages dentine, then completely withdrawn from the canal. Files must never be forced apically, and a pecking motion should be avoided. Following withdrawal, the file flutes are wiped clean of debris and the previous step is repeated using the file the clinician started with until working length is achieved. If some brushing action is needed it can also be performed by selecting the TF (continuous rotation) mode in the motor. The same steps are repeated using the next instruments in the sequence.

Since Twisted Files (TF) and TF Adaptive files have different operative sequences and different sizes, in the present study a single-file technique was chosen, using a #25.06 file, which is available in both TF and TF Adaptive files.

The aim of this study was two-fold: to evaluate whether the Adaptive Motion had any effect on safety (measured by *in vitro* resistance to cyclic fatigue) and on the cutting ability (measured by *in vitro* instrumentation time) of TF instruments compared with traditional continuous rotation.

Material and methods

Forty TF #25.06 NiTi instruments were randomly divided into four groups ($n = 10$ each). All of the instruments had been previously inspected using an optical stereomicroscope at 20x magnification for morphological analysis and for any signs of visible deformation. If defective instruments were found, they were discarded.

The first 20 instruments were submitted to cyclic fatigue tests. Group 1 instruments were tested using Adaptive Motion, while Group 2 instruments were used in continuous rotation for control. The speed was set at 500 rpm for Group 2, in accordance with the manufacturer's guidelines. The speed of Adaptive Motion is presently undisclosed.

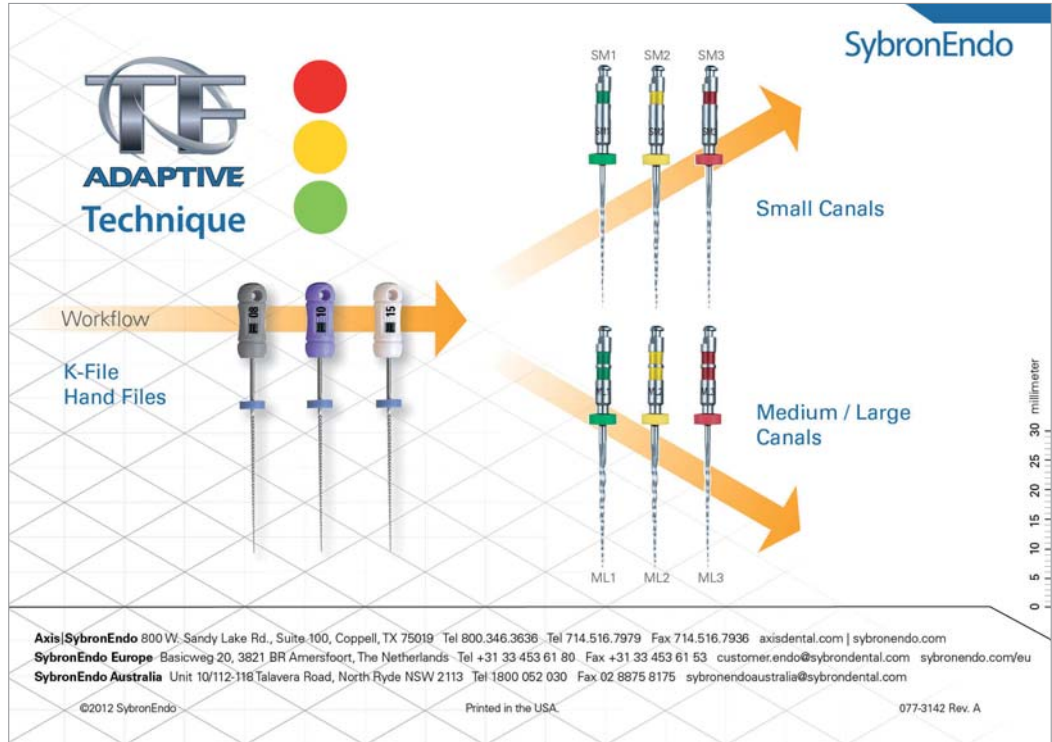
The cyclic fatigue testing device used in the present study has been used for studies on cyclic fatigue resistance previously.¹⁶ The device consists of a mainframe to which a mobile plastic sup-

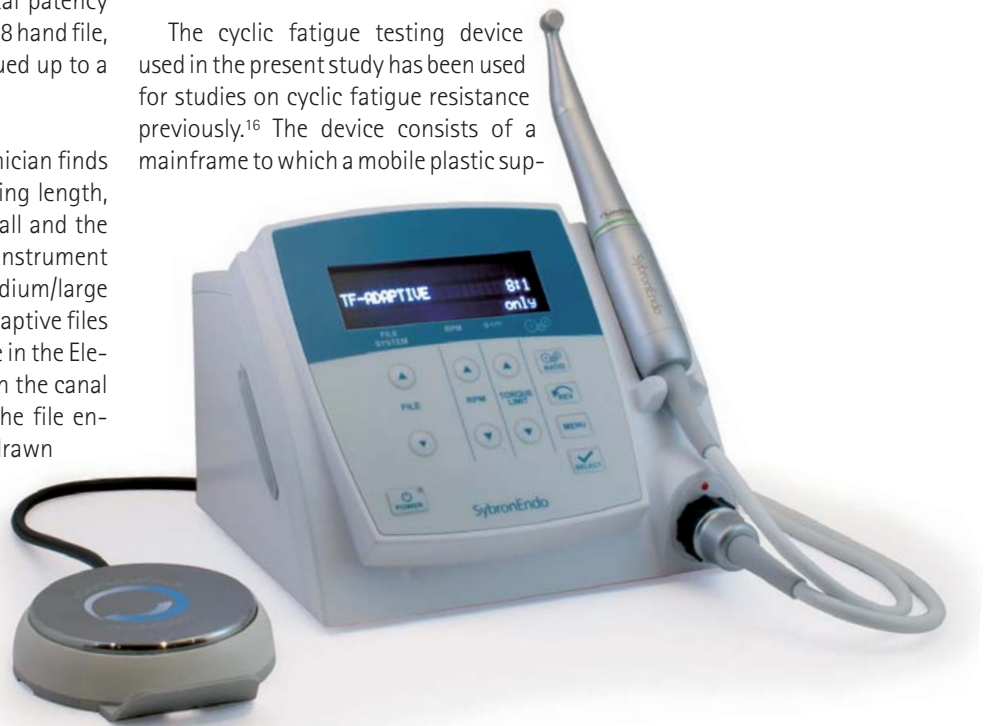

Fig. 1_The TF Adaptive motor.

port is connected for the electric handpiece and a stainless-steel block containing the artificial canals. The electric handpiece was mounted on a mobile device to allow precise and reproducible placement of each instrument inside the artificial canal. This ensured 3-D alignment and positioning of the instruments to the same depth. The artificial canal was manufactured by reproducing an instrument's size and taper, thus providing the instrument with a suitable trajectory that respected the parameters of the curvature chosen. A simulated root canal with a 60-degree angle of curvature and 5 mm radius of curvature was constructed for instrument type. The centre of the curvature was 5 mm from the tip of the instrument, and the curved segment of the canal was approximately 5 mm in length. All instruments

Fig. 2_The TF Adaptive workflow.



were rotated or reciprocated until fracture occurred. The time to fracture was recorded visually with a 1/100-second chronometer. Mean and standard deviations were calculated. All data was recorded and subjected to statistical evaluation with an analysis of variance test. (Statistical significance was set at $P < 0.05$.)

The other 20 instruments were randomly assigned to Group 3 (Adaptive Motion) and Group 4 (continuous rotation), and they were used to prepare a curved artificial canal in a transparent plastic block (SybronEndo preparation block) using a single-file instrumentation technique. Instrumentation time to reach working length was recorded visually with a 1/100-second chronometer. Mean and standard deviations were calculated. All data was recorded and subjected to statistical evaluation with an analysis of variance test. (Statistical significance was set at $P < 0.05$.)

Results

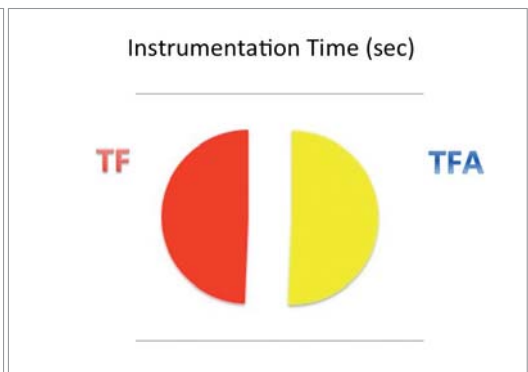
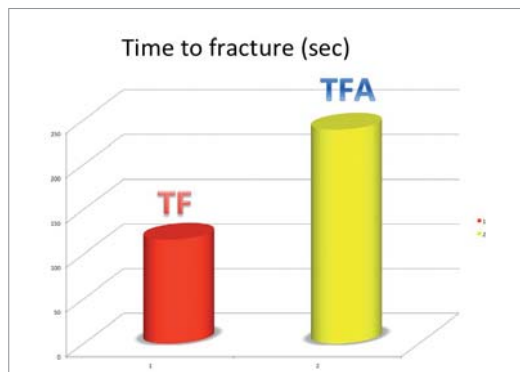
Adaptive Motion showed a significant increase ($p < 0.05$) in the time to fracture compared with continuous rotation. The mean time to fracture was 239 seconds (SD 11.5 seconds) for Group 1 and 116 seconds (SD 9.5 seconds) for Group 2. The mean instrumentation time was 11.5 seconds (SD 1.5 seconds) for Group 3 and 11.2 seconds (SD 1.5 seconds) for Group 4. Statistical analysis did not find significant differences ($p > 0.05$) between the two groups.

Discussion

Although multiple factors contribute to file separation, cyclic fatigue has been demonstrated to be one of the leading causes.¹⁷ Recently, the advancement in TF technology and the manufacturing process has allowed the production of a new generation of NiTi instruments, with better flexibility and greater resist-

Fig. 3_Cyclic fatigue resistance of TF #25.06 used with Adaptive Motion (AD: yellow column) and continuous rotation (CR: red column).

Fig. 4_Cyclic fatigue resistance of TF #25.06 used with Adaptive Motion (AD: yellow column) and continuous rotation (CR: red column).



ance to cyclic fatigue.¹⁸ Very few studies have been published so far about the effect of reciprocation on the lifespan of TF endodontic instruments, but they have all found very positive results: reciprocating motion extends cyclic fatigue life compared with continuous rotation.¹⁹ However the term "reciprocating motion" includes several possible movements and angles, each of which may influence the performance and strength of the NiTi instruments.

In the present study, a new reciprocating motion (Adaptive Motion) was evaluated and compared with traditional continuous rotation, using TF instruments. The results of the present study clearly demonstrate that Adaptive Motion significantly extended the cyclic fatigue life of TF instruments compared with continuous rotation. Kinematics is among the many factors that may affect the lifespan of NiTi instruments because it determines the stress distribution that the instrument accumulates over time.

No statistically significant differences were found in the instrumentation time between TF used in the Adaptive Motion and continuous rotation. This is a positive finding because reciprocating motion is considered to be less effective in cutting (and in debris removal) compared with continuous rotation. This is easy to understand because the design has cutting angles and flutes that tend to remove debris in one direction of rotation, and a releasing angle (which is theoretically non-cutting or less cutting) with flutes that do not tend to remove debris in the opposite direction of rotation. In some marketing brochures, reciprocating single-file instrumentation techniques have been shown to reduce instrumentation time significantly, but these results are mainly due to one instrument being compared with a sequence of four to six instruments. The real advantage of kinematics regarding the reduction of instrumentation time of a single instrument has not yet been proven.

Although the angles are not disclosed by the manufacturers, visual inspection and video recordings show that Adaptive Motion is a reciprocating motion with cutting angles (CW angles in Adaptive Motion) much greater than those of WaveOne movements. As a consequence the TF Adaptive instrument works at a CW angle more often, which allows better cutting efficiency and removal of debris (and less tendency to push debris apically) because the flutes are designed to cut dentine and remove debris in a CW rotation. In this way, TF Adaptive takes advantage of the use of a motion that is more similar to continuous rotation for optimal cutting and debris removal. There are obviously some changes in the angles depending on canal anatomy (the more complex, the smaller the CW angle, or the larger the CCW angle), but they did not seem to influence the overall results in the present

study significantly. On the contrary, these changes influenced resistance to metal fatigue, since TF instruments used with Adaptive Motion were found to have superior resistance to cyclic fatigue compared with the same TF instruments used in continuous rotation. Hence, we may conclude that Adaptive Motion has a positive effect on safety (measured by *in vitro* resistance to cyclic fatigue), while maintaining efficiency (cutting ability measured by *in vitro* instrumentation time) of TF instruments compared with traditional continuous rotation.

Editorial note: A complete list of references is available from the publisher.

_about the authors

roots

Prof. Gianluca Gambarini is a Professor of Endodontics at the Sapienza University of Rome's dental school in Italy. He is an international lecturer and researcher, and the author of numerous scientific articles, books and chapters in books. He has lectured extensively all over the world, and has been invited as a main speaker to the most significant international endodontic congresses in Europe, North and South America, Asia, the Middle East, Australia and South Africa. His research interests include endodontic materials and clinical endodontics. He is actively collaborating with a number of manufacturers all over the world to develop new technologies, operative procedures and materials for root-canal treatment.

He is an official member of the American National Standards Institute/American Dental Association and ISO Committee for Endodontic Materials. He is an active member of the International Association for Dental Research, Italian Endodontic Society (SIE) and European Society of Endodontology (ESE). He is an associate member of the American Association of Endodontics. He is the former scientific editor of the *Giornale Italiano di Endodonzia* (SIE's official journal), and is the country representative for Italy in the ESE. Prof. Gambarini also works in a private endodontics practice in Rome.

Dr Gary D. Glassman, Fellow of the Royal College of Dentists of Canada, graduated from the University of Toronto Faculty of Dentistry in 1984 with a Doctor of Dental Surgery degree, and was awarded the James B. Willmott Scholarship, the Mosby Scholarship and the George Hare Endodontic Scholarship for proficiency in endodontics. A graduate of the Endodontology programme at Temple University in 1987, he received the Louis I. Grossman Study Club Award for Academic and Clinical Proficiency in Endodontics. He is the author of numerous publications, and the endodontic editor for the *Oral Health* journal. He is on the staff at the University of Toronto Faculty of Dentistry in the Graduate Department of Endodontics, and is an Adjunct Professor of Dentistry and Director of Endodontic Programming at the University of Technology, Jamaica, in Kingston. Dr Glassman maintains a private practice, Endodontic Specialists, in Toronto in Canada.

YouTube: <https://www.youtube.com/user/DrGaryGlassman>

Twitter: @doctorg007

Blog: <http://drgaryglassman.blogspot.com/>

Website: www.rootcanals.ca

MounceFiles: A safe, economical and efficient option for canal preparation

Author_Dr Rich Mounce, USA

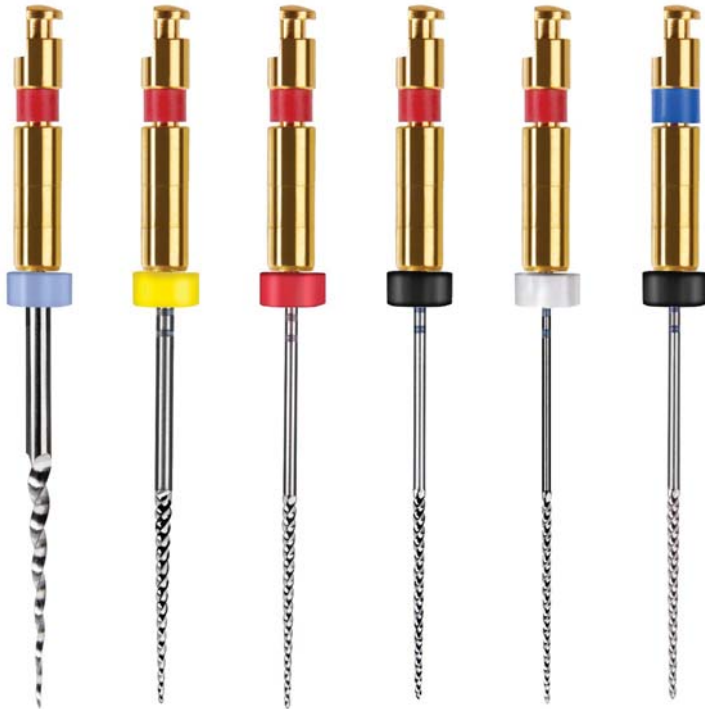

Fig. 1a

Figs. 1a & b_The MounceFile SNT Assorted Pack.

Opinions vary as to the best means to achieve three dimensional, cleansing, shaping and obturation of the root canal system. Emerging technology, literature research and proven clinical success all provide clinicians with options, evidence and methods for their clinical techniques. Presently, there is no commercial consensus on the optimal methods for canal preparation, especially when considered across the wide range of clinical cases encountered. The options in the marketplace are myriad—DENSTPLY, Coltène Whaledent, Axis | Sybron, SpecializedEndo, Brasseler, Ultradent.

Taking into account the present state-of-the-art in nickel-titanium science and manufacture, literature evidence and extensive clinical experience, what follows are the author's chosen materials and meth-

ods of shaping root canal systems, i.e., the MounceFile. This article was written both to introduce the MounceFile and suggest that the reader compare his or her present systems and treatment strategies for achieving the goals of canal preparation.

The goals of canal preparation are to:

- _ Maintain the original position of the canal.
- _ Maintain the original position and size of the apical foramen.
- _ Prepare a tapering funnel with narrowing cross-sectional diameters (in essence, to mimic the shape of a tornado).
- _ Prepare a taper that is proportional to the external dimensions of the root that does not predispose the root to subsequent vertical root fracture.
- _ Prepare a taper that allows cone fit with tug back and ideal obturation hydraulics during down pack with warm vertical obturation techniques (and warm techniques of all types).
- _ Prepare a taper that optimizes the necessary volume and space for activation of endodontic irrigants.

Among other valid and clinically proven marketplace choices, MounceFiles represent a literature-based, clinically valid, safe, efficient and economical option for canal preparation.



Fig. 1a




Fig. 2a Mani D finders.
Fig. 2b Mani K files.
Fig. 2c Safe-ended Mani hand SEC O K file.

Universal application

It is a personal bias that not every instrumentation system is applicable to all canal anatomy encountered. Canal anatomy is infinite in its diversity (three-rooted lower molars, etc.), variety (length, curvature, etc.), clinical challenge (resorption, immature apices, etc.) and the environment in which these canals are treated (limited opening, excessive swallowing by patients, etc.). "One size fits all" algorithms worksome or most of the time, but given the above variables, in the wrong clinical situation, otherwise typical clinical actions can lead to iatrogenic events.

MounceFiles come in two forms of nickel titanium, Controlled Memory (CM) and standard nickel titanium (SNT). CM nickel-titanium files result from a proprietary thermomechanical treatment of nickel-titanium whereby once curved, the files remain curved. Clinically, this means that as a CM instrument rotates through a curvature, the file remains curved, a valuable attribute in a complex canal. SNT files are superelastic, meaning they spring back to their original shape after being stressed (used clinically). CM instruments have shown increased resistance to cyclic fatigue and other attributes relative to their superelastic counterparts.¹⁻⁵

MounceFiles are square in cross section, non-landed and of constant taper throughout their cutting flutes. The square cross-section provides added fracture resistance relative to triangular crosssections due to the increased metal mass in this dimension.

The MounceFile Assorted Pack is designed more for the general dentist and the typical endodontic case. Specifically, this pack is ideal for teeth that are 18–23 mm long, have roots of moderate curvature and canals that are located with relative ease and negotiable with hand files. The MounceFile CM Assorted Pack and MounceFile SNT Assorted Pack are configured (from left to right in the box) from larger tapers to smaller: .08/.25; .06/.25; .04/.25; .03/.25; .02/.25; .03/.30 (Fig. 1).

The MounceFile system was developed to give endodontists a virtually unlimited choice of tapers and tip sizes to custom assemble their file configurations and handle virtually any clinical case. If the endodontist (or general dentist handling complex cases) wants to customize his or her selection of MounceFiles, there are 75 combinations of taper and tip size available in both CM and SNT files. Tapers include .01 in addition to the tapers present in the assorted packs. Tip sizes among the tapers range from 20–60, depending on the taper.

The breadth of this product line gives an unlimited set of options for clinicians of any experience level (from dental school graduates to veteran endodontists) to treat virtually any canal (from a straightforward #8 to a more complex 25 mm C shaped #18 with multiplanar curvature and a relatively open apex in proximity to the inferior alveolar nerve).

Clinical technique

The following directions for use and FAQs have been adapted from PDFs on the www.MounceEndo.com website. These directions reference the MounceFile CM Assorted Pack. The directions for the MounceFile SNT Assorted Pack are identical to those below.

Specifically, the MounceFile CM Assorted Pack is used within the context of the following treatment steps:

Step 1: Estimate the true working length

Before making access, the clinician should estimate the true working length (TWL) from the initial preoperative radiographs. This is the estimated working length (EWL). The EWL is used later to help confirm the TWL, which is determined radiographically or electronically (Foramatron-Parkell, Elements Diagnostic Unit-Axis/Sybron, Root ZX II-J Morita).

Step 2: Prepare straight-line access

Straight-line access is achieved when all of the canals can be seen in one mirror view and hand




Fig. 2d Synea W&H WA-62, a reciprocating hand piece.

Fig. 3a_The MounceFile .08/25 rotary nickel-titanium orifice opener in Controlled Memory (retains its shape once a curve is placed upon it).

and rotary files can be inserted without deflection off the axial walls of the preparation.

Step 3: Remove the cervical dentinal triangle

The .08/25 MounceFile CM is inserted 2–3 mm below the orifice and removed with a brushing motion up and away from the furcation (against the canal wall of greatest thickness). After removal of the CDT, the pulp chamber and canal orifice is irrigated copiously.

Step 4: Shape the coronal third

After CDT removal, using light pressure, the .08/25 MounceFile CM is gently inserted to the point of first canal curvature. Insertion is gentle and should ideally take about three seconds. The file is not used with a pecking motion. If the file will advance easily and shape the coronal third or advance to the point of first curvature, then it can be taken to this level.

If the .08/25 MounceFile CM file will not easily reach the point of first curvature (or shape the coronal third) after several insertions, do not force the file to reach length. Move to Step No. 5. Irrigate copiously after every insertion of the orifice opener.

Step 5: Establish and/or confirm apical patency

Stainless-steel K files are used to establish and/or confirm apical patency (Mani K files, Mani D Finders, Mani Flexile K files). Using the EWL determined from the pre-operative radiographs, pre-curved hand K files (#6, #8, #10; whatever size is appropriate to the canal treated) are inserted successively until the EWL is reached. Now the clinician should verify he or she has reached the apex of the root with an electronic apex locator and/or a radiograph. The EWL and the TWL should be relatively close if not identical.

Step 6: Prepare a glide path

Once a hand file reaches the apex and TWL is established, the canal should be enlarged to the diameter of a #20 hand file, i.e., prepare a glide path. One proven method to prepare a glide path is with #6, #8, #10, #15 and #20 hand K files used in succession. A reciprocating handpiece can be immensely helpful in preparing a glide path, especially using a safe-ended hand K file (Mani SEC O K file) (Figs. 2a–d).

Fig. 3b_The MounceFile .08/25 rotary nickel-titanium orifice opener in Standard NiTi (SNT) (superelastic, returns to its original shape upon being curved/stressed).

Fig. 3a



Step 7: Prepare the canal "crown down"

The .06/25, .04/25, .03/25, .02/25, .03/30 files are used successively until the desired taper and tip size is achieved. In the majority of clinical cases, a .06 taper is prepared to the apex (i.e., to the TWL). Using the MounceFile CM Assorted Pack, this means the .06/25 instrument will be taken to the TWL before preparation of the master apical diameter.

If any given file in the MounceFile CM Assorted Pack does not advance apically without undue pressure, move to the next smaller file in the sequence (from left to right in the pack, i.e., crown down) and continue to use them in succession (from larger tapers to smaller) until the desired taper is prepared to the apex.

As with the .08/25 MounceFile CM file, the insertion should be gentle, to resistance and take approximately three seconds. Such file engagement should remove approximately 4–6 mm of dentin with each insertion. Do not use a pecking motion or force the files apically. After each insertion, irrigate the canal and recapitulate with a small (#8, for example) hand K file to assure patency (Figs 3a, b).

Step 8: Prepare the master apical diameter

Once the final taper is prepared (generally .06 taper), the .03/30 MounceFile CM file is taken to the TWL to prepare the master apical diameter (MAD). If the clinician wishes to prepare a larger MAD, he or she can do so by whatever means is desired.

_Important supplementary information

Use an electric torque control endodontic motor (TCM III-Axis/Sybron).

500 rpm is recommended. Rotational speed can be modified depending on clinician experience and preference from 500–900 rpm.

A gentle and feather touch insertion of the file is recommended. Insertion should seek to minimize engagement of the instrument to 4–6 mm of canal wall per insertion, which generally will take about 3 seconds. Files should be rotating when inserted. Files should be inserted or removed but never left stationary while in use. Do not use a pecking motion or insert the file repeatedly in order to progress apically. If the canal resists apical advancement while using minimal pressure, remove the instrument and chose the next smaller file in the sequence.

After file insertion, the flutes are wiped of debris, the canal irrigated and the canal recapitulated with a small hand K file (Mani K file #8 or #10).

Fig. 3b



To minimize risk of canal transportation and/or file separation, each file should be taken to the true working length only once for 1-2 seconds, then removed.

Irrigation and recapitulation should be performed after every insertion.

If the file is inserted as per the instructions above, using torque control with the auto reverse function engaged is a matter of clinician preference. Single use is recommended.

Discard files in an appropriate Biohazard Sharps Container.

Straight-line access and removal of the cervical dentinal triangle are recommended.

While a step back approach to instrumentation is feasible and possible in many canal anatomies, the MounceFile CM and SNT instruments are used most efficiently in a "crown down" (CD) sequence, shaping the coronal third first, middle third second and apical third last. Clinically, this means that larger taper and tip-sized instruments are used first followed by smaller.

Rubber stopper colors on the MounceFiles indicate taper size: .01 Purple, .02 White, .03 Black, .04 Red, .06 Yellow, .08 Light Blue.

The .08/25 mm orifice opener in the 21 and 25 mm MounceFile CM and MounceFile SNT Assorted Packs is 21 mm long.

No set of instructions or precautions is comprehensive. Evaluation of clinical risks is essential. Treatment algorithms and clinical strategies must often be revised in the face of anatomical challenges (severe calcification, curvature, open apices, etc.). Clinical judgment and caution are advised.

_ FAQs

_ What is "Controlled Memory" (CM) and how do these files differ from standard nickel-titanium files?

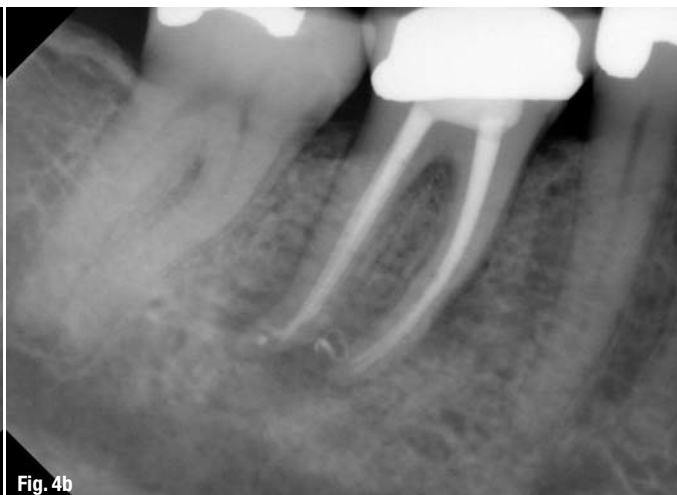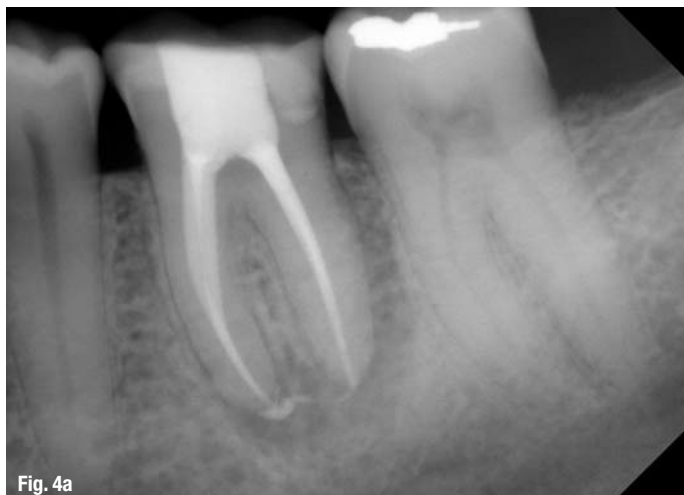Controlled Memory instruments have been subjected to a proprietary thermomechanical treatment that provides significant resistance to cyclic fatigue relative to nickel-titanium (NT) instruments without this treatment. When a CM instrument curves during

AD



Biological & Conservative





Figs. 4a & b Clinical cases treated with the MounceFile CM and SNT Assorted pack (.08/25, .06/25, .04/25, .03/25, .02/25, .03/30) utilizing the techniques discussed.

treatment, it retains its shape. CM treatment reduces the effects of NT shape memory, minimizing transportation. Use of CM instruments versus the MounceFile SNT (standard nickel titanium) files is a matter of personal preference with the limitation that SNT instruments are less resistant to cyclic fatigue relative to the CM variety.

How many times can I use the MounceFile CM and SNT files?

Single use of the MounceFile CM and SNT instruments is recommended.

How do I sterilize new packs of files?

With a steam autoclave, sterilize the instruments at 136 degrees C for 20 minutes.

Can I use MounceFile CM and SNT files to remove gutta-percha?

Yes, appropriately sized MounceFile CM and SNT files can be used to remove gutta-percha in retreatment.

Is torque control recommended?

If the file is inserted as per the instructions below, using torque control with the auto reverse function engaged is a matter of clinician preference.

Why is the .03/30 MounceFile CM instrument at the end of the sequence?

The .03/30 MounceFile CM instrument (at the far right of file box) allows the clinician to prepare the apical diameter to a #30 tip size.

How do I obturate a canal prepared by the MounceFile CM Assorted Pack?

Canals can be obturated in whatever manner the clinician chooses. Using vertical compaction and lateral condensation techniques, it is efficient to learn to trim cones. Specifically, a .06/25 cone trimmed 1 mm from its tip is approximately equivalent to a #30 ISO instrument. If the clinician is using carrier-based obturation, he or she can use a size verifier and place the carrier as desired.

What if I want to prepare a larger apical diameter than a #30 tip size?

The clinician can use whatever means he or she desires to prepare an apical diameter larger than a #30. In the MounceFile CM file system, the .03-tapered instrument is available (among other tip sizes) in a #40 tip size.

What is "crown down" instrumentation and what are the advantages of this approach in canal shaping?

After straight-line access is prepared, the orifice shaped, the canals negotiated to the apical foramen and a glide path prepared, crown down instrumentation means that the coronal third is prepared first, the middle third prepared second and the apical third last. In essence, the clinician is preparing the root from the crown of the tooth to the root apex, so crown down (CD).

The advantages of CD instrumentation outweigh any relative disadvantages. A CD approach removes restrictive dentin, especially in the coronal third, and facilitates its removal by allowing early and copious irrigation prior to enlargement of the middle and apical thirds. Removal of restrictive dentin and its evacuation from the root minimizes the possibility that this debris will be pushed apically. Alternatively, leaving this debris risks canal blockage, an outcome correlated with uncleaned and unfilled canal space and canal transportation.

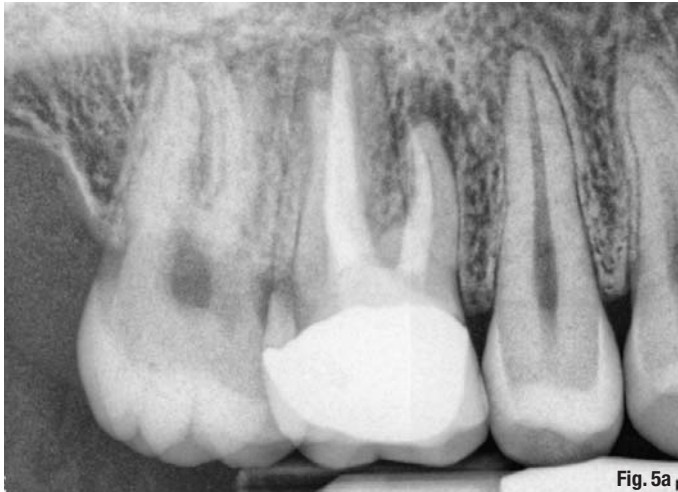

Fig. 5a

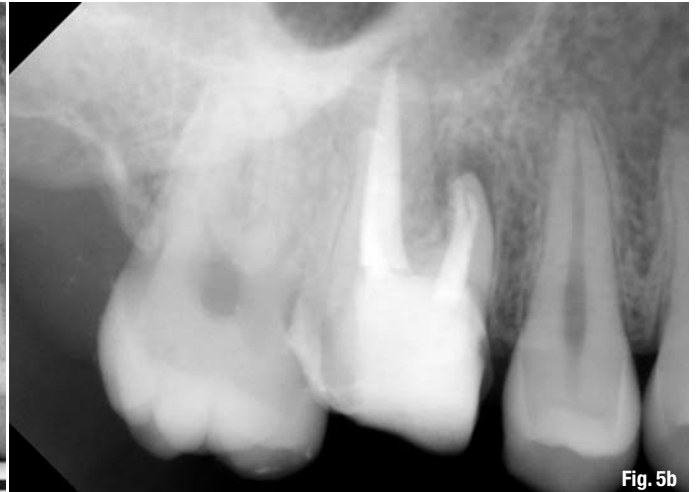

Fig. 5b

Are there any contraindications to crown down instrumentation?

There are no absolute contraindications to the CD technique. There are several clinical situations where a CD approach might be less efficient. Specifically, cases of severe curvature, with or without severe calcification, might argue for a step back (SB) approach or a combination CD and SB approach. Such severe cases are not what the MounceFile CM Assorted Pack were designed to treat and these cases generally require a combination of specialized techniques (Figs. 4, 5).

What pre-operative considerations are correlated with endodontic success (among other factors)?

Optimal visualization (ideally a surgical operating microscope, most certainly loupes, Global Surgical, Zeiss, Orascope).

Copious irrigation.

Use of the rubber dam for every case, without exception.

Use of a bite block where possible.

Profound anesthesia (STA-Milestone Scientific).

Pre-operative assessment of case risks (number of roots, curvature, calcification, risk of perforation, open apices, presence of root resorption, etc.)

Diagnostic radiographs (taken from different angles) and a cone beam where indicated to fully illustrate the anatomy (Planmeca, Sirona).

Referral when it is in the best interest of the patient.

Staff training and education (if the staff knows what each step of the treatment process is intended to accomplish, they can provide the needed support more efficiently).

Having the needed instruments available in the sizes required and having them organized in a fashion that makes them easy to access and store while not in use.

Detailed informed consent.

This clinical article has introduced the MounceFiles, a new, literature-based, clinically valid, safe, economical and efficient rotary nickel-titanium option for canal preparation. Emphasis has been placed on blending proven clinical principles with the instruments discussed. Readers are encouraged to compare their present systems and treatment strategies to those presented here. I welcome your feedback.

Editorial note: A complete list of references is available from the publisher.

Figs. 5a & b Clinical case re-treated with MounceFiles. Pre-operative view (a). Completed case with the MB2 located and treated (b).

about the author

roots



Rich Mounce, DDS,

is in full-time endodontic practice in Rapid City, S.D. He has lectured and written globally in the specialty. He owns MounceEndo, LLC, marketing the rotary nickel-titanium MounceFile in Controlled Memory and

Standard NiTi. MounceEndo is an authorized dealer of Mani stainless-steel hand files and burs. MounceEndo also markets W&H reciprocating hand piece attachments. Mounce can be reached at richardmounce@mounceendo.com, www.mounceendo.com and on Twitter at @MounceEndo

Hands on with the new reciprocating motion file system

Author_ Dr Thomas Jovicich, USA

The frontiers in dental technology are constantly in a state of flux. Today's instruments will become tomorrow's news, as metallurgical principles and manufacturing techniques continue to push the envelope. All of the major dental companies are actively involved in surpassing the boundaries of science and technology. This is especially true in shaping root-canal systems.

Science and technology

Choosing a file system can be quite frustrating. The market is awash in choices. Most major dental companies confuse this issue by offering a plethora of options; one company offers more than ten distinct file lines. How does one choose? What are the parameters used to make the choice?

Dentists base their decisions on any or all of these:

1. price;
2. ease of use;
3. the number of files in each system;
4. safety;
5. what the company representative recommends;
6. the file system already in use when the dentist bought the practice.

As a practising endodontist I want a file system that is a combination of cutting-edge technology, ease of use and safety. The TF Adaptive system satisfies all of those needs for me. TF Adaptive files are manufactured from a single piece of triangular-shaped nickel-titanium (NiTi) wire, manufactured through a proprietary heating, twisting and cooling process, which then undergoes a wash process that minimises handling of the file. Minimal handling of the file in the manufacturing stage increases its ability to withstand torsional and cyclic stresses. This twisting creates a super-elastic file. First-generation NiTi files are lathe cut. Scanning electron microscope studies show that during the manufacturing process these files develop microcrystalline fracture lines, which under torsional



Fig. 1_ The TF Adaptive system and small files.

According to the American Association of Endodontists, 41,000 root canals are performed each day worldwide. In the US, 15 per cent of people still avoid any kind of dental treatment. Statistics point to the need for endodontic treatment. In a busy generalist practice, most endodontic treatments are referred to the specialist. Since the middle of 2006 and the change in world economics, an increasing number of general dentists have begun performing endodontic treatment in the office. Academically, most dentists had limited exposure to endodontics during their student training; therefore, their confidence in performing endodontics in their office is low.

The goal of this article is to aid the reader in choosing a shaping system that is easy to use and simple in design with a focus on safety. Leonardo da Vinci once said, "Simplicity is the ultimate sophistication." The TF Adaptive system (Axis | SybronEndo) epitomises that concept (Fig. 1).

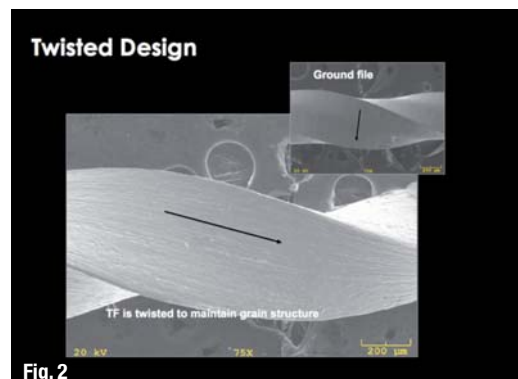


Fig. 2_ The grain structure of a TF vs. lathe-cut (ground) file.

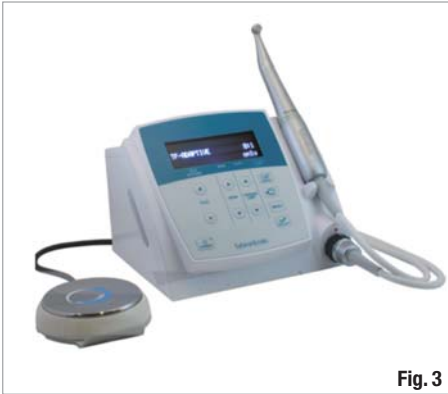

Fig. 3

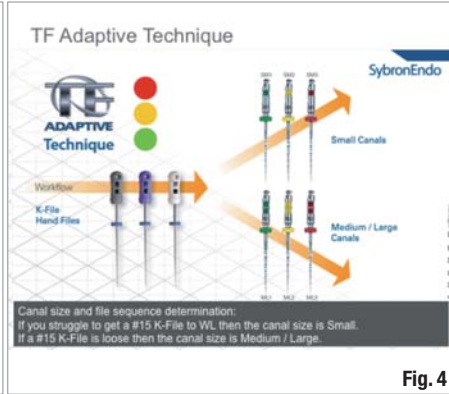


Fig. 4

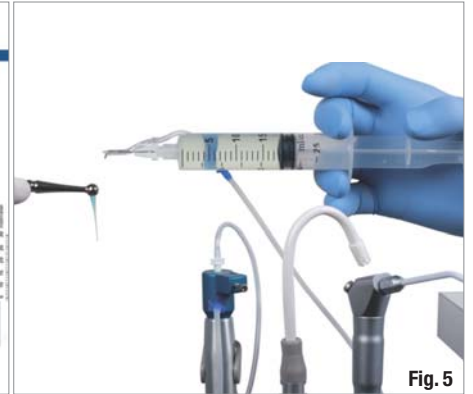

Fig. 5

stress can lead to fatigue and fracture (Fig. 2). Thus, files with this property can lead to premature obturation under stress.

In any dental procedure, success is most likely when the clinician treats with confidence, competence, consistency, and most importantly, common sense. TF Adaptive files are designed primarily with safety in mind, and are used with the Elements Motor (Axis | SybronEndo). This motor is the brain of the system, employing a complex algorithm that detects file loading (Fig. 3).

TF Adaptive files are designed to decrease torsional fatigue, which occurs when a file locks in the canal during rotation. In addition, the amount of cyclic fatigue the file can undergo is increased owing to reciprocation algorithms in the Elements Motor, thereby increasing safety.¹

The TF Adaptive system allows for 600 degrees of interrupted rotation when unloaded. When a load is detected, the file can rotate 370 degrees in a clockwise motion followed by 10–50 degrees of counter-clockwise motion. During clockwise rotation, debris is moved up and out of the canal, minimising apical extrusion of debris and decreasing post-treatment discomfort compared with the WaveOne system (DENTSPLY Tulsa Dental Specialties).

_Clinical impressions

One of the first things I noticed is that the shaping ability of the file continues the tradition of the Twisted Files (TF) shaping system (SybronEndo). Reciprocating motion adds a layer of safety that is unparalleled. Initially, it takes a short time to become used to the interrupted motion of the file. Thereafter, the beauty of the technique is its simplicity and ease of use. You place the file into the canal in a single, smooth motion. Once you feel the engagement, you remove the file from the canal and wipe it clean, looking for any visible changes in the flute. Then you irrigate the canal fully and if needed re-enter the canal with the same

file or move on to the next file in the shaping sequence (Fig. 4).

The system is colour-coded to mirror that of a traffic light. It is easy for your staff too, and markedly decreases the amount of stock you need to keep on hand to perform endodontics.

I found the files to be very easy to use. I found the shaping sequence logical and clinically relevant. The goal is to prepare the apex to at least a #35. This enables me to know that my irrigation protocol using the EndoVac (SybronEndo) will allow my irrigants to reach the apex in sufficient concentration to clean the root-canal system safely (Fig. 5).

The TF Adaptive system increases the clinician's ability to safely, predictably, and efficiently shape the root-canal system. It is a quantum leap in technology that offers unparalleled metallurgical advances, combined with motor technology, to create the safest shaping system currently on the market.

_Conclusion

As a clinical endodontist, I am always looking for a file system that will offer me a way to shape the root-canal system easily, predictably and most of all safely. Over the years, I have come across and used a myriad of file systems, each one promising to be the latest and greatest. Some were very aggressive, some were very stiff, and others tried to be one file fits all. Since incorporating TF Adaptive into my practice on a daily basis, and analysing the science behind the technology through a thorough review of the literature, I believe that TF Adaptive and reciprocating motion offers me the safest, most consistent way to shape a root-canal system.

_Reference

1. Gambarini et al., Influence of different angles of reciprocation on the cyclic fatigue of nickel-titanium endodontic instruments, *Journal of Endodontics*, 38/10 (2012): 1408–11.

Fig. 3_ The Elements Motor has pre-sets for TF Adaptive, TF Classic, the M4 motor attachment, and K3XF, and offers custom-speed settings.

Fig. 4_ Sequence recommendations for TF Adaptive.

Figs. 5_ The EndoVac apical negative pressure irrigation system.

_author	roots
<p>Dr Thomas Jovicich is the director of the West Valley Endodontic Group located in Encino, California, USA. In addition to working in his private practice, he has been a key opinion leader for Sybron Dental Specialties since 2000. He lectures around the world on current concepts and theories in endodontics. Dr Jovicich hosts a learning laboratory in his office for dentists, teaching them to perform clinical endodontics on their patients under the surgical operating microscope utilising state-of-the-art technology and materials.</p>	
<p>_contact Dr Thomas Jovicich Suite 534 5363 Balboa Blvd Encino CA 91316 USA</p>	

Adapting to the anatomy, guided by the canal

Author _ Dr Philippe Sleiman, Lebanon

_Root-canal anatomy with all of its inherent complexity still represents a very serious challenge to modern root-canal therapy. Even with many breakthroughs in technology, we are still not capable of fully cleaning and shaping the root-canal system. It is true that rotary NiTi files are a very helpful treatment tool, yet we are still learning and discovering how to use them effectively to achieve the best possible clinical result with respect to the existing biology and anatomy.

The anatomy often looks seems demanding because it represents several traps and danger zones during the shaping and cleaning process. This is true for the entire length of the canal, but particularly so in the apical region. Stainless-steel files are still the first files to be used, in small sizes, usually no more than #15, in order to avoid failures caused by apical transportation. Rotary files can shape better and faster than stainless-steel hand files can, but depending on their design and the alloy used they may also lead to deformation or straightening of the canal. For this reason, it is crucial to understand both the design of the instrument and the alloy.

According to multiple studies, ground triangular cross-section instruments often modify the existing shape of canals by straightening them in the middle third. This type of instrument in a mesial canal will often lead to a strip perforation due to the instrument's tendency to lean on the internal portion of the canal wall. Using this instrument in a reciprocating motion with fixed angles of rotation has been shown to push debris forward and out of the root-canal system by packing the debris internally.

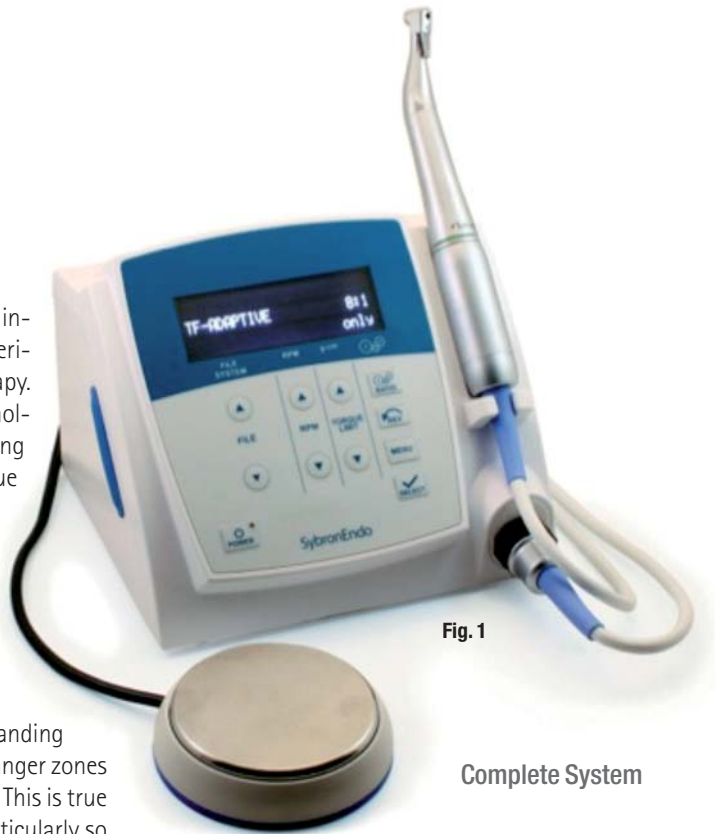


Fig. 1

Complete System

The canal itself is what should lead you down; it determines how it must be negotiated and shaped. What I mean is that the curves of a root canal are not regular, nor are they recurring. Each canal has its own unique anatomy and curves; therefore, it determines both the rotational speed and the angle of engagement between the file and the dentine. Each canal guides the files down the canal safely and preserves the initial shape of the root-canal system.

The most recent innovation from Axis|Sybron-Endo, TFAdaptive (Fig. 1), allows for complete flexibility of rotation angle, and therefore the speed and power required to prepare the canal. The primary forces leading to canal separation are torsional and cyclic fatigue. When these are combined, there is a substantial amount of stress on the file during the shaping procedure. Since the anatomy of each canal is different, we sometimes encounter difficulty using

files in continuous rotation. In these situations, Adaptive Motion may be of great assistance in shaping the canals safely, respecting the original anatomy. In a more difficult curve, the angles of rotation are smaller and change according to the stress applied to the instrument. Clinically, it is very difficult to feel these changes, but we can determine from the sound that the file is progressing more slowly or at a lower angle of engagement. This automatically provides the balanced force required by the instrument to adapt to the canal in order to provide the optimal shape for cleaning of the root-canal system. This is best described as interrupted but continuous rotation with variable reciprocation according to resistance.

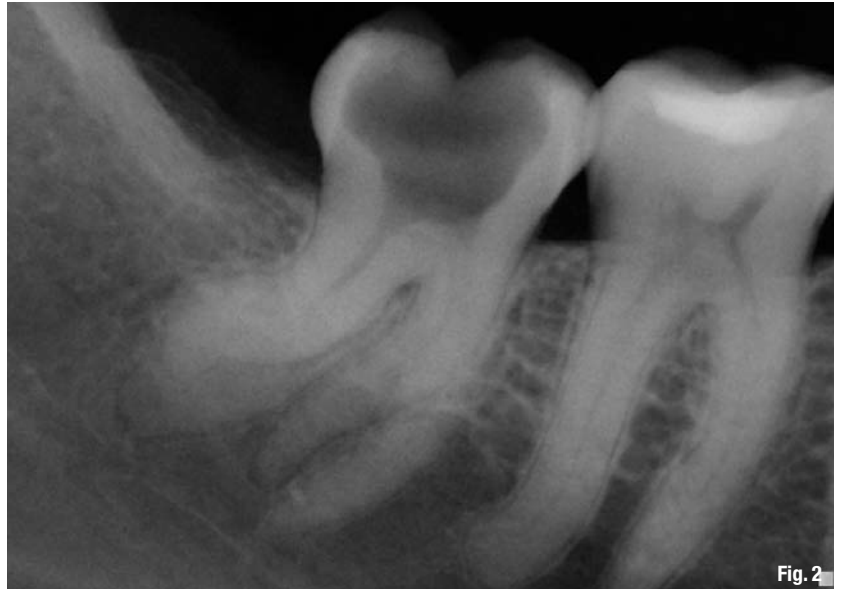Case 1

"Spooked" is the right word to describe my feelings when I first saw this X-ray (Fig. 2). The patient and I were both concerned about the treatment of this mandibular molar. It took 18 months for the patient to return to the office. Fortunately, a mix of double-antibiotic paste and a small amount of steroid had been placed in her canals to maintain some stability during this long period. As the temporary paste's effectiveness had diminished, the patient was motivated to request an appointment.

Once the patient was in the chair, the other dentists in my clinic seemed even more excited by this case than I was because they kept visiting my operatory. After several seconds of EndoVac usage, I checked the patency of the canals with a nicely pre-curved #10 K-file. The distal roots captured my attention because the preoperative X-ray showed very peculiar anatomy. With very careful scouting of the canal, I was able to determine that a single opening led to this very complex root-canal system of multiple canals.

Starting with the M4 Safety Handpiece (Sybron-Endo) and a #10 K-file, I established patency and created a path of lower tension for the NiTi files to follow. I used a sequence of irrigants to prevent the smear layer from blocking access to the rest of the root-canal system. Shaping of the canal was a challenge, and then the moment everyone was waiting for had arrived.

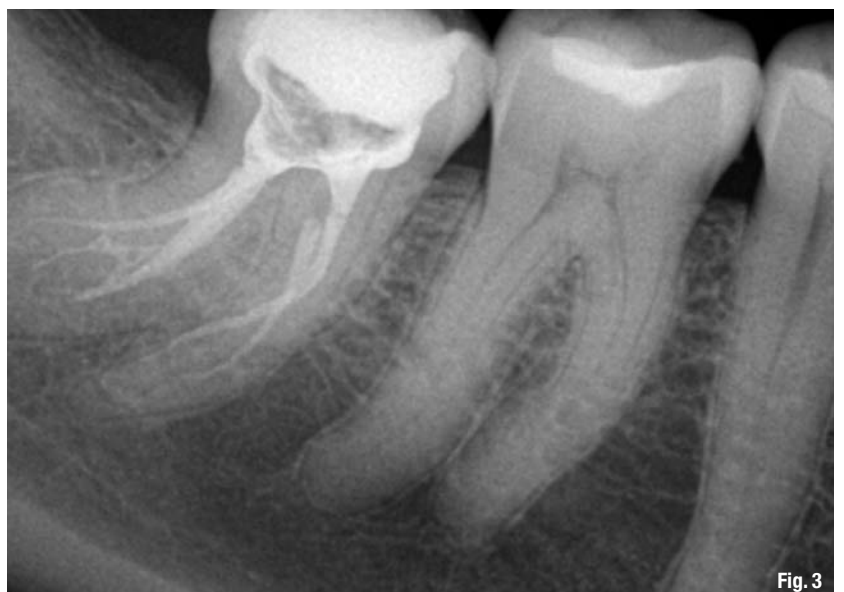Adaptive Motion was selected on the Elements Motor (Axis | Sybron-Endo), and the golden rule of less taper behind the curve was on my mind. Since it was a very unusual case, I chose to approach it in a different way. I first used the #25.08 Twisted File (Sybron-Endo) for only a few millimetres at the orifice of the canal to facilitate the access of other files and to have a stable working length. I then used a #10 K-file to establish working length. I performed shaping and



cleaning first with a TF Adaptive S2 instrument (#20.04) by taking it as deep as it would go with a few strokes in the Adaptive Motion mode. It was interesting to feel and hear the various sounds and the speed changing each time the file went into a canal or upon repeated insertion in the same canal. This file was followed by a #25.04 TF Adaptive file and it was able to reach working length in all the canals after just a few seconds of instrumentation.

Apical enlargement of the last 3 mm in my opinion is essential to success in endodontics. Therefore, I decided to finish with 0.2 taper K3 files (Sybron-Endo) because taper is not as important as tip size with regard to apical enlargement.

The sequence of irrigants used was effective in preventing the smear layer from blocking the root-



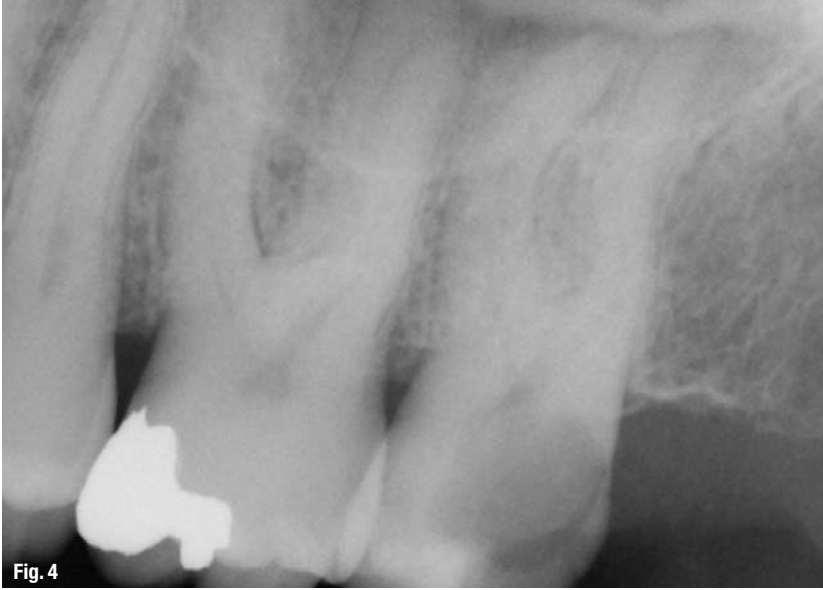

Fig. 4

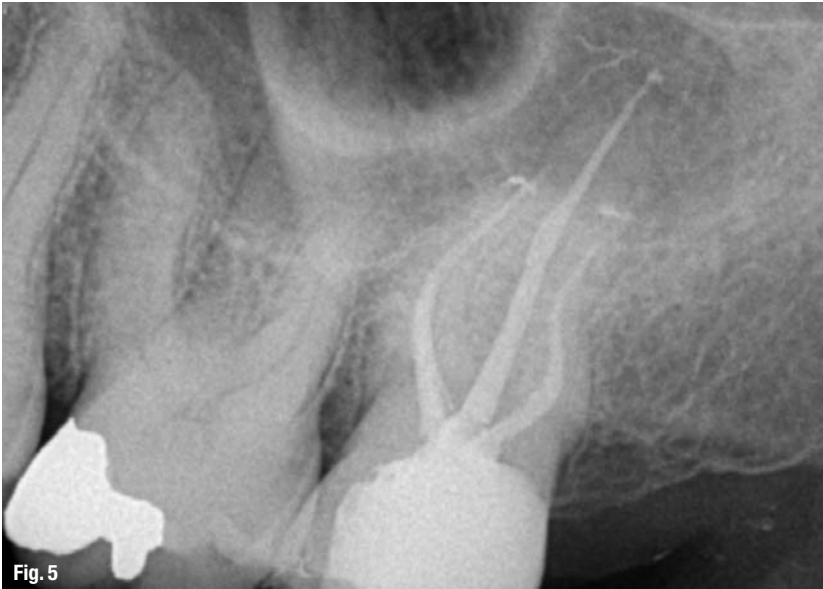


Fig. 5

canal system by using the irrigants with the EndoVac (SybronEndo). The negative apical pressure delivered the irrigants in a very safe, efficient, and effective manner. The EndoVac is a superb way to dry the canal by removing the majority of the liquids from the root-canal system, thereby preventing them from blocking the obturation material compacted using a modified warm condensation technique to seal the root-canal system.

The post-operative X-ray (Fig. 3) showed that this complex had been properly cleaned and shaped, and verified the necessity of the irrigation protocol, the choice of files, and the method of rotation, which prevented debris from being packed into the isthmus. The middle canal of the distal root was not touched with an instrument. Although the X-ray cannot fully reveal the complexity and shape of the anatomy and curves of this molar, the patient left the office more than happy that she was able to retain her natural molar.

Case 2

Maxillary second molars are usually tricky and they sometimes have a strange access cavity. In addition, the patient is very rarely able to open his or her mouth wide enough for the dentist to be able to work properly and comfortably.

On the preoperative X-ray (Fig. 4), a nicely shaped distal canal was evident, as well as some periapical problems. Finding the second mesial canal was very difficult owing to the angulation of the coronal third, and establishing straight-line access required removal of a great deal of tooth structure, thereby making the molar vulnerable to fracture.

The small TF Adaptive pack was chosen, and after checking patency and using the M4 Safety Handpiece for 10–15 seconds per canal, the first file (green) was taken to working length.

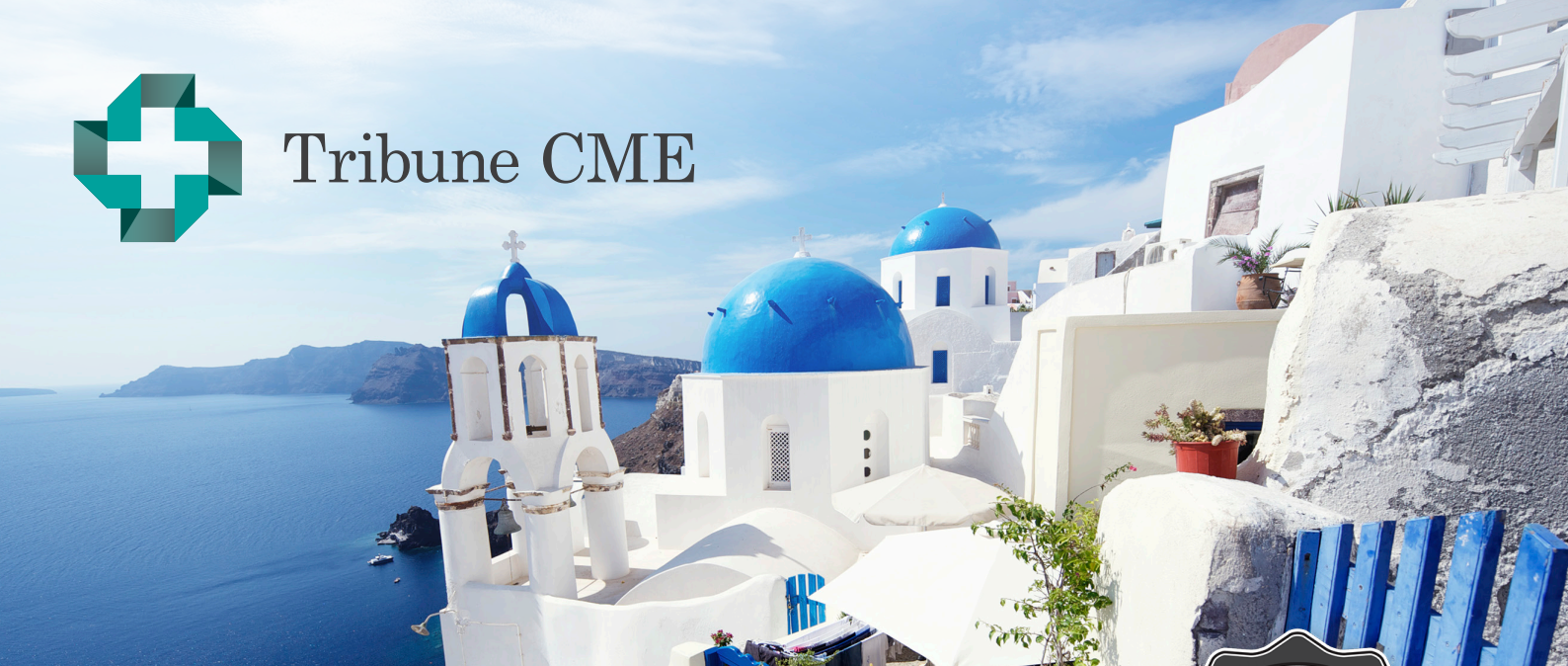It established that the rotary file had prepared the canal sufficiently to maintain a stable working length. This was followed by the second file (yellow) to working length, and the final file (red) was taken to working length too, using just a few strokes in the Adaptive Motion mode.

Shaping the distal canal was not a problem and I could unmistakably feel that the files were changing and adapting to the specific clinical situation each time they were in contact with the dentine. The post-operative X-ray (Fig. 5) shows the shape of the distal canal, and the access to the mesial canals can be assessed.

_author	roots
	<p>Dr Philippe Sleiman American Dental Clinic Dubai Jumeirah Road Dubai UAE phil2sleiman@hotmail</p>



Tribune CME



1 Year Clinical Masters Program in **Aesthetic and Restorative Dentistry**

13 days of intensive live training with the Masters
in **Santorini (GR), Geneva (CH), Pesaro (IT)**



Three on location sessions with **live patient treatment, hands on practice** plus online learning and online mentoring under the Masters' supervision.

Learn from the **Masters** of Aesthetic and Restorative Dentistry:



Dr. Ed McLaren



Dr. Daniel Edelhoff



Dr. Marc Geissberger



Dr. Mauro Fradeani



Dr. Stavros Pelekanos



Dr. Didier Dietschi



Dr. Francesco Mangani

Registration information:


13 days of live training with the Masters
in Santorini, Geneva, Pesaro + self study

Details and dates on www.TribuneCME.com

Curriculum fee: € 9,900 contact us at tel.: **+49-341-48474-302** / email: **request@tribunecme**
(€ 900 when registering, € 3,000 prior to each session)

Collaborate
on your cases

and access hours of
premium video training
and live webinars




University
of the Pacific

you will receive a
certificate from the
University of the Pacific



Latest iPad
with courses

all early birds receive
an iPad preloaded with
premium dental courses



150 ADA CERP
C.E. CREDITS

ADA C.E.R.P.® | Continuing Education
Recognition Program

Tribune America LLC is the ADA CERP provider. ADA CERP is a service of the American Dental Association to assist dental professionals in identifying quality providers of continuing dental education. ADA CERP does not approve or endorse individual courses or instructors, nor does it imply acceptance of credit hours by boards of dentistry.

Eight-year follow-up of successful intentional replantation

Authors_ Dr Muhamad Abu-Hussein, Greece; Dr Sarafianou Aspasia, Greece; & Dr Abdulgani Azzaldeen, Israel

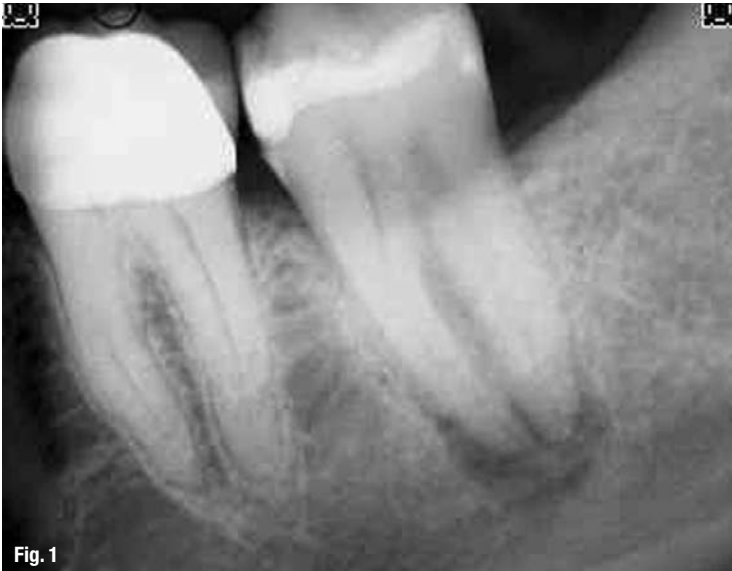

Fig. 1

Fig. 1 Pulpal diagnosis: necrosis, narrow periodontal pocket 10mm deep, Grade I+ mobility.

_Abstract

Intentional replantation has been practised for many years as a treatment modality for pulpless teeth. Although the success ratio for intentional replantation is far below that for routine or surgical endodontics, this procedure should be considered an alternative to tooth extraction. A case of mandibular second molars treated with intentional replantation and retrograde fillings is reported in this article. At the eight-year recall visit, radiographs showed no evidence of pathological changes.

_Introduction

Intentional replantation (IR) is the extraction of a tooth to perform extra-oral root-canal therapy, curettage of an apical lesion when present and its replacement in its socket.^{1,2} Grossman in 1982³

defined it as follows: "A purposeful removal of a tooth and its reinsertion into the socket almost immediately after sealing the apical foramina." He also stated that it is "the act of deliberately removing a tooth and following examination, diagnosis, endodontic manipulation, and repair, returning the tooth to its original socket to correct an apparent clinical or radiographic endodontic failure"⁴ It is a one-stage treatment that will maintain the natural tooth aesthetics if successful.⁵

This method was first reported nearly a thousand years ago. In the eleventh century AD, Abulcasis gave the first account of replantation and use of ligatures to splint the replanted tooth.⁶ Fauchard, in 1712,⁷ reported an IR performed 15 minutes after extraction. In 1768, Berdmore reported IR of mature and immature teeth.⁸ In 1783, Woofendale reported IR of diseased teeth.⁹ In 1778, Hunter believed that boiling the extracted tooth prior to replantation might help to remove the tooth disease.¹⁰

In 1890, Scheff¹¹ addressed the role of the periodontal ligament (PDL) in the prognosis of replanted teeth. In 1955, Hammer¹² described the importance of leaving an intact PDL on intentionally replanted teeth. He believed that a healthy PDL is essential for reattachment and retention of replanted teeth. He stated "an average 10 years life span could be expected when replantation was accomplished in a technically flawless manner." In 1961, Loe and Waerhaug¹³ tried to replant teeth immediately to keep the PDL vital. Consequently, ankylosis was not seen; however, all teeth showed resorption repaired with cementum. These results were confirmed by Deeb in 1965¹⁴ and Edwards in 1966.¹⁵ In 1968, Sherman¹⁶ showed that normal PDL could be kept vital.

Intentional replantation is specifically indicated

- _ when all other endodontic non-surgical and surgical treatments have failed or are deemed impossible to perform;
- _ when the patient is not able to open his or her mouth fully, preventing the performance of non-surgical or peri-radicular surgical endodontic procedures;
- _ in the case of root-canal obstructions; and
- _ when there are restorative or perforation root defects in areas that are not accessible via the usual surgical approach without excessive loss of root length or alveolar bone.

Contra-indications may include

- _ long, curved roots;
- _ advanced periodontal diseases that have resulted in poor periodontal support and tooth mobility;
- _ multi-rooted teeth with diverging roots that make extraction and replantation impossible; and
- _ teeth with non-restorable caries.

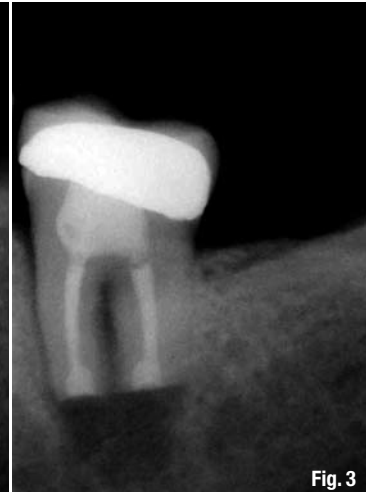
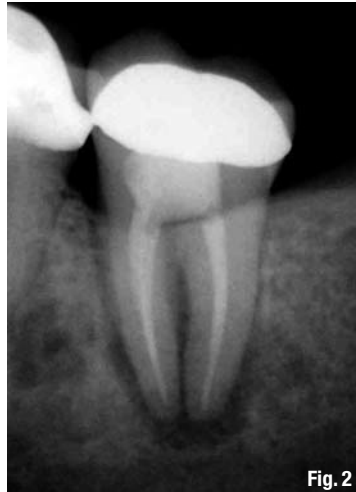In order to provide the best long-term prognosis for a tooth that is to be replanted intentionally, the tooth must be kept out of the socket for the shortest period possible, and the extraction of the tooth should be atraumatic to minimise damage to the cementum and the PDL.^{1,7,8} The PDL attached to the root surface be kept moist in saline, Hanks' balanced salt solution, Viaspan or a doxycycline solution for the entire time the tooth is outside the socket.

We have documented three clinical cases to exemplify the potential of IR as a viable treatment option in select endodontic cases. The purpose of this article is to report a case of successful IR as an alternative to extraction.^{13-15,17}

Case report

A 48-year-old woman was referred for evaluation and treatment of a painful mandibular left second molar. The patient described recent severe throbbing pain associated with the left second molar area, extending to the left ear, of three days' duration. The patient stated that she had had a cavity in tooth 37 (Fig. 1) and her dentist had performed root-canal therapy a few months before her presentation. Upon examination, tenderness to percussion and palpation were noted and sulcus depths around tooth 37 did not exceed 3 mm. Radiographic examination revealed an endodontic failure associated with a periradicular radiolucency (Fig. 2).

The patient was anaesthetised, and tooth 37 was extracted and received in a sterile gauze sponge sat-



urated with saline solution. The wound was packed with sterile gauze and the patient asked to close her teeth together to immobilise the pack. Resection of both the mesial and distal roots was performed by bevelling the root tip with a #702 bur in a straight handpiece. Retro-preparation of the mesial root was accomplished using a #1/2 round bur in a contra-angle handpiece with copious irrigation. An MTA retrograde filling was placed in the root canals (Fig. 3). Once the extra-oral procedure had been completed the socket was irrigated gently with a normal saline solution to remove the clot and the tooth was replanted. No splint was needed.

Six weeks later, the patient was asymptomatic and the replanted tooth was firm in its socket. At the time, the patient was advised to proceed with the final restoration on the replanted molar (Figs. 4-8).

After one year (Fig. 9), three years (Fig. 10), four years (Fig. 11) and eight years (Fig. 12), the patient attended for evaluation and radiographs were taken of the tooth. The radiographs showed no evidence of resorption and the patient was asymptomatic.

Fig. 2 A radiograph after six months: same pocket depth, Grade II mobility, plenty of exudate.

Fig. 3 Extracted, apex filled with MTA; no exudate and Grade I+ mobility at the two-month recall.

Fig. 4 A radiograph after six weeks showing the healing periapical lesion.

Fig. 5 A radiograph after six months showing no fractures; no widened PDL, Grade I mobility.

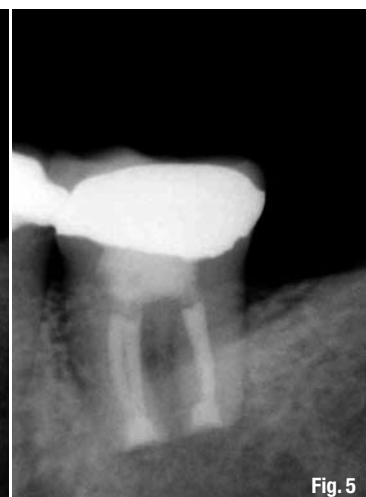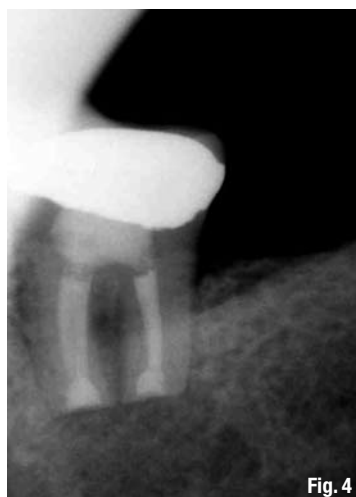

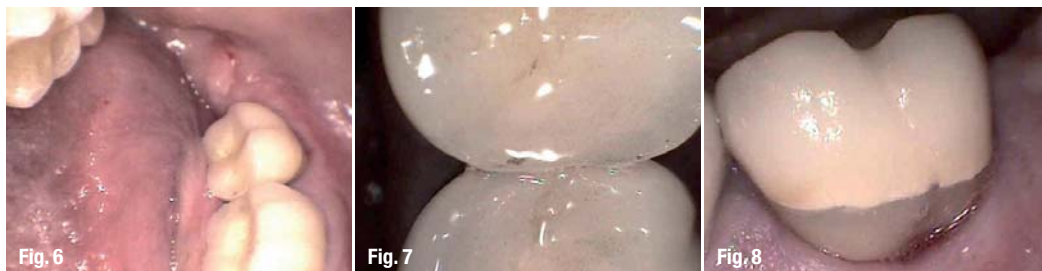
Fig. 6_Intra-oral photograph showing the clinical situation.

Fig. 7_Closed contacts between teeth.

Fig. 8_Gingival recession present, periodontal pocket depths were 2–3 mm around the tooth. There was little bleeding on probing.



Discussion

Intentional replantation is an accepted endodontic procedure in cases in which intra-canal and surgical endodontic treatments are not recommended. Although not frequently used, IR is a treatment option that dentists should consider under these conditions. If the standard protocols during IR are not followed, root resorption and ankylosis may be observed within one month and one to two months, respectively.^{17,18} Most resorptive processes are diagnosed within the first two to three years. However, although rare, new resorptive processes could occur even after five or ten years.¹⁷

As various investigators report varying success rates, it is difficult to predict the outcome for IR. Bender and Rossman¹⁹ evaluated 31 cases with an overall success rate of 80.6 % (six recorded failures). Replanted teeth survived from one day to 22 years. A second mandibular molar that failed after three weeks was replanted successfully a second time with no signs of failure after 46 months of follow-up.

Majorana et al.²⁰ followed 45 cases of dental trauma for five years, recording complications and responses to treatment. Root resorption was observed in 45 cases (17.24%). Of these, nine were associated with luxation injury (20%) and 36 (80%) with avulsion. The authors identified 30 cases of inflammatory root resorption (18 transient and 12

progressive) and 15 cases of ankylosis and osseous replacement.

Aqrabawi¹⁸ evaluated two cases of IR and retrograde filling of mandibular second molars. At the five-year recall visit, radiographs showed no evidence of pathological changes.

Nuzzolese et al.²¹ state that the success rate of IR at five years reported in the literature ranges from 70 to 91 %.

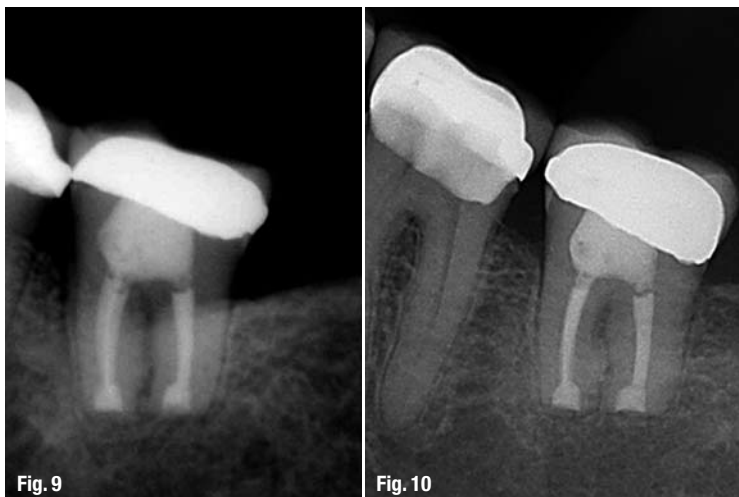
Al-Hezaimi et al.²² treated a radicular groove that predisposed a 15-year-old girl to a severe periodontal defect with a combination of endodontic, IR and Emdogain (Straumann) therapy. At the one-year follow-up, the patient was comfortable and active healing was evident.

Demiralp et al.²³ evaluated the clinical and radiographic results of IR of periodontally involved teeth after conditioning root surfaces with tetracycline hydrochloride. Thirteen patients (seven women and six men; age range: 35–52 years) with 15 periodontally involved non-salvageable teeth were included in this study. During the replantation procedure, the affected teeth were gently extracted and the granulation tissue, calculus, remaining PDL and necrotic cementum on the root surfaces were removed. Tetracycline hydrochloride, at a concentration of 100 mg/ml, was applied to the root surfaces for 5 minutes. The teeth were then replaced in their sockets and splinted. After six months, no root resorption or ankylosis was observed radiographically. Although the period of evaluation was short, the authors suggest that IR may be an alternative approach to extraction in cases in which advanced periodontal destruction is present and no other treatment can be considered.

Araujo et al.²⁴ demonstrated that root resorption, ankylosis and new attachment formation, among other processes, characterised healing of a replanted root that had been extracted and deprived of vital cementoblasts. It was also demonstrated that Emdogain therapy, that is, conditioning with EDTA and placement of enamel matrix proteins on the detached root surface, did not interfere with the healing process.

Fig. 9_A follow-up radiograph after one year.

Fig. 10_A follow-up radiograph after three years.



Peer²⁵ reviewed nine cases of IR that illustrated the feasibility of the procedure for a variety of indications. Only one case of replantation showed evidence of pathosis, reflected by root resorption or ankylosis. His report suggests that IR is a reliable and predictable procedure, and should be considered more often as a treatment method to maintain the natural dentition.

Yu et al.²⁶ reported a case in which a combined endodontic–periodontic lesion on a mandibular first molar was treated by IR and application of hydroxyapatite. Four months after the surgery, a porcelain–metal full-crown restoration was completed. At the 15-month follow-up examination, the tooth was clinically and radiographically healthy and functioned well.

Shintani et al.²⁷ performed an IR of an immature mandibular incisor that had a refractory periapical lesion. The incisor was extracted and the periapical lesion was removed by curettage. The root canal of the tooth was then rapidly irrigated, and filled with a calcium hydroxide and iodoform paste, after which the tooth was secured with an archwire splint. Five years later, no clinical or radiographic abnormalities were found, and the root apex was obturated by an apical bridge formation.

Kaufman²⁸ reported successful results of a maxillary molar tooth treated with IR after a four-year follow-up period. A mandibular first molar, which was replanted, by Czonstkowsky and Wallace²⁹ showed no signs of resorption and ankylosis after six months.¹⁴ Different investigators reported success rates varying from 52 to 95% with follow-ups of between one to 22 years in posterior teeth.^{2,15-17}

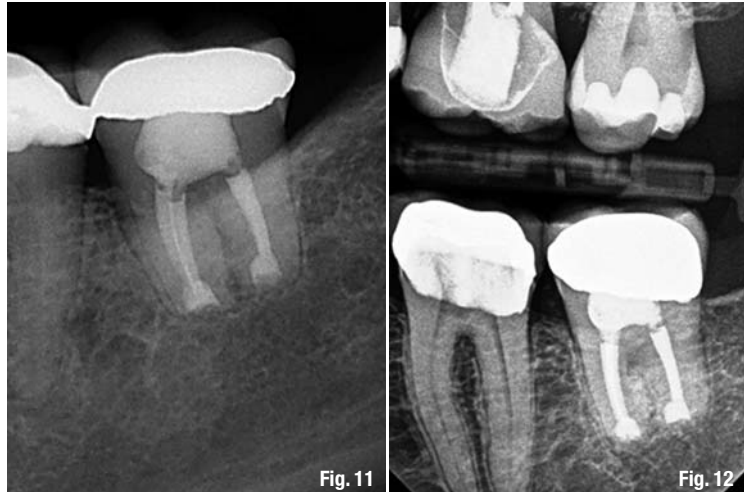Bender and Rossmann¹⁹ reported a success rate of 77.8% in molars. Among 14 mandibular molars, the success rate in first molars was 85.7%, and 71.4% in second molars. Of the four maxillary molars, three first molars and one second molar, one maxillary first molar failed, resulting in a 66.7% success rate in first molars.²

Raghoobar and Vissink³⁰ replanted 29 teeth, consisting of two mandibular first molars, 17 mandibular second molars, one mandibular third molar and nine maxillary second molars, and followed them for an average of 62 months. The success rate was 72% and 25 of them were still in function.¹⁸

_ Conclusion

For extraction and replantation to be successful, the following criteria must be met:

_ Informed consent must be obtained from the patient.



- _ All roots need to be conically shaped.
- _ The teeth need to be somewhat mobile.
- _ A good knowledge of oral surgery is needed with respect to extraction.

Fig. 11 _ A follow-up radiograph after four years.

Fig. 12 _ A follow-up radiograph after eight years.

Intentional replantation is a treatment alternative that should not be underrated, especially when conventional endodontic or surgical treatment is not possible. This is an excellent treatment with a predictable result. I have performed approximately 30 replantations, and have lost only one tooth to date.

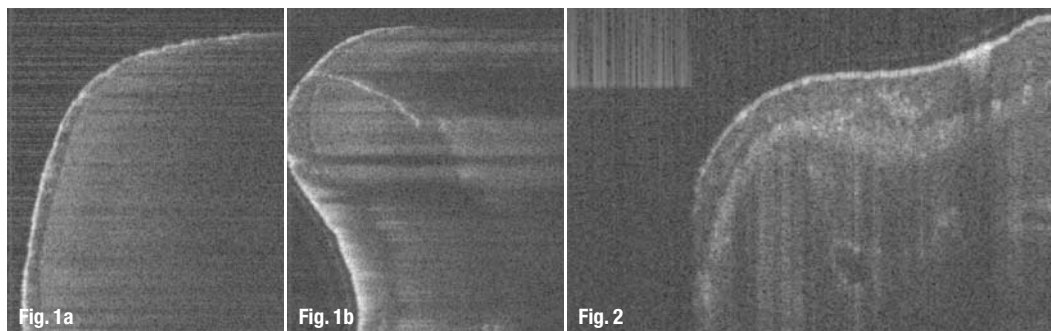
In order to be successful with extraction and replantation cases, the practitioner must have the right patient and the right rapport with that patient. The practitioner must also be able to assess the tooth and be confident that it can be extracted without breakage. Additionally, the practitioner must be able to recognise tooth morphologies that may lead to extraction problems. This is a skill that is perfected through experience. Replantation is a predictable and acceptable method of treatment in my office when patients present with root canals that require retreatment due to failure or those that cannot be completed owing to sclerosing of the canals.

Editorial note: A complete list of references is available from the publisher.

_ contact	roots
<p>Dr Muhamad Abu-Hussein 123 Argus St. 10441 Athens Greece</p> <p>abuhusseinmuhamad@gmail.com</p>	

Visual information and imaging technology in endodontics

Authors_ Prof. Hideaki Suda & Dr Toshihiko Yoshioka, Japan



_In addition to intra-oral and panoramic radiographs, various visual techniques are available for endodontic treatment today. Above all, information obtained through the dental microscope has become essential.

"See better, do better" is a slogan in modern endodontics. The dental microscope is a wonderful tool for problem-solving in endodontics, for instance for the removal of broken instruments and root-filling materials, finding missed canals, perforation repair, diagnosis of tooth fractures, evaluation of marginal integrity of restorations, precise manipulation in periradicular surgery and deep dental caries, and confirmation of root-canal cleanliness. Yoshioka et al. (2002), for example, reported that the rate of detection of root-canal orifices under a microscope was significantly higher than the number detected with the naked eye. It was also found that surgical loupes were relatively ineffective compared with the microscope.

In addition, computed tomography (CT) is becoming increasingly popular among endodontists, particularly in the assessment of difficult cases and for problem-solving in endodontic treatment. Higher use (34.2 per cent) of CBCT was demonstrated by a recent web-based survey of active members of the American As-

sociation of Endodontists in the US and Canada (Dai-ley et al. 2010). Owing to its high radiation dosage, however, careful consideration is needed before taking CT images. Consequently, a project team from the Japanese Association for Dental Science presented a report in 2010 on the use of CT in dentistry, and a joint position statement by the American Association of Endodontists and American Academy of Oral and Maxillofacial Radiology was issued in February 2011. The combined use of the dental microscope and CT for apicectomy was approved as an advanced dental technology by the Ministry of Health, Labor and Welfare in Japan in 2007, and seven Japanese dental hospitals have been using the technology since 1 February 2013.

Optical coherence tomography (OCT) is a high-resolution imaging technique that allows micrometre-scale imaging of biological tissues over small distances. It was introduced in 1991 and uses infrared light waves that are reflected from the internal microstructure within the biological tissues (Shemesh et al. 2008). There have been reports on its use for intra-canal imaging, diagnosis of vertical root fracture (Yoshioka et al. 2013) and perforations. Since OCT is non-invasive and free of radiation, this technology may be very useful for endodontic diagnosis and treatment (Figs. 1a-2).

_author

roots

Prof. Hideaki Suda is a professor of Pulp Biology and Endodontics at the Tokyo Medical & Dental University's Graduate School. During the APEC congress in Seoul, he will be presenting a paper titled "Visual information and imaging technology in endodontics".



DENTAL TRIBUNE
DT STUDY CLUB
KURSE | FOREN | BLOGS | MENTORING

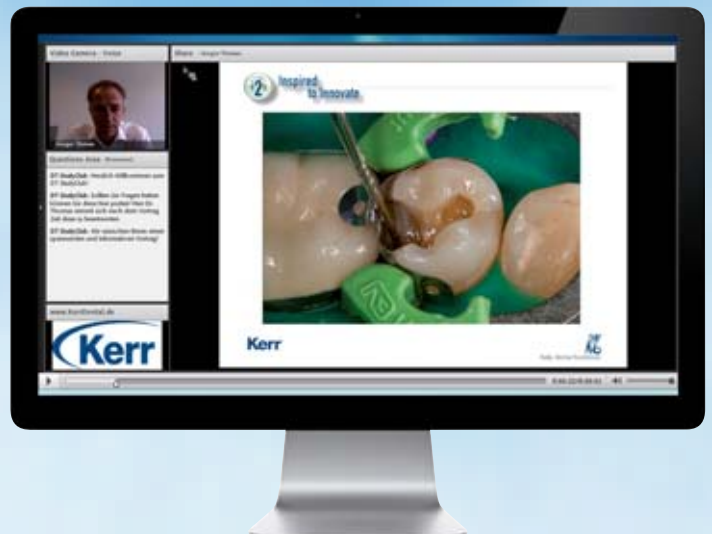Interaktive Live-Webinare und On-Demand-Kurse

Dental Tribune Study Club – Das Online-Portal für zahnärztliche Fortbildung

Der **Dental Tribune Study Club** ist ein umfassendes internationales Web-Portal für die zahnärztliche Fortbildung. Dabei werden Online-Seminare als interaktive Live-Vorträge oder Aufzeichnung sowie Mitschnitte von Vorträgen auf internationalen Kongressen einem weltweiten Fachpublikum unkompliziert zugänglich gemacht.

Die Vorteile der Online-Fortbildung im DT Study Club

- ✓ Effiziente Fortbildung
- ✓ Keine teuren Reise- oder Hotelkosten
- ✓ Keine Praxisausfallzeiten
- ✓ Fortbildung überall und jederzeit
- ✓ Austausch mit Experten und Kollegen problemlos möglich
- ✓ Zugang zu mehr als 100 Vorträgen im DT Study Club-Archiv



Wie erhalten Sie Ihre Fortbildungspunkte?

- 1 Bitte registrieren Sie sich kostenlos in unserem Online-Portal auf www.dtstudyclub.de, erst dann können Sie sich für den Vortrag registrieren und den Vortrag ansehen.
- 2 Nachdem Sie unsere Bestätigungs-E-Mail erhalten haben, klicken Sie auf den darin enthaltenen Link.
- 3 Jetzt, als Mitglied im **DT Study Club**, können Sie sich für jeden Kurs Ihrer Wahl registrieren.
- 4 Los geht's! Viel Spaß mit dem **DT Study Club** Online-Fortbildungsportal!

Für nähere Informationen wenden Sie sich bitte an
Lars Hoffmann, 0341 48474-132 oder
l.hoffmann@dental-tribune.com

www.DTStudyClub.de

Produits Dentaires presents PD MTA White

Produits Dentaires (PD) Switzerland, developer and manufacturer of MAP System for the precise placement of repair material in the root canal presented at the IDS 2013 for the first time his PD MTA White.

Furthermore the very hygienic packaging in two sachets with 280 mg each shows an additional plus for a safe and successful treatment.



For more information please visit www.pdsa.ch

This new endodontic filling material was specially developed to be placed with MAP System but it could be placed with any other technique as well. The PD MTA White offers the following advantages:

- Optimized particle size;
- Avoids bacterial migration;
- Excellent marginal sealing capacity;
- Stimulates the formation of a dentine layer (pulp capping).

contact

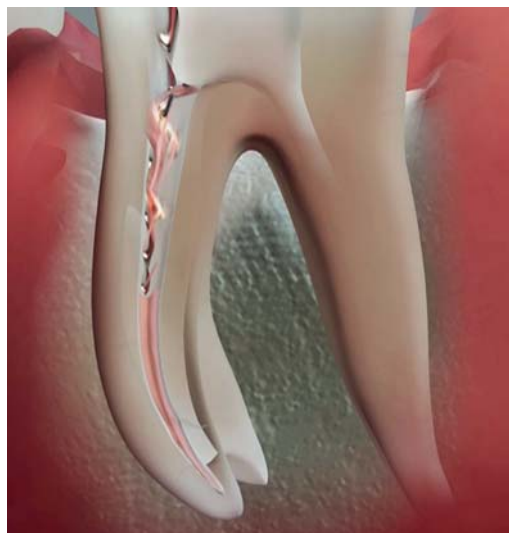roots



Produits Dentaires SA
Vevey, Switzerland

Produits Dentaires SA
Rue des Bosquets 18
1800 Vevey
Switzerland
info@pdsa.ch

RECIPROC—also efficient in retreatment



Within a short period, RECIPROC has proven to be a very successful system worldwide for root-canal preparation using a single instrument.

In addition, the system is effective in removing gutta-percha and carrier-based filling during retreatment. Thanks to the design of the instrument and its good cutting ability, the R25 is able to remove filling material efficiently and reach working length quickly.

If the canal then needs to be further enlarged, additional instrument sizes are available in the RECIPROC system.

With RECIPROC, retreatment is now easy, time-saving and safe. For more information and step-by-step instructional videos, see our website.

contact

roots

VDW GmbH

info@vdw-dental.com
www.vdw-dental.com

INTERNATIONAL EXPODENTAL

EXHIBITION

EVENTS

FORUM

COMMUNITY

MILAN ITALY

17 | 18 | 19 OCTOBER

2013

PAVILION 3
fieramilanocity



UNIDI
Italian Dental Industries Association

EXPODENTAL
forum
CE COURSES

ORGANIZED by PROMUNIDI srl V.le Forlanini, 23 | 20134 Milan | Italy | Ph. +39 02 700612.1 | expodental@expodental.it | www.expodental.it

Axis | SybronEndo: Rotary Meets Endo

Author_ Perry Lowe, USA



The name of our company, Axis | SybronEndo, is most likely both new and familiar to you, so allow me to elaborate.

Over the last year and a half, we have been combining the trusted American brand Axis Dental with the proven SybronEndo brand, with the aim of providing a global brand that focuses on workflow solutions; this led to the creation of the Axis | SybronEndo tag line "Rotary Meets Endo". The Axis products satisfy your restorative and endodontic hardware needs with a wide range of rotary instruments, diamonds, carbides and polishers that complement our SybronEndo endodontic product portfolio.

intra-canal resistance, or put more simply, rotary when you want it; reciprocation when you need it.

This exciting new product will enhance your approach towards endodontic therapy with its easy-to-use colour-coded system and the need for fewer instruments. I hope you will take a moment to try TF Adaptive the next time one of our sales professionals visits your office. Better yet, visit us at www.tfadaptive.com to learn more about this revolutionary instrument and contact us to arrange for an in-office demonstration. I am confident you will like what you see and feel.

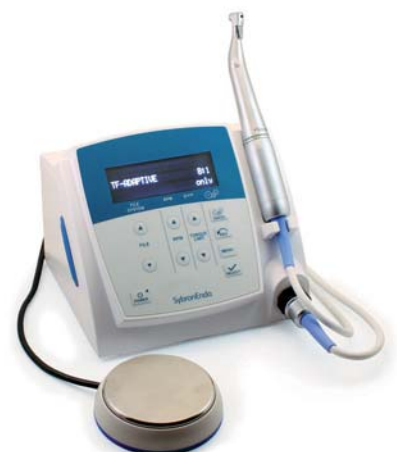_contact roots

Axis | SybronEndo
ROTARY MEETS ENDO

**Perry Lowe, President of
Axis | SybronEndo**
Suite 100
800 West Sandy Lake Rd.
Coppell TX 75019
USA

www.axisdental.com
www.tfadaptive.com

What is most exciting about our future is our increased commitment to driving innovation that improves your experience with our products and improves quality of life for your patients. Recently, we introduced TF Adaptive, an innovative and complete NiTi file system that optimises the unmatched technology, design and clinical results of our classic Twisted File (TF) design, while offering you variable reciprocation according to



The 10th World Endodontic Congress

IFEA

International Federation of Endodontic Associations



Endodontic Excellence at the Apex of Africa

2016

Cape Town, South Africa



THE ENDODONTIC SOCIETY
OF SOUTH AFRICA



A new manufacturing process for new NiTi rotary files

Author_ Dr Arnaud Stanurski, France

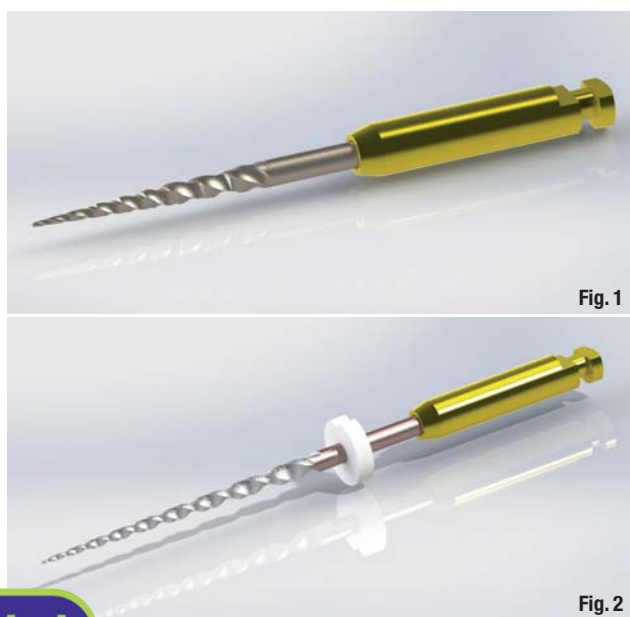

Fig. 1 _neoniti C1 (S25 - T12 - L10)
Fig. 2 _neoniti A1 (S25 - T8 - L25)

_NEOLIX, a French start-up company, is the first manufacturer to machine nickel-titanium (NiTi) files on an industrial scale, using a newly developed wire-cut electrical discharge machining (EDM) process. This manufacturing process entails the melting, evaporation and ejection of material within a dielectric field. The energy required for the machining is produced by high-frequency electrical discharges between two electrodes, that is, the workpiece on the one side and the cutting wire on the other side.

As recently described by Pérard et al.,¹ the main advantages of the EDM process over the conventional grinding process for manufacturing files are high precision—down to the micron; stable machining parameters owing to the constant and automatic adjustment of the cutting tool; stress limited to the metal surface of the workpiece; a wide range of potential geometric designs owing to the lack of tool constraints; three-day walk-away autonomy; and an oil-free, clean process. Furthermore, EDM naturally produces a rough surface on the workpiece, resulting in abrasive properties that greatly enhance the cutting speed of the NiTi rotary files.

With all these advantages, combined with an appropriate heat treatment to lend *progressive flexibility* to the files,² EDM signals a new era in the industrial production of NiTi files and the development of innovations in endodontology.

Using its exclusive EDM manufacturing process, NEOLIX has developed neoniti, a new brand of NiTi rotary files. Two files have been developed thus far: _neoniti C1, an orifice opener (S25, T12 and L10); and _neoniti A1, for root-canal preparation to full working length (S25, T8 and L25).

A series of preclinical tests were performed on natural teeth (20 maxillary molars) using a Novag endodontic motor set at 400 rpm continuous rotation. An initial glide path had been created beforehand using #10 K-files. The canals were constantly irrigated with a 2.5% sodium hypochlorite solution.

_Preliminary results

The neoniti C1 file has a high cutting efficiency, no screwing effect, and good flexibility even towards the handle, allowing good tactile perception during the circumferential brushing action. The repositioning of the canal orifices can be achieved easily and quickly.

The neoniti A1 file has no screwing effect, can achieve an easy and safe access to the apex even in the case of curved canals, and has a rounded *gothic* tip, achieving a satisfying shape of the apex for later successful root-canal filling. According to the preliminary results, it appears that the neoniti A1 file can be used for a single-instrument technique in continuous rotation after the use of the orifice opener. Further studies should be carried out to corroborate these promising preliminary results.

References

1. M. Pérard et al., "INITIAL: Début d'une nouvelle ère d'instruments endodontiques?" *Roots France*, 1 (2012): 32–8.
2. Courtesy of Dr John McSpadden.

_contact	roots
<p>NEOLIX SAS 11, av. Raoul Vadepié 53600 Châtres-la-Forêt France</p> <p>neolix@neolix.eu www.neolix.eu</p>	

THE BUSINESS OF DENTISTRY



**INTERNATIONAL DENTAL
EXHIBITION AND MEETING
APRIL 4 - 6, 2014**

Suntec Singapore International Convention and Exhibition Centre

The Gateway to the Asia Pacific's Dental Markets

IDEM Singapore is a highly targeted trade exhibition and conference that offers exhibitors unrivalled prospects to meet and do business with the dental fraternity in the Asia Pacific region.

With a powerful combination of an extensive international trade exhibition and a world-class scientific conference, IDEM Singapore has been a cornerstone event in the dental community calendar since 2000.

Capitalize on this unique opportunity and participate in this "must attend" event for every professional who is in the business of dentistry.

Endorsed By



Supported By



Held In



In Cooperation With



Co-organizer



International

Ms. Stephanie Sim

T: +65 6500 6723

F: +65 6296 2771

E: s.sim@koelnmesse.com.sg

International Events

2013

ESE Biennial Congress
12–14 September 2013
Lisbon, Portugal
www.e-s-e.eu

**Canadian Academy of Endodontics
Annual General Meeting**
16–22 September 2013
Ottawa, Ontario, Canada
www.caendo.ca

**Italian Academy of Endodontics (AIE)
AIE National Congress**
3–5 October 2013
Montecatini Terme, Italy
www.accademiaitalianaendodonzia.it

AMED Annual Meeting & Scientific Session
3–5 October 2013
Orlando, Florida
www.microscopedentistry.com

DGZ & DGET joint meeting
10–12 October 2013
Marburg, Germany
www.dget.de

The Uruguayan Endodontic Congress
15–18 October 2013
Montevideo, Uruguay
www.endodonciauruguay.com

**Prenez Racines –
International Endodontic Conference**
22 October 2013
Paris, France
www.prenez-racines.com

ADA Annual Session
31 October–3 November 2013
New Orleans, USA
www.ada.org

**Italian Endodontic Society (SIE)
33rd National Congress**
7–9 November 2013
Turin, Italy
www.endodonzia.it

**BAET – Successful Endodontics:
Foundations and new Treatment Avenues**
8 November 2013
Brussels, Belgium
www.baet.org

AAE Fall Conference
14–16 November 2013
Las Vegas, USA
www.aae.org

ADF Annual Dental Meeting
26–30 November 2013
Paris, France
www.adf.asso.fr

3rd Pan Arab endodontic congress
28–30 November 2013
Beirut, Lebanon
www.paec2013.org



© Vlad G

submission guidelines:

Please note that all the textual components of your submission must be combined into one MS Word document. Please do not submit multiple files for each of these items:

- _ the complete article;
- _ all the image (tables, charts, photographs, etc.) captions;
- _ the complete list of sources consulted; and
- _ the author or contact information (biographical sketch, mailing address, e-mail address, etc.).

In addition, images must not be embedded into the MS Word document. All images must be submitted separately, and details about such submission follow below under image requirements.

Text length

Article lengths can vary greatly—from 1,500 to 5,500 words—depending on the subject matter. Our approach is that if you need more or less words to do the topic justice, then please make the article as long or as short as necessary.

We can run an unusually long article in multiple parts, but this usually entails a topic for which each part can stand alone because it contains so much information.

In short, we do not want to limit you in terms of article length, so please use the word count above as a general guideline and if you have specific questions, please do not hesitate to contact us.

Text formatting

We also ask that you forego any special formatting beyond the use of italics and boldface. If you would like to emphasise certain words within the text, please only use italics (do not use underlining or a larger font size). Boldface is reserved for article headers. Please do not use underlining.

Please use single spacing and make sure that the text is left justified. Please do not centre text on the page. Do not indent paragraphs, rather place a blank line between paragraphs. Please do not add tab stops.

Should you require a special layout, please let the word processing programme you are using help you do this formatting automatically. Similarly, should you need to make a list, or add footnotes or endnotes, please let the word processing programme do it for you automatically. There are menus in every programme that will enable you to do so. The fact is that no matter how carefully done, errors can creep in when you try to number footnotes yourself.

Any formatting contrary to stated above will require us to remove such formatting before layout, which is very time-consuming. Please consider this when formatting your document.

Image requirements

Please number images consecutively throughout the article by using a new number for each image. If it is imperative that certain images are grouped together, then use lowercase letters to designate these in a group (for example, 2a, 2b, 2c).

Please place image references in your article wherever they are appropriate, whether in the middle or at the end of a sentence. If you do not directly refer to the image, place the reference at the end of the sentence to which it relates enclosed within brackets and before the period.

In addition, please note:

- _ We require images in TIF or JPEG format.
- _ These images must be no smaller than 6x6 cm in size at 300 DPI.
- _ These image files must be no smaller than 80 KB in size (or they will print the size of a postage stamp!).

Larger image files are always better, and those approximately the size of 1 MB are best. Thus, do not size large image files down to meet our requirements but send us the largest files available. (The larger the starting image is in terms of bytes, the more leeway the designer has for resizing the image in order to fill up more space should there be room available.)

Also, please remember that images must not be embedded into the body of the article submitted. Images must be submitted separately to the textual submission.

You may submit images via e-mail, via our FTP server or post a CD containing your images directly to us (please contact us for the mailing address, as this will depend upon the country from which you will be mailing).

Please also send us a head shot of yourself that is in accordance with the requirements stated above so that it can be printed with your article.

Abstracts

An abstract of your article is not required.

Author or contact information

The author's contact information and a head shot of the author are included at the end of every article. Please note the exact information you would like to appear in this section and format it according to the requirements stated above. A short biographical sketch may precede the contact information if you provide us with the necessary information (60 words or less).

Questions?

Magda Wojtkiewicz (Managing Editor)
m.wojtkiewicz@oemus-media.de

roots

international magazine of endodontology

Publisher

Torsten R. Oemus
oemus@oemus-media.de

CEO

Ingolf Döbbecke
doebbecke@oemus-media.de

Members of the Board

Jürgen Isbaner
isbaner@oemus-media.de

Lutz V. Hiller

hiller@oemus-media.de

Managing Editor

Magda Wojtkiewicz
m.wojtkiewicz@oemus-media.de

Executive Producer

Gernot Meyer
meyer@oemus-media.de

Designer

Josephine Ritter
j.ritter@oemus-media.de

Copy Editors

Sabrina Raaff
Hans Motschmann

Published by

Oemus Media AG
Holbeinstraße 29
04229 Leipzig, Germany
Tel.: +49 341 48474-0
Fax: +49 341 48474-290
kontakt@oemus-media.de
www.oemus.com

Printed by

Silber Druck oHG
Am Waldstrauch 1
34266 Niestetal, Germany

Editorial Board

Fernando Goldberg, Argentina
Markus Haapasalo, Canada
Ken Serota, Canada
Clemens Bargholz, Germany
Michael Baumann, Germany
Benjamin Briseno, Germany
Asgeir Sigurdsson, Iceland
Adam Stabholz, Israel
Heike Steffen, Germany
Gary Cheung, Hong Kong
Unni Endal, Norway
Roman Borczyk, Poland
Bartosz Cerkaski, Poland
Esteban Brau, Spain
José Pumarola, Spain
Kishor Gulabivala, United Kingdom
William P. Saunders, United Kingdom
Fred Barnett, USA
L. Stephan Buchanan, USA
Jo Dovgan, USA
Vladimir Gorokhovskiy, USA
James Gutmann, USA
Ben Johnson, USA
Kenneth Koch, USA
Sergio Kuttler, USA
John Nusstein, USA
Ove Peters, USA
Jorge Vera, Mexico



Magda Wojtkiewicz, Managing Editor



Copyright Regulations

_roots international magazine of endodontology is published by Oemus Media AG and will appear in 2013 with one issue every quarter. The magazine and all articles and illustrations therein are protected by copyright. Any utilisation without the prior consent of editor and publisher is inadmissible and liable to prosecution. This applies in particular to duplicate copies, translations, microfilms, and storage and processing in electronic systems.

Reproductions, including extracts, may only be made with the permission of the publisher. Given no statement to the contrary, any submissions to the editorial department are understood to be in agreement with a full or partial publishing of said submission. The editorial department reserves the right to check all submitted articles for formal errors and factual authority, and to make amendments if necessary. No responsibility shall be taken for unsolicited books and manuscripts. Articles bearing symbols other than that of the editorial department, or which are distinguished by the name of the author, represent the opinion of the afore-mentioned, and do not have to comply with the views of Oemus Media AG. Responsibility for such articles shall be borne by the author. Responsibility for advertisements and other specially labeled items shall not be borne by the editorial department. Likewise, no responsibility shall be assumed for information published about associations, companies and commercial markets. All cases of consequential liability arising from inaccurate or faulty representation are excluded. General terms and conditions apply, legal venue is Leipzig, Germany.



New Orleans

American Dental Association
ANNUAL SESSION
OCTOBER 31 - NOVEMBER 3, 2013

ADA American Dental Association®
America's leading advocate for oral health

Make the 2013 ADA Annual Session your first choice

Education

Participate in challenging
CE courses that fit into your
schedule and budget

Exhibition

Research and purchase
dental products and services
at a discount

Connections

Mingle with colleagues
from across the world

Registration is open now.
ADA.org/session



Continuing Education



World Marketplace Exhibition



Networking

PD MTA White

Load your MAP System

PD MTA White

- Optimized particle size
- Avoids bacterial migration
- Excellent marginal sealing capacity
- Stimulates the formation of a dentine layer (pulp capping)
- 2 sachets with 280 mg each



Swiss quality
dental products