

Structure and volume in delayed immediate implantation

Authors_Dr Georg Bach & Christian Müller, Germany

_Introduction

Delayed immediate implantation is a viable alternative to immediate implantation, for which there is no distinct evaluation in the literature, and a "regular" implantation after complete osseous healing of the former extraction area, generally associated with volume loss.

Loss of osseous volume after extraction of a non-conservable tooth may be a limiting factor for later implantation. To avoid this problem, many authors recommend immediate implantation, where an implant is inserted immediately after careful and gentle tooth extraction. In cases where immediate implantation is not wanted or possible, delayed immediate implantation after reconstruction of the former tooth area, which is generally carried out three to four weeks after extraction of the non-conservable tooth, is a viable alternative. If the alveolus is (still) mostly intact after extraction, the precondition for immediate implantation can be optimised with a collagen membrane and cone unit.

The focus of interest is on procedures for preserving osseous volume after extraction—many authors emphasise the value of closing the wound by means of a "punch", which they claim to have considerable advantages with regard to protection against resorption. Undisturbed growth of bone-forming cells in the former tooth socket is promoted by preventing the connective tissue from growing into the alveolus. However, this procedure presents more of a challenge for the surgical skills of the dental surgeon in terms of production and insertion, and it is more demanding for the patient, both surgically and financially.

The insertion of so-called collagen membrane and cone units can simplify closure of the alveolus considerably and avoid removal of the punch at a later time. A second procedure is not required because of the absorbability of the material, since the collagen membrane cone unit does not have to be removed.

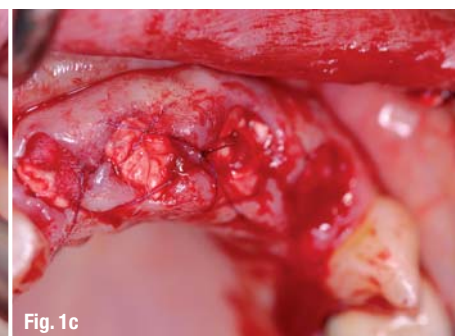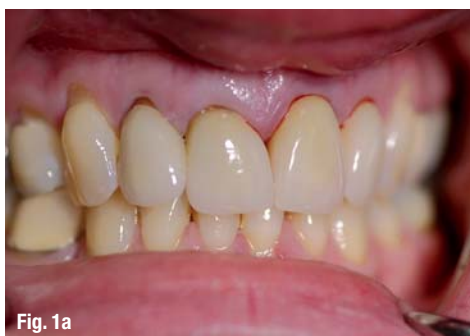_Procedure

The manufacturer recommends the following procedure for the insertion of collagen membrane and cone unit:

Case 1

Due to an extensive dental history, none of the anterior teeth of the maxilla were conservable (Fig. 1a) and had to be removed gently (Fig. 1b). Immediately following extraction of the teeth, collagen and membrane cones were inserted (Fig. 1c) for the purpose of socket preservation and integration of the previously produced (Fig. 1d) interim prosthesis.

The procedure presented in the form of the following three exemplary patient cases also acknowledges this easy surgical procedure.

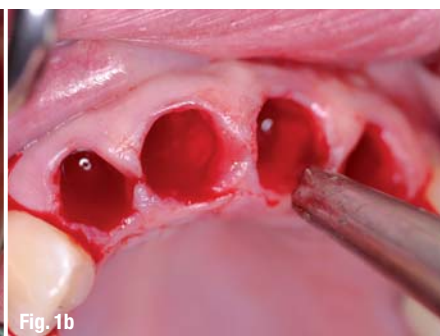

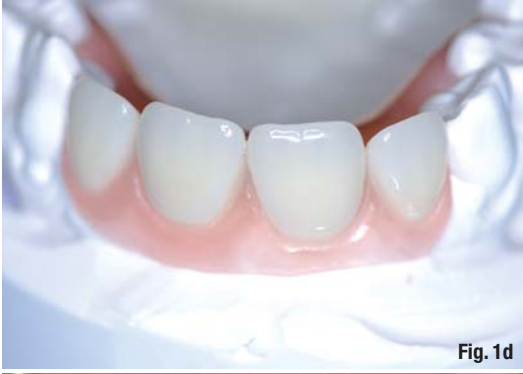


Fig. 1d

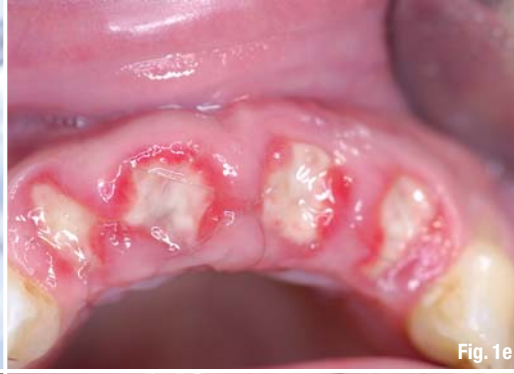

Fig. 1e

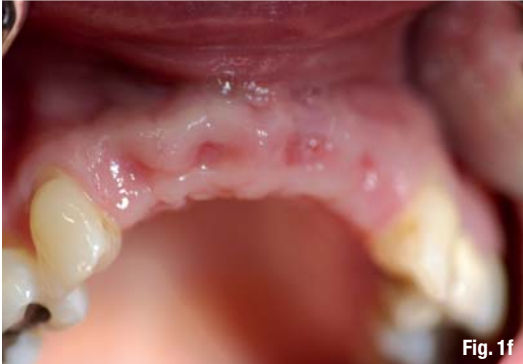

Fig. 1f

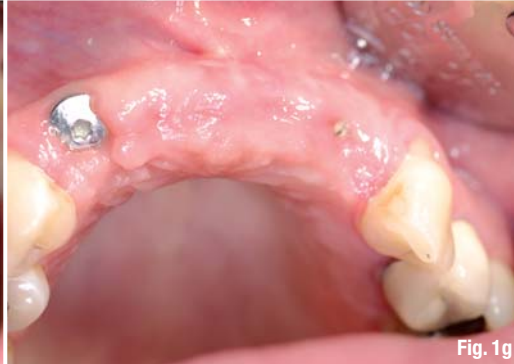

Fig. 1g

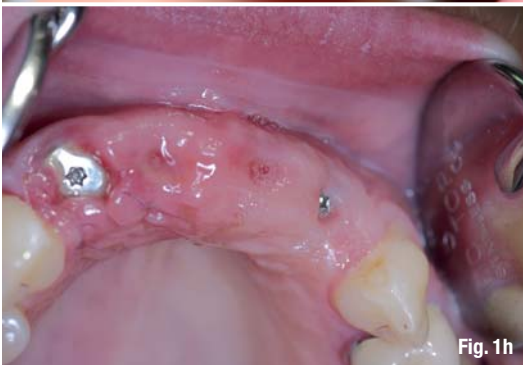

Fig. 1h

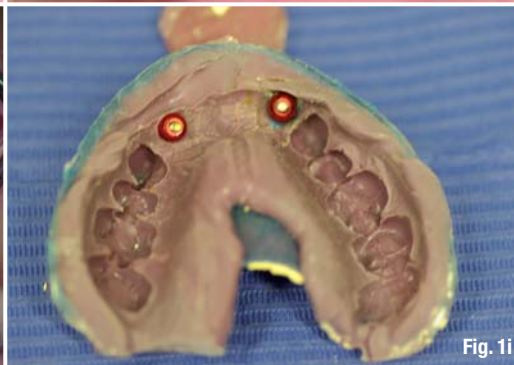

Fig. 1i

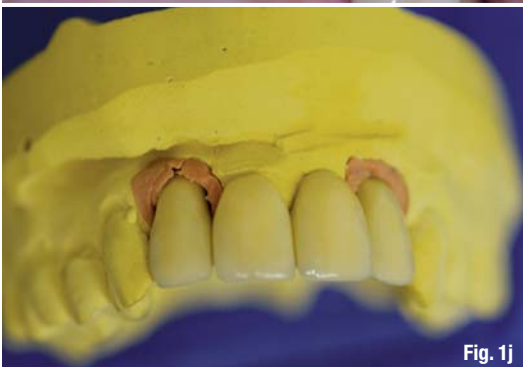


Fig. 1j

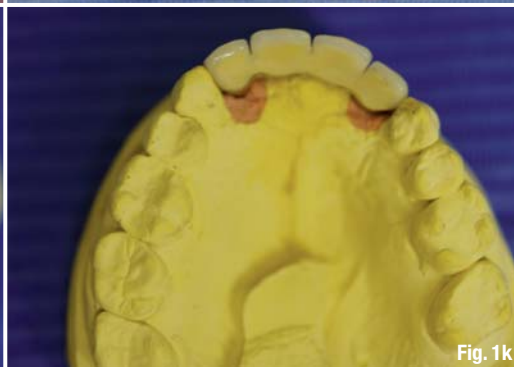

Fig. 1k

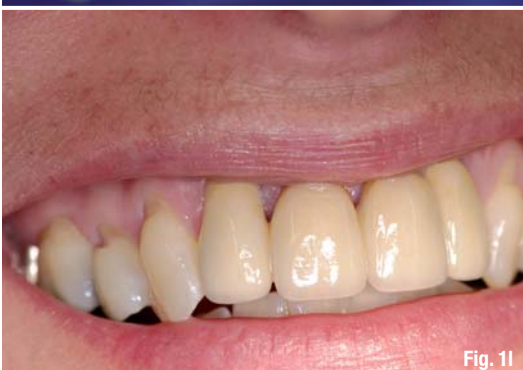

Fig. 1l

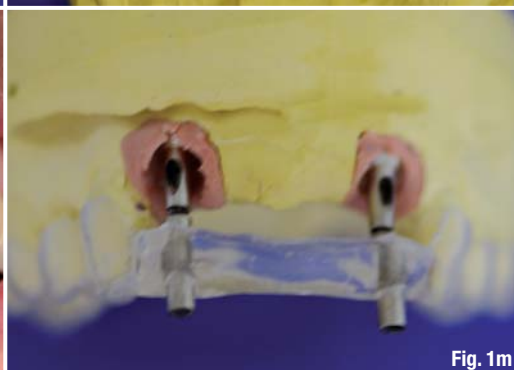

Fig. 1m

Figures 1e and **1f** show the clinical situation one and four weeks after surgery; **Figure 1g** shows the situation after delayed immediate implantation. The intraosseous suture material was removed seven days after implantation (**Fig. 1h**). After completion of the osseointegration phase, the casting was done (**Fig. 1i**), followed by insertion of the abutments using the prepared insertion aid (**Figs. 1j-l**). **Figure 1m** shows the exact conformity between planning (template) and achieved result (abutments).

Case 2

In the right half of the maxilla, the two remaining posterior teeth were fractured and deeply damaged by caries (**Fig. 2a**), thus non-conservable.

The two alveoli remained largely intact (**Fig. 2b**) after gentle removal of the roots, and a customised collagen membrane and cone unit was inserted (**Fig. 2c**).

The suture material was removed one week after surgery (**Fig. 2d**).

After four weeks, the bone bed showed no irritation and a primary reconstruction to a large extent.

We were able to insert two implants after this short waiting period.

Figure 2e shows the condition after implant bed drilling; **Figure 2f** shows the two inserted implants. Please also see the corresponding dental panoramic X-ray (**Fig. 2g**).

Upon completion of the osseointegration period, the implants showed no irritation (**Fig. 2h**), so that the impression could be taken with a customised spoon (**Fig. 2i**) and the dental lab work (**Figs. 2j & k**) was executed.

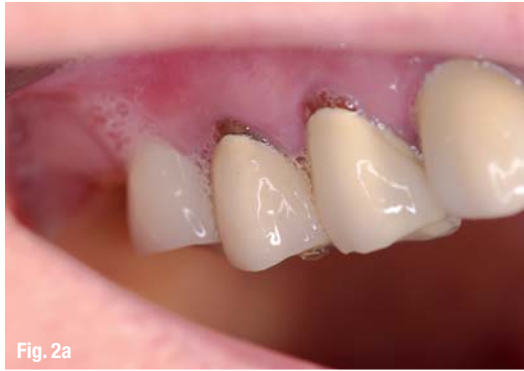

Fig. 2a

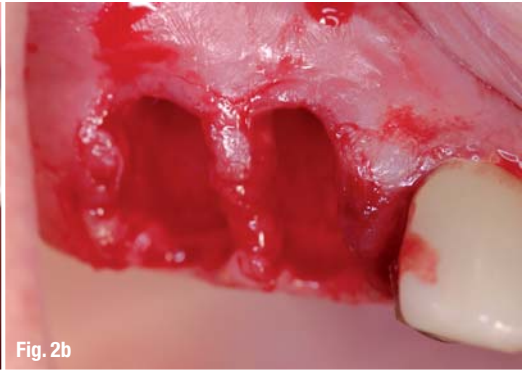

Fig. 2b

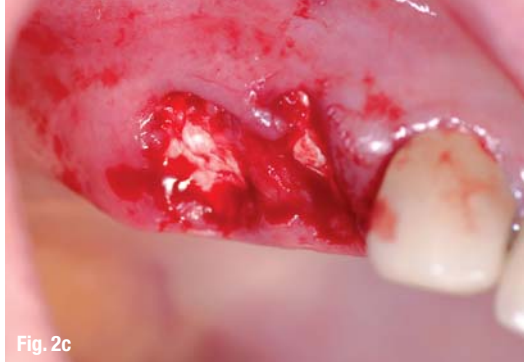

Fig. 2c

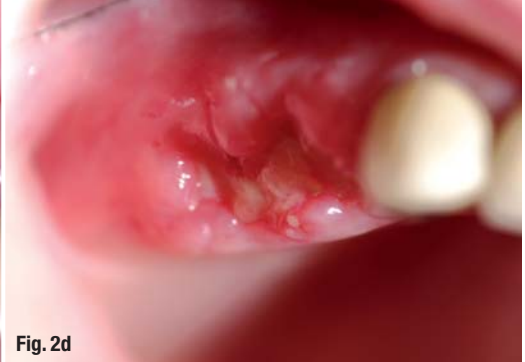

Fig. 2d

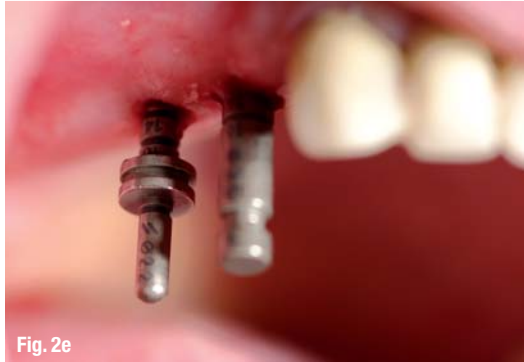

Fig. 2e

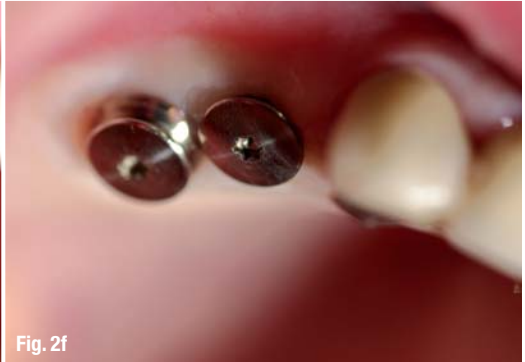

Fig. 2f

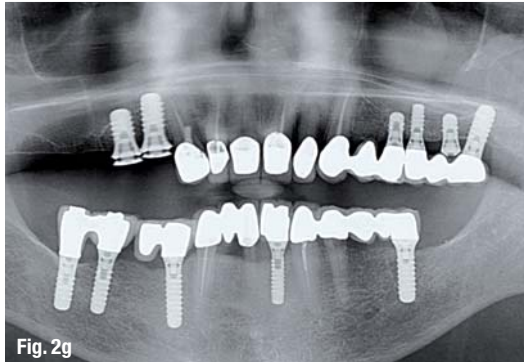


Fig. 2g

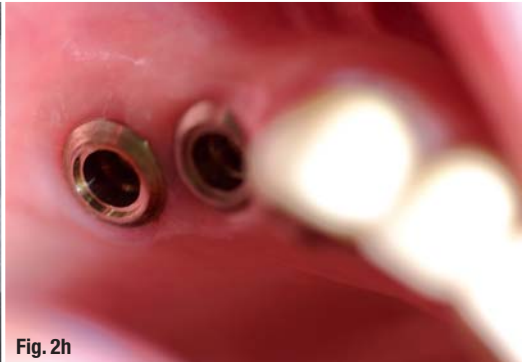


Fig. 2h

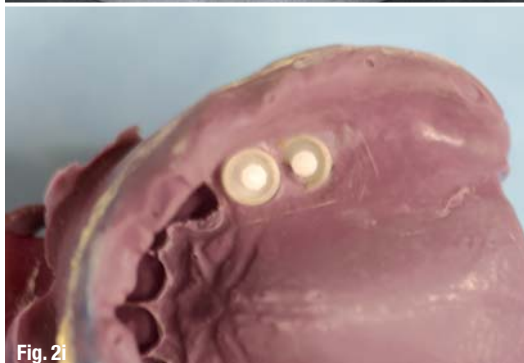

Fig. 2i

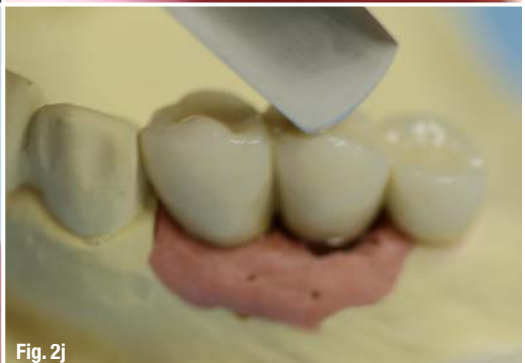

Fig. 2j

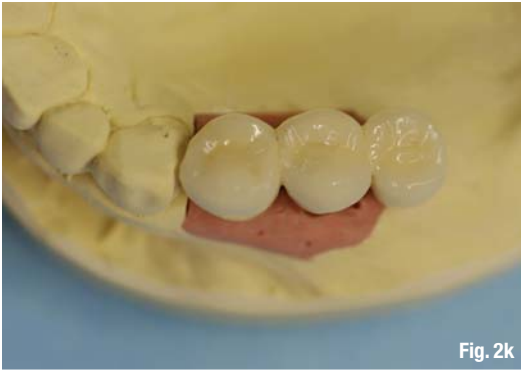

Fig. 2k

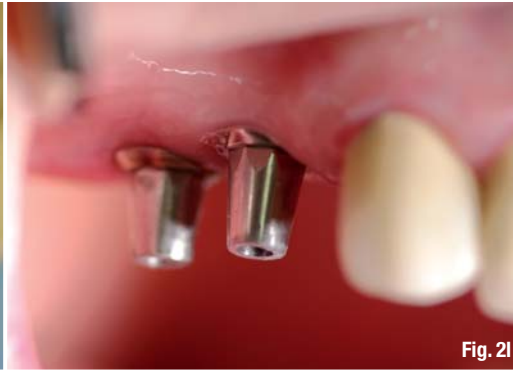

Fig. 2l

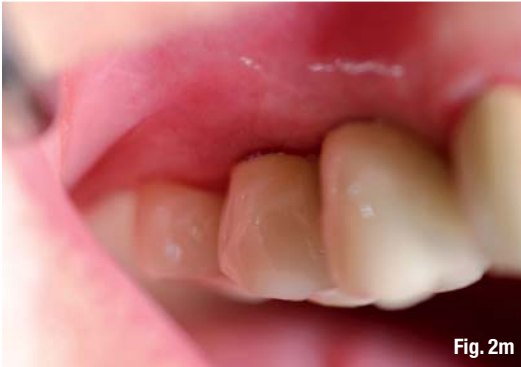

Fig. 2m

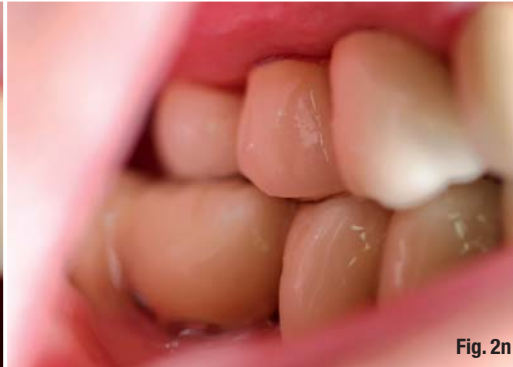

Fig. 2n

Figure 2l shows the inserted abutments, and **Figure 2m** shows the integrated product in the patient's mouth. **Figure 2n** shows the corresponding sagittal view.

1. Preparation for a tight closure

After gentle and non-traumatic extraction of the non-conservable tooth, the marginal gingiva is minimally detached to the alveolar process so that the free membrane side of the collagen membrane and cone unit can be inserted.

2. Customising collagen membrane and cone unit

Moistening is to be avoided because this would make it more difficult to achieve a good fit to the alveolus. Rather, the collagen cone is fitted to the alveolus with the scalpel, and the membrane is configured with small scissors to facilitate insertion under the marginal edges, while at the same time achieving an ideal defect-congruent coverage.

To achieve this, the dimensions of the membrane should be approximately 1–2 mm wider than the diameter of the alveolus.

3. Insertion of collagen membrane and cone unit

Using dry, anatomical, wide tweezers, the collagen membrane and cone units are inserted into the alveolus and then pushed in deep with a moist swab. The membrane part should be seated exactly at the level of the marginal gingiva. Now the free and slightly oversized part of the membrane is pushed carefully under the edges of the marginal gingiva.

4. Protective measures

A back-and-forth suture with a non-absorbable suture material will secure the position of the collagen membrane and cone unit in the alveolus and also adapt the free gingiva edges on the membrane.

_Case presentations

The following three patient cases serve to illustrate and ultimately evaluate the procedure of a delayed immediate implantation using an absorbable collagen membrane and cone unit.

Case 1: Four non-conservable teeth in the anterior maxilla

Due to a trauma of the anterior teeth during adolescence, the patient received endodontic treatment and crowns on the four front teeth, which—after recurring problems—resulted in apicoectomies. The second set of crowns at ten years after the first prosthetic treatment was followed immediately by a second resection due to persistent discomfort. The patient is in her late thirties, and now the four front teeth 12, 11, 21, 22 are no longer conservable. They showed mobility grades of I–II, high circular probing depths and bleeding on probing.

After a removable interim prosthesis 12–22 was produced, the four teeth in the anterior maxilla

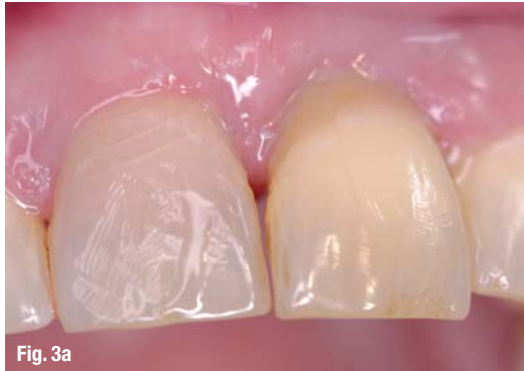

Fig. 3a

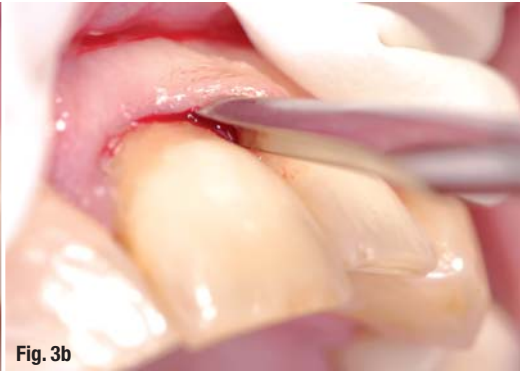

Fig. 3b

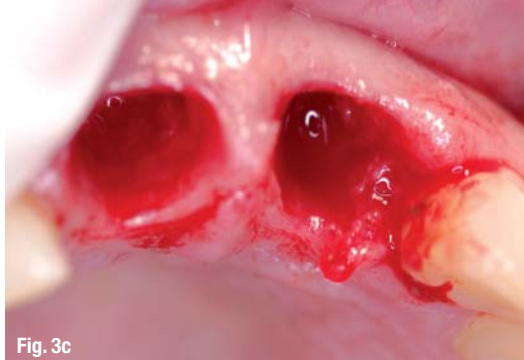

Fig. 3c

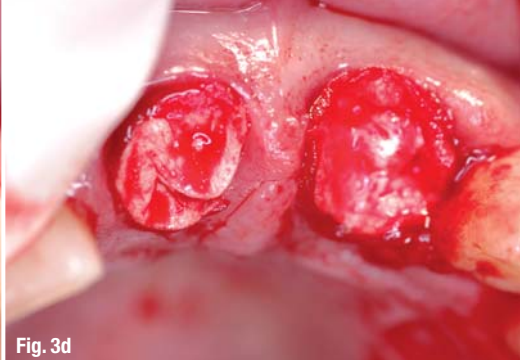


Fig. 3d

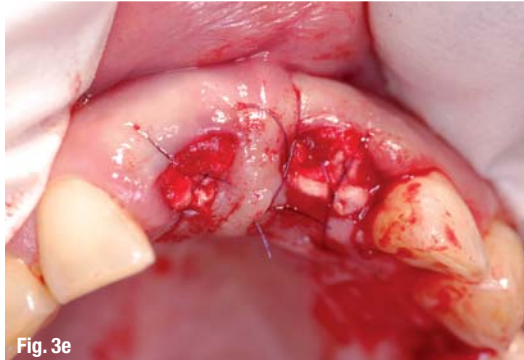

Fig. 3e

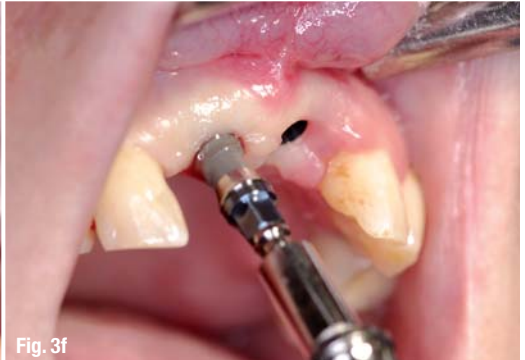

Fig. 3f

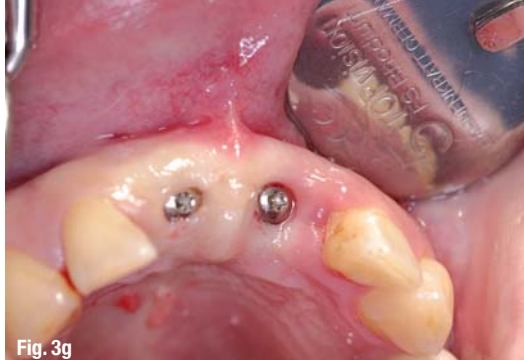

Fig. 3g

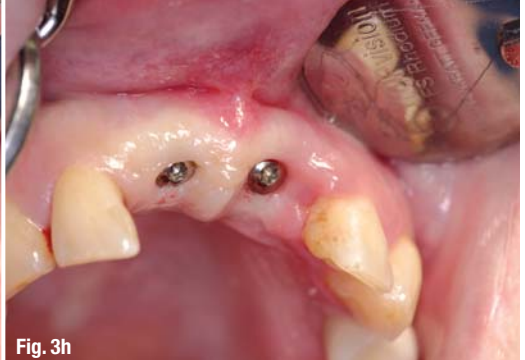

Fig. 3h

Case 3

The teeth were marked by a severe previous periodontitis, and the two upper central incisors were damaged so severely (**Fig. 3a**) that they were considered non-conservable. After minimally invasive removal of the two upper central incisors (**Fig. 3b**), the alveoli of the incisors were found to be intact (**Fig. 3c**) so that, for the purpose of socket preservation, collagen cone and membrane units were inserted (**Fig. 3d**) and fixated (**Fig. 3e**). Two implants (**Fig. 3f**) were inserted after primary healing of the soft tissue. **Figure 3g** shows the immediate postoperative status; **Figure 3h** shows the status after one week. The two implants were fitted with crowns upon completion of further eight weeks of healing time. **Figure 3i** shows the clinical findings after six months within the scope of a recall appointment.

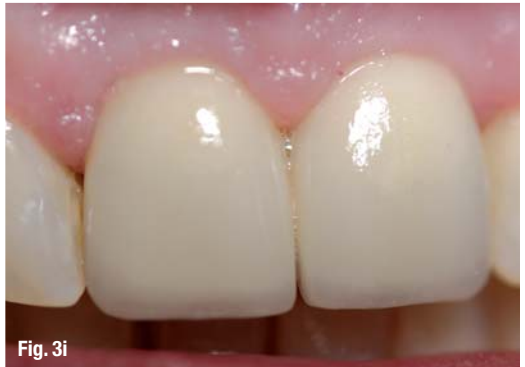

Fig. 3i

THE BUSINESS OF DENTISTRY



**INTERNATIONAL DENTAL
EXHIBITION AND MEETING
APRIL 4 - 6, 2014**

Suntec Singapore International Convention and Exhibition Centre

The Gateway to the Asia Pacific's Dental Markets

IDEM Singapore is a highly targeted trade exhibition and conference that offers exhibitors unrivalled prospects to meet and do business with the dental fraternity in the Asia Pacific region.

With a powerful combination of an extensive international trade exhibition and a world-class scientific conference, IDEM Singapore has been a cornerstone event in the dental community calendar since 2000.

Capitalize on this unique opportunity and participate in this "must attend" event for every professional who is in the business of dentistry.

Endorsed By



Supported By



Held In



In Cooperation With



Co-organizer



International

Ms. Stephanie Sim

T: +65 6500 6723

F: +65 6296 2771

E: s.sim@koelnmesse.com.sg

were extracted gently and the periradicular granulation tissue was also removed as non-traumatically as possible. The wound was closed with four collagen membranes and cone units; they were fitted to the alveolus by resizing the collagen part. The membrane part facing the oral cavity was adapted to the edges of the wound to enable a tight closure with suture material. Four weeks after extraction of the teeth, the former tooth area 12–22 was non-irritated with good remaining structure and volume. ITI implants were inserted in areas 12–22 which were fitted with a fixed bridge after twelve weeks of healing.

Case 2: Free-end situation in the right half of the maxilla

The free-end situation in the right half of the maxilla that occurred 31 years ago had been fitted with a disto-cantilever bridge 16-15-14 BM-KM-KM. At a later time, both of the two premolars (abutment teeth) received endodontic treatment and a root filling. Both teeth fractured so unfavourably that they were non-conservable. The patient requested "the same treatment, but with implants instead of teeth".

To prevent further fractures of the teeth that had fractured on the subgingival level, the remaining two root portions were extracted gently and carefully. Two collagen-cone units were customised with a scalpel (collagen part) and scissors (membrane) in such a way that they were flush with and filled the former alveolus in addition to providing a finish. The final closure was achieved by way of intraosseous sutures. A delayed immediate implantation was also carried out after about four weeks; two implants were inserted in areas 14, 15, which were again fitted with a cantilever bridge (16 as a premolar pontic) after several weeks of osseointegration.

Case 3: Replacement of periodontally severely damaged teeth 11, 21

The patient in her mid-thirties had already lost several teeth in the lateral dental area of the maxilla. The fact that she is a heavy smoker was certainly a considerable co-factor in this unpleasant situation. A trauma of the front teeth (a fall at home) that had occurred many years ago had required splinting of the two upper central incisors which now, only ten years after the procedure, showed a high degree of mobility. The patient also complained of pain when biting.

After the production of a clip-free interim partial prosthesis, the two upper central incisors were

extracted, taking care to avoid any traumatisation. A collagen membrane cone unit was also used for treating both of the two alveoli. Since the patient was not prepared to stop smoking, maintaining structure and volume was just as important as achieving a fast and tight closure by using the collagen membrane and cone unit. After four weeks of primary healing time, two implants were inserted in areas 11, 21, which then received two crowns as a supra-construction after eight weeks.

_Evaluation

The procedure presented here is definitely not a substitute for a proven treatment scheme, but it can serve to simplify it. If the alveolus is largely intact, which must be defined as the precondition for executing the treatment steps described here, a GBR procedure can be performed quickly and without any further trauma to the tissue. The goal is to conserve as much volume of the former tooth socket as possible, thus creating favourable preconditions for a delayed immediate implantation. The procedure has obvious limitations in cases where the former tooth socket has been largely destroyed (due to a complicated extraction or previous procedures resulting in a loss of most of the buccal bone lamella), where the non-conservable tooth shows a profound infection, and in situations where the patient does not want the use of materials of animal origin.

Information regarding the employed collagen product: Absorbable collagen membrane-cone –PARASORB-Sombrero®—Absorbable local hemostatic agent with membrane for guided bone regeneration of equine origin. Manufacturer: RESORBA (Germany).

The authors hereby confirm that there is no conflict of interest.

_contact



Dr Georg Bach

Oral surgery specialist
Rathausgasse 36
79098 Freiburg/Breisgau, Germany

doc.bach@t-online.de

Christian Müller

Master Dental Technician
Christian Müller Dental-Technik
Carl-Kistner-Straße 21
79115 Freiburg/Breisgau, Germany

Under the Patronage of
H. H. Sheikh Hamdan Bin Rashid Al Maktoum
Deputy Ruler of Dubai, Minister of Finance
President of the Dubai Health Authority

تحت رعاية
سمو الشيخ حمدان بن راشد آل مكتوم
نائب حاكم دبي، وزير المالية
رئيس هيئة الصحة بدبي

مؤتمر الإمارات الدولي لطب الأسنان ومعرض طب الأسنان العربي UAE INTERNATIONAL DENTAL CONFERENCE & ARAB DENTAL EXHIBITION

إيكد AEEEDC DUBAI

Delivering Science & Technology

4 - 6 February, 2014

مركز دبي الدولي للمؤتمرات والمعارض
Dubai International Convention & Exhibition Centre

www.aeedc.com

Organised by



In Cooperation with



Strategic Partner



Supported by



INDEX® Conferences & Exhibitions Organisation Est.

Dubai Healthcare City, Ibn Sina Medical Complex #27, Block B, Office 203 | P.O. Box: 13636, Dubai, United Arab Emirates
Tel: +971 4 3624717, Fax: +971 4 3624718 | E-mail: info@aeedc.com, Website: www.index.ae