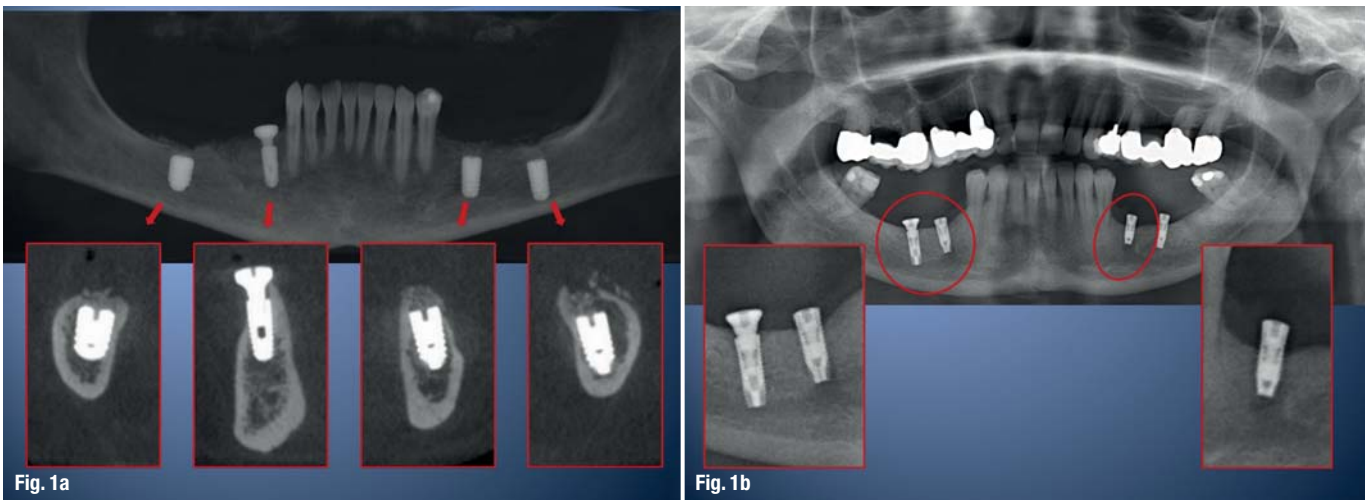


# Safe interdisciplinary navigation

**Authors** Dr Frank Schaefer, Dr Dagmar Schaefer, Dr Mike C. Zäuner & Master Dental Technician Jürgen Sieger



**Fig. 1** Current clinical cases as examples for inadequate 3-D diagnostics and manual placement:  
**a)** Implants in the third quadrant and the region of tooth 47 are impacted completely; those in the regions of teeth 37 and 47 have penetrated the mandibular nerve canal. These image sections show orthogonal alveolar ridge sections through the centres of the implants.  
**b)** Implants in the regions of teeth 35 and 45 have been fully inserted into the mental foramen. The mandibular nerve has a lesion in region 46.

## Introduction

Every day we hear about new curative procedures and their successful application in therapy. The new media broadcast information about medical performances worldwide instantly to wide sections of the population. This environment places greater demands on us, the operators, to meet our patients' increasing expectations for high quality.

It is increasingly less feasible for a "universal genius" to perform complex dental medical therapy alone—consistent interdisciplinary cooperation has become essential. Diagnostics and therapy strategies are necessary and increasingly extensive prerequisites which must be carried out prior to the actual manual dental procedures. Advance planning of therapeutic measures as well as the continuous use of treatment procedures and working instructions with regard to a quality management system form the basis for successful complex oral rehabilitations.

Three-dimensional imaging procedures, upon which dental diagnostics and implant navigation are based, are an important component. Navigation pro-

cedures are considered established methods in implantology. Although they have been in use for almost 20 years, colleagues continue to disagree about them vehemently even today. Comments range from "no need" and "won't work anyway" to "I cannot do without them".

For 3-D diagnostics and implant planning, meeting the requirements by processing and evaluating 3-D radiographic data is essential. In dentistry, cone-beam computed tomography is increasingly used as the source for 3-D radiological image data.

In its guidelines 2005: Cone-beam computed tomography (CBCT)—S1—Recommendation and 2012: Indications for implantological 3-D radiographic diagnostics and navigation-guided implantology—S2k guideline, DGZMK (German Society of Dental, Oral and Craniomandibular Sciences) debates this topic fundamentally. Not only are the technical principles, prerequisites and indications summarised and commented on, but they also discuss the currently feasible results when using navigation-guided implantation. The few *in vivo* data available show that deviations of 2.4 mm in 2005 at the implant tip appear to

have deteriorated to 4.7 mm in the 2012 S2K guideline. This also applies to deviations in the implant axes which have deteriorated from 4 degrees (2005) to 9.8 degrees (2012). In comparison, the deviations in the position of the implant tips decreased in the *in vitro* studies cited (2005: 6 mm; 2012: 2.5 mm), as did the deviations in the implant axes (2005: 11 degrees; 2012: 7.9 degrees).

These data show that all current types of 3-D navigation surgery are considerably better than manual implant placement without 3-D diagnostics but do not represent a reliable basis for an exactly planned procedure as demanded by the increased expectations placed on modern forms of medical therapy (Figs. 1a & b).

There is a multitude of causes of these deviations: Firstly, as described in detail in these publications, only a minimal amount of *in vivo* and *in vitro* data is available. Secondly, there are numerous options for errors due to working stages not always being carried out consistently and co-ordinately. It is even more important that all those involved follow standardised procedures: The prosthodontist, surgeon, dental

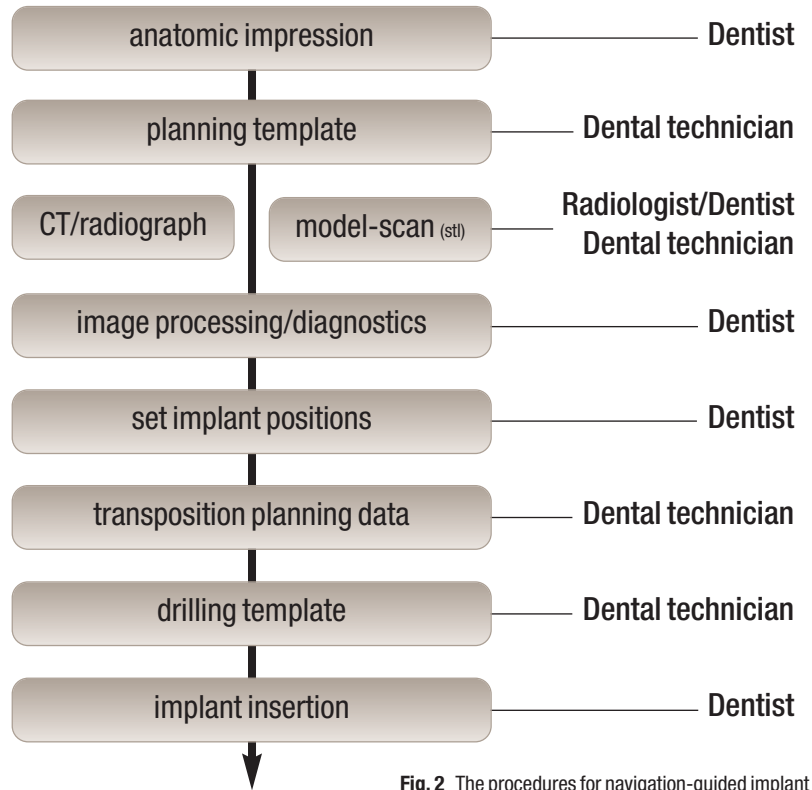


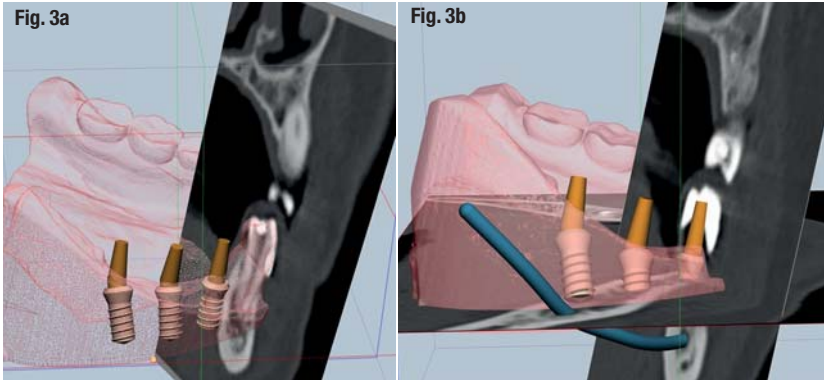
Fig. 2\_The procedures for navigation-guided implant placement using a template.

AD

become an author  
for "implants"

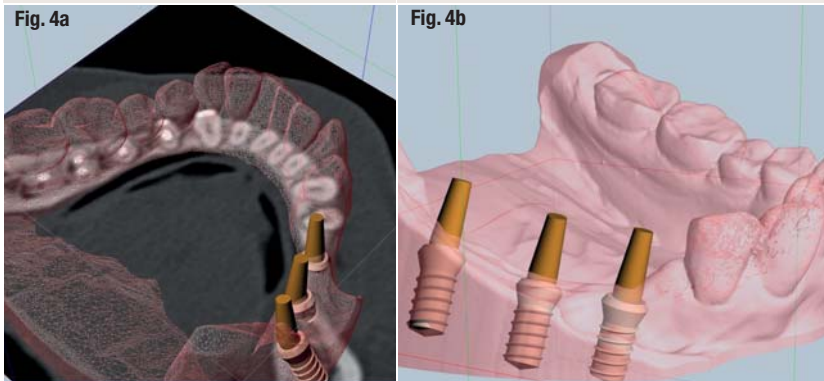


Please contact Claudia Jahn  
✉ c.jahn@oemus-media.de



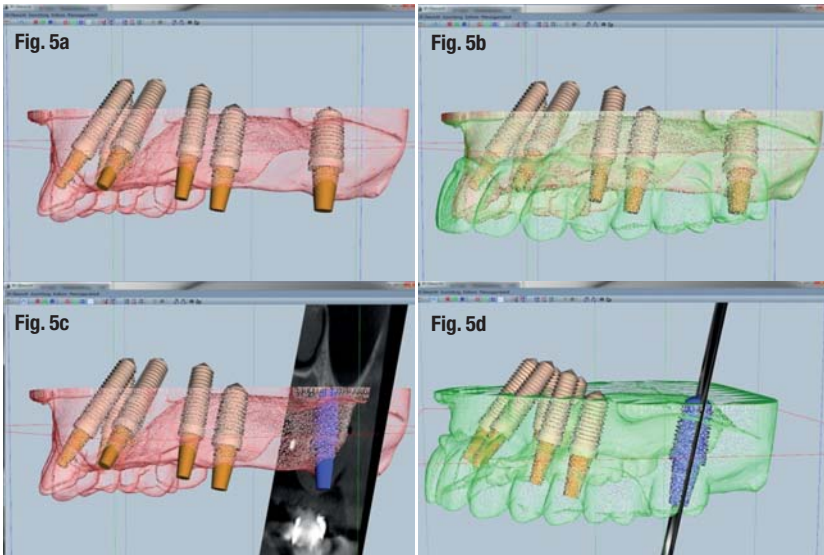
▲ *Stl-data (mesh) in connection with picture of alveolar ridge cut and plannes implants with abutments.*

▲ *Stl-data (rendered) in connection with picture of alveolar ridge cut, z-level-picture, planned implants including abutments an rd reconstructed channel of N. mandibularis.*



▲ *Model mesh with z-level-cut.*

▲ *Rendered model with virtual (inside X-ray-date-file) planned implants.*



**Figs. 3a–b & 4a–b** A selection of the options for merging the optical scan of the model with 3-D radiological planning data.

**Figs. 5a–d** Merging the optical scan of the model (red) with an aesthetic set-up (green) using 3-D radiological planning data.

technician, radiologist, where relevant and, of course, the patient. The CTV system provides conveniently for this type of cooperation in planning and carrying out treatment, including the documentation of the responsibilities, concise treatment counselling with the patient and, last but not least, success evaluation.

### Error analysis

Errors during 3-D-based navigation-guided implant placement may have a multitude of causes. As

in all error analyses, one must differentiate between coincidental and systematic errors. It can be seen from the principal procedure for template-guided navigated implantation (Fig. 2) and from the number of its sub-stages and different persons involved that errors can—and do—occur in this working process. When analysing errors, it must be kept in mind that navigated implant surgery involves planning and operating within the range of millimetres or even below. In addition, errors during the sub-stages may have grave consequences for the ensuing stages. It is therefore advisable to analyse precisely and develop procedures for avoiding these errors.

Errors with the longest-lasting consequences have turned out to occur during impression-taking of the jaw planned for implant placement, when taking the 3-D radiograph as well as when retransferring the planned virtual implant position to the model or surgical navigation template.

The quality of the 3-D radiographic dataset is dependent on the image-taking procedure selected, be it CT, CBCT or truncated CBCT. Also, regardless of the machine used, all radiographs are subject to the laws of optics and exhibit distortion, interference and diffraction phenomena. Apart from that, the image may be blurred if the patient moves while it is taken. The actual pixel size in the image sensor of the unit also has an effect, as does the algorithm used for reconstructing the image in the X-ray machine. Last but not least, correct setting of the parameters and positioning the patient properly in the machine are also decisive for the quality. Assuming that the impression of the jaw was taken correctly and the planning template was fabricated properly, incorrect positioning of the template in the patient's mouth during image-taking also leads to far-reaching planning and transfer errors. Errors during and due to 3-D image-taking are always coincidental and therefore irreparable – which rules out compensating for them with diagnostics and planning.

Once the radiograph has been taken with an X-ray machine, which is subject to quality management based on the (German) radiation act, during the following image-processing, often too little attention is paid to retaining the information included in the primary image data. These processes are often not adequately certified and mostly do not comply with the radiation act. In addition, a loss of detail/structural information is thoughtlessly taken into account.

The difference between the patient's position when the radiograph was taken and the actual model of the jaw is especially crucial for retransferring the virtual implant positions to the model of the jaw. Retransferring with the various compensation mecha-

nisms (e.g. CeHa implant [X1;X2]™, coDiagnostiX [gonyX]™ etc.) may also be a considerable source of error for the transfer process. Intraoperative errors may also occur: an incorrectly placed surgical navigation template will certainly lead—in case of specific navigated implant placement—to malpositioning of the implants, thus possibly resulting in inadvertent, unplanned injury to the adjacent structures. Malpositioning of implants may also occur if the “half-guide” (only the pilot drilling is navigated) procedure is employed. As far as this is concerned, “full-guide” procedures appear safer but may be limited in their applicability. This excerpt of errors is a possible explanation for the relatively high inaccuracy of procedures used to date as documented in the above-mentioned DGZMK guidelines.

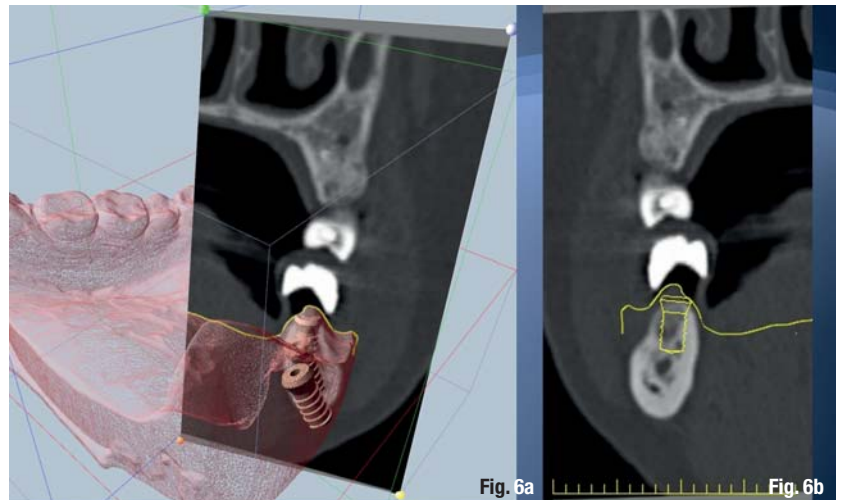
### Further development

The CTV system follows different paths, based on comprehensive theoretical and clinical evaluation, in order to attain interdisciplinary cooperation and reliable planning with only minimal toleration of errors. Use of the CTV system allows coincidental and therefore unforeseeable errors to be identified and, wherever feasible, systematic errors to be compensated for.

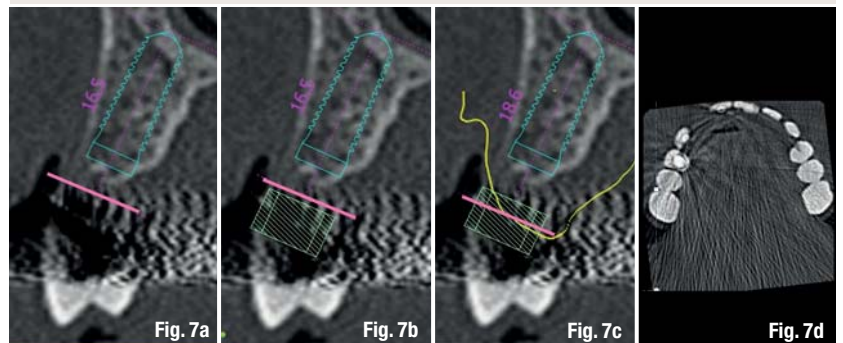
The quasi-analogue image processor developed for the CTV system is relatively tolerant where quality and alignment of the primary radiographic dataset are concerned. It permits any image sections in 3-D cubes to be created with no limitations to angles, distances and locations. These images reproduce impressive details and structures as do plain images, calculated panoramic tomographs and calculated teleradiographs. The operator is provided with the usual “analogue” image quality.

But the same applies here, too: The quality of the primary dataset and the density of the information it contains is decisive for the 3-D diagnostic and planning options. In addition, the CTV system merges data from an optical scan of the planning template, model and/or wax-up/aesthetic set-up and/or drilling template with the 3-D radiographic planning dataset (Figs. 3-5). This fully automatic matching process discovers and compensates for coincidental errors in images (Figs. 6 & 7).

Regarding bone availability and prosthesis positioning, the planning positions can thus be determined more comprehensively and exactly. When using this method, the emergence profile can already be estimated accurately during prosthetic (pre)planning. The surgical navigation template can also be fabricated based on STL datasets. When this template is then matched with image planning, the (virtual)



▲ Yellow line: automatically reconstructed line of gingiva on basis of model scan.

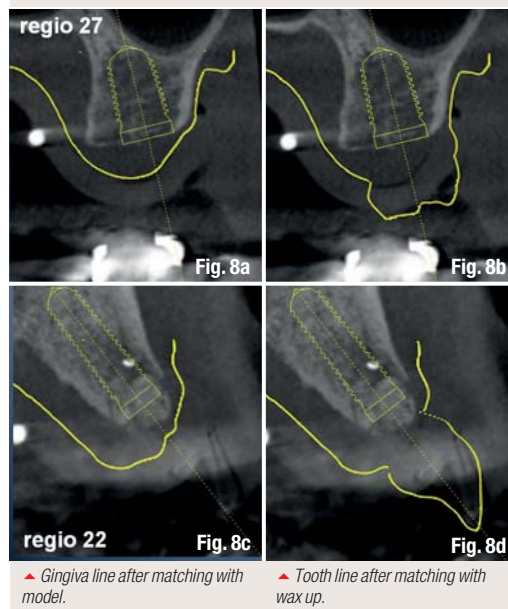


▲ Determined height of gingiva in X-ray planning (pink).

▲ Out of implant planning resulting position of the drill.

▲ Yellow line: real line of gingiva on basis of scanned model—sleeve below gingiva!

▲ Source of error: artefacts in CT-scan due to precious metal containing restoration (z-level-cut).



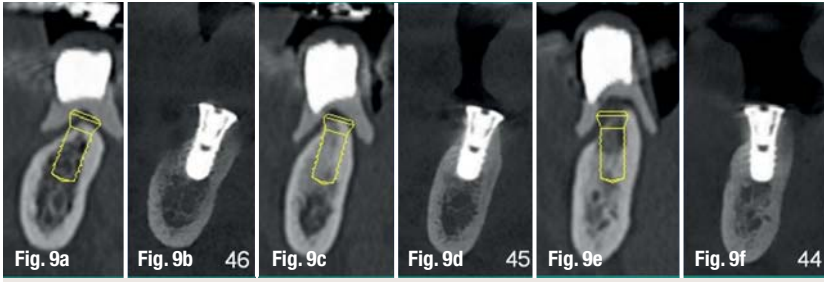
▲ Gingiva line after matching with model.

▲ Tooth line after matching with wax up.

**Figs. 6a–b & 7a–d** An example of error recognition – checking and determining the gingival contours on the planning radiographs using the scan of the model.

**Figs. 8a–d** The gingiva or tooth structures are recognised automatically when the radiological planning data are matched to the model of the jaw or wax-up.

planning positions can be checked for correct alignment with the sleeve positions in the template prior to placement. Starting with optical and radiological digital data, the entire planning and fabrication process is digitized from one single base without further interim stages, which eliminates inaccuracies

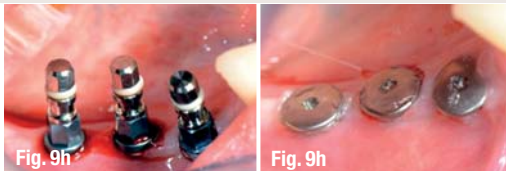


▲ Review of success: left – planning target, right – result.

**Figs. 9a-h** Clinical success—The condition after transgingival navigated implant placement (2012).

**Fig. 10** Matching to check for success—left: The 3-D radiological planning (blue implant) was made congruent with the model (red), wax-up (green) and 3-D image post-operatively (eclipsed by the virtual implant); right: Matching planning, postoperative radiograph with the gingival contours from the model of the jaw (2012).

**Fig. 11** Documentation of the responsibilities for the total process—below: RFID Reader, model base with RFID chip, customised Ident Keys for the RFID Reader.



▲ Clinical status after insertion implants—screwing parts (Straumann).  
▲ Clinical status immediatly after operation.

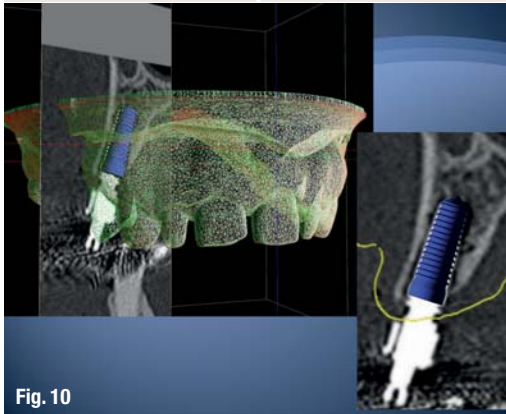


Fig. 10

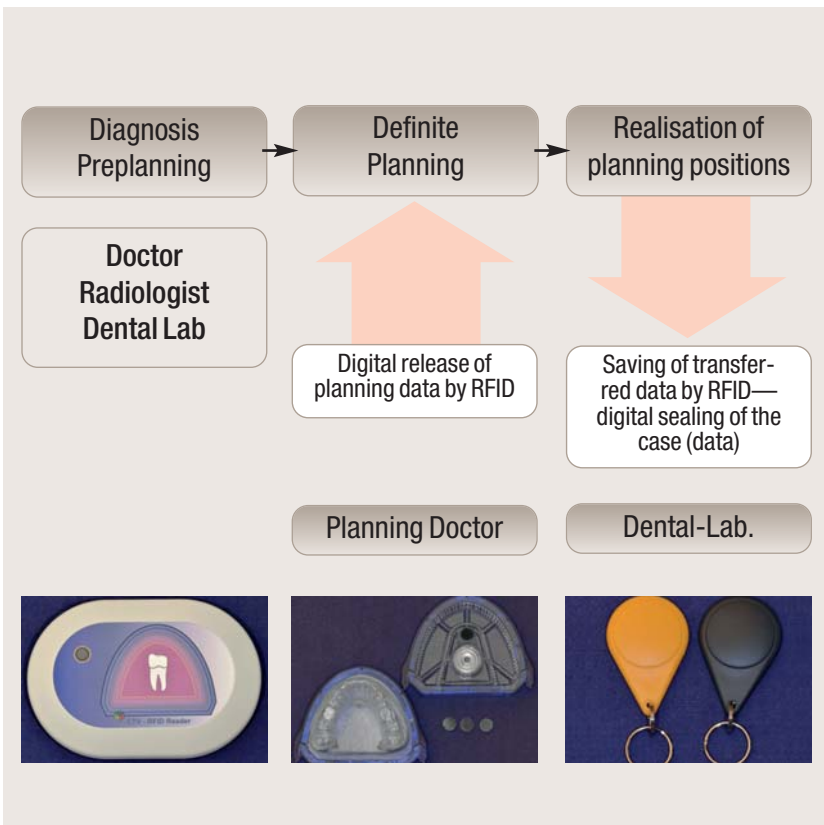
encountered with conventional methods involving transferring virtual positions to the actual model.

The CTV system provides for reliable postoperative examination once the implants have been placed. This means that unerringly precise congruency is achieved between planning dataset and postoperative 3-D radiological dataset for comparing the actual implant positions with the planned positions. It is irrelevant whether the planning and control datasets stem from the same machine (Figs. 8 & 9). This enables the user to check for success at an early stage as well as analyse the cause of any errors which may occur. This should lead to errors being avoided long-term (learning effect).

Of course, the CTV system can generate comprehensive and custom expandable, forensically dependable case documentations at the push of a button. They can be stored as PDF files, printed and/or forwarded. The use of RFID chips integrated into the model of the jaw ensures that the CTV system stores a complete documentation of the responsibilities as part of the total process (Fig. 10).

### Conclusion

The combination of radiological and optical data and simultaneous integration of CAD/CAM processes enables errors to be identified at an early stage and, together with suitable compensation measures, leads to a much better match between planning requirements and outcome. The numerous options for combining images create optimum conditions for interdisciplinary understanding as well as explaining the therapy strategy to the patient in a plausible and understandable manner. The indications of this new technique range far beyond mere implant planning and can be used in-house without having to purchase costly special equipment and transfer units.



_contact	implants
<p><b>Dr Frank Schaefer</b>          Praxis          Haarbergstr. 21          99097 Erfurt, Germany</p> <p>Tel.: 0361 4230713          PraxisSoft@web.de</p>	