

# Retromolar bone grafts prior to implant placement

## Outcomes and complications—Part I

**Authors** Andreas Sakkas, Carsten Winter, Frank Wilde & Alexander Schramm, Germany

### Introduction

The dental rehabilitation of partially or totally edentulous patients with oral implants has become common practice with reliable long-term results.<sup>1</sup> However, unfavourable local conditions of the alveolar ridge due to atrophy, periodontal disease, trauma sequel, malformation or neoplasia may cause insufficient bone volume, which may complicate the therapy of the masticatory function with dental implants.<sup>2</sup> When alveolar ridges lack the appropriate bone volume, additional surgical reconstructive procedures are required.

The use of autologous bone grafts with dental implants was described originally by Brånemark et al. in 1975, and today is a well-accepted procedure in oral and maxillofacial rehabilitation.<sup>3-5</sup> Insertion of an endosseous implant requires sufficient bone volume for complete bone coverage. Physiologically, an ideal bone grafting material should provide osteogenicity, osteoinductivity and osteoconductivity for new bone formation. Despite some recent advances in bone-substi-

tute technology, autogenous bone grafts remain the "gold standard" in reconstructive surgeries because of their osteoinductive, osteoconductive and non-immunogenic properties. Guided bone regeneration (GBR) is an alternative technique to onlay grafting for localised alveolar ridge augmentation prior to dental implant placement.<sup>6,7</sup> The clinical potential of membrane techniques for bone regeneration was recognised by Nyman et al.<sup>8</sup> They demonstrated that membranes act as a physical barrier when applied over bone defects, preventing the ingrowth of competing, non-osteogenic cells into the membrane-protected space.<sup>7,9</sup> Space provision, such as guided tissue regeneration, was shown to be effective in regenerating new bone on atrophied alveolar ridge, either vertically or horizontally, with the use of a membrane. Similar to onlay bone graft, which also serves as a space maintainer, GBR may incur similar complications that pertain to the use of onlay graft. Complications related to GBR may come from membrane exposure, miniscrew exposure and contamination. Exposed membranes or fixation screws often cause local inflammation with decreased bone formation.<sup>10</sup>

**Figs. 1 & 2** Exposure of the recipient site for the graft prior to harvest, measurement of its dimensions and the minimal time elapsed between graft harvest and placement.

**Fig. 3** Preoperative situation.

**Fig. 4** Mean surgical time of five minutes for harvesting.

**Fig. 5** Inferior osteotomy connecting the posterior and anterior vertical cuts.

**Figs. 6 & 7** Fixing of the block grafts after appropriate separation into smaller parts.

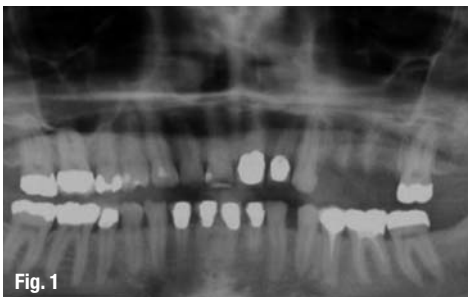


Fig. 1

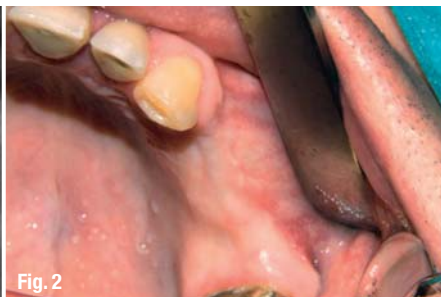

Fig. 2

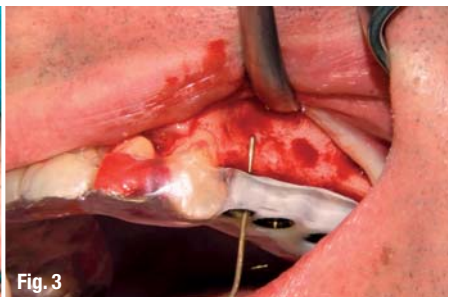

Fig. 3

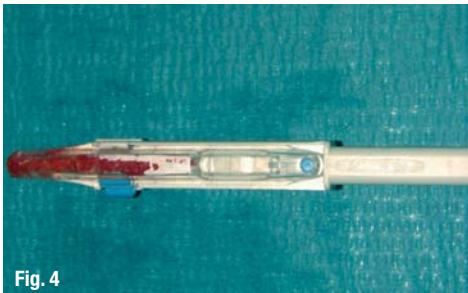


Fig. 4

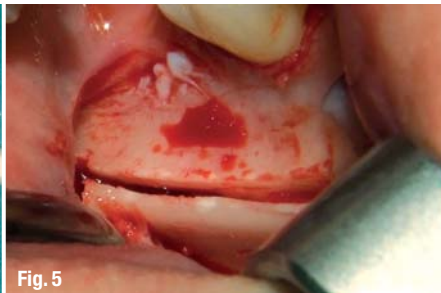


Fig. 5





Fig. 6

# Legacy™ System

100% Compatible with Zimmer® Dental



**Reality Check**  
Zimmer Customers

## Legacy™3 Implant

All-in-One Packaging includes implant, abutment, transfer, cover screw & healing collar €145

## Legacy™ Implant System Advantages:

**Industry-Compatible Internal Hex**

Prosthetic compatibility with Zimmer Dental Screw-Vent®, BioHorizons® & MIS implants

**Surgical Compatibility with Tapered Screw-Vent®**

No need to change surgical protocol or tools

**Three Implant Designs & Packaging Options**

Allows for selection based on price, packaging or thread design

**Legacy1:** €115 includes cover screw, healing collar & plastic carrier

**Legacy2:** €130 includes cover screw, healing collar & temporary abutment/transfer

**Legacy3:** €145 includes cover screw, healing collar & preparable abutment/transfer

**Micro-Threads**

Reduce crestal stress for improved initial stability

**Widest Range of Dimensional Options**

The entire Legacy system includes seven implant diameters (3.2, 3.7, 4.2, 4.7, 5.2, 5.7, 7.0mm) & six implant lengths (6, 8, 10, 11.5, 13, 16mm)



Laboratory Abutment	Straight Snap-On	Straight Contoured	15° Angled Contoured	Gold/Plastic	Zirconia/Ti Abutment	Plastic Temporary Abutment	Ball Attachment	GPS™ Attachment	Angled GPS™ Attachment	Multiple-Unit w/Cap & Transfer	Multiple-Unit w/Cap & Transfer
€60	€75	€75	€75	€90	€90	€30	€68	€90	€90	€75	€90

## Legacy™1

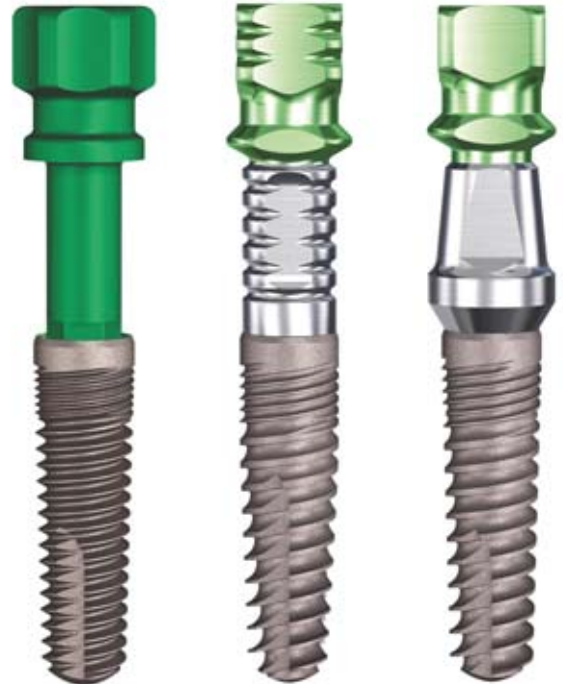Standard "V" Threads  
Matches Screw-Vent®

## Legacy™2

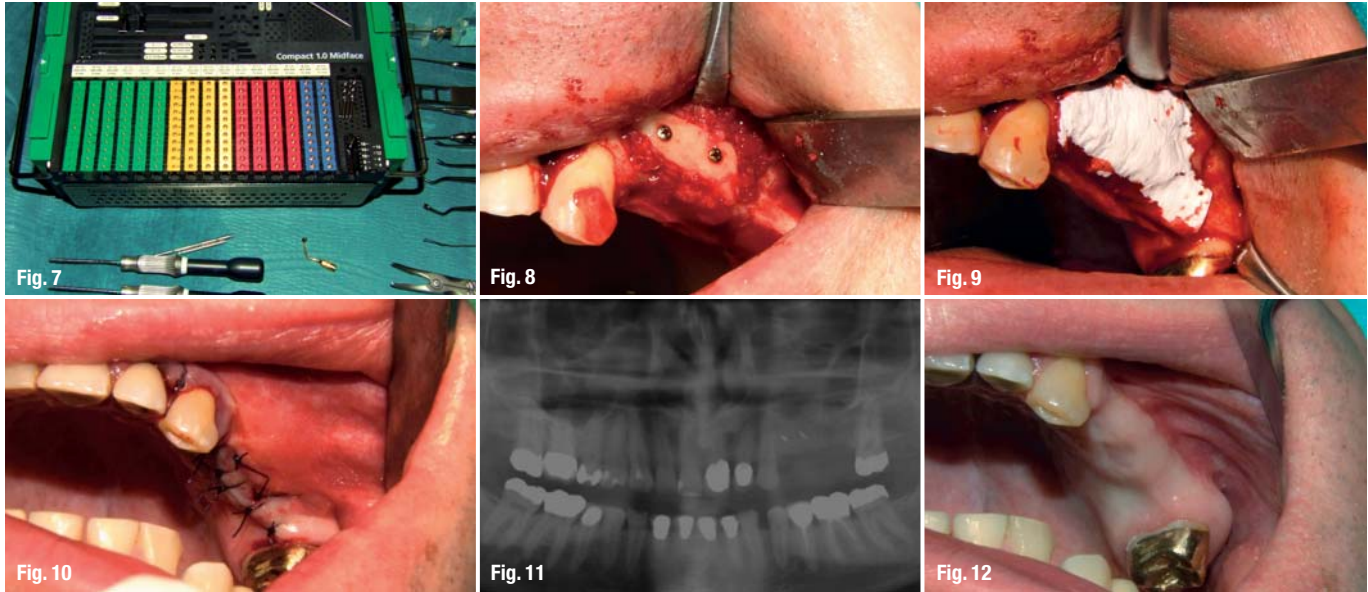
Spiral Threads  
for Increased Stability

## Legacy™3

Buttress Threads  
for Increased Surface







**Figs. 8 & 9** Filling of the small gaps between bone graft and alveolar crest with corticocancellous bone.

**Fig. 10** Periosteal releasing incisions.

**Fig. 11** Orthopantomographic control to evaluate the outcome of the surgical procedure.

**Fig. 12** Crestal incision and subperiosteal dissection of the alveolus, removal of the fixation screws. Implant site preparation with guidance from the laboratory-made splint. Positioning of the implants.

The significance of early membrane exposure on the regenerative outcome has been somewhat controversial in guided tissue regeneration and GBR procedures. Several studies have shown better responses when the membranes remained submerged than when they became exposed during healing.<sup>11,12</sup> However, other studies failed to show such differences.<sup>13,14</sup>

It must be pointed out that patients affected by partial edentulism do not easily accept major surgical procedures that may imply hospitalisation or general anaesthesia. These disadvantages, together with the fact that dental implants do not demand a large amount of bone, lead to the growing use of autogenous block bone grafts from intraoral sources rather than from extraoral.<sup>15-20</sup>

The use of the mandible as a donor site is said to be less invasive, to save surgical and anaesthetic time and to be accomplished in the outpatient operatory.<sup>13,21,22</sup> Harvesting of bone grafts from the retromolar region has been reported several times before.<sup>22-26</sup> In the repair of localised alveolar defects, bone grafts from the retromolar region offer several benefits: a) the proximity of donor and recipient sites that reduces operative and anaesthetic time; b) conventional surgical access; and c) making them ideal for outpatient implant surgery. Minimal discomfort and decreased morbidity are also reported for this type of bone grafting.<sup>27-29</sup> This technique can be combined with impacted third molar extractions.<sup>30</sup>

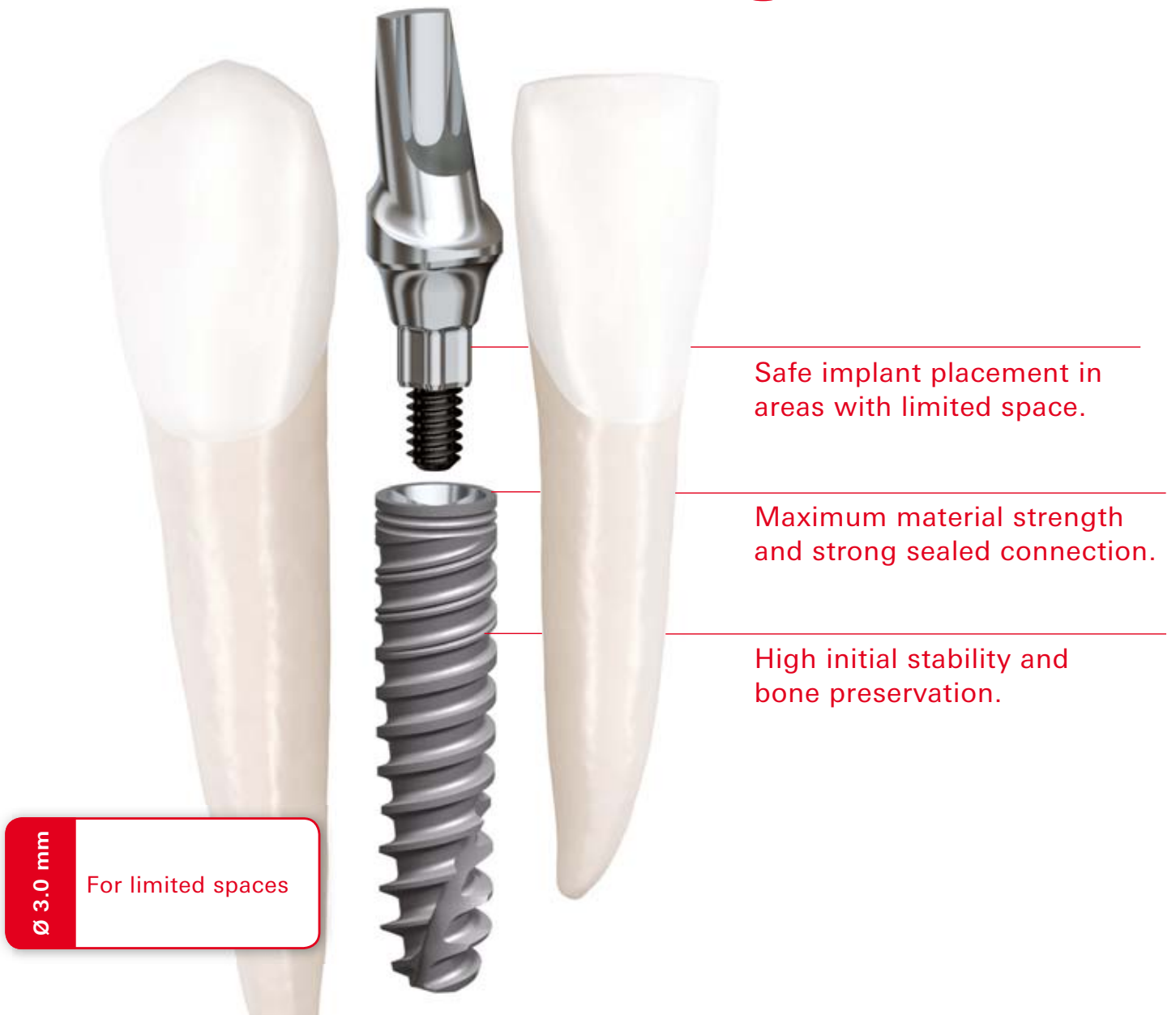The purpose of the present retrospective study was to evaluate the surgical success and to assess the rate of complications that arise from harvesting retromolar bone grafts in a group of partially edentulous patients prior to implant placement. We used a two-stage technique. In the first surgical stage, one or more cortico-

cancellous bone blocks harvested from the retromolar region were fixed with osteosynthesis titanium screws to the recipient site as onlay grafts to achieve a horizontal and/or vertical augmentation of the ridge volume. In the second procedure, three to six months later, the screws were removed and implants were placed. The results regarding bone augmentation, donor and recipient site morbidity, bone graft stability and resorption prior to implant placement were recorded during the postoperative period and healing phase. Complications associated with this procedure mostly involve infection, incision line opening, nerve dysfunction, wound dehiscence, loss of portion of the bone graft, and graft mobilisation (Table 1).<sup>31</sup> A short review of the literature is presented in Table 2.

### Materials and methods

A consecutive retrospective study was conducted on patients who underwent retromolar onlay bone grafting from January 2008 until January 2011. Files of 86 patients (77 males and 9 females) reporting 104 bone graft operations were reviewed. Patients ranged in age from 20 to 58 years (average 37.9 years). From the current study, patients were excluded if their data covered: a) grafting of bone defects caused by tumour resections, osteoradionecrosis and bisphosphonate-associated osteonecrosis, b) grafting of bone defects in syndrome patients with craniofacial involvement and with congenital malformations, such as cleft patients, c) grafting of extraction sockets and intraalveolar defects simultaneously with immediate implant placements and d) augmentations including the application of distraction osteogenesis. Medical history, cause of tooth loss and smoking status at the time of operation were recorded. All patients underwent primary clinical and radiographic examinations and were diagnosed as having an inadequate quantity of bone for implant placement.

# Smaller and stronger.



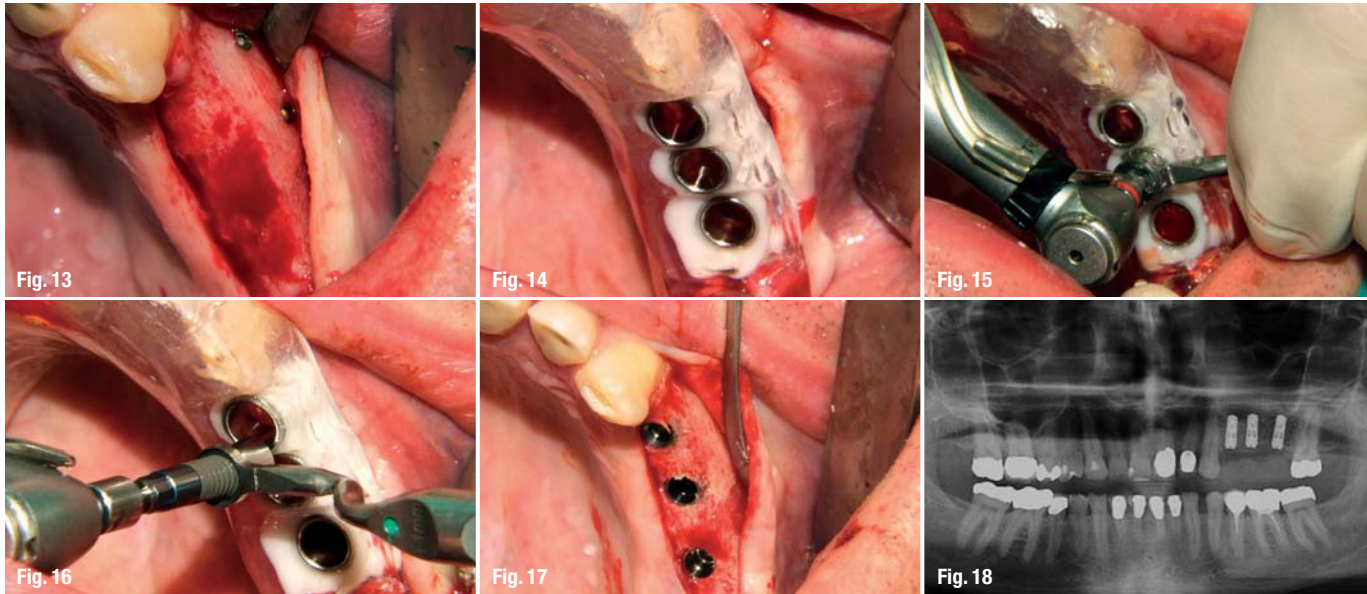
**It's called NobelActive 3.0.** This unique implant is the ideal solution for narrow spaces in the anterior region. The drilling procedure is designed to retain as much bone as possible, while the implant body and thread design condenses bone during insertion enhancing initial stability. The sharp apex and cutting blades enable you to adjust the implant position for optimal

restorative orientation. Together with the strong sealed connection and built-in platform shifting, NobelActive 3.0 allows you to safely produce excellent esthetic results. After 45 years as a dental innovator we have the experience to bring you future-proof and reliable technologies for effective patient treatment. **Their smile, your skill, our solutions.**



Visit [nobelbiocare.com/active3](http://nobelbiocare.com/active3)





**Figs. 13–18** Crestal incision and subperiosteal dissection of the alveolus, removal of the fixation screws. Implant site preparation with guidance from the laboratory-made splint. Positioning of the implants.

Table 3 shows the frequency of causes for the tooth loss. All the patients were informed in advance that bone reconstruction might be necessary prior to implant placement, since the need to augment the alveolar ridge can be evaluated correctly using panoramic radiographs only when there is vertical resorption of the ridge. Conventional radiographic examination provides little or no information about ridge thickness. Because of this, all the patients of the study underwent, except a conventional panoramic radiograph of the jaws, CT scans reformatted with Dentscan software. In disagreement with other authors, we believe that reformatted CT images always provide a precise treatment guide when the decision to graft or not to graft has to be made in critical cases.<sup>32</sup> A total of 104 alveolar segments were treated: 22 procedures involved the maxilla and 82 the mandible. In six of the augmented areas on the maxilla posterior, a Sinus elevation was also performed. Fifteen patients included in the study were treated in separate procedures for augmentation of different alveolar sites. Each augmented site was studied. 67 procedures were carried out under local anaesthesia and 37 under general anaesthesia. All sites were treated in a similar fashion. The number of bone blocks, donor sites and number of implants inserted in each augmented site were also recorded. The choice of donor site, left or right, was determined preoperatively, based on defect morphology and recipient site location. When the augmentation was planned in the posterior mandible, a single surgical field was needed, thus reducing patient discomfort. The recipient site was healed completely prior to graft surgery.

### Surgical protocol

#### *Stage 1 surgery*

The bone harvesting procedure was performed using a standardised surgical technique. The anaesthesia of all patients was carried out with Ultracain™ D-S

(Hoechst Marion Roussel Deutschland, Frankfurt, Germany) containing 1:200,000 epinephrine at the donor and recipient sites. A single shot of 2,2 g amoxicillin and clavulanic acid (Augmentan®, GlaxoSmithKline Consumer Healthcare GmbH & Co. KG) or, if penicillin allergic, 600 mg Clindamycin (Clinda-saar®, MIP Pharma GmbH) as well as 250 mg Prednisolon (Solu-Decortin®, Merck Pharma GmbH) was administered intravenous to patients a few minutes prior to surgery.

The proposed recipient site for the graft was exposed prior to graft harvest in all cases. In this manner, the dimensions and morphology of the bony defect were measured, and minimal time elapsed between graft harvest and placement (Figs. 1 & 2). Figure 3 presents the preoperative situation. The recipient site was prepared and recon toured with the Safescraper (C.G.M. S.p.A., Divisione Medica META, Italy) by pushing the end of the devise toward the bone surface and simultaneously pulling the devise backward. Collection of 2–3 ml of bone was feasible with a mean surgical time of five minutes for harvesting (Fig. 4). The collected bone was preserved in a sterile environment until grafting. To access the ramus area, the concavity formed by the border between the ascending ramus and the external oblique ridge was identified and used as a starting point for the mucosal incision.

The incision was made medially to the external oblique ridge and extended mesially toward the buccal aspect of the second molar. Care was taken to ensure that the incision was not extended too far lingually, preventing damage to structures on the lingual aspect of the mandible. A mucoperiosteal flap was elevated superiorly, exposing the lateral aspect of the ramus. The osteotomy was carried out with an osteotomy kit for Piezosurgery® (Mectron, Deutschland Vertriebs GmbH) and was started anteriorly to the coronoid process at the



# A Real Breakthrough in Implantology.

Roxolid® SLActive® – Setting New Standards, Reducing Invasiveness

With Roxolid® SLActive® Implants we break new ground:

- Eliminating invasive grafting procedures
- Increasing patient acceptance

Our new generation of implants provides you exceptional material strength combined with excellent osseointegration properties for greater confidence.

Now available:

- All diameters
- 4 mm Short Implant Line
- Loxim™ Transfer Piece

Discover more benefits on [www.straumann.com/roxolid](http://www.straumann.com/roxolid)



point were adequate bone thickness developed. A micro reciprocating saw was used to cut through the cortex along the anterior border of the ramus medially to the external oblique ridge. The anterior vertical cut was made in the mandibular body in the molar region with a vertical saw. The length of this cut was dependent on the size requirements of the graft and on the position of the inferior alveolar canal. The posterior vertical cut was made on the lateral aspect of the ramus, perpendicularly to the external oblique osteotomy. The inferior osteotomy connecting the posterior and anterior vertical cuts was made with a straight saw. This was a shallow cut into the ramus to create a line of fracture (Fig. 5). A thin chisel was gently tapped along the entire length of the external oblique osteotomy, and care was taken to parallel the lateral surface of the ramus, so that a fracture would occur at a particular level. This level was modified to predetermine the size of the corticocancellous bone graft. Thus, the splitting of the graft from the ramus was completed. The bone block was lifted carefully to ensure that the inferior alveolar nerve was not trapped within the graft. The donor area was filled with a collagen cotton sponge for local haemostasis.

The block grafts were then fixed with small-diameter titanium osteosynthesis screws (Matrix Midface, Synthes® 2011 NHS Supply Chain) after appropriate separation into smaller parts (Figs. 6 & 7). Corticocancellous bone, collected with the Safescraper, was then used to fill the small gaps between the bone graft and the alveolar crest (Fig. 8). In all cases, a collagen membrane (Bio-Gide, Geistlich Biomaterials, Wolhusen, Switzerland) was cut appropriately and adapted to cover the defect and extended 2 to 3 mm sideways, being laid over the graft in a saddle configuration. It was tucked underneath the palatal or lingual flap to cover the ridge and buccal defect, moistened, and pressed gently to adapt to the underlying bone (Fig. 9). Periosteal releasing incisions were made when necessary to achieve easy closure of the mucosal flaps on top of the grafts without tension (Fig. 10). An orthopantomographic control was performed postoperatively to evaluate the outcome of the surgical procedure (Fig. 11).

Postoperatively, patients were instructed to rinse their mouth with chlorhexidine 0.2% for two to three weeks twice a day. After this period, the sutures were removed. Removable provisional prostheses were adjusted generously. Patients were instructed to use their prostheses for cosmetic appearance and for eating rather than function for the whole period of healing, i.e. three months. At that time, patients were scheduled for implant surgery. No antibiotic therapy was continued after surgery and patients were instructed to use non-steroidal anti-inflammatory drugs (Ibuprofen®, Docpharm® Arzneimittelvertrieb GmbH & Co. KGaA) only if pain was present.

### Stage 2 surgery

After a healing period varying between three to six months after the grafting procedure, clinical and radiographic evaluations were performed and implants were placed in a routine fashion using the special program for guided implant surgery CoDiagnostiX® (IVS Solutions AG). All patients underwent CT scan before the implant placement to assess new bone formation and plan the accuracy of the implant position. A crestal incision and subperiosteal dissection of the alveolus were performed and the fixation screws were removed. Implant site preparation was performed with guidance from the laboratory-made splint and the implants were positioned (Figs. 12–18). We used bone-level type titanium implants. The most common in use were Straumann® Bone Level implants (Institut Straumann AG, Switzerland), followed by Astra® (Astra Tech Inc.) and Camlog® (CAMLOG Vertriebs GmbH, Germany). In total, 155 implants were positioned, 39 in the maxilla and 116 in the mandible. Three to six months later, the prosthetic work was started.

Clinical appointments were performed after surgery to evaluate any complication at the donor and recipient site, such as dehiscence, infection, swelling, sensory disturbances or haemorrhage. Graft loss and graft removal were defined as failure; swelling, wound dehiscence, incision line opening, infection with pus or temporary paresthesia were defined as complications. Buccal nerve damage from incision along the external oblique ridge as well as the damage of inferior alveolar nerve is possible. Graft incorporation was evaluated following the removal of the fixation screws. Statistical analysis included descriptive statistics using IBM SPSS Software for Windows. The significance level of  $p \leq 0.05$  for all statistical tests was definite. The residents of our department operated and followed upon all patients, and the results were analysed in percentage and presented in tables and diagrams.

### Disclosure

The authors do not have any financial interests, either directly or indirectly, in the products listed in the study.

### \_contact

### implants

#### Andreas Sakkas

Oral Surgeon  
Department of Oral and Maxillofacial Surgery, Facial Plastic Surgery  
Military Hospital Ulm and Academic Hospital  
University Ulm  
Ulm, Germany

Tel.: +49 731 17101701  
andreaszfc13@yahoo.gr

*Editorial note: To be continued in implants 4/2013 with results, an extensive discussion and tables. A full list of references is available from the publisher.*

A black and white photograph of a woman with long, wavy hair, wearing a dark, short-sleeved dress and high-heeled shoes. She is sitting in a modern, white, egg-shaped chair. There are two other similar chairs visible in the background, one to the left and one to the right. The background is a plain, light-colored wall.

**I AM A FAN**

like most of my colleagues.

Dr. Leyli Behfar | Specialist in Oral Surgery

CAMLOG is my first choice when it comes to dental implants. With their high-precision implant systems, I find an answer for every indication. Implantations can be performed easily, efficiently and with excellent quality standards. CAMLOG is an inspiring partner in many ways – and that is getting around. [www.camlog.com](http://www.camlog.com)

a perfect fit™

**camlog**