

# Treatment of aphthous stomatitis using low-level laser therapy

**Authors** Pedro J. Muñoz Sánchez, Cuba, José Luis Capote Femenias, Cuba & Jan Tunér, Sweden

[PICTURE: © MATHAGRAPHS]

## Introduction

Aphthous stomatitis has been investigated to a great extent; however, the aetiology of these lesions is still to be identified accurately. Recurrent aphthous stomatitis is considered a chronic illness accompanied by painful oral ulcers that reappear with irregular frequency.

The following categories have been described:

- smaller aphthous ulcers (80–85% of cases; of a diameter of 1–10 mm; healing spontaneously in seven to ten days);
- larger aphthous ulcers (Sutton's disease; 10–15% of cases; of a diameter larger than 10 mm; healing spontaneously within ten to 30 days or more; may leave a scar); and
- herpetiform ulcers (5–10% of cases; multiple clusters of lesions of a diameter of 1–3 mm, which can coalesce into larger erosions; healing in seven to ten days).<sup>1</sup>

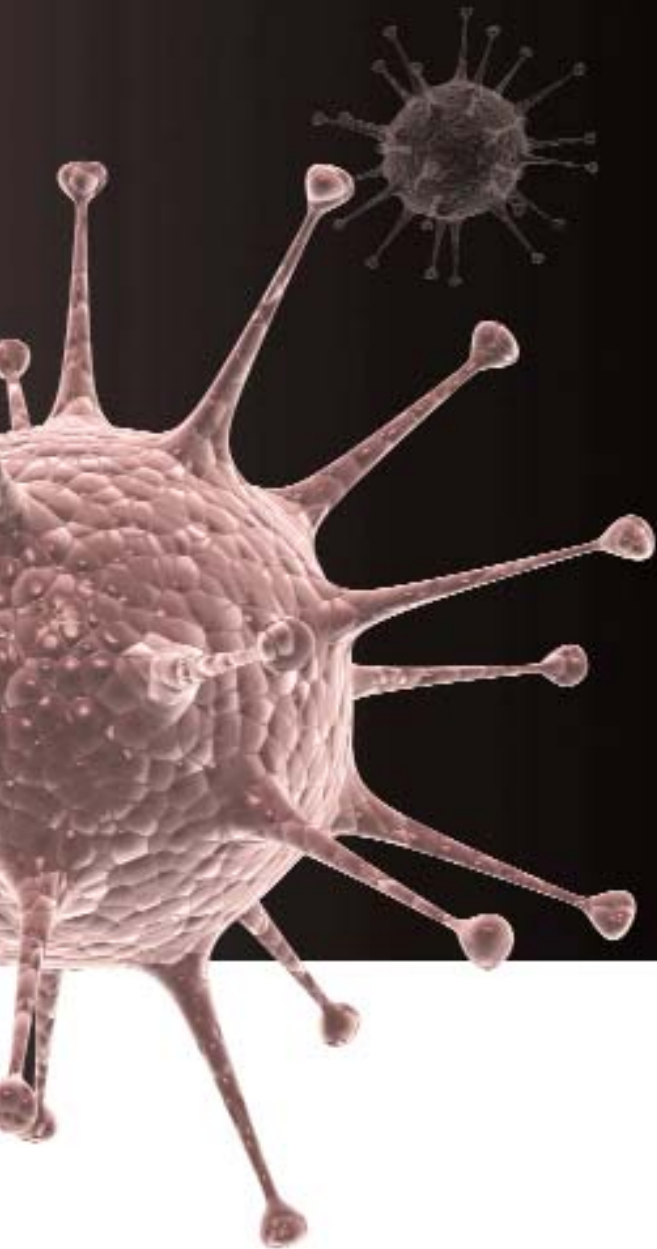The predisposing factors of recurrent aphthous ulcers are speculative; among them are trauma, emotional stress, coeliac disease, hormonal changes, hypersensitivity to certain foods, allergic reactions and intoxications.<sup>1</sup> It is believed that aphthous stomatitis affects 20% of the US population

and studies have demonstrated a worldwide prevalence of 31–66%.<sup>2</sup> It is important to highlight that the diagnosis of aphthous stomatitis is primarily clinical and should be differentiated from systemic conditions, such as coeliac disease, Crohn's disease, herpes simplex virus Type 1, Reiter's syndrome, syphilis, systemic lupus erythematosus, T cell disorders, chicken pox and B6 deficiency.<sup>3–7</sup>

The benefits of local therapies have been demonstrated with anaesthetics and corticosteroids, applied in prodromal stages or in early stages of the lesions. When treating with systemic steroids, it is important to consider the course of the ulcer.<sup>8–21</sup> According to reports from Cuba, treatment with low-level laser therapy (LLLT) is effective, achieving rapid relief of pain, quicker wound healing and lower frequency of recurrence.<sup>22–24</sup> The aim of the present clinical unblinded study was to evaluate the prevalence of aphthous stomatitis in various age groups, as well as the effect of LLLT in the treatment of aphthous stomatitis.

## Material and methods

An experimental study was carried out in patients with a clinical diagnosis of aphthous stom-



atitis attending the Leonardo Fernández Sánchez dental clinic in Cienfuegos in Cuba between September 2010 and March 2011. Among the 252 patients registered, 208 attended the clinic until the lesions had healed completely. The study was approved by the Scientific Council of the University of Medical Sciences, Cienfuegos. All of the patients were informed about the parameters of the study and gave their informed consent.

LLLT was administered to 104 patients (study group) and the remaining 104 (control group) received conventional treatment, such as topical anaesthetics (2% lidocaine), dietary advice and oral painkillers. Every second patient with the same type of ulcer was allocated to either the study or the control group. The two groups consisted of 56 males and 148 females, with a great variation in age distribution (Table 1).

All of the patients were seen daily and the patients in the study group received LLLT every second

day unless their ulcer had already healed. The patients were categorised with regard to age and ulcer type (Tables 1 & 2). Special diagnostic procedures were performed in patients with large ulcers to confirm a safe differential diagnosis. Pain was evaluated, but since pain is subjective, it was decided only to register the time until wound closure (Fig. 1), which can be registered objectively. No patient in the study group reported any negative effects of the laser irradiation.

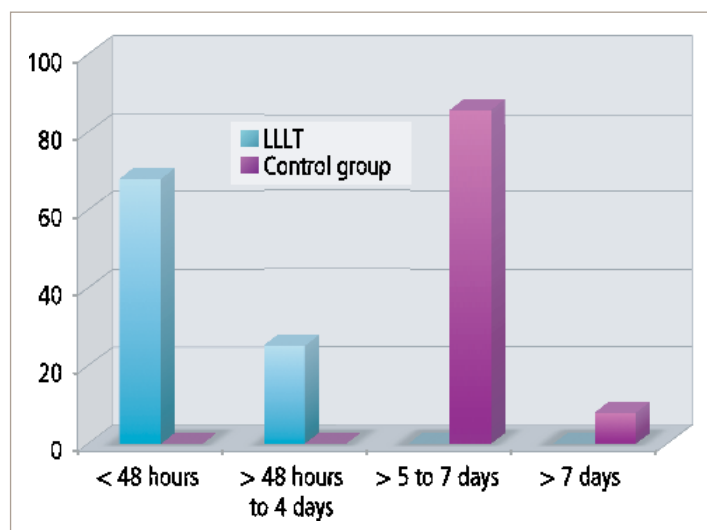
The laser used was the Lasermed 670DL (Cuban manufactured), 670 nm, 40 mW. Each ulcer underwent 40 seconds of irradiation at 1.6 J, 2.04 J/cm<sup>2</sup> and 51 mW/cm<sup>2</sup> from a distance of about 0.5 cm. The parameters used were based upon the successful application of these in a previous study on herpes simplex virus Type I blisters.<sup>32</sup>

The study was unblinded. A 660 nm laser emits clear red light and, although a patient-blinded design is possible, it is not possible to mask a placebo laser for the therapist.

The distribution of the age of the patients, of the types of ulcer according to age, and of the types of ulcer in the study and control groups is shown in Tables 1–3. This data corresponds with the literature, where smaller aphthous ulcers represent 80–85% of cases, larger ulcers 10–15% and herpetiform ulcers 5–10%.<sup>1</sup>

## Results

The main results of the study are presented in Figure 1. The results shown are for small ulcers, which were the dominant type of ulcers treated. As for the large ulcers in the study group, four scarred between two and four days, and another four scarred between five and seven days. In the control



Sex	Age group (years)					Total
	0–9	10–19	20–39	40–59	60+	
Male	4	4	16	24	4	52
Female	4	20	48	52	28	152
Total	8	24	64	76	32	204

Clinical type	Age group (years)					Total
	0–9	10–19	20–39	40–59	60+	
Small ulcers	4	24	60	64	28	180
Large ulcers	–	–	8	12	–	20
Hepetiform ulcers	–	–	–	–	4	4
Total	4	24	68	76	32	204

Clinical type	Age group (years)		Total
	Study group	Control group	
Small ulcers	92	92	184
Large ulcers	8	8	16
Hepetiform ulcers	4	–	4
Total	104	100	204

group, eight large ulcers scarred within seven days. For ethical reasons, and because of the small number of cases, the four herpetiform ulcers were all treated with laser. They healed between two and four days. According to the literature, the normal healing time with no treatment is seven to ten days for small aphthous ulcers, ten to 30 days for large aphthous ulcers, and seven to 14 days for herpetiform ulcers.<sup>1,3</sup>

## Discussion

The use of LLLT to treat aphthous stomatitis was suggested in 1986 already by Quang-Hua<sup>25</sup> using a helium–neon laser and in 1987 by Von Alften<sup>26</sup> using a gallium arsenide laser. Recent studies, such as the one by De Souza et al.<sup>27</sup> have used a laser similar to ours, 670 nm, 50 mW, 3 J/cm<sup>2</sup>. It therefore appears that the wavelength itself is not decisive. Indeed, Zand et al.<sup>28</sup> report good results using a carbon dioxide laser at non-thermal levels in combination with a transparent gel to reduce beam absorption. Surgical lasers have also been reported to be effective, but the mechanism here ought to be different, since it entails superficial tissue evaporation. Tezel et al.<sup>29</sup> report fair results using an Nd:YAG laser, while the erbium laser in addition can be used for surface modification of the lesion and pain relief.<sup>30</sup>

The biological mechanism behind the effect of the various lasers is still unknown. The power setting used in our study was rather low and the effect of higher power settings needs to be investigated.

Another aspect is the number of sessions. In our study, the patients were treated every second day until wound closure had been achieved. In the De Souza study,<sup>27</sup> patients were treated daily until an obvious result was observed. Only four patients with a herpetiform ulcer took part in the current study. Although these ulcers responded well to LLLT, no definite conclusions can be drawn, since all four were included in the study group.

Patients typically have an occasional aphthous ulcer. The problem arises in patients with recurrent aphthous ulcers. The frequency of recurrence was not investigated in our study, but no presently available treatment has been able to reduce recurrence.<sup>31</sup> However, such a possibility is suggested in some sources.<sup>22–24</sup> In a recently published study,<sup>32</sup> our clinic found that LLLT reduced the recurrence frequency in herpes simplex virus Type I patients. Although aphthous ulcers are different to herpes simplex virus Type I blisters, LLLT might reduce their frequency of recurrence too.

## Conclusion

LLLT appears to be a safe and effective option for treating aphthous stomatitis. The distribution of aphthous stomatitis in the various age groups was found to be in accordance with previous reports.<sup>33</sup> Further studies are warranted to investigate the optimal laser parameters and frequency of irradiation.

## Statement

The present study was financed by the authors and their clinics. Pedro J. Muñoz Sánchez and José Luis Capote performed the clinical part. Jan Tunér served as scientific advisor and authored the manuscript.

*Editorial note: A list of references is available from the publisher.*

## contact

laser

Jan Tunér

Spjutvagen 11  
772 32 Grängesberg  
Sweden

jan.tuner@swipnet.se



## New Orleans

American Dental Association

# ANNUAL SESSION

OCTOBER 31 - NOVEMBER 3, 2013

**ADA** American Dental Association®  
America's leading advocate for oral health

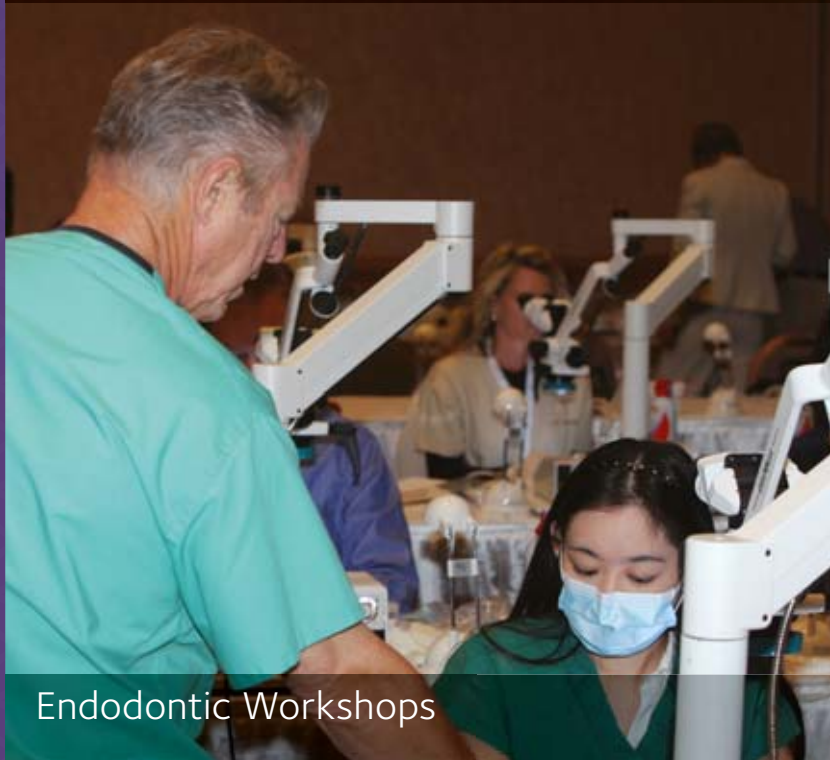## Make the 2013 ADA Annual Session your first choice for endodontic education

Select from 13 endodontic courses at the 2013 Annual Session and learn from renowned speakers such as Dr. David Beach, Dr. John Olmsted, Dr. Clifford Ruddle, Dr. Jordan West and more.

**Registration is open now.**  
**[ADA.org/session](http://ADA.org/session)**



Endodontic Education



Endodontic Workshops



Endodontic Lectures