

# Surgical management of peri-implantitis with laser

## A Case Report with eight years follow up

**Authors** Prof. Dr Aslan Yağar Gokbuget, Emin Selim Pamuk, Res. Asst. Dt. Necla Asli Kocak, Turkey

[PICTURE: ©BUSLIK]

### Introduction

The term peri-implantitis first appeared in the literature in 1987 in a study by Mombelli and colleagues. It was described as an infectious disease with many features common to periodontitis. Since then, a growing interest in defining peri-implant disease as a clinical entity and to propose a treatment approach for it has been observed. Peri-implantitis has been defined as the inflammatory reactions associated with loss of supporting bone around an implant in function. Along with this definition of peri-implantitis in the 1<sup>st</sup> European Workshop on Periodontology (EWOP) in 1994, another implant-related pathology, which is peri-implant mucositis was defined as a 'reversible' inflammatory reaction in the soft tissues surrounding a functioning implant. These definitions thus imply that the inflammatory process that occurs in peri-implantitis lesions is irreversible. Peri-implantitis affects 5% to 10% of implant patients, and is a major cause of implant failure.

### Clinical presentation of peri-implant diseases

#### *A) Peri-implant mucositis*

This is a reversible inflammatory reaction in the soft tissues that surround an implant in function. Clinically it is characterised by:

- Presence of bacterial plaque and calculus
- Oedema, redness and mucosal hyperplasia
- Bleeding affecting mucosal sealing on probing

- Exudate or pus formation on occasions (gingival microabscess)
- Radiological absence of bone reabsorption

#### *B) Peri-implant osteitis (Peri-implantitis)*

This is an irreversible inflammatory reaction in the soft and hard tissues that surround an implant in function, because natural bone loss occurs if no treatment is given. It has more florid clinical symptoms because, in the initial phase, it may present the same signs as peri-implant mucositis, but these are later accompanied by the symptoms of bone loss itself.

The most common signs are:

- Presence of bacterial plaque and calculus
- Oedema and redness of peripheral tissues
- Mucosal hyperplasia in zones with a lack of keratinised gingiva
- Increased probe depth. The level of probe reaches the apex
- Bleeding and slight pus formation after probing and/or palpation
- Vertical bone destruction in relation to peri-implant pocket
- Radiological presence of bone reabsorption
- Implant mobility
- Pain is not very common, but is sometimes present

### Treatment peri-implant diseases

#### *A) Treatment of implant mucositis*

Treatment is principally focused on controlling bacterial plaque, although other surgical treat-



ments may be performed to eliminate the hyperplasia of surrounding soft tissue as well as to graft keratinised gingiva, if necessary.

Thus, treatment consists of several phases:

1. Professional peri-implant hygiene:
  - Mechanical elimination of bacterial plaque
  - Irrigation of the surcus-pocket with 0.12% chlorhexidine
  - Removal and disinfection of the prosthesis
  - Modification of unhygienic prosthesis designs
  - Sometimes a partial-thickness flap is performed to irrigate with sterile physiological saline, followed by the application of a tetracycline cream
  - laser treatment in refractory cases
2. Personal peri-implant hygiene:
  - Chemical plaque control with 0.12% chlorhexidine 12 hourly.
3. Local and systemic antibiotics
4. Regular professional control

#### B) Treatment of peri-implantitis

Treatment using the cumulative, interceptive, supportive therapy (CIST) protocol, Mombelli and Lang<sup>1</sup> (1998) recommend various treatment options according to the severity of the peri-implant infection. Mechanical debridement, antiseptic agents, local or systemic antibiotic therapy and surgical therapy are used alone or in combination, based on pocket depth (PD), bleeding on probing (BOP) and degree of bone loss. Mechanical debridement can be attempted with carbon, plastic or metal curettes, ultrasonic scaling or air abrasion.<sup>2,3</sup> Chlorhexidine

digluconate can be used as a disinfectant, either as a mouth-rinse at 0.1 to 0.2%, a subgingival irrigant at 0.2% or locally applied as a gel.<sup>1</sup> Persson et al. (2006)<sup>2</sup> reported the use of tetracycline fibres and minocycline microspheres, both sustained antibiotic release devices for treating peri-implantitis. Surgical therapy can involve gingivectomy for better access to implant structures, apically repositioned flap, osteoplasty or guided bone regeneration.<sup>1</sup> Unfortunately, each of the aforementioned methodologies presents different limitations and, as yet, there is no 'gold-standard' treatment that can reliably decontaminate peri-implantitis-associated implants and provide long lasting improvement in clinical parameters. The fundamental requirement in successful peri-implantitis treatment, with or without the use of bone regeneration protocols, is to decontaminate the implant surface, removing bacteria and toxins. Peri-implantitis treatment must be based on the stabilisation of progressive bone loss, and in special cases, to retrieve lost bone with regenerative treatment. The treatment can be divided into two phases:

- Phase 1: Initial conservation treatment
  - A. Manual-mechanical methods to control bacterial plaque (similar to mucositis)
  - B. Chemical methods
    - B.1. Local: 0.12% chlorhexidine, citric acid, local application of tetracycline
    - B.2. Systemic: Antibiotic therapy
  - C. Lasers
- Phase 2: Regenerative treatment

#### Treatment of soft tissues

A crestal incision is scalloped around the implant neck to eliminate the internal epithelium and granulation tissue from the pocket. A mucoperiosteal flap is lifted to expose the implant, and bone tissue and granulation tissue is eliminated from the bone defect with a metal curette without touching the implant. A cold sterile physiological saline solution is irrigated throughout the procedure to prevent bone dehydration.

#### Detoxification of the implant surface

Limitations of treatment; Karring et al.<sup>4</sup> found that neither ultrasonic debridement, using a carbon fibre tip, nor mechanical debridement, using carbon fibre curettes, were effective in reducing pocket probing depth after six months, in patients with failing implants. Lavigne et al.<sup>5</sup> found no clinical or microbiological effect when 0.12% chlorhexidine was used to irrigate implants with probing depths of greater than 3 mm. Mombelli and Lang<sup>6</sup> reported that mechanical debridement of implant surfaces in conjunction with a 0.5% chlorhexidine rinse and

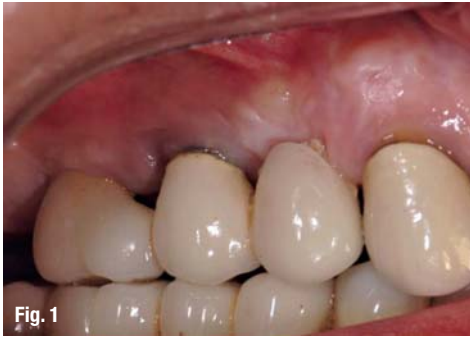

Fig. 1

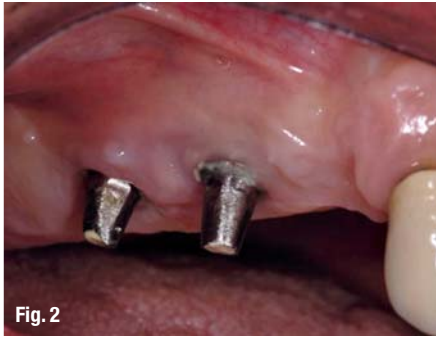

Fig. 2

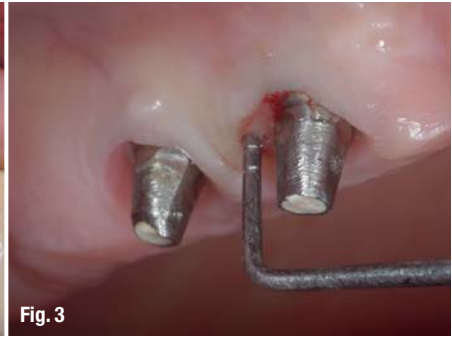

Fig. 3

**Fig. 1**\_First examination.  
**Fig. 2**\_After removal of the dental prosthesis.  
**Fig. 3**\_Probing depth around implants.

systemic antibiotic therapy (single daily oral dose of 1,000 mg ornidazole) led to reduced levels of inflammation after one year, however there was no statistically significant reduction in bacterial level or proportions of bacteria. Miller<sup>7</sup> states that tetracycline paste can be used to decontaminate implant surfaces, although it is not effective in removing bacterial endotoxin.

### Types of implant surface detoxification

#### A. Chemotherapeutic agents

1. CHX
2. Tetracycline, polymyxin B, or H<sub>2</sub>O<sub>2</sub>
3. Citric acid

#### B. Laser

A promising method for decontaminating implant surfaces involves the use of laser energy. The use of lasers is becoming increasingly common in dentistry, with applications in soft tissue surgery, caries removal, and also in the treatment of peri-implantitis. Unlike mechanical decontamination methods, which can not fully adapt to the irregularities on the surface of an implant, lasers can irradiate the whole surface, reaching areas that are too small to receive mechanical instrumentation. Recent *in-vivo* studies have analysed the outcome of peri-implantitis treatment using the Er:YAG laser<sup>8-14</sup> and CO<sub>2</sub> laser<sup>15-17</sup>. Many of these studies show promising short-term results (< six months) but report no long-term follow up. When considering the use of lasers in the treatment of peri-im-

plantitis, there are a number of decisions that the clinician must make. First is the type of laser to use, options of which include Nd:YAG, Er:YAG, Er,Cr:YSGG, diode or CO<sub>2</sub> laser. Power settings are variable, and the clinician must also choose a setting that will effectively disinfect the implant while not damaging the surface. Additionally, the exposure time and distance from which the laser is applied also has an effect on both the success of decontamination and damage to the implant surface. The clinician also has the option of combining laser therapy with other types of decontamination therapy. Current research tends to focus on the bactericidal properties of Nd:YAG, Diode, Er:YAG, CO<sub>2</sub> and Er,Cr:YSGG lasers and the effects that they have on implant surfaces.

### Guided bone regeneration used in implantology

Iovanovic and Nevins<sup>18</sup> evaluated four adult patients with insufficient bone that were selected for treatment with the titanium-reinforced membrane (TRM, Gore Corp.) with or prior to placement of Brånemark implants. Sites treated with GBR without grafting had a fibrous layer up to 3 mm thick, whereas those treated with GBR+ grafting had a fibrous layer only 1 mm thick. Lundgren et al.<sup>19</sup> reported the use of a bio-resorbable material (GUIDOR™, Butler Corp.) to cover implant exposures after the installation of Brånemark implants, with and without the use of autologous bone chips. Their conclusion was that the material, which resorbed in six to seven months, was a satisfactory barrier but that a supporting grafting material should be used to prevent barrier collapse. However, other investigators<sup>20-22</sup> are of the opinion that an allograft is not essential or advantageous in guided tissue or guided bone regeneration.

GBR is also used in the implant modalities to facilitate repair and in regeneration procedures associated with an ailing, failing dental implant, with and without grafting materials.<sup>23-35</sup> Regardless of the material used, non-resorbable or absorbable/resorbable, with and without the addition of a

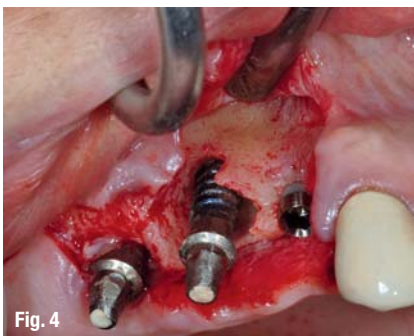

Fig. 4

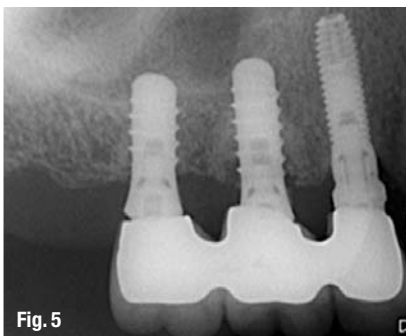


Fig. 5

grafting material (auto, allo, xenograft, or alloplast), the membrane used for GBR must be left in place for as long as possible and not removed prematurely.

## **\_Clinical presentation and case management**

A 60-year-old female patient presented at our private clinic PGG for treatment of the implants at the right maxillary molar site. The implant has been placed seven years ago and the implant supported simulated porcelain fused to metal fixed partial denture was made (Fig. 1). Upon review of her medical history she was otherwise healthy. She previously had been treated for chronic periodontitis with non-surgical approach. Then radiographic examination was made and revealed a combined marginal and vertical radiolucency. The implant crown was removed (Fig. 2) and on clinical examination deep probing depths were isolated (Fig. 3). No clinically detectable mobility of the fixture was present. The patient was referred for an extra implant on the right first premolar site while doing a surgical entry for the peri-implantitis around the two implant at the right maxillary molar site. One hour prior to surgery, the patient was given 2 g of Amoxicillin and following surgery placed on a regimen of Amoxicillin 1,000 mg tid for 5 days post-op. A crestal incision is scalloped around the implant neck to eliminate the internal epithelium and granulation tissue from the pocket. A mucoperiosteal flap is raised to expose the implants (Fig. 4), and bone tissue and granulation tissue is eliminated from the bone defect with Er:YAG laser with power settings of VSP 120 mJ, 10 Hz with water and air flushing and Nd:Yag laser with 300 µm tip, VSP, 2Hz, 20 W power setting is used for implant surface detoxification. An additional 3.3 x 13 mm TSW implant was placed to first premolar site, then Xenogenous bone grafts (Bio-Oss®) compacted into the defect. A non-resorbable Gore-Tex® barrier was placed over the defect and was extended buccally and lingually. The buccal and lingual flaps were released and tension-free primary closure was achieved with 4-0 teflon sutures. She was instructed to continue the antibiotics as prescribed and to rinse with the 0.12% Chlorhexidine gluconate bid for one minute, twice a day. Finally, a strict maintenance and oral hygiene protocol were established.

The area healed uneventfully after six months. Periapical radiographs were taken throughout the healing process to evaluate the mineralization of the graft over time. After six months, a Gore-Tex® barrier was removed and healing abutments are placed. After one week the previous restoration was replaced. Bone formation within the bony defect

was evident. At that time the previous screw retained restoration was replaced. At the six-months follow-up, the implant was evaluated and found to have probing depths of 1–3 mm with 1–2 mm of recession on the mid-buccal aspect radiographically it appeared that there was increased mineralisation of the bone surrounding the implant. The patient was again examined every one year and eight years after treatment a new radiograph was taken which demonstrated complete resolution of the bony defect surrounding the implant (Fig. 5).

## **\_Discussion**

There is no standard of care for the treatment of peri-implantitis, and clinicians are faced with a lot of choices when deciding upon a method of treatment. This case has shown the use of lasers to treat peri-implantitis. It must be noted that the treatment of peri-implantitis requires decontamination of implant surfaces and maintaining a healthy peri-implant environment. Long-term success is dependent upon patient cooperation, regular maintenance and assessment, and adaptation of treatment planning as symptoms improve or decline. This case has shown that laser therapy is potentially a very useful tool in the treatment of peri-implantitis, however, further research is needed to aid clinicians in providing the ideal treatment for this disease.

## **\_Conclusion**

Although no definitive conclusion can be drawn from a single case report, the guided-bone-regeneration-combined laser technique described in this case report effectively eliminated implants associated three-wall bony defect and deep pocket. Under the conditions of the present case, it may be concluded that the Er:YAG laser can be safely and effectively utilised for degranulation and implant surface debridement in the surgical treatment of peri-implant infection.

*Editorial note: A list of references is available from the publisher.*

### **\_contact**

**laser**

#### **Prof. Dr Aslan Y. Gokbuget**

PGG Dental Clinic  
Tevsikiye Caddesi Kismet Apt. 133 d.8  
34365 Nisantasi  
Istanbul, Turkey

Tel.: 0212 248 0317  
Fax: 0212 247 5118