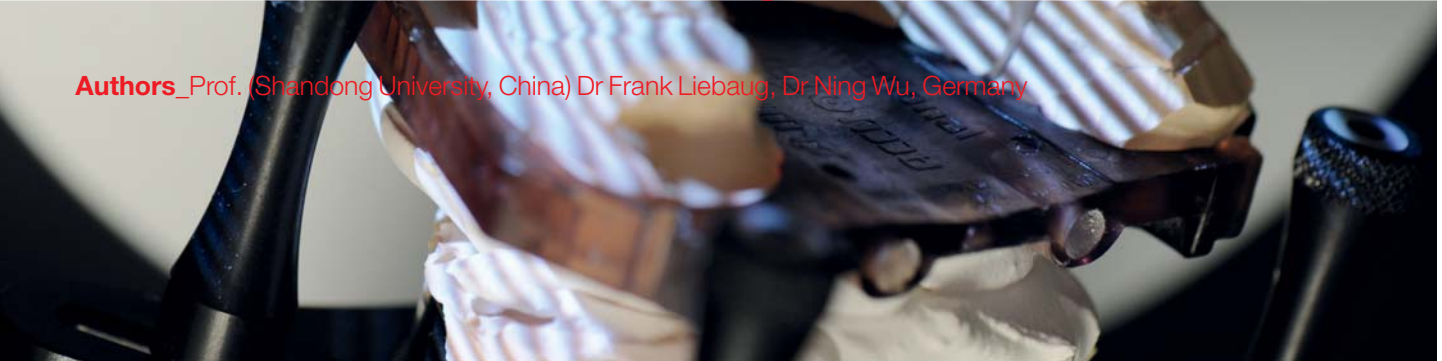

Diode laser application optimises the clinical outcomes of digital workflow

Authors Prof. (Shandong University, China) Dr Frank Liebaug, Dr Ning Wu, Germany



Introduction

"Digital Workflow" has become an established term in present-day dentistry, helping to solve problems in dental technology which would have been rejected due to an unwarranted high analogous effort some years ago.

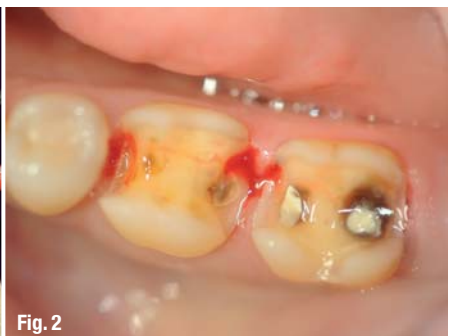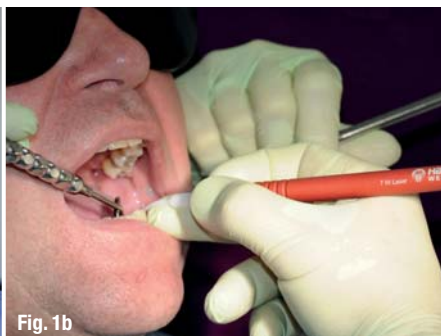day's dental technicians in terms of reliability in planning and treatment. Now, neighbouring teeth, roots and nerves can be captured precisely via digital volume tomography, with the data being visualised three-dimensionally. These options result in a significant risk reduction of implant placement in the jaw bone. Furthermore, digitalisation has achieved a fundamental change in patient communication. Dental technicians and dentists are thus no longer demanded exclusively as clinicians and craftsmen. For instance, CADM/CAM technology and intraoral cameras allow for presenting transparent solutions for an improvement of the aesthetic situation to the patient already in the practice. Therefore, the patient is informed more soundly and can be included in decisions on treatment planning.

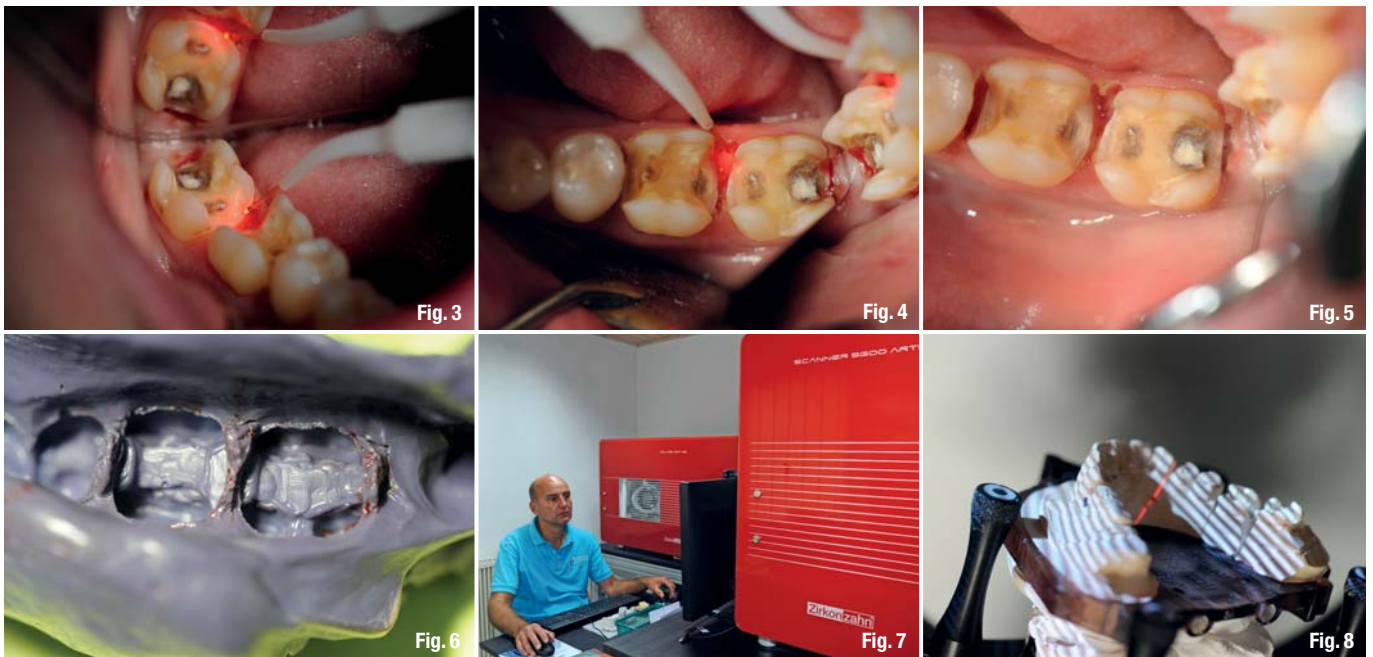
Fig. 1a Laser HF (Hager & Werken GmbH & Co.KG, Duisburg, Germany): The only device combining two lasers 975 nm/6 W and 66 nm/25–100 mW and HF surgical component 2.2 MHz for easy, fast and precise cutting of soft tissues.

With digital procedures entering the realms of diagnosis, therapy and production, the workflow of dentists and dental technicians has changed considerably over the past years. Today, all dental disciplines rely on digital technologies to achieve exact diagnosis, modelling and production. The broad spectre of technologies reaches from intraoral scanners for three-dimensional scanning of the stomatognathic system to the production of models via CAD-data by 3-D printers. Dentists and dental technicians make use of these technologies as well as of manual procedure steps. Digital technologies have improved the highly demanding work of to-

The production of restorations has undergone a tremendous change in the past years. All-ceramic crowns have replaced porcelain fused to metal as the standard. The properties of materials such as zirconium

Fig. 1b The preparation margin can be traced ergonomically via the laser hand piece like holding a fountain pen.
Fig. 2 Blood and saliva make the depiction of the prosthetic preparation margin more difficult.





oxide have been improved to deliver perfect aesthetic results.

Dentistry without digital technology and CAD/CAM procedures has become inconceivable. Intraoral and extraoral measurement, scanning of antagonists and registration, three-dimensional construction on screen (Fig. 7), applying a large variety of tooth shapes from the data base, designing anatomical occlusal surfaces, the functional articulation in the virtual model, the subtractive processing of high-performance ceramics—all of this would be impossible without computers.

New procedures influence established steps of the process, and advances simplify workflows. Thus, virtual construction models, the articulation via Windows interface, biogeneric design of occlusal surfaces via intelligent software, rapid-prototyping and 3-D printing are only a small sample of the topics which are discussed in scientific publications with regard to CAD/CAM dentistry. Small and medium-sized dental laboratories or, as in my case, larger practice laboratories will acknowledge their core competence of producing high-class aesthetic restorations as well as individually designed partial dentures and implant dentures.

It has thus become a prevailing trend to produce inlays, onlays, partial dentures and single-tooth restorations as well as large-span bridges and suprastructures assisted by computer. In addition, the computer-assisted production of long-term temporary restorations according to functional criteria has become an established method in our practice for implantology and its suprastructures.

Exact transfer of the oral situation as the base

Without an impression of the actual patient situation, modern dentistry is unthinkable. For decades, not much has changed with regard to impression technique, except for the development of impression materials. Already in the 1980s, the first trials in digital impression taking were conducted in the form of intraoral optical scans and then introduced as a new technique. By now, this technique is so well-developed that it can be applied in a multitude of indications.

However, an exact transfer of the oral situation on the virtual or physically present model is the foundation and the beginning of digital workflow. Whether analogous impression taking or digital scanning by optical procedures is applied, the mode of preparation, especially the preparational margin, must be depicted exactly.

Although sometimes the soft tissues can be pushed away from the subgingival preparational margin because of the viscosity of the impression material, opti-




Fig. 3 Working tip of the diode laser for haemostasis.

Fig. 4 Excision of interfering soft tissue can be done fast and effectively via laser.

Fig. 5 After laser application, the preparational margin is depicted clearly. This is mandatory for analogous as well as optical impression taking in order to achieve optimum results in the patient's prosthetic rehabilitation.

Fig. 6 Detail of the polyether impression taking (Impregum Penta Soft, ESPE Company, Seefeld, Germany) with individual impression tray confirms the exact depiction of the oral situation, especially the preparational margin at the cavity margin.

Fig. 7 Milling machine M5 with strip light scanner S600 ARTI as a component of the CAD/CAM system 5-TEC in Ferrari red by Zirkonzahn GmbH, Italy.

Fig. 8 Model under strip light (inside the scanner S 600 ARTI).

Fig. 9 Articulator with model of upper and lower jaw in the strip light scanner S600 ARTI.

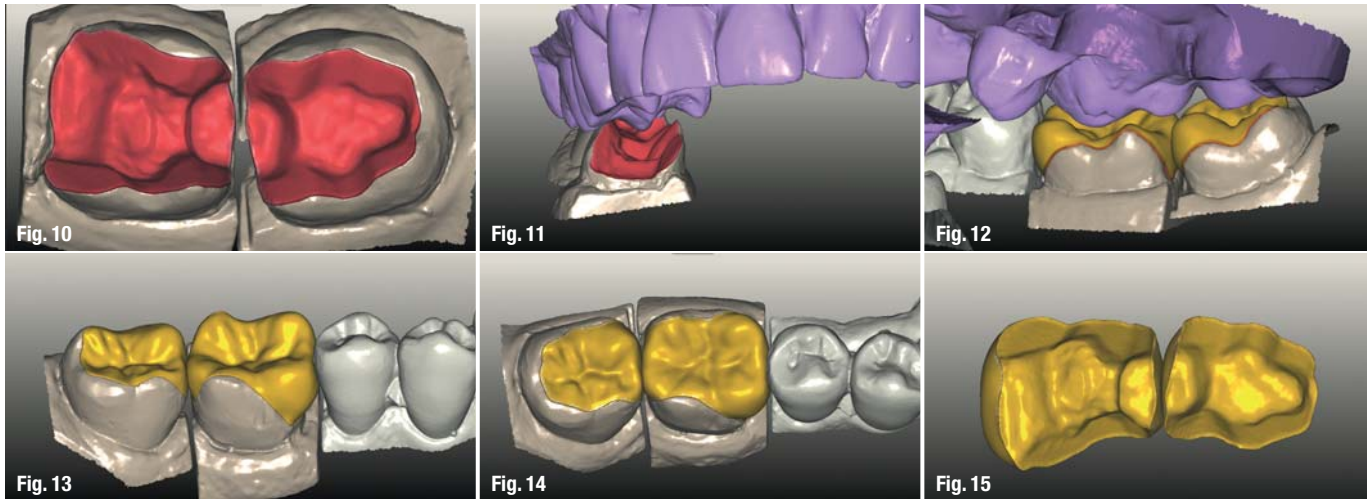


Fig. 10 Depiction of the form of the preparation, especially the level ranges on the monitor, after cutting less relevant aspects of the model situation image digitally.

Fig. 11 Checking of the minimum layer depth for the future ceramic restoration is more practical than via the analogous model.

Fig. 12 Articulation can be checked from various perspectives.

Fig. 13 Production and checking of the optimum occlusal configuration.

Fig. 14 Okklusal view of the digitally planned partial crowns.

Fig. 15 In the end of the digital planning phase, the restoration can be checked from all special dimensions even before the milling process.

cal impression taking via scanner systems does not allow for this option.

While optical impression taking systems make a contribution to standardization, direct control of the preparation outcome and thus to the quality of the impression, conventional as much as digital optical impression taking can only capture structures which are visible to the human eye. Optical impression taking cannot replace conventional impression taking techniques completely. This holds true especially for removable and complete dentures as well as circular implant suprastructures. In addition, the transfer of virtual data into real-life working models, which is often mandatory, has not yet been perfected.

However, the current trend is digital impression taking, although many obstacles have yet to be overcome.

A review of the literature and published reports shows that in most cases supragingival preparation margins are treated, which some colleagues might be able to take an impression from without any retraction cords. Extensive haemostasis measurements and tissue suppression can cause more trouble, since a camera will only be able to scan areas optimally which are easily accessible.

No optical system has been able to see through a pooling of saliva or offer usable data for an exact rendering of the preparation margin. Imprecision can accumulate between impression taking and final prosthesis. Thus, both the advantages and the precise results produced by digital workflow would be taken ad absurdum.

But the clinical, deeply subgingival preparation margin with bleeding of the adjacent gingiva (Fig. 2) can be a severe challenge for experienced clinicians using the traditional analogous impression technique. Without cord techniques or astringent auxil-

iaries, a good result is hard to achieve from impression taking. Or is it?

Twenty years ago, I have introduced high-frequency technology and shortly afterwards dental lasers to our praxis because of the high quality standards in solving prosthetic problems by our team of clinicians and dental technicians. Especially the compact diode lasers can be applied effectively in this field.

Laser radiation

Not only is laser radiation absorbed by the tissue and then transformed into heat, but it is also partly transmitted through the tissue. This takes place independently from the respective dental laser and determines the indication. The cutting speed of the laser radiation is limited by the tissue, which can only be ablated in layers. Laser radiation produced by the dental laser is led to the application site in the oral cavity by fibre optic systems consisting of mirror joint arms and flexible glass fibres. Here, laser radiation from the anterior fibre heats the surface layer of the tissue in a closely-defined area, thus ablating the tissue. In order to reach deeper layers, the tissue must be ablated layer by layer. Although some authors see this as a disadvantage¹, this minimally invasive and tissue-conserving procedure is especially helpful in the sensitive cervical areas and in sulcus extension previous to impression taking.²

Clinical Procedure

The handpiece of the diode laser device (Fig. 1) is placed in the hand like a fountain pen (Fig. 1 a). With the thin fibre tip, the preparation margin is traced circularly around the anchor tooth, either over its total circumference or only the gingival level range of the partial crown (Figs. 3–5), by using it like a fine fibre pen of a diameter of only 0.3 mm.

Thus, uneven gingival areas or gingival areas damaged iatrogenically during abutment preparation are removed and haemostasis is achieved. If light oozing bleeding occurs, haemostasis is achieved punctually via laser fibre by increasing the pulse energy (Fig. 4). For this, only little anaesthesia is necessary and the procedure is much more pleasant for the patient. If a scanning system demands the use of powder in order to improve optical impression taking, special care must be taken to ensure that the powder does not bind with blood or cervicular fluid. Otherwise, optical impression taken could provide imprecise results and thus cannot be used as the starting point of the digital process chain.

After the working field was prepared as described and the complete preparation level range is easily accessible by the clinician and can be prepared dryly (Fig. 5), the impression taking technique favoured by the dentist can be performed.

Laser application is seen as part of the prosthetic quality management in my practice and is thus a standardised aspect of every preparation. Immediately before the drainage, precision impressions are taken. For this, I often use individual impression trays and Impregnum (3M ESPE, Seefeld, Germany), as can be seen from Figure 6. The dental technicians in our team check the impression by stereo magnifying glasses and release it for further processing. After the classical production of the model from superhard plaster, the digital process chain starts with the strip light scanner S600 ARTI (Fig. 7).

_Strip light scanner S600 ARTI

The all-automatic, optical strip light scanner S600 ARTI (Zirkonzahn) with two cameras, precision gears without tooth belt and 360° rotation and 100° swivel axis, digital model scanning of almost any object is possible with a precision of about seven micron. Differences can thus be registered easily. The oversized measuring field of 95 x 75 x 100 mm allows for complete scans of the articulator or the whole arch (Figs. 8 & 9). Combined with the software Zirkonzahn.Scan, it is the only scanning system by which the dental technician can register his own laboratory articulator with the scanner und measure its axes. This is necessary for rendering realistic articulator situations with regard to the facial arch in the three-dimensional system of coordinates of the software. When the model situation is depicted on the monitor, the result of the dental preparation after exposure of the levels via laser can be depicted in detail (Fig. 10). This is another opportunity for the treatment team to check for errors. Articulation and layer depths of the planned ceramic restoration can be depicted as seen in Figures 11 and 12. Then, the optimum occlusal planes as well as the form of crown or

partial crown can be planned (Figs. 13 & 14). In addition to the milling machine M5, the scanner S600 ARTI forms a component of the CAD/CAM system 5-TEC (Zirkonzahn) that we use in our practice laboratory. Of course, every step of the process is guided by know-how and expertise in dental technology, which must not be underestimated during sintering process, individualization or veneering.

_Laser light in the placement of the prosthetic restoration

After the dental laboratory fabrication, we have come the full circle with the placement of the full ceramic restoration, for again we need cleanliness and a dry working field free of bleeding for this final dental treatment step. Often, localized gingivitis with an increased bleeding propensity can occur postoperatively or due to the temporary restoration, which often interlocks a number of prepared teeth to achieve stability. Furthermore, personal oral hygiene of the patients, especially flossing, is limited at this stage, which can cause localized gingivitis. Gingival hyperplasia also sometimes occurs, but it can be removed precisely and within seconds by diode laser. This holds especially true for the haemostasis of capillary bleeding and the drainage of the gingival sulcus in close proximity to the preparation margin.

This is the only way to make sure that the various bonding cements or bonding systems are applied according to the manufacturer's instructions.

_Conclusion

Diode lasers are mandatory for an effective quality improvement in the beginning and at the end of the digital process chain. The form of the preparation, especially the preparation margin, must be depicted precisely, whether in analogous impression taking or digital scanning via optical techniques. The routinely application and consequent use of laser technique are the basis for clinical long-term success of the prosthetic restoration. It can therefore help to meet the high demands of the patients.

_contact

laser

Prof. (Univ. Shandong) Dr Frank Liebaug

Praxis für Laserzahnheilkunde und Implantologie
Arzbergstr. 30
98587 Steinbach-Hallenberg, Germany

Tel.: +49 36847 31788
frankliebaug@hotmail.com
www.laserzahnarzt-liebaug.de