



JFROSS ©AMERICA

The green power

Author_Dr Darius Moghtader, Germany

Introduction

Just in time for last year's DGL Annual Congress, elexxion presented its new and well-noted colouring agent Perio Green, which can be applied in photodynamic therapy with an 810 nm diode laser. This article presents more information about this innovation.

Perio Green is a photodynamic product for the treatment of bacteria in the oral cavity. For its activation, a light source of 780 to 820 nm (laser) is mandatory. This light source must fulfil predefined predicaments (wavelength, output power, applicators). Perio Green is a medical device class IIa.

Indications and mode of action

Until now, elexxion has released the non-surgical therapy of chronic periodontitis as a supplement to the removal of hard dental plaque (root scaling & planing) as well as periimplantitis therapy. Further indications, such as its application in the root canal or in infectious mucocutaneous diseases, for example

herpes, are currently being investigated and will be released when they were examined successfully.

Perio Green's effective component is the colourant indocyanine green. It attaches itself to defined plasma proteins which occur in the membranes of bacterial cells. Upon irradiation with light of a defined wavelength and energy, a chemical bond of the colourant molecule is broken and an oxygen molecule is released (singlet oxygen). Singlet oxygen is highly aggressive and changes the cell wall of the bacterial cells, resulting in their death.

In addition, a quasi-antibiotic effect by disabling the Quorum Sensing is discussed. This means that intercellular communication is hampered. Quorum Sensing is used by bacteria to coordinate processes which would be inefficient if they were conducted only by a single cell, for example the production of biofilm or pathogenicity factors.

Additionally a thermal effect concentrated on the bacteria is discussed using 300mW. The low viscosity of Perio Green ensures a safe and complete, independent penetration of the colourant to the bottom of the pocket without any help from the dentist. A subsequent rinsing of the pockets is not necessary. After the therapy, there is no colouring of the mouth or the lips which might trouble the patient.

Case presentation

The first patient who was treated with Perio Green in our practice was a case which is familiar to most dentists. This patient is a nonsmoker, does not suffer from diabetes, but from a normal amount of stress and a rapid formation of calculus and attends our practice for professional oral hygiene two to four times a year. He cleans his interdental spaces daily with interdental brushes and his teeth with a Curaprox supersoft toothbrush applying the Bass technique.

Fig. 1_Initial X-ray.

Figs. 2 & 3 _Sensitive tooth necks in the front area.

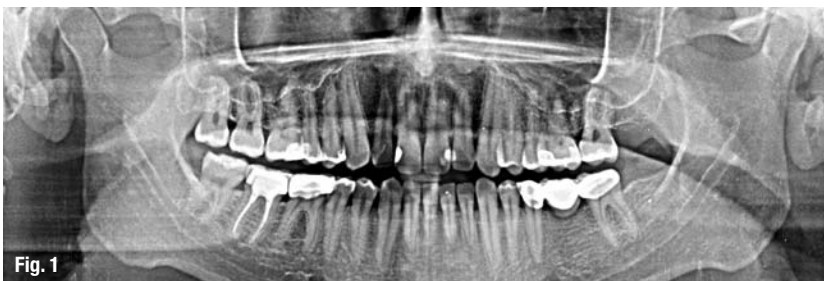

Fig. 1

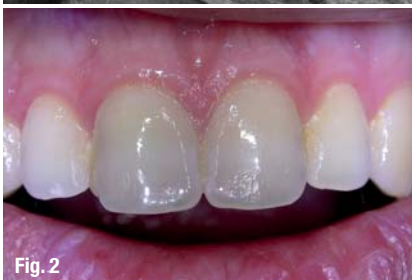

Fig. 2

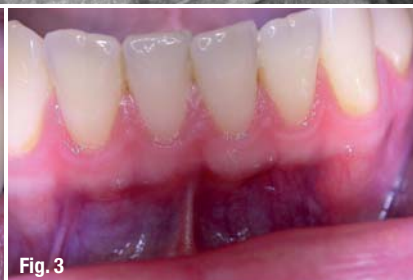
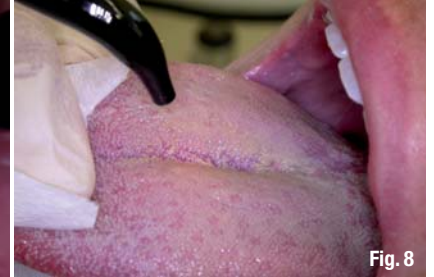
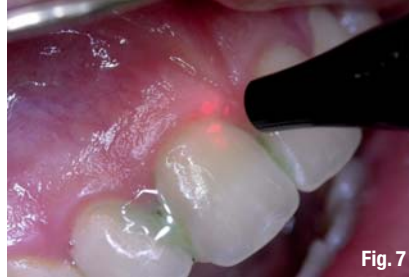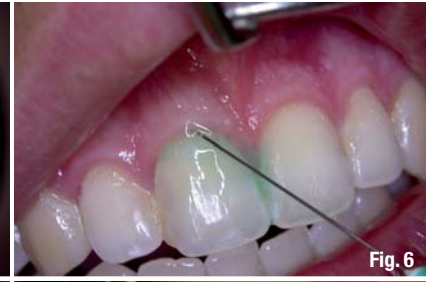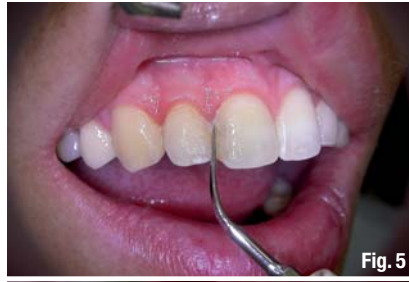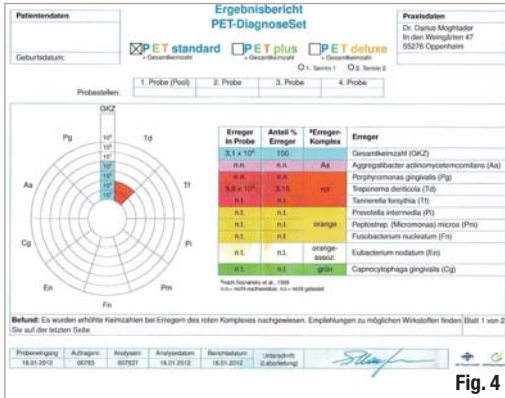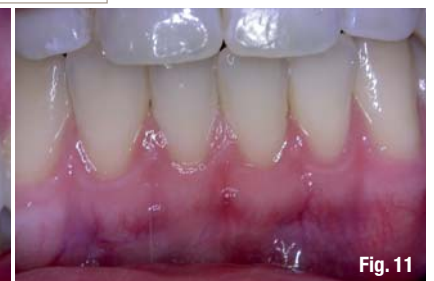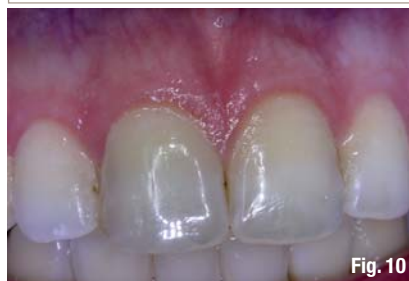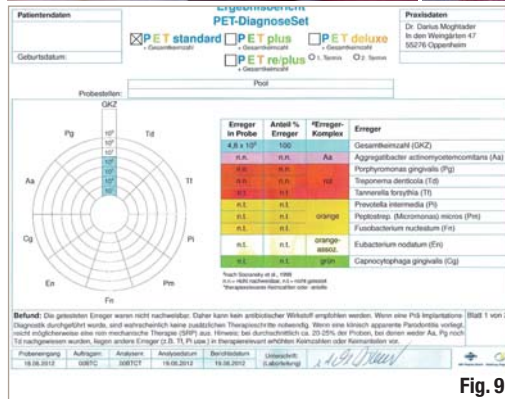
Fig. 3



PSI, API and PBI do not indicate any periodontal disease. Impressions remain inconspicuous (Fig. 1) and the probing depths of 1 up to 3 mm are within the physiological level. No concretions were found.

So was everything alright? Was it not? On several occasions a year, this patient presents with painful and bleeding localised complaints. These are accompanied by sensitive tooth necks especially in the front area (Figs. 2 & 3). These problems usually prevail for one or two days and have often disappeared altogether until his appointment in our practice. However, loosening of the tissue and a distinct reddening were maintained. There was no bleeding upon probing, but bleeding occurred after professional oral hygiene in a higher degree and for an above-average amount of time. Therefore, we suspected bacterial infection with periodontally pathogenic germs. MIP basic test (Fig. 4) confirmed this suspicion and gave evidence for an infection with an enhanced number of Treponema denticola. The patient gave his informed consent for therapy with Perio Green.

After the careful removal of plaque and rinsing of the pockets via low-level ultrasound, Perio Green was applied (Fig. 5) in order to create an aquatic space (Fig. 6). Afterwards, the obligatory internal activation of the colouring agent with an elnexion diode laser of a wavelength of 300 mW and a 300 µm-PA fibre was conducted for 30 seconds vestibularly and orally. The periodontium of each tooth was irradiated for 30 seconds vestibularly and externally, orally with the glass rod T6 of the elnexion Pico in the Perio Green programme with 300 mW (Fig. 7). According to the manufacturer, this step is facultative. The bacterial load of tongue and throat were treated equally (Fig. 8). After two weeks, the patient attended the practice for check-up and MIP bacterial basis test (Fig. 9). The test showed that the elimination of the bacteria was successful. The clinical images showed firm tissue with a healthy, pale pink colour (Figs. 10 & 11). The patient reported that he did not feel any dentin hypersensitivity und has not had bleeding or inflammation for six months.



Conclusion

These first results give reason for the optimistic view of Perio Green offering another effective therapy option against the widespread disease of periodontitis. We are looking forward to seeing further research in order to find scientific proof for these empirical findings.

Fig. 4 MIP basis test. The bacteria test before treatment shows a high amount of Treponema denticola.
Fig. 5 Plaque removal and rinsing of the pockets via ultrasound.
Fig. 6 Application of Perio Green.
Fig. 7 Irradiation of the periodontium with the glass rod T6 of the elnexion Pico.
Fig. 8 Irradiation of the tongue and the throat.

Fig. 9 MIP basis test. The control test after treatment proves the successful bacteria reduction.
Figs. 10 & 11 Clinical pictures.

_contact
laser

Dr Darius Moghtader
 In den Weingärten 47
 55276 Oppenheim, Germany

dr-moghtader@hotmail.de
 www.oppenheim-zahnarzt.de