

# laser

international magazine of laser dentistry

3<sup>2013</sup>

## | research

Treatment of aphthous stomatitis using low-level laser therapy

## | overview

Surgical management of peri-implantitis with laser

## | industry report

Diode laser application optimises the clinical outcomes of digital workflow



# BE AMAZED BY WATERLASE®

The WaterLase iPlus system is simply amazing. It is our most advanced, most powerful and simplest WaterLase yet. But don't take our word for it. See for yourself at

[AMAZEDBYWATERLASE.COM!](http://AMAZEDBYWATERLASE.COM!)

**+ BREAKS THE SPEED BARRIER**

- Up to 100/pulses per second
- Patented tech delivers 600 mJ/pulse
- As fast as a high-speed drill

**+ ILASE 940nm DIODE LASER DOCKING STATION**

- Adds dual wavelength convenience
- First totally wireless diode laser
- Battery operated with finger operation

**+ INTUITIVE USER INTERFACE**

- 52 illustrated procedure pre-sets
- Touch-screen controls
- Greatly simplifies the learning curve

**+ BIOLOGICALLY FRIENDLY DENTISTRY**

- No micro-fractures or thermal damage
- More precise, minimally invasive
- Relies on water and light to cut

**CONTACT US TO LEARN MORE  
ABOUT WATERLASE IPLUS!**

OR VISIT [AMAZEDBYWATERLASE.COM](http://AMAZEDBYWATERLASE.COM) TO VIEW  
INSTANT REACTIONS FROM DOCTORS AND PATIENTS!

**GO TO [BIOLASE.COM](http://BIOLASE.COM) TO FIND  
YOUR LOCAL DISTRIBUTOR.**



©BIOLASE, Inc. All rights reserved. For use by licensed professionals only. BIOLASE, WaterLase, iPlus, and Deep Pocket Therapy with New Attachment are trademarks of BIOLASE, registered in the U.S. and other countries.

FOLLOW US!

f t in YouTube P g | [www.biolase.com](http://www.biolase.com) | +1.949.361.1200

**BIOLASE®**

# Minimally invasive? See for yourself!



Dr Georg Bach

Dear readers of **laser** international magazine of laser dentistry,

Minimally invasive – a buzzword! Overused? Trite? I don't think so.

The almost inflationary application of this term by one or the other dental publication can safely be countered by the honest quest of dentists around the world for new, improved or modified procedures, which are less stressful for the patient, can be performed fast and with good results.

Dental therapy supported by laser light—I hope you don't mind this connecting passage—usually fulfills these demands completely:

Minimal: As a general rule, laser therapy requires less time than conventional techniques which are not supported by laser.

In: Laser therapies are "in", they have an exceedingly positive image and the demand among our patients is high.

And yet, they sometimes are invasive, but thanks to the laser light they result in less pain, less intraoperative bleeding and they usually come with good recovery and healing.

Laser is minimally invasive. See for yourself if my depiction of laser technology holds true on the 23<sup>rd</sup> Annual DGL Congress! Renowned speakers will present an extensive overview on the state-of-the-art of laser dentistry as well as tips for laser application in the daily practice on 15 and 16 November at the Maritim Hotel Berlin, Germany.

I am glad to invite you to this "MUST" in the name of the German Society for Laser Dentistry, which has been the cooperation partner of laser for many years.

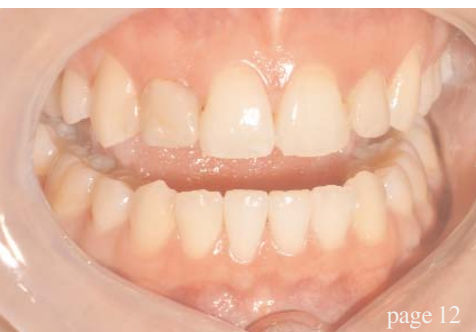By the way, Berlin is always worth a trip!

With this in mind, enjoy reading this issue of **laser** international magazine of laser dentistry.

Warm regards,

Dr Georg Bach

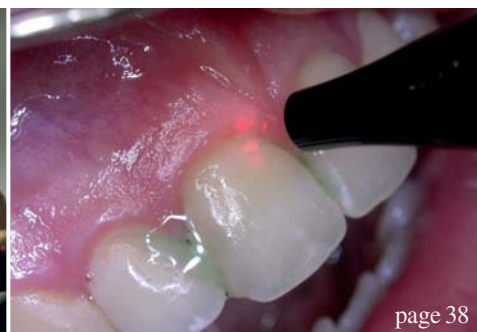



page 12



page 26



page 38

## | editorial

03 **Minimally** invasive? See for **yourself!**

| Dr Georg Bach

## | research

06 **Incision** and **drainage** of a vestibular space **abscess** by **diode** laser

| Dr Wariya Panprasit *et al.*

12 The diode **laser** as an **electrosurgery** replacement

| Dr Glenn A. van As

18 Treatment of aphthous stomatitis using low-level laser therapy

| Pedro J. Muñoz Sánchez *et al.*

## | overview

22 Surgical management of **peri-implantitis** with **laser**

| Prof. Dr Aslan Ya ar Gokbuget *et al.*

## | industry report

26 Diode **laser** application **optimises** the clinical outcomes of **digital workflow**

| Prof. Dr Frank Liebaug *et al.*

30 **Lasers** in **periodontal therapy**: the TwinLight® approach

| Giovanni Olivi *et al.*

34 Treatment of **drug-induced** gingival **enlargement** with Er:YAG **laser**

| Dr Blagovesta Yaneva *et al.*

38 The green **power**

| Dr Darius Moghtader

## | economy

40 Gain **power** at your **laser** clinics!

| Dr Anna Maria Yiannikos

## | interview

44 Ultimately, I wish for laser education to be completely integrated within the school of dentistry, everywhere.

| An interview with Macedonian Professor Ana Minovska

## | meetings

46 **1<sup>st</sup> Meeting** of the **WFLD North American** Division

| Prof. Dr Georgios Romanos

## | news

42 **Manufacturer** News

48 **News**

## | about the publisher

50 | imprint



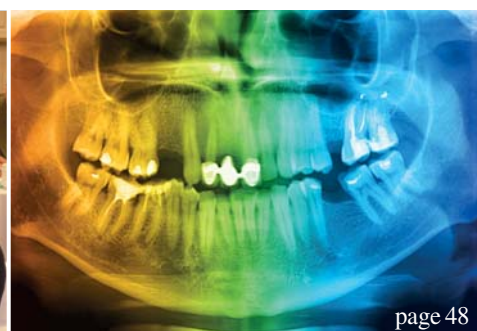
background image: ©Barbol



page 44



page 46



page 48



The first digitally controlled  
dental laser handpiece

## X-Runner

- instantly adjustable spot size and shape
- precise coverage of large areas
- lightweight, ergonomic design
- for Fotona LightWalker AT laser systems

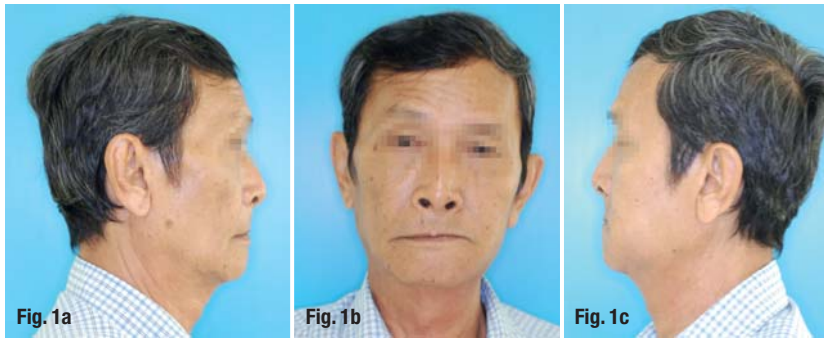

The universe at your fingertips.

• LightWalker<sup>®</sup>

# Incision and drainage of a vestibular space abscess by diode laser

**Authors**\_Drs Wariya Panprasit & Sajee Sattayut, Thailand



**Figs. 1a–c**\_Extra-oral swelling of the left cheek, right side (a); front view (b); and left side (c).

**Fig. 2**\_Intra-oral swelling at the vestibular area of the mandibular left premolar and molar.

**Fig. 3**\_Generalised horizontal bone loss, complicated crown fracture, exposed pulp of the mandibular left first molar.

**Fig. 4a**\_Diode laser incision and drainage. The diode laser (Fotona) with a wavelength of 810 nm.

## \_Introduction

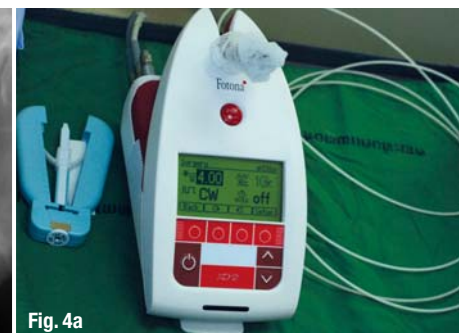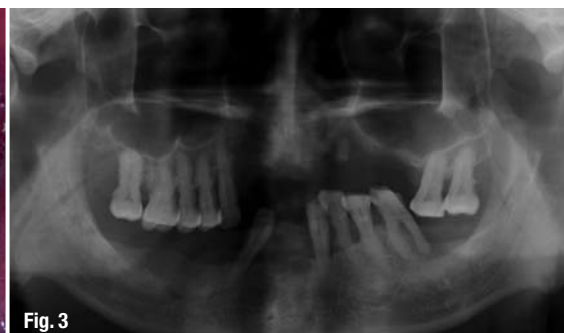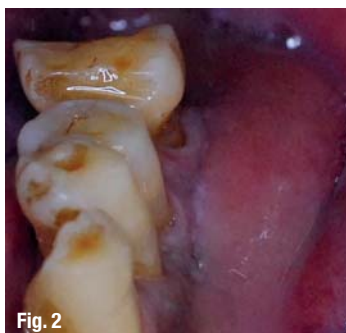Odontogenic infection in the orofacial regions causes tenderness, swelling, limited mouth opening and reduced function. In addition to this, the progressive infection may be life-threatening. The management of odontogenic infections entails rapidly eliminating the cause of infection; performing surgical drainage, which may be as simple as creating endodontic access for the removal of necrotic pulp or as complex as creating a wide incision for open drainage of accumulated pus and necrotic debris; administration of appropriate antibiotics; and supportive physical care. Typically, incision and drainage for the reduction of pus is performed using sharp dissection and retaining a Penrose or rubber tube drain until the

infection has subsided. This normally takes about two to five days, depending on the severity of the infection.<sup>1,2</sup> There are some disadvantages of these procedures: bleeding during operation, the need for suturing, post-operative pain and oedema, early healing due to scar formation and discomfort from the inserted drain.

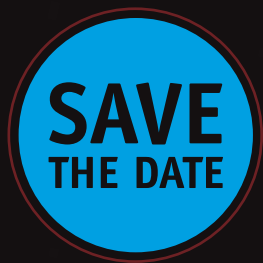The properties of the diode laser provide advantages in soft-tissue surgery, such as producing precise surgical incisions with haemostasis, not requiring suturing, less post-operative swelling and pain, slower epithelial regeneration compared with traditional surgical wounds by producing necrotic tissue, and the promotion of good wound healing.<sup>3–8</sup> Therefore, the diode laser can be used to simplify the surgical phase of odontogenic infection management considerably, as shown in this case report, illustrating the clinical use and efficacy of the diode laser for incision and drainage as a part of the management of intra-oral space abscesses.

## \_Methods of laser incision and drainage

The surgical procedure was performed under local anaesthesia, 2% mepivacaine with 1:100,000 epinephrine. An 810 nm diode laser (320 diameter fibre optic, 4 W, continuous wave) was used to ablate the







NOVEMBER 15–16,  
2013// BERLIN,  
GERMANY//MARITIM HOTEL

# LASER START UP 2013



# 22nd ANNUAL CONGRESS OF THE DGL e.V.



**DOWNLOAD**  
PROGRAMME AND  
REGISTRATION FORM

**PLEASE FAX THIS FORM**  
+49 341 48474-390

Further information about:

☐ LASER START UP 2013    ☐ 22nd ANNUAL CONGRESS OF THE DGL e.V.  
November 15–16, 2013, Berlin, Germany

NAME/E-MAIL

OFFICE STAMP

laser 3/13

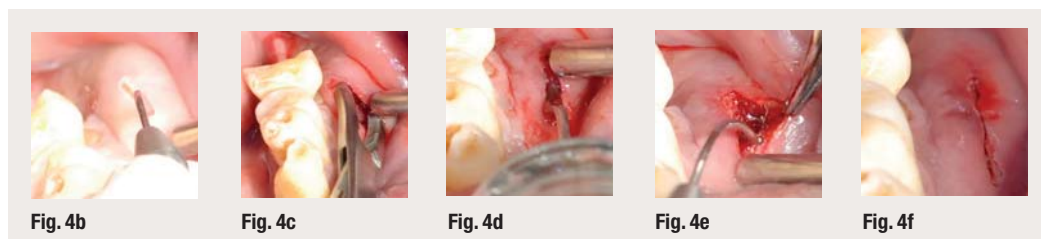
**Fig. 4b** Ablating mucosa with the diode laser; power setting at 4 W, continuous wave.

**Fig. 4c** Blunt dissection using curved artery forceps.

**Fig. 4d** Irrigation with a normal saline solution.

**Fig. 4e** Coagulating the incisional margin with the diode laser; power setting at 2 W, continuous wave.

**Fig. 4f** Finishing the surgical treatment without bleeding, suturing or a drain.



tissue from the most fluctuated oral mucosal area through the submucosal layer without perforating the periosteum, creating an incision of 1.5–2 cm in length.

Then, blunt dissection was performed. After irrigation with a normal saline solution, the incisional margins and submucosal layers were coagulated using the diode laser at 2 W, continuous wave. This aimed at maintaining soft-tissue tunnelling for pus drainage without placing sutures and inserting a drain. Amoxicillin, metronidazole, paracetamol and 0.12% chlorhexidine mouthwash were prescribed. Three cases of vestibular space abscess were treated.

### Case 1

A 65-year-old male patient presented to the Department of Oral and Maxillofacial Surgery of the Faculty of Dentistry at Khon Kaen University in Thailand with swelling of and pain in the left cheek that had lasted for one day. The left submandibular lymph node was tender and movable with a diameter of 0.5 cm (Figs. 1a–c). The patient had normal mouth opening and the buccal vestibule of the mandibular left posterior teeth was swollen. It was soft in consistency, with normal mucosal colour and texture. There was a partial fracture of the mandibular left first molar, exposing pulp (Fig. 2). The tooth mobility was Grade I. In the radiographic examination, the panoramic radiograph (Fig. 3) showed that there was furcation involvement in the mandibular left first molar, with total bone loss of the distal root with a circumscribed periapical radiolucency of 2 x 4 mm in size, and 20% bone loss of the mesial root. Other significant findings from the radiographic examination included 50% horizontal bone loss of the mandibular left canine and premolars, extrusion of the maxil-

lary left second and third molars, generalised bone loss with subgingival calculus of the maxillary right canine and premolars, normal condylar shape and position, and normal density of the maxillary antrum. The case was diagnosed as a vestibular space abscess secondary to a complicated crown fracture of the mandibular left first molar. The treatment was a combination of diode laser incision and drainage under local anaesthesia (Figs. 4a–f), extraction of the mandibular left first molar and antibiotic administration.

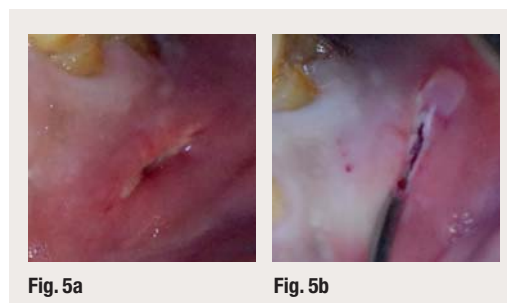On day three after treatment, there was clinical improvement and the infection had subsided. The drainage via the laser incision remained intact. Irrigation with a 0.9% normal saline solution was carried out (Figs. 5a & b). Then, the mandibular left first molar was removed by a simple extraction technique under local anaesthesia.

### Case 2

A 21-year-old female patient presented with swelling and pain in the region of the maxillary anterior teeth that had lasted for two days. She was undergoing orthodontic treatment. The extra-oral examination found a mild swelling of the philtrum. The intra-oral examination found a swelling of 1 x 2 cm in size at the labial gingiva, extending to the vestibule, that was soft in consistency, with tenderness on palpation. There were large tooth-coloured material fillings at the mesial surfaces of the maxillary left and right central incisors. The restorative filling of the maxillary right central incisor was significantly discoloured (Fig. 6a). The periapical film showed a well-circumscribed periapical radiolucency at the right central and lateral incisors of 1 x 1 cm in size and at the left central incisor of 0.3 x 0.3 cm in size (Fig. 6b). A vestibular space abscess was diagnosed. The treatment plan entailed root-canal treatment for the maxillary right incisors and the maxillary left central incisor, diode laser incision and drainage of the vestibular space abscess, and antibiotic administration. Diode laser incision and drainage (Fig. 6c) were performed at the first visit and antibiotics were administered. The patient presented again for follow-up visits one day and three days post-treatment. On day five after the operation, the incisional wound had almost completely healed and

**Fig. 5a** Laser incision with a thin coagulum three days post-treatment.

**Fig. 5b** Irrigation at the area of laser incision with a normal saline solution.





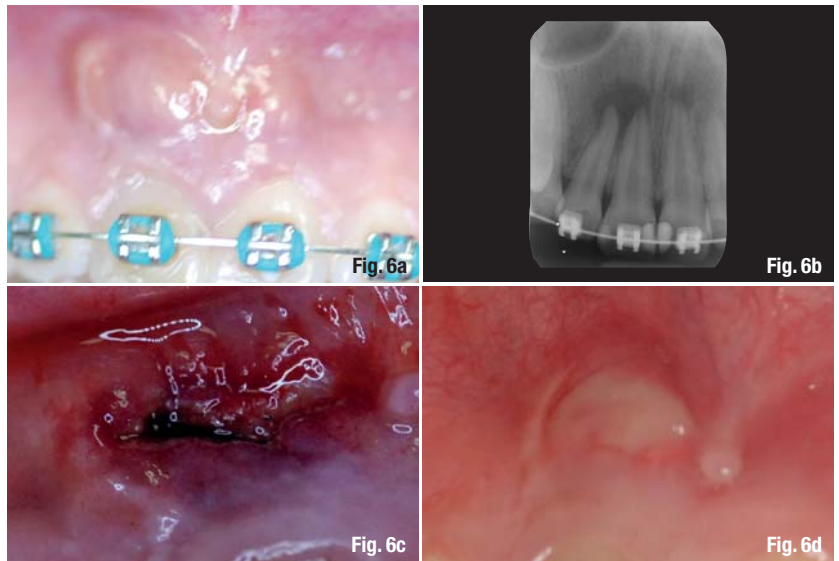
irrigation was not required (Fig. 6d). The clinical symptoms had resolved completely.

### Case 3

A 27-year-old male patient presented with swelling and pain in the left cheek that had lasted for three days. The extra-oral examination findings were clinically within normal limits. The intra-oral examination found both swelling and shallowing of the vestibule of the mandibular left premolars and the first molar. There was an extensive carious lesion with pulpal exposure of the first molar (Fig. 7a).

The panoramic radiograph showed a well-circumscribed periapical radiolucency at the mandibular left first molar (Fig. 7b). The diagnosis was a vestibular space abscess. The treatment plan was the same as that of case 2. At the first visit, diode laser incision and drainage were performed (Fig. 7c) and antibiotics were prescribed. On day three after the operation, the laser wound was covered with a thin coagulum and irrigation could be performed (Figs. 7d & e).

Clinical symptoms, such as swelling and tenderness, had decreased. On day six after laser incision and drainage, all clinical symptoms had resolved



completely. A small opening remained in the laser wound for irrigation (Fig. 7f).

### Discussion

When the blunt dissection was performed, the cases presented showed infection only in the superficial areas at a depth of less than 3 cm. In comparison with other types of lasers, such as the carbon dioxide,

**Fig. 6a** Vestibular space abscess of the maxillary incisors.

**Fig. 6b** Periapical film showing periapical radiolucencies of the maxillary incisors.

**Fig. 6c** Immediately post-treatment with diode laser incision and drainage.

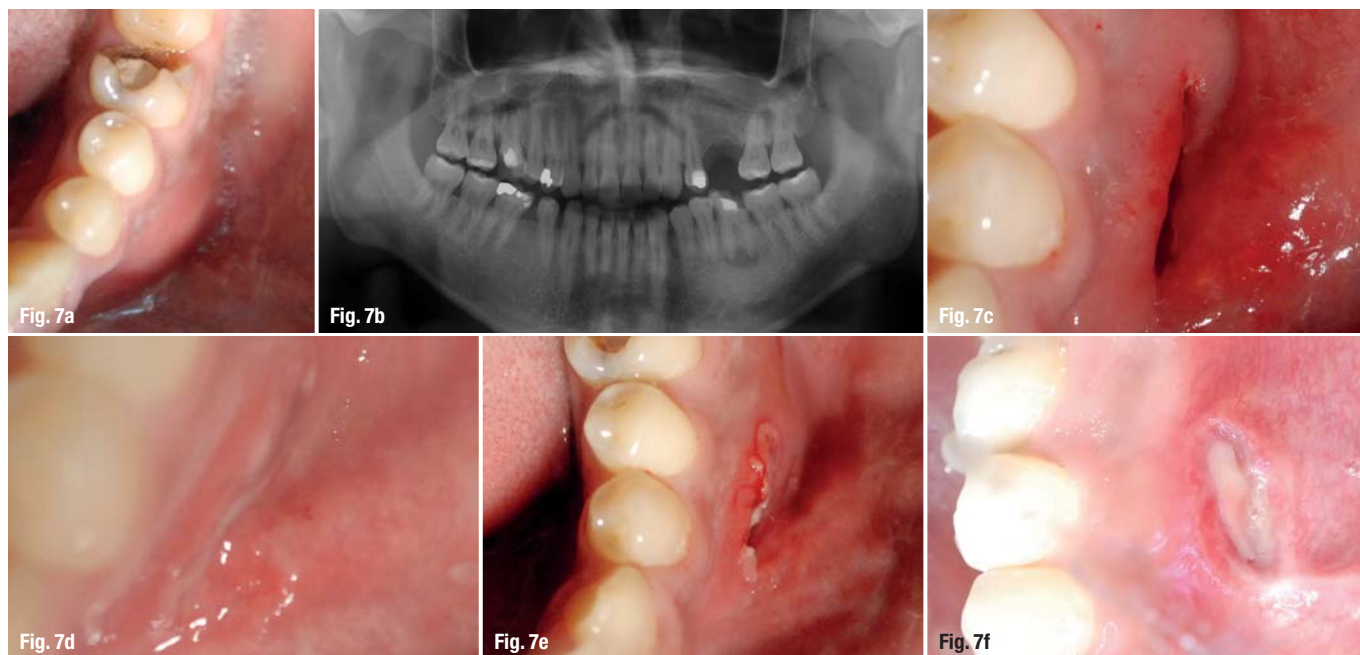
**Fig. 6d** Laser wound on day five post-treatment.

AD

*become an author  
for "laser"*



Please contact Claudia Jahn  
✉ c.jahn@oemus-media.de



**Fig. 7a**\_Swelling extending from the premolars to the first molar.

Fig. 7b: Panoramic view.

**Fig. 7c**\_Immediately post-treatment with diode laser incision and drainage.

**Fig. 7d**\_Laser wound on day three post-treatment.

**Fig. 7e**\_After irrigation with a normal saline solution on day three post-treatment.

**Fig. 7f**\_Laser wound on day six post-treatment.

Nd:YAG and Er:YAG laser, the diode laser shows less water absorption, as well as moderate haemoglobin and melanin absorption. Therefore, this laser can provide moderate cutting with reasonable laser coagulation.<sup>3, 5, 9</sup> This enabled us to minimise initial bleeding on operation and delayed wound healing, thus allowing for the drainage of pus and exudate without requiring suturing and the insertion of a drain.

Regarding diode laser wound healing, Camillo et al. compared the wound healing of incisions made by scalpel and by a 808 nm diode laser at 4 W and 6 W in the oral tissue of rats.<sup>4</sup> They found the same level of inflammation and complete wound healing at 14 days in the scalpel and diode laser at 4 W groups, while inflammation in the diode laser at 6 W group was worse and took more than 14 days to heal completely. Therefore, they recommended a power setting of no more than 4 W for the diode laser when cutting soft tissue. Jin et al. studied wound healing in the buccal mucosa of guinea pigs following incision by diode laser compared with incision by scalpel.<sup>10</sup> They found that the diode laser was a good cutting device, but it resulted in more tissue damage and greater inflammation than the scalpel did in a period of five days post-treatment. After that period, there was no difference between the diode laser wound and the scalpel wound. Complete healing was observed 14 days post-treatment in both groups. In this case report, we used power settings of 4 W for ablation and 2 W for tissue coagulation. Wound healing was observed within no more than 14 days. Therefore, the results were considered to be similar to those of the studies mentioned.

## \_Conclusion

Incision and drainage by diode laser for ablation and coagulation were successful in treating vestibular space abscesses within a depth of 3 cm. The coagulative zone of the incision created by the diode laser provided adequate drainage without the need for inserting a drain. It is recommended that further studies be conducted on the treatment of odontogenic infection involving one or two spaces with a depth of 3–5 cm with diode laser incision and drainage without placing a rubber drain. The duration of wound healing in relation to clinical symptoms could also be observed in future clinical studies.

## \_Acknowledgement

The authors wish to thank Ms Pissamai Wijarn, as well as the staff of the Oral and Maxillofacial Surgery clinic in the Faculty of Dentistry at Khon Kaen University, and the OPD Department of Hospital Dentistry at Khon Kaen University.

## \_contact

## laser

### Dr Sajee Sattayut

Associate Professor of Oral Surgery  
Department of Oral and Maxillofacial Surgery  
Lasers in Dentistry Research Group  
Faculty of Dentistry  
Khon Kaen University, Khon Kaen,  
40002 Thailand

+66 43 202405  
sajee@kku.ac.th



# Master of Science (M.Sc.) in Lasers in Dentistry

Batch: EN2014 - Fulltime (new) or Module based

**Next Start: 22 September 2014**

**Aachen, Germany**

**4 semesters**



## Become part of the International Dental Elite

- Create new economic potential for your practice
- Two year career-accompanying postgraduate programme at the University of Excellence RWTH Aachen
- Combination of lectures, skill training sessions, live ops, tutorials, and practical workshops
- Internationally accepted and accredited by the German Government, the European Union, the Washington Accord and the Bologna Process
- Science-based and practice-orientated on highest national and international level
- Increased patient satisfaction: minimal contact reduced vibration and pain



**RWTH INTERNATIONAL  
ACADEMY  
AACHEN UNIVERSITY**

RWTH International Academy  
Kackertstraße 10 | 52072 Aachen | Germany  
phone +49 241 80 23543 | fax +49 241 80 92525  
info@academy.rwth-aachen.de  
www.academy.rwth-aachen.de

**PROFESSIONAL EDUCATION PROGRAMMES**

**AALZ**

**Aachen Dental Laser Center**

AALZ GmbH  
Pauwelsstraße 17 | 52074 Aachen | Germany  
phone +49 241 47 57 13 10 | fax +49 241 47 57 13 29  
info@aalz.de  
www.aalz.de



# The diode laser as an electrosurgery replacement

Author\_Dr Glenn A. van As, Canada

## \_Introduction

In 2008, Dr. Gordon Christensen wrote an article in JADA comparing the soft tissue cutting abilities of diode lasers to those of electrosurgery (radio-surgery) units.<sup>1</sup> In comparing these two technologies against each other, he found that both dental lasers and the less expensive electrosurgery units have advantages and disadvantages, and he summarized with several key points:

1. Although, there was considerable overlap in their uses and both technologies were effective, Christensen found that diode lasers were able to be used around metal (amalgam and gold) as well as with dental implants.
2. He stated that lasers did not harm dental hard tissues (bone) or soft tissues (pulp), and that the clinician could use the laser with less anesthetic, and finally he mentioned that lasers were antimicrobial (antibacterial).
3. The acceptance and use of lasers, especially the diode laser, was increasing in dentistry, and that

lasers attract patients because of their recognized and accepted role within the field of medicine (LASIK eye surgery).

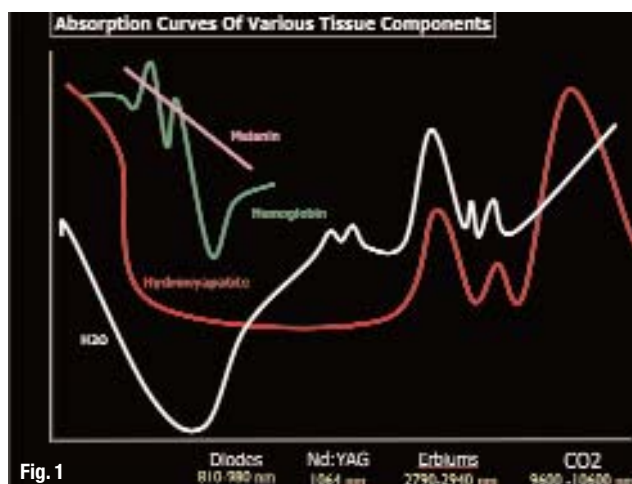
4. Electrosurgery units were "far less expensive than the least expensive diode lasers" and he questioned whether "the advantages of the diode laser were significant enough to compensate for the additional cost."

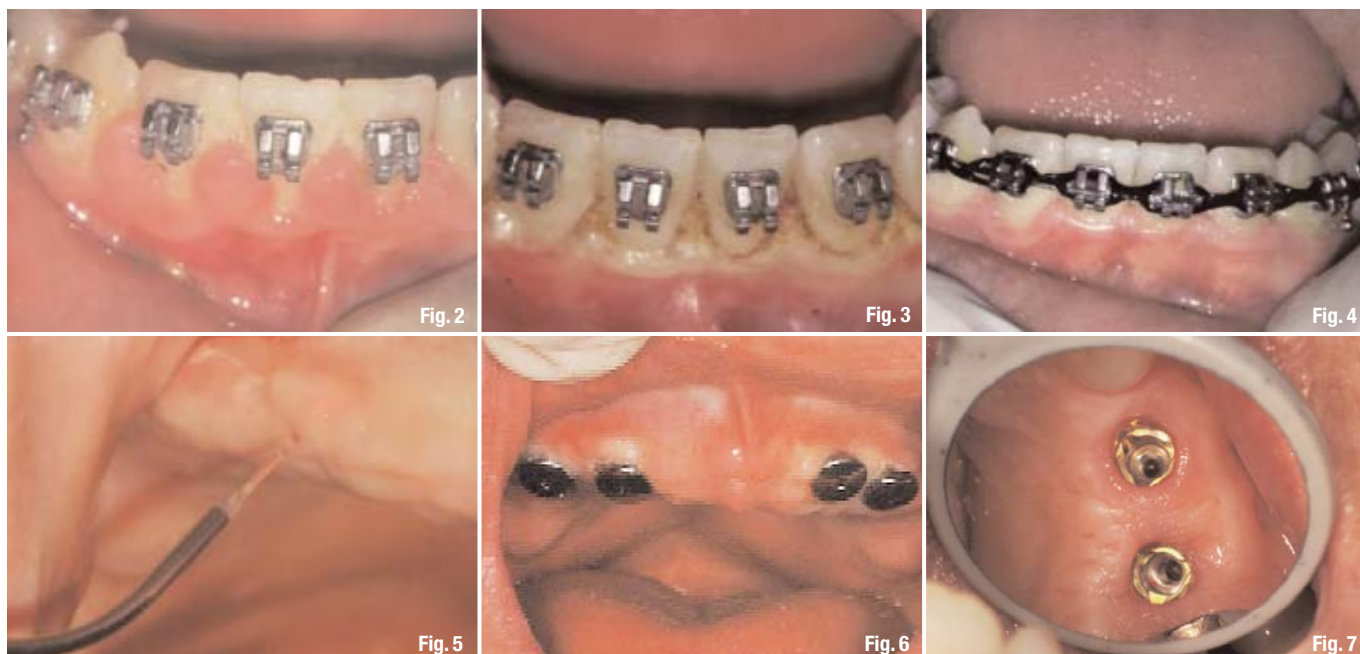
There are two basic types of electrosurgical units that can be purchased in dentistry:

- Monopolar, in which a single electrode exists and the current travels from the unit down a single wire to the surgical site. The patient must be grounded with a pad placed behind the patient's back (a part of the procedure that many patients may question). Heat is produced when the electrode contacts the tissue, and due to pain that is produced, anesthetic must be used.
- Bipolar, in which two electrodes are placed in very close proximity to each other. Bipolar units are more expensive than diode lasers and the electrical current flows from one electrode to the other, thus eliminating the need for a grounding pad. Bipolar units, because of the two wires, create less of a precise cut than the monopolar or diode laser.

Although electrosurgical units are inexpensive, require no safety glasses and can remove large amounts of tissue quickly, diode lasers have become much more common in dental operatories in the four years since Christensen's article was published. The primary reasons for their increased popularity are that diode lasers have a small footprint, are reliable and durable lasers, and are portable. Where a few short years ago, diode lasers could cost in the range of \$10,000 to \$15,000, they are now cost effective and can be purchased for less than \$2,500.

**Fig. 1** Absorption curve of various tissue components shows diode lasers to be well absorbed in melanin (pigment), hemoglobin and to some degree water. (Images/Provided by Glenn A. van As, BSc, DMD)





## Advantages of diode lasers over electrosurgery

### *Ability to work around metals intraorally*

Diode lasers in the range of 810–1,064 nm are well absorbed in hemoglobin, melanin (pigment) and to some degree water (Fig. 1). These mid infrared dental wavelengths in the absorption spectrum offer the dental clinician the ability to ablate soft tissues precisely while controlling hemostasis, providing the clinician with an excellent view of the surgical site with a reduced reliance on sutures. Diode lasers have features that make them attractive as mentioned earlier, but they also have several advantages in function over electrosurgical units<sup>2</sup> (Table 1). Perhaps the greatest benefit of these lasers is that they allow the clinician to work safely around metals. The literature has shown that monopolar electrosurge units can accidentally create catastrophic results when touching metal intraorally. Published reports have shown that contact for very short periods of time with the electrode of a monopolar electrosurgical unit can cause both pulpal and periodontal problems,<sup>3</sup> bone loss,<sup>4</sup> severe intraoral burns,<sup>5</sup> arcing, and that within three seconds of exposure to a dental implant electrosurgical units can cause failure of osseointegration and loss of an implant.<sup>6,7</sup> In clinical practice, with today's emphasis on the more esthetically pleasing composite resins and newer porcelains, there are still many metallic materials used intraorally, including cast partial denture frameworks, gold, amalgam, orthodontic brackets and semi-precious alloys. Diode lasers, unlike their electrosurgical counterparts, show little interaction with metallic objects used intraorally. It is important to

remember that due to the laser's ability to reflect off mirrored surfaces and potentially cause eye damage, that all members of the dental team as well as the patient must wear laser safety glasses for eye protection if they are within the nominal ocular hazard zone (NOHZ) during laser operation. This zone is most often between 3 and 7 feet, but some diodes can have extended NOHZ ranges of 40 feet. Orthodontic patients will often exhibit gingival hyperplasia when in brackets that can make it difficult to work on them. This overgrowth of tissue can be due to poor oral hygiene, space-closing mechanics, excess cement or a combination of factors. The diode laser can be used for gingivectomies to safely remove and recontour the excess tissue and healing can be remarkable in a very short period of time (Figs. 2–4).

**Fig. 2** Gingival hyperplasia around orthodontic appliances.

**Fig. 3** Immediate post-op after diode laser gingivectomy completed.

**Fig. 4** Eight-day healing of soft tissue around brackets.

**Fig. 5** Diode laser for second-stage implant uncovering in edentulous maxilla.

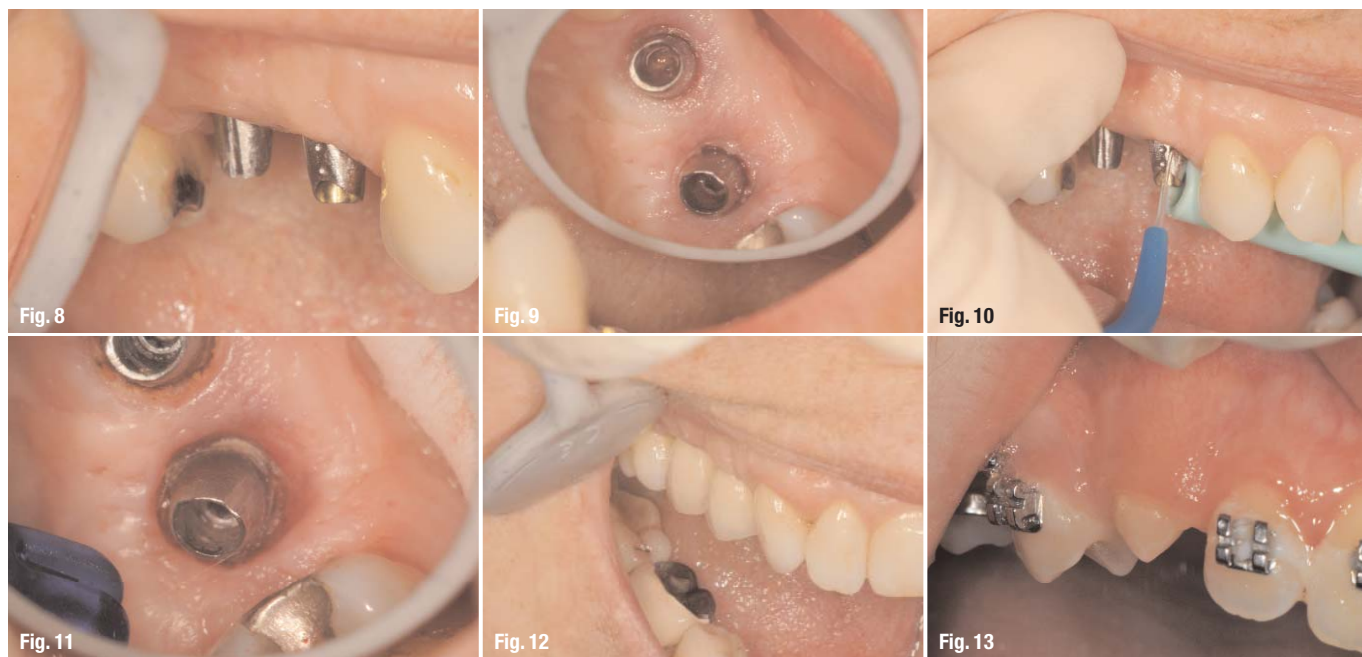
**Fig. 6** Four healing cuffs in place in maxilla immediately after uncovering with the diode laser.

**Fig. 7** Replace select implant fixtures for upper right premolars.

**Table 1** Comparison of diode laser versus monopolar electrosurgery units.

Diode Laser vs Electrosurgery		
Feature	Electrosurgery	Diode Lasers
Work around Metals	No - causes sparks, pulp death etc.	Yes and safe.
Proximalizers	No cannot be used.	Yes can be used
Anesthetic	Local Anesthetic needed	Sometimes topical only
Antibacterial	No antibacterial qualities	Yes kills bacteria.
Lateral Thermal damage	Can cause recession when used.	Less Likely to cause recession.
Uses	Good for large tissue removal	Multiple uses as seen today.

Table 1



**Fig. 8\_** Abutments in place for both teeth.

**Fig. 9\_** Soft tissue on margins preventing full seating of crowns.

**Fig. 10\_** Picasso Lite diode laser removing tissue on abutment margins.

**Fig. 11\_** Note tissue off the margins of abutments after diode use.

**Fig. 12\_** Final crowns cemented onto abutments without soft tissue impingement.

**Fig. 13\_** Partially exposed canine requires orthodontic bracket.

#### *Ability to work around dental implants safely*

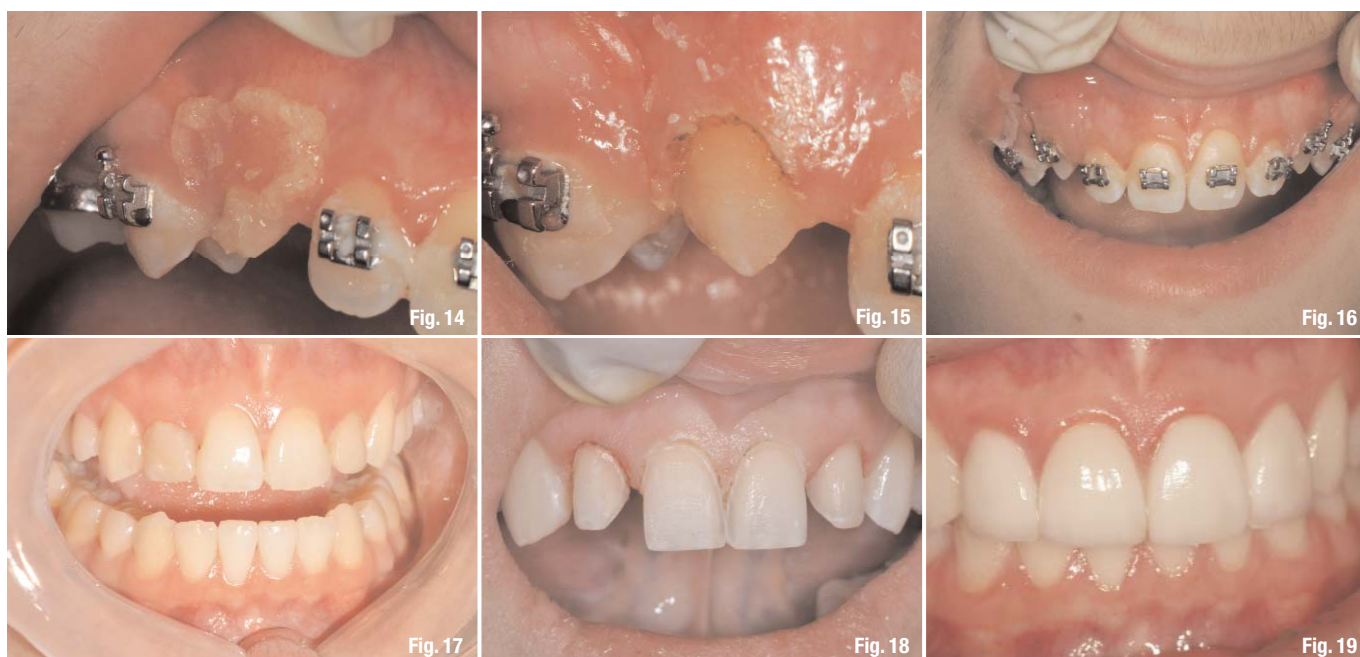Various laser wavelengths that are available today can offer the clinician who needs to expose an implant during second stage surgery an alternative to traditional methodologies. The ability of the diode laser to ablate tissue, at times without the need for local anesthetic, while controlling hemostasis, provides the clinician a great view of the surgical site. In addition, the diode wavelength, like all laser wavelengths, provides for decontamination of the implant site through its antibacterial actions. Bacterial reduction with the diode laser can lead to an almost sterile operative field (98 per cent reduction of pathogenic bacteria). Finally, there is a growing body of evidence that suggests that lasers used at lower energy settings can have a biostimulatory effect on tissue which in turn can reduce postoperative discomfort, improve healing and shorten healing times while even improving early osseointegration.<sup>8-12</sup> As an aside, there have been clinicians who routinely use monopolar electrosurgery units to expose implants. It is imperative to realize that although more expensive bipolar (two electrodes) electrosurgery units can be used safely around implants, that the more commonly purchased single electrode (monopolar) units may damage the implant surface and can cause complete loss of osseointegration with resulting implant failure with contact times as short as three seconds.<sup>13,14</sup> Lasers, in contrast, can be used safely with tremendous coagulation and a reduction in pain postoperatively for the patient<sup>15</sup> (Figs. 5 & 6) Diode lasers are also useful when it comes time to seat the final abutment and restoration. Tissue management around dental implant restorations can be difficult, be it for the initial cementation or, even worse, if an implant-re-

stored crown comes loose. Tissue quickly slumps onto the abutment, and subgingival margins can be almost impossible to retrieve with traditional methodologies. The laser can truly be a "life-saver" for these situations where soft tissue must be safely and quickly removed to allow for ideal cementation of the implant retained crowns onto the abutments (Figs. 7-12).

#### *Reduced need for anesthetic*

Monopolar electrosurgery units do not have the ability to be used routinely without local anesthetic. In contrast, diode lasers can often be used either with low wattages or in pulsed modes to remove minor to moderate amounts of soft tissue with only topical anesthetics. Although at times this may not seem significant to the clinician, there are many instances where soft tissue acts as a barrier to ideal restorative treatment, and if local anesthetic can be eliminated it becomes a big selling point to patients. Many patients are looking for alternatives to local anesthetic, and when the occasion allows for the procedure to be completed without the patient being numb, the overwhelming majority of patients are grateful for this. Situations such as laser gingival crown troughing for tissue management around endodontically treated teeth, exposure of partially erupted canines for orthodontic brackets and gingivectomies around moderately sized Class V lesions in geriatric patients are all situations where the author has been able to routinely and consistently complete soft tissue ablation with only a stronger topical anesthetic. In fact, the literature has shown that a variety of soft tissue procedures (even frenectomies) can be completed on with only topical anesthetic<sup>16-18</sup> (Figs. 13-16).





#### *Ability to do gingivectomies and crown troughing with less recession*

White et al have mentioned that laser gingivectomies are the most common soft tissue procedure done with diode lasers<sup>19</sup>, and when combined with esthetic porcelain restorations the simple recontouring of tissue can take a good case and make it great.<sup>20–24</sup> A key difference from electrosurgery ablation of soft tissue is that alterations to the symmetry of the soft tissue contours in the maxillary anterior teeth can be safely and precisely completed on the same day as the preparation and impressions of these teeth. The risk of recession and exposure of margins can be far less with a diode laser than with other techniques, particularly when adequate magnification (e.g., 4.0X loupes) and cautious settings (0.6–0.9 W continuous wave) are used for the recontouring. When biologic width is respected, and adequate attached and keratinized tissue exists, then judicious recontouring of the gingiva on the same day as the preparations can yield stunning results (Figs. 17–19). The diode laser has become a popular technology as an alternative for tissue management compared to the traditional methodology of placing a single or double retraction cord in the sulcus. The diode laser can be used in almost all instances to produce gingival retraction as an alternative to cord with excellent results both in terms of gingival retraction and margin delineation for the laboratory. Unlike electrosurgical units where recession can be an issue, as can postoperative pain, diode lasers offer the clinician the ability to precisely remove overhanging, inflamed tissue while creating a gingival trough that is not likely to cause damage to bone, cementum or pulp tissue like electrosurgical units can. In addition, there is research that suggests that the

lateral thermal damage done with lasers is significantly lower than that with electrosurgery.<sup>25</sup>

#### *Ability to photocoagulate vascular lesions and treat oral lesions*

One of the advantages of a diode laser is the ability to treat oral lesions, including: recurrent aphthous ulcers (RAU), venous lake lesions of the lips, and herpetic lesions. Research has shown that lasers can be safely used to treat these lesions<sup>26–28</sup>, and in addition it is possible that if caught early during the prodromal stage that herpetic lesions can be aborted or significantly reduced in terms of length of time they are present.<sup>29</sup> In addition, it has been the author's experience that, once treated with the laser, the lesions are often less likely to reappear in the same area. In fact some evidence suggests that herpetic lesions treated in the early stages with the diode laser can cut the healing time in half and create a remission period that is twice as long before it reoccurs.<sup>30,31</sup> Vascular lesions called venous lakes or hemangiomas can occur on soft tissue areas including the upper and lower lips, buccal mucosa and palate. These lesions can be difficult to treat with traditional methods where significant bleeding may occur. The diode wavelengths are rapidly absorbed by hemoglobin and therefore can be used to coagulate and eradicate these esthetically undesirable purplish lesions often with only topical anesthetic. Literature has shown that the diode can be used in almost 100 per cent of cases to eliminate these lesions, most often in only a single session lasting only a couple of minutes<sup>32–35</sup> (Figs. 20–22).

#### *Anti-bacterial capabilities of lasers*

Many articles in the literature have demonstrated the tremendous ability of all lasers with re-

**Fig. 14**\_Topical gel placed on soft tissue prior to gingivectomy to uncover soft tissue.

**Fig. 15**\_Pulsed mode at 1.4 W shows removal of attached tissue to expose canine.

**Fig. 16**\_Brackets in place on both canines — immediate post-op view.

**Fig. 17**\_Pre-op prior to maxillary incisor veneers.

**Fig. 18**\_After recontouring of lateral incisors and laser crown troughing for tissue management prior to impressions.

**Fig. 19**\_Immediate postoperative result for four e.max veneers.

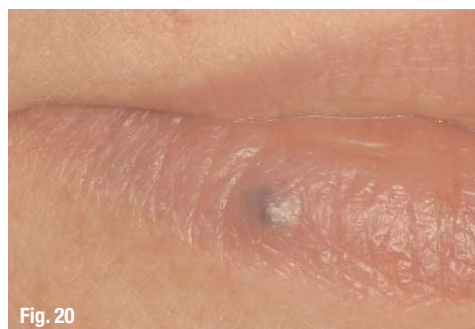

Fig. 20

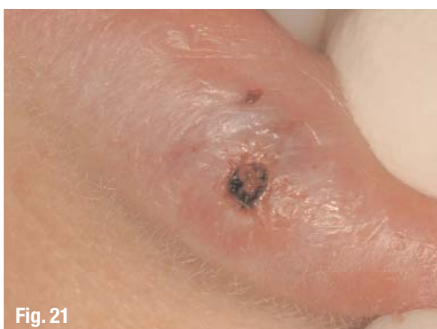

Fig. 21

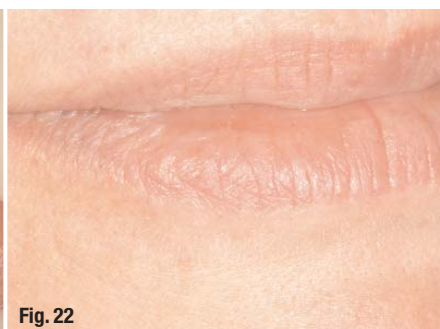

Fig. 22

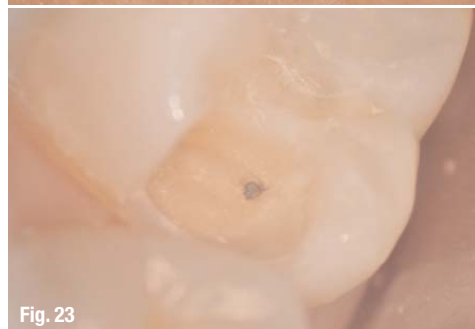

Fig. 23

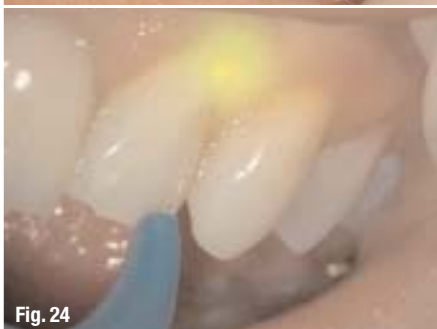

Fig. 24

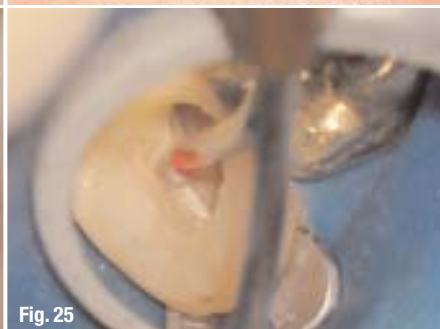

Fig. 25

**Fig. 20** Pre-op view of venous lake on lower lip.

**Fig. 21** Immediate post-op appearance.

**Fig. 22** Two-week healing of lesion on lip is complete.

**Fig. 23** Diode direct pulp cap to lower bacteria count on MO cavity preparation.

**Fig. 24** Diode laser in gingival sulcus lowering bacteria count (image of diode pulse captured with video camera on operating microscope — typically the image is not visible to the human eye).

**Fig. 25** Diode laser used to reduce bacterial counts inside a DB canal of upper right second molar after completion of instrumentation and prior to obturation of the canals.

spect to the reduction of bacterial and even fungal infections.<sup>36–43</sup> The excellent antibacterial capabilities make lasers effective and desirable in many areas in the oral cavity where the risk of postoperative infection may be reduced. Electrosurgical units do not typically possess the same ability to provide bacterial reduction as lasers do. Particular interest is now occurring with the role of lasers in endodontic, periodontic and peri-implantitis cases where the need to reduce bacterial loads without such a great deal of reliance on antibiotics might be exciting. Although more research is needed on how the bactericidal capabilities of the diode laser might be beneficial in these areas, there is no debating that all lasers can help healing through decreasing the risk of infection through laser light alone (Figs. 23–25). In addition, growing research has demonstrated that the risk of high bacterial loads in periodontal pockets and in particular in endodontic situations may be reduced by lasers. These newer articles have implications for improving traditional methodologies locally where used, and in helping to reduce the potential greater systemic health risks generally. The role of lasers continues to be researched today, but present research has shown that diode lasers can be used safely within root canals with minimal fear of developing iatrogenic complications when conservative settings are used.<sup>44–48</sup>

## Conclusion

The diode laser has become the “soft tissue hand-piece” in many dental offices. The advantages of being able to work around metals including dental implants, a reduced need for anesthetic, a reduced risk of recession postoperatively, the ability to reduce bacteria, and to use the diode to photocoagulate vascular lesions

have all provided dentists with a new alternative for soft tissue surgery. Lasers have two added benefits in that they do not require a pad to be placed under the patient for grounding, and they can be used safely with pacemakers. Diode lasers have found their place in dentistry. Once considered an application looking for a purpose, these small, cost-effective and reliable lasers have discovered their niche as the new go-to solution for many soft tissue problems in our daily dental practices.

## author

## laser



**Glenn A. van As, BSc, DMD**, is the clinical director of the International Center of Laser Education at AMD Lasers (DENTSPLY), and is a founding member of the Academy of Microscope Enhanced Dentistry and a former president of the group. He has obtained standard and advanced proficiency as well as a mastership in laser dentistry from the Academy of Laser Dentistry and was distinguished with the Leon Goldman award for worldwide clinical excellence in the field of laser dentistry in 2006. An expert both in the utilization of the dental operating microscope for clinical dentistry and in the utilization of multiple wavelengths of hard- and soft-tissue lasers, he has lectured and provided workshops internationally more than 450 times on these topics. He acts as a consultant for several companies and reviews articles for PPAD and Dentaltown. He may be contacted at [glennvanas@me.com](mailto:glennvanas@me.com).

obtained standard and advanced proficiency as well as a mastership in laser dentistry from the Academy of Laser Dentistry and was distinguished with the Leon Goldman award for worldwide clinical excellence in the field of laser dentistry in 2006. An expert both in the utilization of the dental operating microscope for clinical dentistry and in the utilization of multiple wavelengths of hard- and soft-tissue lasers, he has lectured and provided workshops internationally more than 450 times on these topics. He acts as a consultant for several companies and reviews articles for PPAD and Dentaltown. He may be contacted at [glennvanas@me.com](mailto:glennvanas@me.com).

*Editorial note: A list of references is available from the publisher.*



# CROIXTURE

PROFESSIONAL MEDICAL COUTURE



EXPERIENCE OUR ENTIRE COLLECTION ONLINE

[WWW.CROIXTURE.COM](http://WWW.CROIXTURE.COM)



# Treatment of aphthous stomatitis using low-level laser therapy

**Authors** \_Pedro J. Muñoz Sánchez, Cuba, José Luis Capote Femenias, Cuba & Jan Tunér, Sweden

[PICTURE: ©MATHAGRAPHS]

## \_Introduction

Aphthous stomatitis has been investigated to a great extent; however, the aetiology of these lesions is still to be identified accurately. Recurrent aphthous stomatitis is considered a chronic illness accompanied by painful oral ulcers that reappear with irregular frequency.

The following categories have been described:

- smaller aphthous ulcers (80–85% of cases; of a diameter of 1–10 mm; healing spontaneously in seven to ten days);
- larger aphthous ulcers (Sutton's disease; 10–15% of cases; of a diameter larger than 10 mm; healing spontaneously within ten to 30 days or more; may leave a scar); and
- herpetiform ulcers (5–10% of cases; multiple clusters of lesions of a diameter of 1–3 mm, which can coalesce into larger erosions; healing in seven to ten days).<sup>1</sup>

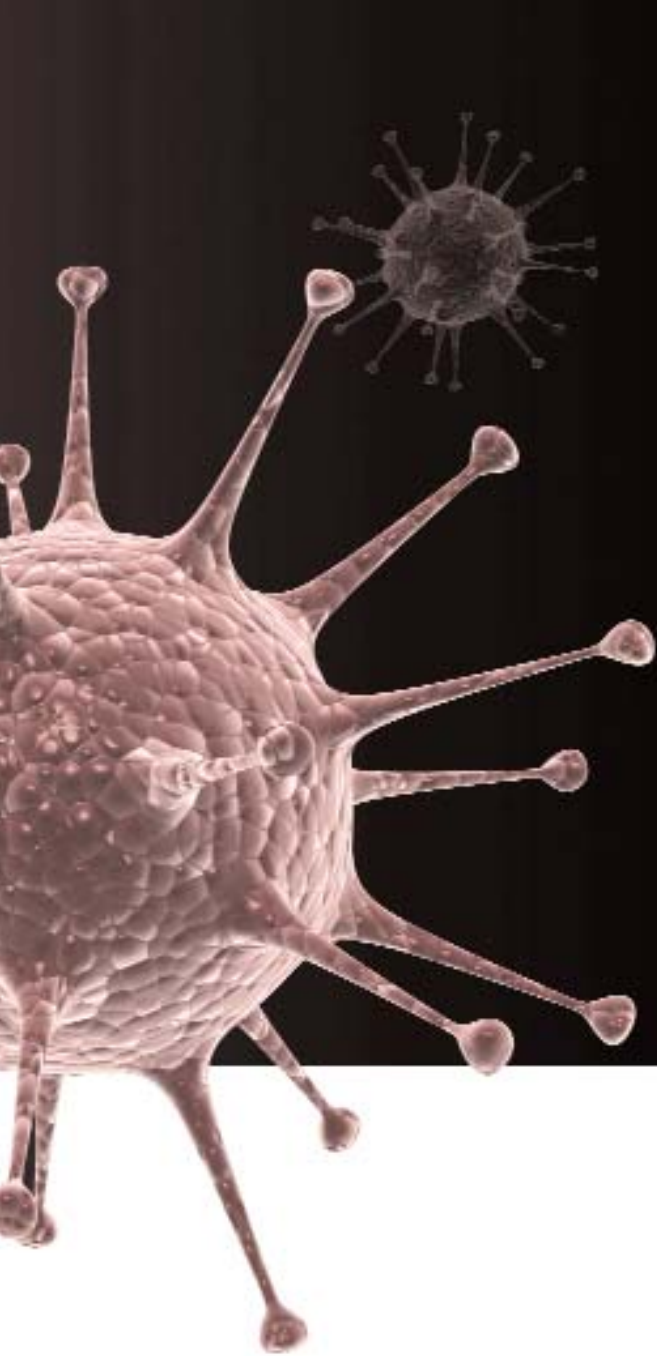
The predisposing factors of recurrent aphthous ulcers are speculative; among them are trauma, emotional stress, coeliac disease, hormonal changes, hypersensitivity to certain foods, allergic reactions and intoxications.<sup>1</sup> It is believed that aphthous stomatitis affects 20% of the US population

and studies have demonstrated a worldwide prevalence of 31–66%.<sup>2</sup> It is important to highlight that the diagnosis of aphthous stomatitis is primarily clinical and should be differentiated from systemic conditions, such as coeliac disease, Crohn's disease, herpes simplex virus Type I, Reiter's syndrome, syphilis, systemic lupus erythematosus, T cell disorders, chicken pox and B6 deficiency.<sup>3–7</sup>

The benefits of local therapies have been demonstrated with anaesthetics and corticosteroids, applied in prodromal stages or in early stages of the lesions. When treating with systemic steroids, it is important to consider the course of the ulcer.<sup>8–21</sup> According to reports from Cuba, treatment with low-level laser therapy (LLLT) is effective, achieving rapid relief of pain, quicker wound healing and lower frequency of recurrence.<sup>22–24</sup> The aim of the present clinical unblinded study was to evaluate the prevalence of aphthous stomatitis in various age groups, as well as the effect of LLLT in the treatment of aphthous stomatitis.

## \_Material and methods

An experimental study was carried out in patients with a clinical diagnosis of aphthous stom-



atitis attending the Leonardo Fernández Sánchez dental clinic in Cienfuegos in Cuba between September 2010 and March 2011. Among the 252 patients registered, 208 attended the clinic until the lesions had healed completely. The study was approved by the Scientific Council of the University of Medical Sciences, Cienfuegos. All of the patients were informed about the parameters of the study and gave their informed consent.

LLLT was administered to 104 patients (study group) and the remaining 104 (control group) received conventional treatment, such as topical anaesthetics (2% lidocaine), dietary advice and oral painkillers. Every second patient with the same type of ulcer was allocated to either the study or the control group. The two groups consisted of 56 males and 148 females, with a great variation in age distribution (Table 1).

All of the patients were seen daily and the patients in the study group received LLLT every second

day unless their ulcer had already healed. The patients were categorised with regard to age and ulcer type (Tables 1 & 2). Special diagnostic procedures were performed in patients with large ulcers to confirm a safe differential diagnosis. Pain was evaluated, but since pain is subjective, it was decided only to register the time until wound closure (Fig. 1), which can be registered objectively. No patient in the study group reported any negative effects of the laser irradiation.

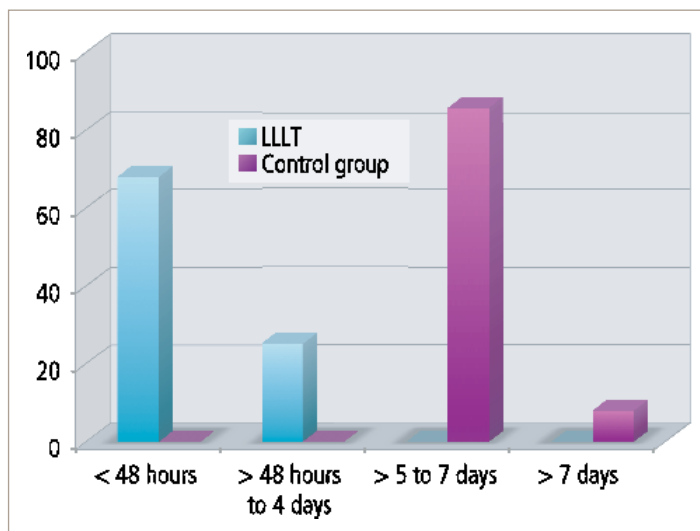
The laser used was the Lasermid 670DL (Cuban manufactured), 670 nm, 40 mW. Each ulcer underwent 40 seconds of irradiation at 1.6 J, 2.04 J/cm<sup>2</sup> and 51 mW/cm<sup>2</sup> from a distance of about 0.5 cm. The parameters used were based upon the successful application of these in a previous study on herpes simplex virus Type I blisters.<sup>32</sup>

The study was unblinded. A 660 nm laser emits clear red light and, although a patient-blinded design is possible, it is not possible to mask a placebo laser for the therapist.

The distribution of the age of the patients, of the types of ulcer according to age, and of the types of ulcer in the study and control groups is shown in Tables 1–3. This data corresponds with the literature, where smaller aphthous ulcers represent 80–85% of cases, larger ulcers 10–15% and herpetiform ulcers 5–10%.<sup>1</sup>

## Results

The main results of the study are presented in Figure 1. The results shown are for small ulcers, which were the dominant type of ulcers treated. As for the large ulcers in the study group, four scarred between two and four days, and another four scarred between five and seven days. In the control



Sex	Age group (years)					Total
	0–9	10–19	20–39	40–59	60+	
Male	4	4	16	24	4	52
Female	4	20	48	52	28	152
Total	8	24	64	76	32	204

Clinical type	Age group (years)					Total
	0–9	10–19	20–39	40–59	60+	
Small ulcers	4	24	60	64	28	180
Large ulcers	–	–	8	12	–	20
Hepetiform ulcers	–	–	–	–	4	4
Total	4	24	68	76	32	204

Clinical type	Age group (years)		Total
	Study group	Control group	
Small ulcers	92	92	184
Large ulcers	8	8	16
Hepetiform ulcers	4	–	4
Total	104	100	204

group, eight large ulcers scarred within seven days. For ethical reasons, and because of the small number of cases, the four herpetiform ulcers were all treated with laser. They healed between two and four days. According to the literature, the normal healing time with no treatment is seven to ten days for small aphthous ulcers, ten to 30 days for large aphthous ulcers, and seven to 14 days for herpetiform ulcers.<sup>1,3</sup>

## Discussion

The use of LLLT to treat aphthous stomatitis was suggested in 1986 already by Quang-Hua<sup>25</sup> using a helium–neon laser and in 1987 by Von Alften<sup>26</sup> using a gallium arsenide laser. Recent studies, such as the one by De Souza et al.<sup>27</sup> have used a laser similar to ours, 670 nm, 50 mW, 3 J/cm<sup>2</sup>. It therefore appears that the wavelength itself is not decisive. Indeed, Zand et al.<sup>28</sup> report good results using a carbon dioxide laser at non-thermal levels in combination with a transparent gel to reduce beam absorption. Surgical lasers have also been reported to be effective, but the mechanism here ought to be different, since it entails superficial tissue evaporation. Tezel et al.<sup>29</sup> report fair results using an Nd:YAG laser, while the erbium laser in addition can be used for surface modification of the lesion and pain relief.<sup>30</sup>

The biological mechanism behind the effect of the various lasers is still unknown. The power setting used in our study was rather low and the effect of higher power settings needs to be investigated.

Another aspect is the number of sessions. In our study, the patients were treated every second day until wound closure had been achieved. In the De Souza study,<sup>27</sup> patients were treated daily until an obvious result was observed. Only four patients with a herpetiform ulcer took part in the current study. Although these ulcers responded well to LLLT, no definite conclusions can be drawn, since all four were included in the study group.

Patients typically have an occasional aphthous ulcer. The problem arises in patients with recurrent aphthous ulcers. The frequency of recurrence was not investigated in our study, but no presently available treatment has been able to reduce recurrence.<sup>31</sup> However, such a possibility is suggested in some sources.<sup>22–24</sup> In a recently published study,<sup>32</sup> our clinic found that LLLT reduced the recurrence frequency in herpes simplex virus Type I patients. Although aphthous ulcers are different to herpes simplex virus Type I blisters, LLLT might reduce their frequency of recurrence too.

## Conclusion

LLLT appears to be a safe and effective option for treating aphthous stomatitis. The distribution of aphthous stomatitis in the various age groups was found to be in accordance with previous reports.<sup>33</sup> Further studies are warranted to investigate the optimal laser parameters and frequency of irradiation.

## Statement

The present study was financed by the authors and their clinics. Pedro J. Muñoz Sánchez and José Luis Capote performed the clinical part. Jan Tunér served as scientific advisor and authored the manuscript.

*Editorial note: A list of references is available from the publisher.*

## contact

## laser

**Jan Tunér**  
Spjutvagen 11  
772 32 Grängesberg  
Sweden  
[jan.tuner@swipnet.se](mailto:jan.tuner@swipnet.se)





## New Orleans

American Dental Association

# ANNUAL SESSION

OCTOBER 31 - NOVEMBER 3, 2013

**ADA** American Dental Association®  
America's leading advocate for oral health

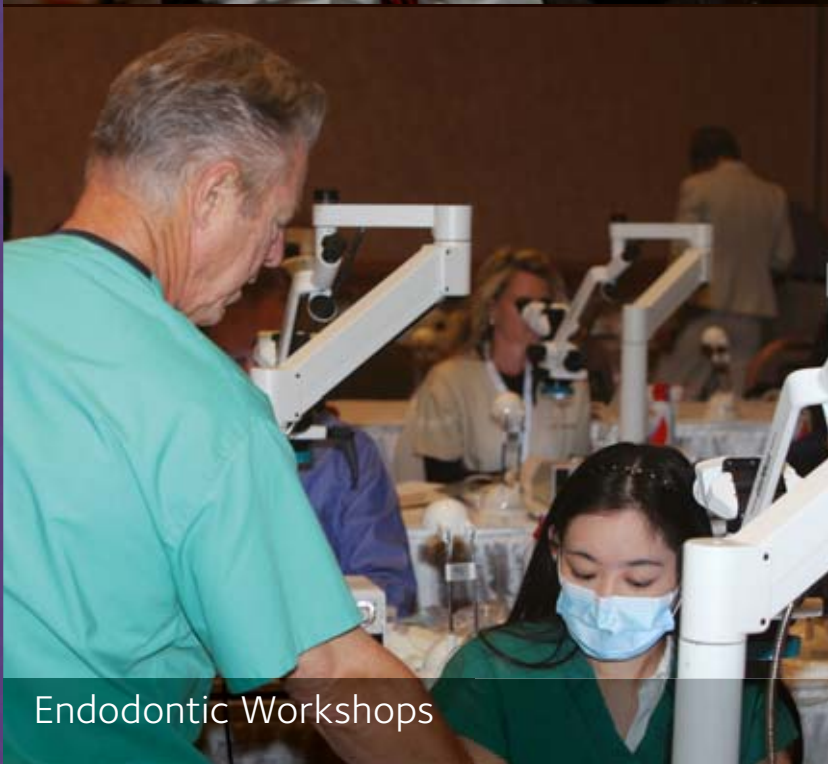## Make the 2013 ADA Annual Session your first choice for endodontic education

Select from 13 endodontic courses at the 2013 Annual Session and learn from renowned speakers such as Dr. David Beach, Dr. John Olmsted, Dr. Clifford Ruddle, Dr. Jordan West and more.

**Registration is open now.**  
**[ADA.org/session](http://ADA.org/session)**



Endodontic Education



Endodontic Workshops



Endodontic Lectures

# Surgical management of peri-implantitis with laser

## A Case Report with eight years follow up

**Authors** Prof. Dr Aslan Yaşar Gokbuget, Emin Selim Pamuk, Res. Asst. Dt. Necla Aslı Kocak, Turkey

[PICTURE: ©BUSLIK]

### \_Introduction

The term peri-implantitis first appeared in the literature in 1987 in a study by Mombelli and colleagues. It was described as an infectious disease with many features common to periodontitis. Since then, a growing interest in defining peri-implant disease as a clinical entity and to propose a treatment approach for it has been observed. Peri-implantitis has been defined as the inflammatory reactions associated with loss of supporting bone around an implant in function. Along with this definition of peri-implantitis in the 1<sup>st</sup> European Workshop on Periodontology (EWOP) in 1994, another implant-related pathology, which is peri-implant mucositis was defined as a 'reversible' inflammatory reaction in the soft tissues surrounding a functioning implant. These definitions thus imply that the inflammatory process that occurs in peri-implantitis lesions is irreversible. Peri-implantitis affects 5% to 10% of implant patients, and is a major cause of implant failure.

### \_Clinical presentation of peri-implant diseases

#### A) *Peri-implant mucositis*

This is a reversible inflammatory reaction in the soft tissues that surround an implant in function. Clinically it is characterised by:

- Presence of bacterial plaque and calculus
- Oedema, redness and mucosal hyperplasia
- Bleeding affecting mucosal sealing on probing

- Exudate or pus formation on occasions (gingival microabscess)
- Radiological absence of bone reabsorption

#### B) *Peri-implant osteitis (Peri-implantitis)*

This is an irreversible inflammatory reaction in the soft and hard tissues that surround an implant in function, because natural bone loss occurs if no treatment is given. It has more florid clinical symptoms because, in the initial phase, it may present the same signs as peri-implant mucositis, but these are later accompanied by the symptoms of bone loss itself.

The most common signs are:

- Presence of bacterial plaque and calculus
- Oedema and redness of peripheral tissues
- Mucosal hyperplasia in zones with a lack of keratinised gingiva
- Increased probe depth. The level of probe reaches the apex
- Bleeding and slight pus formation after probing and/or palpation
- Vertical bone destruction in relation to peri-implant pocket
- Radiological presence of bone reabsorption
- Implant mobility
- Pain is not very common, but is sometimes present

### \_Treatment peri-implant diseases

#### A) *Treatment of implant mucositis*

Treatment is principally focused on controlling bacterial plaque, although other surgical treat-



ments may be performed to eliminate the hyperplasia of surrounding soft tissue as well as to graft keratinised gingiva, if necessary.

Thus, treatment consists of several phases:

**1. Professional peri-implant hygiene:**

- Mechanical elimination of bacterial plaque
- Irrigation of the surcus-pocket with 0.12% chlorhexidine
- Removal and disinfection of the prosthesis
- Modification of unhygienic prosthesis designs
- Sometimes a partial-thickness flap is performed to irrigate with sterile physiological saline, followed by the application of a tetracycline cream
- laser treatment in refractory cases

**2. Personal peri-implant hygiene:**

- Chemical plaque control with 0.12% chlorhexidine 12 hourly.

**3. Local and systemic antibiotics**

**4. Regular professional control**

*B) Treatment of peri-implantitis*

Treatment using the cumulative, interceptive, supportive therapy (CIST) protocol, Mombelli and Lang<sup>1</sup> (1998) recommend various treatment options according to the severity of the peri-implant infection. Mechanical debridement, antiseptic agents, local or systemic antibiotic therapy and surgical therapy are used alone or in combination, based on pocket depth (PD), bleeding on probing (BOP) and degree of bone loss. Mechanical debridement can be attempted with carbon, plastic or metal curettes, ultrasonic scaling or air abrasion.<sup>2,3</sup> Chlorhexidine

digluconate can be used as a disinfectant, either as a mouth-rinse at 0.1 to 0.2 %, a subgingival irrigant at 0.2 % or locally applied as a gel.<sup>1</sup> Persson et al. (2006)<sup>2</sup> reported the use of tetracycline fibres and minocycline microspheres, both sustained antibiotic release devices for treating peri-implantitis. Surgical therapy can involve gingivectomy for better access to implant structures, apically repositioned flap, osteoplasty or guided bone regeneration.<sup>1</sup> Unfortunately, each of the aforementioned methodologies presents different limitations and, as yet, there is no 'gold-standard' treatment that can reliably decontaminate peri-implantitis-associated implants and provide long lasting improvement in clinical parameters. The fundamental requirement in successful peri-implantitis treatment, with or without the use of bone regeneration protocols, is to decontaminate the implant surface, removing bacteria and toxins. Peri-implantitis treatment must be based on the stabilisation of progressive bone loss, and in special cases, to retrieve lost bone with regenerative treatment. The treatment can be divided into two phases:

– Phase 1: Initial conservation treatment

A. Manual-mechanical methods to control bacterial plaque (similar to mucositis)

B. Chemical methods

B.1. Local: 0.12% chlorhexidine, citric acid, local application of tetracycline

B.2. Systemic: Antibiotic therapy

C. Lasers

– Phase 2: Regenerative treatment

*Treatment of soft tissues*

A crestal incision is scalloped around the implant neck to eliminate the internal epithelium and granulation tissue from the pocket. A mucoperiosteal flap is lifted to expose the implant, and bone tissue and granulation tissue is eliminated from the bone defect with a metal curette without touching the implant. A cold sterile physiological saline solution is irrigated throughout the procedure to prevent bone dehydration.

*Detoxification of the implant surface*

Limitations of treatment; Karring et al.<sup>4</sup> found that neither ultrasonic debridement, using a carbon fibre tip, nor mechanical debridement, using carbon fibre curettes, were effective in reducing pocket probing depth after six months, in patients with failing implants. Lavigne et al.<sup>5</sup> found no clinical or microbiological effect when 0.12 % chlorhexidine was used to irrigate implants with probing depths of greater than 3 mm. Mombelli and Lang<sup>6</sup> reported that mechanical debridement of implant surfaces in conjunction with a 0.5% chlorhexidine rinse and



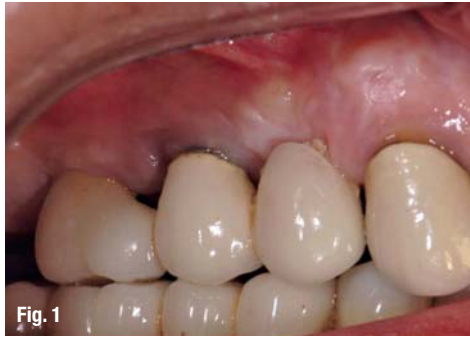

Fig. 1

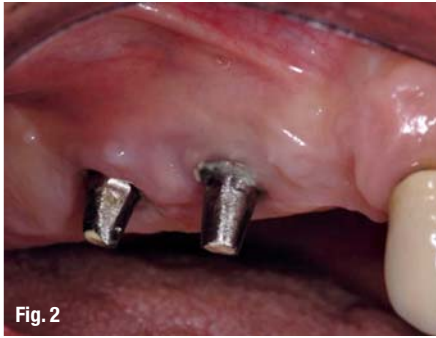

Fig. 2

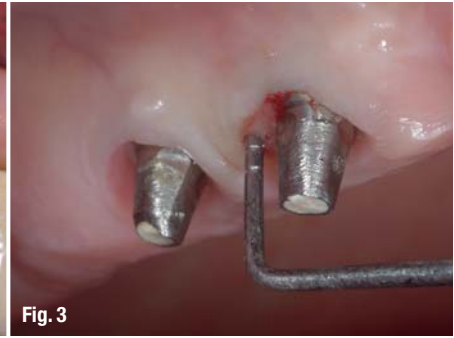

Fig. 3

**Fig. 1** First examination.

**Fig. 2** After removal of the dental prosthesis.

**Fig. 3** Probing depth around implants.

systemic antibiotic therapy (single daily oral dose of 1,000 mg ornidazole) led to reduced levels of inflammation after one year, however there was no statistically significant reduction in bacterial level or proportions of bacteria. Miller<sup>7</sup> states that tetracycline paste can be used to decontaminate implant surfaces, although it is not effective in removing bacterial endotoxin.

### Types of implant surface detoxification

#### *A. Chemotherapeutic agents*

1. CHX
2. Tetracycline, polymyxin B, or H<sub>2</sub>O<sub>2</sub>
3. Citric acid

#### *B. Laser*

A promising method for decontaminating implant surfaces involves the use of laser energy. The use of lasers is becoming increasingly common in dentistry, with applications in soft tissue surgery, caries removal, and also in the treatment of peri-implantitis. Unlike mechanical decontamination methods, which can not fully adapt to the irregularities on the surface of an implant, lasers can irradiate the whole surface, reaching areas that are too small to receive mechanical instrumentation. Recent *in-vivo* studies have analysed the outcome of peri-implantitis treatment using the Er:YAG laser<sup>8-14</sup> and CO<sub>2</sub> laser<sup>15-17</sup>. Many of these studies show promising short-term results (< six months) but report no long-term follow up. When considering the use of lasers in the treatment of peri-im-

plantitis, there are a number of decisions that the clinician must make. First is the type of laser to use, options of which include Nd:YAG, Er:YAG, Er,Cr:YSGG, diode or CO<sub>2</sub> laser. Power settings are variable, and the clinician must also choose a setting that will effectively disinfect the implant while not damaging the surface. Additionally, the exposure time and distance from which the laser is applied also has an effect on both the success of decontamination and damage to the implant surface. The clinician also has the option of combining laser therapy with other types of decontamination therapy. Current research tends to focus on the bactericidal properties of Nd:YAG, Diode, Er:YAG, CO<sub>2</sub> and Er,Cr:YSGG lasers and the effects that they have on implant surfaces.

### Guided bone regeneration used in implantology

Iovanovic and Nevins<sup>18</sup> evaluated four adult patients with insufficient bone that were selected for treatment with the titanium-reinforced membrane (TRM, Gore Corp.) with or prior to placement of Brånemark implants. Sites treated with GBR without grafting had a fibrous layer up to 3 mm thick, whereas those treated with GBR + grafting had a fibrous layer only 1 mm thick. Lundgren et al.<sup>19</sup> reported the use of a bio-resorbable material (GUIDOR™, Butler Corp.) to cover implant exposures after the installation of Brånemark implants, with and without the use of autologous bone chips. Their conclusion was that the material, which resorbed in six to seven months, was a satisfactory barrier but that a supporting grafting material should be used to prevent barrier collapse. However, other investigators<sup>20-22</sup> are of the opinion that an allograft is not essential or advantageous in guided tissue or guided bone regeneration.

GBR is also used in the implant modalities to facilitate repair and in regeneration procedures associated with an ailing, failing dental implant, with and without grafting materials.<sup>23-35</sup> Regardless of the material used, non-resorbable or absorbable/resorbable, with and without the addition of a

**Fig. 4** Surgical entry.

**Fig. 5** X-ray control after eight years.

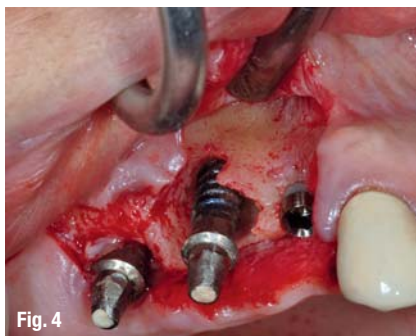

Fig. 4

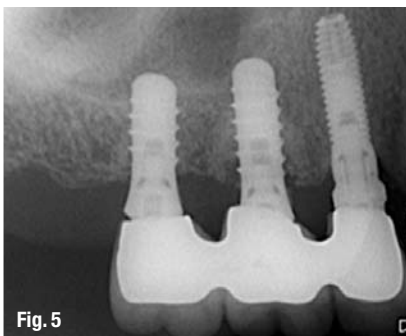


Fig. 5

grafting material (auto, allo, xenograft, or alloplast), the membrane used for GBR must be left in place for as long as possible and not removed prematurely.

## Clinical presentation and case management

A 60-year-old female patient presented at our private clinic PGG for treatment of the implants at the right maxillary molar site. The implant has been placed seven years ago and the implant supported simulated porcelain fused to metal fixed partial denture was made (Fig. 1). Upon review of her medical history she was otherwise healthy. She previously had been treated for chronic periodontitis with non-surgical approach. Then radiographic examination was made and revealed a combined marginal and vertical radiolucency. The implant crown was removed (Fig. 2) and on clinical examination deep probing depths were isolated (Fig. 3). No clinically detectable mobility of the fixture was present. The patient was referred for an extra implant on the right first premolar site while doing a surgical entry for the peri-implantitis around the two implant at the right maxillary molar site. One hour prior to surgery, the patient was given 2 g of Amoxicillin and following surgery placed on a regimen of Amoxicillin 1,000 mg tid for 5 days post-op. A crestal incision is scalloped around the implant neck to eliminate the internal epithelium and granulation tissue from the pocket. A mucoperiosteal flap is raised to expose the implants (Fig. 4), and bone tissue and granulation tissue is eliminated from the bone defect with Er:YAG laser with power settings of VSP 120 mJ, 10 Hz with water and air flushing and Nd:Yag laser with 300 µm tip, VSP, 2 Hz, 20 W power setting is used for implant surface detoxification. An additional 3.3 x 13 mm TSW implant was placed to first premolar site, then Xenogenous bone grafts (Bio-Oss®) compacted into the defect. A non-resorbable Gore-Tex® barrier was placed over the defect and was extended buccally and lingually. The buccal and lingual flaps were released and tension-free primary closure was achieved with 4-0 teflon sutures. She was instructed to continue the antibiotics as prescribed and to rinse with the 0.12% Chlorhexidine gluconate bid for one minute, twice a day. Finally, a strict maintenance and oral hygiene protocol were established.

The area healed uneventfully after six months. Periapical radiographs were taken throughout the healing process to evaluate the mineralization of the graft over time. After six months, a Gore-Tex® barrier was removed and healing abutments are placed. After one week the previous restoration was replaced. Bone formation within the bony defect

was evident. At that time the previous screw retained restoration was replaced. At the six-months follow-up, the implant was evaluated and found to have probing depths of 1–3 mm with 1–2 mm of recession on the mid-buccal aspect radiographically it appeared that there was increased mineralisation of the bone surrounding the implant. The patient was again examined every one year and eight years after treatment a new radiograph was taken which demonstrated complete resolution of the bony defect surrounding the implant (Fig. 5).

## Discussion

There is no standard of care for the treatment of peri-implantitis, and clinicians are faced with a lot of choices when deciding upon a method of treatment. This case has shown the use of lasers to treat peri-implantitis. It must be noted that the treatment of peri-implantitis requires decontamination of implant surfaces and maintaining a healthy peri-implant environment. Long-term success is dependent upon patient cooperation, regular maintenance and assessment, and adaptation of treatment planning as symptoms improve or decline. This case has shown that laser therapy is potentially a very useful tool in the treatment of peri-implantitis, however, further research is needed to aid clinicians in providing the ideal treatment for this disease.

## Conclusion

Although no definitive conclusion can be drawn from a single case report, the guided-bone-regeneration-combined laser technique described in this case report effectively eliminated implants associated three-wall bony defect and deep pocket. Under the conditions of the present case, it may be concluded that the Er:YAG laser can be safely and effectively utilised for degranulation and implant surface debridement in the surgical treatment of peri-implant infection.

*Editorial note: A list of references is available from the publisher.*

## contact

## laser

### Prof. Dr Aslan Y. Gokbuget

PGG Dental Clinic  
Tevsikiye Caddesi Kismet Apt. 133 d.8  
34365 Nisantasi  
Istanbul, Turkey

Tel.: 0212 248 0317  
Fax: 0212 247 5118

# Diode laser application optimises the clinical outcomes of digital workflow

**Authors** Prof. (Shandong University, China) Dr Frank Liebaug, Dr Ning Wu, Germany

## Introduction

"Digital Workflow" has become an established term in present-day dentistry, helping to solve problems in dental technology which would have been rejected due to an unwarranted high analogous effort some years ago.

**Fig. 1a** Laser HF (Hager & Werken GmbH & Co.KG, Duisburg, Germany): The only device combining two lasers 975 nm/6 W and 66 nm/25–100 mW and HF surgical component 2.2 MHz for easy, fast and precise cutting of soft tissues.

**Fig. 1b** The preparation margin can be traced ergonomically via the laser hand piece like holding a fountain pen.

**Fig. 2** Blood and saliva make the depiction of the prosthetic preparation margin more difficult.

With digital procedures entering the realms of diagnosis, therapy and production, the workflow of dentists and dental technicians has changed considerably over the past years. Today, all dental disciplines rely on digital technologies to achieve exact diagnosis, modelling and production. The broad spectre of technologies reaches from intraoral scanners for three-dimensional scanning of the stomatognathic system to the production of models via CAD-data by 3-D printers. Dentists and dental technicians make use of these technologies as well as of manual procedure steps. Digital technologies have improved the highly demanding work of to-

day's dental technicians in terms of reliability in planning and treatment. Now, neighbouring teeth, roots and nerves can be captured precisely via digital volume tomography, with the data being visualised three-dimensionally. These options result in a significant risk reduction of implant placement in the jaw bone. Furthermore, digitalisation has achieved a fundamental change in patient communication. Dental technicians and dentists are thus no longer demanded exclusively as clinicians and craftsmen. For instance, CADM/CAM technology and intraoral cameras allow for presenting transparent solutions for an improvement of the aesthetic situation to the patient already in the practice. Therefore, the patient is informed more soundly and can be included in decisions on treatment planning.

The production of restorations has undergone a tremendous change in the past years. All-ceramic crowns have replaced porcelain fused to metal as the standard. The properties of materials such as zirconium



Fig. 1a

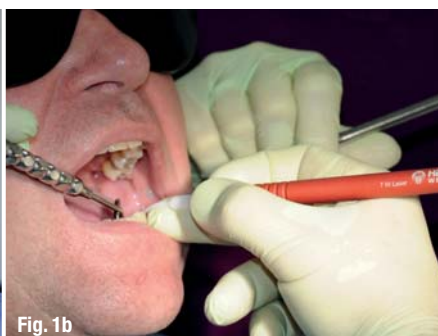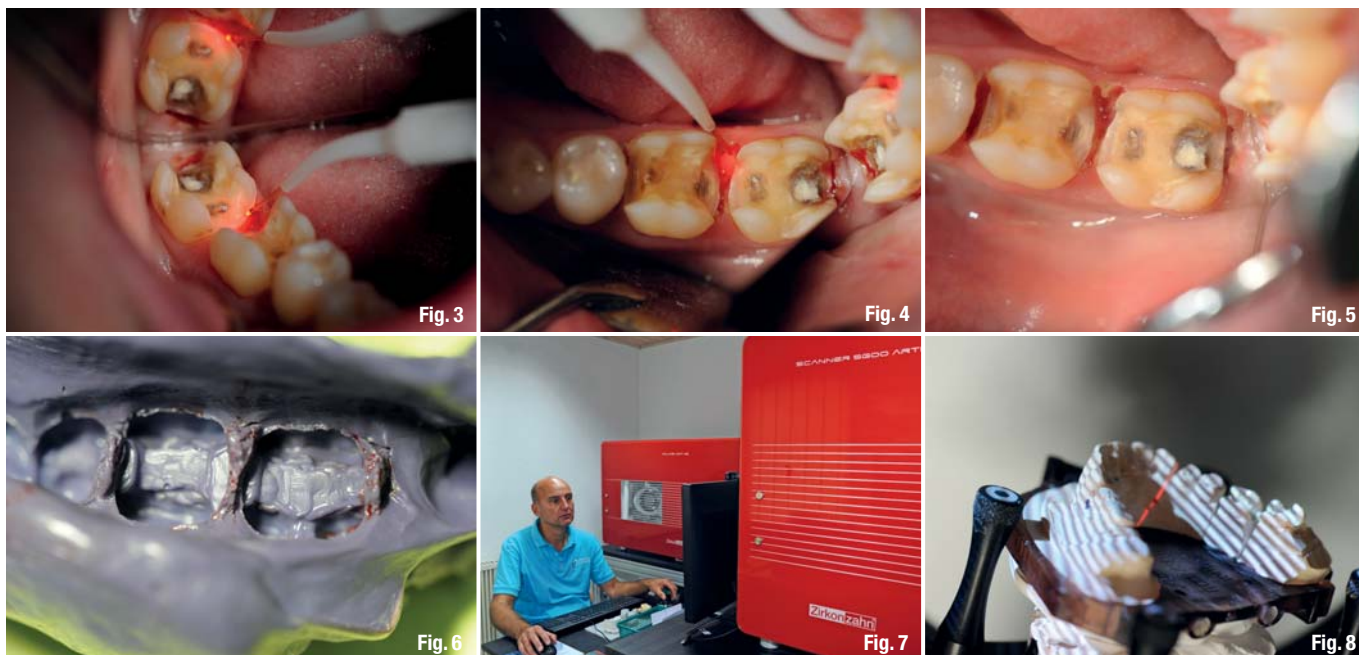


Fig. 1b

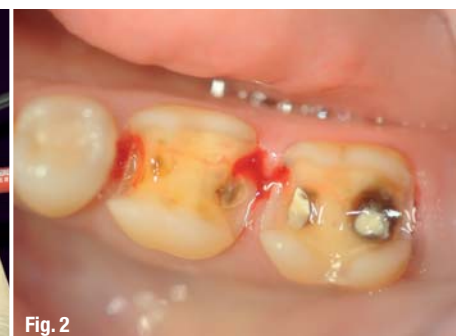

Fig. 2





oxide have been improved to deliver perfect aesthetic results.

Dentistry without digital technology and CAD/CAM procedures has become inconceivable. Intraoral and extraoral measurement, scanning of antagonists and registration, three-dimensional construction on screen (Fig. 7), applying a large variety of tooth shapes from the data base, designing anatomical occlusal surfaces, the functional articulation in the virtual model, the subtractive processing of high-performance ceramics—all of this would be impossible without computers.

New procedures influence established steps of the process, and advances simplify workflows. Thus, virtual construction models, the articulation via Windows interface, biogeneric design of occlusal surfaces via intelligent software, rapid-prototyping and 3-D printing are only a small sample of the topics which are discussed in scientific publications with regard to CAD/CAM dentistry. Small and medium-sized dental laboratories or, as in my case, larger practice laboratories will acknowledge their core competence of producing high-class aesthetic restorations as well as individually designed partial dentures and implant dentures.

It has thus become a prevailing trend to produce inlays, onlays, partial dentures and single-tooth restorations as well as large-span bridges and suprastructures assisted by computer. In addition, the computer-assisted production of long-term temporary restorations according to functional criteria has become an established method in our practice for implantology and its suprastructures.

### Exact transfer of the oral situation as the base

Without an impression of the actual patient situation, modern dentistry is unthinkable. For decades, not much has changed with regard to impression technique, except for the development of impression materials. Already in the 1980s, the first trials in digital impression taking were conducted in the form of intraoral optical scans and then introduced as a new technique. By now, this technique is so well-developed that it can be applied in a multitude of indications.

However, an exact transfer of the oral situation on the virtual or physically present model is the foundation and the beginning of digital workflow. Whether analogous impression taking or digital scanning by optical procedures is applied, the mode of preparation, especially the preparation margin, must be depicted exactly.

Although sometimes the soft tissues can be pushed away from the subgingival preparation margin because of the viscosity of the impression material, opti-

**Fig. 3** Working tip of the diode laser for haemostasis.

**Fig. 4** Excision of interfering soft tissue can be done fast and effectively via laser.


**Fig. 5** After laser application, the preparational margin is depicted clearly. This is mandatory for analogous as well as optical impression taking in order to achieve optimum results in the patient's prosthetic rehabilitation.

**Fig. 6** Detail of the polyether impression taking (Impregum Penta Soft, ESPE Company, Seefeld, Germany) with individual impression tray confirms the exact depiction of the oral situation, especially the preparational margin at the cavity margin.

**Fig. 7** Milling machine M5 with strip light scanner S600 ARTI as a component of the CAD/CAM system 5-TEC in Ferrari red by Zirkonzahn GmbH, Italy.

**Fig. 8** Model under strip light (inside the scanner S 600 ARTI).

**Fig. 9** Articulator with model of upper and lower jaw in the strip light scanner S600 ARTI.



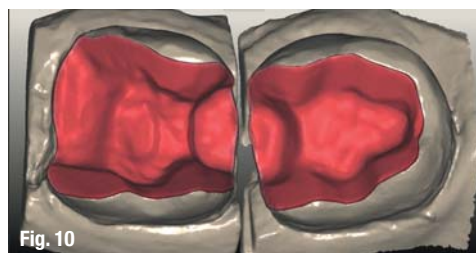


Fig. 10

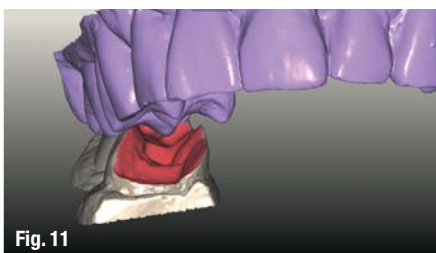


Fig. 11

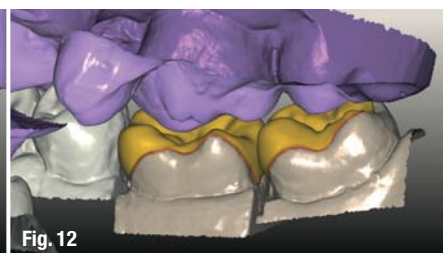


Fig. 12

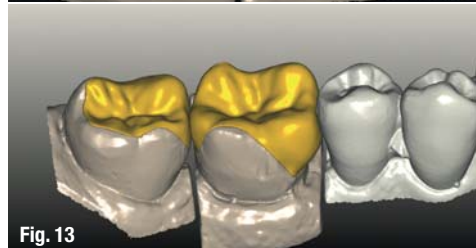

Fig. 13

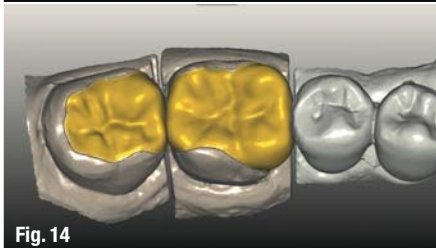

Fig. 14

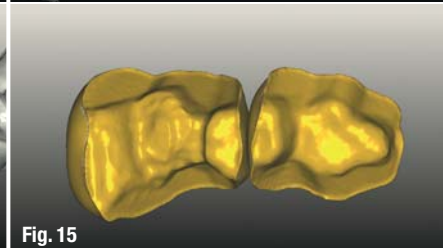


Fig. 15

**Fig. 10** Depiction of the form of the preparation, especially the level ranges on the monitor, after cutting less relevant aspects of the model situation image digitally.

**Fig. 11** Checking of the minimum layer depth for the future ceramic restoration is more practical than via the analogous model.

**Fig. 12** Articulation can be checked from various perspectives.

**Fig. 13** Production and checking of the optimum occlusal configuration.

**Fig. 14** Okklusal view of the digitally planned partial crowns.

**Fig. 15** In the end of the digital planning phase, the restoration can be checked from all special dimensions even before the milling process.

cal impression taking via scanner systems does not allow for this option.

While optical impression taking systems make a contribution to standardization, direct control of the preparation outcome and thus to the quality of the impression, conventional as much as digital optical impression taking can only capture structures which are visible to the human eye. Optical impression taking cannot replace conventional impression taking techniques completely. This holds true especially for removable and complete dentures as well as circular implant suprastructures. In addition, the transfer of virtual data into real-life working models, which is often mandatory, has not yet been perfected.

However, the current trend is digital impression taking, although many obstacles have yet to be overcome.

A review of the literature and published reports shows that in most cases supragingival preparation margins are treated, which some colleagues might be able to take an impression from without any retraction cords. Extensive haemostasis measurements and tissue suppression can cause more trouble, since a camera will only be able to scan areas optimally which are easily accessible.

No optical system has been able to see through a pooling of saliva or offer usable data for an exact rendering of the preparation margin. Imprecision can accumulate between impression taking and final prosthesis. Thus, both the advantages and the precise results produced by digital workflow would be taken ad absurdum.

But the clinical, deeply subgingival preparation margin with bleeding of the adjacent gingiva (Fig. 2) can be a severe challenge for experienced clinicians using the traditional analogous impression technique. Without cord techniques or astringent auxil-

iaris, a good result is hard to achieve from impression taking. Or is it?

Twenty years ago, I have introduced high-frequency technology and shortly afterwards dental lasers to our praxis because of the high quality standards in solving prosthetic problems by our team of clinicians and dental technicians. Especially the compact diode lasers can be applied effectively in this field.

### Laser radiation

Not only is laser radiation absorbed by the tissue and then transformed into heat, but it is also partly transmitted through the tissue. This takes place independently from the respective dental laser and determines the indication. The cutting speed of the laser radiation is limited by the tissue, which can only be ablated in layers. Laser radiation produced by the dental laser is led to the application site in the oral cavity by fibre optic systems consisting of mirror joint arms and flexible glass fibres. Here, laser radiation from the anterior fibre heats the surface layer of the tissue in a closely-defined area, thus ablating the tissue. In order to reach deeper layers, the tissue must be ablated layer by layer. Although some authors see this as a disadvantage<sup>1</sup>, this minimally invasive and tissue-conserving procedure is especially helpful in the sensitive cervical areas and in sulcus extension previous to impression taking.<sup>2</sup>

### Clinical Procedure

The handpiece of the diode laser device (Fig. 1) is placed in the hand like a fountain pen (Fig. 1 a). With the thin fibre tip, the preparation margin is traced circularly around the anchor tooth, either over its total circumference or only the gingival level range of the partial crown (Figs. 3–5), by using it like a fine fibre pen of a diameter of only 0.3 mm.

Thus, uneven gingival areas or gingival areas damaged iatrogenically during abutment preparation are removed and haemostasis is achieved. If light oozing bleeding occurs, haemostasis is achieved punctually via laser fibre by increasing the pulse energy (Fig. 4). For this, only little anaesthesia is necessary and the procedure is much more pleasant for the patient. If a scanning system demands the use of powder in order to improve optical impression taking, special care must be taken to ensure that the powder does not bind with blood or cervicular fluid. Otherwise, optical impression taken could provide imprecise results and thus cannot be used as the starting point of the digital process chain.

After the working field was prepared as described and the complete preparation level range is easily accessible by the clinician and can be prepared dryly (Fig. 5), the impression taking technique favoured by the dentist can be performed.

Laser application is seen as part of the prosthetic quality management in my practice and is thus a standardised aspect of every preparation. Immediately before the drainage, precision impressions are taken. For this, I often use individual impression trays and Impregnum (3M ESPE, Seefeld, Germany), as can be seen from Figure 6. The dental technicians in our team check the impression by stereo magnifying glasses and release it for further processing. After the classical production of the model from superhard plaster, the digital process chain starts with the strip light scanner S600 ARTI (Fig. 7).

### **\_Strip light scanner S600 ARTI**

The all-automatic, optical strip light scanner S600 ARTI (Zirkonzahn) with two cameras, precision gears without tooth belt and 360° rotation and 100° swivel axis, digital model scanning of almost any object is possible with a precision of about seven micron. Differences can thus be registered easily. The oversized measuring field of 95 x 75 x 100 mm allows for complete scans of the articulator or the whole arch (Figs. 8 & 9). Combined with the software Zirkonzahn.Scan, it is the only scanning system by which the dental technician can register his own laboratory articulator with the scanner and measure its axes. This is necessary for rendering realistic articulator situations with regard to the facial arch in the three-dimensional system of coordinates of the software. When the model situation is depicted on the monitor, the result of the dental preparation after exposure of the levels via laser can be depicted in detail (Fig. 10). This is another opportunity for the treatment team to check for errors. Articulation and layer depths of the planned ceramic restoration can be depicted as seen in Figures 11 and 12. Then, the optimum occlusal planes as well as the form of crown or

partial crown can be planned (Figs. 13 & 14). In addition to the milling machine M5, the scanner S600 ARTI forms a component of the CAD/CAM system 5-TEC (Zirkonzahn) that we use in our practice laboratory. Of course, every step of the process is guided by know-how and expertise in dental technology, which must not be underestimated during sintering process, individualization or veneering.

### **\_Laser light in the placement of the prosthetic restoration**

After the dental laboratory fabrication, we have come the full circle with the placement of the full ceramic restoration, for again we need cleanliness and a dry working field free of bleeding for this final dental treatment step. Often, localized gingivitis with an increased bleeding propensity can occur postoperatively or due to the temporary restoration, which often interlocks a number of prepared teeth to achieve stability. Furthermore, personal oral hygiene of the patients, especially flossing, is limited at this stage, which can cause localized gingivitis. Gingival hyperplasia also sometimes occurs, but it can be removed precisely and within seconds by diode laser. This holds especially true for the haemostasis of capillary bleeding and the drainage of the gingival sulcus in close proximity to the preparation margin.

This is the only way to make sure that the various bonding cements or bonding systems are applied according to the manufacturer's instructions.

### **\_Conclusion**

Diode lasers are mandatory for an effective quality improvement in the beginning and at the end of the digital process chain. The form of the preparation, especially the preparation margin, must be depicted precisely, whether in analogous impression taking or digital scanning via optical techniques. The routinely application and consequent use of laser technique are the basis for clinical long-term success of the prosthetic restoration. It can therefore help to meet the high demands of the patients.

### **\_contact**

### **laser**

#### **Prof. (Univ. Shandong) Dr Frank Liebaug**

Praxis für Laserzahnheilkunde und Implantologie  
Arzbergstr. 30  
98587 Steinbach-Hallenberg, Germany

Tel.: +49 36847 31788  
frankliebaug@hotmail.com  
www.laserzahnarzt-liebaug.de



# Lasers in periodontal therapy: the TwinLight<sup>®</sup> approach

**Authors** \_Giovanni Olivi and Matteo Olivi, Italy

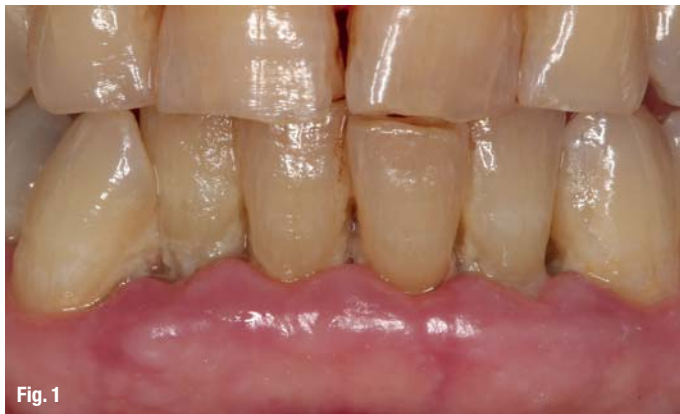

Fig. 1

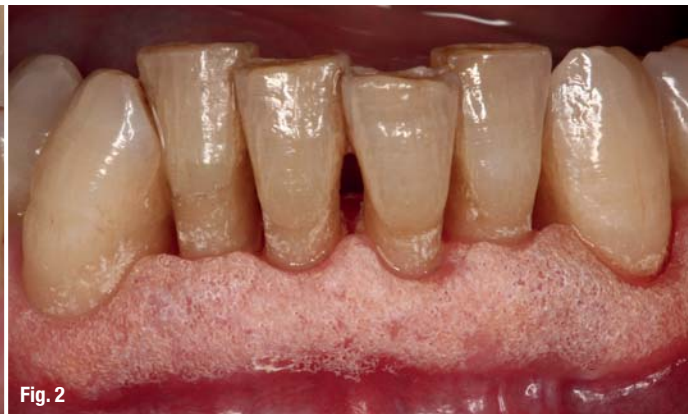

Fig. 2

**Fig. 1** \_Image of the anterior group before the initial periodontal therapy.

**Fig. 2** \_Laser therapy starts with the de-epithelialisation of the external and internal side of the gum. In this case, an Er:YAG laser was used at 60–80 mJ, 20 Hz, with SP mode. The handpiece strokes the gum from side to side (water spray off).

## \_Introduction

The objectives of periodontal treatment are to remove all calcified concretions from the root surface<sup>1</sup> and inflamed tissues from the periodontium and to reduce the bacterial load inside the gingival pockets.

The periodontal pocket may be considered an open system where different bacterial species live in different layers and can exercise disruptive action. Aerobic and anaerobic bacteria colonise the radicular cement at different depths, in a very adherent and robust manner. It is very difficult to completely eradicate the biofilm with chemical, mechanical and physical devices; furthermore, it is difficult for dentists and dental hygienists to explore, clean and disinfect such a complex system because of the specific location and anatomy of the roots. Another problem of periodontal treatment is the maintenance of the patient's health conditions after the initial periodontal therapy, as microbiological studies have indicated that recolonisation of the periodontal pocket occurs between three and six months after healing.<sup>2,3</sup>

## \_Laser in non-surgical periodontics

In recent decades, laser has been used as a monotherapy or as an adjunctive treatment to conventional periodontal therapy. The international literature reports contradictory results on the efficacy of laser treatment, and a common consensus on the real advantages of different laser techniques has not been

reached. Studies have reported that, when used as monotherapy, laser therapy has failed to reach all the goals of periodontal treatment completely. However, clinical outcomes of laser therapies have reported several advantages that encourage the use of the laser as an adjunct to conventional mechanical therapy in periodontics.<sup>4</sup> In addition to the outstanding reviews on this topic, which refer to studies ranging from 1990 up to 2008,<sup>5,6</sup> further investigations are required to consider the possible advantages derived from the use of newer technologies and techniques in recent years.

## \_Advantages and disadvantages of laser irradiation in periodontal therapy

Various advantages derived from the use of a laser, such as haemostatic effects, increased visualization of surgical sites, de-epithelialization of the gingival walls, selective calculus ablation, bactericidal effects against periodontopathic pathogens, reduced postoperative pain and high patient acceptance<sup>7</sup>, might lead to improved treatment outcomes.<sup>6,8-10</sup>

Several laser wavelengths are commonly used in non-surgical periodontics:

- Near-infrared lasers include semiconductor diode lasers (wavelengths ranging from 810 to 1,064 nm) as well as Nd:YAG and Nd:YAP lasers (at 1,064 and 1,340 nm respectively). Near-infrared lasers are highly absorbed in pigmented tissues (haemoglobin and melanin). Reaching depths ranging from 1 to 4 mm as

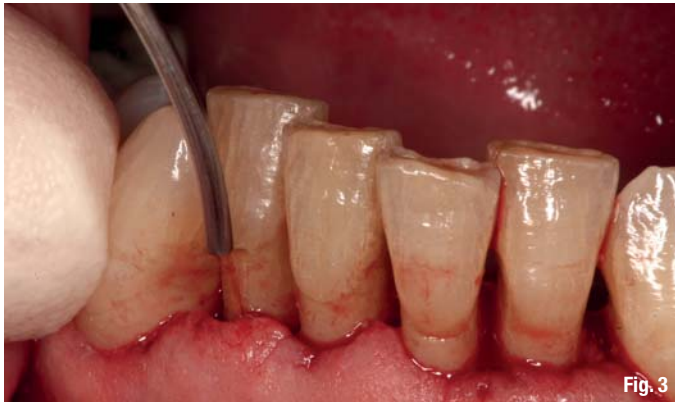

Fig. 3

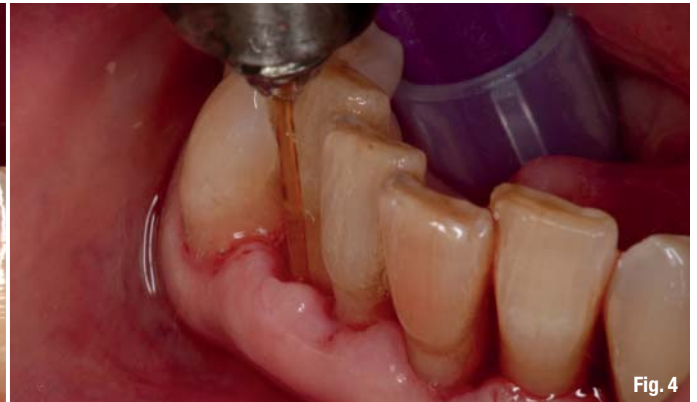

Fig. 4

a function of optical diffusion, minimal absorption in water and reflection, near-infrared irradiation can help with subgingival curettage, de-epithelialisation and disinfection of the periodontal pockets with various degrees of success.<sup>6,11-13</sup>

- Shorter wavelengths, both visible and near infrared, are also used as activators of specific photosensitisers in the so-called Photo-Activated Disinfection (PAD).<sup>14,15</sup>
- Medium-infrared lasers (Er:YAG at 2,940 nm and Er,Cr:YSGG at 2,780 nm) are superficially absorbed in water within the hard and soft periodontal tissues; the micro-explosion of water molecules helps with calculus removal<sup>3,16-20</sup> and the removal of biofilm from the root surfaces. It must be also emphasized that the degree of treatment discomfort scored significantly lower for the Erbium laser when compared to other treatment modalities.<sup>21</sup>

On the other hand, several studies have reported thermal side effects, such as melting, cracking or carbonisation when Nd:YAG and diode lasers were used directly on root surfaces, as well as damage to periodontal hard tissues if irradiation parameters were not adequate.<sup>22-25,19</sup> Near-infrared lasers were also proven to be ineffective at removing mineralised deposits from the root surface<sup>24,12,13,19</sup> and different studies have also indicated that Er:YAG laser radiation may not have any beneficial adjunctive effect at the microbiological level when compared with conventional treatment procedures alone. All of these findings lead to further considerations.

## Discussion

According to the different effects of the two laser groups (near- and medium-infrared), a combination of different wavelengths could work as a more effective adjunct to conventional periodontal therapy (SRP). Each wavelength can perform its characteristic action, helping in the resolution or control of some aspect of the periodontal disease (bacterial load, inflamed tissue, tartar). The different wavelengths, energy settings, exposure time and operative modes, as used in different

studies, may explain the varying results obtained for the resolution of periodontal disease. Also, considering the same wavelength, another point that must be explored is related to the different technologies available nowadays.

## Twin wavelengths approach (Figs. 1-7)

The latest technologies allow the use of new laser tips, settings and operating modes that are required to achieve a level of results that cannot be obtained otherwise. VSP (Variable Square Pulse) technology is a patented solution for generating square laser pulses for more controlled energy absorption (LightWalker AT, 1,064 nm & 2,940 nm; Fotona-Ljubljana). This technology minimizes unnecessary laser energy absorption into the tissues and helps to ensure ultimate performance and patient comfort during laser treatments. The pulse duration can be adjusted in the following increments: 50  $\mu$ s (SSP mode), 100  $\mu$ s (MSP mode), 300  $\mu$ s (SP mode), 700  $\mu$ s (LP mode) and 1,000  $\mu$ s (VLP mode), depending on the procedure, thereby avoiding or limiting the thermal side effects.

When Er:YAG is used at very short pulse durations (SSP and MSP modes), photomechanical and photoacoustic phenomena can be initiated inside the pocket,

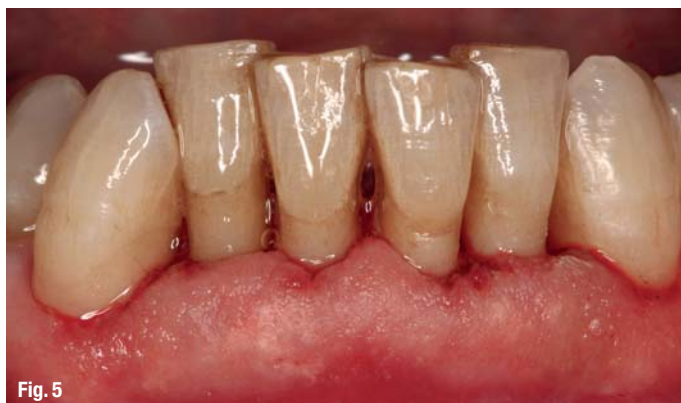**Fig. 3** The Nd:YAG laser is used to decontaminate and to de-epithelialise the internal side of the pocket. The fiber works side by side and up and down.

**Fig. 4** The Er:YAG laser is used again to refine the root scaling and debriding, using different tips: X-pulse, Varian or PIPS. The handpiece strokes up and down the pocket (water spray on).

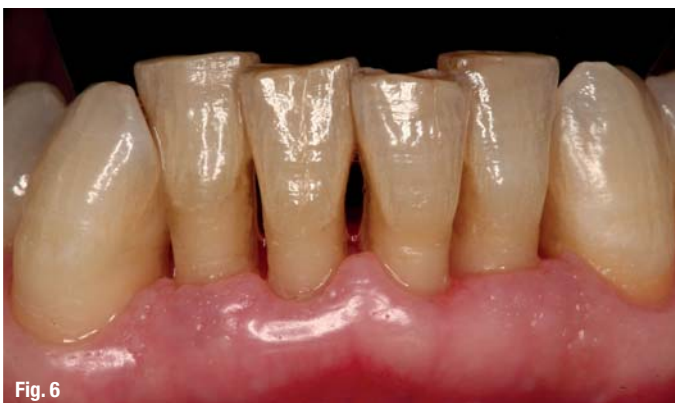### TwinLight® and WPT™ parameters

1 <sup>st</sup> step:	De-epithelialisation and decontamination Nd:YAG handpiece stroke side to side MSP – 20 Hz – 100-125 mJ – 2.0-2.5 W
2 <sup>nd</sup> step*:	Calculus removal (debriding refining) Er:YAG Varian tip, 600 micron, handpiece stroke up and down SSP – 50 Hz – 30 mJ – 1.5 W
3 <sup>rd</sup> step*:	Decontamination (Biofilm removal: PIPS™) Er:YAG PIPS TIP, 400-600 micron; surface mode SSP – 40 Hz – 20 mJ – 0.8 W
4 <sup>th</sup> step:	Clot formation Nd:YAG activate laser on out stroke only VLP – 20 Hz – 175-200 mJ – 3.5-4.0 W

\*Steps 2 and 3 may be performed at the same time with the same tip, changing the setting.



**Fig. 5** Immediately post-operative image.



**Fig. 6** Image of two weeks postoperative control showing healing in progress.

improving the biofilm removal from the root surface and also minimizing unwanted thermal side effects in the periodontal tissues. This method has already been found effective in endodontics for biofilm and debris removal using the PIPS® technique.<sup>26-28</sup> At low energy and a high repetition rate (SSP, 30–40 mJ, 40–50 Hz), the Er:YAG laser is useful for effective debris removal from the bottom of the pockets, deeply in the furcations of molars and premolars, where curettes scarcely work. This procedure helps in promoting periodontal healing, improving some periodontal indices (PI and BOP). Longer pulse duration (SP, 60–80 mJ) can be used for a superficial de-epithelialization of the buccal and gingival side of the gum, thus delaying the migration of epithelial cells into the pocket: this procedure can promote a gain in the clinical attachment level (CAL), reducing the PD. Also the Nd:YAG laser can de-epithelialize the gingival walls. Studies demonstrated that the deep penetration of the Nd:YAG laser, at 3 W, is effective in reducing bacterial populations.<sup>29</sup> Accordingly, the use of modern Nd:YAG technology at short pulse duration (MSP mode – 100 µs, 100 mJ, 20 Hz, 360 micron fiber) can help to reduce the bacterial load in the gingival pockets and to de-epithelialize the gingival walls, at only 2 W, thus limiting unwanted thermal side effects. This procedure is useful to improve the periodontal indices (BOP and PD). When a thermal effect is required for the formation of a clot, superficially in the pocket, a longer pulse duration (LP mode – 650 µs, 175–200 mJ, 20 Hz) is also available. The fibrin clot temporarily prevents bacterial re-colonisation, while de-epithelialization allows for a faster attachment of connective tissue, together

improving the periodontal healing. Repeating the decontamination phase every three months seems to control the recolonisation of the gingival pockets, promoting long-term healing. Two different protocols utilise the dual 1,064 nm and 2,940 nm wavelengths for non-surgical periodontal therapy (TwinLight® and WPT™) with slight differences in laser settings and tips, however, both are used for the same applications (see Table 1).

## Conclusion

With the limited available information on different laser therapies provided in the literature, it is possible to conclude that the combined application of modern Nd:YAG and Er:YAG laser technology, as an adjunct to ultrasonic debridement in a non-surgical approach to periodontal disease, is a useful procedure to improve short-term healing without adverse effects on dental and periodontal tissues. Regular patient recall is required to maintain long-term healing.

*Editorial note: A list of references is available from the author.*

**Fig. 7** From left to right, different tips for the TwinLight® procedure: Chisel, PIPS 600/9, X-pulse 400/14, Varian 500/14.



## contact

## laser

### Giovanni Olivi

MD, DDS

Prof. a.c. of Laser Paediatric Dentistry—University of Genoa

SIOI—Italian Society of Paediatric Dentistry

SIE—Italian Society of Endodontics

AIOM—Italian Academy of Microscope Dentistry

Private practice:

InLaser, Rome

Advanced Center for Esthetic and Laser Dentistry

Piazza F. Cucchi, 3 00152

+39 065815190

olivilaser@gmail.com

www.inlaser.it



Under the Patronage of  
**H. H. Sheikh Hamdan Bin Rashid Al Maktoum**  
Deputy Ruler of Dubai, Minister of Finance  
President of the Dubai Health Authority

تحت رعاية  
سمو الشيخ حمدان بن راشد آل مكتوم  
نائب حاكم دبي، وزير المالية  
رئيس هيئة الصحة بدبي

## مؤتمر الإمارات الدولي لطب الأسنان ومعرض طب الأسنان العربي UAE INTERNATIONAL DENTAL CONFERENCE & ARAB DENTAL EXHIBITION



Delivering Science & Technology

4 - 6 February, 2014

مركز دبي الدولي للمؤتمرات والمعارض  
Dubai International Convention & Exhibition Centre

[www.aeedc.com](http://www.aeedc.com)

Organised by



In Cooperation with



Strategic Partner



Supported by



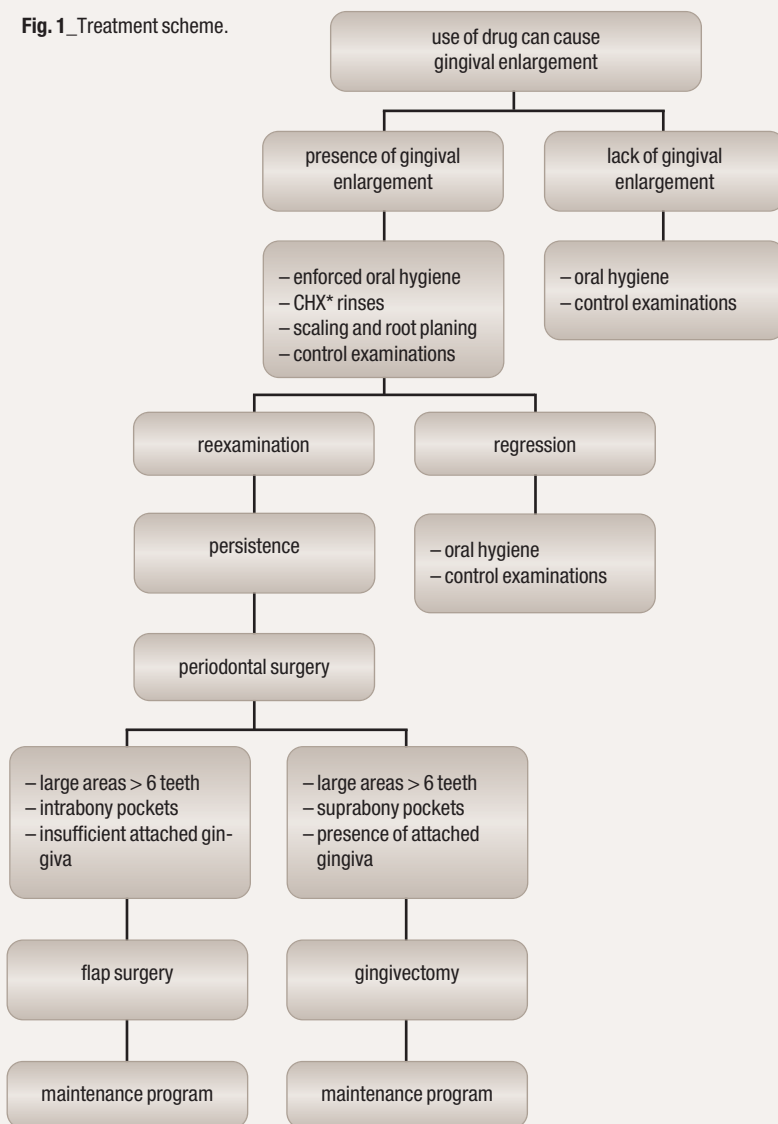
**INDEX® Conferences & Exhibitions Organisation Est.**

Dubai Healthcare City, Ibn Sina Medical Complex #27, Block B, Office 203 | P.O. Box: 13636, Dubai, United Arab Emirates  
Tel: +971 4 3624717, Fax: +971 4 3624718 | E-mail: [info@aeedc.com](mailto:info@aeedc.com), Website: [www.index.ae](http://www.index.ae)

# Treatment of drug-induced gingival enlargement with Er:YAG laser

**Authors**\_Dr Blagovesta Yaneva & Prof. Dr Georgi Tomov, Bulgaria

**Fig. 1**\_Treatment scheme.

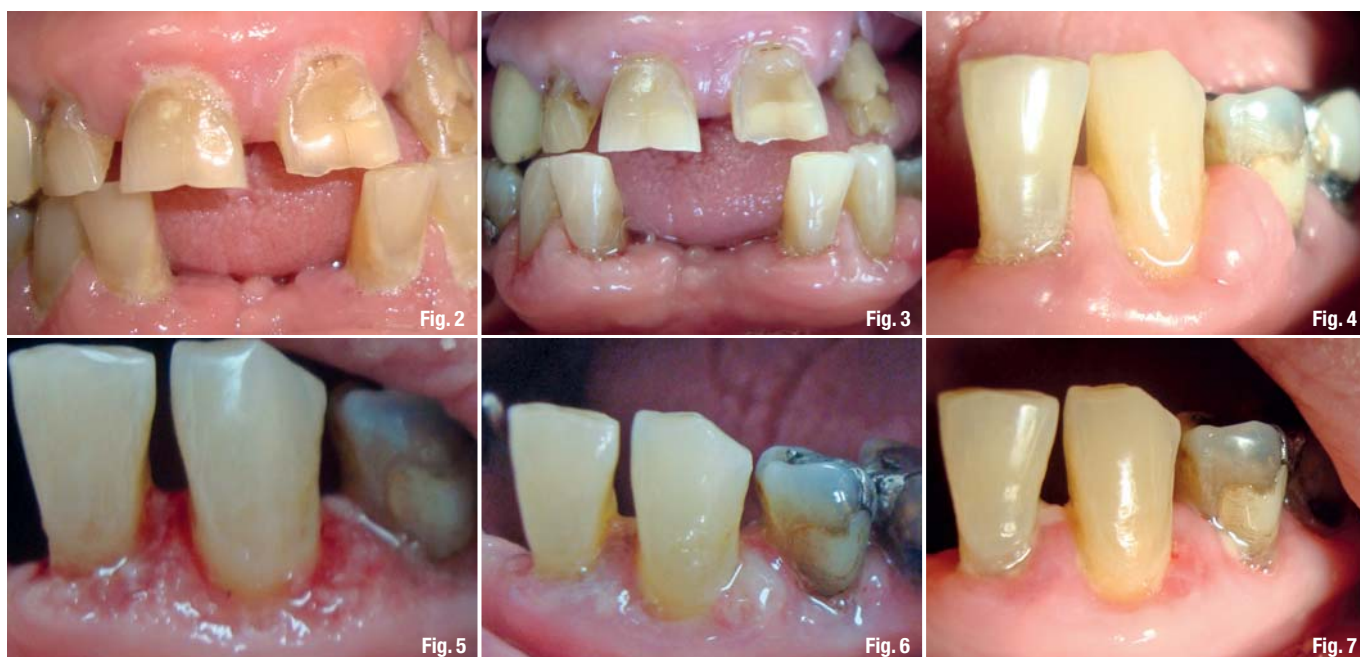

## \_Introduction

According to the Classification System for Periodontal Diseases and Conditions (1999)<sup>1</sup>, drug-induced gingival enlargement belongs to the group of gingival diseases modified by medications which are part of dental plaque-induced gingival diseases. Gingival overgrowth is associated with systemic use of anticonvulsant drugs used for treatment of epilepsy, immunosuppressive drugs used to avoid host rejection of grafted tissues and calcium channel blockers used as antihypertensive drugs. It was first reported by Kimball in 1939 connected to systemic use of phenitoin.<sup>2</sup> Since then, gingival enlargement has been reported in association of administration of several drugs including cyclosporin<sup>3</sup> and different antihypertensive drugs as calcium channel blockers<sup>4,5</sup>, angiotensine converting enzyme (ACE) inhibitors and B-blockers.<sup>6</sup>

Clinically, gingival enlargement is presented as painless, firm, nodular expansion of interdental papilla. It is a generalised condition, but is more severe in the maxillary and mandibular anterior segments. Gingival enlargement occurs in proximity to the teeth and not in toothless jaw sections. Drug-induced gingival overgrowth can occur in sites with minimal or no plaque, but it interferes with oral hygiene and may often lead to chronic inflammation, which complicates the enlargement. In cases with secondary gingival inflammation, the gingiva is bluish-red in colour, with a lobulated surface and a tendency for bleeding.<sup>7</sup>

Histopathologically this condition is presented by hyperplasia of connective tissue and epithelium. There is acanthosis of the epithelium and deep ep-



ithelial ridges are penetrating into the subepithelial connective tissue.<sup>8</sup> The connective tissue presents many blood vessels and inflammatory cells. But the target cells in this disease are the fibroblasts and there is proliferation of fibroblasts and increased formation of collagen fibres.

### **Treatment modalities for gingival enlargement**

The possibility of drug substitution must be discussed with the physician of the patient. Subsequently, a treatment scheme as can be seen in Figure 1 should be considered (adapted from Caranza's Clinical Periodontology).

### **Surgical treatment**

Surgical intervention is the most frequent management strategy for gingival enlargement caused by drugs.<sup>10</sup> Gingivectomy was firstly introduced by Robicsek in 1884<sup>11</sup>, but the procedure that is employed today was first described by Goldman in 1951.<sup>12</sup> Following the rules of the procedure, bleed-

ing points are marked first with probes and then the incision is performed apically from these points in coronal direction. The aim of the procedure is to move out the gingival tissue above the bone crest without touching it and without operating on the bone. The standard gingivectomy procedure is performed with scalpels and periodontal knives.

Later, other techniques were reported like tissue removal by using caustic chemicals<sup>13</sup>, gingivectomy by electrosurgery<sup>14</sup>, gingivectomy by cryosurgery<sup>15</sup> and gingivectomy by lasers.<sup>16</sup> Different types of laser systems can be used in gingivectomy procedures, like CO<sub>2</sub>, diode, Nd:YAG, and Er:YAG. All of them interact in different ways with biological tissues depending on their wavelength.<sup>17</sup>

The Er:YAG laser has the best absorption in water molecules and thus is particularly well suited for the treatment of soft tissue such as the gingiva.<sup>18</sup> In contrast to other laser systems, the Er:YAG does not have haemostatic properties, but the healing process after Er:YAG laser surgery is faster, without thermal damage, necrosis etc.<sup>19</sup>

**Fig. 2**\_Initial clinical situation.

**Fig. 3**\_After professional oral hygiene.

**Fig. 4**\_Before gingivectomy.

**Fig. 5**\_Immediately after laser gingivectomy.

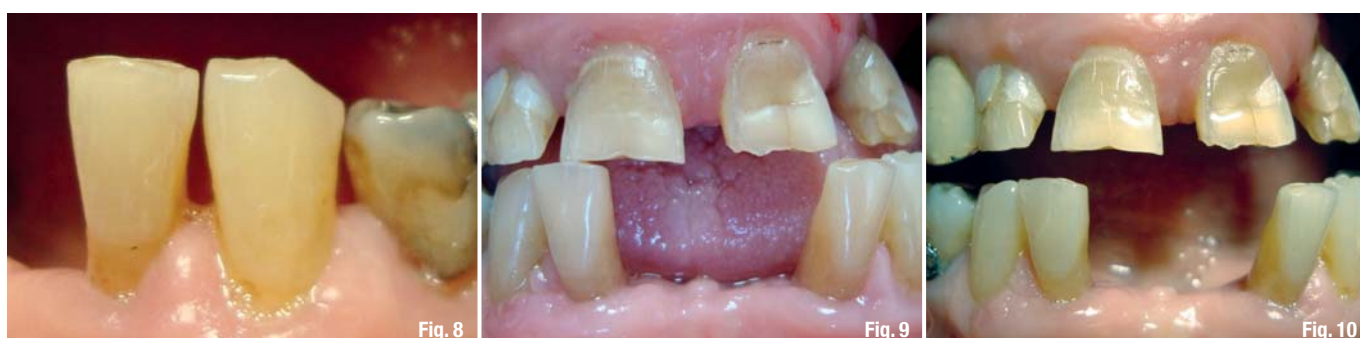**Fig. 6**\_One day after laser gingivectomy.

**Fig. 7**\_One week after laser gingivectomy.

**Fig. 8**\_Six months after laser gingivectomy.

**Fig. 9**\_Two months later.

**Fig. 10**\_Six months after laser gingivectomy.





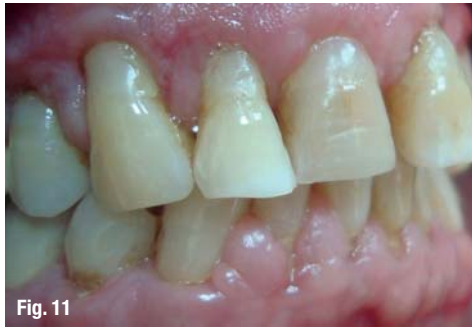

Fig. 11

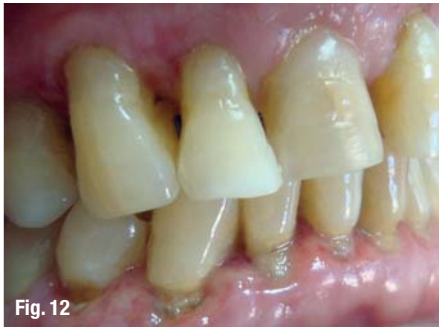

Fig. 12

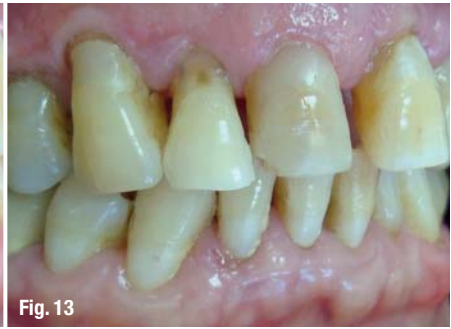

Fig. 13

Fig. 11\_Before gingivectomy.

Fig. 12\_One week after laser gingivectomy.

Fig. 13\_Two months later.

The present report deals with Er:YAG laser surgical treatment of two patients with drug-induced gingival hyperplasia. We assess the treatment results and follow-ups, and investigate the technique to: (a) maximize the precision of the gingival surgery; (b) control postoperative pain after the excision of the hypertrophic gingival tissue; (c) reduce the frequency of relapse in the treated area; and (d) ensure a rapid and compliant postoperative course

### \_Clinical cases

Two patients aged 67 and 73 with complaints of gingival enlargement were referred to the department of Periodontology, Medical University, Plovdiv. Besides gingival hyperplasia, they reported also bleeding gums, halitosis and inability for good oral hygiene.

The patients' medical history revealed systemic use of ACE inhibitors (Prestarium 2.5 mg and Co-Enalapril 20 mg/12.5 mg) for antihypertensive treatment.

The intraoral examination revealed generalised, grade II gingival enlargement<sup>20</sup> in the anterior segment of the mandible (case I and case II) and the maxilla (case II). There was a high score of debris and calculus index according to Greene-Vermillion index.<sup>21</sup> The gingiva showed signs of inflammation as redness, bleeding on probing and suppuration. Halitosis was also detected. The measurement of pocket probing depth revealed deep pockets of about 7–8 mm (Figs. 2–14).

Fig. 14\_Six months after laser gingivectomy.

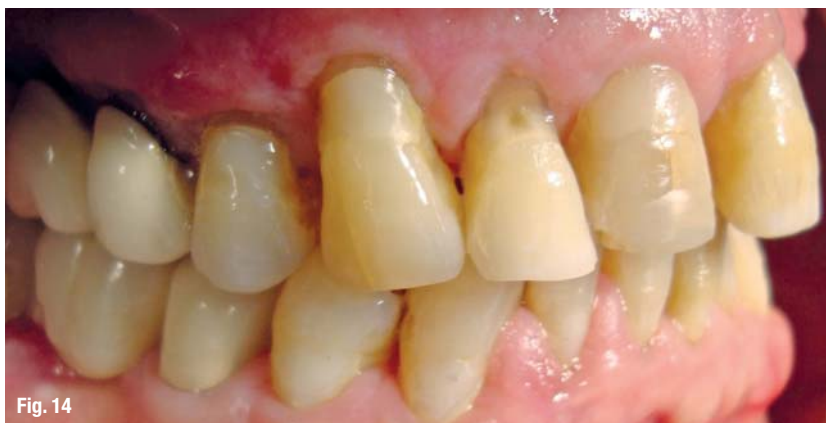

Fig. 14

### \_Management of the patients

Before treatment, a written consent was obtained from the patients and their physicians reported no contraindications for dental procedures. Then, the patients were instructed for intensive oral hygiene including tooth brushing two times a day, rinsing with 0.2% CHX solution and diluted 3% H<sub>2</sub>O<sub>2</sub>. They were also instructed to use additional oral hygiene tools like interdental brushes and flossing once daily. The initial treatment phase also included ultrasonic cleaning with Piezon Master 400 (EMS, Switzerland). Scaling and root planning with Gracey curettes (Hu Friedy, USA) was performed in one week.

Persistent gingival enlargement was evident after one month and laser gingivectomy was performed in two to four sessions (depending on the treated area) with one week interval between sessions.

### \_Laser gingivectomy

Gingivectomy was performed by Er:YAG laser (LiteTouch™, by Syneron Dental Lasers, Israel) at the following settings: 200 mJ, 18 Hz, 3–4 water spray level. External bevel gingivectomy with tip (0.4 x 17 mm) was performed. Only 10% Lidocaine spray was used for local anaesthesia. An excisional biopsy was taken during gingivectomy, which was fixed in 10% formalin solution and referred for pathological examination (Fig. 15). The level of pain and discomfort during the treatment and healing period was assessed by visual analog scale (VAS).

### \_Results

The Er:YAG laser ablated the soft tissue easily and effectively and the procedure was performed with local anaesthesia only. Although the Er:YAG laser does not possess good haemostatic action, there was no excessive bleeding during and after the gingivectomy. Healing and the patients' subjective assessment were estimated one day, one week and one month after the procedures. The healing process pro-

ceeded without complications and side effects. Patients reported score 0 in the VAS examination, which meant absence of pain and discomfort during and after the laser gingivectomy procedure. Pathological examination confirmed the diagnosis gingival hyperplasia. The tissue samples showed no thermal damage in the incision area. Wound healing was fast and complete within one to two weeks. There were no side effects or complications. Patients were monitored for recurrence during a one-year period.

## Discussion

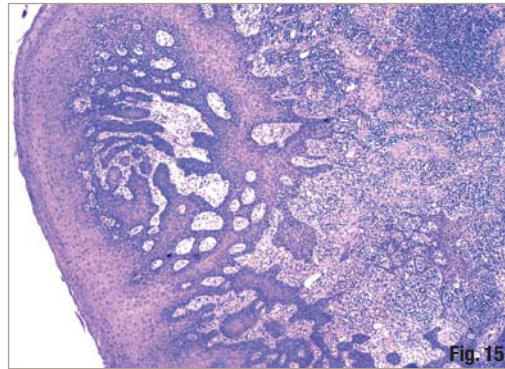
As a first line of treatment for the reduction of gingival overgrowth and anticipating recurrence after surgery, drug withdrawal or substitution was considered. Surgical reduction of the overgrown tissues is frequently necessary to accomplish an aesthetic and functional outcome. The treatment may consist of scalpel gingivectomy or laser gingivectomy. Laser is one of the most promising new technical modalities in periodontal treatment. The Er:YAG laser has a wavelength of 2,940 nm, is well absorbed by water and therefore very effective for the surgery of soft tissues, which have a high water content. The advantages of lasers over scalpel surgery are its relatively better haemostatic effect and pronounced bactericidal effect. Also lasers provide good conditions for an accelerated healing process.

However, the practitioners must have excellent knowledge of their specific characteristics and interactions with the tissues to be properly applied in certain manipulations. In the cases presented, the level of thermal damage caused by the Er:YAG laser does not impact the capability of the histological examination of the specimen's peripheral zone. This correlates with the results of the other researchers investigating laser systems effects on soft tissue in the oral cavity.<sup>23</sup>

The advantage of the LiteTouch™ Er:YAG laser is a shallower penetration of the laser energy into the tissue (0.05 mm) and the presence of additional water cooling.<sup>23</sup> There are different speculations about the laser thermal effects on soft tissue in the oral cavity. Pathomorphological changes obtained by the CO<sub>2</sub>, diode and Nd:YAG lasers are in the zones of moderate and severe thermal damage.<sup>23</sup>

This level of modification makes it difficult or even impossible to accurately evaluate cells' changes in the treated areas.<sup>23</sup>

These results are relevant for the postsurgical period (lack of oedema, pain, necrosis) and treatment outcome. For these reasons, the LiteTouch™ Er:YAG laser is a preferred tool in oral soft tissue surgery for



**Fig. 15** Histopathological view of the excised specimen shows stratified squamous epithelium with proliferating rete ridges; connective tissue showing abundant plump and proliferating fibroblasts that are spindle shaped forming a network. Few endothelial lined blood vessels are also observed (H&E, 60x).

different procedures such as gingivectomy, frenectomy, operculectomy, incisions, etc.<sup>22</sup>

In the presented cases, the gingival overgrowth was treated satisfactorily via initial periodontal therapy including oral hygiene instructions, followed by surgical gingivectomy with LiteTouch™ Er:YAG laser. This case report also demonstrates that without a change in associated drug, a proper periodontal treatment using laser can yield a satisfactory clinical response. However, there is a possibility for the gingival hyperplasia to recur as long as the associated medication is continued and in persistence with other risk factors.<sup>24</sup>

There are a few studies on recurrence rates after a scalpel gingivectomy, but in this case report, patients' follow-up after twelve months showed no signs of recurrence.

## Conclusion

Our case report confirms the effectiveness of the LiteTouch™ Er:YAG laser use for gingivectomy of drug-induced gingival hyperplasia. The treatment was well accepted by the patients, who had no pain and discomfort both during and after the procedure. However, inspection and further assessment of patients are mandatory to avoid relapse.

*Editorial note: A list of references is available from the publisher.*

## contact

## laser

### Dr Blagovesta Yaneva

DDS

3 Hristo Botev Blvd., 4000 Plovdiv, Bulgaria

Department of Periodontology and oral diseases,

Faculty of Dental Medicine,

Medical University-Plovdiv

Tel.: +359 888 53 95 88

b\_yaneva@yahoo.com



[FROGS © ANNEKA]

# The green power

**Author**\_Dr Darius Moghtader, Germany

## \_Introduction

Just in time for last year's DGL Annual Congress, elxxion presented its new and well-noted colouring agent Perio Green, which can be applied in photodynamic therapy with an 810 nm diode laser. This article presents more information about this innovation.

Perio Green is a photodynamic product for the treatment of bacteria in the oral cavity. For its activation, a light source of 780 to 820 nm (laser) is mandatory. This light source must fulfil predefined preconditions (wavelength, output power, applicators). Perio Green is a medical device class IIa.

## \_Indications and mode of action

Until now, elxxion has released the non-surgical therapy of chronic periodontitis as a supplement to the removal of hard dental plaque (root scaling & planing) as well as periimplantitis therapy. Further indications, such as its application in the root canal or in infectious mucocutaneous diseases, for example

herpes, are currently being investigated and will be released when they were examined successfully.

Perio Green's effective component is the colourant indocyanine green. It attaches itself to defined plasma proteins which occur in the membranes of bacterial cells. Upon irradiation with light of a defined wavelength and energy, a chemical bond of the colourant molecule is broken and an oxygen molecule is released (singlet oxygen). Singlet oxygen is highly aggressive and changes the cell wall of the bacterial cells, resulting in their death.

In addition, a quasi-antibiotic effect by disabling the Quorum Sensing is discussed. This means that intercellular communication is hampered. Quorum Sensing is used by bacteria to coordinate processes which would be inefficient if they were conducted only by a single cell, for example the production of biofilm or pathogenicity factors.

Additionally a thermal effect concentrated on the bacteria is discussed using 300mW. The low viscosity of Perio Green ensures a safe and complete, independent penetration of the colourant to the bottom of the pocket without any help from the dentist. A subsequent rinsing of the pockets is not necessary. After the therapy, there is no colouring of the mouth or the lips which might trouble the patient.

## \_Case presentation

The first patient who was treated with Perio Green in our practice was a case which is familiar to most dentists. This patient is a nonsmoker, does not suffer from diabetes, but from a normal amount of stress and a rapid formation of calculus and attends our practice for professional oral hygiene two to four times a year. He cleans his interdental spaces daily with interdental brushes and his teeth with a Curaprox supersoft toothbrush applying the Bass technique.

**Fig. 1**\_Initial X-ray.

**Figs. 2 & 3**\_Sensitive tooth necks in the front area.

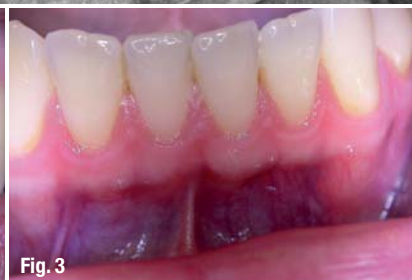
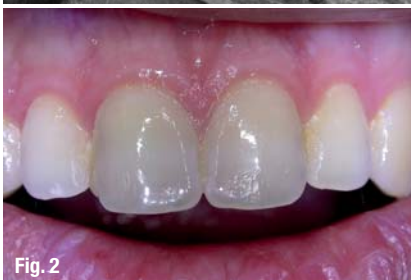
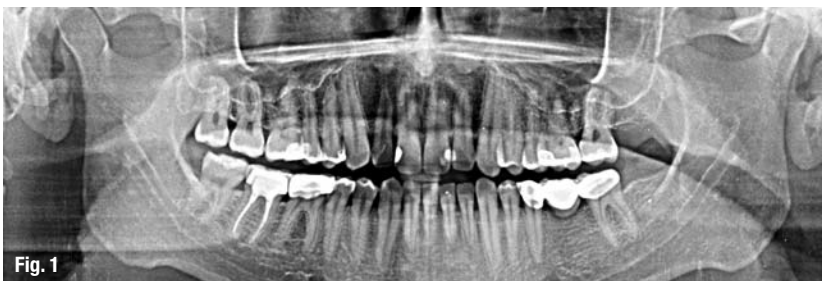



Fig. 4

PSI, API and PBI do not indicate any periodontal disease. Impressions remain inconspicuous (Fig. 1) and the probing depths of 1 up to 3 mm are within the physiological level. No concretions were found.

So was everything alright? Was it not? On several occasions a year, this patient presents with painful and bleeding localised complaints. These are accompanied by sensitive tooth necks especially in the front area (Figs. 2 & 3). These problems usually prevail for one or two days and have often disappeared altogether until his appointment in our practice. However, loosening of the tissue and a distinct reddening were maintained. There was no bleeding upon probing, but bleeding occurred after professional oral hygiene in a higher degree and for an above-average amount of time. Therefore, we suspected bacterial infection with periodontally pathogenic germs. MIP basic test (Fig. 4) confirmed this suspicion and gave evidence for an infection with an enhanced number of *Treponema denticola*. The patient gave his informed consent for therapy with Perio Green.

After the careful removal of plaque and rinsing of the pockets via low-level ultrasound, Perio Green was applied (Fig. 5) in order to create an aquatic space (Fig. 6). Afterwards, the obligatory internal activation of the colouring agent with an ellexion diode laser of a wavelength of 300 mW and a 300 µm-PA fibre was conducted for 30 seconds vestibularly and orally. The periodontium of each tooth was irradiated for 30 seconds vestibularly and externally, orally with the glass rod T6 of the ellexion Pico in the Perio Green programme with 300 mW (Fig. 7). According to the manufacturer, this step is facultative. The bacterial load of tongue and throat were treated equally (Fig. 8). After two weeks, the patient attended the practice for check-up and MIP bacterial basis test (Fig. 9). The test showed that the elimination of the bacteria was successful. The clinical images showed firm tissue with a healthy, pale pink colour (Figs. 10 & 11). The patient reported that he did not feel any dentin hypersensitivity and has not had bleeding or inflammation for six months.

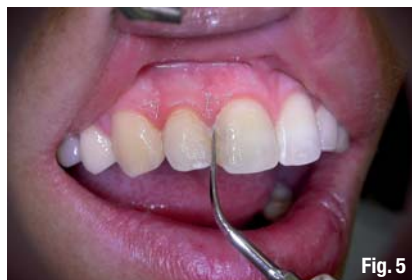

Fig. 5

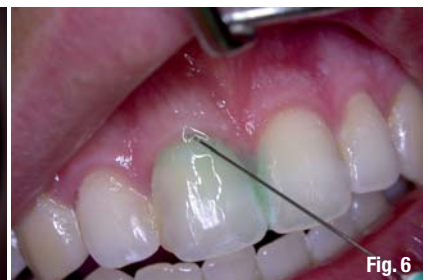

Fig. 6

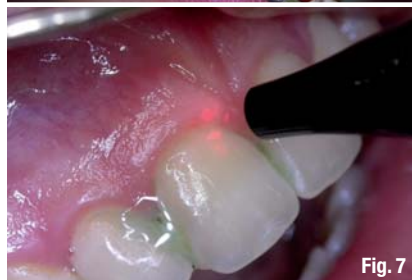

Fig. 7

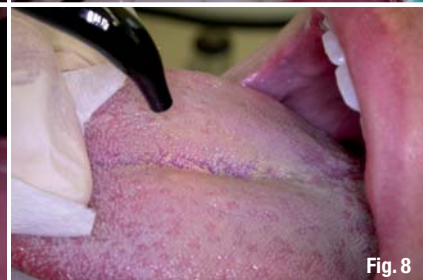

Fig. 8

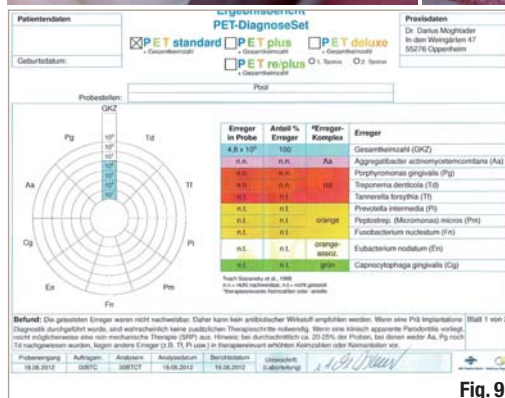

Fig. 9

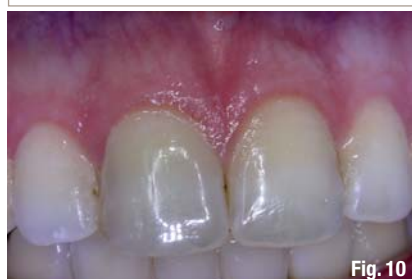

Fig. 10

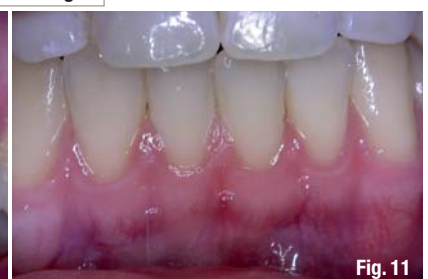

Fig. 11

## Conclusion

These first results give reason for the optimistic view of Perio Green offering another effective therapy option against the widespread disease of periodontitis. We are looking forward to seeing further research in order to find scientific proof for these empirical findings.

## contact

**Dr Darius Moghtader**  
In den Weingärten 47  
55276 Oppenheim, Germany

dr-moghtader@hotmail.de  
www.oppenheim-zahnarzt.de

## laser

**Fig. 9** MIP basis test. The control test after treatment proves the successful bacteria reduction.  
**Figs. 10 & 11** Clinical pictures.

# Gain **power** at your **laser** clinics!

**Author**\_Dr Anna Maria Yiannikos, Germany/Cyprus

## \_Introduction

We are not only dentists, we are the managers, the leaders of our clinics, we are the ones that are responsible for the selection, training and appraisal of our employees, we are the ones that must communicate clearly with our patients, negotiate with our colleagues and suppliers—we deal with so many different aspects every day in order to be sustainable and profitable. But who knows exactly what to do? We are taught none of the above from our dental schools, we find out through the difficult way—if we are lucky from the mistakes of our colleagues if we are not from our own. Mastering our dental management skills is all about being the one that will:

1. Control our team. In this fast food era that we all live in, we face problems with our staff we must solve urgently. Otherwise, they can cause us extra money and time. We might have different generations in our workplace, let's acknowledge their characteristics and treat them accordingly. For example, if one of our staff members belongs to the millennium generation (born between 1980–2000) we should use different phrases to motivate them: "You will be working with other bright, creative people." On the other hand, if our employees belong to 'XERS' generation (born between 1965–1980), let's express our coaching ability through phrases like, "You and your co-workers can help turn this clinic around" or "You can be a hero here".
2. Control our accountant by learning their jargon so to read our financial statements in order to prevent mistakes that could cost us.
3. Find our unique and personal style that will enable us to present with confidence dental cases to our patients or make presentations in congresses.

4. Knowing how to be proactive and not reactive.
5. Be aware of our patients' behavior and needs.
6. Learn how to develop and 'read' patient satisfaction surveys.
7. Finding our own 'equilibrium' based on the principles of economics, the right amount of money that our employees should be paid, all the economic vocabulary that affect us directly, what is our opportunity cost for a purchase of a laser equipment—study each purchase without acting only with impulse!
8. Finally remember the approach that we should have for our laser marketing: The holistic approach!

In the 1980s, Terrance Rynn a leading healthcare marketing consultant embraced a profound concept about the difference between marketing and selling:

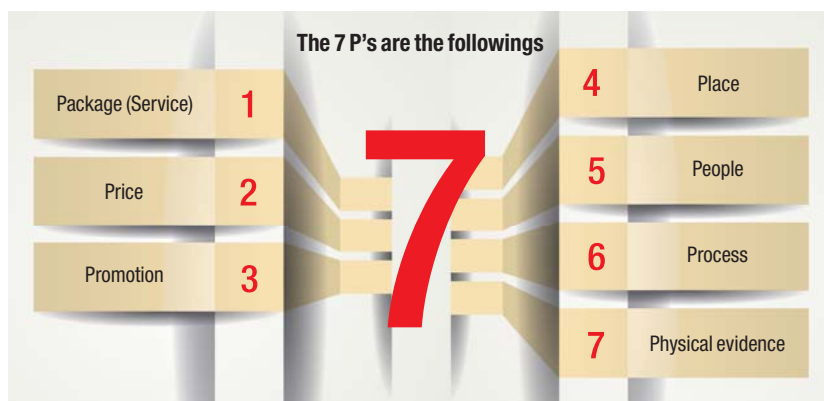
*"Selling is trying to get people want what you have, but Marketing is trying to have what people want. When you have what people want then it makes selling unnecessary!"*

Always have in mind that we are doctors. We do not sell, we treat people!

Let's take laser treatment as an example where we cover our patient's needs for:

- Minimal pain
- Minimal or no anaesthesia
- No drill sound
- Less fear, anxiety, stress
- Minimal or no bleeding
- Faster healing
- Reduced post-operative complications
- Less time in dental chair.

Marketing is not only advertising and promotion, on the contrary, it is the combination of seven elements, the 7 Ps and each one of these aspects should make obvious our high tech laser clinic. My goal during the next issues is to give you a short description of the above so to deliver and follow them in our clinics. And yes, mastering dental management skills is all about learning how to gain your power!\_



## \_contact

**laser**

**Dr Anna Maria Yiannikos**

Adjunct Faculty Member of AALZ at RWTH Aachen University Campus  
DDS, LSO, MSc, MBA

# dental tribune istanbul



## ISTANBUL WELCOMES DENTAL PROFESSIONALS

22 International Speakers

Lectures on implantology, oral surgery, aesthetics, endodontics, laser dentistry

Workshop / Live demonstrations

Hands-on courses

Visit free exhibition area on 2.500 sqm

Enjoy open buffet lunch from the chef masters

Online congress booking is available at

[dentalistanbul.com](http://dentalistanbul.com)

To book your booth please contact [derya.arslan@vyg.com.tr](mailto:derya.arslan@vyg.com.tr)

**di** **DENTAL  
ISTANBUL'13**

ARALIK / DECEMBER 07-08, 2013  
GRAND CEVAHİR KONGRE MERKEZİ

**dti** Dental  
Tribune  
International

**vyg**  
vestiver  
publishinggroup



# Manufacturer News

Henry Schein

## New advanced diode laser system

The CAO Group (CAO), a world-leading, high-technology dental company, has launched the latest in restorative dental products with the new Precise®SHP Diode Laser, equipped with the most sophisticated technology for diode laser procedures. The product will be available exclusively through Henry Schein Dental, the global dental business of Henry Schein, Inc. (NASDAQ: HSIC).

The Precise SHP Diode Laser, designed with state-of-the-art laser technology, is the first mobile touch-screen diode laser to feature the iPod touch®. This comprehensive laser system provides live support via FaceTime® and allows dentists to watch training videos and demos as well as stay current with unlimited updates.

The Precise SHP Diode Laser System is highly versatile with 21 presets covering a wide spectrum of specialties, making everyday dental procedures easier to perform with excellent outcomes. The SHP Laser also features access to step-by-step setup instructions, laser procedure demonstrations and training videos, all through the iPod touch. FaceTime can be used to directly



contact CAO technical, clinical and customer support experts.

The Precise SHP Diode Laser provides temporary pain relief for soft tissue, joint and muscle pain, offers laser-assisted in-office professional teeth whitening and is ideal for a multitude of procedures to avoid the difficulties of scalpel use such as bleeding, swelling, infection and pain. Additionally, the Precise SHP is the first diode laser system to include sterilised, disposable fiber tips for every procedure.

The Precise SHP Diode Laser is currently available in the US only. For more information about the Precise SHP Diode Laser, visit [www.precise-lasers.com](http://www.precise-lasers.com) or [www.henryscheindental.com](http://www.henryscheindental.com).

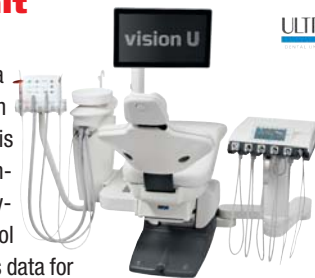**Henry Schein**  
Corporate Headquarters, USA  
135 Duryea Road  
Melville  
NY 11747, USA

[www.henryschein.com](http://www.henryschein.com)

ULTRADENT

## The (r)evolution of the treatment unit

vision U, the new multimedia system is so much more than an output device. vision U is also an input device, entertainment and infotainment service, provides system control and remote diagnosis, saves data for quality management and can even be used as a diagnostic monitor for X-ray images. vision U is intuitive and really easy to operate. The interactive multimedia system with a 21.5-inch high-resolution multi-touch screen with multi-touch gestures is as easy to use as a tablet computer and meets all the requirements of dental practices now and in the future. vision U is, of course, approved by the MPG (German medical devices law). vision U provides an additional function that records all data before, during and after treatment. Together with the ULTRADENT premium class, vision U realizes many technical visions, ensures captivation, satisfaction and a future-oriented dental practice. So, enjoy this (r)evolution and put this innovation to use in your dental practice.



ULTRADENT

**ULTRADENT**  
Dental-Medizinische Geräte GmbH & Co. KG  
Eugen-Sänger-Ring 10  
85649 Munich, Germany

[info@ultradent.de](mailto:info@ultradent.de)  
[www.ultradent.de](http://www.ultradent.de)

Syneron Dental Lasers

## LiteTouch™ wins prestigious Red Dot Design Award

Syneron Dental Lasers has been selected among the winners of the international Red Dot Award for product design in the Science and Medicine Category. LiteTouch™ laser was awarded the internationally renowned Red Dot Design Award. This year, a jury of international experts evaluated over 4,700 entries



initiator and CEO of the Red Dot, has pointed out that strong design competence and economic success nowadays go hand in hand: "The winners of the Red Dot Award: Product Design 2013 are the protagonists of a highly developed design culture and design industry. Those product creations that

pass the test before the critical eyes of the international Red Dot jury will not disappear into the crowd and will be able to fend off global competition." Syneron Dental Lasers is the inventor of ground-breaking LiteTouch, the most versatile dental laser for hard & soft tissue treatments.

Its innovative Laser-in-Handpiece™ mimics the feel of the turbine drill, yet incorporates laser unique benefits: micro surgery, quicker healing, minimal invasive treatments and higher acceptance of patients to dental treatments.

**Syneron Dental Lasers**  
Tavor Building, Industrial Zone  
20692 Yokneam Illit, Israel

[dental@syneron.com](mailto:dental@syneron.com)  
[www.synerondental.com](http://www.synerondental.com)

# Moscow 2014



## Dental-Salon

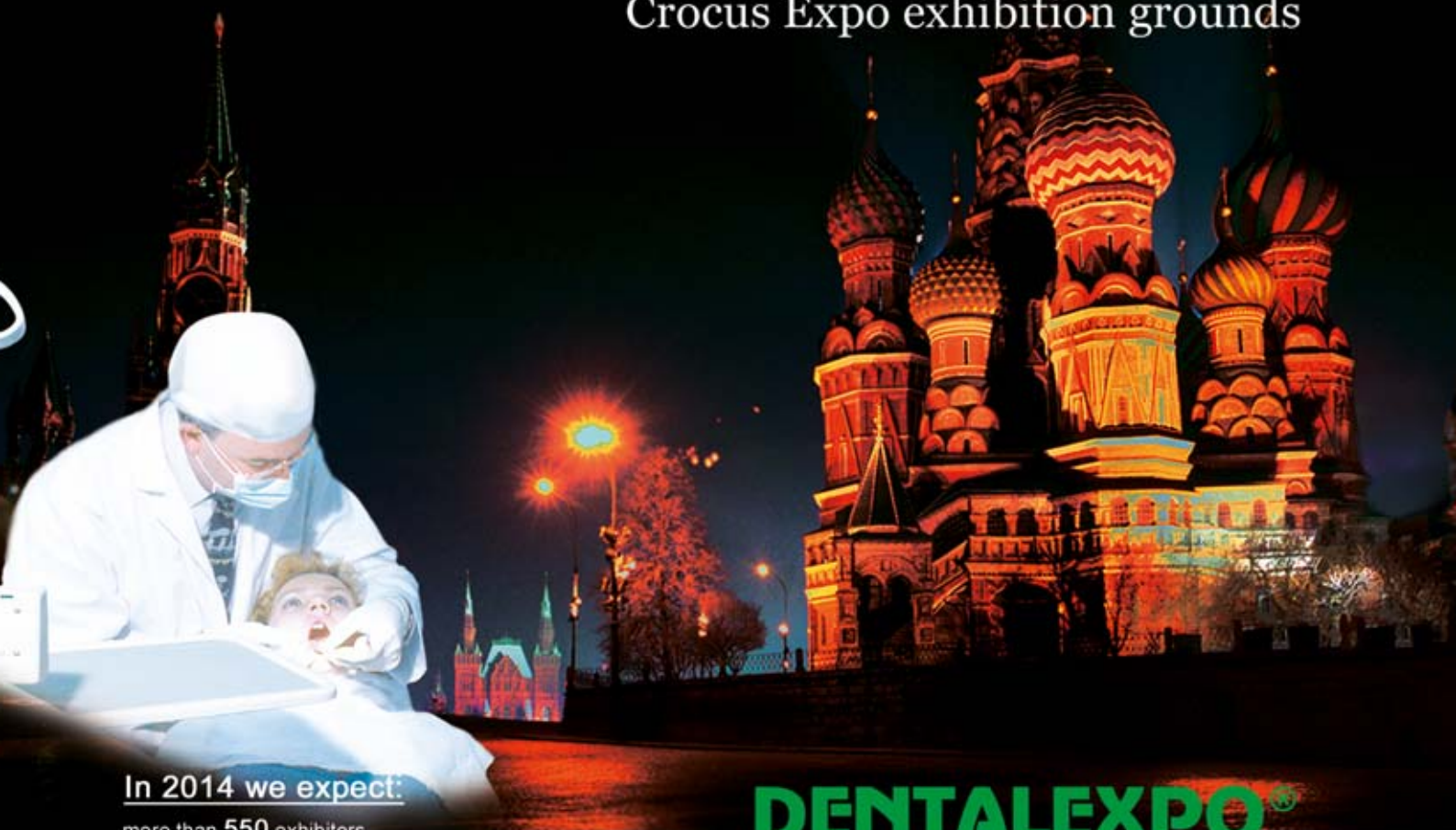April 21-24



## Dental-Expo

September 29 - October 2

Crocus Expo exhibition grounds



### In 2014 we expect:

more than 550 exhibitors  
more than 30000 visitors  
more than 30 countries  
more than 500 lectures

## DENTALEXPO®

[www.dental-expo.com](http://www.dental-expo.com)

[international@dental-expo.com](mailto:international@dental-expo.com)

# “ Ultimately, I wish for laser education to be completely integrated within the school of dentistry, everywhere ”

An interview with Macedonian Professor Ana Minovska

In a recent interview with Prof. Ana Minovska, DDS, PhD of the Faculty of Medical Sciences, General Stomatology University "Goce Delcev" Stip, R. Macedonia. Prof. Minovska talked about the Er:YAG-laser assisted periodontal dental treatments and the importance and benefits of laser based treatments.



Professor Ana Minovska

**laser:** Please tell us about your clinical daily routine and patients.

Besides being a professor at the Faculty of Medical Sciences, I also manage a dental clinic, which provides our patients with comprehensive oral health care. We incorporated laser technology early on in order to realise the idea to shift from mechanical generated technology to a light-generated practice. The process of

shifting our clinical work to laser energy took a couple of years to implement, but today, all general practitioners at my clinic are using the Er:YAG dental laser to perform a wide range of dental procedures. Most patients are not aware of the numerous benefits of laser dentistry, so we make sure to inform them. Once they become aware of the unique benefits they stop avoiding routine check-ups.

What are the most popular procedures performed at the clinic? At ETERNAdent, we conduct general oral care, but are best known for periodontal procedures. Just like everywhere in the world, in Macedonia too, there is a growing need for periodontal treatments and surgery. We have incorporated the Er:YAG (2,940 nm) laser at our clinic because of its unique clinical benefits, which include bactericidal effect, which eliminates most of the existing bacteria, its homeostasis ability for better healing, its ability to selectively ablate granulation tissue, soft tissue surgery, and many others. We also provide our patients with treatments in restorative dentistry, oral surgery, cavity preparations, implantology, prosthodontics and cosmetic dentistry. My team consists of professional dentists all of whom implement the Er:YAG laser in most of their procedures.

**laser:** Please share with us highlights of your academic career.

I have been part of the academic world for the past 31 years. So I have vast experience working with students and in a variety of research fields. During my career as a professor at the Faculty of Dentistry at University Ss Cyril and Methodius of Skopje, I held various positions, including Director of Clinical Research and Deputy Dean of Dental Medicine. I also founded the School of Oral Hygiene programme, which is now an integral part of the Faculty of Dentistry at University Ss Cyril and Methodius of Skopje.

Throughout the years, I did a lot of dentistry-related work, but in recent years have been spending my



time on research, mainly focused on the clinical benefits of laser energy on the human body and oral health. In one case we conducted a scientific comparison of laser-assisted bleaching vs. the conventional plasma arc light accelerated bleaching method. In another research we found the use of Er:YAG advantageous for desensitisation of sensitive cervical areas, treatment of herpes simplex, pericectomy and other issues. Features like minimal invasiveness, bio-stimulation and growth factors generation are extremely important in achieving better clinical results, and it is fascinating to see that the Er:YAG laser has so many virtues.

*Prof. Minovska, based on your experience, how do you see the future of laser dentistry?*

The use of Er:YAG laser technology is growing very quickly. However, with regards to dentistry, I believe that we need a laser that can be used by general dentistry. We need a laser wavelength that can be used in the treatment of soft and hard oral tissues and for a wide variety of purposes. The dental laser should be able to fulfil all the requirements of conservative dentistry or the mechanical approach for performing everyday dentistry. Now that research has demonstrated that Er:YAG is the ideal wavelength, there is a growing number of experts gaining substantial experience and who are strong supporters of the technology. It is clear that traditional dentistry must change, just as laser has become an integral tool in eyes and ENT surgeries. I am sure the same will happen in dentistry. Personally, I prefer Er:YAG, as it allows me to provide my patients with better clinical results and service. I have also worked with diodes and Nd:YAG, but I can tell you that I will be sticking to Er:YAG because it can be used in such a variety of dental fields.

*What kind of dental lasers do you use at your clinic and for which treatment?*

At my clinic, I have two lasers: a Fotona laser and the LiteTouch from Syneron Dental Lasers. These two give me a combination of Er:YAG and Nd:YAG. Both these lasers are very good and I can use either one of them to perform similar treatments. However, their technological concept is very different. The LiteTouch is easy to use thanks to its unique Laser-in-the-hand-piece™ technology, which allows me freehand movement. I also like the fact that it is small and can easily fit anywhere in the clinic. Its friendly shape and the fact that it's very quiet (doesn't make a mosquito sound) turns it into a "fear buster", allowing me and my team to calm patients before treatment.

*What do you feel should be the role of the academia in the introduction of laser dentistry?*

The first step is for dentists to become more familiar with laser dentistry and gain a deeper understanding of the vast treatment abilities of the laser light. I believe this is in the hands of academic institutions—they

must take responsibility for exposing new discoveries and technologies to future generation practitioners. This particular technology allows us to use the energy of light we use every day also in the field of dentistry. Ultimately, I wish for laser education to be completely integrated within the school of dentistry, everywhere. I am currently the President of ETERNITAS, The Macedonian Society of Oral Laser Applications, and we have committed to broadening and spreading the knowledge of lasers.

*What was the theme of the congress held in Skopje and how did it contribute to the promotion of laser dentistry in the region?*

As organisers of the 18<sup>th</sup> congress, we promoted the idea of implementing, positioning and establishing laser dentistry education. This area is very new not only in Balkan countries, but to the rest of Europe's dental professionals. I believe that at this Congress, laser dentistry was brought closer than ever before to traditional dentistry, and dentists were able to see for themselves that everything that can be done in traditional dentistry can also be realised with a brand new instrument that happens to use laser technology.

The association of dentists, ETERNITAS, received the great honour of organising this year's congress in Macedonia. The congress took place from 23 to 25 April at the Hotel Aleksandar Palace in Skopje, with more than 400 dentists from the region actively participating. The theme of the Congress was "Where the Future of Dentistry Stands", and we had a series of excellent lectures on laser dentistry by top professionals in the field, including: Prof. Adam Stabholtz and Dr Sharonit Sahar-Helft both from the Hebrew University of Jerusalem, Prof. Jean Paul Roca from the University of Nice, and Dr Avi Reyhanian, an outstanding Israeli practitioner who shared his experience of working with the Syneron Dental Lasers device.

We hope that the congress demonstrated our great enthusiasm of modern dentistry and we hope that we were able to demonstrate why laser dentistry, as a field, is beneficial to both the patients and the dentists, and should be practiced much more intensely.

## \_contact

## laser

**Prof. Dr Ana Minovska, DDS**

ETERNAdent

Skopje, R. Macedonia

Tel: +389 23091470

aminovska@eternadent.com.mk

www.eternadent.com.mk

# 1<sup>st</sup> Meeting of the WFLD North American Division

**Author**\_Prof. Dr Georgios Romanos, USA

The Stony Brook University, School of Dental Medicine, hosted the first meeting of the World Federation of Laser Dentistry (WFLD), North American Division on May 10, 2013 at the newly opened Hilton Garden Inn Hotel located on the Stony Brook University Campus. Close to 100 participants from the United States, but also from other countries, especially South America, had the opportunity to learn about the innovative laser technology and the applications of lasers in all areas of dentistry. The meeting was co-sponsored by a dental publishing house as well as corporate sponsors from different laser companies. The aim of the World Federation for Laser Dentistry (WFLD) is to serve as a non-profit medium for the exchange, advancement and dissemination of scientific knowledge, related to the use of lasers for application and research in the oral and dental environment. The Dean of the School of Dental Medicine, Dr Ray Williams (Stony Brook, NY) opened the meeting and welcomed the guests. He congratulated the team responsible for the organisation and emphasised the importance of incorporating lasers in dental education. "Laser technology is part of our education at the School of Dental Medicine", he said and "we are interested for the innovation and latest news to improve the quality of patient care."

The Chair of the North American Division of the WFLD and Associate Dean for Clinical Affairs at Stony Brook University, School of Dental Medicine, Dr Georgios Romanos (Stony Brook, NY) introduced the WFLD organization, its history and role of the WFLD in the laser dental community and the role of lasers in the dental profession. He introduced the speakers, who all have diverse

clinical and research backgrounds, and informed about their professional accomplishments in laser dentistry.

The meeting contained information about basic laser physics, the properties of laser light, the role of light absorption by the chromophores and the use of specific laser wavelengths in the dental fields. Dr Robert Convisar (New York, NY) focused on the use of lasers in general dentistry, important aspects of the laser marketing and the costs of the laser technology, which is significant in order to promote this technology in the dental profession. According to his lecture, training is important and should be provided by the laser companies. Peer-reviewed literature should follow in order to make the correct decision in the purchase a laser. He presented a high number of clinical cases treated by different laser wavelengths with main focus on operative dentistry, pediatric dentistry and periodontology. His final statement was to improve the internal marketing, educating the medical doctors (in hospitals and private practices) about the possibilities of laser dentistry. Dr Khalid Almas came from the University of Connecticut, School of Dental Medicine and presented the criteria of evidence to make the assessment for decision-making in laser dentistry. Based on his presentation, there are so many differences in publications and the role of Patient and Problem, Intervention, Comparison and Outcomes (PICO) questions is important to present quality, quantity and consistency of evidence. Bringing examples from the literature, he was able to show differences in the examined parameters to grade the quality of evidence and to balance between desirable and undesirable effects. The speaker was able to show the increase





of publications of laser dentistry in the last ten years according to data presented via Pubmed. He demonstrated the number of meta-analyses in the various fields of dentistry, such as scientific publications of the lasers and oro-facial pain, lasers in pediatric dentistry, lasers in endodontics, lasers in orthodontics, lasers and photodynamic therapy (PDT) and last but not least lasers in the treatment of periimplantitis. The third speaker of the day focused on the use of lasers in oral surgery. Dr Georgios Romanos (Stony Brook, NY) presented clinical studies and case series. Through a step-by-step analysis, he illustrated in his presentation the different clinical examples of the surgical treatment of benign tumors with various wavelengths (CO<sub>2</sub>, diode lasers), the removal of vascular lesions using the Nd:YAG or high power diode lasers. The removal of leukoplakia using the CO<sub>2</sub> laser and bone removal for implant placement with the laser-assisted technology, like the use of the Er:YAG or Er,Cr:YSGG laser was also part of his presentation. He was able to clearly demonstrate evidence of excellent wound healing without postoperative complications, such as bleeding and scar tissue formation. The next presentation provided scientific information about the use of photodynamic therapy (PDT) in the dental profession. Dr George Bilalis (New York, NY) presented the different studies with PDT in the areas of cancer treatment, periodontal therapy and use of this method in the treatment of periimplantitis. He was able to explain the role of the different photosensitisers for the effective use of PDT and also to differentiate the laser systems of the market in order to provide a good clinical outcome.

Further presentations of the day (Dr Georgios Romanos, Stony Brook, NY) included the use of laser systems in the treatment of periodontal and periimplant diseases. He reviewed different concepts of therapeutic options using laser technology, such as the decontamination of implant surfaces, reduction of periodontopathogenic bacteria in the pockets, stimulation of the bone and improvement of healing, the use of soft lasers for bone regeneration and the use of surgical lasers for crown lengthening procedures without flap elevation.

The afternoon was filled with new advances in laser technology using low intensity laser therapy (LILT). One of the well-known international leaders in the field,

Dr Aldo Brugnera (President of the WFLD, Unicastelo, Brazil) was able to present animal and clinical studies, promoting the healing in chronic wounds, and improving the postoperative clinical result, reducing the pain using the correct dose and method with LILT. One of the final presentations was focused on the use of lasers in orthodontics to reduce pain during orthodontic treatment and also to accelerate the dental movement in order to improve the clinical outcome. Dr Celestino Nobrega (São Paulo, Brazil) enthusiastically covered his topic and provided a lot of good energy to the audience with new ideas and future trends of the use of low power lasers in dentistry.

The last lecture was given by Dr Robert Convisar (New York, NY) who reviewed the requirements for laser safety using all different laser systems. He also explained the role of the laser safety officer for the dental office and classified the lasers according to safety groups. The meeting was finalised with a written examination for participants to achieve Basic Laser Certification, according to the WFLD requirements. The full day of learning was concluded with a wine reception, where speakers and attendants had the opportunity to chat and network. During the course of the meeting, participants had the opportunity to visit the exhibition of the laser systems. They had the chance to learn more about the various laser systems and have the opportunity to receive some hands-on training in the use of CO<sub>2</sub> lasers (LuxarCare), diode lasers (Alta), Er,Cr:YSGG lasers (Bio-lase) and other lasers that were being showcased, such as systems of Helios Laser Inc. (Henry Schein) and AMD lasers (DENTSPLY).

For new members of the WFLD please visit the official website of the WFLD at [www.wfld-org.info](http://www.wfld-org.info).

#### \_contact

#### laser

##### WFLD – Germany

Pauwelsstr. 30  
52074 Aachen  
Tel.: 0241 8088164

[www.wfld-org.info](http://www.wfld-org.info)



## Sleep deprivation

### Affects facial appearance



In order to investigate the facial cues by which individuals recognise that someone is sleep deprived, the researchers at the Karolinska Institute in Stockholm photographed the faces of five men and five women after eight hours of normal sleep and after 31 hours of sleep deprivation. Afterwards, 20 male and 20 female participants with an average age of 25 rated the photographs with respect to fatigue, facial cues and sadness.

Overall, the faces of sleep-deprived individuals were perceived as having more wrinkles or fine lines and droopier corners of the mouth, the researchers reported. The participants also stated that those who had slept less had droopier eyelids, redder eyes, eyes that were more swollen, darker circles under the eyes and paler skin. In addition, sleep-deprived individuals appeared sadder than after normal sleep, and this apparent sadness was related to looking fatigued.

“Since facial regions, such as the eyes and mouth in particular, contain a lot of information on which humans base their interactions with each other, how fatigued a person appears may affect how others behave toward him or her,” said Tina Sundelin, lead author and a doctoral student at Stockholm University’s Department of Psychology.

The study, titled “Cues of fatigue: Effects of sleep deprivation on facial appearance”, was published in the September issue of the *SLEEP journal*.

## American Dental Association

### Statement on Regular Dental Visits



To maintain optimal oral health, the American Dental Association (ADA) recommends regular dental visits, at intervals determined by a dentist. In light of a new study published in the *Journal of Dental Research* titled “Patient Stratification for Preventive Care in Dentistry,” the ADA wants to remind consumers that the frequency of their regular dental visits should be tailored by their dentists to accommodate for their current oral health status and health history. In the June 10 issue of the journal, researchers from the University of Michigan School of Dentistry explored

the link between long-term tooth loss and frequency of preventive dental visits in adults with and without three risk factors for periodontal disease: smoking, diabetes and interleukin-1 genetic variations.

The study concluded that individual risk factors help to dictate the frequency of cleanings needed per year to help prevent periodontal disease. Based on data analysis, researchers speculate that high-risk patients would likely benefit from more frequent dental visits, while low-risk patients may see the same benefits from only one cleaning per year. The key takeaway for consumers, underscored by this study, is that personalised oral care is a necessity for good dental health. The ADA encourages people to work closely with their dentists to identify any potential risk factors that would determine the need for and frequency of follow up visits to enhance the outcomes of preventive care.

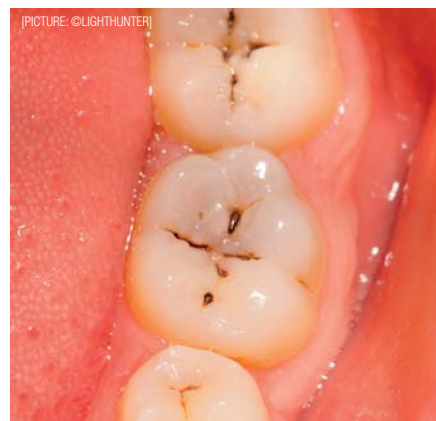For more information on the ADA’s recommendations for healthy teeth and gums at every life stage, please visit [mouthyhealthy.org](http://mouthyhealthy.org).

## Dental caries may

### Prevent oral cancer

In order to test the association between dental caries and head and neck squamous cell carcinoma, researchers from the University at Buffalo examined the oral cavities of 399 patients diagnosed with primary head and neck squamous cell carcinoma between 1999 and 2007, and 221 healthy controls.

They observed that cancer patients had a significantly lower mean number of teeth with caries, crowns, endodontic treatment and fillings. However, they had more missing teeth compared with controls. After adjusting for age, sex, marital status, smoking status and alcohol use, the researchers found that the prevalence of head and neck squamous cell carcinoma was lower among participants with prevalent dental caries and more crowns.



Although the mechanism underlying this inverse association between head and neck squamous cell carcinoma and dental caries is not fully understood by the scientists, the study suggests that lactic acid bacteria, which demineralize tooth structures, and their associated immune response may have a positive effect on the cancer cells.

According to the Centers for Disease Control and Prevention, dental caries is the most common chronic disease among children aged six to eleven years and adolescents aged twelve to 19 years in the US. It also affects the majority of adults, with nine in ten over 20 having some degree of tooth-root decay. More than 30,000 new cases of cancer of the oral cavity and pharynx are diagnosed each year. The study, titled “Dental Caries and Head and Neck Cancers,” was published online on Sept. 12 in the *JAMA Otolaryngology—Head and Neck Surgery journal*.

Laser therapy could help

## Relieve pain after orthodontic treatment

Many patients experience significant levels of pain or discomfort after the placement of separators before band placement to separate the molar teeth. Now, a team of Korean researchers has suggested that laser therapy might be an effective method of reducing such orthodontic pain.

The study included 88 patients who received elastomeric separators on the first molars. To determine whether low-level laser therapy (LLLT) would have an effect on the participants' perception of pain after separator placement, the patients were randomly assigned to a laser group, a light-emitting diode (LED) placebo group and a control group. After irradiation of the molars for 30 seconds every twelve hours for one week, significant differences in pain perception among the three groups were reported. The researchers observed that pain scores in the laser group were significantly lower than in the control group up to 24 hours after placement. However, no such effect was found in the LED group.

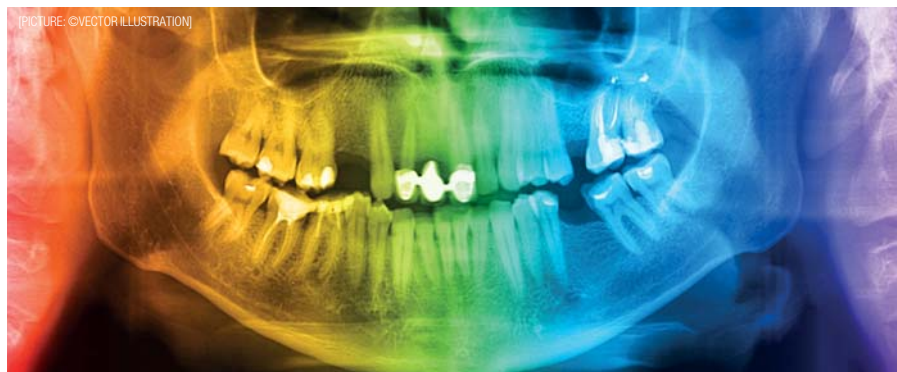
Thus, the scientists concluded that frequent LLLT may be an effective way to reduce orthodontic pain for the first day after separator placement. In addition, the researchers observed that the perception of pain was not significantly different based on age or sex. However, the effect of laser irradiation was more pronounced in male subjects.



According to the study, the effect can mainly be attributed to the anti-inflammatory properties of the laser and its regenerative effect on neurons. The findings are in line with those of previous studies that have demonstrated that LLLT may increase the blood supply and promote healing of dental tissue. The study, titled "Effect of frequent laser irradiation on orthodontic pain", was published in the July issue of the *Angle Orthodontist journal*.

Pakistan introduces

## First oral diagnostic lab



The scope of Oral Pathology has always been restricted to histopathology only. Now a wide range of oral diagnostic investigations are being brought to Pakistan and are being offered from this platform where saliva is being used to detect different pathologies.

Pathodont is the first laboratory and diagnostic center in Pakistan that is dedicated solely to oral health. In addition to providing maxillofacial and oral diagnostic services, Pathodont has introduced state of

the art American Biolase laser technology in Pakistan for the first time. As a leader and a pioneer in providing diagnostic opportunities to maintain oral health, pathodont, a subsidiary of Health.net, is committed to enhance the oral health care of Pakistani Patients, providing diagnostic tests for different kinds of oral pathologies. The center offers complete management protocols, established according to the latest guidelines, for different oral pathologies, including the latest LLLT laser treatment for a wide range of maxillofacial and oral pathologies.

Award for

## Statement on Regular Dental Visits



The International Association for Dental Research (IADR) has recognised a dental student for his research on the clinical effectiveness of mouthwash made from the bark of the neem tree, which used in traditional South-East Asian medicine. His study found that the plant-derived mouthwash is just as effective as conventional mouthwashes. As reported online by the *Myanmar Times*, Mg Ye Htut Oo, a final-year student at the University of Dental Medicine, Yangon, was awarded second place in a regional dental research competition. The prize was awarded during a meeting of the IADR's Asia Pacific divisions in Australia, New Zealand, China, Japan, Korea and South-East Asia that was held from 21 to 23 August in Bangkok.

# laser

international magazine of laser dentistry



## Publisher

Torsten R. Oemus  
[oemus@oemus-media.de](mailto:oemus@oemus-media.de)

## CEO

Ingolf Döbbecke  
[doebbecke@oemus-media.de](mailto:doebbecke@oemus-media.de)

## Members of the Board

Jürgen Isbaner  
[isbaner@oemus-media.de](mailto:isbaner@oemus-media.de)

Lutz V. Hiller  
[hiller@oemus-media.de](mailto:hiller@oemus-media.de)

## Editor in Chief

Norbert Gutknecht  
[ngutknecht@ukaachen.de](mailto:ngutknecht@ukaachen.de)

## Coeditors in Chief

Samir Nammour  
Jean Paul Rocca

## Managing Editors

Georg Bach  
Leon Vanweersch

## Division Editors

Matthias Frentzen  
*European Division*

George Romanos  
*North America Division*

Carlos de Paula Eduardo  
*South America Division*

Toni Zeinoun  
*Middle East & Africa Division*

Loh Hong Sai  
*Asia & Pacific Division*

## Senior Editors

Aldo Brugneira Junior  
Yoshimitsu Abiko  
Lynn Powell  
John Featherstone  
Adam Stabholz  
Jan Tuner  
Anton Sculean

## Editorial Board

Marcia Martins Marques, Leonardo Silberman, Emina Ibrahim, Igor Cernavin, Daniel Heysselaer, Roeland de Moor, Julia Kamenova, T. Dostalova, Christliebe Pasini, Peter Steen Hansen, Aisha Sultan, Ahmed A Hassan, Marita Luomanen, Patrick Maher, Marie France Bertrand, Frederic Gaultier, Antonis Kallis, Dimitris Strakas, Kenneth Luk, Mukul Jain, Reza Fekrazad, Sharonit Sahar-Helft, Lajos Gaspar, Paolo Vescovi, Marina Vitale, Carlo Fornaini, Kenji Yoshida, Hideaki Suda, Ki-Suk Kim, Liang Ling Seow, Shaymant Singh Makhani, Enrique Trevino, Ahmed Kabir, Blanca de Grande, José Correia de Campos, Carmen Todea, Saleh Ghabban, Stephen Hsu, Antoni Espana Tost, Josep Arnabat, Ahmed Abdullah, Boris Gaspirc, Peter Fahlstedt, Claes Larsson, Michel Vock, Hsin-Cheng Liu, Sajee Sattayut, Ferda Tasar, Sevil Gurgan, Cem Sener, Christopher Mercer, Valentin Preve, Ali Obeidi, Anna-Maria Yannikou, Suchetan Pradhan, Ryan Seto, Joyce Fong, Ingmar Ingenegeren, Peter Klee-mann, Iris Brader, Masoud Mojahedi, Gerd Volland, Gabriele Schindler, Ralf Borchers, Stefan Grümer, Joachim Schiffer, Detlef Klotz, Herbert Deppe, Friedrich Lampert, Jörg Meister, Rene Franzen, Andreas Braun, Sabine Sennhenn-Kirchner, Siegfried Jänicke, Olaf Oberhofer, Thorsten Kleinert

## Editorial Office

Georg Isbaner  
[g.isbaner@oemus-media.de](mailto:g.isbaner@oemus-media.de)

Claudia Jahn  
[c.jahn@oemus-media.de](mailto:c.jahn@oemus-media.de)

## Executive Producer

Gernot Meyer  
[meyer@oemus-media.de](mailto:meyer@oemus-media.de)

## Designer

Sarah Fuhrmann  
[s.fuhrmann@oemus-media.de](mailto:s.fuhrmann@oemus-media.de)

## Customer Service

Marius Mezger  
[m.mezger@oemus-media.de](mailto:m.mezger@oemus-media.de)

## Published by

OEMUS MEDIA AG  
Holbeinstraße 29  
04229 Leipzig, Germany  
Tel.: +49 341 48474-0  
Fax: +49 341 48474-290  
[kontakt@oemus-media.de](mailto:kontakt@oemus-media.de)  
[www.oemus.com](http://www.oemus.com)

## Printed by

Löhnert Druck  
Handelsstraße 12  
04420 Markranstädt, Germany

## laser

international magazine of laser dentistry  
is published in cooperation with the World Federation for Laser Dentistry (WFLD).

## WFLD Headquarters

University of Aachen Medical Faculty  
Clinic of Conservative Dentistry  
Pauwelsstr. 30, 52074 Aachen, Germany  
Tel.: +49 241 808964  
Fax: +49 241 803389644  
[ngutknecht@ukaachen.de](mailto:ngutknecht@ukaachen.de)  
[www.wfld-org.info](http://www.wfld-org.info)

## Copyright Regulations

The **laser** international magazine of laser dentistry is published by OEMUS MEDIA AG and will appear in 2013 with one issue every quarter. The magazine and all articles and illustrations therein are protected by copyright. Any utilization without the prior consent of editor and publisher is inadmissible and liable to prosecution. This applies in particular to duplicate copies, translations, microfilms, and storage and processing in electronic systems.

Reproductions, including extracts, may only be made with the permission of the publisher. Given no statement to the contrary, any submissions to the editorial department are understood to be in agreement with a full or partial publishing of said submission. The editorial department reserves the right to check all submitted articles for formal errors and factual authority, and to make amendments if necessary. No responsibility shall be taken for unsolicited books and manuscripts. Articles bearing symbols other than that of the editorial department, or which are distinguished by the name of the author, represent the opinion of the afore-mentioned, and do not have to comply with the views of Oemus Media AG. Responsibility for such articles shall be borne by the author. Responsibility for advertisements and other specially labeled items shall not be borne by the editorial department. Likewise, no responsibility shall be assumed for information published about associations, companies and commercial markets. All cases of consequential liability arising from inaccurate or faulty representation are excluded. General terms and conditions apply, legal venue is Leipzig, Germany.



# laser

international magazine of laser dentistry



**Subscribe now!**

**You can also subscribe via  
[www.oemus.com/abo](http://www.oemus.com/abo)**

■ I would like to subscribe to **laser** international magazine of laser dentistry (4 issues per year) for € 44 including shipping and VAT for German customers, € 46 including shipping and VAT for customers outside Germany, unless a written cancellation is sent within 14 days of the receipt of the trial subscription. The subscription will be renewed automatically every year until a written cancellation is sent to OEMUS MEDIA AG, Holbeinstr. 29, 04229 Leipzig, Germany, six weeks prior to the renewal date.

► **Reply** via Fax +49 341 48474-290 to OEMUS MEDIA AG or per E-mail to [grasse@oemus-media.de](mailto:grasse@oemus-media.de)

Last Name, First Name

Company

Street

ZIP/City/County

E-mail

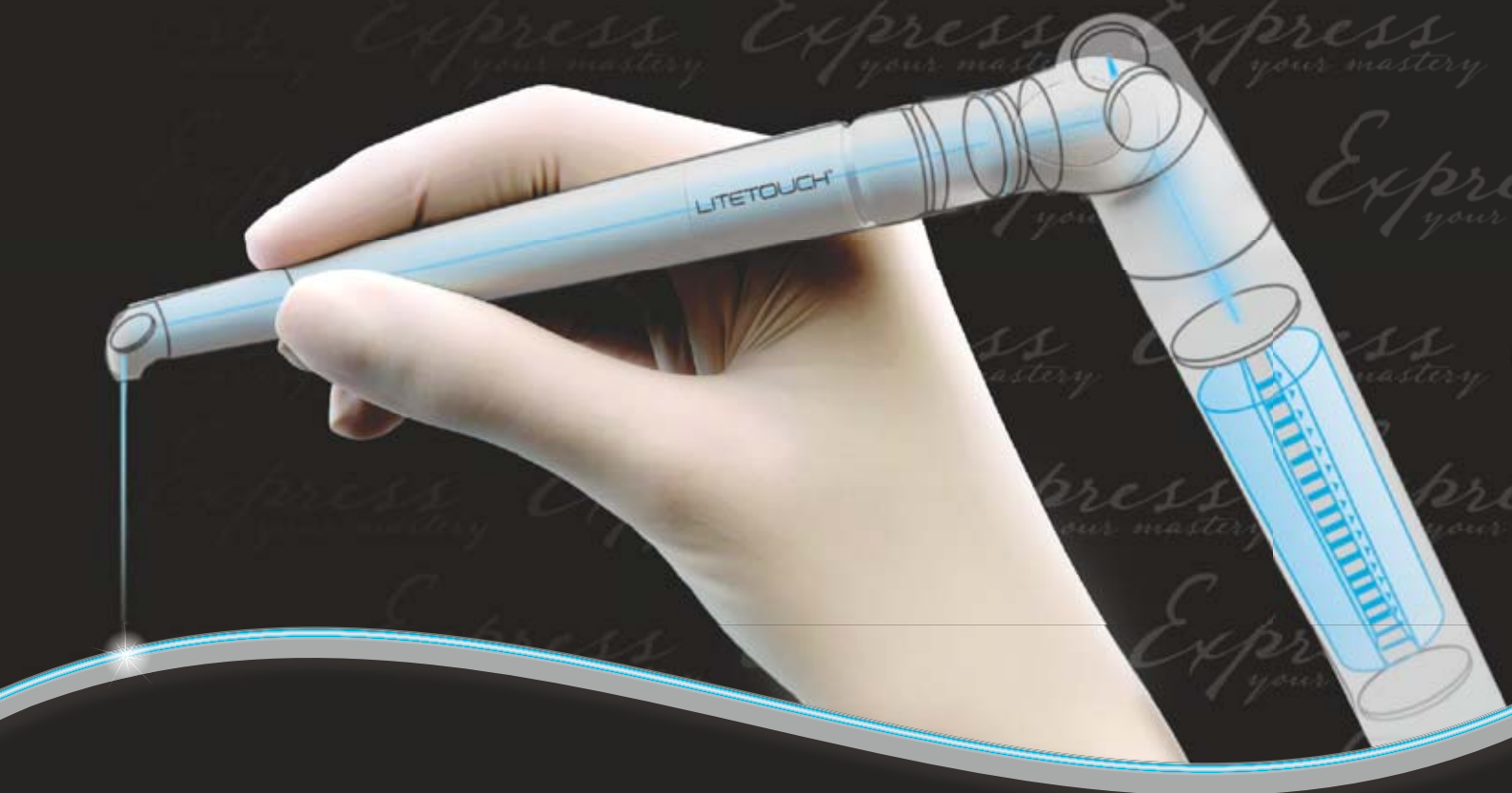Signature

Notice of revocation: I am able to revoke the subscription within 14 days after my order by sending a written cancellation to OEMUS MEDIA AG, Holbeinstr. 29, 04229 Leipzig, Germany.

Signature



**Syneron**<sup>TM</sup>  
DENTAL LASERS



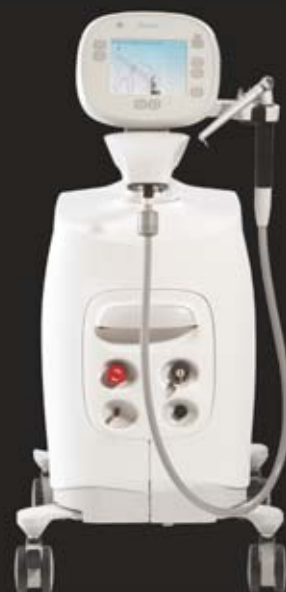Education. Technology. Family.

Join the Syneron Dental Lasers Family

presenting

**LITETOUCH**<sup>TM</sup>

The unique fiber-free Er:YAG laser  
that has changed the face of laser dentistry



To learn more about our innovative technology solutions,  
contact: [dental@syneron.com](mailto:dental@syneron.com), [www.synerondental.com](http://www.synerondental.com)

