

A new technique for the preparation of the implant site

Through Piezoelectric Surgery (PES)

Authors Prof. Mauro Labanca, Prof. Luigi F. Rodella & Prof. Paolo Brunamonti Binello, Italy

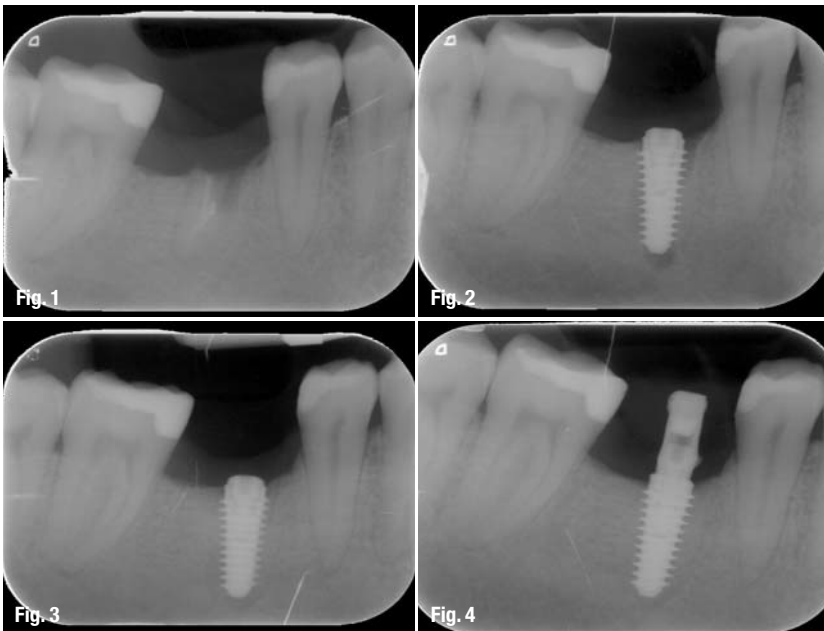


Fig. 1 PA Rx with a residual root in a alveolar process (4.5 position).

Fig. 2 PA Rx after insertion with the described combined technique. We can see the periapical defect after the extraction.

Fig. 3 Three months after, good healing of the periapical defect.

Fig. 4 After three months of loading, good osseointegration with no residual bone defect and perfect maintenance of the bone profile around the implant neck.

Introduction

Piezosurgery (PES) is a surgical technique born in the 90s; because of its versatility and effectiveness, it immediately spread from the oral surgery field to many other specialised surgical branches, such as, for example, maxillofacial surgery, orthopaedics and neurosurgery.¹

This method exploits the well-established physical principle of cavitation according to which the ultrasonic microvibrations with modulate amplitude ranging between 60 and 200 microns are able to perform incisions even on markedly mineralised tissues, such as bone tissue, tooth enamel and dentin.²

These incisions are characterised by the following features:

- Ease of execution
- Reproducibility

- Standardisable procedure
- High accuracy (linear and conservative incisions)
- Minimal to no trauma to the surrounding soft tissues compared with traditional techniques
- Drastic reduction in harmful complications suffered by the sensitive anatomical structures of the orofacial region (Schneiderian membrane, inferior alveolar nerve, arteries, etc.), in the event of direct accidental contact.

For the above-mentioned reasons, PES has deservedly gained immediate success even in implantology.

Considering the current state of the art, in fact, many rehabilitation protocols involve the use of PES not only in more advanced and complex medical conditions (split-crest, sinus floor lift, etc.)³⁻¹⁰, but also in less complex cases, like the normal preparation of individual implant sites.^{6, 11, 12} In fact, even in not-advanced implantology, that does not involve the simultaneous regeneration of the residual alveolar process for the insertion of the fixture, there are clinical conditions that pose real difficulties, at least during the early stages of preparation of the surgical site.

Here are some examples of such situations:

- Positioning of immediate post-extraction implants at the level of the anterior region.
- Positioning of immediate post-extraction implants at the level of inter-radicular bifurcation.
- Positioning of implants at the level of the edentulous alveolar process with morphological irregularities at the crest level or with very low residual profile.
- Positioning of implants at the level of the edentulous alveolar process with the presence of buccal-lingual undercuts (or buccal-palatal if the upper jaw is concerned, Figs. 1-4).

For the experienced operator, such circumstances do not pose particular problems, but they still encumber

the initial preparation of the implant site, using only the pilot dental drills available in all implant-prosthetic systems on the market (Figs. 13–14). This is due to the fact that the rotation of the bur, and therefore its macro-movement, makes its stabilisation exactly where desired by the operator in the initial phase extremely difficult, also in case a lance-tip bur is used. In this sense, the use of the PES is an important improvement for the clinician, as it is a safe and reliable method with clear benefits from both an intraoperative (technology-related) and biological point of view (see Labanca et al 2008 for review, Figs. 5–10).

The main technical-executive advantages for the operator can be summarised as follows:

- It allows for more stable positioning of the guide insert on the crestal profile for the creation of the first implant hole.
- It allows the definition of a more correct implant axis, favouring the success of the implant-prosthetic rehabilitation.
- It allows for possible intra-operative corrections of the implant axis above mentioned.
- It makes the crestal cortical osteotomy procedure safer, since the piezoelectric ergonomic handpiece is not subject to tilt and therefore does not pose those

“shaking” phenomena, specific to each rotating system initial working phases.

- It makes the initial osteotomy less traumatic, fully exploiting the cavitation process with constant irrigation.
- It reduces the emotional impact on the patient, who does not feel the annoying vibrations caused by the dental drill.

The biological advantages are in any case technical-related and consist of (Figs. 20–23):

- Reduction of thermal stress on bone tissue;
- better bone vitality;
- greater respect of the osteoblastic turnover and better bone response after resection;
- preservation of soft tissue and of any noble anatomical structures (inferior alveolar nerve, Schneiderian membrane, etc.) adjacent to the osteotomy.

This paper will therefore illustrate the fundamental execution techniques, aimed at achieving the best possible clinical success both from a biological and functional and aesthetic point of view, in order to achieve implant-prosthetic rehabilitation more likely to meet the daily demands of both the clinician and the patient.

AD

SMALL IN SIZE, GREAT IN PERFORMANCE...



IMPLA Mini-conetop:
specifically developed for supporting bar constructions



IMPLA Mini-balltop:
excellently suited to the overdenture technique

Dr. medic. (RO) Ch. Jerecinski, MSc., Paderborn

„IMPLA Mini implants are defined by their very high primary stability and the fact that they can be easily inserted.“



IMPLA Mini Implants

- » 50 years' experience in implantology
- » sand-blasted and acid-etched surface
- » minimally invasive procedure
- » short drilling protocol = shorter surgery times
- » economic implant restoration

Further information:

www.schuetz-dental.com

Newsletter registration:

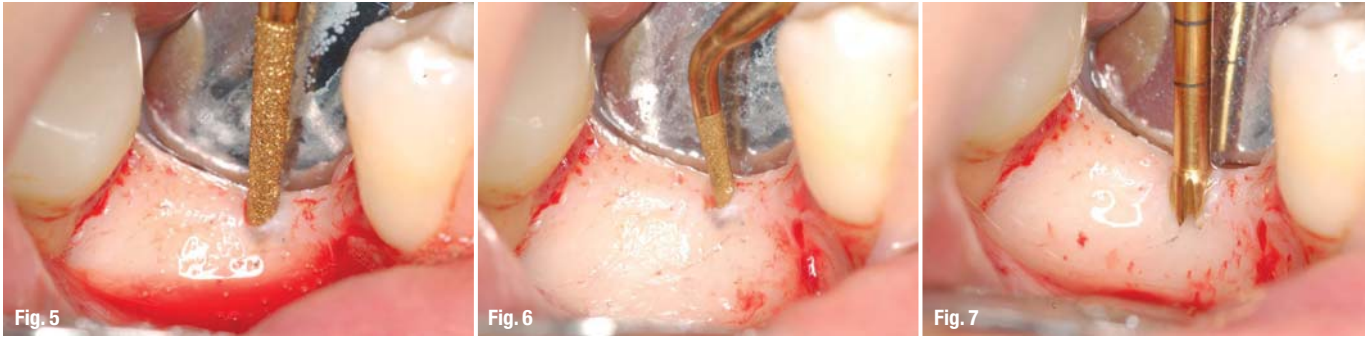


Scan me.

<http://sdent.eu/newe>



Schütz Dental GmbH • Dieselstr. 5-6 • 61191 Rosbach/Germany
Tel.: +49 (0) 6003 814-365 • Fax: +49 (0) 6003 814-907 • www.schuetz-dental.com • export@schuetz-dental.de



Figs. 5–7 Implant site preparation with only the use of piezo inserts.

The technique proposed by the authors is intended to use the piezoelectric surgery in the initial stage of preparation (Fig. 11), in order to benefit from its undisputed advantages, namely in the drilling phase of the cortex, the definition of the working length and the inclination of insertion and complete, however, the implant site preparation with dedicated burs (Fig. 12).

The authors think that in the final stages of preparation the level of friction, and therefore the overheating level of the bur on the bone, is remarkably reduced, while it is essential for a correct fitting of the implant, and a proper compliance with the surgical protocol suggested by the various dental implant manufacturers, that the burs have the shape and length suitable and specifically dedicated to the implant concerned. The universality of the implant insert does not allow a final preparation that is exactly congruent with the multiplicity of existing implants, thus risking losing retentive capability or fitting accuracy.

The paper is aimed at describing the results obtained and observed after a 36-month trial, assessing the effectiveness of the technique from both a clinical and histological point of view; a technique which provides for the use of piezoelectric inserts, instead of other surgical methods, during the first stage of preparation of the implant site.

Materials and methods

As already pointed out in the introduction, the goal of the research was to set up—on a random sample of patients—a comparison between the preparation of

the implant site using piezoelectric inserts only during the early stages, compared to the conventional technique with dental drills, or that is the exclusive use of piezoelectric inserts.

The main evaluation parameters considered were the following:

- Immediate biological response, assessed by histology of tissue removed during surgery (Figs. 15–16).
- Successful implant-prosthesis on medium (12 months) and long term (36 months), checked with intraoral periodic X-rays (Figs. 17–19), and peri-implant plaque and bleeding indices every six months from the placement of the final prosthesis.

Thirty patients were randomly selected.

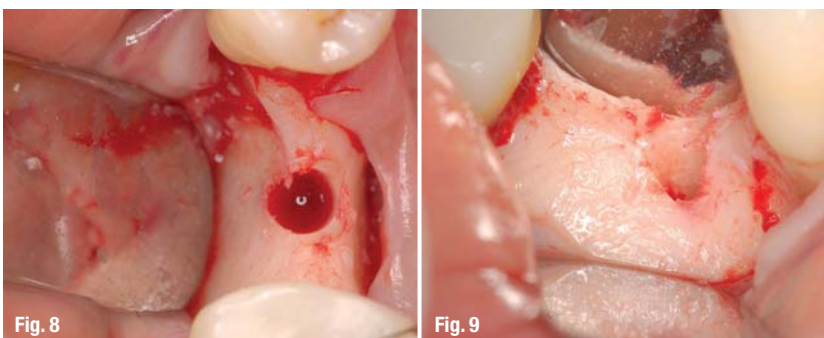
In order to create protocol uniformity, the patients were required to necessarily meet the following basic requirements:

- Aged between 30 and 50;
- good general health (absence of decompensated systemic diseases);
- no smoking;
- interlayer edentulism;
- residual alveolar process in the edentulous area sufficient to the insertion of an implant not less than 10.0 mm long and not less than 4.0 mm wide;
- lack of necessity for regenerative surgery.

In order to standardise the surgical procedures, the following common features were chosen:

- Use of submerged implants with surface obtained by subtraction.
- Implant dimension not <10.0 mm in length and not <4.0 mm in diameter.
- Use of grafting materials avoided.
- Bone density between values 2 and 4, according to the classification of Misch.
- Implant placement only in edentulous areas with the exception of the incisal areas and distal ones at the sixth teeth.
- Implant placement through surgical “full thickness” flap.
- Implants inserted at least four months after tooth extraction.

Figs. 8 & 9 Final result of the implant site preparation; a modest vestibular dehiscence is evident.



A Real Breakthrough in Implantology.

Roxolid® SLActive® – Setting New Standards, Reducing Invasiveness

With Roxolid® SLActive® Implants we break new ground:

- Eliminating invasive grafting procedures
- Increasing patient acceptance

Our new generation of implants provides you exceptional material strength combined with excellent osseointegration properties for greater confidence.

Now available:

- All diameters
- 4 mm Short Implant Line
- Loxim™ Transfer Piece

Discover more benefits on www.straumann.com/roxolid



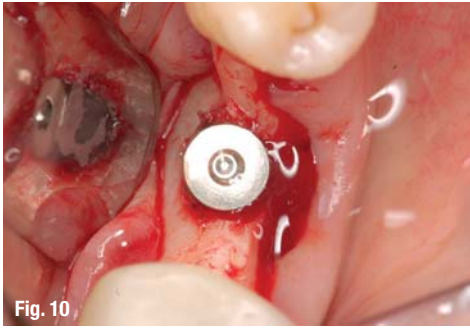


Fig. 10

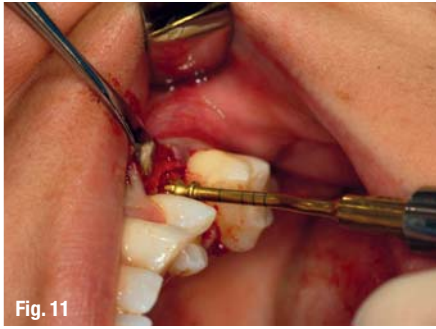

Fig. 11

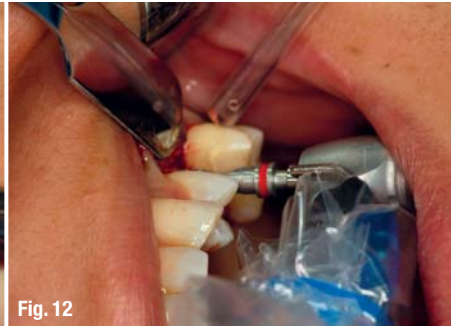


Fig. 12

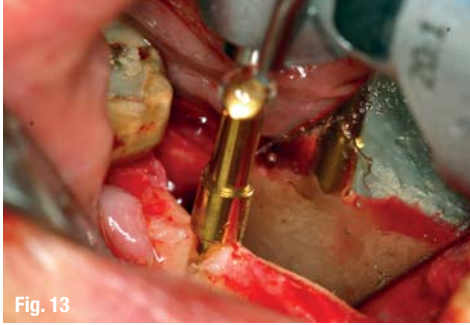


Fig. 13

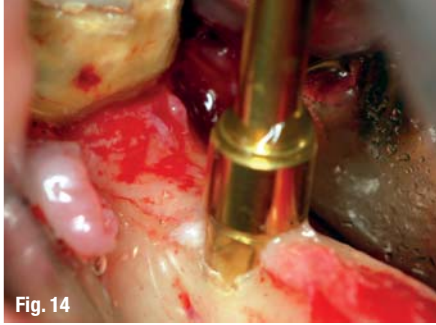


Fig. 14

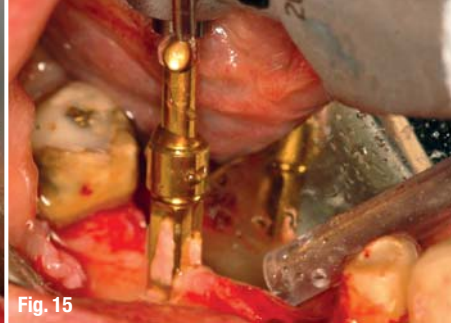


Fig. 15

Fig. 10_Implant in site. It is visible the neck profile exposed in the vestibular aspect.

Fig. 11_Implant site preparation with the authors suggested technique: first steps with piezo inserts.

Fig. 12_Final preparation of the same area with drills suggested by the implant company.

Figs. 13 & 14_Implant site preparation with rotating instruments.

Figs. 15 & 16_It is evident how the bone chips remain around the drill.

The patients selected for the trial were subsequently divided into three groups of ten each, according to the following criteria:

- Group 1: Ten patients undergoing implant site preparation through exclusive use of conventional dental drills, dedicated to the corresponding implant system.
- Group 2: Ten patients undergoing implant technique with site preparation carried out only using piezoelectric inserts.
- Group 3: Ten patients undergoing initial preparation of the implant site with piezoelectric inserts, while the final phase of preparation of the same surgical site was completed with the burs specifically dedicated to the implant system (technique proposed by the authors and subject to the verification of this study).

For each patient treated—after a specific consent form—samples of bone tissue were taken during surgery at the area corresponding to the implant site, implementing the three different methods described above, in order to compare, histologically, the extent of bone tissue damage created during each different preparation method.

All patients treated were subjected to antibiotic therapy as follows:

- Amoxicillin + Clavulanic acid 1 g tablets, 1 tablet every 8 h (3 tablets/day) for 6 days, Start therapy p.o. (by mouth) 1 day before surgery.

All patients were also prescribed post-surgical daily mouthwashes with 0.2% Chlorhexidine Gluconate up to the removal of the sutures. All patients were sutured with Ethicon Vicryl Plus 4.0®, braided synthetic ab-

sorbable suture, Triclosan-coated, in order to improve prevention against surgical site infection. Therefore, according to the above parameters, a total of 64 implants were inserted, including 28 in the lower jaw and 36 in the upper jaw. The 36-month follow-up after surgery also included the following steps:

- 1 intraoral X-ray examination approximately every month;
- 1 intraoral X-ray examination when uncovering;
- 1 intraoral X-ray examination at the end of definitive prosthesis placement;
- 1 intraoral X-ray examination every six months after definitive prosthesis placement.

As regards the prosthesis, the following criteria were chosen and applied:

- Traditional prosthetic timing (a waiting time of three months for the implants placed in the mandible (lower jaw) and six months for those placed in the maxilla (upper jaw).
- ISQ value detected through Ostell® compared with that recorded at the end of the surgical procedure.
- Prosthetic procedure with provisional abutment and provisional, screwed resin crown.
- Reduced intercuspitation of posterior elements.

After an appropriate period of load and clinical and functional checking (on average three months) the definitive prosthesis was placed, always subject to verification of the ISQ value, by placing the titanium abutment tightened with a torque wrench according to the instructions of the implant company and cementing the metal-ceramic crown with ImplaCem Precision (Dentalica). The following steps were carried out for the preparation of the implant sites with the mixed technique object of this trial.

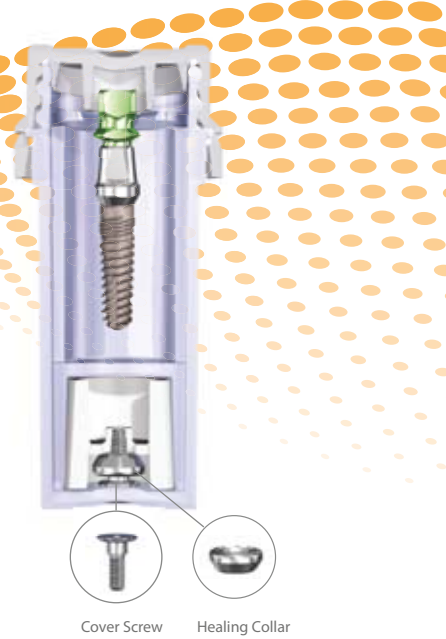
Legacy™ System

100% Compatible with Zimmer® Dental



6mmL

NOW AVAILABLE!



Reality Check
Zimmer Customers
Legacy™3 Implant

All-in-One Packaging includes implant, abutment, transfer, cover screw & healing collar €145

Legacy™ Implant System Advantages:

- Industry-Compatible Internal Hex
- Prosthetic compatibility with Zimmer® Dental Screw-Vent®, BioHorizons® & MIS implants
- Surgical Compatibility with Tapered Screw-Vent®
- No need to change surgical protocol or tools

Three Implant Designs & Packaging Options

- Allows for selection based on price, packaging or thread design
- Legacy™1:** €115 includes cover screw, healing collar & plastic carrier
- Legacy™2:** €130 includes cover screw, healing collar & temporary abutment/transfer
- Legacy™3:** €145 includes cover screw, healing collar & preparable abutment/transfer

Micro-Threads

Reduce crestal stress for improved initial stability

Widest Range of Dimensional Options

The entire Legacy system includes seven implant diameters (3.2, 3.7, 4.2, 4.7, 5.2, 5.7, 7.0mm) & six implant lengths (6, 8, 10, 11.5, 13, 16mm)

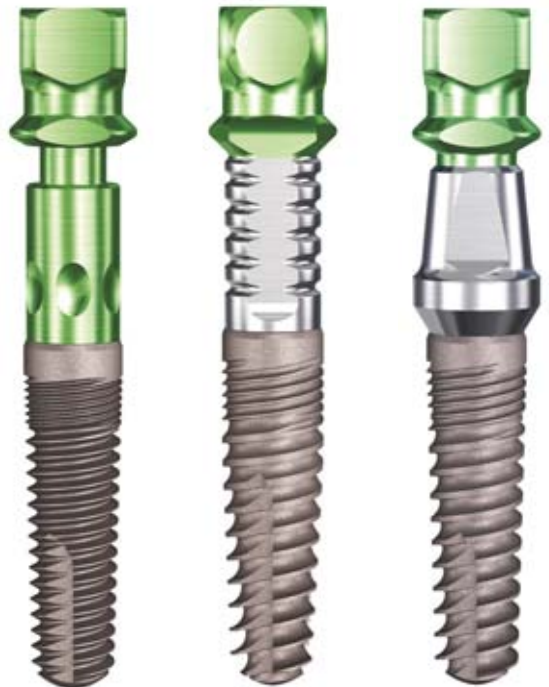

Laboratory Abutment	Straight Snap-On	Straight Contoured	15° Angled Contoured	Gold/Plastic	Zirconia/Ti Abutment	Plastic Temporary Abutment	Ball Attachment	GPS™ Attachment	Angled GPS™ Attachment	Multiple-Unit w/Cap & Transfer	Multiple-Unit w/Cap & Transfer
€60	€75	€75	€75	€90	€90	€30	€68	€90	€90	€75	€90

Legacy™1
Standard "V" Threads
Matches Screw-Vent®

Legacy™2
Spiral Threads
for Increased Stability

Legacy™3
Buttress Threads
for Increased Surface



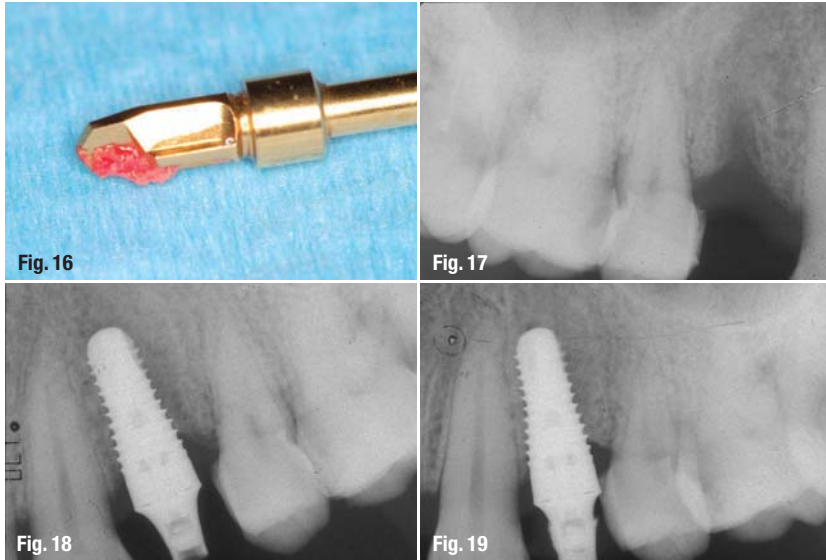


Fig. 16

Fig. 17

Fig. 18

Fig. 19

Fig. 17_Rx pre op.

Fig. 18_Rx after three months of loading (preparation with mixed technique).

Fig. 19_Rx after six months of temporary loading with a perfect bone level.

Mixed technique for the initial preparation of the implant site through piezoelectric inserts

Once an appropriate full-thickness flap is executed in order to expose the edentulous area, the technique of initial preparation of the implant site through piezoelectric inserts provides the following three intra-surgical fundamental phases:

- 1) Initial pilot osteotomy by using a Mectron IM 15 piezoelectric insert.
- 2) Use of the IM 2 insert (A or P depending on the area treated). Optimization of the concentricity of the implant site preparation between 2/3 mm in diameter through an IP 2–3 piezoelectric insert, OT 4 in case of need for correcting the inclination.
- 3) If required, further enlargement of the implant site through a Mectron IM 3 piezoelectric insert (A or P depending on the area treated).

The next stage of completion and optimisation of the implant-prosthetic site was carried out using a handpiece implant rotating bur specifically dedicated to the system used, needed to obtain, at the end of the preparation, the exact diameter expected by the operator for both the implant and the type of bone concerned. It is known that, depending on the chosen implant system or the type of bone concerned, different preparation methods are required (over- or under-preparation). The authors believe that this approach offers the following advantages:

- High precision;
- possibility to optimise the inclination of the implant axis;
- reduced tissue trauma;
- compliance with the operating sequence of the implant system implemented;
- more predictable clinical success.

Results

In total, 64 implants were inserted, including 25 in the lower jaw and 39 in the upper jaw, divided as follows:

- 21 implants placed in Group 1 (exclusive use of conventional dental drills, specifically dedicated to the corresponding implant system), including 13 in the upper jaw and 8 in the lower jaw.
- 22 implants placed in Group 2 (exclusive use of piezoelectric inserts), including 12 in the upper jaw and 10 in the lower jaw.
- 21 implants placed in Group 3 (use of piezoelectric inserts only during the initial preparation of the implant site, while the last phase of preparation of the same surgical site was completed with the burs specifically dedicated to the implant system implemented), including 14 in the upper jaw and 7 in the lower jaw.

The terms of clinical success were divided in short (removal of the suture knots in the eighth day), medium (6/8 weeks after surgery) and long term (about 36 months after the definitive prosthesis placement).

As mentioned above, the following criteria were used to assess the clinical success:

- Primary stability measured by the torque in Nm (and detected using the surgical motor Bien Air model iChiropro, Fig. 24) and with verification of the Implant Stability Quotient (ISQ) through Ostell® (Fig. 25)
- Secondary stability (through ISQ)
- Periimplant bleeding indices (from 1 to 3)
- Plaque indices (from 1 to 3)
- Degree of Patient's satisfaction (from 1 to 3).

In all rehabilitated cases, the long-term success was noticed and none of the 64 implants inserted failed. However, due to the aforementioned intraoperative histological samples taken (see the previous section "Materials and Methods"), considering the histological point of view, significant differences were observed in the bone tissue damage between the three different methods of implant site preparation implemented (Figs. 20–23). In particular, in the cases treated with mixed technique (Group 3), better results were noticed in terms of:

- Correct positioning of fixtures;
- healing in the medium- and long-term;
- localised tissue trauma.

With respect to the histological findings, in both techniques providing the use of piezoelectric inserts, a better health condition of the bone margin adjacent to the implant site preparation was observed.

Conclusions

Based on the results achieved, as well as on data reported in the literature¹², we can say that the use of

piezoelectric inserts—limited to the initial preparation of the implant site and combined with the use of handpiece rotating burs specifically dedicated to the implant system during the final phases of the procedure—improves clinical outcomes, allowing the achievement of the following key objectives:

- Correct positioning of fixtures.
- Excellent initial fitting and excellent primary retention.
- Excellent secondary bone retention and excellent maintenance of bone peaks.
- Optimal recovery in the medium and long-term.
- Extremely reduced local tissue trauma.

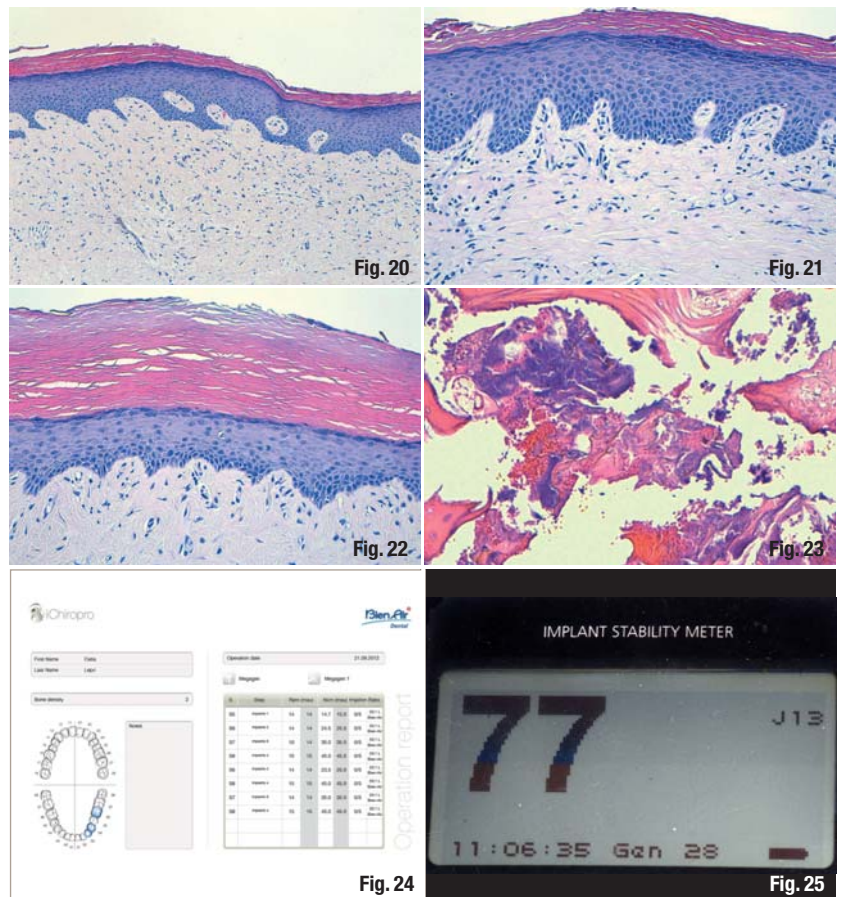
The above is more predictable and repeatable than the techniques of preparation exclusively carried out with rotating burs or with piezosurgery inserts.

Technical advantages together with the biological benefits are valid only if the piezoelectric instrument is used in a proper and correct manner, and of course if the piezosurgery system chosen meets the characteristics described in the introduction of this paper.

Actually, there are studies that show how, under certain circumstances, an improper use of the piezosurgery may be potentially risky, even iatrogenic, when compared with traditional osteotomies made with dental drills. In particular, some studies show that an excessive and prolonged pressure exerted by the operator on the handpiece (and then on the vibrating insert) during cutting, as can erroneously occur in the case of extended osteotomies and in the presence of particularly high bone densities, can generate temperatures greater than those generated by traditional burs on hard tissues.¹³⁻¹⁶

As known, the thermal stress induces a consequent significant tissue damage and interferes with the neoangiogenesis. Such an intraoperative case is particularly important, especially when the bone dimensions are minimum, as is usual in implantology or, more generally, in oral surgery.¹⁷

In addition, it should be noted that not everything that vibrates falls within the field of piezosurgery. It is possible to find systems on the market that, although described as useful for this procedure, do not have the appropriate characteristics, are not accompanied by the necessary validating histological studies or do not allow the appropriate mode and frequency of use. It follows that the unwary purchase of a wrong system may lead the operator to rely purely and simply on the benefit of piezosurgery concepts but, because of the incorrect choice, obtain a clinical and biological result worse than that achievable with conventional rotary instruments. In view of these considerations about the



pros and cons on the use of piezosurgery in oral surgery and objective data provided by a rich literature of EBM and in that sense exhaustive, the authors deem the implementation of a surgical protocol advisable, reproducible and standardized, which provides for the use of piezoelectric device only during the initial phase of preparation of the implant site, then completing the site preparation with the burs provided by the implant protocol chosen by the operator.

Finally, these highly satisfactory results, therefore, encourage clinical research in this direction and the procedure described is, in the opinion of the authors, a viable alternative—albeit not a substitute—to conventional techniques already thoroughly discussed in the literature.

Editorial note: A complete list of references is available from the publisher.

_contact

implants

Prof. Dr Mauro Labanca
 Consultant Professor in Oral Surgery
 Corso Magenta, 32
 20123 Milano, Italy
 maurolab@tin.it

Fig. 20—Histologic of bone tissue in mixed technique for the initial preparation of the implant site through piezoelectric inserts with a visible reduction of the cortical and basal level.

Fig. 21—Drawing of bone tissue in mixed technique for the initial preparation of the implant site through piezoelectric inserts with only an initial reduction of cortical level.

Fig. 22—Histologic of healthy bone tissue in technique for the preparation of the implant site only with piezoelectric inserts.

Fig. 23—Histologic of bone tissue in technique for the preparation of the implant site only with dental drills. We can see an objective tissue's damage, with a lot of necrotic areas.

Fig. 24—The example of torque measurement.

Fig. 25—The example of ISQ measurement.