

Vertical bone augmentation procedures—Part I

Authors Prof. Dr Dr Florian G. Draenert & Dominic Hützen, Germany

Introduction

The success of an implantological procedure largely depends on the alveolar situation and the bone supporting the soft tissues. Until today, complex augmentation procedures pose high demands on the clinician and there is still a great need for research in this field. The following article discusses the basics of implantology relevant to bone augmentation and presents an overview on complex bone augmentation techniques. Part I of this consecutive article series introduces basics in bone morphology, biomaterials and transplants. To be continued in 2014 with issue 1/2014.

Basics

Bone morphology

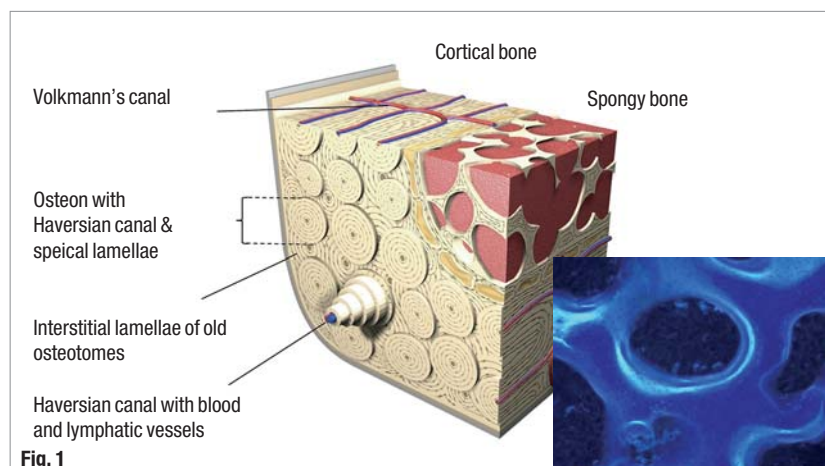
The histomorphology of bone distinguishes between lamellar bone of complex structure and plexiform bone.¹ Plexiform bone does allow fast healing and growth, but only simple structures of orthogonal primary osteone structure with a mechanical overall weakness of evolutionary relevance in large organisms. It is therefore often found in small mammals like mice, rats, and in part rabbits. Larger mammals including pigs, dogs and humans have a complex lamellar bone structure. Ontogenesis of bone in humans starts with embryonal plexiform bone structures leading to the mature bone structure with secondary osteons (Haversian sys-

tem). The two morphological forms of bone are cancellous and compact bone. Cancellous bone shows a trabecular structure with an internal lumen containing bone marrow with several function including pluripotent stem cells and vessels. Healing starts in a lamellar fashion from the bone marrow space. Cortical bone is a compact more stiff structure with higher mechanical stability and no internal remodelling capabilities. The internal structure of both bone tissues is lamellar as described above. Osteons with central Haversian canal containing osteocyte and vessels surrounded by mineralised matrix lamellae is the structure principle of compact bone and surrounded by interstitial lamellae (Fig. 1). Osteocytes are connected with each other via gap junctions through the Canaliculi ossei. The bony part of cancellous bone is similar in structure. Periosteum separates bone from surrounding connective tissue and consists of two layers Stratum fibrosum (external) and Stratum osteogenicum (internal) containing nerves, vessels and also osteogenic progenitor cells allowing chemotactic migration during bone healing. Bone tissue consists of cells and matrix (ossein). Ossein contains anorganic minerals, mostly hydroxyl apatite, and organic molecules mostly collagen type I.² The organic matrix also contains several other molecules with complex functions including proteoglycans like aggrecan with its glycosaminoglycan arms and multiadhesive proteins but also its hyaluronic acid cores or newly discovered fibrils and other structures under current research.³⁻⁵


Bone healing

Healing of augmented bone transplants and biomaterials at the interface site is analogous to defect fracture healing^{1,6-16} aseptic inflammation and chemotactic cell migration; loose preliminary tissue (soft callus); mineralised immature bone (hard callus); remodelling resulting in full functional bone (Fig. 2).¹⁷ This mode of healing concerns all free avascular transplants including guided bone regeneration (GBR) and block augmentations contact healing is therefore not an issue in all of these augmentations and would require both sides of the healing site to be vasculated vital bone tissue (Fig. 2). The gap healing in bone augmentations includes lamellar healing at the interface site and the periosteum

Fig. 1 Bone Augmentation with compacta and spongiosa (left). Sequence marking with tetracycline in the rabbit at two different times makes the shell-like bone structure observable.



The implant system without compromises!



Maximum safety. Perfect aesthetics. Easy handling.

Discover the perfect symbiosis of the Dentaaurum implant systems. Safe and simply perfect for you and your patients. Convince yourself of our intelligent solutions and find out more about our complete product range.



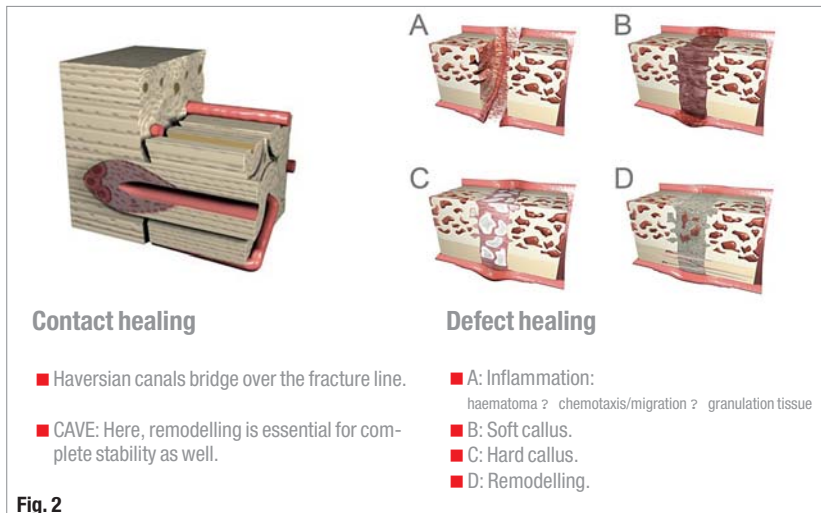
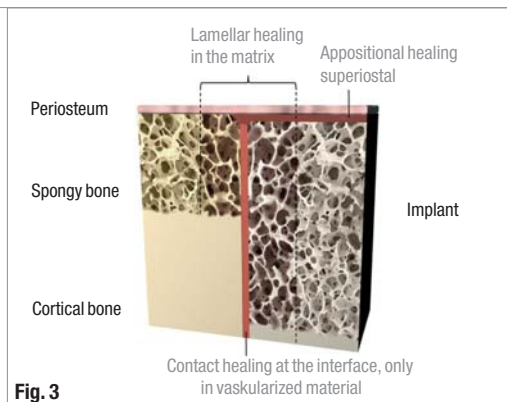


Fig. 2_Synopsis of the types of bone healing: contact healing (left), defect healing (right).

Fig. 3_Synopsis of the subperiosteal implant healing.



with cell recruitment from blood, bone marrow and the periosteum depending on the local anatomy (Fig. 3). This cell recruitment includes local osteoblast progenitors (human trabecular bone derived cells - HTBs), and blood-derived CD-34-positive embryogenic progenitor cells (EPCs).¹⁸⁻²¹ Differentiation of local adult stem cells is not well understood yet. However, the differentiation of EPC follows a stepwise change into an osteoblast while losing pluripotent capabilities from the EPC with high CD34-positive cells, followed by the stage of "circulating osteoblast lineage cell" towards the "blood mesenchymal precursor cell" (BMPC) direct differentiation into osteoblasts with continuously rising percentage of stromal cell-derived factor-1 (SDF-1) CXCR4-receptor.¹⁸ Vascular cells in newly formed bone tissue are also derived from EPCs.^{22,23} Osteoclast however are part of the mononuclear phagocyte system and derived syncytia formations of these cell lineages.²⁴ Vicerocranial bone of the facial area is mesektodermal tissue derived from the branchial arch rather than mesenchymal tissue derived bone in the remaining skeleton.²⁵⁻²⁸ This issue is often not fully considered when discussion bone of the skull.

Cell induction in bone tissue: osteoinduction and neangiogenesis

The time course of bone healing is influenced by many factors. This includes the stability and morphol-

ogy of the transplant or mesh graft with biomaterial as well as biological factors. Those factors are osteoconductivity, osteoinductivity/vasoinductivity and osteogenicity present in the bony implant bed and the graft or mesh. Osteoconductivity concerns macro and micromechanical and morphological properties that to promote a bone tissue specific activity and differentiation including matrix-cell-interactions, but also pore-size, surface properties and interconnectivity of pores in biomaterials and bone grafts, and finally also external mechanical influences like shock waves.²⁹⁻³⁴ Osteoinductivity leads to bone growth and differentiation by specific ligand-dependent cell activation by growth factors and other molecules, that are mostly related to the TGF- β family, like BMPs (bone morphogenic proteins) e.g. BMP-2 oder BMP-7, or basic FGF and VEGF.^{16,35-44} The last ones are also strong vasoinductive factors. There are several approaches to apply growth factors in clinics.⁴⁵⁻⁵³ However, this application will remain limited to specific problematic conditions due to some main reasons. On the one hand, tissue healing is limited by cell activity, including the described phases of bone healing with cell recruitment, chemotaxis, differentiation and specific tissue matrix production that cannot be accelerated beyond biological limits and external growth factors are therefore not relevant even if certain effects can be shown *in vitro* and *in vivo*.^{17,54} On the other hand, it is a fact that application of growth factors bears the immanent risk of carcinogenic transformation.^{55,56} Osteogenic properties concern the continuity of living bone cells after transplantation that can be achieved with small bone pieces combined with fast revascularisation (e.g. particulate bone augmentation), press-fit in cancellous bone healing (clinically not relevant in oral- and maxillofacial surgery), and microvascular transplants like fibula flaps. Main signal transduction in bone cells includes classic general elements like ras und MAP-kinases, but also Smad-dependent pathways and integrin-associated signaling.⁵⁷⁻⁶⁰ Smad-dependent signalling includes specific second messengers like RunX2 and consists of a complex system of sub-elements depending on the associated ligand-system. BMPs activate Smad 1, 5 and 8 complex that binds Smad 4 and others as DNA-binding complex.⁵⁸⁻⁶⁰ Integrins on the other hand represent an element of signal transduction activation by specific matrix binding.³²⁻³⁴

II. Biomaterials and transplants

Bone transplants and alloplastic biomaterials

We will not discuss the wide field of biomaterial products in depth as already published elsewhere.^{61,62} Materials for bone augmentation are divided into alloplastic (artificial) biomaterials and transplants alongside with their natural xenogenic, allogenic or autologous derivatives.⁶³⁻⁷³ Most common alloplastic materials are: β -tricalciumphosphate,⁷² bioactive glasses,⁷¹ and hydroxylapatite.⁷³ Bone material can be further

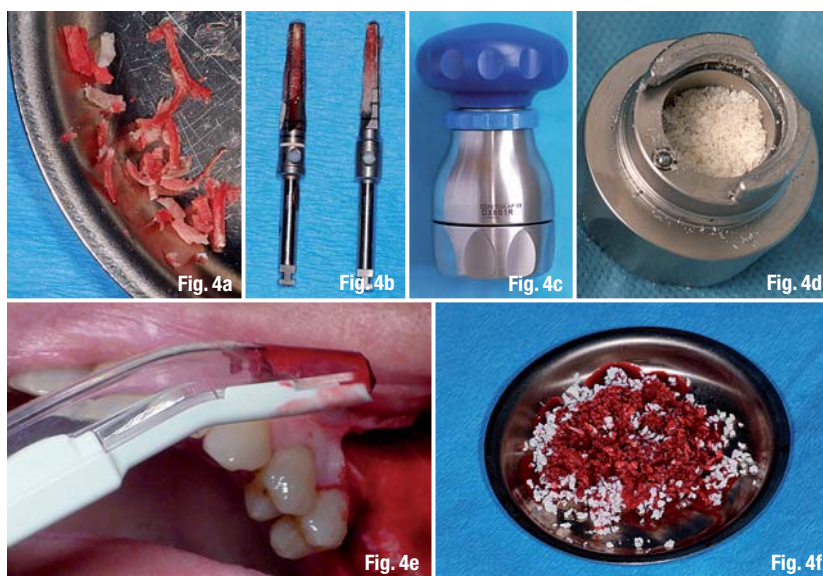
characterized as: autologous (fresh or frozen), allogeneic (e.g. DBM "demineralized bone matrix"), and xenogeneic. Important material properties concerning bone healing are pore size and interconnectivity, resorbability without severe inflammation and macro stability of particle material.⁷⁴ Some of these factors are evaluated scientifically like pore sizes and surface properties, while other factors are mostly clinically based experiences like macro stability.^{29,30} Materials can be further characterized by their potential to influence bone healing:⁶ osteoconductive (promotes bony ingrowth); osteoinductive (induces bone tissue generation by receptor-mediated cell activation); osteogenic (material contains living bone cells or bone cell precursors). Most common particulate materials are bone chips from the implant site, milled bone blocks, scraped bone chips, mesh grafts with alloplastic materials (Fig. 4). Growth factors and tissue engineering are future option in compromised bone healing and complex reconstructive surgery.^{18, 22, 39, 41, 44-47, 75-81} Conceptual problems arise, if these novel techniques concerning cost and carcinogenic risks of growth factors are not addressed.^{18, 22, 45, 45, 47, 76, 82, 83} Dental implantology therefore offers limited indications for these options.

Donor sites for bone transplants

Choosing the appropriate donor site for bone transplants is the second step after analysis of the defect and augmentation planning. Most common donor sites are:⁷⁴

- Mandible
(chin, angle, linea obliqua, corpus mandibulae)⁸⁴
- Maxillary
(tuber, spina nasalis, crista zygomaticoalveolaris)
- Calvaria (tabula externa)
- Pelvic rim
- Tibia.

Local donor sites are of special interest for applications in oral and maxillofacial surgery. Intraoral donor sites are shown to be less painful for patients (Fig. 5).⁸⁵ Big defects require extraoral donor sites mostly from the pelvic rim region. Quality and healing properties of various bone transplants concern their ontological origin in particular. While local skull bone is branchial tissue of mesektodermal origin, pelvic and most other bone transplants are mesenchymal tissues.²⁵⁻²⁸ Mandibular bone is the most common transplant in dentistry with several donor regions: chin, linea obliqua, angle, corpus mandibulae, lingual exostosis.^{69, 74, 85, 86} Bone is harvested as a block for either immediate transplantation or generation of particles in a bone mill or similar device.^{84, 87} Using a scraper is a modern way of directly generating bone chips.⁸⁷ The chin region bears more donor site morbidity problems due to the mental muscle attachment and should be limited to augmentations in the same region to avoid a second surgery site or other serious indications.⁸⁵ The linea obliqua area offers a ver-



satile donor site with limited risks and complications if the anatomy of the alveolar nerve is carefully evaluated.⁷⁴ The area of the mandibular angle is another site in the same area and similarly difficult with risks for the local nerve like the lingual exostosis. The maxilla offers only limited amounts of bone material. However, using tuber bone or scraping chips from the anterior wall in combination with sinus lift surgery can be the right option. Harvesting bone from the pelvic rim is the method of choice for most indications requiring large amounts of autologous bone due to limited risks and good approach.⁸⁸⁻⁹⁰ There is an anterior and a posterior approach.^{88, 89, 91} It is discussed that the rarer posterior approach is offering more bone and less morbidity.^{88, 89, 92} Complications of this donor site are pain, bleeding, nerve lesions (N. cutaneus femoris lateralis), and fractures of the pelvic bone.⁸⁸

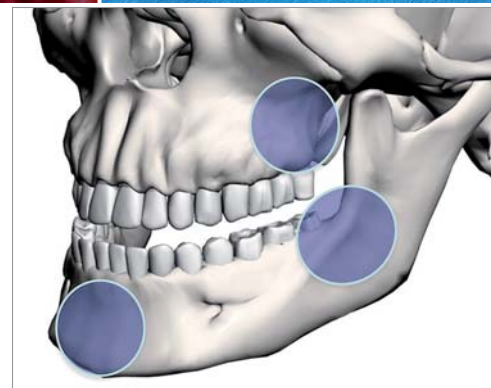


Fig. 4a-f Common augmentation materials: a) bone chips from the implant bed, b) bone mill for particularization of blocks, c) bone scraper, d) commercial biomaterial. **Fig. 5** Bone harvesting sites in the jaw: metal, Crista zygomaticoalveolaris and Tuber maxillae; Linea oblique of the mandibula and the angle of the jaw.

Editorial note: To be continued in implants 1/2014 with osteotomy and complex bone augmentation techniques. A complete list of references is available from the publisher.

_contact

implants

Prof. Dr Dr Florian Draenert

Devissi Implantology Institute
Xaver-Weismor-Str. 60a
81829 Munich, Germany

Tel.: +49 160 6127828
draenert@floriandraenert.com