

implants

international magazine of oral implantology

1 2014



| **research**

Maximal aesthetics in the periodontally compromised anterior maxilla

| **case report**

Comprehensive prosthetic restoration

| **industry report**

Influence of implant design on osseointegration





More than an implant. A sense of trust.

The Straumann® Dental Implant System is a worldwide leading solution for general practitioners and specialists. Our commitment to research ensures high quality backed by independent science. Producing innovations that improve patient care has made us a trusted business partner in over 70 countries.

www.straumann.com

60 YEARS


simply doing more

How many **scientists fabricate and falsify research?**



Dr Rolf Vollmer

—“The frequency with which scientists fabricate and falsify data, or commit other forms of scientific misconduct is a matter of controversy. Many surveys have asked scientists directly whether they have committed or know of a colleague who [has] committed research misconduct, but their results appeared difficult to compare and synthesize.”

“To standardize outcomes, the number of respondents who recalled at least one incident of misconduct was calculated for each question, and the analysis was limited to behaviours that distort scientific knowledge: fabrication, falsification, ‘cooking’ of data, etc. Survey questions on plagiarism and other forms of professional misconduct were excluded.” Twenty-one surveys were included in the systematic review and 18 in the meta-analysis.

While I am familiar with reports of scientific misconduct, I was shocked about the high occurrence in medicine and pharmacy reported in Fanelli’s meta-analysis of these surveys—the first of its kind: “A pooled weighted average of 1.97% (N = 7, 95% CI: 0.86–4.45) of scientists admitted to have [having] fabricated, falsified or modified data or results at least once—a serious form of misconduct by any standard—and up to 33.7% admitted [to] other questionable research practices. In surveys asking about the behaviour of colleagues, admission rates were 14.12% (N = 12, 95% CI: 9.91–19.72) for falsification, and up to 72% for other questionable research practices. Meta-regression showed that self reports surveys, surveys using the words ‘falsification’ or ‘fabrication’, and mailed surveys yielded lower percentages of misconduct. When these factors were controlled for, misconduct was reported more frequently by medical/pharmacological researchers than others.”

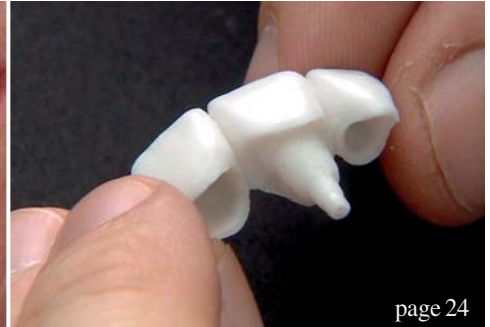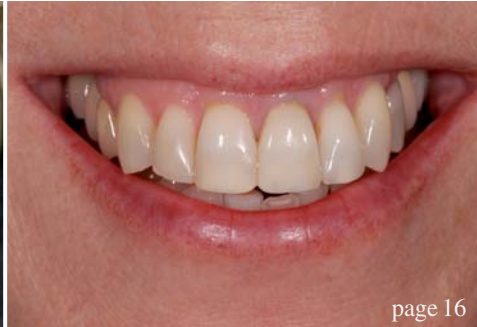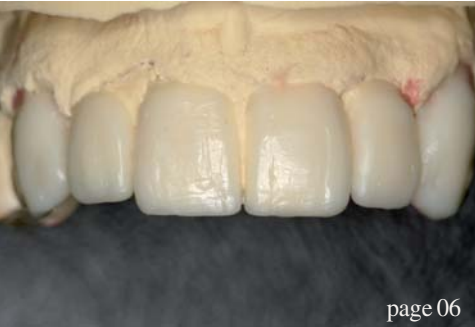The study cited above should make us consider all we read carefully. Especially with the development of new materials (for bone replacement, for example), we should always critically examine the current research and determine whether one can actually trust the evidence. For each of us, we need to ensure that our decisions are for the benefit of our patients and that they do not make them test subjects.

In this regard, the DGZI (German Association of Dental Implantology) offers you up-to-date training opportunities, such as the recently completely redesigned implantology curriculum and the presentations at our annual meetings (our next annual meeting is on 26 and 27 September in Düsseldorf), as well as critical, unbiased, objective information on companies and products.

We hope you will enjoy reading our current **implants international magazine of oral implantology**.

Yours faithfully,

Dr Rolf Vollmer



| editorial

03 How many **scientists fabricate** and **falsify research**?
| Dr Rolf Vollmer

| research

06 Maximal **aesthetics** in the **periodontally** compromised anterior maxilla
| Dr Nikolaos Papagiannoulis *et al.*

10 **Ridge augmentation** for an **atrophied posterior mandible** using NanoBone block
| Dr Omar Soliman *et al.*

| case report

16 Comprehensive **prosthetic** restoration
| Michael Peetz *et al.*

| industry report

20 **Jawbone cavitation** and its **implication** in implant **dentistry**
| Prof. Dr Mauro Marincola

24 **Immediate implantation** and **full-ceramic restoration** in the **maxillary anterior region**
| Dr Arndt Happe *et al.*

32 Influence of **implant** design on **osseointegration**
| Dr R. Fromental *et al.*

| interview

40 **The time** has come
| Interview by Jürgen Isbaner

42 **Short implants**
| An interview with Prof. Dr Christoph Hammerle, Switzerland

| meetings

44 **International implantology** in Berlin

46 More than **500** attend **ISOI** annual meeting in **Tokyo**
| Dr Rolf Vollmer

| news

36 **Manufacturer** News

49 **News**

| about the publisher

50 | imprint



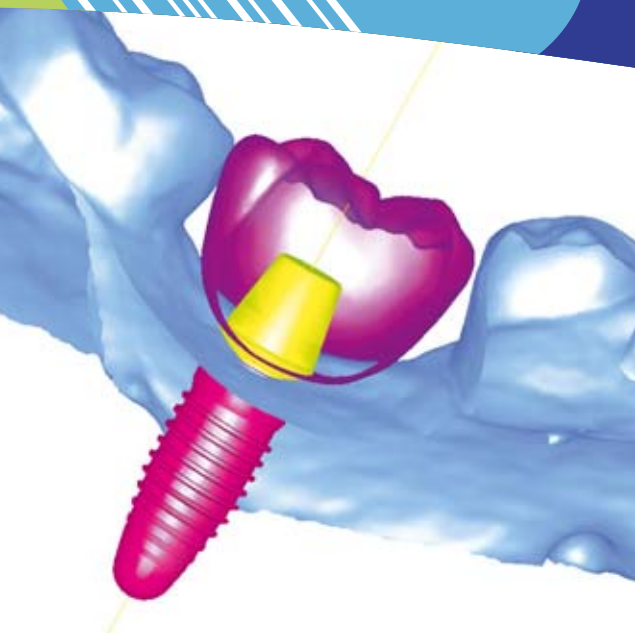
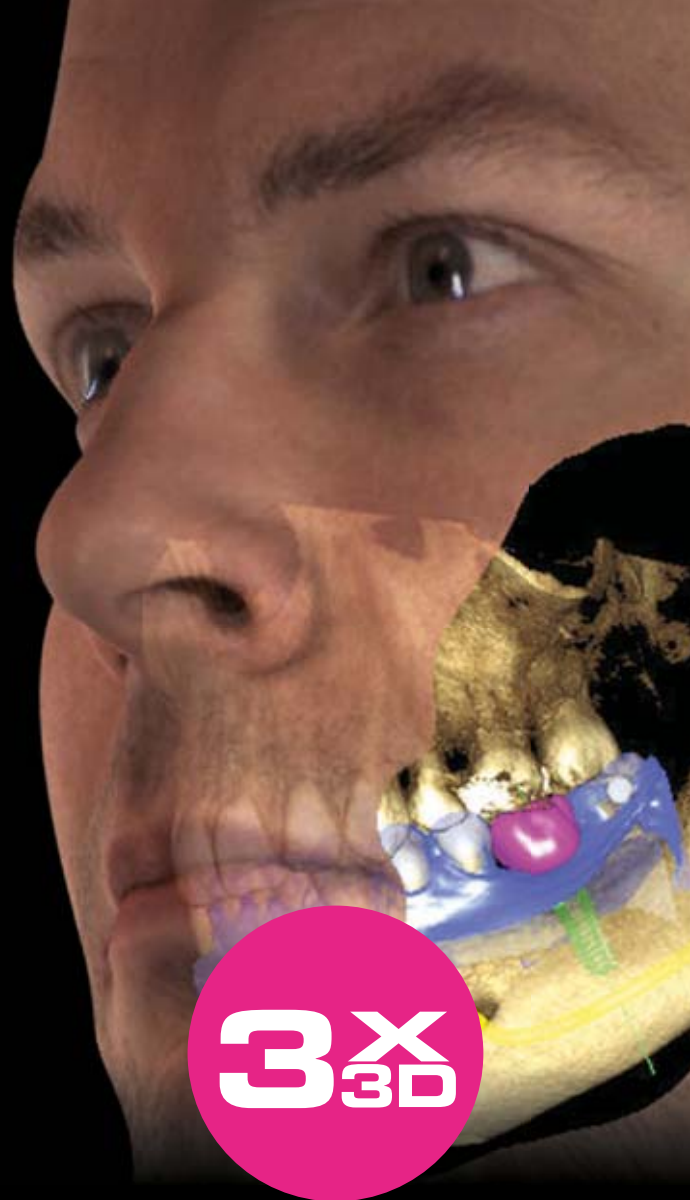
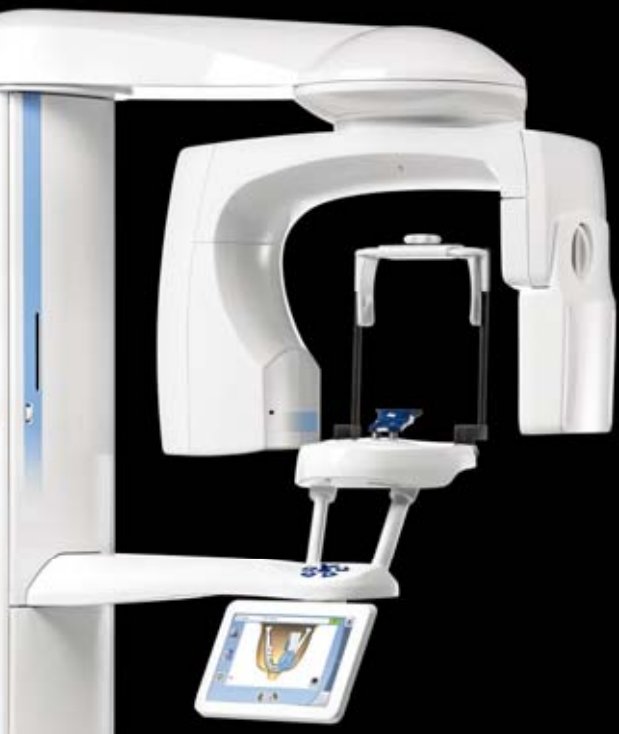Cover image courtesy of
BEGO Implant Systems GmbH & Co. KG
www.bego-implantology.com
Original Background: ©Click Bestsellers
Artwork by Sarah Fuhrmann, OEMUS MEDIA AG.



Planmeca ProMax® 3D

Planmeca Romexis®

Implant planning made easy



Planmeca Romexis® 3D Implant Planning software offers the most sophisticated tools for the needs of modern implantology.

- Superimpose surface scan on to CBCT data
- Use crown library or import patient-specific crown from CAD system
- Position the implant using realistic implant and abutment libraries
- Verify the implant plan with verification tool
- Order surgical guide directly from the software

Find more info and your local dealer
www.planmeca.com

PLANMECA



Maximal **aesthetics** in the **periodontally** compromised anterior maxilla

Immediate **implantation**

Authors_Dr Nikolaos Papagiannoulis, Dr Eduard Sandberg & Dr Marius Steigmann, Germany

Introduction

In addition to habits, systemic diseases and bruxism, periodontal diseases are challenging problems in oral implantology. Here, surgeons have to deal with tooth loss, prolonged epithelia, bone resorption and loss of periodontal ligament. In the following case, we could clearly see at the preclinical analysis that major bone resorption had occurred horizontally as well as vertically. The bony defects referred to more than one wall, the bone resorption around the root was like a crater, infiltrated with soft tissue. Primary stability was difficult to achieve for the implant.

The periodontal treatment was the primary focus, accompanied by fillings and extraction therapy to cure acute inflammations and achieve oral health. Nevertheless, periodontal treatments result in regular to functionally and aesthetically compromised situations and unsatisfied patients. Further, periodontal treatment does not secure the adequate prosthetic treatment of the patient. Depend-

ing on the art of the restoration, teeth often have to be extracted, in spite of successful periodontal treatment. So the question to be asked is whether and when a periodontal treatment makes sense as a definite treatment or if it should be a tool that enhances later surgical and restorative procedures.

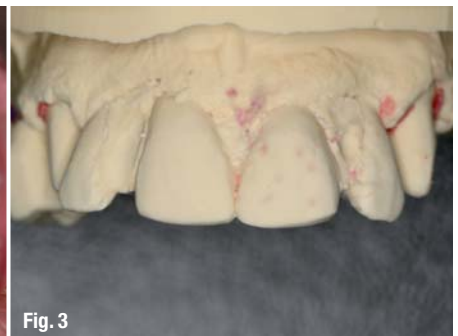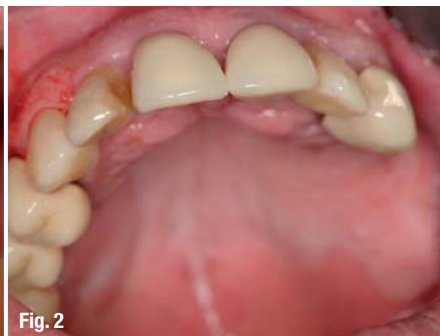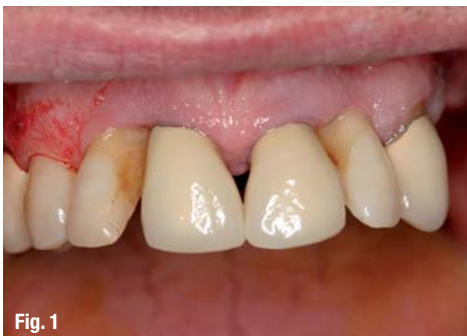Clinical and radiological findings

The clinical examination showed a severe periodontal defect, screening index of Grade IV, pockets of up to 6 mm, tooth mobility grade II–III and a bleeding index of 3–4. The functionality was very limited and the aesthetic situation unsatisfactory. The existing prosthetics on the central incisors were too long to cover the recessions, resulting in further attachment loss. The aesthetics also were compromised, following periodontal fibre loss and bone support. Especially the lateral incisors suffered severely from loss of interproximal bone, followed by mesiorotations and ante-inclination (Figs. 1 and 2). Radiological findings confirmed that all four upper incisors needed to be extracted.

Fig. 1 _Initial clinical situation.

Fig. 2 _Initial clinical situation, coronally.

Fig. 3 _Situation models for provisional planning.



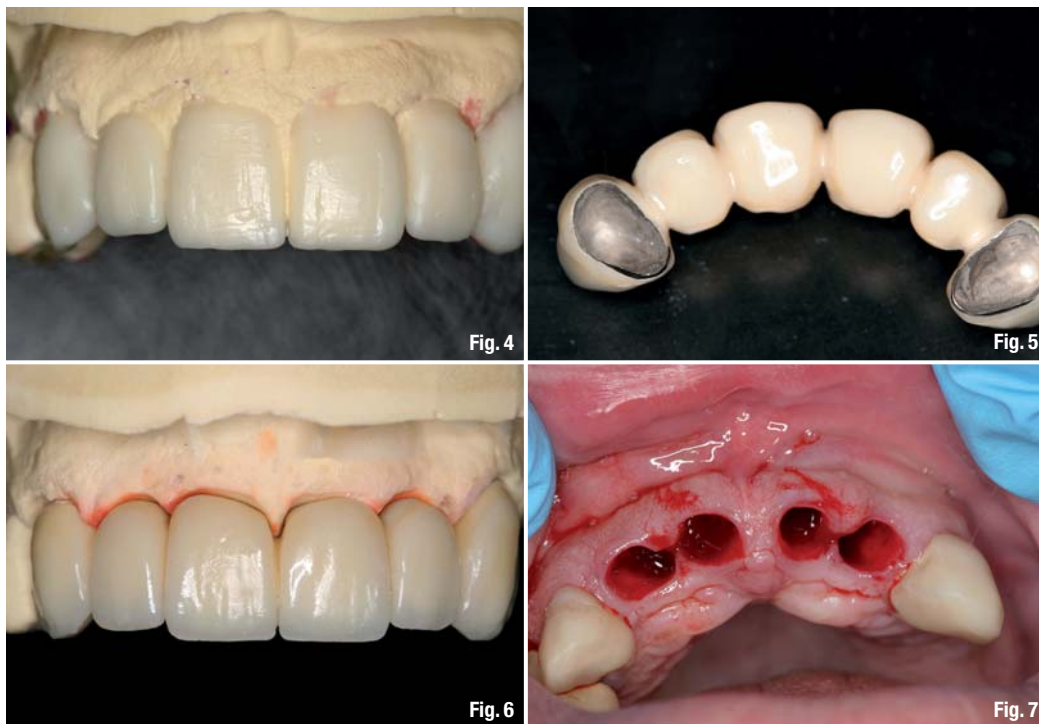


Fig. 4 Wax-up of the provisional bridge.

Fig. 5 Provisional bridgework with pontics.

Fig. 6 Provisional bridgework frontally.

Fig. 7 Extraction sockets.

_Treatment plan

Taking into consideration that the goal of surgical periodontal treatments is a screening index of 2–3 mm and that they almost always result in recessions, the outcome of these procedures is aesthetically poor. Especially in highly scalloped biotypes, patients are rarely satisfied. Longer prosthetics to cover the free root surface do not improve this outcome. On the other hand, these procedures are not always successful, resulting additionally in thermal sensitivities and persisting tooth mobility. Because of the high costs of surgical periodontology and the previous arguments, patients increasingly ask for alternative procedures. In the case discussed in this article, periodontal treatment would further neither aesthetic nor functional improvement, but only maintain the teeth for some months or years. The risk would be additional loss of bone and soft tissue, compromising future plans and prosthetic possibilities. The treatment plan for this case included conservative periodontal treatment and recall to treat inflammations, tooth extraction and immediate implantation with guided bone and tissue regeneration.

_Surgery

Before extracting the incisors, the crowns 13 and 23 were removed and the teeth were prepared to receive temporary bridgework. With a wax-up on the situation model and pontics, an optimal form was created to support and manipulate soft tissue during the healing phase. At the same time the tempo-

rary bridge functions as wound coverage if primary closure is not possible (Figs. 3–6).^{1–4}

In the next step, the teeth 12 to 22 were extracted. The flap outline spared the middle papilla and mesial ones on 12 and 22. Due to interproximal bone defects, raising of the papilla in this region would have led to severe recessions. The vertical bone defects, especially between 11 and 12, were obvious after raising a full-thickness flap. Releasing incisions were placed distally at the canines and only in the attached gingiva to prohibit scar formation through vertical cuts in the mucosa. The low vestibule made a split thickness or periosteal pocket flap less logical. Mobilizing soft tissue from the lips by other flap designs would provoke functional limitations, suture tension and a secondary gum plastic to reposition the coronal transpositioned soft tissue. The wound margins were freshened to remove prolonged epithelia and the bone defects freed from soft tissue ingrowth (Figs. 7–10). The horizontal bone loss was moderate. Implants were placed slightly subcrestally. Although the gap between implants and the buccal plate was approximately 1–1.5 mm and the buccal plate thickness 1–1.5 mm due to the resorption, we decided for 3.8 mm implants, leaving a 1.5 mm gap to the buccal plate.^{5–10}

The interimplant space and the buccal plate were augmented with a combination of allograft and xenograft. Xenograft was also placed on the buccal plate so as to manipulate buccal plate resorption. A pericardium membrane was used as barrier (Fig. 11).

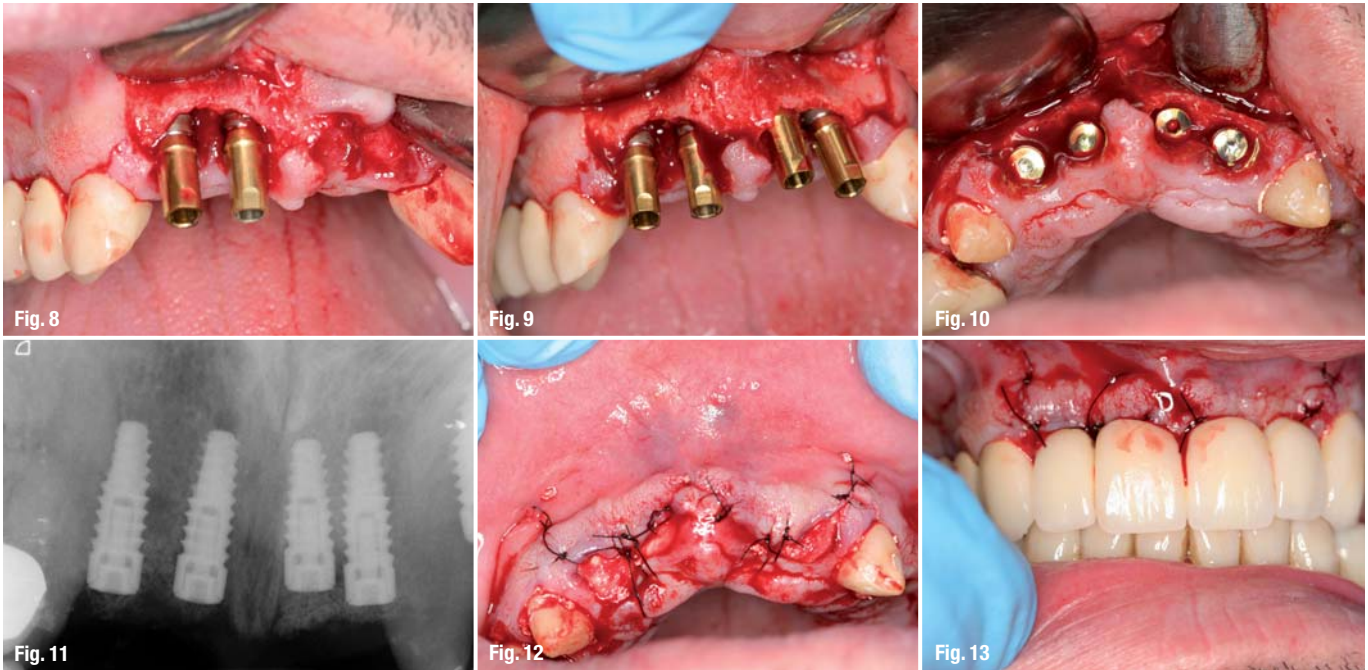


Fig. 8_Flap raising and implantation.
Fig. 9_Implantation of four implants.
Fig. 10_Inserted implants, coronally.
Fig. 11_Radiological control after surgery.
Fig. 12_Flap closure.
Fig. 13_Provisional bridge in situ.

The anatomy of the upper jaw and the low vestibule did not allow primary closure. To protect the membrane from proteolytic resorption and the augmentation, we placed two layers of tissue fleece above the membrane. Through the collagen fleece and the protection of the provisional bridge, free granulation of the extraction socket cover was expected after two weeks (Fig. 12).^{11,12}

The patient received a weekly recall with prophylaxis and hygiene instructions. Three weeks postoperatively, sutures were removed. The clinical situation showed no irritation and the wound healing and closure ideal (Fig. 13).

Re-entry and prosthetics

The re-entry was performed after three months with minimally invasive crestal cuts. A papilloplastic adjusted the wound margins between 11-12 and 21-22 (Fig. 14). After three additional weeks, impression was performed. The healed situation showed optimal soft tissue quality and adequate attached gingiva quantity. We measured 2-2.5 mm soft tissue height above the implant necks, enough for the necessary emergence profile. With the help of convex or concave formed prosthetics, soft tissue can be manipulated to the direction needed for esthetics (Figs. 15 & 16).¹³⁻¹⁶

The final crowns show great results. The papillas and pseudopapillas fill up the approximal space. The approximal contact had to be longer and wider than normally in order to compensate the former vertical bone loss, especially in the region 11-12. Nevertheless, there were no black triangles, the patient was satisfied

and with the proper hygiene, the aesthetic outcome will be optimized in the next months. Therefore, there was no need to work with rose ceramics (Figs. 17-19).

Discussion

In the periodontally compromised situation, it is important to decide on whether a curative periodontal treatment offers satisfactory long term results. As in this occasion, the extraction in a crucial moment helps us preserve what we have, use it to the maximum for the implant surgery and risk no further bone loss or recessions. Any other procedure would have led to a two-stages surgical approach and probably to removable prosthetics. Very favourable was the thick biotype of the patient, such as the low lip line. The soft tissue quantity was evident. Tension on the flap closure was prohibited by the surgical protocol and the free granulation of the wound. The bone quantity insured a primary stable implant insertion. Immediate implantation provided stability for the augmentation and less material. The positioning of the implant allowed us to create an optimal emergence profile, making complicated soft tissue procedures unnecessary.¹⁷⁻¹⁹

The clinical situation and the bony defects made clear during surgery that we would have to make an aesthetic compromise in region 11-12. The bony support of the interproximal soft tissue is difficult to regenerate and the pseudopapilla formation not predictable. Immediate implantation in these regions preserve hard and soft tissue. Through the positioning of the implants and the free granulation of the extraction wound, we enhance the soft tissue, a major advantage for the re-entry and prosthetics.²⁰⁻²²

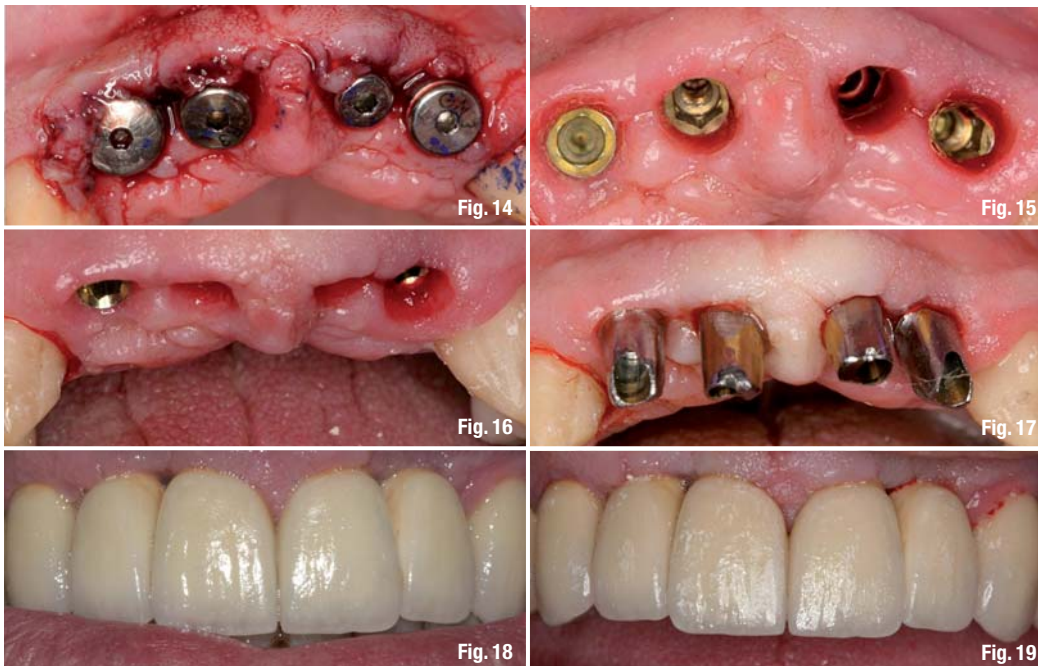

Fig. 14_ Re-entry with healing abutments.
Fig. 15_ Three weeks after re-entry.
Fig. 16_ Papilla morphology after healing abutments.
Fig. 17_ Definite abutments try-in.
Fig. 18_ Final prosthetics.
Fig. 19_ Pseudopapilla formation after three months of loading.

The implants placed feature micro grooves at the implant neck in a height of 1 mm. This laser manufactured design imitates biology and promises an improved cell adhesion on this surface. These modern designs, combined with the advantages of platform switching, result in high tech products. Modern crestal bone maintenance functions because of the protection of the crestal bone. When implants are placed subcrestally or crestally, a soft tissue ring builds on the platform and protects the bone beneath. When implants are placed supracrestally, implant neck options secure the crestal bone beneath, through soft tissue fibre attachment of their necks.^{23,24}

In cases in which primary closure is not possible or mobilization of neighbouring soft tissue through other flap designs is not wanted, temporary prosthetics are essential. The soft tissue manipulation begins from the very first moment and decides about the aesthetic outcome.²⁵⁻²⁷

The clinical situation after three weeks with healing abutments needed to be altered buccally at 11 and 21 and manipulated 0.5 mm apically. This was achieved via individualized abutments with convex base and breadth of 1 mm. In contrast, the gingiva margins at the lateral incisors needed to be corrected coronally. Therefore, we used narrow abutments to give soft tissue more space to head coronally.¹³⁻¹⁵

The combination of the biomaterials belongs to our standard augmentation protocol and is well documented. The results of guided bone regeneration are predictable and can be planned, even in major defects. In addition to the combined biomaterials, their structure is very important. Rocky and edgy particles help

internal stabilisation at the augmentation area. Often is an external stabilization with pins or screws unnecessary. The porosity of the particles is defined through their biology. This is the reason why we prefer no alloplastic biomaterials and take advantage of the pros of combined allografts and xenografts. At the same time, these are the requirements of modern biomaterials, accompanied of course by inductivity and conductivity.²⁸⁻³⁰ Periodontal diseases are a regular limitation factor in oral implantology. Thus, there are situations in which periodontal disease pose no contraindication to implantology. Preconditions for similar procedures are understanding and knowledge of biology, surgery and prosthetics. These procedures underlie no algorithms but proper diagnosis, analysis and planning of every individual patient and the choice of the appropriate implant system and biomaterials. Modern implantology provides all tools for successful implant treatment. Complications are, however, severe and can hardly be solved without compromises.

Editorial note: A list of references is available from the publisher.

_contact implants

Dr. Nikolaos Papagiannoulis
 Steigmann Institute
 Bahnhofstraße 64
 69151 Neckargemünd
 Germany

m.steigmann@t-online.de
 www.implantologie-heidelberg.de

Ridge augmentation for an atrophied posterior mandible using NanoBone block

Part I: Treatment outcome of complications

Authors Dr Omar Soliman & Prof. Dr Dr Mohamed Nassar, Egypt

Introduction

Reconstruction of the posterior mandible is challenging because the deformity involves deficiencies in both bone and mucosa,¹ and unlike the maxillary sinuses, the alveolar ridge does not provide a natural cavity to contain particulate grafting material.² Therefore, the graft must have sufficient strength and rigidity to be fixated at the recipient site. It must also be three-dimensionally stable to withstand muscular forces.³ Constraints in autogenous bone block graft availability from intra-oral sites often limit treatment possibilities.⁴ Among the possible alternatives to autogenous bone block grafting is the use of synthetic NanoBone block (ARTOSS GmbH). This article will discuss the potential complications during atrophied posterior mandible augmentation using NanoBone block, practically focusing on outcome of complications treatment (Figs. 1&2).

section of bone block graft often requires release cuts and dissection of the periosteum. Dissection of the periosteum is a common technique for elongation of the flap. However, excessive periosteum releasing incisions can also result in overthinned or overstretched soft tissue which when placed over the bone block graft may lead to perforation or flap necrosis. Tension-free wound closure is a key factor for success in bone block grafting procedures. So, full-thickness flaps should be prepared in the area of the grafted site and split-thickness flaps beyond the site to provide tension-free wound closure. Sharp edges of the bone block should be carefully avoided to prevent flap injuries.⁵

Complications during block grafting

Complications related to problems in bone block management

Shaping of the bone block for a perfect fit into the surgical site using rotating instruments may pose a risk of injury to the surgeon and fracture of the bone block.

Complications related to problems in soft tissue management

Soft-tissue related problems are even more difficult to handle and are often underestimated. Delicate mucosa, scar tissue and lesions may complicate coverage with sufficient soft tissue. The volume added by the insertion of bone block often requires release cuts and dissection of the periosteum. Opening of the wound due to flap retraction or flap necrosis with subsequent graft infection is one of the major complications in bone grafting procedures. However, this problem is predominantly one of soft tissue. Tension-free

Fig. 1 NanoBone block fixation at ridge augmentation procedures.

Fig. 2 Bone gained six months after ridge augmentation.

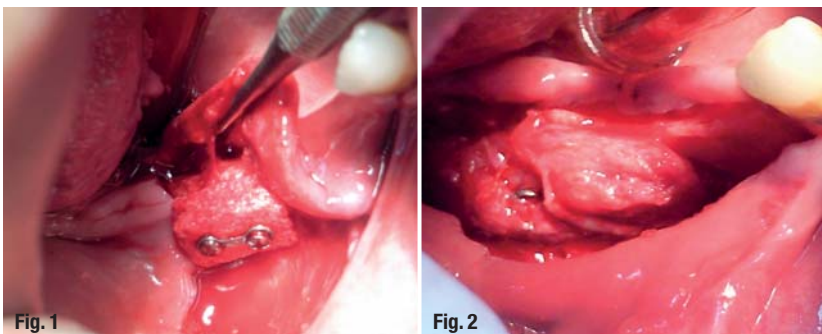


Fig. 1

Fig. 2

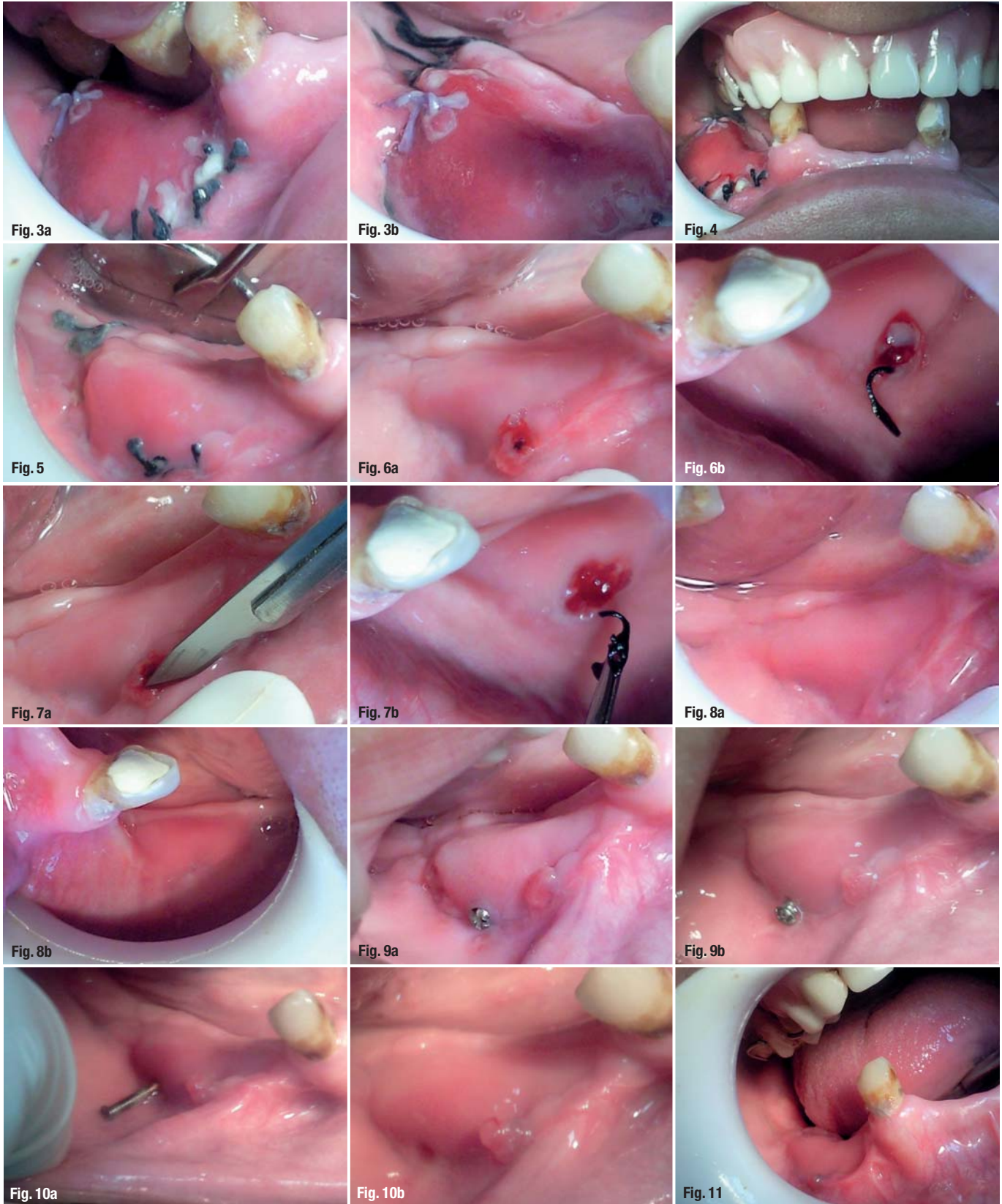


Portugal	March 21-22
Russia	June 11-13
Germany-Austria-Switzerland	June 26-28
USA	July 14-16
Japan	Sep 5-7
Belgium	Oct 17
Italy	Oct 23-25
Spain	Oct 30-Nov 1

Join us at our Symposia 2014
and find out how to treat
more patients better.

More information
[nobelbiocare.com/
symposia2014](http://nobelbiocare.com/symposia2014)





Figs. 3a & b _Trauma to overlying mucosa from upper molar.

Fig. 4 _Upper denture made to maintain centric occlusion.

Fig. 5 _Complete healing of the traumatic ulcer.

Figs. 6a & b _Infection to NanoBone graft (right side) and Fisiograft (left side).

Figs. 7a & b _Suture removal.

Figs. 8a & b _Complete healing.

Figs. 9a & b _Cover screw exposure.

Figs. 10a & b _Cover screw removal.

Fig. 11 _Healing of the overlying tissue.

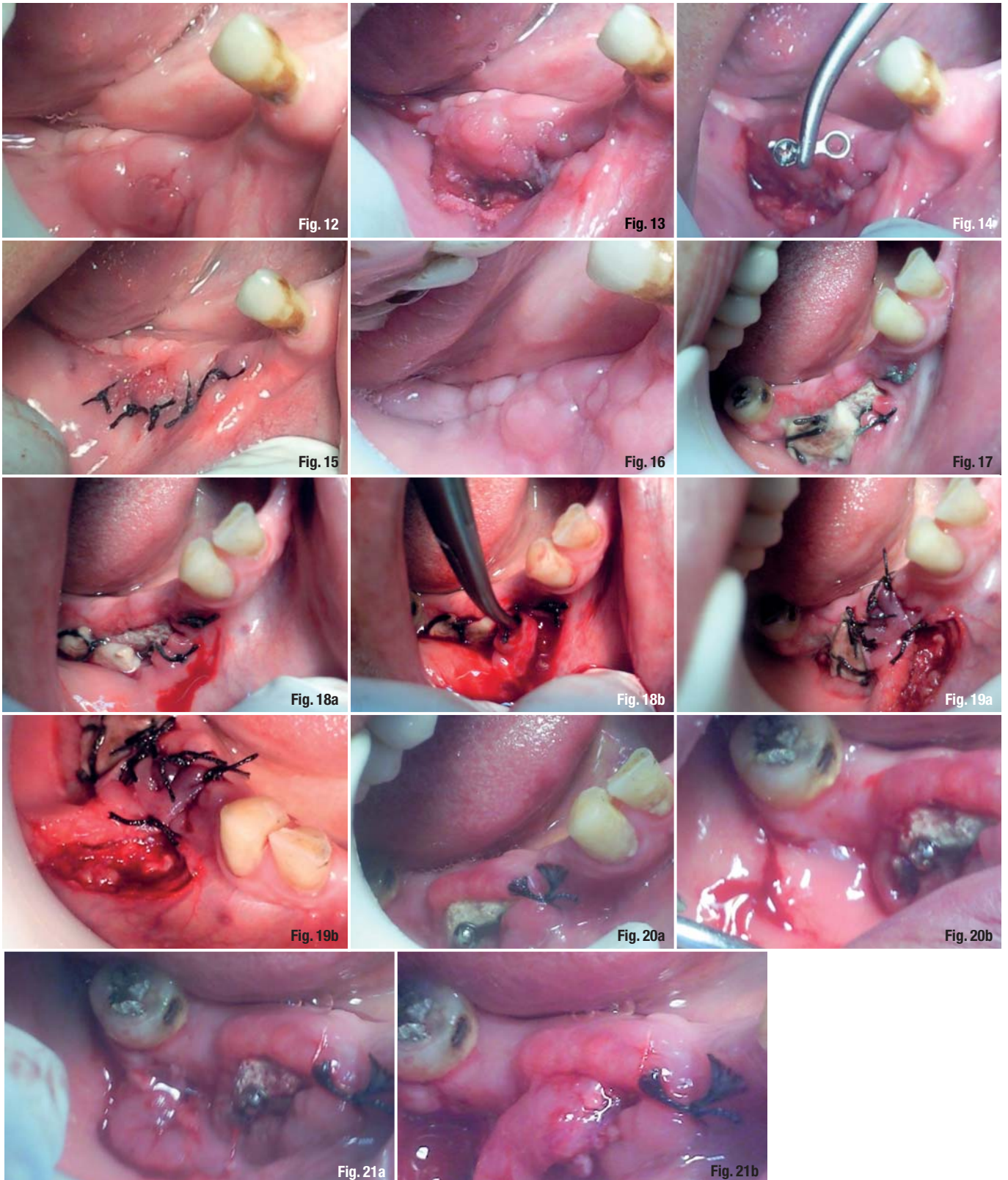


Fig. 12_ Inflammation of NanoBone block graft.
Fig. 13_ Vestibular incision.
Fig. 14_ Removal of miniplate and miniscrew.
Fig. 15_ Suturing.
Fig. 16_ NanoBone graft healing.
Fig. 17_ NanoBone block graft exposure.

Figs. 18a & b_ Vestibular incision and pedicle flap to cover NanoBone block graft.
Figs. 19a & b_ Suturing.
Figs. 20a & b_ Partial distal graft exposure.
Figs. 21a & b_ Distal pedicle flap.

wound closure is a key factor for success in bone grafting procedures. Dissection of the periosteum is a common technique for elongation of the flap. However, excessive periosteum releasing incision can also result in overthinned or overstretched soft tissue, which when placed over the bone graft may lead to perforation or flap necrosis. Full-thickness flaps should be prepared in the area of the grafted site and split-thickness flaps beyond the site to provide tension-free wound closure. Sharp edges of the graft should be carefully avoided to prevent them from injuring the flap or affecting the microcirculation of the tissue. Double layer wound closure, pouch or tunnel approaches, and pedicle connective tissue flaps are suitable techniques for prevention of these problems.⁵

Postoperative complications

Early Complications

- 1) Haematoma, swelling and ecchymosis: Swelling is a normal surgical effect, but it is also a cause of great concern to the patient. For this reason, patients must be informed that the surgical site or the face may swell. The patient must be assured that the degree of swelling is not an indicator of the success or failure of the surgery or the degree of difficulty of the case. Haematoma can complicate and prolong the postoperative phase. Ecchymosis is primarily an aesthetic problem. Discoloration of the facial and oral soft tissue is caused by extravasation and subsequent breakdown of blood in subcutaneous tissues. Ecchymosis is more common in fair-skinned patients and in elderly patients with fragile capillaries. It is basically the deposition of the blood from the surgery in the interstitial tissue spaces and will be resorbed. Heparin gel may accelerate the process of resorption.⁵
- 2) Dehiscence and flap necrosis: These soft-tissue complications are frequently the result of vascular compromise caused by inadequate planning, insufficient flap range or excessive surgical trauma, especially in smoking patients. Also, mechanical overloading of the grafted area with a removable prosthesis or through biting of the antagonist teeth could also be the cause of complication, with exposure of the graft to the complex microbiological spectrum in the mouth and graft infection which leads to graft degradation and total failure of the procedures. Dehiscence may occur because of premature separation of sutures as a result of inadequate suture technique or tension of the soft tissues. Retraction of a soft tissue flap is most likely where the vestibule is shallow or the muscle pull is great.⁵

Late complications

- 1) Exposure of the screws: During the healing process, a decrease in graft volume is a normal sign of the re-

modeling process. Vorhoeven et al. 2000 reported a loss of up to 25% of the overall height of bone graft.⁷ While the bone volume decreases, the fixation screws stay in their original position and may emerge through the overlying soft tissue. In the early stages of the healing, the screws have to stay in place for proper stabilisation of the graft. In the later stage, exposed screw can be removed. The soft tissue perforation will heal properly after a couple of days.⁵

- 2) Exposure of part of the graft: Knife-edge graft can provoke perforation of the overlying soft tissue with subsequent dehiscence. In addition, pressure from a removable temporary prosthesis can create local irritation and dehiscence, which will jeopardise the success of the operation. Hollowing out of existing provisional prosthesis to avoid direct contact with the wound bed is another key factor for success in bone graft procedures.⁵

If a small dehiscence occurs after block grafting, treating the site with chlorhexidine gel and mouth rinse can be attempted until wound closure. Exposed bone chips have to be removed. Exposed parts of the graft are considered to be contaminated and debridement with a bur has to be performed. Surgical intervention is used to achieve soft tissue closure only when the early stage of soft tissue healing is over. After the initial healing process, debridement of the graft has to be performed and a conventional flap design may be used to try to close the soft tissue. If the site is not covered with soft tissue during the first two weeks after intervention, the complete graft has to be removed.⁵

Editorial note: To be continued in the next issue of implants: international magazine of oral implantology, with an extensive description of complications and conclusion.

A complete list of references is available from the publisher.

contact

implants

Dr Omar Soliman

PhD Candidate Perioimplant Dentistry

Tel.: +20 1009634358, +20 1201005457

Omar.Soliman77@yahoo.com

Prof. Dr Dr Mohamed Nassar

Professor of Perioimplant Dentistry

Faculty of Dentistry, Tanta University, Egypt

Tel.: +20 1121522221

prof_mnassar@yahoo.com



ENTER THE DRIVE WORLD



Dental Implants Designer and Manufacturer - Training Center - Pole of Excellency

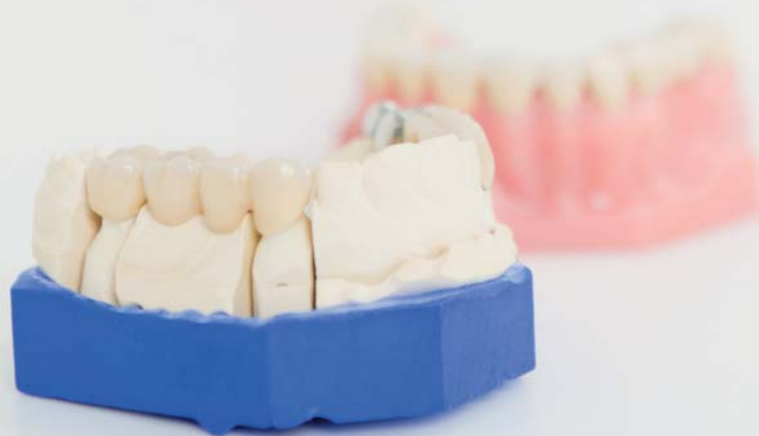Contact : 0033 (0)9 62 30 67 27
Lyon - FRANCE

www.driveimplants.com



Comprehensive prosthetic restoration

Authors Michael Peetz & Dominik Büchi, Switzerland



[PICTURE: ©RACORN]

Introduction

In clinical practice, cases are often much more complex than described in textbooks and selection of the best treatment option is not always straightforward.

Dental Campus contains numerous clinical cases that are structured in a standardised format. You can follow every treatment phase, from the initial findings to the maintenance therapy, and you can discuss with colleagues from all over the world.

Fig. 1 Screenshot of the initial findings. The case presentation simulates the situation on the desk of the practitioner.

Would you like to expand your clinical knowledge, be able to discuss your cases and the various treatment solutions with your colleagues while collecting CME credits? These features are brought to you by the new e-learning platform Dental Campus.

Discover the second case of the Dental Campus series presented below in which other practitioners may have chosen different "optimal" therapies and create your own treatment plan online. The full case can be found at: www.dental-campus.com/cases/comprehensive-case-in-a-woman.

Fig. 2 Intraoral radiographs.

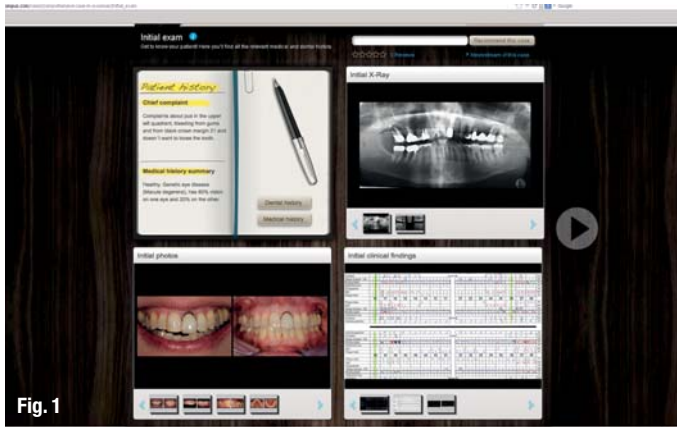
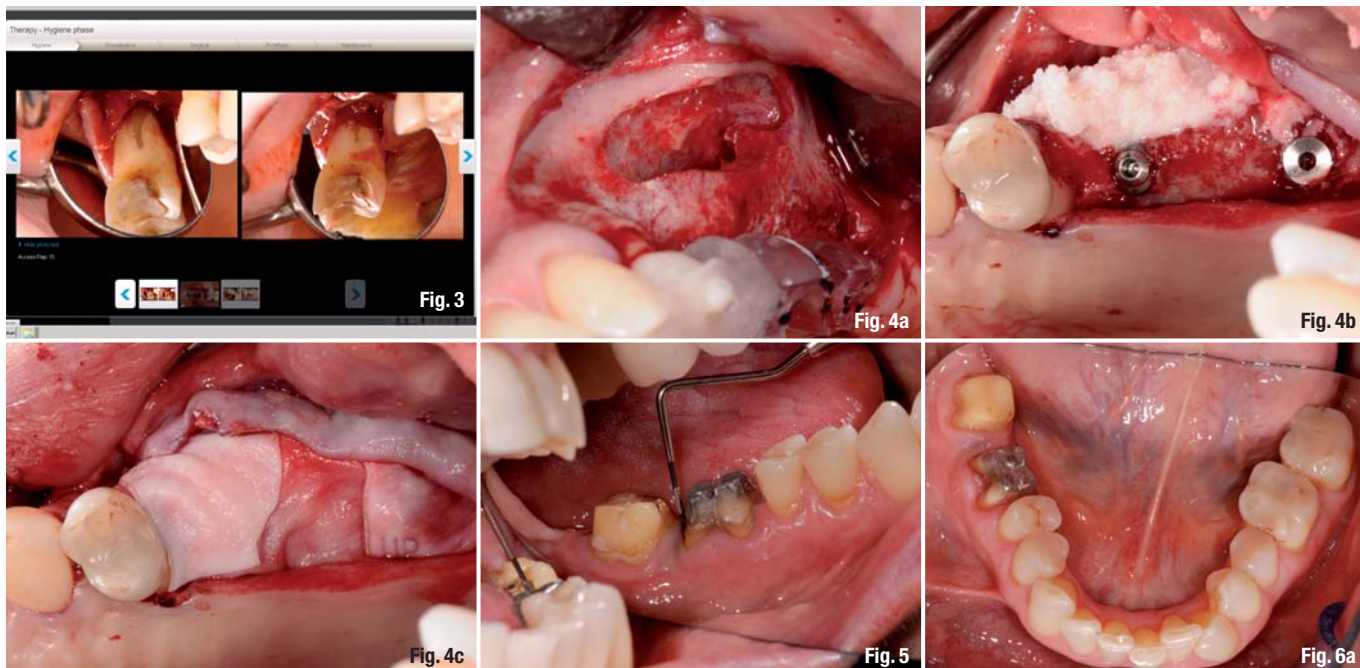


Fig. 1

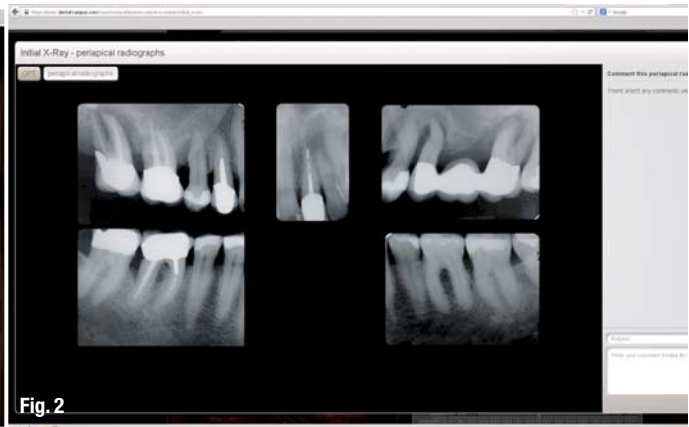

Fig. 2



Clinical findings

The patient complains about a purulent inflammation in the left upper quadrant and gingival bleeding (Fig. 1). Metal crown margins in the aesthetic zone on tooth 21 are visible and cause a significant dissatisfaction for the patient. The patient expresses a strong interest in keeping this tooth. Generally, she suffers from macular degeneration with vision loss of 20 and 80 per cent.

The periodontal examination shows increased probing depths of up to 12 mm in the mandible and up to 13 mm in the maxilla, with a BOP of 36 per cent. Vertical bone loss and apical radiolucency are evident from the OPTG and the intraoral dental X-ray images (Fig. 2).

The teeth 17, 25, 27 and 38 are not worth retaining and prognoses of the teeth 16, 15, 21, 24 and 46 are questionable.

How would you proceed?

A chronic aggressive periodontitis is diagnosed. The detailed diagnosis of the case can be found online at Dental Campus. At the e-learning platform, you can also create your own diagnosis for this patient with a few mouse clicks, define the prognosis for each tooth and plan the treatment using the digital dental chart. Then, you may compare your planning with the planning of other users and with the actual therapy option chosen by the treating practitioner. Optionally, you can discuss the treatment options in the forum.

Therapy

a) Periodontal pretreatment with tooth extraction

Which teeth should be extracted before the periodontal treatment? Teeth 17, 16, 25, 27 and 38 are to be extracted. During periodontal therapy, the patient is given a partial denture anchored on teeth 15 and 24.

For teeth 15 and 46, an open procedure is chosen. Here we observe that tooth 15 is also not worth preserving, although the tooth during the cold test responded as vital (Fig. 3). At tooth 46, the probing depth has decreased but still amounts to 6 mm distolingually and 7 mm distobuccally.

b) Surgical phase

After periodontal therapy, the sinus floor is bilaterally augmented (Fig. 4a). In order to improve the bone volume, a horizontal ridge augmentation in quadrant 2 is also performed (Figs. 4b-c). Implants are placed in regions 17, 16, 25 and 27.

c) Prosthetic restoration

Selected stages of the prosthetic restoration are shown in Figures 5–8. The entire detailed procedure is illustrated online with numerous images.

Tooth 21 is re-crowned on the original post and abutment. Teeth 46 and 47 each receive single crowns. Teeth 24, 36, 37 and 45 get new composite fillings.

Would you have chosen the same approach, or would you recommend a different therapy option for the patient? Instead of large-scale fillings on teeth 24,

Fig. 3 The open periodontal therapy shows that tooth 15 is not worth preserving. The tooth is extracted.

Figs. 4a–c Bilateral sinus floor elevation, implantation and horizontal ridge augmentation. Only Quadrant 2 is shown.

Fig. 5 Preparation of tooth 46 and 47.

Figs. 6a & b Clinical situation at impression-taking.

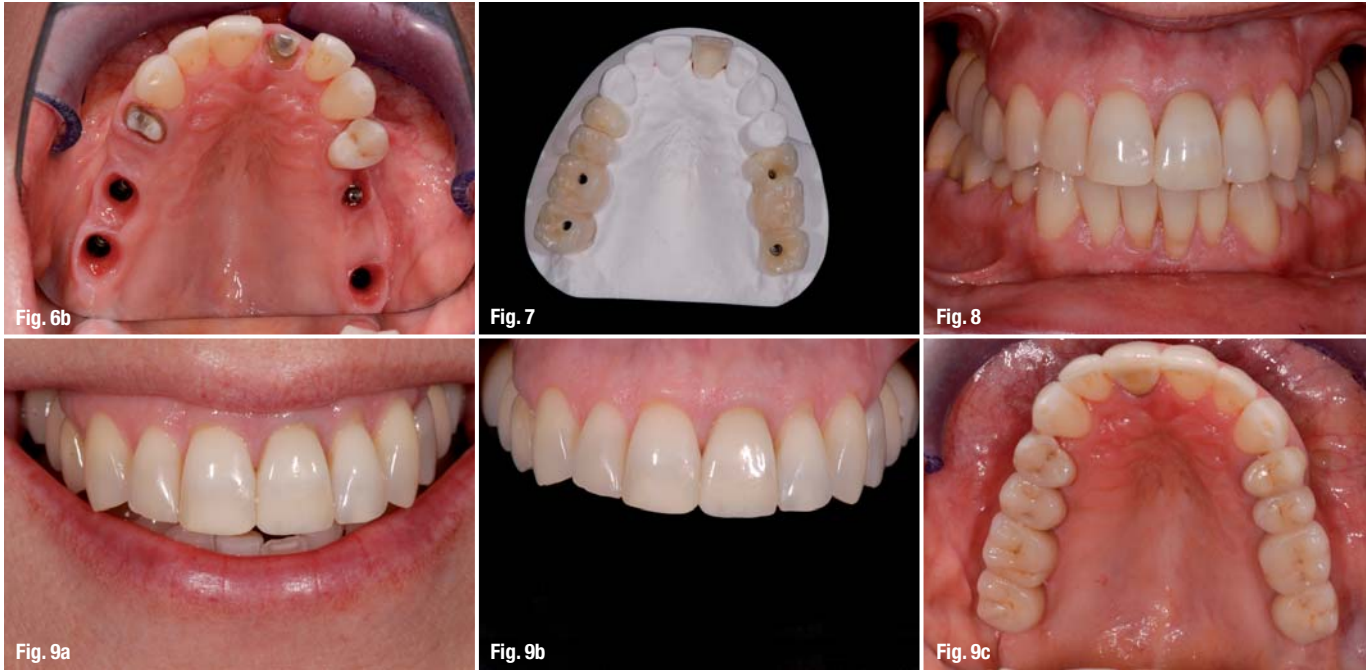


Fig. 7_Wax-up maxilla. 36, 37 and 45, partial crowns could have also been a solution.
Fig. 8_Try-in.
Figs. 9a–d_Final results.

How would you have treated tooth 46? This tooth has a questionable prognosis and additional costs are associated with the open periodontal therapy. Instead of the single crown, would you rather have chosen to extract the tooth and place a bridge over teeth 44, 45 and 47? Or would you have replaced tooth 46 with an implant? Log on to Dental Campus and discuss this case!

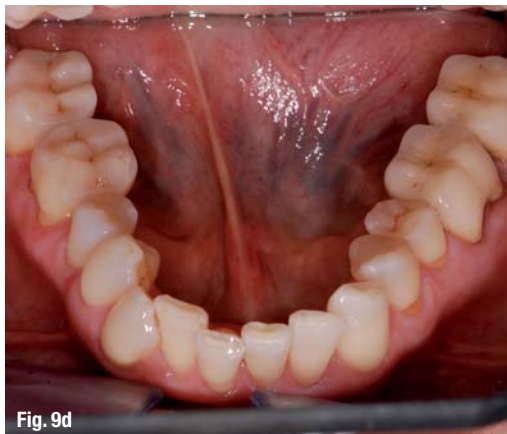**_Treatment outcome—
 What do you think?**

The patient has an appealing restoration with which she is satisfied (Fig. 9). Periodontal therapy enabled the probing depth at tooth 46 to be reduced to 4 mm distolingually and 3 mm at all other points measured.

The implant in region 25 has a mesiobuccal probing depth of 6 mm. The patient received detailed oral hygiene instructions and was integrated into a regular recall program.

The case described here is an example of a typical case and documentation found on Dental Campus. Extensive background information and a detailed presentation of each treatment step allow you to closely follow the treatment planning, understand its implementation, with high practical relevance for your daily practice.

How do you rate the choice of treatment and the outcome of this case? Would you have handled the case differently? Register as a Dental Campus user, discuss the treatment with your dental colleagues and receive 2 CME credits for your work on the case.



_contact	implants
<p>Dental Campus Englischviertelstr. 32 8032 Zurich, Switzerland</p> <p>Tel.: +41 44 5156010 Fax: +41 44 5156911</p> <p>info@dental-campus.com www.dental-campus.com</p>	



5TH INTERNATIONAL

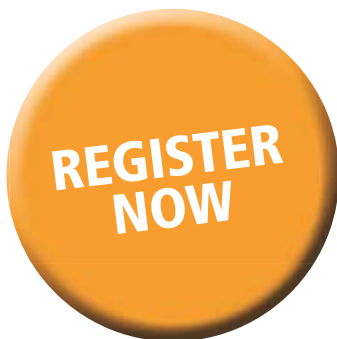CAMLOG CONGRESS

26TH – 28TH JUNE 2014

VALENCIA, SPAIN



CONGRESS OF THE YEAR



No claims without proof! And proof we have! Not only do the delegates give us enthusiastic feedback, they keep registering again and again. Not surprising, having attended once, you never want to miss another congress! Focused competence, practical benefits and the lively atmosphere at the congress speak for themselves. Register for the congress - we look forward to welcoming you!

THE EVER EVOLVING WORLD OF IMPLANT DENTISTRY

camlogfoundation

More information and registration:
www.camlogcongress.com



Jawbone cavitation and its implication in implant dentistry

Author_Prof. Dr Mauro Marincola, Italy

Introduction

A cavity is a hole in a tooth, whereas a cavitation is a hole in bone. Unlike most tooth cavities, bone cavitations cannot be detected by simply looking at the bone, rather they must be determined radiographically and the interpretation thereof requires an expert eye, consequently many cavitations are missed.

In the last several years, the term "cavitation" has been used to describe various bone lesions that appear both as empty holes in the jawbones and holes filled with dead bone and fibrous marrow. The term "cavitation" was created in 1930 by an orthopaedic researcher who described a disease process in which a deficiency in blood flow into the area resulted in a hole in the jawbone

and other bones. Dr G.V. Black described this cavitation process in 1915 as a progressive process in the jawbone in which bone cells are destroyed, generating large cavitation areas within the jawbones.¹ Black found it striking that this disease produces vast jawbone damage without redness in the gingiva, pain, swelling of the jaw, or a rise in body temperature. In effect, this disease process produces small blockages or infarctions of the small blood vessels in the jawbones, leading to areas of dead bone or osteonecrosis. These dead areas are today called neuralgia-inducing cavitational osteonecrosis lesions.

The results of recent research by Dr Boyd Haley, former Chairman of the Department of Chemistry at the University of Kentucky, show that the cavitation tissue

Fig. 1 Only a cavitation that has formed with additional calcification around a well-defined border will be visualized on X-ray. Observe the encapsulated extraneous body.

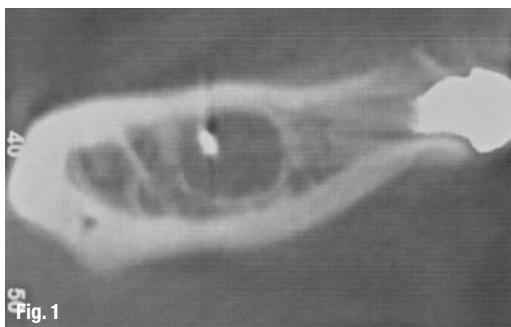
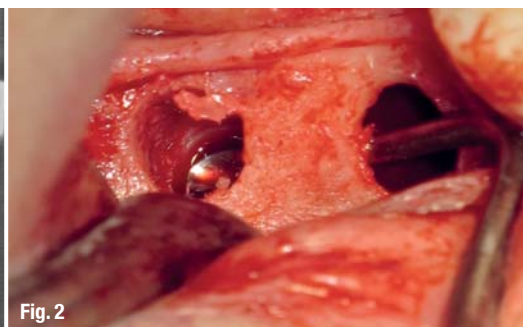


Fig. 2 An explored channel might be counted as only one cavitation when it actually developed from more than one unhealed extraction site. Larger cavitations can extend below the mandibular nerve.



Figs. 3a & b 15 mm mesio-distal and 10 mm vertical bone cavitation filled with β -TCP graft. The distal hole was a third of dimension and a Short Implant (Bicon) could be placed immediately.

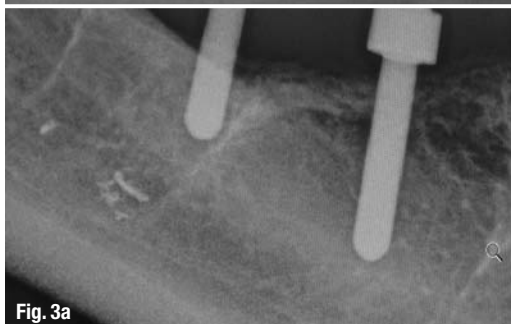

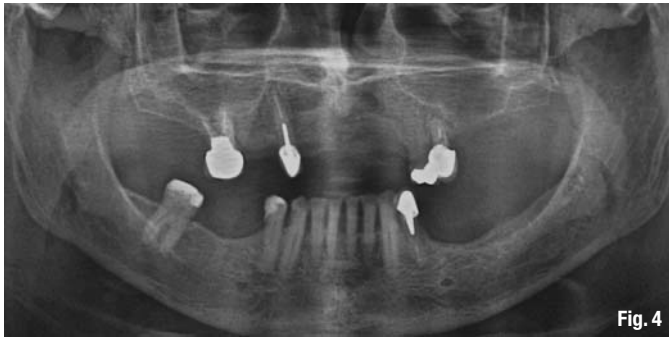


Fig. 4

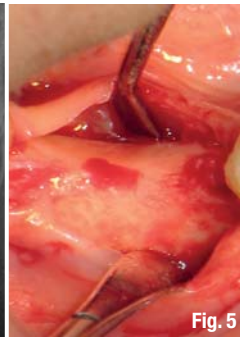


Fig. 5

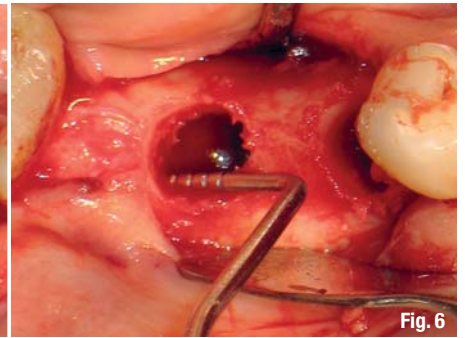


Fig. 6

samples he tested contained toxins that significantly inhibit one or more of the five basic body enzyme systems necessary for the production of energy.² These toxins, which are most likely metabolic waste products of anaerobic bacteria, may produce significant systemic effects, as well as play an important role in localised disease processes that negatively affect the blood supply in the jawbone. There are indications that when these toxins combine with certain chemicals or heavy metals (e.g. mercury), much more potent toxins may form.

Factors associated with cavitation bone lesion development

Cavitation lesions can be caused by many factors, most likely a combination of these will characterise occurrence, type, size, progression and growth patterns.

Initiating factors

Probably the major initiating factors are of dental origin in terms of physical, bacterial and toxic traumas.

- Physical trauma: tooth extractions, dental injections, periodontal surgery, root canal procedures, grinding and clenching, electrical trauma from dissimilar metal restorations, incomplete removal of periodontal ligament after tooth extraction, overheat from high-speed drilling.
- Bacterial trauma: periodontal disease, cysts, abscesses, root canal bacteria from non-vital teeth, infected wisdom teeth.
- Toxic trauma: dental materials, root canal toxins, anaesthetics with vasoconstrictors, chemical toxins.

Risk factors

Predisposing factors encompass antiphospholipid antibody syndrome; blood clotting disorders (thrombophilia and hypofibrinolysis); age; changes in atmospheric pressure owing to occupation; Gaucher's disease; gout; haemodialysis; homocystinaemia; hyperlipidaemia; lymphoma or bone dysplasia; osteoporosis; physical inactivity; radiation or chemotherapy; rheumatoid arthritis; sickle-cell anaemia; systemic lupus erythematosus; and thyroid or growth hormone

deficiencies. Cavitation lesions are prompted by many factors. Many of them affect the occlusion or blockage of small blood vessels of the jawbone. In addition to minor risk factors, the most prominent are alcoholism, heavy smoking, long-term high-dose cortisone use, oestrogen use, pancreatitis or pregnancy.

Research shows that 45–94 per cent of all cavitation lesions are found at wisdom teeth extraction sites.³ These areas contain many small blood vessels, making them an ideal developing site for bony lesions, as these vessels are easily affected by trauma in surgical procedures. As a result, osteonecrosis can develop. In addition, numerous local anaesthetic solutions contain vasoconstrictors (particularly epinephrine). Vasoconstrictors are applied in order to restrict or reduce the blood supply to bone, teeth or gingival tissue, thus prolonging the anaesthetic effect and minimizing bleeding. As many local anaesthetics are injected in the wisdom teeth area, their application increases the occurrence of cavitation lesions in this region.

Another frequent cause of ischemic osteonecrosis in the jawbone is improper endodontic treatment. Few endodontic treatments are performed by a specialised dentist and the result is that the root canals become loaded with anaerobic bacteria or chemically toxic material used for the canal filling. The pathogenetic substance reaches the bone, eventually causing loss of bone density and holes inside the cancellous bone (Fig. 1). Since there is no longer a sufficient blood supply, the body cannot fight the toxins and the bony structure degenerates into necrotic bone and fibrous marrow.

As a reminder, neuralgia-inducing cavitation osteonecrosis is not so much an infection in the bone as necrosis or gangrene (dead tissue) of the bone marrow as a result of impaired blood flow (ischemia). A cavitation often develops because of incomplete healing after routine extraction.

When the periodontal ligament is not entirely removed from the socket after extraction, the surrounding bone receives no notification that the tooth is gone. The continued presence of any portion of the ligament gives the biological message to the surrounding jaw-

Fig. 4 A trained eye is needed to recognise the circular bone cavitation mesial to the lower right molar. Observe the capsulation, the thin crestal cortical and the lack of trabecular geometry.

Fig. 5 Intra-oral view of the cavitation region. No defect can be observed clinically.

Figs. 6 & 7 Depth gauge demonstrating the absence of trabecular bone. The distal extension of the hole is approx. 10 mm.

Fig. 8_Solid, healthy bone must be reached to allow the normal regeneration of bone. When infection or necrosis remain throughout the socket and adjacent bone, with or without condensing osteitis, healing will rarely ever be completed.

Figs. 9 & 10_The hole is filled with a synthetic graft material (Synthograft) after elimination of fibrous marrow and disinfection of the cavity.

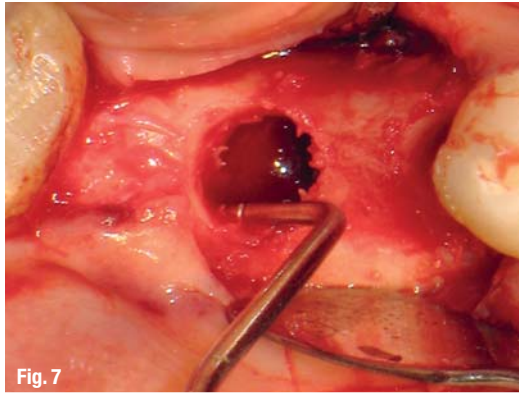


Fig. 7

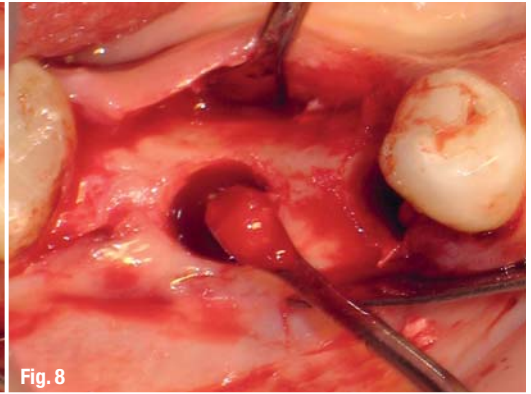


Fig. 8

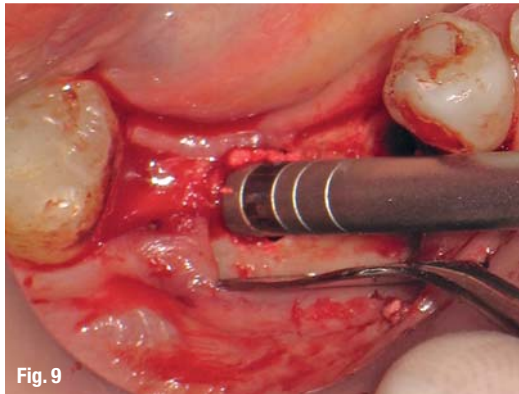


Fig. 9

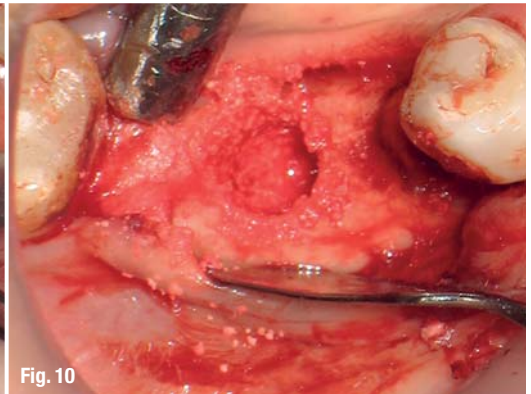


Fig. 10

bone that all is well, and no new bone growth is needed. Bone cells thus do not start new growth and then migrate through a barrier naturally designed to limit such growth. The jawbone determines that if the ligament is still there, the tooth must be there as well.

Since the periodontal ligament does not extend to the upper edge of the extraction site, new bone growth activity will not be inhibited at the top of the socket, and a characteristic thin cap of bone will eventually extend over the extraction hole. Larger cavitations often have only a cap of gingival tissue over them. Even the thin overlying cap of bone does not form in these cases. In routine dental extraction, portions of the periodontal ligament will sometimes be more strongly attached to the tooth than the bone and be removed along with the tooth. When partially removed in this fashion, the haphazard absence of the ligament will permit equally haphazard growth of bone, resulting in the wide variety of cavitation shapes and sizes (Fig. 2).

Treatment

Surgery is often necessary to clean out a cavitation site properly and thoroughly, for there is no other way to remove dead bone. The key to bone healing and regeneration is the removal of the necrotic tissue. If the necrotic tissue is not thoroughly removed, the necrosis will spread and cause further destruction to the bone, nerves and blood vessels. This kills teeth in the process, for they are cut off from their blood supply. Once the necrotic tissue has been cleaned out, healing can then

take place and new bone cells will fill in the cavitations. Neither antibiotic injections into the bone nor laser treatments will stop the progressive necrosis if not all debris has been thoroughly curetted out of the cavitation.

The next treatment step is a bone grafting procedure to fill the cleaned and disinfected cavity. If the cavitation is limited to 5–6 mm in diameter, a plateau press fitted root form implant can be placed into the grafting material immediately. Otherwise, the implant will be placed in a larger grafted area after three months of healing (Figs. 3a & b).

Clinical implications

The following case is representative of many other cases I have encountered during 25 years of clinical experience in numerous clinics in various countries. A 52-year-old female patient came to the practice with 19 missing teeth in both the maxillae and the mandible. The second premolars and first molars had been extracted between five and 12 years ago, after incorrect endodontic treatment. She noted that the molars had had abscesses and the premolars had fractured a few years after the poor endodontic treatment.

The treatment plan was to insert four short implants to replace the second premolars and first molars of the mandible. The dental panoramic tomogram showed a circular formation of 5–6 mm in diameter mesial to the second molar root on the right side of the mandible

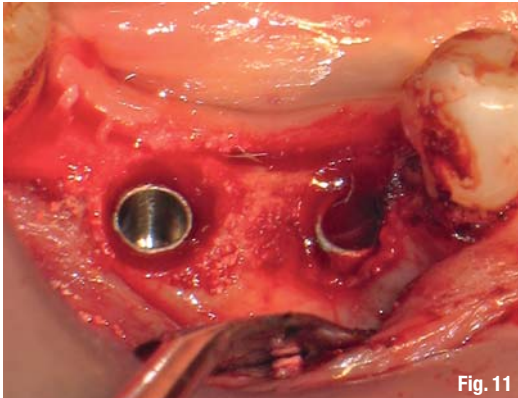


Fig. 11

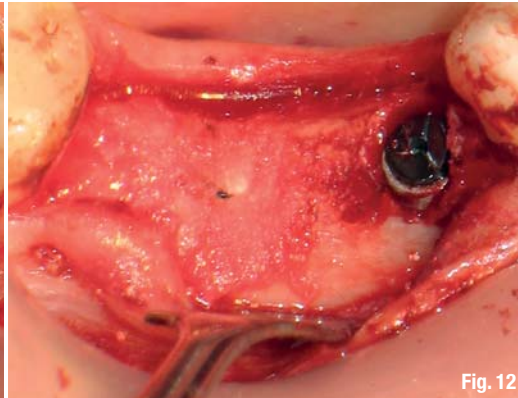


Fig. 12

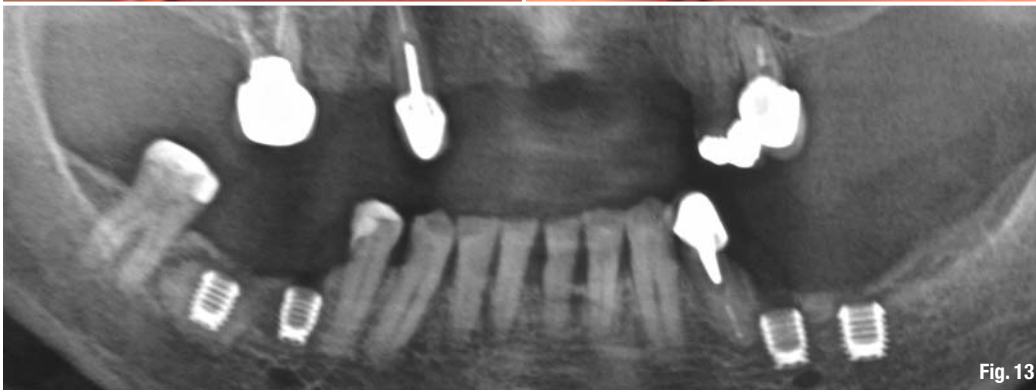


Fig. 13

Figs. 11 & 12 Two 5 x 6 mm Short Implants (Bicon) are directly placed into the graft and buried under the crestal bone.

Fig. 13 Evidence of the grafted bone cavitation and implant placement. Mandatory is the use of Short Implants in order to avoid proximity to the mental nerve and the alveolar nerve.

(Fig. 4). My experience with bone cavitations suggested a surgical approach that would entail performing an osteotomy and afterwards cleaning, disinfecting and filling the cavitation before placing the implant. Bone cavitations are not visible at crest level (Fig. 5) because the bony defect is located inside the bone marrow.

Once the diameter of the planned implant size (5 mm) had been achieved, the walls and floor of the osteotomy were controlled with a depth gauge. All walls except the lingual plate were missing and no floor limited the 8 mm length of the osteotomy. The depth gauge established a distal hole of 10 mm. The mesial and buccal defects extended for only a few millimetres (Figs. 6 & 7).

The fibrous tissue was removed from the cavity with a Lucas curette (Fig. 8). Multiple applications of a diode laser combined with local antibiotics were performed before proceeding to fill the cavity.

The graft material should be 100 per cent synthetic in order to avoid cross infection, as may be the case with xenografts. The beta-tricalcium phosphate (β -TCP; SynthoGraft, Bicon) was mixed with the patient's blood and injected into the cavity (Figs. 9 & 10). Once the cavity had almost been filled, two Short Implants (\varnothing 5 mm, length 6 mm) were placed into the graft (Fig. 11). Finally, the implants were completely buried under the crestal bone (Fig. 12), in accordance with the characteristics of the implant design (plateau press fitted root form implant).

Short implants were necessary in this case because of the reduced vertical jaw dimension and the proximity to the mental nerve and the inferior alveolar nerve (Fig. 13).

Conclusion

It is paramount for a good clinician to be able to recognise bone cavitation. Performing a correct osteotomy depends on the integrity of the four walls and the floor. If one or more of the structures mentioned are missing during inspection with the depth gauge, the quality and consistency of the bone marrow should be tested.

In some cases, a screw-retained implant may be retained in the crestal bone only while most of the implant body is unstable because of the presence of a hole. Owing to the multifactorial causes listed in this article, the cancellous bone in that specific area has become necrotic tissue, creating the cavitation.

Editorial note: A list of references is available from the publisher.

_contact

implants

Prof. Dr Mauro Marincola

Via dei Gracchi 285
00192 Rome, Italy

Immediate implantation and full-ceramic restoration in the maxillary anterior region

Authors Dr Arndt Happe & Andreas Nolte, Germany

Introduction

Implant-supported single-tooth crowns in the aesthetic zone are a special challenge, particularly when immediate implantation is planned—if there is insufficient bone volume and a thin biotype. A whole chain of critical factors need to be considered here, including implant positioning,^{1,2} hard- and soft-tissue management^{3–5} and the natural design of the crown.⁶ These days, a number of digital methods are available to simplify the process and make it safer.⁷ Depending on the initial situation, that is maximum aesthetic demands, however, many dentists prefer analogue methods, as in the following example.

ing to a weakening of tooth substance, resulting from excessive cavitation as part of post-endodontic restoration (Fig. 2). In addition, the existing crown kept coming off owing to the poorly retentive design of the abutment.

In order to obtain the most accurate assessment of the initial situation, the dental technician photographed the patient in his laboratory. Using the photograph and initial models, he defined the shape and colour of the planned restorations and carefully analysed their position in the arch for the temporary restoration (Fig. 3). Based on the data obtained, a temporary bridge was fabricated for teeth 12 to 21 once tooth 11 had been extracted.

Initial findings and planning

A young female patient with full-ceramic crowns on teeth 12 to 22 presented at our clinic desiring bright and natural new restorations (Fig. 1). Her medical history was unremarkable and her gingival type was classified as thin. Tooth 11, which had undergone root canal therapy, could not be saved and would have to be replaced with an implant ow-

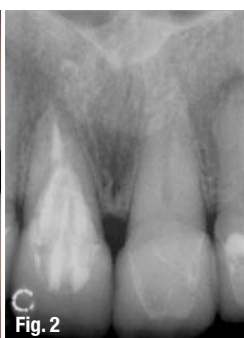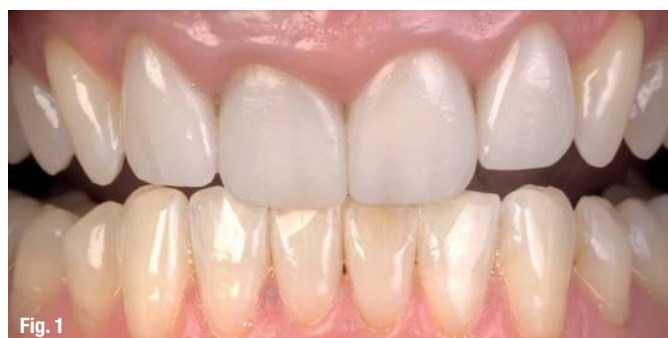Immediate implantation and temporary restoration

In order to extract tooth 11 with as little trauma as possible, the surgeon first severed the periodontal fibre system with a periotome (Fig. 4) and expanded the coronal alveolar gap with piezo-surgical instruments. First, the crown was luxated and extracted with extraction pliers, then the root,

Fig. 1 The female patient wanted new restorations with bright, natural-looking crowns in regions 12 to 22.

Fig. 2 Tooth 11 could not be saved and was to be replaced with an implant.

Fig. 3 The photographs and situation models were analysed in terms of aesthetics, and all details diligently recorded on the relevant form.



44TH

INTERNATIONAL ANNUAL CONGRESS OF THE DGZI

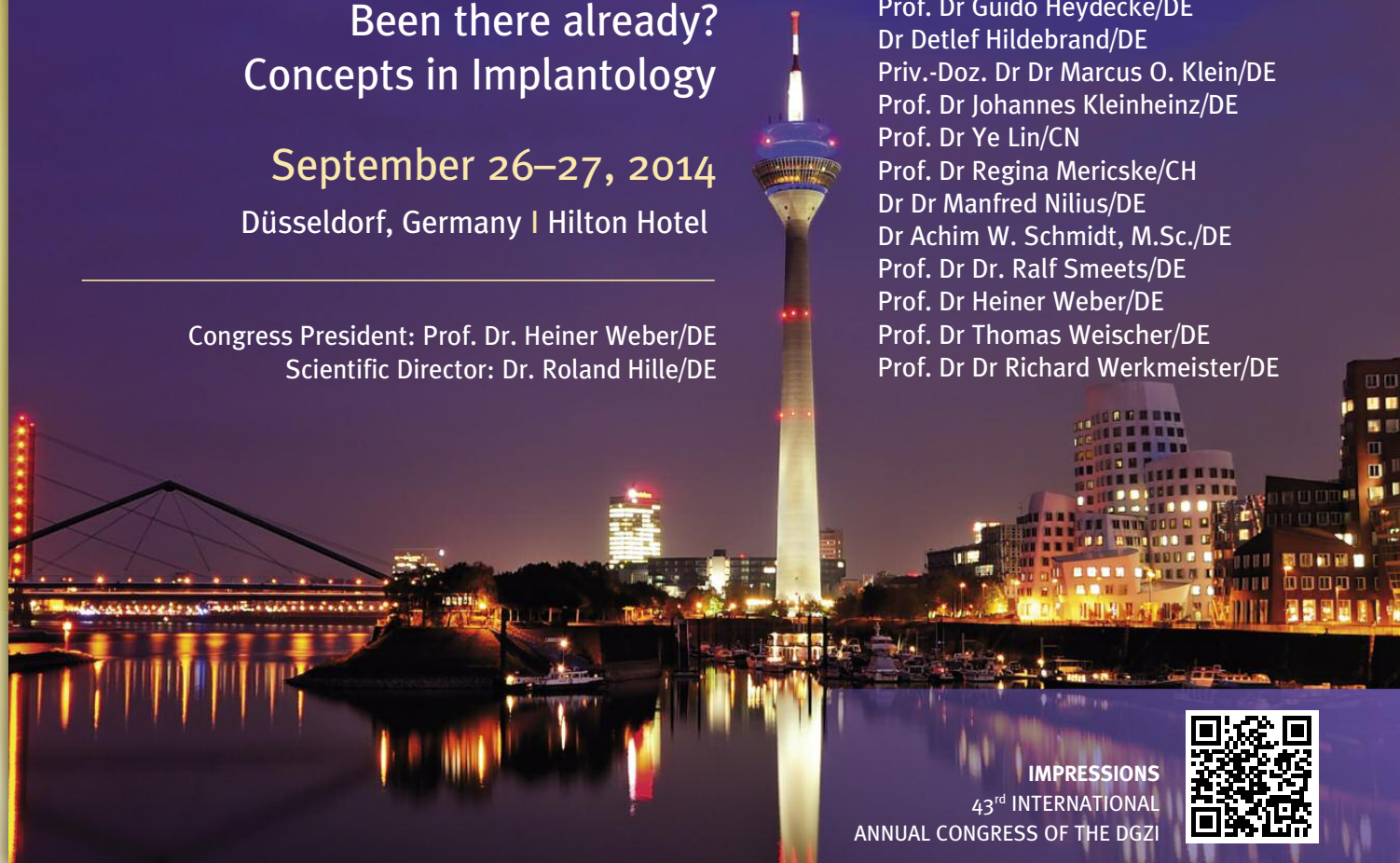Been there already?
Concepts in Implantology

September 26–27, 2014
Düsseldorf, Germany | Hilton Hotel

Congress President: Prof. Dr. Heiner Weber/DE
Scientific Director: Dr. Roland Hille/DE

SPEAKERS

Prof. Dr Florian Beuer/DE
Priv.-Doz. Dr Kai-Hendrik Bormann/DE
Prof. Dr Suheil Boutros/US
Dr Dirk U. Duddeck/DE
Prof. Dr German Gomez-Roman/DE
Prof. Dr Wolf-D. Grimm/DE
Priv.-Doz. Dr Friedhelm Heinemann/DE
Prof. Dr Kai-Olaf Henkel/DE
Prof. Dr Guido Heydecke/DE
Dr Detlef Hildebrand/DE
Priv.-Doz. Dr Dr Marcus O. Klein/DE
Prof. Dr Johannes Kleinheinz/DE
Prof. Dr Ye Lin/CN
Prof. Dr Regina Mericske/CH
Dr Dr Manfred Nilius/DE
Dr Achim W. Schmidt, M.Sc./DE
Prof. Dr Dr. Ralf Smeets/DE
Prof. Dr Heiner Weber/DE
Prof. Dr Thomas Weischer/DE
Prof. Dr Dr Richard Werkmeister/DE



IMPRESSIONS
43rd INTERNATIONAL
ANNUAL CONGRESS OF THE DGZI



Gold Sponsor



Silver Sponsor



Bronze Sponsor



FAX REPLY // +49 341 48474-290

Please send me further information on the
44TH INTERNATIONAL ANNUAL CONGRESS OF THE DGZI
on 26–27 September, 2014, in Berlin, Germany.

Office Stamp

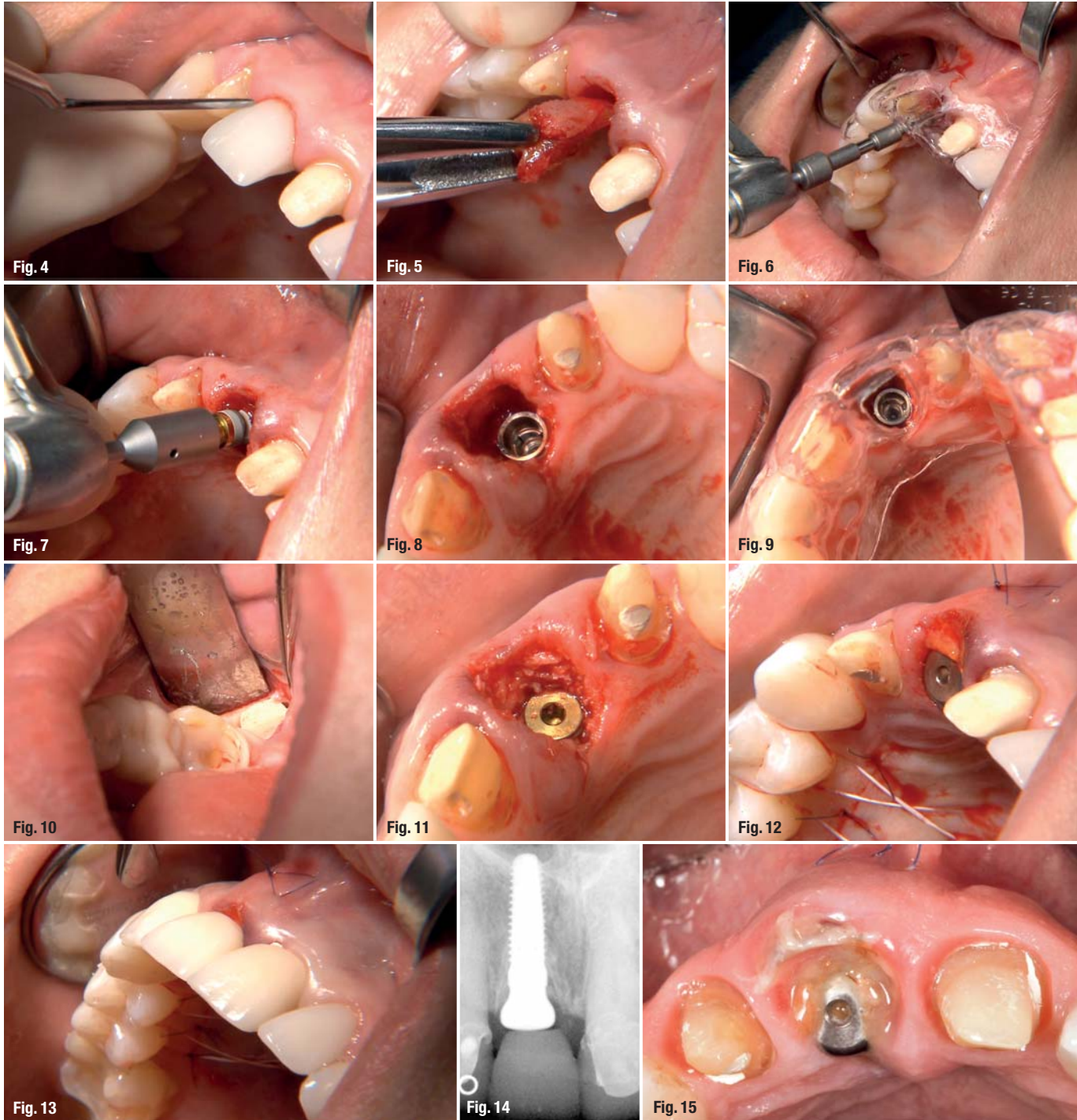


Fig. 4 After removing the temporary crowns on teeth 12 and 21, the supra-alveolar periodontal attachment of tooth 11 was severed with a periosteal elevator.
Fig. 5 The root was extracted after atraumatic removal of the crown. The buccal bone lamella connected to the root surface was lost during the process.
Fig. 6 The palatal margin of the alveolus was marked with the pilot drill through a deep-drawn guide prepared in the laboratory.
Fig. 7 When inserting the implant, the surgeon oriented himself along the palatal bone wall.
Fig. 8 The implant was palatally displaced in the correct position; the buccal bone lamella no longer existed.
Fig. 9 The position of the implant in the dental arch was checked with the aid of the guide.

Fig. 10 A retromolar bone cylinder was harvested with a trephine drill to obtain autologous bone for augmentation of the buccal lamella.
Fig. 11 The space between the implant and buccal soft tissue was filled with a mixture of autologous bone and bovine bone replacement material.
Fig. 12 In order to obtain optimal buccal contours, a connective-tissue graft harvested from the palate was drawn under the soft tissue and sutured.
Fig. 13 The temporary bridge was cemented with the healing cap without contact with the pontic.
Fig. 14 The sub-crestal bone position and good cervical join of the temporary bridge are shown on the post-operative X-ray.
Fig. 15 Good healing and successful integration of the connective-tissue graft are evident one week after immediate implantation. The white-yellow deposits are fibrin.

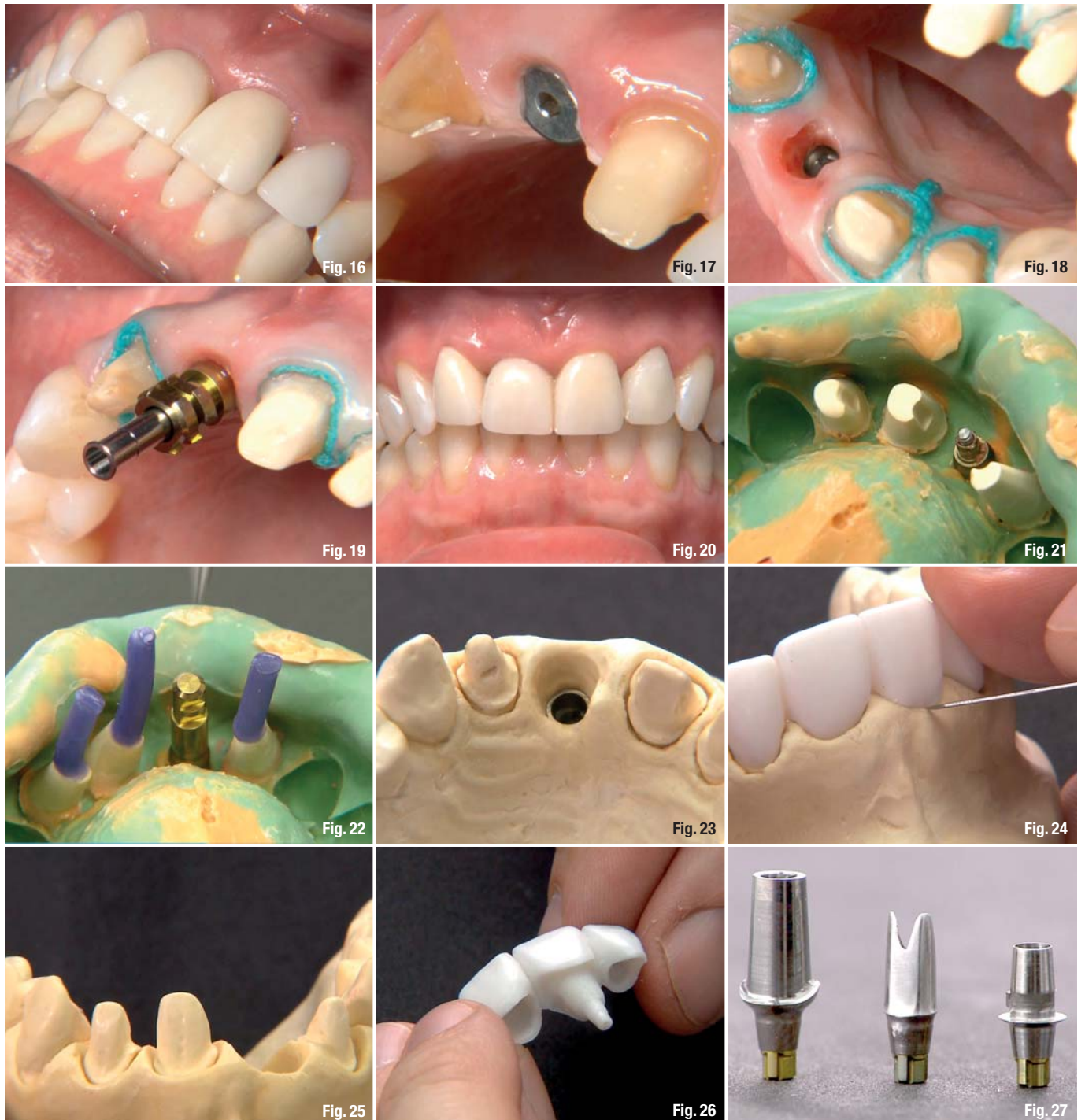

Fig. 16_ After a three-month healing period, the implant was successfully osseointegrated and the soft tissue had stabilised for final impression taking.

Fig. 17_ The peri-implant soft tissue is well formed and largely irritation free under the temporary bridge.

Fig. 18_ Good perfusion of the peri-implant soft-tissue well can be observed. Buccal tissue thickness exceeds 3 mm.

Fig. 19_ Impression taking of the prepared teeth and the implant.

Fig. 20_ Following reinsertion of the temporary bridge, excess soft tissue was observed in the area of the implant (position 11).

Fig. 21_ Individual stumps made of super-hard plaster with grooves to prevent rotation were fixed in the impression with instant adhesive.

Fig. 22_ Preparation of the master model. The wax pins served as access to the stumps on the master model.

Fig. 23_ The precise periodontal and peri-implant soft-tissue situation was represented on the master model.

Fig. 24_ The marginal border of the planned implant crown was transferred to the plaster surface.

Fig. 25_ The peri-implant emergence profile was expanded and the papillae sharpened to provide a harmonious gingival profile.

Fig. 26_ Optimal hold of the wax-up during try-in through filled implant interface.

Fig. 27_ Overview of abutment options (from left: CONELOG Esthomic abutment (1.5–2.5 mm gingiva height) prior to and after customising, the CONELOG Titanium base CAD/CAM).

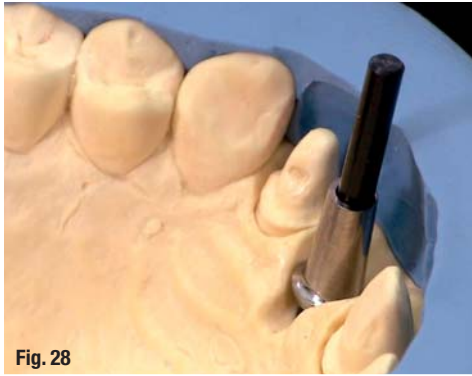

Fig. 28

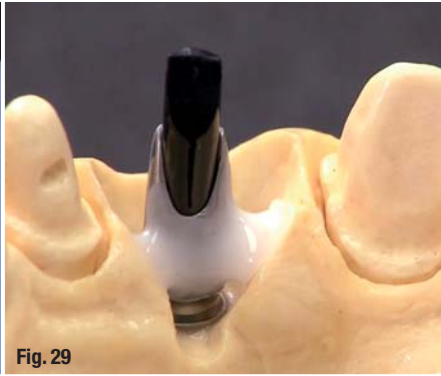

Fig. 29

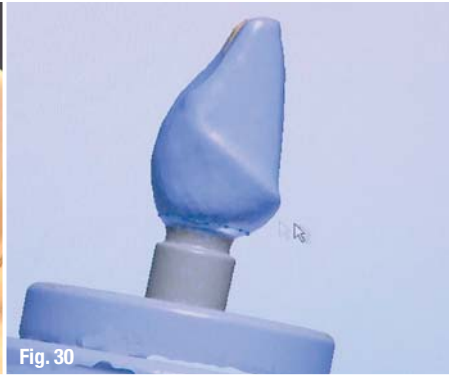


Fig. 30

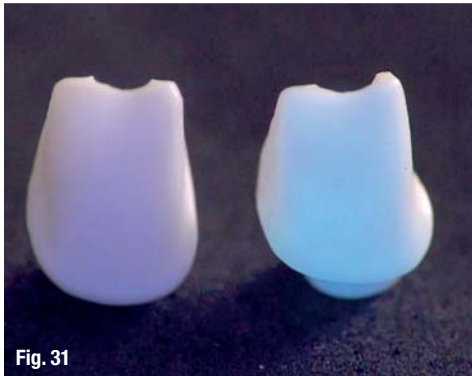

Fig. 31



Fig. 32

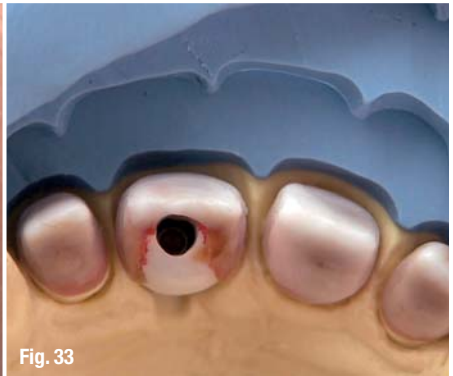

Fig. 33

Fig. 28_ The Esthomic abutment, extended with a bonding aid, shows the palatal positioning of the access channel.

Fig. 29_ Customising the primary abutment ensures sufficient coating strength of the zirconium oxide abutment.

Fig. 30_ The titanium base and the completed model of the secondary abutment were scanned in the laboratory. Buccal space was left for the planned pressed ceramic veneer.

Fig. 31_ The sintered abutment left without and right with fluorescent solution treatment.

Fig. 32_ Firing of a highly fluorescent, etchable zirconium oxide veneer ceramic. The shape of the abutment was optimised prior to modelling the press cap.

Fig. 33_ The layer thicknesses for veneering the pressed ceramic caps were checked with the aid of the vestibular, twice-divided silicone index.

again with piezo-surgery, a sharp lever and diamond pliers. This revealed that the thin buccal bone lamella was connected to the root (Fig. 5). The osseous margin of the alveolus was examined carefully with a periodontal probe (bone sounding).

Despite a lack of bone wall, an immediate implantation as planned was to be performed according to the protocol of the University Medical Center of the Johannes Gutenberg University of Mainz.⁸ With the aid of the guide prepared in the laboratory; the positions were marked prior to preparing the implant bed (Fig. 6). Pilot drilling and further drilling steps were performed by the surgeon without a guide and with drill extension for optimal cooling. Insertion of the implant (CONELOG, CAMLOG; 3.8 mm diameter, 13 mm length) was also performed without a guide (Fig. 7).

Correct 3-D orientation of the implant was checked with the final drill and using the drill guide. The buccal implant shoulder should be 3 mm apical of the marginal soft tissue and distinctly palatal to the dental arch (Figs. 8 & 9). This ensures that the subsequent implant-supported crown can be screwed in palatally. The gap between the implant and buccal soft tissue was filled with bone material. This was a mixture of autologous bone gained during preparation. Granular autologous bone harvested from the retromolar area and bovine bone augmentation material were used to prevent resorption (Figs. 10 & 11).

In order to obtain the best possible soft-tissue conditions in the sense of a thicker gingival type, the surgeon harvested a connective-tissue graft from the palate. Using the tunnel technique according to Azzi,⁹⁻¹¹ this was pulled between the bone granulate and the buccal soft tissue and fixed with a monofilament, non-absorbable suture material (Fig. 12). Then a CONELOG wide-body healing cap (4 mm height) was screwed in and the temporary bridge cemented (Fig. 13). This supported the soft tissue, but did not contact the healing cap, so that the lower section of the pontic could be cleaned with super floss. Figures 14 and 15 show the post-operative X-ray and the situation at the check-up one week after immediate implantation.

After three months of implant healing, the peri-implant and periodontal tissues were ready for final impression taking (Figs. 16 & 17). To this end, double 0 sutures soaked in glycerine were placed in the sulci and the preparation borders placed slightly subgingivally as part of final fine preparation. Then a thicker retraction cord, strength 0, soaked in epinephrine was placed (adrenaline; Fig. 18). The healing cap was unscrewed (Fig. 18) and a CONELOG impression post for open trays screwed in (Fig. 19). Impression taking was performed after drying and removal of the thick retraction cord (Fig. 19) in one step with an individual open tray and a two-phase polyvinyl siloxane (A-silicone). Following arbitrary transfer of the occlusal relations with a bite fork, facebow and bite registry, the healing caps and temporary bridge were reinserted. A tem-

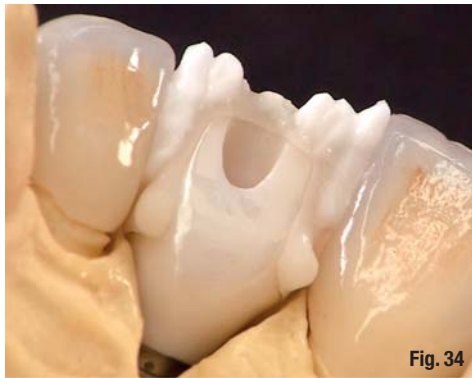

Fig. 34

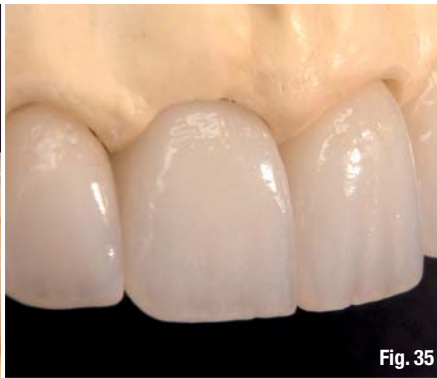

Fig. 35



Fig. 36



Fig. 37

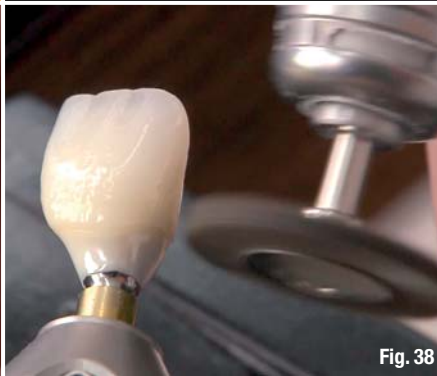

Fig. 38

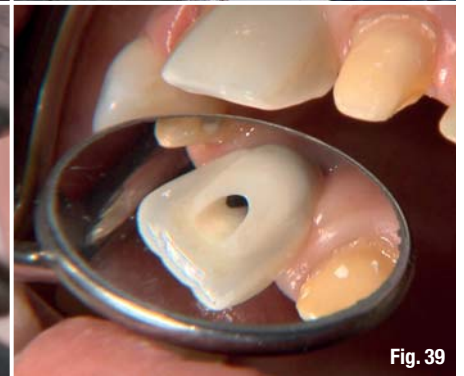

Fig. 39

porary crown was fabricated for tooth 22 (Fig. 20). The marginal gingiva in the region of the implant had to be moved slightly in an apical direction with the definitive restoration owing to the excess tissue.

Fabrication of abutments and final crowns

Using super-hard plaster, the dental technician fabricated root-shaped (conical) stumps to prevent rotation. These were placed in the impression to fabricate the master model and extended with wax pins (Figs. 21–23). A new wax-up was prepared based on the updated aesthetic analysis and the outer cervical contour of the implant restoration was transferred to the model (Fig. 24). The anatomical shape of the emergence profile was then created with a fine milling machine. The implant crown was thus given a natural emergence contour. The papillae were slightly sharpened and smoothed to give an optimal gingival contour. The optimised shape of the papillae avoided concavities occurring later in the cervical, slightly subgingival ceramic areas, which are difficult to clean and can lead to irritation of the gingiva (Fig. 25). The wax-up was fitted with a pin at the implant position, which engaged with the implant interface for better fixation of the wax-up during try-in (Fig. 26).

A suitable abutment was selected from the CONELOG Esthomic abutment set and the silicone indexes based on the wax-up. In this case, the

CONELOG Titanium base CAD/CAM was too low owing to the apical position of the implant shoulder. Therefore, the dental technician decided on a considerably longer, straight CONELOG Esthomic abutment, which was customised for use as a titanium bonding base (Figs. 27–29). He modelled a secondary abutment with wax on the customised titanium base (primary abutment), which was to be fabricated from zirconium oxide. Subsequent bonding with the titanium base resulted in a hybrid abutment with full anatomical contours, both in the palatally and subgingivally positioned emergence area through the soft tissue. Room was left on the buccally visible area for a pressed ceramic veneer to be fixed by bonding (Fig. 30). Using a double scan, the dental technician imported the 3-D shape of the primary abutment and the wax model of the secondary abutment into the planning software (Abutment Designer, 3Shape; Fig. 30).

Then the secondary abutment was ground from zirconium oxide ceramic with CAM technology and immersed unsintered into a fluorescent solution (Fig. 31). The screw channel was prepared prior to sintering. As zirconium oxide cannot be etched, the dental technician had to fire a thin layer of etchable, highly fluorescent zirconium oxide veneer ceramic on to the buccal surface and preparation margin of the hybrid abutment prior to modelling the cap for the pressed ceramic veneer (Fig. 32). Fluorescence ensures the transmission of light in the gingival area. This has a positive effect, particularly in the case of a thin gingiva. Then, the dental technician

Fig. 34 Modelling of the mamelon for the implant-supported veneer from a palatal view.

Fig. 35 After glaze firing and polishing, the natural anatomy and surface characteristics of the restoration were checked.

Fig. 36 Aesthetic try-in: The patient and her dental technician, Andreas Nolte, appreciating the highly successful outcome and nearly completed treatment.

Fig. 37 The pressed ceramic veneer was mounted on the previously bonded hybrid abutment by bonding with dual-curing composite.

Fig. 38 The transitions between the abutment and the veneer were smoothed and polished to a high gloss with a brush and polishing paste.

Fig. 39 The implant restoration is screw-retained. For biomechanical reasons, the screw access channel was placed in the zirconium oxide section.

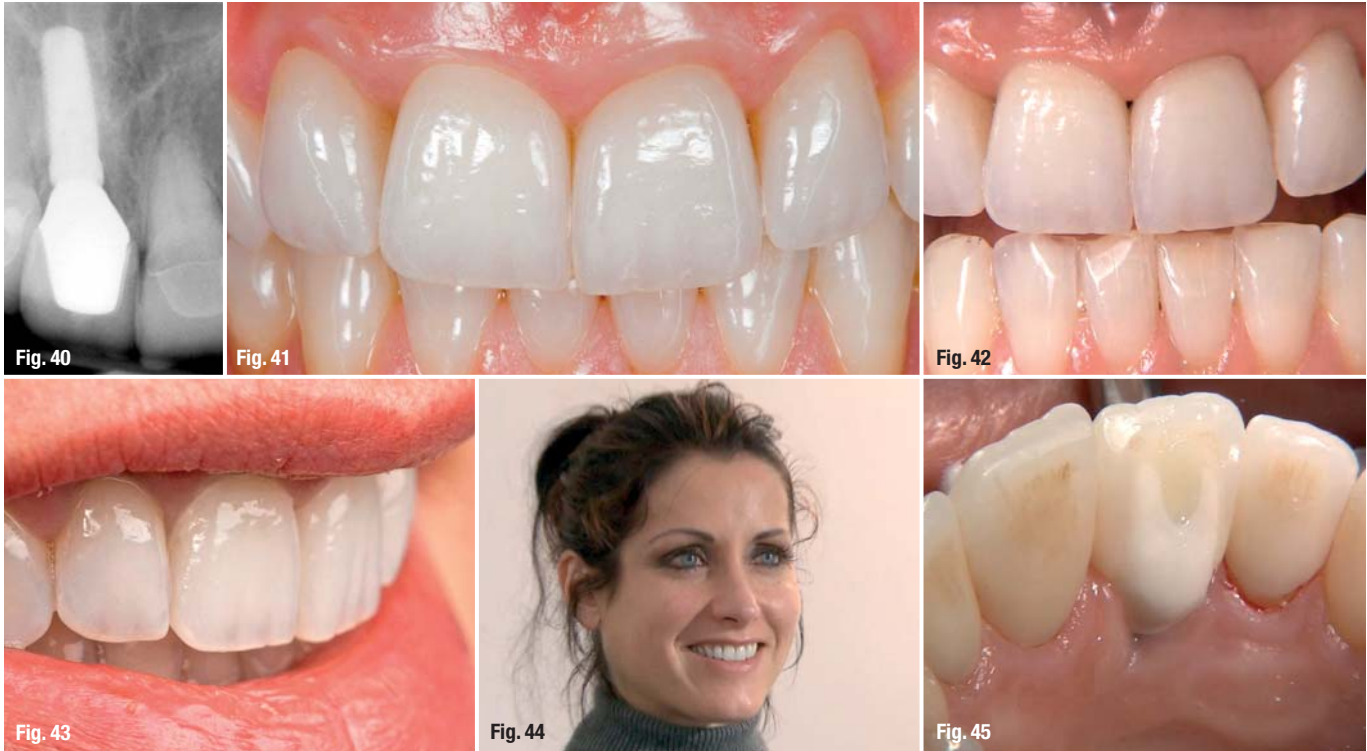

Fig. 40_ The palatally inserted crowns and the sealed screw access channel of the implant crown.

Fig. 41_ The X-ray check-up confirmed successful osseointegration and the natural emergence profile of the implant-supported restoration.

Fig. 42_ The crowns on teeth 12, 21 and 22 and the implant restoration in position 11 fitted harmoniously to the dental arch and the remaining teeth.

Fig. 43_ The close-up shows the healthy peri-implant soft tissue and the natural surface of the restorations.

Fig. 44_ The side profile also shows the natural contours of the restoration and the successful interplay between red and white.

Fig. 45_ The patient's relaxed smile confirmed that the effort and attention to detail were appreciated.

fabricated and veneered the pressed ceramic caps for the crowns and veneers (Figs. 33–35).

After a successful aesthetic try-in in the laboratory (Figs. 36 & 45), the individual parts were combined. First, the titanium base was sand-blasted and conditioned, then the secondary zirconium oxide abutment was conditioned. Both parts were bonded with special composite. Then the inner side of the veneer and the sintered zirconium oxide veneer ceramic of the hybrid abutment were etched with hydrofluoric acid, conditioned and bonded with dual-curing composite (Fig. 37). Then, the transition areas were smoothed and polished (Fig. 38).

_Insertion

The crowns were mounted by bonding and the implant-supported veneer crown was screw-retained (Figs. 39 & 40). This was followed by a careful check of the approximal contacts and function. The final X-ray confirmed successful osseointegration of the implant and harmonious emergence of the implant-supported restoration from the bone (Fig. 41). Figures 42 to 45 show the aesthetically successful outcome and a very satisfied patient.

_Discussion

The example demonstrates successful immediate implantation in the anterior maxilla of a female patient with a thin biotype and high smile line. In addition, the buccal bone lamella was missing, so

that the bone and soft tissue had to be augmented as part of immediate implantation—without preparing a flap. This demanding task can only succeed when the surgeon and if applicable the prosthodontist and the dental technician work together as an optimal team and use suitable methods and materials. In the case presented, surgery and prosthetics were performed by the same dentist, who had been working together intensively for many years with the dental technician in the same location. At the beginning of treatment, the patient presented to the laboratory for an aesthetic analysis to give the dental technician a detailed understanding of the situation.

In order to obtain adequate tissue volume in the implantation area, the surgeon employed proven bone and soft-tissue surgical procedures. These included using a bone mixture for augmentation and a tunnel technique for thickening the buccal soft tissue.^{10, 11} The literature shows that stable tissue volume and a constant marginal soft-tissue border can be achieved in this way^{5, 12} even in the case of an impaired implantation site with missing bone lamella.^{8, 13} This procedure is not (yet) recommended in the current consensus statements by the professional associations owing to difficult predictability of individual results.¹⁴

_Analogue and digital

A large part of the treatment and technical work steps were performed with conventional surgical

implants

international magazine of oral implantology

prosthetic and craft-dominated technical dental methods (analogue). Computer-supported planning was not employed, so that the surgeon was not guided but implanted freely in accordance with the surrounding structures. This requires a precise clinical and radiographic analysis of the initial situation, appropriate planning and a high degree of expertise. Impression taking also followed conventional techniques.

A speciality here is the use of a two-part hybrid abutment as the base for the pressed ceramic veneer. In order to obtain a biochemically optimal titanium bonding base, a straight CONELOG Esthomic abutment was customised in place of the alternative CAD/CAM component. The secondary zirconium oxide abutment was waxed up. Then, both components were scanned. This is where the CAD/CAM process came into play with the fine-tuning of the design on the screen and machine fabrication of the zirconium oxide secondary abutment. Despite using a titanium primary abutment, the dental technician achieved a natural light effect by the consequent use of fluorescing materials.

As all components of the implant-supported restoration were bonded in the laboratory, the dentist was able to screw them in place together as a single piece and in a single session. This meant fewer treatment sessions for the patient, who did not have to return to the practice after impression taking until final insertion. The aesthetic try-in before final bonding of the individual parts was performed in the laboratory. The procedure described is only possible in close co-operation and with full confidence between the team partners. _

Editorial note: A list of references is available from the publisher.

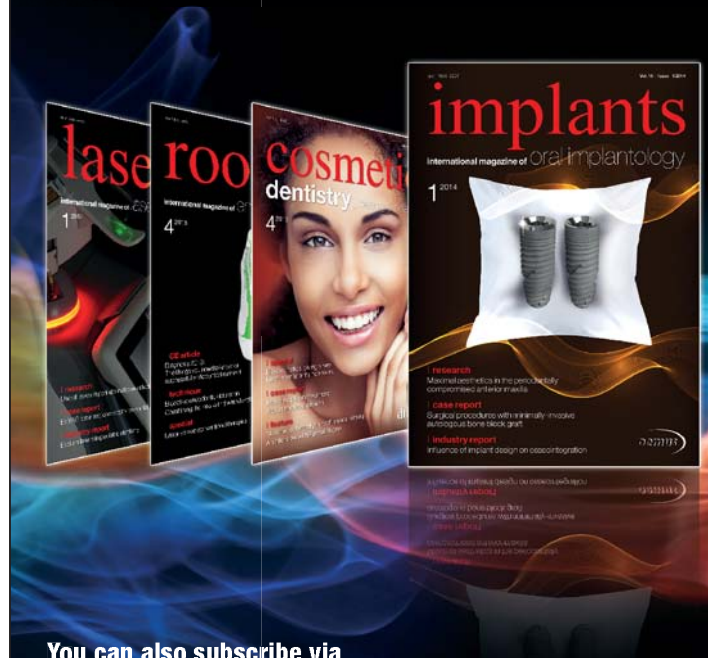_contact

implants


Joint practice Drs Happe

Schützenstraße 2
48143 Münster
Germany

info@dr-happe.de
www.dr-happe.de



You can also subscribe via
www.oemus.com/abo

 **Subscribe now! One issue free of charge!**

I hereby agree to receive a free trial subscription of **implants international magazine of oral implantology** (4 issues per year). I would like to subscribe to **implants** for € 44 including shipping and VAT for German customers, € 46 including shipping and VAT for customers outside of Germany, unless a written cancellation is sent within 14 days of the receipt of the trial subscription. The subscription will be renewed automatically every year until a written cancellation is sent to OEMUS MEDIA AG, Holbeinstr. 29, 04229 Leipzig, Germany, six weeks prior to the renewal date.

▶ Reply via Fax +49 341 48474-290 to OEMUS MEDIA AG or per E-mail to: grasse@oemus-media.de

Last Name

First Name

Company

Street

ZIP/City/County

E-Mail

Signature

Notice of revocation: I am able to revoke the subscription within 14 days after my order by sending a written cancellation to OEMUS MEDIA AG, Holbeinstr. 29, 04229 Leipzig, Germany.

Unterschrift

OEMUS MEDIA AG
Holbeinstr. 29, 04229 Leipzig
Tel.: +49 341 48474-0
Fax: +49 341 48474-290
E-Mail: grasse@oemus-media.de

Influence of **implant** design on **osseointegration**

Authors Dr R. Fromental, Dr S. Langonnet, S. Chesnay, Prof. J.C. Béra, Dr B. Lavandier, Dr A. Gleizal, Dr M. Paris, Dr R. Gourmet & Prof. M. Rivoire, France

Introduction

Nowadays, numerous studies attempt to show the importance of implant surface treatment¹ for accelerating the osseointegration process.² Surface finishing, notably roughness generation, has allowed to increase the ability of titanium to link directly to bone without any intermediary fibrous tissue.³ Thus, it seems that if the osteoblast response is obviously measured by histology, it does not inform on long-term implant success but only on the cell organisation of the peri-implant bone tissue and it provides no information on the architecture of this tissue.⁴ Only the study of newly-formed trabecular bone tissue around the implant can provide predictive results concerning implant durability. Trabecular tissue forms only 20 per cent of the skeletal mass but 80 per cent of the exchange surface between bone and marrow. This microstructure plays a mechanical role because it en-



Fig. 1



Fig. 2

ures that the external loads be correctly distributed in the bone volume. Due to its mechanical function, trabecular bone is a preferential site to study the spatial and geometrical properties of this bone tissue and the interaction between medical apparatus and bone tissue. The future of a dental implant after loading mainly depends on: trabecular organisation, intimacy of contact between metal structure and bone, surrounding bone volume, bone density.⁵ The aim of the present work was to characterise the periimplant bone organisation and to evaluate the influence of implant shape on osseointegration, using a porcine model. Implantations were carried out on growing piglets on maxilla and trabecula, because the experimental results published up to now mostly concern fixtures set on tibia or iliac of pork or dog (results so obtained concern mainly cortical bone and less trabecular bone).⁶

Material and method

28 implant fixtures (diameter 3.5 mm, length 7 mm) were set in the jawbones of eight pigs, 16 in the mandible and 12 in the maxilla. Two types of implant were used: implant B with a cylindrical body and implant D presenting a shrink under its neck as shown in Figs. 1 and 2. Histomorphometric analysis was carried out on samples taken 45 days after implantation. Samples were analysed with a resolution of 18 µ.

Animal experiments

Experiments were carried out on eight pigs of mean weight of 12.1 kg at day 0 and 32.3 kg when sacrificed. Initial denture is mixed, complete and healthy for each animal. The project was presented to the ethiccomity of Institute of Experimental Surgery (ICE) of Centre Léon Bérard (Lyon, France). Animal choice and care, and experimental procedure were approved by the committee.

- Fig. 1_ Implant tested – D.
- Fig. 2_ Reference implant – B.
- Fig. 3_ Drilling of implant wells.
- Fig. 4_ Positioning of the implants on the maxilla.
- Fig. 5_ Implants in place.
- Fig. 6_ Periimplant bone organisation.

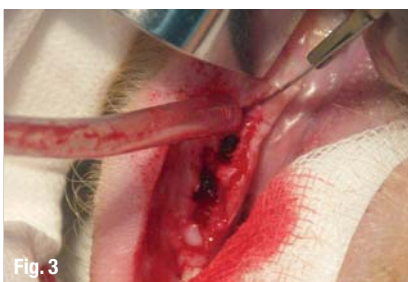

Fig. 3

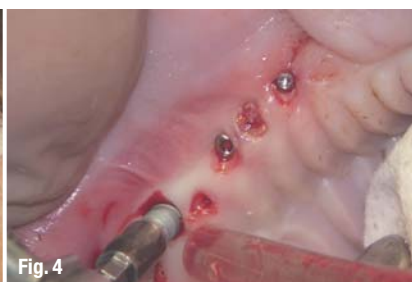

Fig. 4

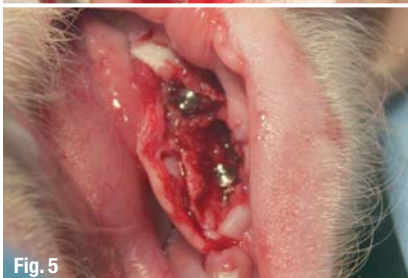

Fig. 5

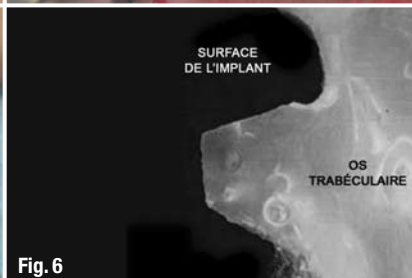

Fig. 6

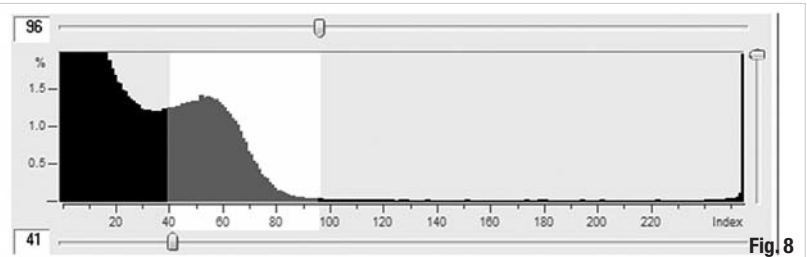



Fig. 8

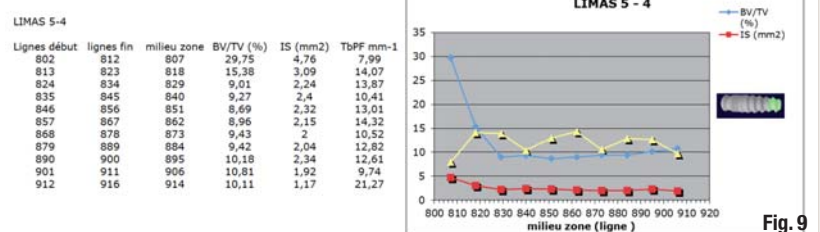


Fig. 9

_Operating protocol

The placement of the implants was achieved in the operating room under general anaesthesia. Animals received medication performed according to the following protocol: Intramuscular premedication injection: 3 à 5 ml/kg of Imalgène 1000 + 0.1 ml/kg of Stresnil + 1 ampoule of atropine; Intravenous induction of general anaesthesia: 0.003 ml/kg of the XKZ mixture (Xylazine, Kétamine, Zolazepam) for a duration of about 30 minutes. Mandibular implants were placed in the space between canine and first premolar, and maxillary implants were placed either distally of the lateral incisor or mesially of the first premolar.

_Surgery technique

It was the same as in human oral surgery: asepsis of the surgery field, crestal incision, localisation of the implant site, boring, threading, implant placement, suturing of gingival flap with interrupted sutures separated stitches. Referenced titanium implants were used (Figs. 1–5).

_Operating hazards

The main difficulty arose from insufficient height and thickness of the alveolar crest in the mandibular sites and to the relatively important size of the nasal cavities on maxillary sites, which imposes to use implants of low diameter and height. Some implants were lost due to a supracrestal or crestal positioning which did not resist animal tongue forces. An infectious event also occurred, resulting in the exclusion of one animal from the study.

_Sample collection

Samples were collected at day 45, after anaesthesia of the animal, following the protocol established

with the ethic committee. Bone was cut with a mechanical saw around the implant sites. Samples were immersed in formaldehyde and transferred to the imaging department for histomorphometric analysis.

_Histomorphometric analysis⁷

Analysis was conducted with CtAn™ software (SkyScan™) dedicated to scanner imaging. Bone histomorphometry consisted in the measurements of the parameters reflecting bone structure, microarchitecture and remodelling. The study of samples including bone and implant permits us to visualize the bone architecture around the implant from neck to apex, with the osseointegration phase being at its terminal stage.

Parameters considered for result analysis⁸

- BV/TV (%): ratio between bone volume and tissue volume; depending on the depth of the analysed volume, V represents cortical or trabecular bone.
- IS (mm²): surface of bone intersection with implant structure.
- TbPF (mm⁻¹): trabecular pattern factor, quantifying the interconnection of the bone (ratio between the numbers of concave and convex surfaces, quantifying the connections inside a 3-D structure).
- BS/TV (%): reflecting the density of the bone mesh.

Analysis methodology (Figs. 6–8)

A step-by-step analysis as a function of implant depth can be effected by a block of ten frames, each block corresponding to a slice of a thickness of 180 µm. Corresponding data were plotted as a function of depth, depth being defined as the centre of the slice. An example of results is shown in Fig. 9. A global analysis of data corresponding to the sum of all slices was done next. For this volume of interest

Fig. 7 3-D representation of bone surrounding the implant: the choice of low and high threshold values allows to eliminate metal and any soft tissue.

Fig. 8 Corresponding histogram: for this example the selected range (41–96) is taken into account as bone tissue.

Fig. 9 Illustration of the histomorphometric analysis method, data are plotted as a function of depth along implant.

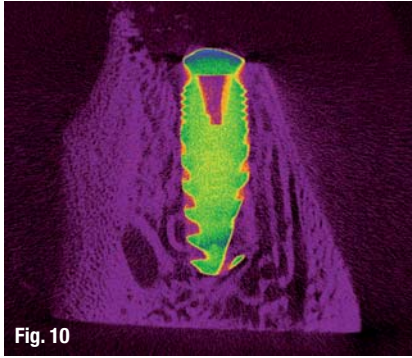


Fig. 10

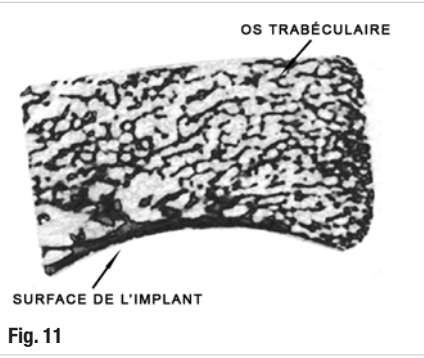


Fig. 11

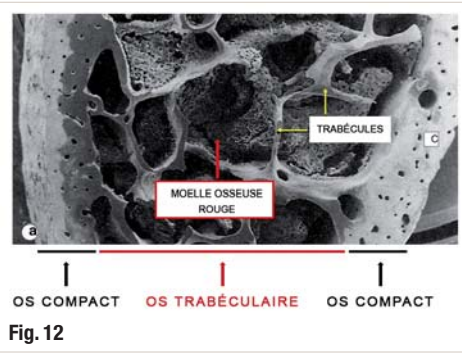


Fig. 12

Fig. 10_Front section view of the whole implant, showing the periimplant osseointegration.

Fig. 11_Transverse section view: contact between implant surface and trabecular bone.

Fig. 12_Histological section of trabecular bone.

one obtained: $BV/TV = 12\%$, $IS = 14\text{ mm}^2$, $BS/TV = 6.2\text{ mm}^{-1}$ and $TbPF = 1.13\text{ mm}^{-1}$.

Result analysis: relation between parameters¹⁰

At implant neck

The depth evolution of the ratio between trabecular bone volume and tissue volume is superimposable with the shape of the implant neck. IS is approximately constant, which corresponds to a satisfactory adhesion between the bone surface and the implant surface.

TbPF follows a curve symmetrical to the one of BV/TV: spongy trabecular bone is well organized and linked. BS/TV presents a mean value about 6, corresponding to an interesting bone density.

At implant apex

As shown in Fig. 9, the BV/TV curve follows the implant shrinkage jumping from 30 up to a plateau at about 10. TbPF varies from 8 about a screw turn hollow, follows the apex shape with a mean value of 13 and ends to 21. IS presents a plateau at 1.75.

Comparison between the two types of implants

Fig. 13 and 14 illustrate the comparison between two implants placed at the same position in the anterior maxillary sites.

At implant neck:

Implant B (cylindrical neck): BV/TV varies from 2 to 21, IS varies from 1.6 to 7.2, $TbPF$ varies from 20 to 30 and then up to 8.2 under the neck, BS/TV varies from 2 to 8.

Implant D (shrunk neck):

BV/TV varies from 10 to 15, IS varies from 3.7 to 3, $TbPF$ varies from 14 to 28 and then up to 2.9 under the neck, BS/TV varies from 5 to 11. It is noticeable that BV/TV and BS/TV are higher with the shrunk neck, while $TbPF$ is slightly better with a cylindrical neck.

At implant apex:

Implant B: BV/TV varies from 6 to 13, IS varies from 2.1 to 3.8, $TbPF$ varies from 12.7 to 14.3, BS/TV varies from 4 to 6.

Implant D: BV/TV varies from 7 to 21, IS varies from 1.6 to 3.3, $TbPF$ varies from 14.4 to 23, BS/TV varies from 4.1 to 4.4.

Fig. 13 Example of results at the neck and apex for implant B (control).

Fig. 14 Example of results at the neck and apex for implant D.

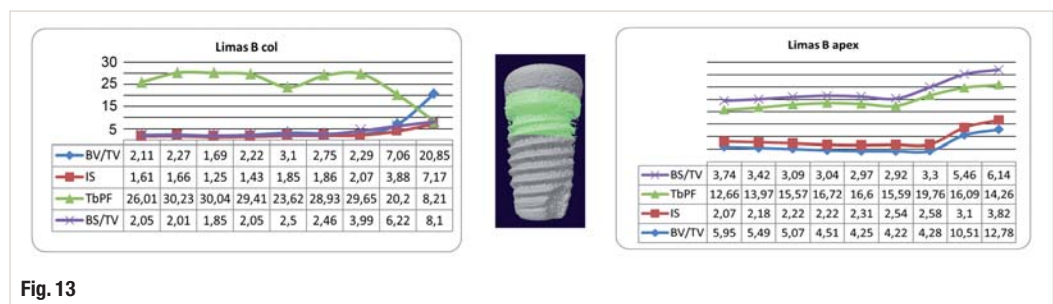


Fig. 13




Fig. 14

One observes that IS and BV/TV curves have the same pattern for implants B and D, but with lower values for B implant. Moreover, TbPF presents lower values for implant B, but TBPF does not decrease at the apex for implant B. For implant D, bone density is constant along the implant, the TbPF curve is superimposable with the BV/TV one, revealing a good trabecular architecture, IS is constant and BV/TV increases up to apex.

_Conclusions

Osseointegration is defined as a direct anatomic and functional junction between living bone and implant surface. Osseointegration is determined by several factors linked to the host and to the implant. On a biological point of view, osseointegration occurs in two phases: the first one consists in a mechanical stabilisation and anchorage in the prepared site; the second phase is characterised by the formation of a biological cohesion between implant surface and bone tissue.

The present study is an investigation on histomorphometric analysis of osseointegration. The preliminary results indicate that bone volume and bone den-

sity would recover better with a shrunk neck shaped as a Bone Launching Pad™ (implant D) than with a cylindrical neck. It is the same for the surface intersection between bone and implant, which appears to be larger, revealing denser bone around the implant. Concerning the body and apex of the implant, the more spaced turns of implant D would favour the bone density along the implant body and a higher and more uniform ratio between trabecular bone and tissue volumes. The trabecular architecture seems thus to be impacted by the shape of implant neck and apex.

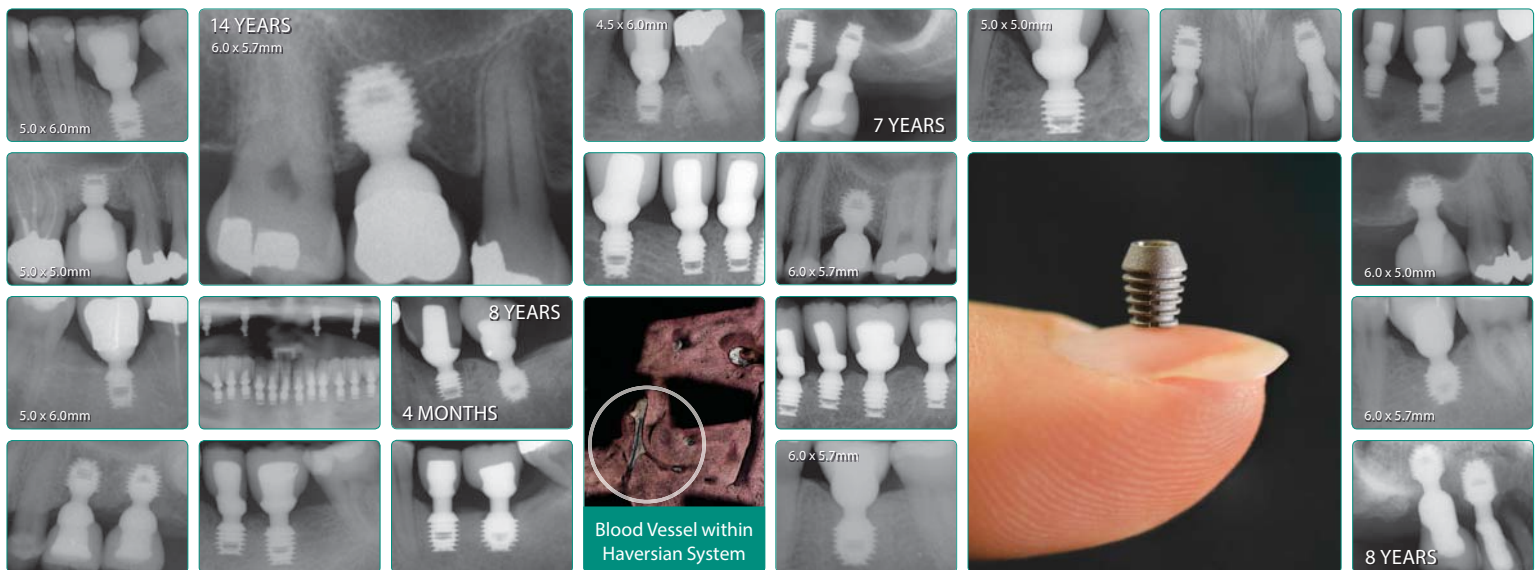
Editorial note: A list of references is available from the publisher.

_contact implants



Dr Robert Fromental
 14 place Jules Ferry
 69006 Lyon, France
 +33 4 72740025
 robert.fromental@yahoo.fr

AD



Manufacturer News

Straumann

More than an implant. A sense of trust.

In 2014 the Straumann® Dental Implant System offers more value for dental clinicians and patients. Our product range focuses on the groundbreaking Roxolid® material, which is specifically designed for the use in dental implantology. Outstanding biological and mechanical properties allow Roxolid® Implants to offer more treatment options than conventional titanium implants.

More treatment options with smaller implants: the reduced-diameter Roxolid® Implants with the hydrophilic SLActive® surface and higher strength revolutionized the market in 2009. At the EAO 2013 Straumann launched a new range of sizes of Roxolid® SL-



More than solid – Roxolid®.
Reducing invasiveness.

Active® Implants as well as a 4 mm Roxolid® SLActive® Implant. This Roxolid® SLActive® Short Implant is designed to avoid extensive bone augmentation procedures. Now, in 2014 for the first time, Roxolid® Implants are also available with the well-established SLA® surface. Roxolid®—setting new standards, reducing invasiveness: offering all implants with the Roxolid® material helps dental professionals to reduce the invasiveness of implant treatments by using smaller, shorter implants which are stronger than conventional titanium implants. Roxolid® helps to avoid patient trauma, pain and discomfort while saving time and money. Straumann® Roxolid® Implants are delivered with the new Loxim™ Transfer Piece, which is connected to the implant with a snap-in mounting and offers clinicians many benefits. Straumann – simply doing more.

Institut Straumann AG

Peter Merian-Weg 12
4052 Basel, Switzerland
www.straumann.com

LARADO

Implant test unit allows testing during production



Implant systems are normally tested according to the DIN EN ISO 14801 Norm before they are launched. LARADO presents an especially developed dental implant testing unit—DORA 14801—which guarantees the observance and consistency for product quality before and during production and also allows for immediate design modifications. The DIN EN ISO 14801 Norm concerns itself with the testing of dental implants regarding wear and failures caused by alternating stress or loads. The DORA 14801 provides a simple and

economic solution for testing with a maximum of efficiency regarding cost and time. In principle; it relates to the quality of implants which must be insured not only in the development phase, but also in later production by batch and ISO 14801-exams. Thus, a high level of security is obtained with respect to endurance, connection and structure of implants. The main factor of efficiency is obtained through one master control unit and is the basis for the connection of 1 to 8 individual test stations that provides independent, validated and documented test results. A variable sinus amplitude and dynamic-power of up to 800 N at a variable of 1–15 Hz, a low-space requirement for machine placement, the simple connection to a 110–230-volt power-outlet and the independence from compressed air or hydraulic systems are some of the advantages of the DORA 14801.

LARADO

Mainzer Str. 346
55411 Bingen am Rhein, Germany
www.14801.de

Nobel Biocare

Entering the regenerative field

Nobel Biocare launches its latest innovation, creos xeno.protect, beginning in the European markets. This new collagen membrane will be part of a larger regenerative product line under the brand name “creos”. Additional products will follow this year. “The introduction of creos xeno.protect emphasises Nobel Biocare’s long-standing commitment to improving quality of life through innovation. It is a product that harnesses the ingenuity of nature to the benefit of the patient, while at the same time making life easier for the clinician,” said Nobel Biocare CEO, Richard Laube.

Clinical studies and early results from clinicians after an extensive prelaunch period confirm it possesses optimal handling qualities, maintains its size when hydrated and is very tear-resistant.¹ The optimal fit can be found without extensive trimming which limits waste and minimizes costs for both clinicians and pa-



tients. The creos xeno.protect membrane has an extended barrier function that does not compromise on the established high industry standards for biocompatibility or vascularization behavior. As it is produced without any chemical crosslinking, creos xeno.protect offers high tissue compatibility for fast and predictable healing.

¹ Clinical studies, product information and first-user feedback are available at creos.com/xeno-protect.

Nobel Biocare

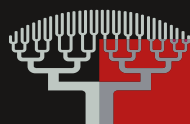
PO Box
8058 Zurich Airport, Switzerland
www.nobelbiocare.com

ORAL IMPLANTOLOGY WORLD CONGRESS

PARIS, July 2nd 2014

Maison de la Chimie
28, rue Saint-Dominique - 75007 Paris

wfld@clq-group.com



UNIVERSITÉ
PARIS DESCARTES

www.oiwc-paris2014.com

CAMLOG

Register now for the 5th International CAMLOG Congress in Valencia

From 26 to 28 June 2014, the 5th International CAMLOG Congress will be held in Valencia under the motto "The Ever Evolving World of Implant Dentistry". Renowned experts from Europe, Asia and America will be presenting current results from their research and clinical experience. In eight workshops, experienced specialists will convey the latest technologies and treatment methods. Several hundred dentists and dental surgeons have already registered.

Since the first congress in 2006 and the founding of the CAMLOG Foundation, the international CAMLOG Congresses have established themselves as the most important communications and



further education event in implant dentistry. Top-level speakers, practice-oriented workshops and an attractive location for the event highlight the 5th CAMLOG Congress: the international elite of dental surgeons and dental implantologists makes the spectacular Palau de les Arts in Valencia its

meeting place. The established scientific committee of the CAMLOG Foundation, chaired by Prof. Mariano Sanz and Prof. Fernando Guerra, is responsible for the program.

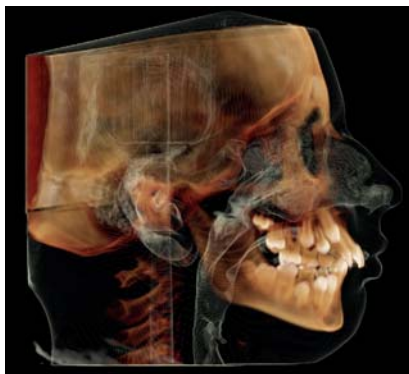The surgical and prosthetic concepts and treatment guidelines, which are presented in two sessions, are based on the CAMLOG Foundation Consensus, which was prepared over several meetings by experts from up to 18 countries.

CAMLOG Foundation

Margarethenstrasse 38,
4053 Basel, Switzerland
www.camlogfoundation.org

Planmeca

**Less is more:
Planmeca has the Ultra-Low Dose Mode**



Planmeca, the Finnish dental equipment manufacturers, have developed the Ultra-Low Dose Mode.

The lowest effective radiation level to which a patient is exposed is just 14.4 µSv for a 3-D image of the entire skull. All Planmeca ProMax 3-D units enable CBCT imaging with a lower radiation dose than conventional 2-D panorama X-ray technology.

The cutting-edge Ultra-Low Dose protocol is based on Planmeca's own intelligent 3-D algorithm, providing detailed anatomic information despite the minimal radiation level.

"We measure the radiation dosage of the ProMax units according to the effective dose measurement protocol described by Ludlow et al.¹ The ef-

fective dose is calculated in accordance with the revised guidelines issued by the International Commission on Radiological Protection (ICRP 103)²", explains Juha Koivisto, a physicist employed in Planmeca's Research & Development department.

The Ultra-Low Dose Mode is of invaluable assistance in pre-operative planning, monitoring the treatment and locating impacted or displaced teeth. In addition to facilitating the definition of facial asymmetry and cephalometric reference points, it even supports informative sinus imaging or the measuring of the respiratory tract in diagnostics.

All Planmeca ProMax X-ray units provide a wide range of pre-programmed, easily adjustable imaging modalities for all volume sizes while effectively eliminating interference and artefacts like shadows and flickering lines from the CBCT images.²

¹Ludlow JB, Brooks SL, Davies-Ludlow LE, Howerton B. Dosimetry of 3 CBCT units for oral and maxillofacial radiology. *Dentomaxillofac Radiol* 2006; 35:219-26.

²International Commission on Radiological Protection (ICRP). Recommendations of the ICRP. *ICRP Publication 103. Ann ICRP* 2008; 37:2-4.

Planmeca Vertriebs GmbH

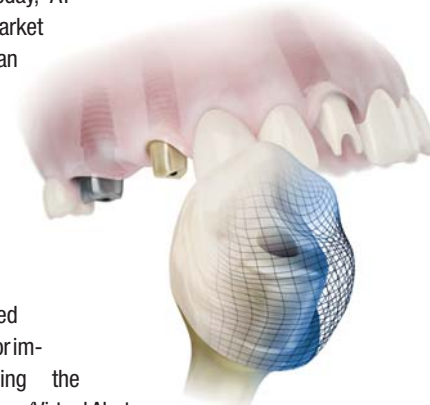
Walther-Rathenau-Str. 59
33602 Bielefeld, Germany
www.planmeca.com

DENTSPLY Implants

**Patient-specific
implant treatment**

DENTSPLY Implants designs and produces patient-specific abutments and implant suprastructures. These original CAD/CAM restorations are compatible with all major implant systems while offering perfect fit to each patient's oral anatomy. Quality, price as well as prompt delivery save time and resources. Dr. James G. Hannoosh, who was involved in the development of the ATLANTIS™ abutment concept from day one, is convinced of the systems advantages: "The patient-specific implant prostheses offer a high economic benefit whilst at the same time achieving a very high level of patient satisfaction, both reasons why today, ATLANTIS™ acts as market leader with more than one million abutments sold."

ATLANTIS™ abutments are available for both cement-retained and single-tooth screw-retained restorations for all major implant systems. Using the patented VAD™ software (Virtual Abutment Design), the patient-specific CAD/CAM-abutment is designed based on the final tooth shape.



DENTSPLY Implants

Steinzeugstraße 50
68229 Mannheim, Germany
www.dentsplyimplants.com

German Association of Dental Implantology

(Deutsche Gesellschaft für zahnärztliche Implantologie e.V., DGZI)

Founded in 1970



Central Office &
Secretary of the Board

Please send your membership application to:

DGZI e.V.

Paulusstr. 1
40237 Düsseldorf

DGZI e.V.
Paulusstr. 1
40237 Düsseldorf
Germany

Phone: +49 211 16970-77
FAX: +49 211 16970-66

GERMANY

office@dgzi-info.de
www.dgzi.de

MEMBERSHIP APPLICATION FORM

Please complete this application form in block letters.

PERSONAL DATA

NAME	FIRST NAME
TITLE	CITIZENSHIP
DATE OF BIRTH	
STREET	CITY, ZIP CODE
COUNTRY	
PHONE, COUNTRY AND AREA CODE	FAX
E-MAIL	Homepage
SPECIAL QUALIFICATION	
SPOKEN LANGUAGES	

Do you have experience in implantology?

Yes No

MEMBERSHIP FEE

I wish to apply for membership of the DGZI.

- Full membership (outside Germany) – 125 Euro p.a.
- Students/auxiliaries (outside Germany) – 60 Euro p.a.
- I have transferred the annual fee to the DGZI bank account c/o Dr Rolf Vollmer:
IBAN: DE33 5735 1030 0050 0304 36 | KSK Altenkirchen |
SWIFT/BIC: MALADE51AKI

AGREEMENTS

I hereby agree to have my personal data processed and published for all purposes of the DGZI.

SIGNATURE

PLACE, DATE

PAYMENT

By credit card:

Please use your: (Please mark as appropriate)

Visa MasterCard

Card holder's name _____

Card number | | | | | | | | | | | | | | | | | | | | | |

Expiry date ____ / ____

The time has come

Interview by Jürgen Isbaner

By the end of last year, BEGO Implant Systems GmbH & Co. KG introduced their long-awaited new implant system. With regard to the—especially in Germany—highly competitive implant market, where numerous providers of implantological products compete with each other for the same target group, innovations are of particular importance. Our editors interviewed Dr Nina Chuchracky, head of product marketing BEGO Implant Systems, and Mr Walter Esinger, CEO of BEGO Implant System. Among others, they talked about current trends in implantology and the latest implant systems.



Fig. 1

Fig. 1 Jürgen Isbaner, Chief Editor ZWP Zahnarzt Wirtschaft Praxis, the leading German dental magazine, in a conversation with Dr Nina Chuchracky, Product Marketing Manager BEGO Implant Systems, and Walter Esinger, CEO BEGO Implant Systems.

Dr Chuchracky, Mr Esinger, how do you assess the potential of the German implantology market with respect to your company's strategic orientation?

Dr Chuchracky: In advance to our development project, we have observed and assessed some trends, which have established themselves on the global implantology market in recent years. According to our observations, between 40 and 70 per cent of the users prefer tapered, self-tapping implants. Our products were only partially suited to accommodate these customer demands. Those products, which were introduced at the DGI Congress, fully correspond to the market development, helping us to gain access to a new range of customers with whom we will meet our high growth expectations.

BEGO has been "expecting" the new addition to their product portfolio for nine months. This unprecedented advertising campaign has caused a stir. Are the proud parents happy with the result?

Mr Esinger: Yes, we are very pleased with the result. Our expectations have even

been exceeded. We had made the conscious decision to "abandon" our well-known corporate design especially for this campaign in order to enhance both print and online media attention by the special colouring.

Of course we are eager to learn the name of your "offspring".

Mr Esinger: They are twins. Our new implant systems are named BEGO Semados®RS and RSX.

What is special about this "offspring" in comparison to its older "siblings"?

Mr Esinger: The twins are entirely new developments. However, we have made sure not to abandon the positive properties of our well-known BEGO Semados®S and RI implants. The new implants therefore have the same surface as S and RI implants, the TiPure^{plus} surface. The tapered connection has remained unchanged as well. Therefore, all known prosthetic components are compatible with each other. New additions are the bionic design of the thread and especially the micro threads at the implant neck (patent pending).

Dr Chuchracky: In addition to a version with a machined implant shoulder, there will be another version with a fully structured neck. This way, users can choose according to patient-specific demands and their own preferences. Both of the two systems also feature an integrated platform switch. The cutting flutes have been designed to create an optimum length of the bone graft. Bone grafts are transported crestally via the cutting flutes, thus ensuring an especially high primary stability, which contributes to a fast osseointegration after implantation.



Fig. 2

What is the target group of the new system?

Mr Esinger: We address users who want to implant fast, with only a few drilling steps, and achieve a predictable and secure treatment result. To be more precise, these are users who are looking for a cost-efficient alternative to available premium providers without having to make compromises in quality. We also address the large number of international users who have been missing a self-tapping, tapered implant with platform switch in the BEGO implant system.

With the new system, you promise implantologists fast and easy handling. How do you achieve this?

Dr Chuchracky: The surgical protocol was completely redeveloped and is accompanied by high-performance drilling tools. With the help of the previously-described thread geometry and the especially effective processing of the drill channel, a two- or three-step strategy is sufficient in more than 90 per cent of the cases. In addition, the tapered design of the implant reduces the implantation effort significantly.

What is the significance of micro threads in the implant neck of the new system?

Dr Chuchracky: The micro threads in the implant neck have been designed bionically in order to reduce the application of force in the crestal bone significantly by the geometry of the threads. This effect was illustrated in the simulation by Prof. Dr-Ing M. Flach's team at the University of Koblenz, Germany. This design, which has been registered for patent approval, will reduce bone resorption caused by an application of high forces.

Mr Esinger: At the moment, the University of Koblenz and other selected European universities are conducting further investigations in this field. We will keep you updated! All previous investigations have been showing that we are on the right track.

With an implant diameter of 3.0 mm up to 5.5 mm and a length of 7 to 15 mm, you cover a relatively broad spectrum. What is the idea behind?

Mr Esinger: That's right. At BEGO Implant System, we see our task in providing users with products which can be expected by a company perceiving itself as a system provider. Therefore, we value having a "real" 3.0 mm implant among our products by mid-2014, which is applicable in borderline indications such as narrow gaps.

Dr Chuchracky: Another borderline indication is covered by the short 7 mm implants. These implants are applied when the vertical bone dimension is limited and extensive augmentations must be avoided. The availability of shorter and thicker (< 6 mm) implants is demanded by only a few customers. There-

fore, 7 mm implants are seen as an adequate and predictable solution, completing our system.

Some will prophesy that this is more like taking the bull by the horns than a deliberate decision. How do you respond to these critics?

Mr Esinger: Markets change constantly. It is our task to observe those changes and to assess its implications for the future strategy of BEGO Implant Systems. To be honest, we don't have any objections to our users thinking we "take the bull by the horns". We actually like it. Seriously, we neither have the re-



Fig. 3a



Fig. 3b

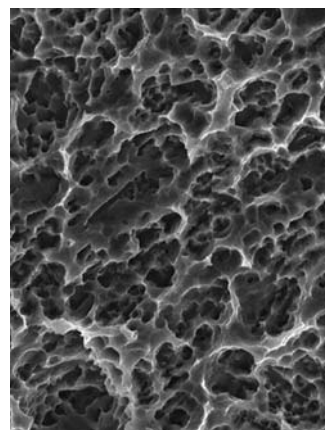


Fig. 4



Fig. 5

sources nor are we willing to undertake or finance any ill-considered steps. You know that developing an implant system is only the beginning. We operate internationally and have to cover the high costs for worldwide certifications and research.

Will you keep us updated on the developments of your „offspring“?

Mr Esinger: Of course we will.

What can we expect from BEGO in the upcoming months?

Mr Esinger: You will be surprised! We continue to work on many innovative products which will enhance the implant market in 2014.

Thank you for this interview.

_contact

implants

BEGO Implant Systems GmbH & Co. KG

Technologiepark Universität,
Wilhelm-Herbst-Straße 1
28359 Bremen, Germany

Tel.: +49 421 2028-246

info@bego-implantology.com
www.bego-implantology.com

Figs. 3a and b The new BEGO Semados® RS und RSX implant lines with micro thread structure at the implant neck.

Fig. 4 High-purity, homogenous, blasted and etched TiPure^{plus} surface; the same surface as in the S and RI implants.

Fig. 5 The tried and tested internal tapered connection with its 45° medium taper angle, internal hex anti-rotation protection and platform switching.

Short implants

An interview with Prof. Dr Christoph Hämmerle, Switzerland

Source_Institut Straumann AG



Prof. Dr Hämmerle

Looking at the recent publications in implant dentistry, we see an increased interest in short implants. What can be considered a short implant and what do you think is driving the professional interest in these implants?

There are different definitions for short implants. The EAO consensus conference defined them as 8 mm and less. The key interest is that with short implants you can provide less invasive treatments. Furthermore, short implants can lead to fewer complications and less morbidity. They decrease the costs, can deliver more predictable outcomes and are also easier to perform in many cases. With short implants sometimes you need less complex diagnostics and you run fewer risks. All these factors make short implants an attractive option, often providing a completely different strategy for implant placement.

You mentioned many cases where short implants make a difference. What do you see as indications that can be treated with a short implant?

Short implants would primarily be used in the posterior segment of the jaw, as in the anterior segment there is generally a sufficient bone height for a regular implant. In addition, in atrophic mandible and maxillary, where the vertical space is limited, short implants are also very valuable.

The latest improvements in implant materials and surfaces promise higher osseointegration and mechanical stability of implants. Do you believe

these properties can compensate for the smaller implant dimensions?

Yes, absolutely, this has clearly been demonstrated—medium-rough surfaces provide a better anchorage in the surrounding bone compared to smoother type of surfaces. This property is the key that makes shorter implants possible. Previous studies have shown that short implants with 10 mm or less had a lower rate of osseointegration and lower clinical success, but we don't see the same in implants with medium-rough surfaces.

I think advances in implant surface technologies offer the kind of anchorage that implants with more traditional surfaces could not achieve in the past. Hence, short implants can deliver a good anchorage nowadays in situations with limited bone height.

What kind of indications do you see as a challenge for this implant? Could a short implant be a good alternative to avoid vertical augmentation?

Most publications describe the use of the short implants primarily in the posterior region. Short implants are valuable in the maxilla to avoid sinus lift augmentation, while in the mandible they help to avoid vertical ridge augmentation.

A challenging indication could be a patient requiring a short implant because of a reduced bone height, but still needing an additional augmentation procedure due to the insufficient bone width.

Alternatively, in the sinus area, in cases of soft bone, it would be difficult to get a good anchorage with a short implant. The healing time needs to be increased and implant loading delayed to ensure an undisturbed osseointegration process.

Thank you Prof. Hämmerle, do you have any additional comment about short implants?

As implant technology progresses, I expect to see more innovative solutions which provide less invasive, less costly and more straightforward types of treatments. I believe such progress is in the interest of the dentist, the patient and the industry.



**ACADEMY OF
PROSTHODONTICS**

International Congress 2014

May 16/17, 2014
Congress Center Kursaal
Bern, Switzerland

IN COLLABORATION WITH
SWISS SOCIETY FOR
RECONSTRUCTIVE DENTISTRY



SSRD

WELCOME TO BERN

Dear Colleagues and Friends,

It is my great pleasure to invite you to the International Congress of the Academy of Prosthodontics 2014, which will be held in Co-Sponsorship with the Swiss Society for Reconstructive Dentistry. This exciting professional meeting, the first of its kind, will take place on May 16–17, 2014 at the Congress Center Kursaal in the beautiful City of Bern, Switzerland. It will feature a world-class scientific program with expert panelists from both sides of the Atlantic.

I want to thank the Board of the Swiss Society of Reconstructive Dentistry for its willingness to partner, and the Center for Continuing Dental Education of the University of Bern for its great assistance with meeting organization and logistics.

I'm looking forward to seeing all of you next May in Bern!

Sincerely,

Hans-Peter Weber, President,
The Academy of Prosthodontics



SPEAKERS AND MODERATORS

Urs Belser, SUI	Carlo Marinello, SUI
Urs Braegger, SUI	Konrad Meyenberg, SUI
Larry Brecht, USA	Dean Morton, USA
Daniel Buser, SUI	Carlo Poggio, ITA
German Gallucci, USA	Harold Preiskel, GBR
Charles Goodacre, USA	Anton Sculean, SUI
David Gratton, USA	John Sorensen, USA
Christoph Hämmerle, SUI	Clark Stanford, USA
Ronald Jung, SUI	Joerg Strub, GER
Robert Kelly, USA	Hans-Peter Weber, USA
Kenneth Malament, USA	Nicola Zitzmann, SUI

FRIDAY, MAY 16

08:40 – 12:45	SESSION 1
14:00 – 17:45	SESSION 2
18:00	SSRD Cocktail Reception

SATURDAY, MAY 17

09:05 – 11:05	SESSION 3
12:30 – 14:30	SESSION 4

More Information:

www.ccde.ch

International implantology in Berlin

Japanese lecturers at the **DGZI Annual Congress 2013**



International speakers impressed the audience with their scientific knowledge on the international podium on the first day of the congress, among them Dr Keiichi Naruse, Dr Shohei Ikeda and Yoshishige Taniguchi from Japan. The following excerpts provide a summary of their enlightening speeches.



Three types of mandibular bone resorption and their respective bone augmentation techniques for successful dental implant treatments

Dr Keiichi Naruse

With reference to older and the latest research, particularly Naruse et al., I share my opinions and experience on bone augmentation techniques according to the condition of the bone or degree of bone resorption.

Bone augmentation in patients with resorbed mandibular ridges due to severe periodontal disease requires the use of advanced techniques. Mandibular bone resorption and the respective bone augmentation techniques are divided into three types based on the condition of severely and vertically resorbed mandibular ridges. One bone augmentation technique entails using non-autogenous bone. I agree with other researchers that autogenous bone, owing to its osteogenic, osteoinductive and osteoconductive abilities, is preferred as a bone replacement material in bone augmentation. However, I am also aware

that this invasive technique may cause subsequent infection in the donor site. Therefore, in order to perform minimally invasive surgery, I performed 15 mm bone augmentation without using autogenous bone and the case was successful.

Reference

K. Naruse et al., "Advanced alveolar bone resorption treated with implants, guided bone regeneration, and synthetic grafting", *Implant Dentistry*, 19/6 (2010): 460-7.



Effect of metal artefacts on the visualization of peri-implant anatomy in cone-beam computed and volumetric tomography images

Dr Shohei Ikeda

The objective of this study was to assess the effect of metal artefacts on the confidence levels of observers in the analysis of cross-sectional peri-implant anatomy in the buccolingual plane using CBCT and volumetric tomography (VT).

The VT machine used was OP200 D (Instrumentarium Dental) and the CBCT machine was 3DX (Morita). ITI implants (Straumann; Ø 3.8 mm, L 15 mm) were used. A 2:1 mixture of plaster of Paris and sawdust was used to simulate the bone block. Metallic posts (Ø 2 mm, L 2.5 mm) were used to simulate the

metal objects to generate the artefacts on the image. The implant was placed in between two metallic posts of similar diameter in the same line separated by equal distances in the simulated bone block. Fourteen different combinations were prepared using two posts to simulate the possible locations of such posts in vivo. Thus, prepared blocks were then used to record the images using both modalities by adjusting the exposure parameters to the density of the simulation device. The images obtained were analysed by five oral radiologists and their confidence levels regarding their assessment of the images were recorded for both modalities. The observers were asked to score the images in the central regions of the implants. A visual grading characteristics analysis was carried out to assess the relative confidence levels of observer responses for both modalities to determine their statistical significance. The assessment of peri-implant anatomy using CBCT was significantly better in the central region of the implant in comparison to VT, whereas in the periphery of the implant region both modalities performed similarly.



A recovery case with maxillary sinusitis and inferior alveolar nerve paralysis

Yoshishige Taniguchi

This case report presents a four-year follow-up of an implant recovery case caused by inappropriate implant therapy owing to insufficient examination and diagnosis, which was resolved by the removal and replacement of the implants with new implants.

Case description

A 62-year-old male patient complaining of implant movement and discomfort while eating first visited our clinic in March 2007. He had maxillary sinusitis on both sides and implants in positions 15–17, 25–27 and 45 with severe peri-implantitis. The screw was loosening in implant 17 and the implant fixture in position 25 was fractured. Other complications were that patient had inferior alveolar nerve paralysis on the right side of the mandible and fluid leaking from the nasal passage after drinking. The patient had always felt extremely dissatisfied with his dental treatment. He desired retreatment with new implants. Our clinical examination of both maxillary sinuses found that they were packed with non-absorbable bone substitute from the implant site; this was the cause of the sinus infection. The patient underwent radical maxillary sinus surgery, and all the implants and a loose tooth were extracted at a university hospital. After nine months (January 2008), new implants (NobelSpeedy Groovy; Nobel

Biocare) were placed in positions 47, 44, 42 and 32 in our clinic. An implant with a 15 degree tilt was placed in position 44. At same time, absorbable bone substitute was used to avoid the mental foramen and owing to the severely atrophic alveolar ridge. In October 2009, new implants (NobelSpeedy Groovy) were inserted into the maxillary alveolar bone in accordance with the All-on-4 concept. A provisional prosthesis was then made from acrylic resin and seated on the same day.

Results and discussion

The final prostheses were fabricated six months from the day of surgery. The patient's complaints have been resolved and the final prostheses for both jaws are stable. Applying the All-on-4 concept in the maxillae and implant tilting in the mandible are the best methods available for implant recovery cases for patients for whom sinus augmentation is impossible and who have a severely atrophic alveolar ridge around the molars in the mandible.



More than 500 attend ISOI annual meeting in Tokyo

Author_Dr Rolf Vollmer, Germany



International Society of Oral Implantology (ISOI) President Dr Naotaka Sugiyama, Vice-President Dr Yamawaki, Conference President Dr Tomohiro Ezaki, and Prof. Shoji Hayashi from the Kanagawa Dental College in Yokohama hosted a superb conference in Tokyo in Japan on 16 and 17 November 2013. In his opening speech, Sugiyama highlighted the importance of collaboration with the German Association of Dental Implantology (DGZI) and of scientific exchange between the two partner associations for the Japanese members, who hold German dentistry standards in high regard, especially in the field of oral implantology. The ISOI, which has more than 1,000 members, established the DGZI Japan Section in 2007.

Before presentations started on the first morning of the meeting, Sugiyama reviewed the association's activities and relevant information over the last year, among this was the participation of ISOI board members in the October 2013 DGZI congress in Berlin in Germany. The ISOI and DGZI reaffirmed their partnership for the exchange of scientific and technical information in dental implantology today and in the future. Sugiyama gave a warm welcome to the DGZI's newly elected president, Prof. Heiner Weber, Medical

Director and head of the Department of Prosthodontics at the University of Tübingen, and expressed his hope for further close co-operation.

The ISOI President announced the DGZI 2014 congress to be held in Düsseldorf in Germany on 26 and 27 September 2014. He stated that he was looking forward to many of the ISOI's friends and colleagues taking part. He stated that if enough colleagues from Japan attended it would be possible to offer simultaneous interpreting into Japanese for the presentations. In addition, he encouraged ISOI members with an authority in implantology certificate or a clinical certificate from the ISOI to become an expert or specialist in implantology through the DGZI. Before the congress began, the German guests had the opportunity to witness the high standards of the written and oral examinations for the authority and clinical certificates.

The main congress topics were the opportunities and risks of aesthetic, surgical and prosthetic implantology, as well as the use of dental CT or CBCT, anaesthesiology and otorhinolaryngology. Lectures for hygienists and dental technicians were held in parallel.

The Japanese speakers discussed both their most successful and failed clinical cases.

The DGZI was represented at the ISOI annual meeting by Weber, DGZI Vice-President Dr Rolf Vollmer, board member Dr Rainer Valentin and Dr Mazen Tamimi from the DGZI International Section in Jordan. Weber lectured on the minimisation of the impact of an implant restorative treatment on the patient using various patient cases. He stated that all kinds of dental therapies will potentially have an impact on our patients. The extent of this impact will depend on various factors, such as the professional positions of the patients; their physical, mental, and medical condition (this could affect compliance for example); and the complexity of the surgical and/or the restorative treatment. Parameters include the total length of the surgical and restorative treatment time, the number of appointments and the visibility of the treatment steps within the patient's environment. The discomfort and pain caused by all of this will also have a bearing on the impact. Based on his more than thirty years' clinical implant and restorative experience, he gave practical advice regarding how to perform, modify and combine different treatment steps, including medication, surgery and temporisation. The clinical conclusions and the take-home message captivated the audience.

The second German speaker, Dr Martina Vollmer (oral surgeon), gave a presentation titled "The SAC classification—From simplicity to complicated implant cases". She stated "We are seeing more and more misadventures dealing with complex implant cases. The vast majority of these issues relate to a failure in the initial diagnosis. Diagnosis and decision-making are always the most difficult things to teach and convey. Although implant dentistry is now an integral part of many dental practices, most dentists receive, if at all, their education in implant dentistry after graduation, with little emphasis on the identification of the complexity and risks of treatment."

Dr Martina Vollmer explained that SAC stands for Straightforward, Advanced, and Complex, and was first described by Sailer and Pajarola in 1999 as a method to categorise the degree of difficulty in oral surgery. The SAC classification has applications in aesthetic, restorative and surgical situations. Estab-



lishing in advance how complex an implant case is can ensure there are no surprises in the course of treatment. If necessary, it can allow referral of the case to someone better able to perform the risky portion and return the case for the easier treatment. Dr M. Vollmer insisted that finding an appropriately qualified colleague to manage a particularly complex case can prevent catastrophic complications and a poor outcome.

The content of the plan of action and its implementation should be checked against reality periodically. Regardless of how well planned, things never work out quite as envisaged; too often real-time developments lead to detours from the plan. In order to minimise such occurrences, modern implantology diagnostic tools like CBCT and computer-assisted planning can be helpful in complex cases but never absolve you from your responsibility to the patient.

In addition to the papers presented, two workshops were held. Owing to the high request for the workshops both of them were fully booked with almost 40 participants.

In the first workshop, Dr Valentin introduced a new technique for harvesting autogenous bone, as well as various sinus lift techniques. As the range of indications for dental implants is quickly changing, even patients with thin crestal bone or poor bone quality can be treated.

Congratulations for DGZI expert in implantology examination

Drs Susumu Moriyama and Ryoichi Sakamaki, Japan, passed the German Association of Dental Implantology (DGZI) expert in implantology examination after successful completion of the International Society of Oral Implantology (ISOI) authority in implantology certificate in Japan.



Valentin explained that osteotomes compress cancellous bone to provide a better bone quality and thus a good primary stability of the endosseous implant. The technique is based on saving as much natural bone as possible. As drilling the pilot hole is always accompanied by bone loss, the use of hollow osteotomes is recommended to combine the advantages of conventional osteotomes with the simultaneous removal of bone at the implant site. The sharp edges of the hollow instrument can manually be pushed or inserted into the alveolar bone with gentle taps on the proximal end of the working element when the jawbone is relatively soft, such as in areas of D3 or D4 bone (according to Misch's classification).

Valentin emphasised that a low risk of overheating the bone compared with the use of rotating instruments is another advantage, particularly when using navigation templates.

Meeting attendees later tested the various techniques, including direct and indirect sinus lift, on artificial specimens and were impressed with the easiness of these techniques.

Attendees were also very interested in the second hands-on workshop. The workshop presenters, Tamimi and M. Vollmer, demonstrated a surgical technique in which the inferior alveolar nerve is placed in a posterior position to increase the ability to place longer implants in a mandible in which there is significant resorption of the posterior ridge. Tamimi gave a clear theoretical introduction to the topic, and with M. Vollmer demonstrated the procedure step by step with the aid of a video. Although Tamimi explained that the procedure has limited application, attendees made use of the practical part to refresh their specialist knowledge of the anatomy of

the mandible by performing the nerve transpositioning technique on porcine jaws.

The Japanese colleagues were very interested in sharing in the DGZI's vast experience and in adopting its successful educational design. At present, this type of postgraduate education is not offered anywhere in Japan; however, Hayashi has proposed the implementation of the first implantology curriculum in Japan at a private university in Yokohama.

All attendees of the ISOI conference in Japan were met with great hospitality, and there was an exceedingly positive overall attitude towards the DGZI, which bodes well for continued successful collaboration and scientific exchange. The boards of both associations agreed that the ISOI meeting in Japan and the DGZI congress in Germany should be set events in the calendar for both societies in future.

Weber stated the following in his closing speech: "Annual meetings of professional societies tend to become routine. However, two factors can prevent this from happening: the topic to be discussed and the people who are to meet each other. Dental implantology is always developing, practically guaranteeing that there is something new to be discussed and to learn. The people we met at this meeting are very active, open-minded and internationally oriented. Thus, such a meeting does not only affirm old friendships, but is also a good opportunity to meet with new colleagues and to establish new friendships."

Having been in contact with Japanese colleagues in private practice, as well as working at various universities, I am very happy and honoured to be part of such a meeting as organised by the ISOI this year. From experience, I can say that Japanese organisation and hospitality are unsurpassed in the world. I would like to thank the ISOI organising committee for all its fruitful efforts to make this meeting another success. In addition to these acknowledgements, I would like to express my sincere best wishes not only for this meeting, but also for the continued outstanding relationship between our two societies."

Sugiyama's and Weber's closing invitations: "Looking forward to a meeting with all of you and thanking you again on behalf of the board and members of our society, we hope to see many colleagues from Japan at our meeting this year in Düsseldorf on 26 and 27 September."

"We invite all our DGZI friends from Germany to join us in Japan on 15 and 16 November in Osaka to experience the warmth and hospitality of the Japanese people and colleagues. So, we hope to see you in Düsseldorf, Germany, and in Osaka, Japan." _

Gingival implant supports

Reduction of cluster headache



Cluster headache is one of the most severe forms of headache. It is usually unilateral and occurs mostly around the eye or in the temple. Attacks last up to several hours. In many people, cluster headache leads to a significant loss of quality of life. A new type of cluster headache treatment is the stimulation of the sphenopalatine ganglion (SPG). The ATI Neurostimulation System stimulates the SPG in order to break the pain cycle. The neurostimulator, which is the size of an almond, is inserted through a small incision in the gingiva and programmed by the physician. As cluster headache occurs unilaterally, the implant is inserted on the relevant side. The surgery is performed under general anaesthetic and takes about an hour.

The patient can control his or her therapy independently via a remote control. When a cluster attack occurs, he or she holds the device against the cheek to activate the implant. This stimulates the SPG and abates the attack. In many patients, the frequency of attacks decreases permanently.

The effectiveness of the ATI Neurostimulation System has been clinically proven in the most comprehensive medical study on cluster headache. With the ATI neurostimulator, 82 per cent of all attacks—even medium to severe—can be treated effectively, the manufacturer, Autonomic Technologies, stated. In 46 per cent of patients, the attack frequency was reduced significantly—from an average of 14 down to two attacks per week. The ATI Neurostimulation System has been introduced at nine clinics in Germany and is in use in Belgium.

Dental implants and prostheses

Market worth more than \$9 billion by 2018

The global market for dental implants and prostheses is estimated to be worth \$9.1 billion by 2018, Market-sandMarkets, a US-based market research and consulting company, has announced. This means a 30 per cent increase compared to 2013, when the market was estimated to be worth \$6.4 billion. The market is driven mainly by the rising edentulous population, increasing adoption of advanced dentistry in developed countries, the increase in disposable incomes, and increasing awareness of dental care.



Despite the increase, the economic slowdown and limited reimbursement are factors that inhibit the growth of the market to a certain extent, the company explained in a press release. Despite competitive pressure from local players, the key contributors are expected to retain their leading positions in the global

market. This is primarily supported by continuous investment by these companies in research and development and by their strong global presence. Therefore, the top three companies are expected to maintain their positions with around 50 per cent share of the dental implants market in the next few years. The major players in this market include Liechtenstein-based Ivoclar Vivadent, Swiss companies Nobel Biocare and Straumann, as well as US manufacturers DENTSPLY International, Zimmer Dental, BIOMET 3i, BioHorizons and 3M.

The complete report, titled "Dental Implants & Prosthetics Market (Implants, Crowns & Bridges, Dentures, Abutments) Current Trends, Opportunities & Global Forecasts to 2018," which discusses the key market drivers, restraints, and opportunities of the global implants and prostheses market, as well as its submarkets, can be purchased online.

Could chewing gum prevent

Implant failure in the future?

About 6 to 15 per cent of patients suffer from peri-implantitis, inflammation that destroys soft and hard tissue surrounding the implant after placement. It is known that the concentration of matrix metalloproteinase-8, an enzyme that is also responsible for periodontitis, increases significantly when inflammation around the dental implant arises. Prof. Lorenz Meinel from the Institute of Pharmacy and Food Chemistry at the University of Würzburg explained that this increase could be identified through a special chewing gum using a small peptide chain that is bound to a bitter-tasting compound. Once enzyme concentrations in a patient's saliva exceed a certain level owing to complications with the implant, the peptide chain will snap, releasing the bitter compound. In the future, special chewing gum could be part of post-operative care in addition to routine check-ups. Patients would have to contact their dentist upon recognising the bitter taste.

In addition to the development of the chewing gum, the researchers are considering developing a coating that uses the peptide chain system and can be applied to the implant directly.



The project will be carried out in collaboration with Swiss dental implant manufacturer Thommen Medical and various other European companies and scientific institutions. The research has received funding of €1 million for two years from the European Union.

implants
international magazine of oral implantology



Publisher

Torsten R. Oemus
oemus@oemus-media.de

CEO

Ingolf Döbbecke
doebbecke@oemus-media.de

Members of the Board

Jürgen Isbaner
isbaner@oemus-media.de

Lutz V. Hiller

hiller@oemus-media.de

Chief Editorial Manager

Dr Torsten Hartmann (V. i. S. d. P.)
hartmann@dentalnet.de

Editorial Council

Prof. Dr Heiner Weber
heiner.weber@med-uni-tuebingen.de

Dr Roland Hille

dr-hille@t-online.de

Prof. Dr Kurt Vinzenz

kurt.vinzenz@aon.at

Dr Torsten Hartmann

hartmann@dentalnet.de

Dr Suheil Boutros

SMBoutros@aol.com

Editorial Office

Georg Isbaner
g.isbaner@oemus-media.de

Claudia Jahn

c.jahn@oemus-media.de

Executive Producer

Gernot Meyer
meyer@oemus-media.de

Designer

Sarah Fuhrmann
s.fuhrmann@oemus-media.de

Customer Service

Marius Mezger
m.mezger@oemus-media.de

Published by

OEMUS MEDIA AG
Holbeinstraße 29
04229 Leipzig, Germany
Tel.: +49 341 48474-0
Fax: +49 341 48474-290
kontakt@oemus-media.de

Printed by

Silber Druck oHG
Am Waldstrauch 1
34266 Niestetal, Germany

implants

international magazine of oral implantology
is published in cooperation with the German
Association of Dental Implantology (DGZI).

DGZI President

Prof. Dr Heiner Weber
DGZI Central Office
Paulusstraße 1, 40237 Düsseldorf, Germany
Tel.: +49 211 16970-77
Fax: +49 211 16970-66
office@dgzi-info.de

www.dgzi.de
www.oemus.com

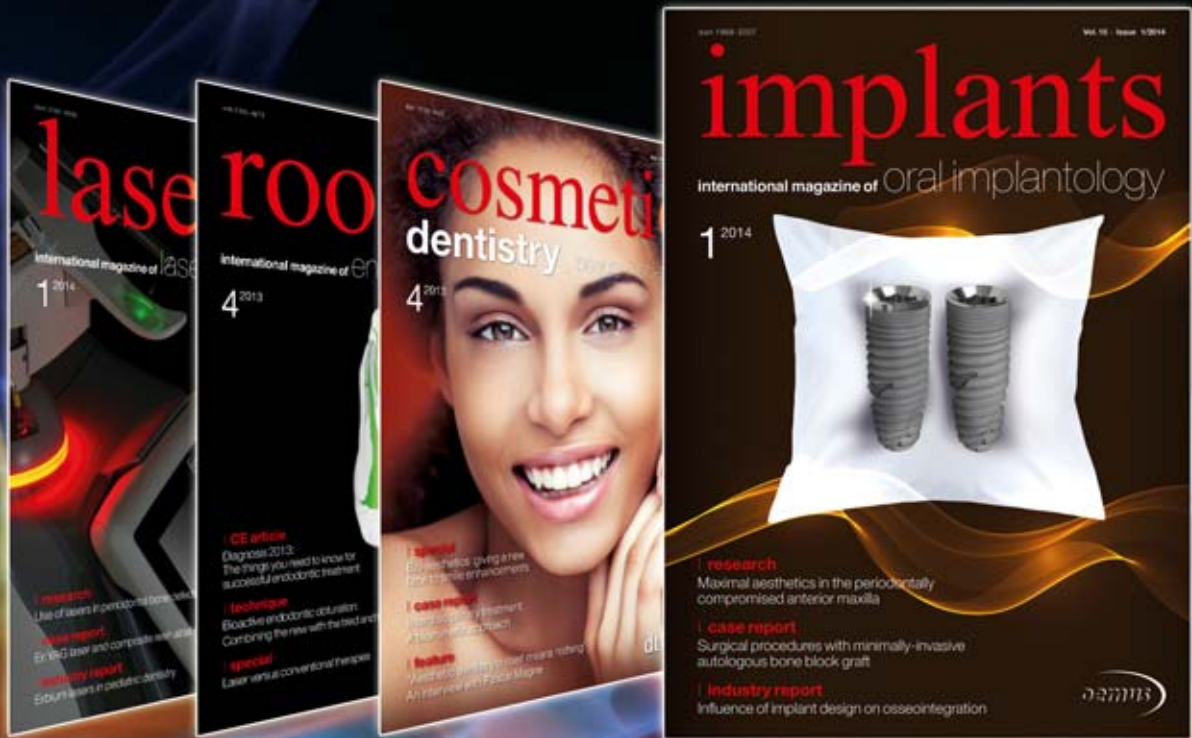Copyright Regulations

implants international magazine of oral implantology is published by Oemus Media AG and will appear in 2014 with one issue every quarter. The magazine and all articles and illustrations therein are protected by copyright. Any utilization without the prior consent of editor and publisher is inadmissible and liable to prosecution. This applies in particular to duplicate copies, translations, microfilms, and storage and processing in electronic systems.

Reproductions, including extracts, may only be made with the permission of the publisher. Given no statement to the contrary, any submissions to the editorial department are understood to be in agreement with a full or partial publishing of said submission. The editorial department reserves the right to check all submitted articles for formal errors and factual authority, and to make amendments if necessary. No responsibility shall be taken for unsolicited books and manuscripts. Articles bearing symbols other than that of the editorial department, or which are distinguished by the name of the author, represent the opinion of the afore-mentioned, and do not have to comply with the views of Oemus Media AG. Responsibility for such articles shall be borne by the author. Responsibility for advertisements and other specially labeled items shall not be borne by the editorial department. Likewise, no responsibility shall be assumed for information published about associations, companies and commercial markets. All cases of consequential liability arising from inaccurate or faulty representation are excluded. General terms and conditions apply, legal venue is Leipzig, Germany.

implants

international magazine of oral implantology



Subscribe now!

I would like to subscribe to **implants international magazine of oral implantology** (4 issues per year) for €44 including shipping and VAT for German customers, €46 including shipping and VAT for customers outside Germany, unless a written cancellation is sent within 14 days of the receipt of the trial subscription. The subscription will be renewed automatically every year until a written cancellation is sent to OEMUS MEDIA AG, Holbeinstr. 29, 04229 Leipzig, Germany, six weeks prior to the renewal date.

▶ Reply via Fax +49 341 48474-290 to OEMUS MEDIA AG or per E-mail to grasse@oemus-media.de

You can also subscribe via www.oemus.com/abo

Last Name, First Name

Company

Street

ZIP/City/County

E-mail

Signature

Notice of revocation: I am able to revoke the subscription within 14 days after my order by sending a written cancellation to OEMUS MEDIA AG, Holbeinstr. 29, 04229 Leipzig, Germany.

Signature



ASTRA TECH
IMPLANT SYSTEM



Join the **EV**olution

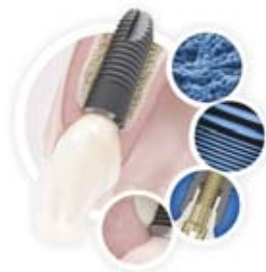

The new
ASTRA TECH Implant System™ EV
– now available

Learn more



www.jointheev.com



The foundation of this evolutionary step remains the unique **ASTRA TECH Implant System BioManagement Complex**, well-documented for its long-term marginal bone maintenance and esthetic results. www.dentsplyimplants.com

DENTSPLY
IMPLANTS