

cosmetic

dentistry _ beauty & science

3²⁰⁰⁹

_case study

Management of full mouth
prosthodontic rehabilitation

_feature

Aesthetics and the brain

_industry report

Temporaries: Perfect provisional restorations



dti Dental
Tribune
International

YOU CAN VISIT US AT FDI,
STAND Q01-10 OR
WWW.NOBELBIOCARE.COM



NobelProcera™

Full zirconia product assortment in four colors.



white



light



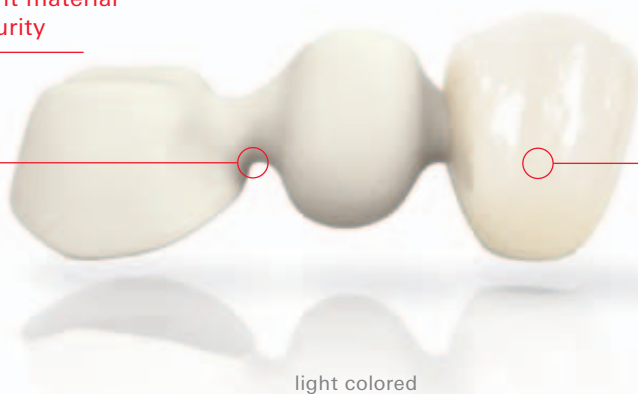
medium



intense

Certified for excellent material
homogeneity and purity

Excellent flexural
strength and no
degradation in
strength compared
to white zirconia*



light colored

intense colored

Innovative coloring
technique

Excellent esthetic
results supported by
the coloring of the
underlying framework

* Nordic Institute of Dental Materials (NIOM) NobelProcera™ Zirconia testing: S306269B, S306205B.

** Products for NobelActive™ platform are currently under development.



Following the success of shaded NobelProcera Zirconia Crowns, the same colors are now available for the full assortment** – crowns, copings, bridges, abutments, implant bridges. The innovative coloring technique ensures excellent material homogeneity, consistent color throughout frameworks. External studies show no degradation in strength compared

to white zirconia*. NobelProcera offers solutions for all indications – single crowns, bridges up to 14 units, cemented or screw retained, fixed or removable prosthetics on natural teeth and implants. NobelProcera provides extensive experience and access to a quality-assured centralized industrial manufacturing. Precision of fit, quick turnaround

times, consistent and predictable results – you will enhance your customer satisfaction and the efficiency of your practice. Nobel Biocare is the world leader in innovative evidence-based dental solutions. For more information, visit our website. www.nobelbiocare.com/nobelprocera

Dear Reader,



Dr Sushil Koirala
Editor-in-Chief

Since the beginning of the year **cosmetic dentistry** has shown a strong presence at various international seminars, conferences, trade shows, and scientific meetings. The amount of positive feedback we have received thus far has encouraged us immensely and given more responsibility to our team in aiming to meet the expectations of our professional colleagues around the world. With the electronic edition of **cosmetic dentistry** now available at www.dental-tribune.com, our readers across the globe now have 24/7 access to information on the latest developments in the field.

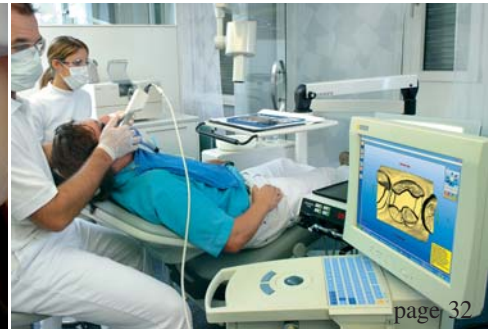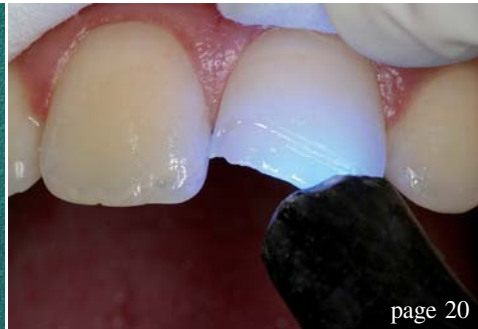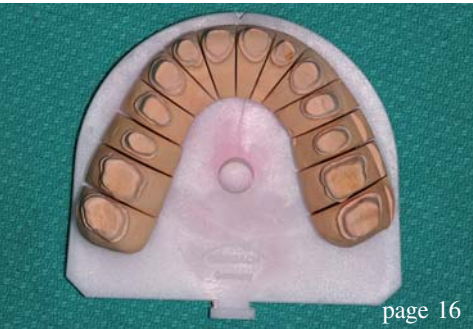It is encouraging to note that various aesthetic events are now hosted in Asia. Additionally, general dental associations are demonstrating increasing eagerness to invite speakers on aesthetic topics to their scientific meetings. As the demand for aesthetic procedures amongst our patients increases, so too does the demand for quality aesthetic dentistry lectures, training and accreditation programmes. Unfortunately, many Asian countries are still lagging behind owing to the lack of such activities at a national level. Because of financial and time constraints, participation in international aesthetic dentistry activities is not viable for many of our Asian colleagues. I suggest that a possible solution to this for our Asian dental professional associations, societies, academies and various educational centres is to utilise the advanced information technology available in the knowledge and skills dissemination process.

It is my pleasure to announce here that the South Asian Academy of Aesthetic Dentistry will launch its online aesthetic dentistry accreditation (fellowship) programme at www.dentistrysouthasia.com on November 2009. We believe that this effort is a milestone in the development of voluntary professional accreditation systems in South Asia. In addition, the Asia Pacific Dental Federation is planning to launch a two-year fellowship programme in aesthetic dentistry. The concept paper and syllabus for this programme were presented at the ICCDE board meeting during APDC Hong Kong 2009.

As always, I hope you will enjoy this new edition of **cosmetic dentistry**, in which we present a combination of clinical cases, expert opinion pieces and product information. I look forward to receiving your valuable feedback. Please feel welcome to share your clinical expertise and experiences with us.

Sincerely,

Dr Sushil Koirala
Editor-in-Chief
President Vedic Institute of Smile Aesthetics (VISA)
Kathmandu, Nepal



| **editorial**

03 **Dear Reader**
_ Dr Sushil Koirala, Editor-in-Chief

06 **Welcome to our international colleagues**
_ Dr Suhit R. Adhikari

| **case study**

08 **Immediate dentures:** Are you missing out?
_ Dr Craig Callen

12 **Ceramic restorations—**What is the key to success?
_ Robert Michalik

16 Management of **full mouth prosthodontic rehabilitation** using high-strength CAD/CAM zirconium-oxide crowns
_ Dr Ansgar C. Cheng et al.

| **clinical technique**

20 **Anatomic stratification technique** for lifelike anterior composites
_ Dr Ratnadeep Patil & Dr Kavita Mahesh

| **special**

24 **Smile Design Wheel™:** A practical approach to **smile design**
_ Dr Sushil Koirala

| **feature**

30 **Aesthetics and the brain**
_ Dr David L. Hoexter

32 **Ceramic instead of composite**
_ Manfred Kern

| **industry report**

34 **Temporaries:** Perfect provisional restorations
_ Dr Hans Sellmann

38 **Customised abutments** for long-term aesthetics—**software tools** to meet clinical and laboratory requirements
_ Hans Geiselhöringer & Dr Stefan Holst

| **industry news**

42 **Ivoclar:** Progress knows **no clinical limitations**

| **lifestyle**

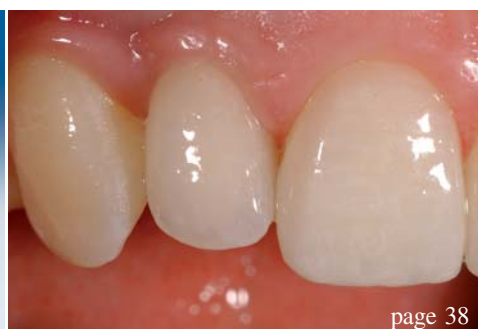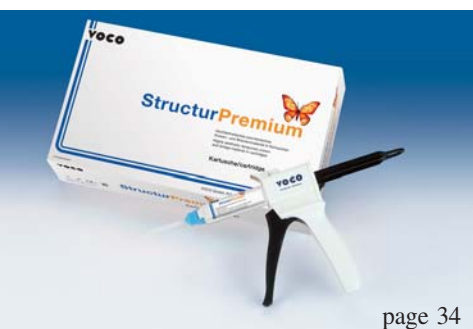44 **Enjoy your trip and indulge** in the journey!
_ Annemarie Fischer

| **meetings**

48 **Cosmetic events**

| **about the publisher**

49 _submissions
50 _imprint





Welcome to our international colleagues



Dr Suhit R. Adhikari

The South Asian Academy of Aesthetic Dentistry (SAAAD) was founded in 2005 as the first web-based, regional professional academy in South Asia. The academy is dedicated to advancing the art and science of aesthetic dentistry and to promoting high standards of ethical conduct and responsible patient care, by institutionalising a standard continuing professional development programme through the provision of relevant accreditation (fellowship) processes. In order to fulfil its mission, the academy conducts regional aesthetics meetings and skills-oriented aesthetic training programmes and aims to organise its biennial scientific conference on a rotation basis amongst its member countries.

It is my pleasure to announce here that Nepal, the home country of the SAAAD initiator, is hosting the first SAAAD biennial scientific conference from 28 to 29 November 2009. The conference theme is *Minimally Invasive Cosmetic Dentistry: A Holistic Approach*. The conference is organised in collaboration with the Asian Academy of Aesthetic Dentistry, the Nepalese Academy of Cosmetic and Aesthetic Dentistry (NACAD), the Sri Lankan Academy of Aesthetic and Cosmetic Dentistry, the Bangladesh Academy of Aesthetic Dentistry and the Esthetic Academy of Bangalore, India.

It will be the first meeting of its kind in South Asia, with many renowned regional and international aesthetic dentists meeting in one place to share their knowledge and skills in order to promote the art and science of aesthetic dentistry. We believe that the conference theme demonstrates our interest in quality, health and ethical issues of aesthetic dentistry in Asia. We look forward to bringing positive changes through our mutual collaboration.

On behalf of the organising committee and the host country, I would like to cordially invite you all to participate in the forthcoming SAAAD conference in Kathmandu to foster great relationships as professionals and friends and to enjoy the hospitality, natural beauty and cultural richness of Nepal. To sign up for the SAAAD Nepal conference, please visit www.saaad.org. I hope to see you in Kathmandu!

Namaste,
Dr Suhit R. Adhikari
SAAAD 2009 Conference Organizing Chairman
SAAAD Secretary General
NACAD President



Immediate dentures: Are you missing out?

Author_ Dr Craig Callen, USA

All of the courses advertised today tout the productivity of porcelain facings, orthodontics, automated root canal and implants. While any of these treatments can be rewarding and profitable, the often-overlooked area of treatment that is highly rewarding and profitable is that of removable prosthetics. Yes, I said it, dentures! Many of us became burnt out on making dentures in dental school and never recovered, but times have changed. Not only is there a huge untapped market for high-quality dentures as the population ages, but it can also be one of the most rewarding and profitable procedures you provide for your patients per hour.

Fig. 1_After, full face.



In addition, with the materials available to you today, this can be a relatively easy treatment. A lot of what we know about cosmetic dentistry came from prosthodontics. Full denture treatment used to be the ultimate in cosmetic dentistry before periodontal care changed the way dentists practice.

Prosthodontists were really the first dentists to study things such as facial proportions as related to tooth size and shape.

_How to get denture patients

Our office offers a *Free Aesthetic Denture Consult*. This allows patients to meet us and see what we can do for them in a non-threatening environment. If a patient calls in requesting fees, they are offered the option of the free consult. The patient is scheduled for a 10-minute time block with a doctor in the consultation room. He or she fills out a short form that pertains strictly to dentures. Then the patient is given a printout that describes his or her denture options and procedures. We also show the patient pictures of our cases and how natural they look.

We just had two large discount denture centres move into our area (and they tend to be more bait-and-switch than discount centres). We not only had to compete, but also differentiate our office by showing that we provide high quality, aesthetic dentures, not cheap ones.

Most of our dentures are set with Dentsply's Portrait IPN denture teeth, which look amazingly natural. We run a small advertisement in the local paper promoting aesthetically pleasing dentures. In addition, we belong to www.denturewearers.com, which is a great online informational site for denture patients



Fig. 2

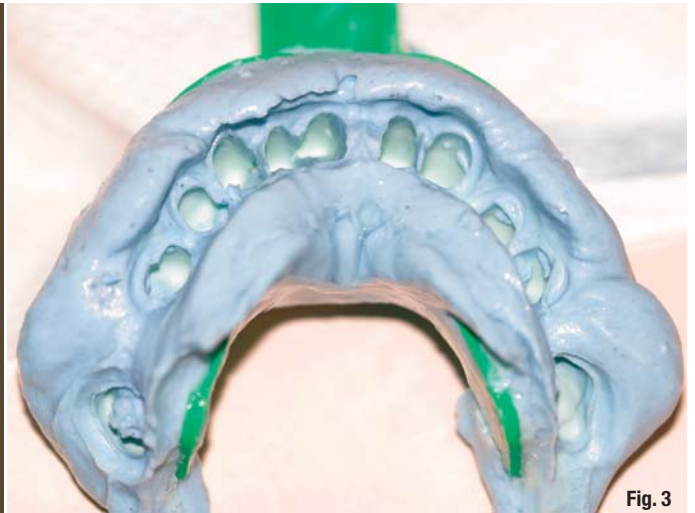

Fig. 3

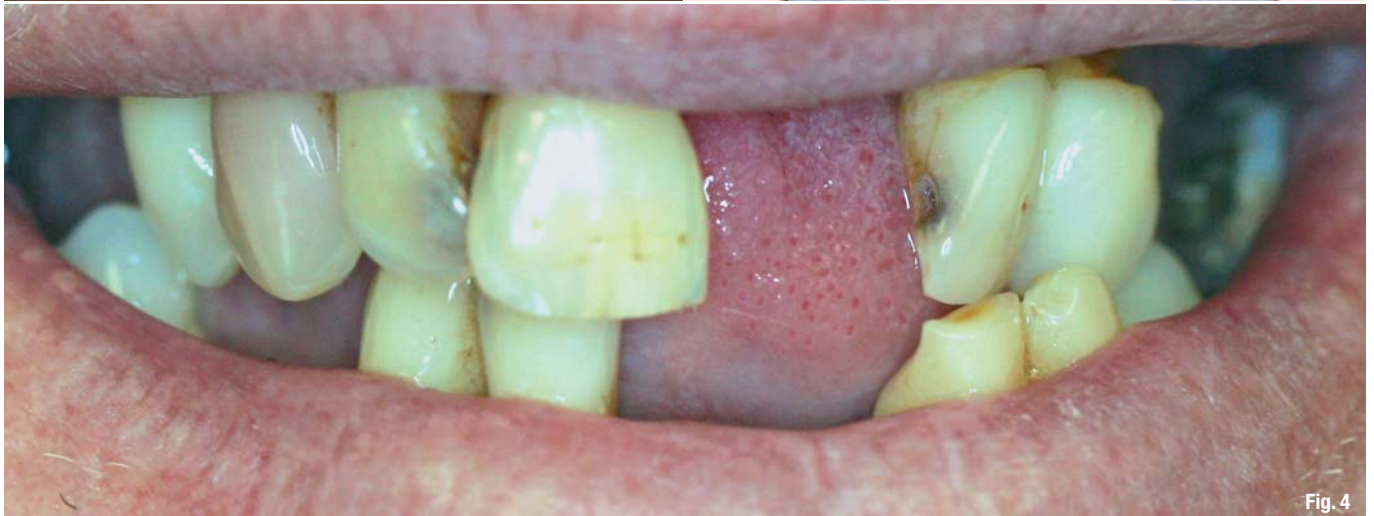

Fig. 4

and will help drive them toward your own Web site and office looking for solutions (Fig. 2).

Technique appointment No. 1

Randy is a typical patient who came in for a free consultation for immediate maxillary and mandibular dentures. He had been told a long time ago that he had severe periodontal disease and that his teeth could not be saved. A busy contractor, he put off treatment for years. We were able to appoint him for a complete examination and X-ray films, which verified his story.

Financial arrangements were made and we set-up an appointment for impressions, shade and bite (Fig. 3). At the next appointment, we took about an hour to get nice impressions with the Accudent dual alginate system with stock trays.

If Randy had been edentulous, we would have used Accudent's anatomically corrected denture trays. This utilises a light and heavy

body alginate mixed in an alginator. The light body sets slower and is applied in a large syringe. Because Randy still had teeth to establish vertical and tooth position, we then took a bite with Discus Dental's Vanilla Mousse, but you can, of course, use your material of choice. If there are many missing teeth, you may also use Discus Dental's Impression Putty for a bite .

The shade was chosen using the Dentsply Portrait Shade Guide. As most people want to bleach their teeth, we see more and more patients choosing lighter coloured teeth. We take several clinical and portrait photos for our records and the lab's use in setting the case.

If the patient wants to change his or her smile, we use *The Smile Style Guide*, written by Dr Lorin Berland and Dr David L. Taub to pick a new smile (www.Digident.com; +1 800 741 7966). It is a great tool that contains a multitude of different smiles progressing from square, pointed, round and flat as well as various length combinations that we include with detailed notes for the lab about exactly what we and the patient want.

Fig. 2 A screen shot of www.denturewearers.com.

Fig. 3 Accudent immediate denture impression.

Fig. 4 Before, close-up.

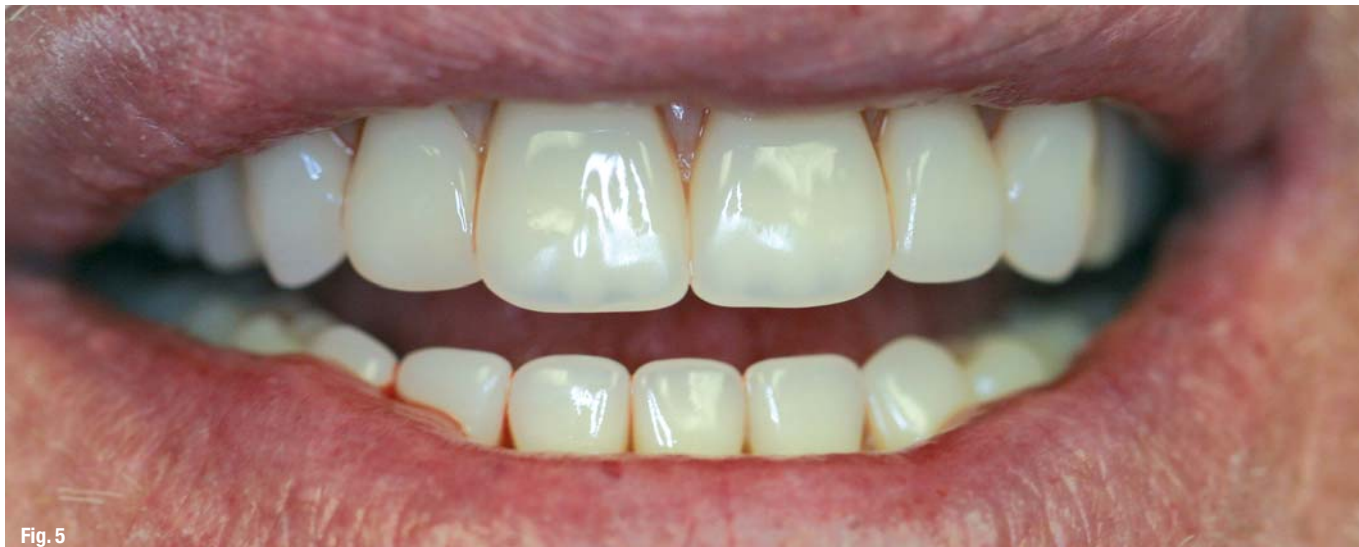

Fig. 5

Fig. 5 After, close-up. **_Technique appointment No. 2**

Because Randy did not need to have posterior teeth removed and prolonged healing time, we progressed right to a wax try-in appointment in two weeks. I do a split set-up to verify the bite and show the patient the set-up. Randy, and his wife, approved the set-up and the aesthetics and we scheduled the surgical appointment in another two weeks. The case is then sent to the lab for proper festooning and life-like base material processing.

_Technique appointment No. 3

Fourteen periodontally involved teeth were removed with local anaesthetic and nitrous oxide and the dentures seated. I relined them with a temporary soft liner to aid in the fit (Fig. 5). We use a cartridge-based system, such as VOCO's UFI Gel SC. When Randy and his wife saw his new smile, they both cried (in a good way) (Fig. 1). She immediately scheduled herself for an appointment for dentures too. In six months we will provide relines.


_Technique appointment No. 4

Randy was back the next day with minimal concerns. I will generally see the patient on the first adjustment, and then delegate the simple adjustments to my well-trained, experienced staff.

My total chair time with the free consultation, examination, impressions, try-in, extractions and seating and the first healing check was about 2.5 hours. My per hour production was higher than what I make on a typical crown and bridge case, and I provided a life-changing treat-

ment for a patient who was a dental cripple. If the patient has trouble wearing dentures, we can proceed to implants to help in retention. One of the keys to providing quality denture care for your patients is to find a laboratory that also is interested in quality. You will pay top dollar, but it will be well worth it.

If you are not providing denture treatment in your practice and you have holes in your schedule, you should think again about this underserved area of cosmetic dentistry. As baby boomers age and lose teeth, there will be a real need for quality denture care.

_author info		cosmetic dentistry
	<p>Dr Craig C. Callen is a full time practicing dentist in the small city of Mansfield, Ohio, USA, in the centre of the rust belt. He graduated from Case Western Reserve School of Dentistry at the age of 23. Callen has written three books for dentists: <i>The Cutting Edge I, II, and III</i>. He is the associate editor for <i>The Profitable Dentist Newsletter</i> and has written numerous articles for national dental publications. Callen is a member of the ADA, AGD and the AACD. He has lectured internationally on clinical and management topics in dentistry. His latest seminar is titled, <i>The Million Dollar Blue Collar Dental Practice</i>. Callen and his wife, Dee, have five children. They live on a farm where they raise horses, alpacas and llamas. In his spare time, he likes to spend time boating and travelling. You can reach Dr Callen via E-mail at craigcallendds@gmail.com.</p>	

VITA Easyshade[®] Compact – The exact shade in the blink of an eye.

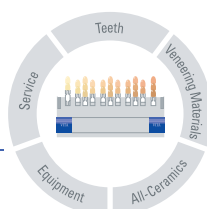


The new generation
of digital tooth shade determination

3384 E



Vita System



3D - Master

VITA

It's digital, cable-free, lightweight and mobile – there are a good many reasons for choosing the VITA Easyshade Compact. And every one of these is in itself a winner. With the new generation of digital shade measurement you determine and check the tooth shade in a matter of seconds. The VITA Easyshade Compact is

designed for all shades of the VITA SYSTEM 3D-MASTER and the VITAPAN classical A1-D4 shades. This high-tech instrument impresses with a great accuracy of measurement using state-of-the-art spectrophotometric measurement technology. See for yourself. Find out more at www.vita-zahnfabrik.com.

Ceramic restorations— What is the key to success?

Author_ Robert Michalik, Poland

Fig. 1_Ceramic crowns made on a metal substructure (CrCo).

Figs. 2-4_Crowns made on a zirconium dioxide substructure.

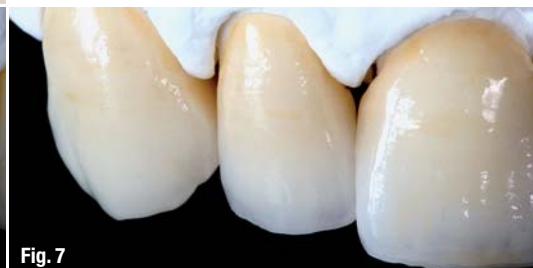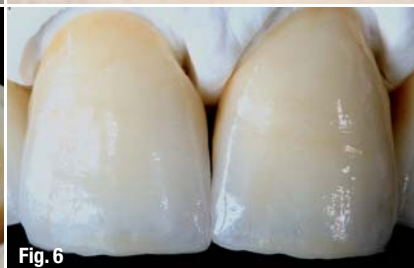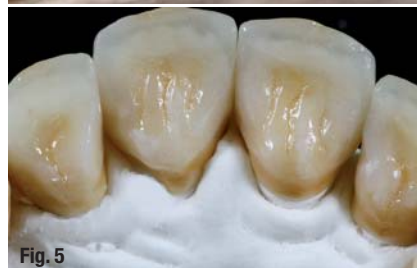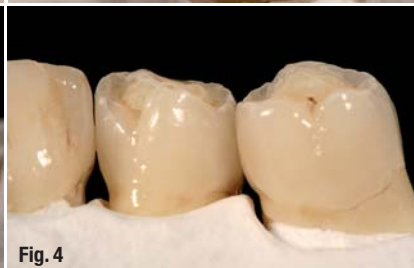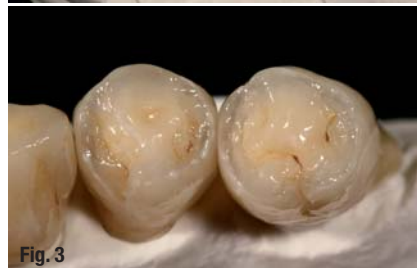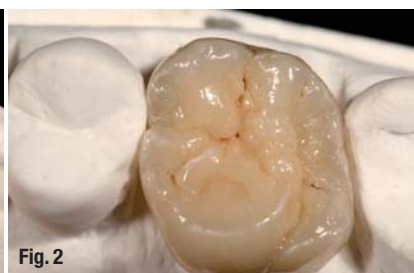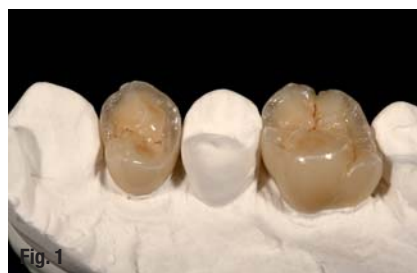Figs. 5-7_Ceramic crowns made on a substructure using the press technique.

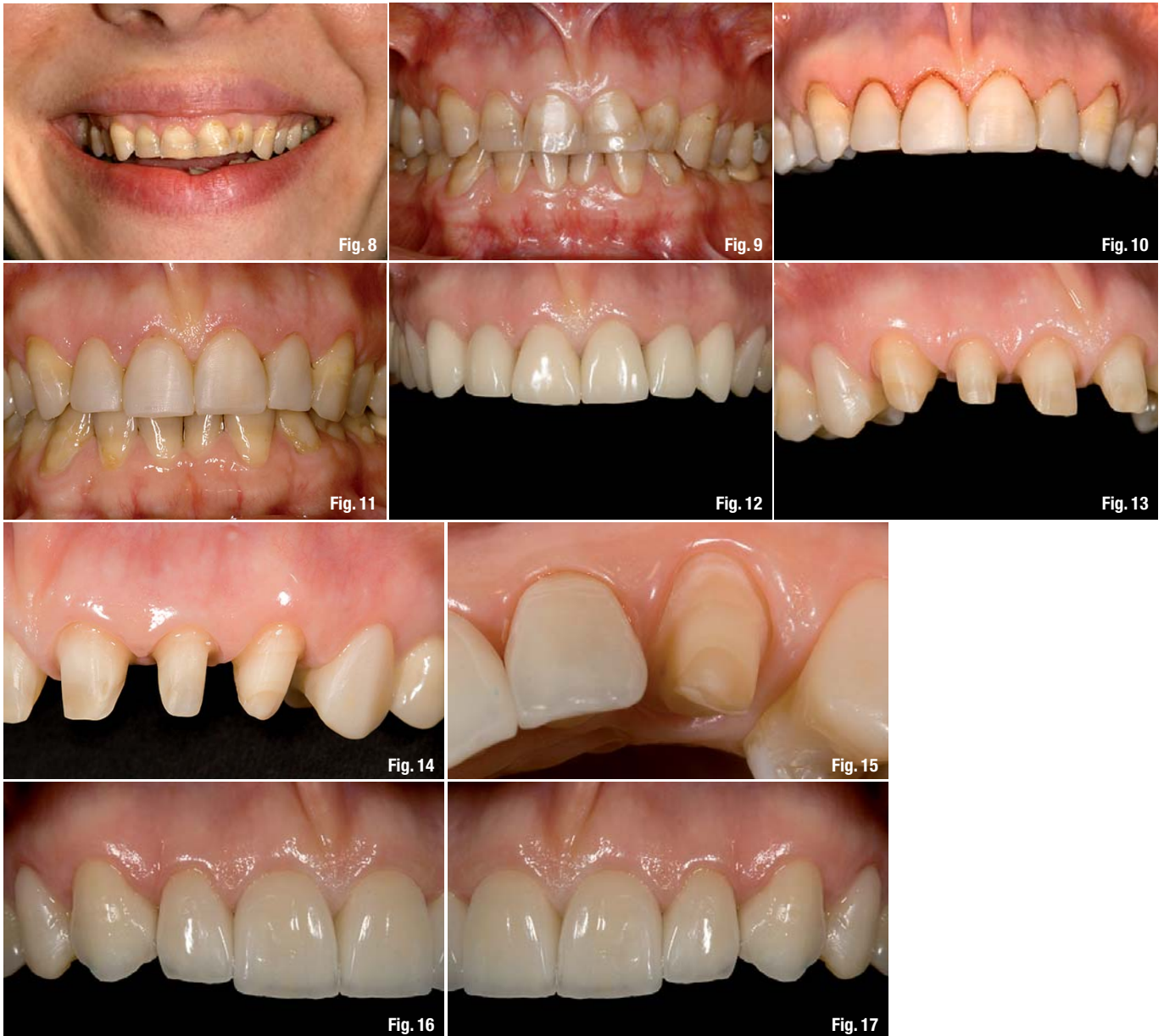_The issue I would like to address in this article is one well known to many of the readers. However, occasionally it can be beneficial for us to consolidate and evaluate our knowledge. Therefore, I would like to set out my own experiences acquired over many years of work as a dental technician. I hope that the majority of readers will share my

opinion that in order to guarantee a successful ceramic restoration it is important to choose the right material and construction and to ensure that it is properly made. Prosthetic work carried out in this way ensures an aesthetically pleasing appearance, perfect marginal seal and durability for the entire restoration. Naturally, it cannot be expected that crowns set on a non-precious metal will look beautiful and provide a natural distribution of light, for example.

Technicians will always face a dilemma when it comes to choosing the right coping, and only a skilful consideration of all the arguments for and against any specific solution will guarantee a successful outcome. My observations primarily concern the materials and technologies that I have most frequently used to make ceramic crowns.

The firing method used for a ceramic mainly depends on the material of the coping. In turn, the aesthetic quality of the prosthetic restoration (transparency, opalescence, fluorescence) is mostly influenced by the type of coping used.





Ceramic prosthetic crowns differ both in the technology used to construct them and in the materials from which the restoration is prepared. Porcelain can be fired on:

- _ alloys: precious metals (alloys with high gold content—above 75%, medium—50–70%, low—up to 50%) and non-precious metals (chrome, cobalt);
- _ galvanic structures;
- _ transparent zirconium dioxide ZrO_2 (nanoceramic—size of grain below $30\mu m$, purity of material 99.9999%, and opaque zircon—grain value above $30\mu m$);
- _ aluminium trioxide Al_2O_3 ;
- _ press porcelain; and
- _ feldspathic porcelain.

I will briefly outline the pros and cons of the crowns we use most frequently in our office.

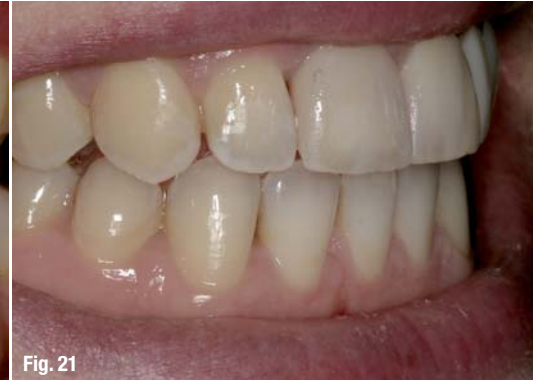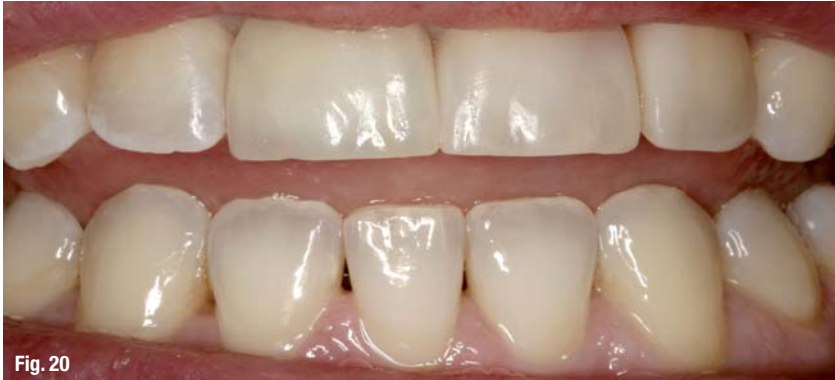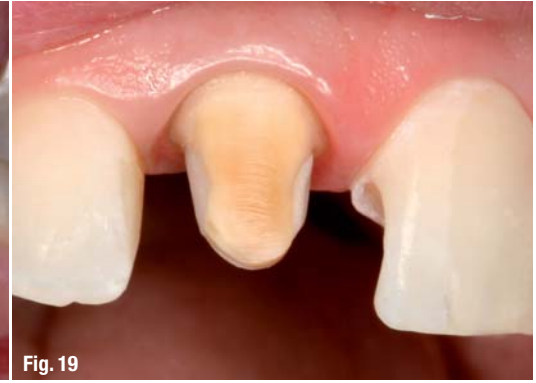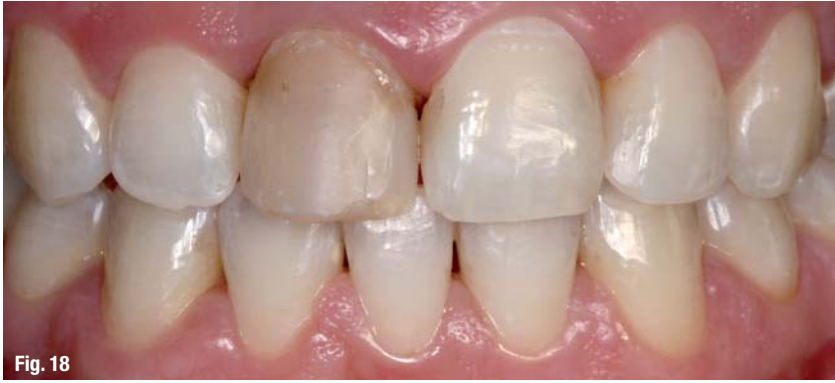_ Porcelain fired directly on refractory die

Advantages

- _ natural distribution of light in finished restoration
- _ optimal cohesion of material
- _ excellent aesthetic effect when making individual crowns for anterior non-discoloured abutment teeth or veneers and inlay/onlay restorations
- _ physiological wear with the antagonist
- _ chameleon effect

Drawbacks

- _ a difficult restoration technology, as no adjustments can be made once the refractory material is removed
- _ not possible to control and monitor individual stages of the work
- _ limited application for making individual anterior crowns to be placed on non-discoloured abutments or for inlay/onlay restorations



_ preparation is possible only with a simple, relatively even shoulder around the entire circumference

_ Porcelain fired on zirconium dioxide ZrO_2

Advantages

- _ reproducibility and accuracy of restoration (only in CAD/CAM system)
- _ good light dispersion
- _ covers dark abutments and metal posts and cores (opaque zircon)
- _ a wide range of applications (crowns, bridges, bars and implant abutments, telescope crowns, ledges)
- _ possibility of preparation with limited shoulder and chamfer/bevel
- _ individual stages of the work can be monitored, even in the patient's mouth
- _ construction retains shape when ceramic is fired

Drawbacks

- _ construction has limited elasticity
- _ micro chipping on active surface
- _ construction cannot be repaired
- _ liners must be used

_ Porcelain fired on metal

Advantages

- _ chemical bonding of construction with porcelain
- _ construction can be repaired
- _ high elasticity
- _ a wide range of applications (bridges, crowns,

telescope prosthetics, posts and cores, bars and implant abutments)

- _ individual stages of the work can be monitored, even in the patient's mouth
- _ oligodynamic effects (in the case of gold)

Drawbacks

- _ no transparency in substructure
- _ oxidation necessary
- _ risk of margin deformation when firing ceramic
- _ external factors may influence construction (temperature, proportion, refractory material)

I will present several cases in which various kinds of substructures were used to achieve the most natural appearance possible.

_ Case I (Figs. 8–17)

A 28-year-old patient presented with pronounced discoloration of the teeth, which was a result of medication from the tetracycline group taken during her childhood (Fig. 8). There was also significant damage to the enamel of the patient's teeth. The uneven cervical line had damaged the aesthetic appearance of her dentition. The patient wished to change both the shape and appearance of her teeth.

The first task was to ensure a proper cervical line and achieve an effect of longer teeth without changing the occlusal line. Owing to the skilful work of the dentist and the ideal construction of the temporary crowns made by the technician, it was possible to

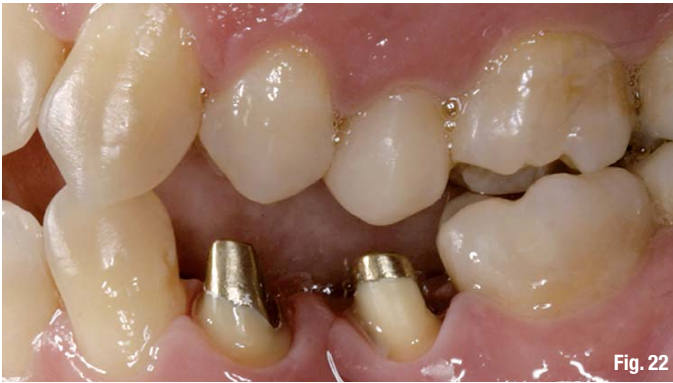

Fig. 22

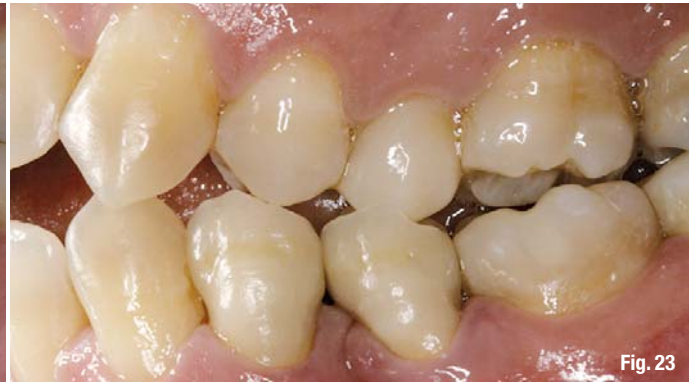

Fig. 23

achieve excellent results in the red aesthetic zone. Figures 16 and 17 show that the gingiva formed in accordance with our expectations.

As I mentioned earlier, in order to guarantee success, it is important to choose the right technology for crown fabrication. In this case, I considered two possibilities for making the restorations: either on a coping using press technology or fired directly on the refractory material. I was faced with such a dilemma because I was unsure whether the crowns made using feldspathic porcelain would cover the dark abutments of the patient's teeth. After the preparation, however, it turned out that the stumps of the teeth were not as drastically discoloured as the colour prior to the preparation had indicated.

The effect of the reconstruction is left to the appraisal of the readers. The use of a metal coping and even a zircon solution would not have achieved the desired aesthetic result.

_Case II (Figs. 18–21)

A 26-year-old patient presented with a discoloured tooth 11 (Fig. 18). Previously, the operations performed by the dentist on the patient had involved making composite veneers, which had changed colour over time.

The first stage of the work involved changing the fillings in teeth 21 and 22, then making the preparation and taking the impression. In this case, I considered three variants for the substructure: made using the press method, a zirconium dioxide coping or a galvanic structure. The patient wanted a natural restoration identical to the one on tooth 21.

The press method would have been too risky, as the stump of the tooth was severely discoloured. I was concerned that the dark colour would show through the cemented crown. A crown inserted on a galvanic gold coping, in spite of its warm tone and its ability to cover the dark abutments, would not have dispersed light in such a way that when looked at from any

angle it would be impossible to notice any features distinguishing it from a natural tooth. Hence, I decided to make a crown based on a zirconium dioxide substructure.

_Case III (Figs. 22–23)

A patient visited our surgery for a typical dental check-up. After a preliminary examination, caries was found to be present in several teeth, including the patient's two lower premolar teeth (secondary caries reaching the pulp chamber). Unfortunately, in cleaning the zone affected with caries the dentist had to devitalise the tooth and perform endodontic treatment. On completion of the treatment, the remaining dental tissue was found not suitable for partial restoration. Hence, the dentist decided to make ceramic crowns and place them on stumps strengthened beforehand with gold alloy posts and cores. The stumps prepared in this way were subjected to analysis that showed that the optimal solution in this case would be porcelain crowns made on a zirconium dioxide substructure. This would ensure an aesthetically pleasing appearance and durability. Such characteristics could not be achieved with crowns made using the press method or fired on a refractory material or a metal coping. Only using zirconium dioxide as a substructure guaranteed the intended effect, which is left to the readers to judge.

In conclusion, I would like to thank the dentists who helped me prepare the work presented here. I would also like to thank Robocam for providing the zirconium dioxide.

_contact

cosmetic
dentistry

Robert Michalik
INTER-DENT Laboratory
Ul. Pustufeczki 23, Warsaw
Poland
Tel.: +48 22 651 5645
E-mail: info@inter-dent.pl

Management of **full mouth** **prosthodontic rehabilitation** using high-strength CAD/CAM zirconium-oxide crowns

Authors_ Dr Ansgar C. Cheng, Dr Helena Lee, Dr Neo Tee-Khin & Ben Lim, Singapore

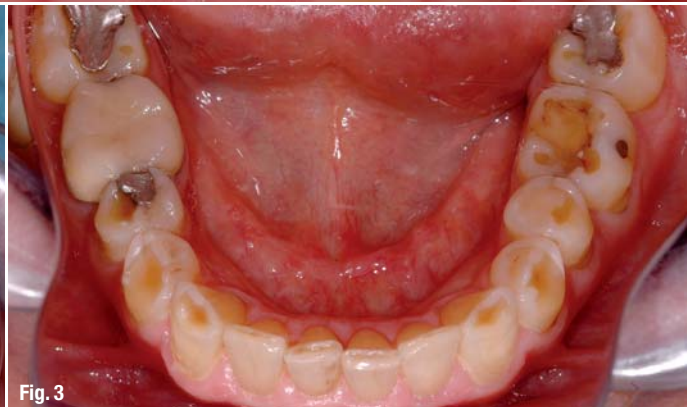
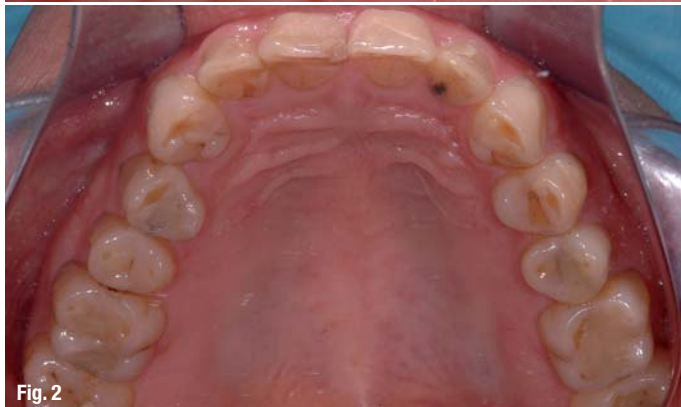
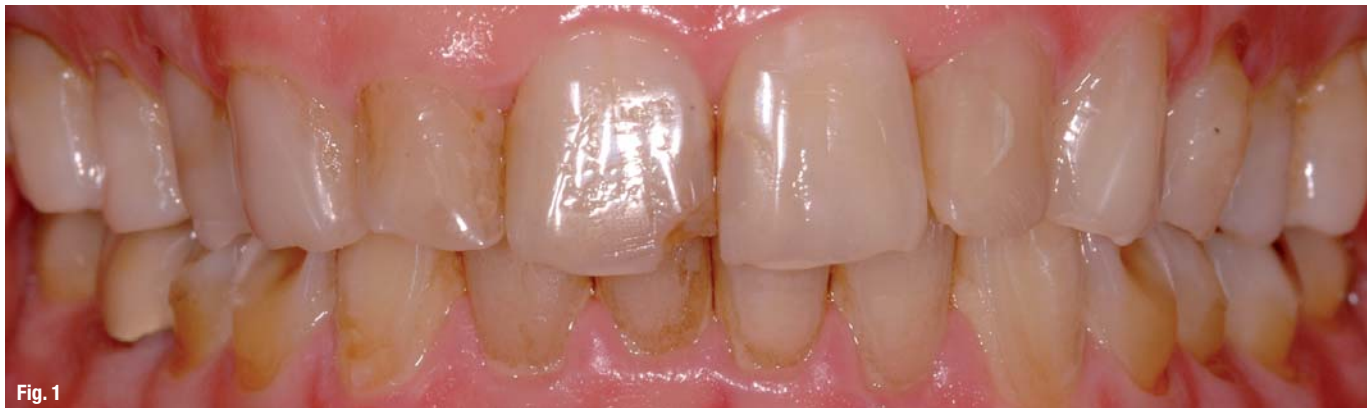Fig. 1_ Pre-treatment frontal view showing attrition, erosion, discoloration and compromised aesthetics.

Fig. 2_ Pre-treatment maxillary occlusal view showing general loss of enamel on the occlusal surfaces.

Fig. 3_ Pre-treatment mandibular occlusal view revealing loss of occlusal tooth structure and differential erosion loss of dentine.

_Introduction

_Prudent clinical judgement and careful consideration of the risks and benefits of various treatment options are essential for the treatment planning and long-term success of prosthodontic treatment.¹ It has been established that loss of the vertical dimension of occlusion (VDO) may pose significant clinical difficulties in prosthodontic treatment.^{2,3} Yet, the re-establishment and maintenance of a new VDO is seldom taught in undergraduate dental curricula.

VDO is defined as the vertical measurement of the face between two selected points superior and inferior to the oral cavity when the occluding members are in contact.⁴ Various methods have been proposed for the assessment and re-establishment of the VDO.³ The difference between the vertical measurement of physiological rest position, which should have a higher value than the VDO, and the VDO is referred to as the inter-occlusal rest space,⁴ which is essential for normal patient function.

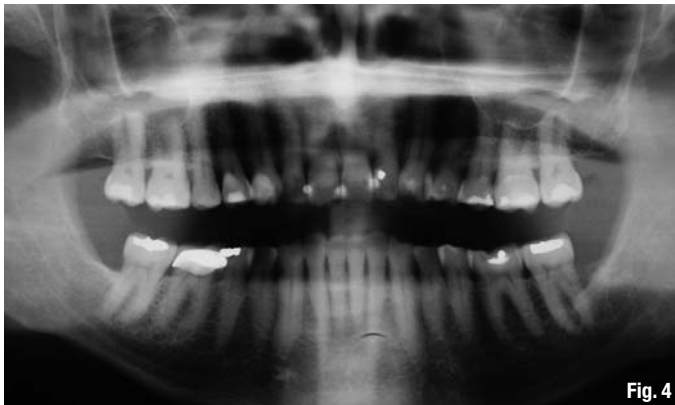


Fig. 4

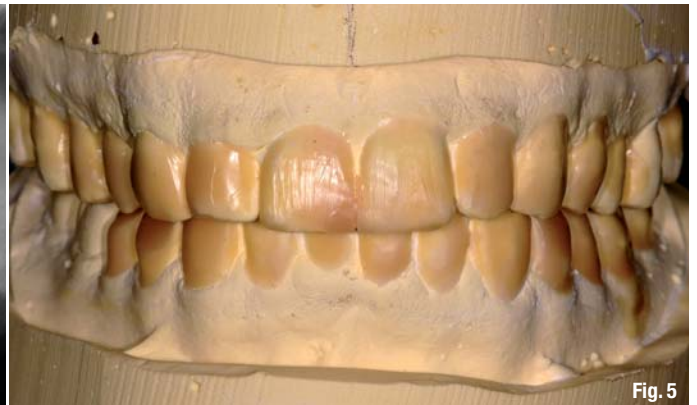

Fig. 5

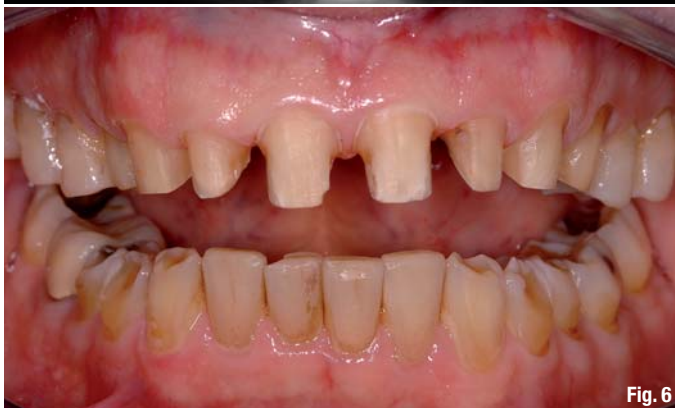

Fig. 6

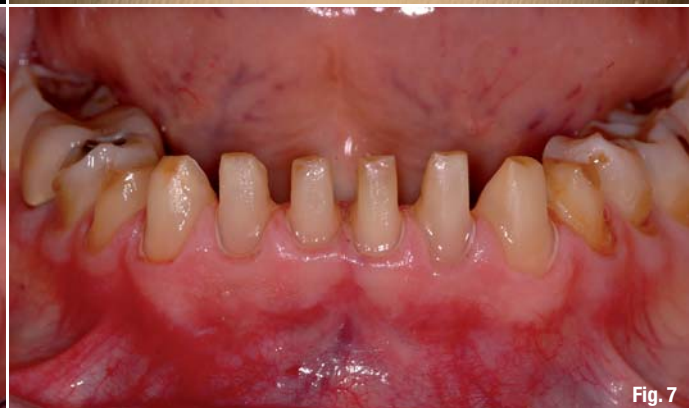

Fig. 7

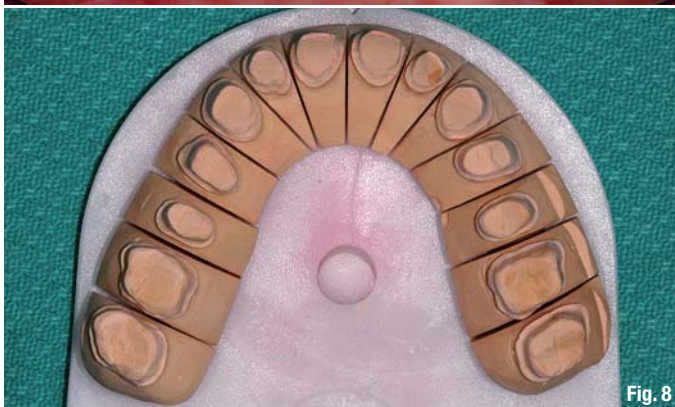

Fig. 8



Fig. 9

As teeth are worn down, the alveolar bone may undergo an adaptive process that may compensate for the loss of tooth structure.⁵ The VDO should be carefully assessed before the initiation of restorative procedures.

Traditional porcelain-fused-to-metal anterior crown restorations require the placement of labial crown margins below the free gingival margin, in order to mask the hue and value transition between the root surface and porcelain-fused-to-metal restoration. However, intra-crevicular placement of crown margins is technique-sensitive and related to adverse periodontal tissue response.⁶⁻⁹ From a periodontal point of view, preparation margins are best kept away from the free gingival margin.^{8,9}

The dentition, masticatory muscles and temporomandibular joints form a Class 3 lever system.

In such a lever system, functional load is inversely proportional to the length of the lever arm. Anterior teeth are under a reduced functional load in comparison with posterior teeth. Porcelain-fused-to-metal restorations are commonly used in the posterior teeth because of their well-documented long-term clinical track record in anterior and posterior teeth.¹⁰⁻¹⁷ Newer zirconium-oxide-based materials are usually prescribed in the anterior region owing to their demonstrated promising physical properties^{18,19} and reasonable clinical longevity.²⁰ In vitro studies also show that the wear of metal occlusal surfaces against porcelain occlusal material is acceptable when there are no bruxing activities.²¹

This article describes the prosthodontic management of a mutilated dentition using high-strength zirconium-oxide crowns.

Fig. 4 Panoramic radiograph showing adequate alveolar support.

Fig. 5 Anterior view of the full maxillary and mandibular diagnostic wax-up.

Fig. 6 Completed maxillary anterior teeth preparations for full coverage restorations. Note the equi-gingival preparation margins.

Fig. 7 Completed mandibular anterior teeth preparations for full coverage restorations. Less than 1.5 mm of tooth structure was removed at the cervical third, owing to smaller tooth size.

Fig. 8 Definitive maxillary cast. No die-spacer was required in the CAD/CAM manufacturing process.



Fig. 10

Fig. 9 Definitive mandibular cast

Tooth reduction was generally more conservative when compared with conventional porcelain-fused-to-metal restorations.

Fig. 10 Coping milling machine Zeno 4030 M1 (Wieland).

Clinical report

A 63-year-old fully dentate male patient presented with discoloured teeth and multiple areas of loss of tooth structure. The patient desired the restoration of function and aesthetics. He presented clinically with defective restorations, insignificant loss of VDO and compromised aesthetics (Figs. 1–3). There were signs of loss of enamel at the occlusal and labial surfaces of most of the teeth. The pre-treatment radiograph was within normal limits (Fig. 4). In spite of the overall condition, the natural teeth were free of active dental caries and oral hygiene was good. An occlusal examination revealed a stable maximal inter-cuspation position with insignificant centric relation to maximal inter-cuspation slide at the teeth level. No para-functional habit was reported.

A diagnostic dental wax-up on mounted maxillary and mandibular casts in a semi-adjustable articulator was performed (Hanau Wide-vue, Teledyne Waterpik; Fig. 5). The proportions of the anterior teeth were corrected to the estimated 0.618 width-to-height ratio of central incisors using the golden proportion^{22–25} as a guideline. The results indicated that no increase of VDO was needed at the incisal pin level in order to restore proper incisal anatomy and anterior guidance. The overall treatment plan included placement of fixed, high-strength zirconium-oxide base restorations in the maxilla and mandible.

The maxillary and mandibular teeth were prepared in the usual manner for complete coverage crown restorations (Figs. 6 & 7). The margins of the tooth preparations were prepared at the gingival level under magnification, and no gingival displacement procedures on the prepared teeth were necessary prior to definitive impression making. High-viscosity vinyl polysiloxane material (Aquasil Ultra Heavy,

DENTSPLY DeTrey) was carefully injected onto all tooth preparations, ensuring that all teeth surfaces including the margins were recorded. A stock tray loaded with putty material (Aquasil Putty, DENTSPLY DeTrey) was seated over the entire dental arch to make the definitive impression. A jaw relation record was made with a vinyl polysiloxane material (Regisil PB, DENTSPLY DeTrey). The maxillary and mandibular definitive casts were mounted in the centre of the articulator using standard settings.^{26,27} Provisional crown restorations (Luxatemp Automix, Zenith/DMG) were placed on the prepared teeth at the established VDO.

The development of the planned definitive crown restorations was carried out using CAD/CAM. The maxillary and mandibular definitive casts (Figs. 8 & 9) were scanned (Zeno Scan, Wieland) and the crown copings were designed using a software programme (3Shape D700). The copings were milled in zirconium base material (ZENO ZrBridge, Wieland) with a milling machine (ZENO 4030 M1, Wieland; Fig. 10). The copings were sintered according to the manufacturer's recommendations. Subsequently, overlaying low-fusing porcelain material (IPS e.max, Ivoclar Vivadent) was manually applied onto the exterior to create proper anatomic form. All maxillary and mandibular anterior teeth were fabricated using the same process. The completed restorations were cemented in resin-modified glass-ionomer luting agent (RelyX Unicem, ESPE; Figs. 11–12 & 15).

The patient was evaluated post-operatively. Anterior guided occlusal schemes were verified intra-orally before and after prosthesis cementation (Figs. 13 & 14). The patient reported no discomfort and adapted well to the new restorations. No abnormal clinical signs were noted.

Discussion

The maintenance and re-establishment of the VDO is a crucial element in full mouth fixed prosthodontic rehabilitation. It was necessary to make impressions that registered all teeth preparations at once.

As the patient desired a high level of aesthetics, full ceramic restorations were chosen for all restorations. The minimum core thickness for this full ceramic system is 0.4 mm, this enabled conservation of tooth structure and achievement of reasonable aesthetics simultaneously.

By prescribing full ceramic restorations, intra-sulcular placement of crown margins on the labial surfaces become less important from an aesthetic point of view. In this report, the teeth were essentially caries free, teeth preparation margins were made at

_contact **cosmetic**
dentistry

Dr Ansgar C. Cheng
Specialist Dental Group™
3 Mount Elizabeth #08-10
Singapore 228510
Republic of Singapore

E-mail:
drcheng@specialistdentalgroup.com

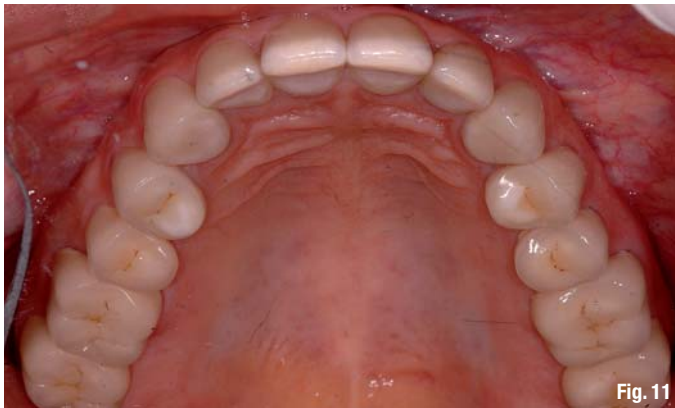

Fig. 11

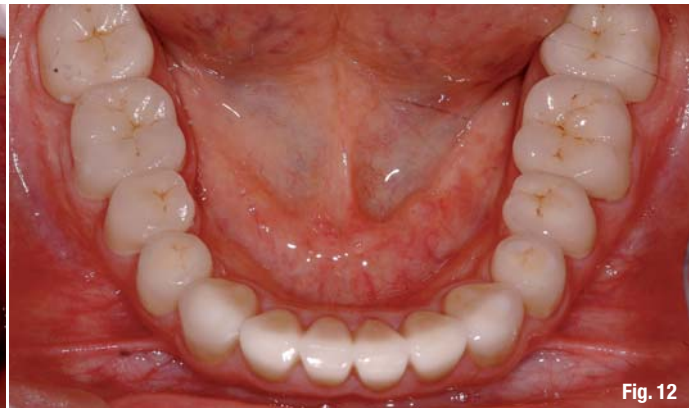

Fig. 12

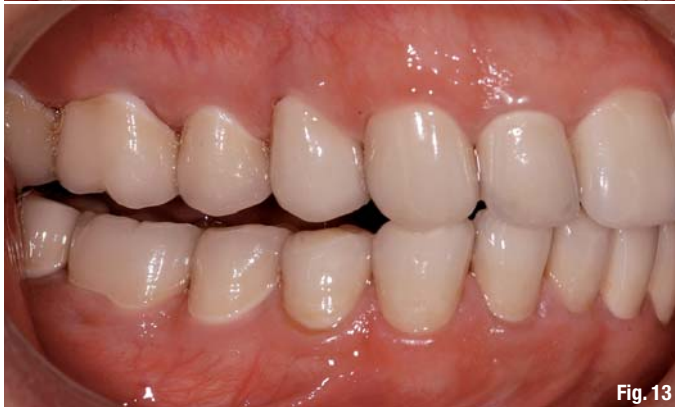

Fig. 13

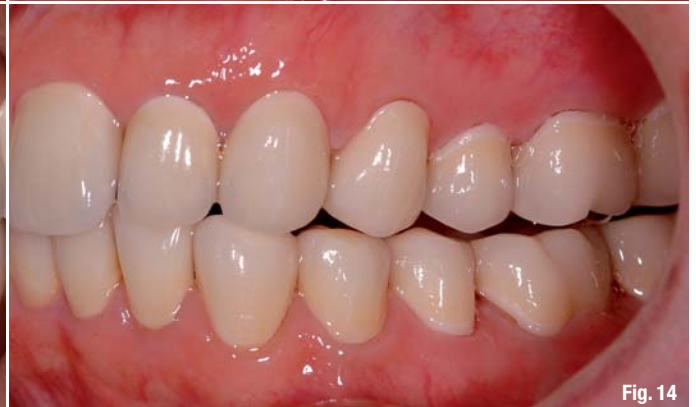

Fig. 14

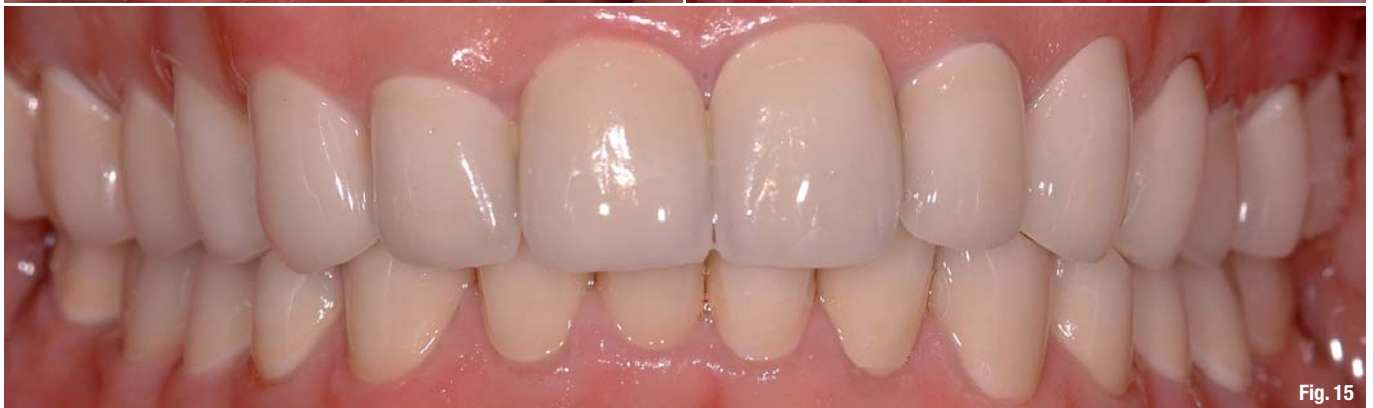

Fig. 15

gingival level and gingival retraction procedures were eliminated. As gingival retraction cord placement was not required, there was less physical trauma to the gingival tissues and less clinical time was needed. This is particularly beneficial for thin gingival biotypes.

Full mouth rehabilitation using fixed prostheses usually requires longer-term provisional restoration in order to facilitate a predictable treatment outcome. In this patient, owing to his busy travel schedule, long-term provisional restoration for verifying his adaptability and multiple professional clinical adjustments of provisional restorations were not feasible. The anterior teeth were restored based on the diagnostic wax-up without long-term provisional restoration before definitive cementation of the definitive crown restorations. This treatment sequence left almost no room for clinical errors in the execution of the planned treatment.

Intra-oral verification of the new occlusal scheme and detailed in situ clinical adjustment of the restorations on the day of prostheses insertion are essential for proper treatment execution. In this unique treatment approach, the patient should be informed of the potential financial and time implications should any need for re-fabrication of the definitive restorations arise.

_Conclusion

The functional management of complex prosthodontic rehabilitation is a clinical challenge. A relatively new restorative material was used in this case. The use of high-strength full ceramic restorations enhances the overall aesthetic outcome and functional predictability over the long-term.

Editorial note: A complete list of references is available from the publisher.

Fig. 11_ Occlusal view of completed definitive maxillary full ceramic crown restorations.

Fig. 12_ Occlusal view of completed definitive mandibular full ceramic crown restorations.

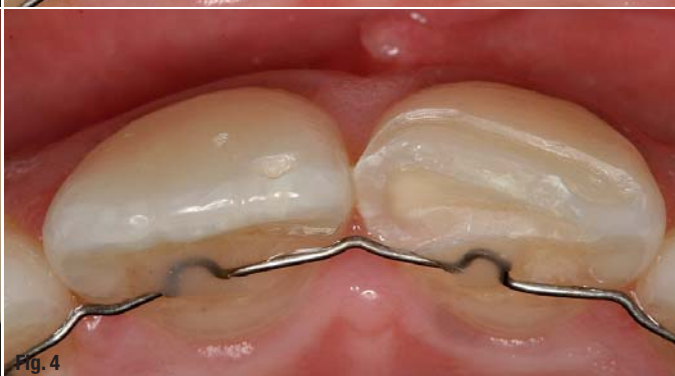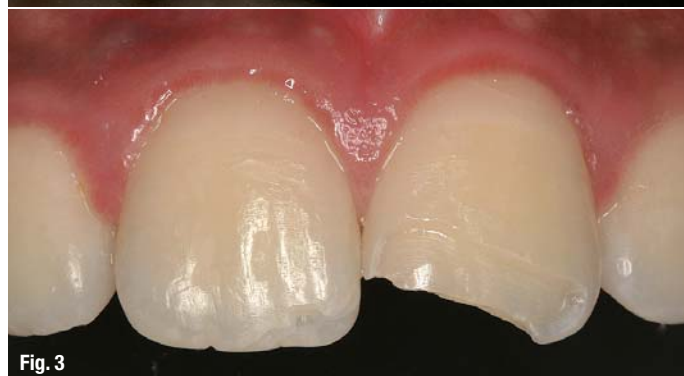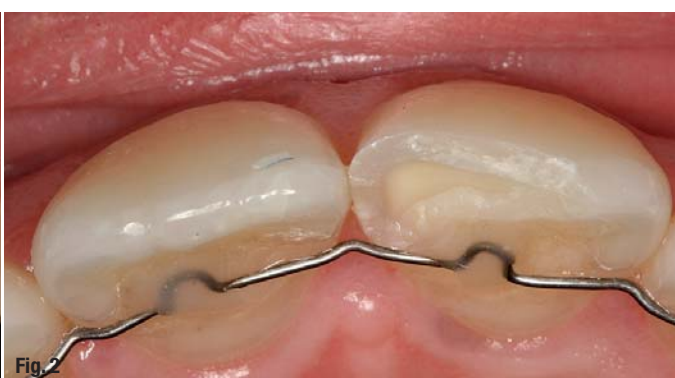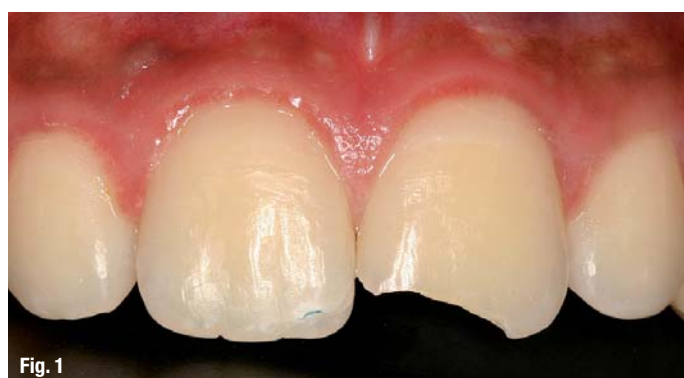Fig. 13_ Side view at right latero-trusion, canine-guided occlusion.

Fig. 14_ Side view at left latero-trusion, posterior teeth were out of occlusion during eccentric movement.

Fig. 15_ Anterior view of the completed maxillary and mandibular crown restorations. The crown margins were placed at the gingival margin with no sub-gingival extension.

Anatomic stratification technique for lifelike anterior composites

Authors_Dr Ratnadeep Patil & Dr Kavita Mahesh, India



_Introduction

_Direct composite resin restoration is a viable treatment option for an aesthetic restoration with minimal tooth reduction, especially in the case of uncomplicated tooth fractures.^{1,2} Such fractures are quite common amongst children and teenagers and may cause aesthetic and psychosocial problems.³

In the past, the outcome of direct resin restorations was compromised as they reproduced the optical properties of natural teeth poorly. Recent advances in adhesive technology and material properties, as well as improved understanding of the optical properties of the natural tooth, have helped

achieve improved vitality and depth of a restoration. The direct resin build-up of a Class IV restoration based on a contemporary layering technique allows clinicians to provide conservative treatment and a virtually imperceptible blend with adjacent tooth structures.⁴

_Case report

A 19-year-old male patient presented with a fractured upper-left central incisor and a chipped upper-right central incisor from a sports injury (Fig. 1). Radiographic examination and the cold test did not reveal any pulpal damage. After discussing various treatment options with the patient, conserva-

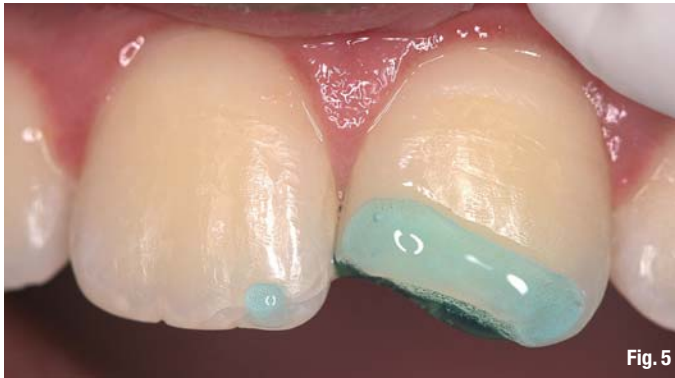

Fig. 5

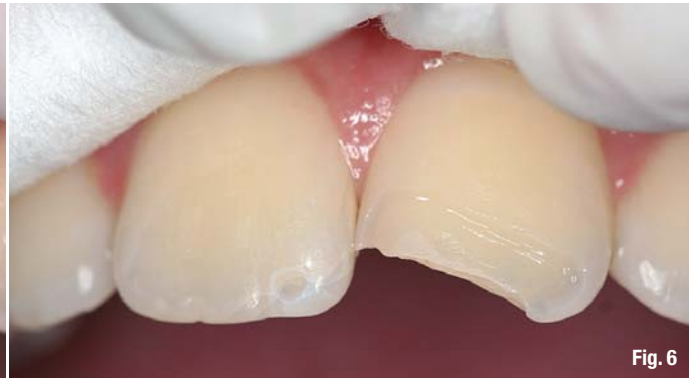

Fig. 6

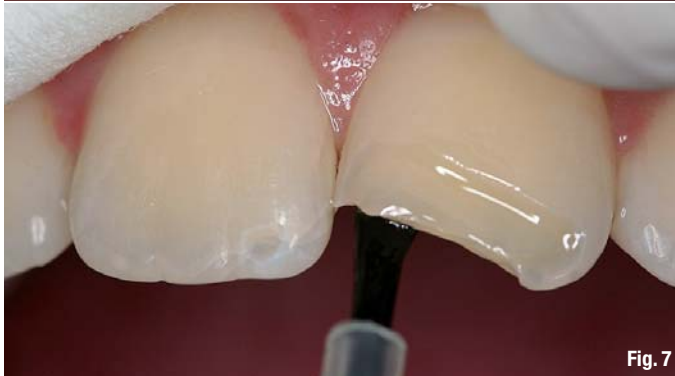

Fig. 7

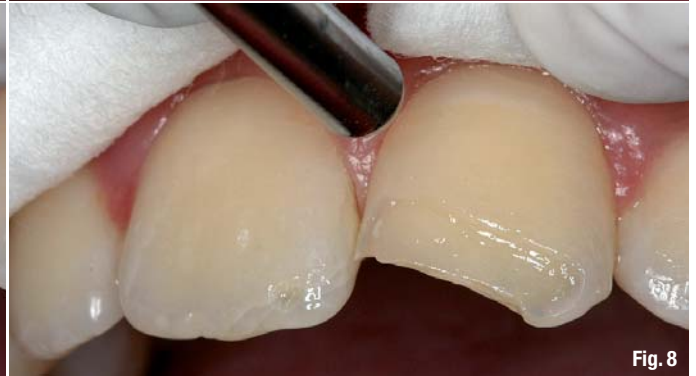


Fig. 8

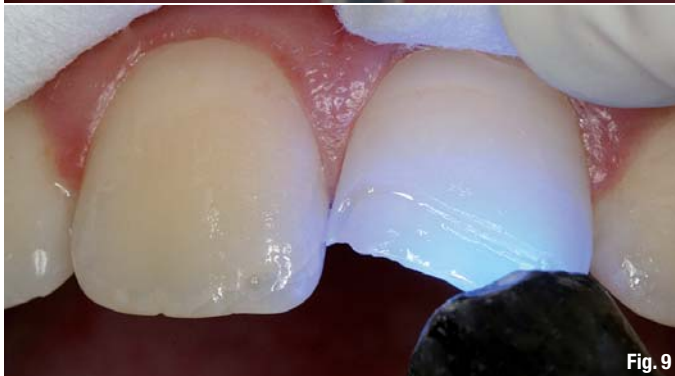

Fig. 9

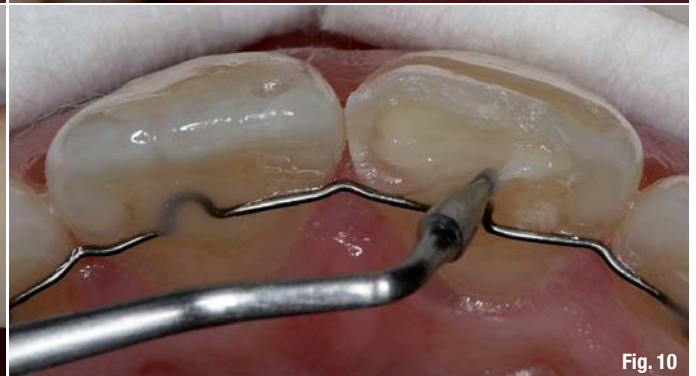

Fig. 10

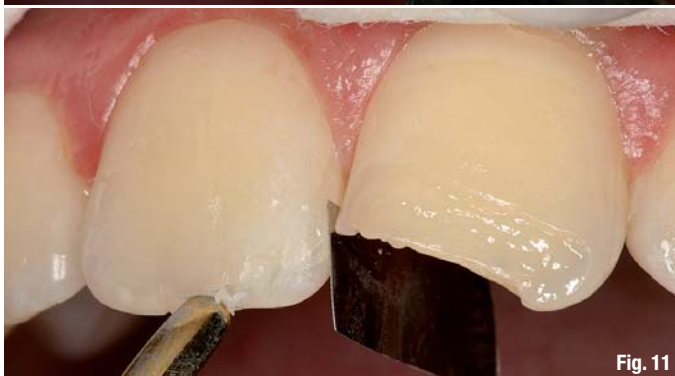

Fig. 11

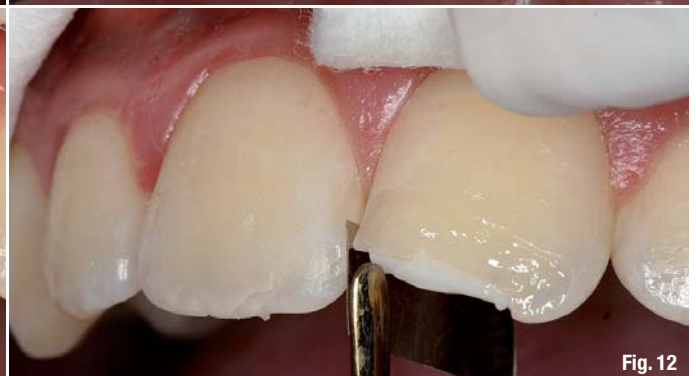

Fig. 12

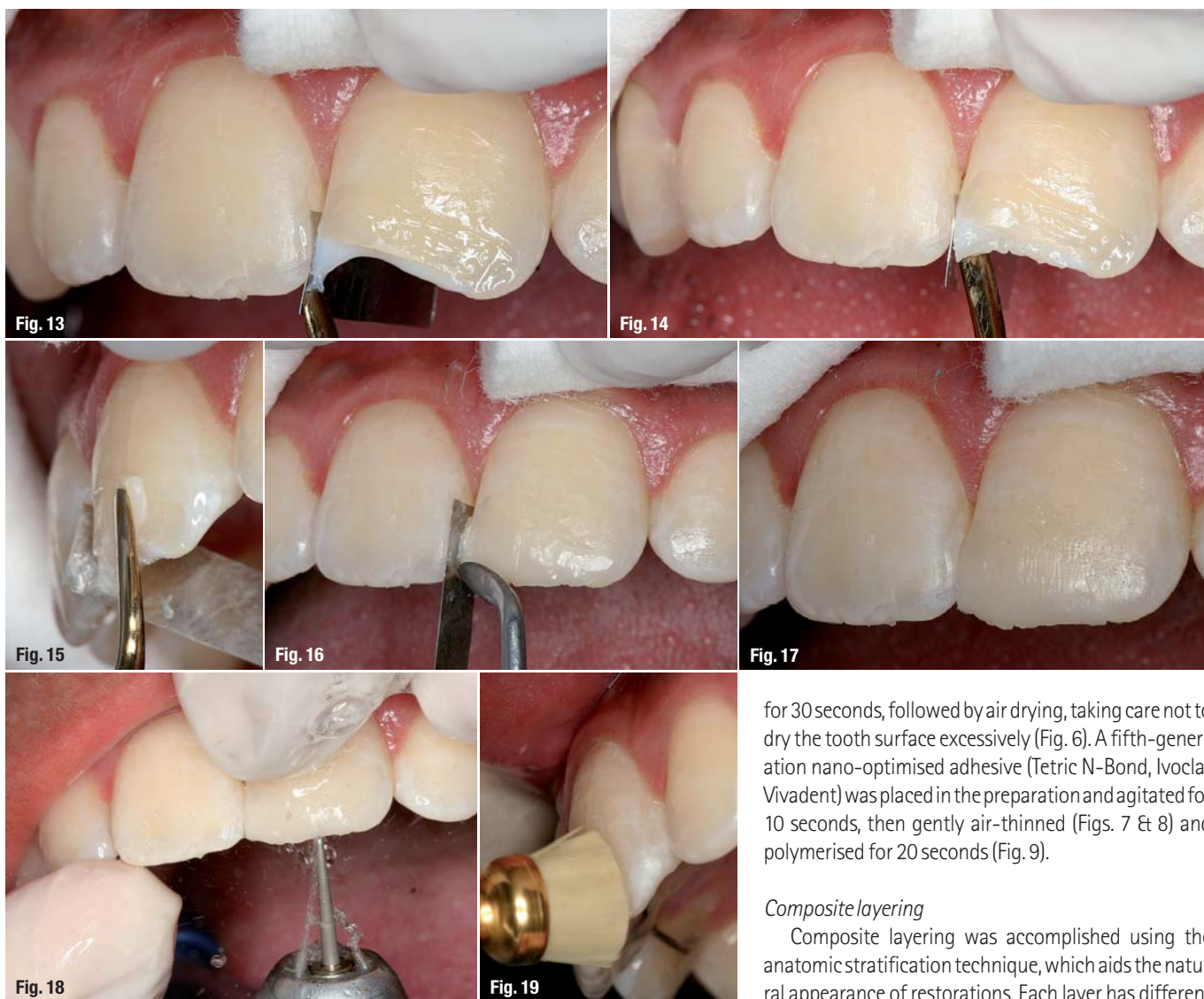
tive restoration using direct composite resin was selected.

Shade selection

The tooth shade was analysed before tooth preparation and thereafter evaluated for each layer of composite. Shade selection involves the dentist visually comparing the natural teeth shade to standard dental shade guides.⁸ Such selection does not ensure that the same-shade composite will yield the desired outcome, as the

inherent opacity and layer thickness will determine shade outcome. Shade matching, on the contrary, is a highly technical process, but also with an unpredictable outcome because it depends on individual skill and knowledge.⁸ Shade matching has to be an integral part of the layering technique.

Using the Tetric N-Ceram shade guide system (Ivoclar Vivadent), the shade was determined to be A3, with a high incisal edge translucency and an orange-red



final effect. Occlusal view of the fractured teeth reveals the difference in opacity and translucency of dentine and enamel in tooth 21 (Fig. 2). Dentine is an opaque and fluorescent tissue that determines the tooth's hue and chroma by reflecting light through the enamel. Enamel is a translucent and opalescent tissue that determines the tooth's value.^{3,6} As the patient is young, the incisal mamelons were intact (Fig. 1).

Preparation design

A 1 mm bevel was placed along the margin of the chipped enamel surface of tooth 11 (Fig. 3). An envelope preparation design extending 2 mm with a 1 mm bevel was prepared on the buccal surface of tooth 21 (Figs. 3 & 4). On the palatal surface of tooth 21, a rounded butt margin was prepared (Fig. 4).

The cavity preparation was disinfected using a 2% chlorhexidine antibacterial solution. Etching was done for 15 seconds using 37% phosphoric acid (Fig. 5). Thereafter, the etchant (Total Etch, Ivoclar Vivadent) was removed and the tooth surface rinsed with water spray

for 30 seconds, followed by air drying, taking care not to dry the tooth surface excessively (Fig. 6). A fifth-generation nano-optimised adhesive (Tetric N-Bond, Ivoclar Vivadent) was placed in the preparation and agitated for 10 seconds, then gently air-thinned (Figs. 7 & 8) and polymerised for 20 seconds (Fig. 9).

Composite layering

Composite layering was accomplished using the anatomic stratification technique, which aids the natural appearance of restorations. Each layer has different shades and opacities when stratified, giving a polychromatic effect with a more realistic depth of colour by creating an illusion of the way light is reflected, refracted, transmitted and absorbed, to simulate that of dentine and enamel. This is crucial to overcome the disadvantage of 'shine through' (silhouette of the fractured area is highlighted by the darkness of the oral cavity) of traditional single- or two-layer techniques.⁶

Current composite resin systems use dentine materials that reproduce the fluorescence of natural dentine and enamel materials that mimic the opalescence and translucence of natural enamel.⁴

Although there is no exact formula for stratification with such results, as shade layering varies from case to case, the general rules are:

1. Replace palatal/lingual wall with an opaque composite. As they have higher colour saturation, when light strikes the optically dense layer more light is reflected back to the eyes, which contributes to the hue and chroma by optically replacing dentine.^{6,7}

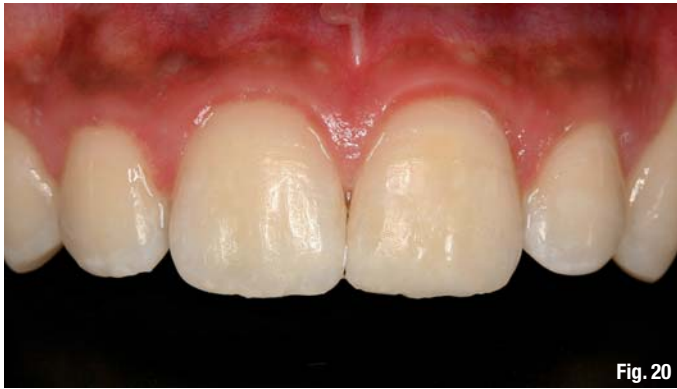

Fig. 20

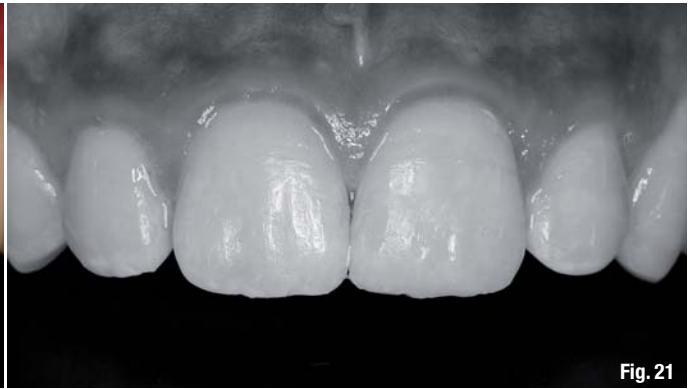

Fig. 21

2. Use thin increments and observe shade after curing each layer, so that the shade of the next layer can be planned. An advantage of this technique is that it minimises the negative effects of shrinkage by creating small incremental shrinkage.⁵
3. Use translucent composites to encapsulate the dentine core. This alters the quantity and quality of the light reflected and thus determines the value of the restoration by optically replacing enamel in the restoration.^{6,7}
4. Finish and polish to replicate natural tooth textures.

In this case, a nano-composite resin (Tetric N-Ceram) was selected as the material of choice for restoring these teeth. Stratification was initiated with a thin layer of flowable resin (Tetric N-Flow, Ivoclar Vivadent; Fig. 10) and thereafter 1 mm of Bleach light shade (Tetric N-Ceram) was placed and cured to replicate the opaque dentine layer (Fig. 11). A metal matrix strip was placed interdentally and a triangular, mesio-incisal layer of the A2 and A3 dentine shades (Tetric N-Ceram) was placed and sculpted to reconstruct the proximal surface (Figs. 12 & 13).

Next, increments of A3 enamel shade (Tetric N-Ceram) were layered (Figs. 14–16) with a long-bladed instrument and texture lines created with a sable brush before curing (Fig. 17). The mamelon effect was completed using the highly translucent Incisal shade (Tetric N-Ceram) at the inciso-lingual matrix, and two notches were placed to duplicate the external contours of the mamelons. The last increment was done using a thin layer of Translucent Opal Shade (Empress Direct Composite, Ivoclar Vivadent).

Finishing and polishing

Finishing focuses on contouring, adjusting, shaping, texturing and smoothing the restoration (Fig. 18), while polishing concentrates on producing a surface lustre (Fig. 19) and highly reflective surface.⁶ For creating texture in finishing, various areas on the buccal surface of the tooth were highly polished to give a lifelike effect to the restoration.^{1,2} Eminence of the proximal convexity, the horizontal and vertical ridges, the lobe effect and facial flattening were effectively projected. The black

and white image of the finished restoration shows that the value of the tooth and restoration is similar (Figs. 20 & 21).

_ Conclusion

The success of the anatomic stratification technique lies largely in the fact that it draws inspiration from the natural layering of dentine and enamel. Continuous technological advances have provided us with materials that can successfully replicate tooth characteristics and retain the characteristics built into them through layering them on tooth surfaces. With this technique, it is possible for clinicians to provide more conservative, yet functional and aesthetic, treatment to their patients.

Editorial note: A complete list of references is available from the publisher.

_ author info

cosmetic
dentistry



Dr Ratnadeep Patil has maintained a successful private practice specialising in aesthetic and implant dentistry in Mumbai since 1988. He is a diplomate of the International College of Oral Implantologists and an active member of the International Association for Dental Research. He has authored a clinical textbook on aesthetic dentistry (*Esthetic Dentistry: An Artist's Science*) and been actively involved in conducting continuing dental education programmes.



Dr Kavita Mahesh has been in clinical practice since she graduated from the Government Dental College and Hospital in Mumbai in 2002. Since 2003, she has been a member of the team at Smile Care in clinics and been involved in continuing dental education programmes and clinical research. She completed her Post-Graduate Certificate in Implant Dentistry at New York University in 2005.

Smile Care

13, Geetanjali, 234, S. V. Road
Bandra (West), Mumbai – 400 050
India

Tel.: +91 22 2643 1670/71
E-mail: smilecarepublication@gmail.com
www.smilecareindia.com

Smile Design Wheel™:

A practical approach to smile design

Author_ Dr Sushil Koirala, Nepal

_Modern trends in cosmetic dentistry and media coverage of smile makeovers have increased public awareness of dental aesthetics.

People now know that smile aesthetics plays a key role in their sense of well-being, social acceptance, success at work and in relationships, and self-confidence. The aesthetic expectations and demands of dental patients have increased substantially. Now, a glowing, healthy and vibrant smile is no longer available only to millionaires and movie stars. Therefore, many dentists are incorporating various smile design protocols in their daily practices to meet the increasing aesthetic demands of their patients.

different and particular to each individual.³ An impaired smile on the other hand, has been associated with higher incidences of depression.⁴

Aesthetics deals with objective and subjective beauty.⁵ Objective beauty is based on the appreciable properties possessed by the object itself. However, subjective beauty is relative to the perception and emotion of the observing person. Perception, however, in smile aesthetics is based on personal beliefs, cultural influences, aesthetic trends and fashion, and input from the media. Hence, smile aesthetics is a multifactorial issue, which needs to be adequately addressed for any aesthetic treatment. The objective beauty of a smile can be established with the application of various principles of smile design, and the creation of subjective beauty may enhance cosmetic value.^{5,6}

_Smile design

Smile design has been defined in various ways in the literature; I would like to summarise it as follows: "Smile design is a systematic process governed by the psychology, health, function and rules of natural aesthetics to bring about some changes in soft- and hard-oral tissue within anatomical, physiological and psychological limitations, thereby creating a positive influence on the overall aesthetics of a person's face and personality as a whole".⁷

We all appreciate a beautiful smile when we see it, but it is difficult to explain exactly what makes a smile beautiful. It is evident that a pleasing smile depends on the following features: the

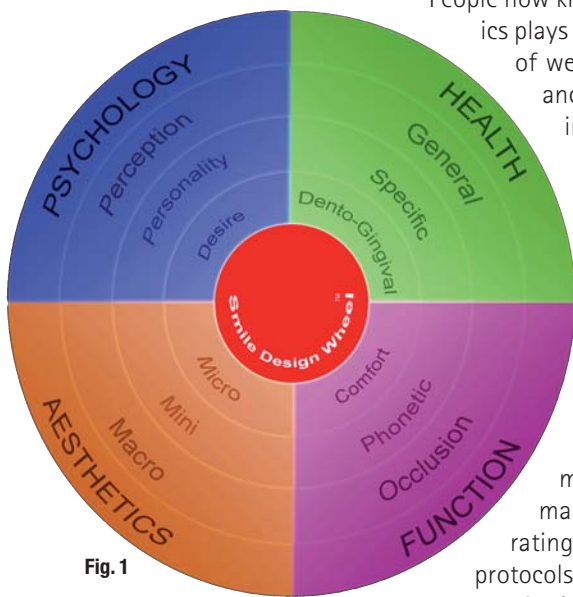


Fig. 1

_Smile aesthetics

A smile is a facial expression that is closely related to the emotions and psychological state of a person. A smile is exhibited when a person expresses happiness, pleasure or amusement.¹ It is the most important of facial expressions and is essential in expressing friendliness, agreement and appreciation.² A smile requires the coordination of facial, gingival and dental components that are stimulated voluntarily or involuntarily by various emotions. It is evident that each smile is

quality of the dental and gingival components, their conformity to the rules of structural beauty, the relationship between teeth and lips, and their harmonious integration with the facial components.⁸ Overall facial beauty and smile aesthetics are normally judged by psychological aspects—perception, personality, desire—the state of health, the mathematical ratio of the facial, dento-facial and dento-gingival components. The psychological aspects are highly subjective and fluctuate constantly because of identity, peer and media pressure. Hence, the only objective method of aesthetic analysis is mathematical.

Indeed, mathematics has been considered the only frame of reference for comprehending nature.⁸ Therefore, the cosmetic dentist needs to be familiar with various mathematical and geometric concepts for achieving smile aesthetics and their clinical protocols.

—The Smile Design Wheel

For any smile design procedure, the clinician needs to consider the elements of the smile design pyramids—psychology, health, function and aesthetics (PHFA), listed here according to order of importance.⁷ It is necessary to determine the patient's psychological status, establish a healthy oral environment, restore function and then give attention to enhancing the aesthetic aspect. All four pyramids should be accorded equal importance to achieve a desirable clinical result.

By integrating these PHFA pyramids, I developed the Smile Design Wheel (Fig. 1), in which each pyramid is subdivided into three related zones. The Smile Design Wheel was devised as a simple guide to the most important components of smile design, their clinical significance and sequence to be maintained during the smile design procedure. I believe that the Smile Design Wheel will help clinicians to easily comprehend the 'complex' smile design procedures of aesthetic dentistry. In the next section, I briefly explain the Smile Design Wheel protocols with PHFH pyramids assessment and their basic objectives.

—Step I: Understand— The pyramid of psychology

According to Prof. Robert A. Baron, psychology is best defined as the science of behaviour and cognitive processes. Behaviour deals with any action or reaction of a living organism that can be observed or measured. Cognitive processes deal with every

aspect of our mental life: our thoughts, memories, mental images, reasoning, decision-making, and so on, in short, with all aspects of the human mind.

In smile design, we normally try to understand the second part of psychology, i.e. the human mind or rather the minds of our patients. There are three fundamental zones we consider in detail for the psychological pyramid assessment: perception, personality and desire.

Perception

Perception is the process through which a person can select, organise and interpret input from their sensory receptors. A person cannot imagine beauty and aesthetics without some input in advance. The media is the most common source of information at present regarding beauty and aesthetics. A patient usually conceives his or her own perception of smile aesthetics based on his or her own personal beliefs, cultural influences, aesthetic trends within society and information from the media.

Dentists need to communicate with their patients to determine such information during the initial consultation, which helps in understanding the patient's perception of the treatment result. The use of questionnaires, visual aids, such as previous clinical cases or smiles of various celebrities, can aid immensely in this process.

Personality

According to the human psychology, personality is an individual's unique and relatively stable pattern of behaviour, thoughts and emotions. It is to be noted that each patient's problem or concern should be comprehensively evaluated with respect to his or her personality type. According to Roger P. Levin,⁹ there are four personality types:

— **Driven:** This type of person focuses on results, makes decisions quickly and dislikes small talk. They are highly organised, like details in condensed form, are businesslike and assertive.

— **Expressive:** This type of person wants to feel good, is highly emotional, makes decisions quickly, dislikes details or paperwork, and likes to have a good time.

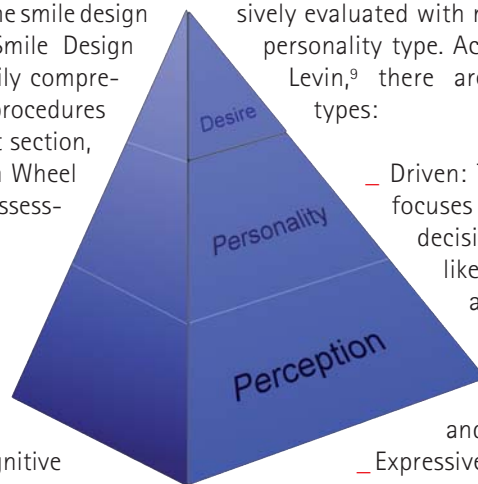


Fig. 2

- **Amiable:** People with this personality type are attracted by people with similar interests, fear consequences, are slow in decision-making, react poorly to pressure, are emotional and slow to change.
- **Analytical:** This type of person requires endless details and information, has an inquiring mind, is highly exacting and emotional. This type is the most difficult to convince and takes the longest to reach a decision.

Desire

Desire is a subjective component. Increased public awareness of smile aesthetics through the media has led to a rapid increase in patients' desires and levels of expectation. Patients are now willing to pay for the enhancement of their smile aesthetics. Therefore, the ethical responsibilities of cosmetic dentists in identifying the need- or want-based desires of patients have also increased. The desires and levels of expectation in many patients are higher than what is clinically achievable, and it is the clinician's duty to explain and guide patients towards a realistic aesthetic goal.

The psychological assessment of any person is very subjective; however, aspects like perception, personality, expectation or desire are important for the smile design procedure. Patient satisfaction is closely related to these aspects. Hence, understanding the pyramid of psychology is an integral aspect in smile design.

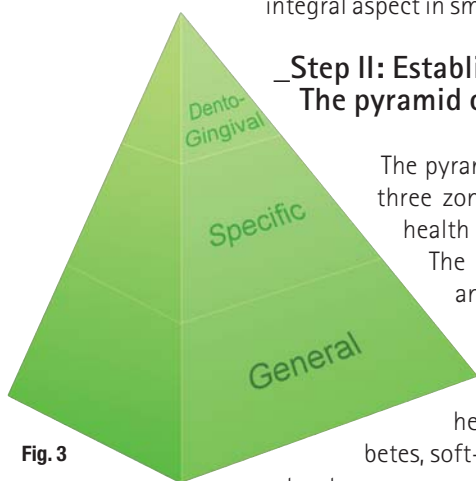


Fig. 3

**Step II: Establish—
The pyramid of health**

The pyramid of health is divided into three zones: general health, specific health and dento-gingival health. The health pyramid assessment and its management play a vital role in most cases, as patients may have certain limitations owing to their health, like uncontrolled diabetes, soft-tissue pathology, poor bone structure, poor oral hygiene, tooth decay, periodontal disease etc., which should be addressed prior to functional and aesthetic treatment.

The health pyramid assessment process includes patient history (medical, dental, nutritional), examinations (extra-oral, intra-oral) and investigations (radiographs, pulp vitality test, study models analysis). Various types of questionnaires and clinical examination and investi-

gation protocols can be used to obtain the necessary information relating to the patient's health. The clinician can use this information to prepare a personalised treatment protocol. All three components of the pyramid of health should be established within normal limits before starting any aesthetic restorative procedure on a patient.

**Step III: Restore—
The pyramid of function**

Function is related to force and movement. Hence, for the pyramid of function assessment, the existing occlusion, comfort and phonetics are properly examined with the evaluation of para-functional habits, level of comfort during chewing and deglutition, and temporomandibular joint movement.

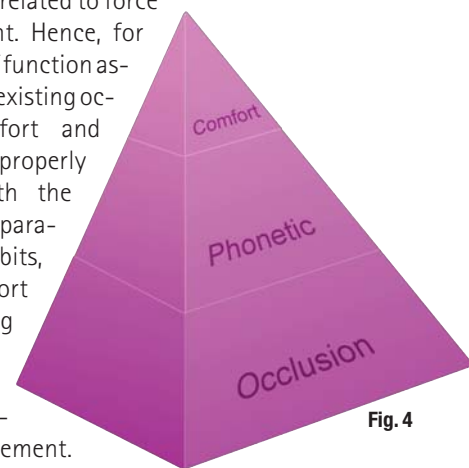


Fig. 4

The clarity of normal speech and pronunciation are also examined. The occlusion, comfort and phonetics components of the functional pyramid should be restored and maintained at an acceptable level before starting the treatment of any aesthetic component.

**Step IV: Enhance—
The pyramid of aesthetics**

The pyramid of aesthetics is the last but most sensitive pyramid of the Smile Design Wheel, as aesthetics has both subjective and objective aspects. The assessment of the subjective aspects—perception, personality, desire—is carried out during the pyramid of psychology assessment.

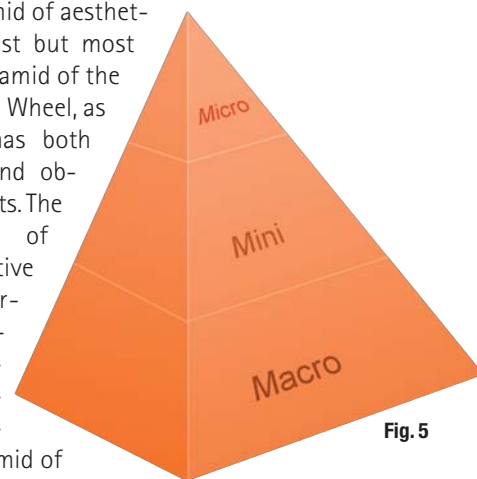
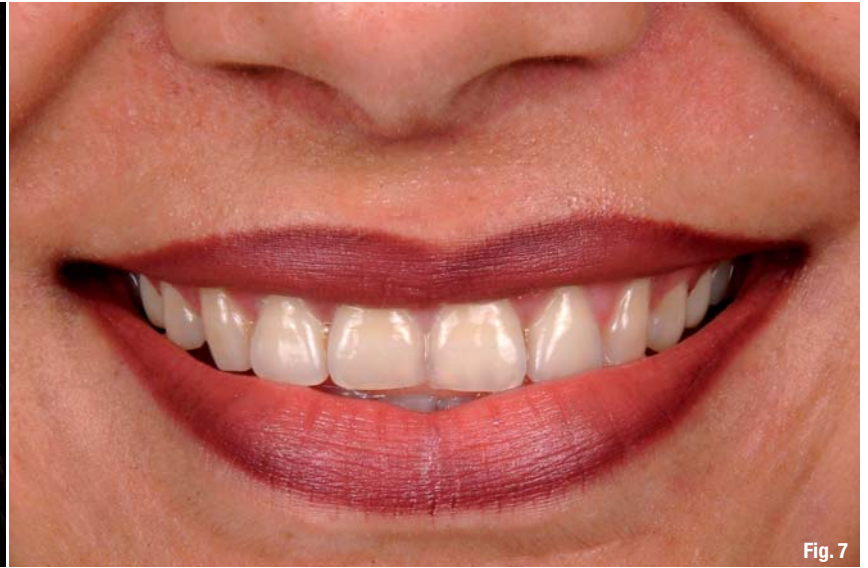

Fig. 5

It is to be noted that the assessment of the objective aspects depends on the distance (focal length) used to visualise the aesthetic component. Hence, the aesthetics pyramid can broadly be divided into three major zones: macro, mini and micro.



Macro-aesthetics

Macro-aesthetics deals with the overall structure of the face and its relation to the smile (Fig. 6). To appreciate the macro-aesthetic components of any smile, the visual macro-aesthetic distance should be more than 5 feet. However, in clinical practice the assessment of the macro-aesthetic components is done using various facial photographs with geometric and mathematical appraisals, using reference points and their interrelation. Various facial reference points and guidelines are used for aesthetic assessment for orthognathic and facial cosmetic surgery; however, in smile design the following macro-aesthetic guidelines are considered fundamental:

- _ facial midline;
- _ facial thirds;
- _ interpupillary line;
- _ naso-labial angle; and
- _ Rickett's E-plane.

Mini-aesthetics

Mini-aesthetics deals with the aesthetic correlation of the lips, teeth and gums at rest and in smile position (Fig. 7). The aesthetic correlation can be appreciated properly when viewed at a closer distance than the visual macro-aesthetics distance.

The visual mini-aesthetics distance is similar to the across-the-table distance, which is normally within 2 to 5 feet. There are various guidelines in aesthetics based on the relationship and ratio between lips, teeth and gingival tissue. These can be analysed during mini-aesthetic assessment using frontal, vertical and transverse char-

acteristics of the smile. Clinical photographs are the basic tools for mini-aesthetic analysis. The smile can be analysed at rest (M-position) or smile (E-position).

In the M-position, the following references are measured and analysed:

- _ commissure height;
- _ philtrum height; and
- _ visibility of the maxillary incisors.

In E-position the following references should be analysed:

- _ smile arc (line);
- _ dental midline;
- _ smile symmetry;
- _ buccal corridor;
- _ display zone and teeth visibility;
- _ smile index; and
- _ lip line.

Micro-aesthetics

Micro-aesthetics deals with the fine structure of dental and gingival aesthetics (Fig. 8). Mini-aesthetics can be appreciated at a visual micro-aesthetic distance of less than 2 feet or within normal make-up distance. For the clinical assessment of micro-aesthetic components of the teeth and gingival tissue, appropriate illumination and magnification tools are required for intra-oral examination. Necessary clinical intra-oral photographs should be taken for documentation and future reference.

For micro-aesthetics, the detail of the individual tooth structure and its relation to the sur-

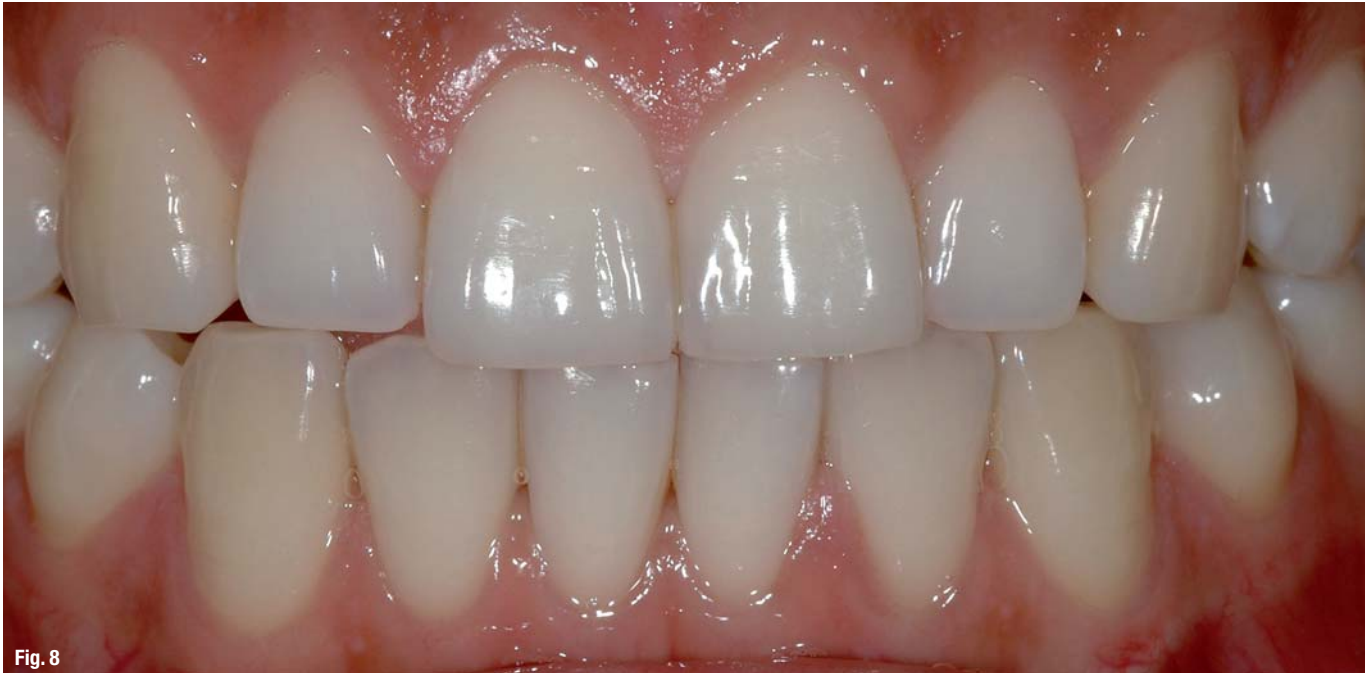

Fig. 8

rounding gingiva and the adjacent teeth should be analysed. The following are the major points to be considered:

- _ upper centrals (tooth size ratio);
- _ principle of golden ratio;
- _ axial inclination;
- _ incisal embrasures;
- _ contact point progression;
- _ connector progression;
- _ shade progression; and
- _ surface micro-texture.

In smile design, the aesthetic conditions related to gingival health and appearance are an essential component. The gingival shape, position, embrasure, and contour in relation to the teeth are interdependent. The following are major aspects that should be addressed during smile design to achieve gingival or pink aesthetics:

- _ gingival shape;
- _ gingival contour;
- _ gingival embrasure;
- _ gingival zenith; and
- _ gingival height (position or level).

To achieve higher patient satisfaction and long-lasting treatment results, the following should be the sequence in any smile design procedure: proper comprehension of psychological aspects, the establishment of health and the restoration of function within its normal limit, and the subsequent enhancement of aesthetic components.

_Conclusion

Today, various protocols of smile design are available in cosmetic dentistry. However, most clinicians wish to use the simplest protocol with the most predictable results. It is to be noted that smile design should always be a multifactorial decision-making process that allows the clinician to treat patients with an individualised and interdisciplinary approach.

The Smile Design Wheel presented in this article clearly indicates the most important components (PHFA pyramids) of smile design, their clinical significance and sequence to be maintained during the smile design procedure. I believe that the Smile Design Wheel is a simple and practical protocol in smile design that can help the clinician to easily comprehend the 'complex' smile design procedures of aesthetic dentistry.

Editorial note: A complete list of references is available from the publisher.

_contact	cosmetic dentistry
 <p>Dr Sushil Koirala, VISA president, can be reached at skoirala@wlink.com.np.</p>	

e.max[®]
IPS

“e.max LITHIUM
DISILICATE IS THE
MOST ROBUST
CERAMIC SYSTEM
TESTED TO DATE.”*

This changes everything.

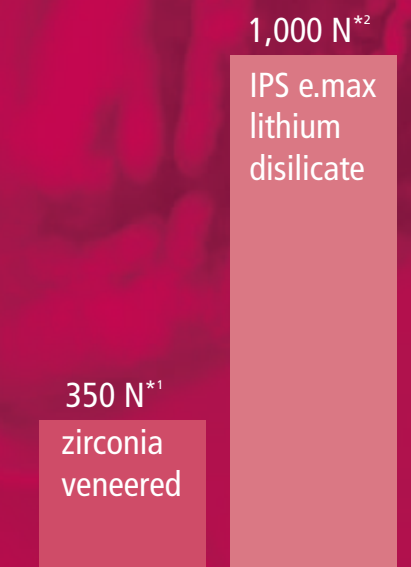
The durability of lithium disilicate glass-ceramic crowns is higher than that of veneered zirconium oxide. Lithium disilicate is therefore the material of choice for single crowns: strong, esthetic, economical. Try it yourself.

*Mouth Motion Fatigue and Durability Study

Petra C Guess, Ricardo Zavanelli, Nelson Silva and Van P Thompson,
New York University, March 2009

¹ 90% failure by 100,000 cycles

² No failures at 1 million cycles



all ceramic
all you need

www.ivoclarvivadent.com

Ivoclar Vivadent AG

Bendererstr. 2 | FL-9494 Schaan | Liechtenstein | Tel.: +423 / 235 35 35 | Fax: +423 / 235 33 60

Ivoclar Vivadent Marketing Ltd. (Liaison Office) India

503/504 Raheja Plaza | 15 B Shah Industrial Estate | Veera Desai Road, Andheri (West) | Mumbai 400 053 | India
Tel.: +91 (22) 2673 0302 | Fax: +91 (22) 2673 0301 | E-mail: info@ivoclarvivadent.firm.in

Ivoclar Vivadent Marketing Ltd. Singapore

171 Chin Swee Road | #02-01 San Centre | Singapore 169877 | Tel.: +65 6535 6775 | Fax: +65 6535 4991

ivoclar
vivadent[®]
passion vision innovation

Aesthetics and the brain

Author_ Dr David L. Hoexter, USA

_The age-old question as to what constitutes beauty has been subjected to yet another wrinkle. Research has been presented showing that left-sided brain people perceive beauty differently than right-sided ones. Beauty is and has been perceived through the ages through individual eyes. Perhaps different cultures encourage different zones of desire and contentment; also, people of different ages may have different views. Whatever the cause or conditioning, our visions encourage that beautiful zone. Is it due to our youth's environment, perhaps where our mother's left side of the brain influenced our concepts early, relating to beauty?

When I was presenting cosmetic periodontal techniques in Sicily, Italy, at a congress dedicated to aesthetics in dentistry, Dr DeLucca, an exquisite prosthodontist with exceptional aesthetic prosthetic results, brought up factors and questions regarding the effects of aesthetics from the right and left sides of the brain as well as the male/female dominance in their respective spheres.

The brain has been relegated to different functions on its left and right side in several factors. The right side is said to be more analytical, more detailed, as well as more scientific, mathematical, computeristic, logical and analytical. In general, the right side is usually related to males. The left side of the brain is, in general, attributed to the female gender. Its characteristics are said to be non-verbal, intentional, emotional, excellence in spacial relationships, and good colour perception.

In the past 20 plus years of dentistry, aesthetics has changed the face of the profession. This is not meant to be a pun but an actual fact. The desire by patients to electively choose to have dentistry is a huge leap from its image of yesteryear. Not relying on motivation from pain or trauma, patients are eagerly trying to improve their



appearance orally. A wonderful bright smile can light up the face and the public is now aware of this fact. At about the same time that cosmetic improvement was encouraged by our profession, the profile of the dental school population started to change. The number of female dental students became more predominant than ever before in the United States. Was this the left side of the brain making its mark?

The initiating pioneers in the dental aesthetic field, Drs Irwin Smigel and Ron Goldstein, forged awareness to the public as well as dentists, and encouraged the patient to request looking better orally. In turn, they encouraged the dentist to provide the services that stimulated dental companies to research and provide better aesthetically appearing, yet formidable, restorative materials. Did it take these pioneers the use of the right side of their brain to forge this field of aesthetics?

In other countries throughout the world, the number of female dental school graduates has been higher than males for years. In addition, 85 per cent is the common percentage of female dentists practicing in many such countries. In the US, that number hovers at about 50 per cent.

Does the right side of the brain dominate our field with the necessary precision that is demanded? Have the materials in dentistry today improved so much that there is compensation in techniques to allow the left side of the brain's activity to transcend and emit an aesthetic sensitivity for the patient's appearance? Can the individual dentist utilise the left and right side of his or her brain as noted in today's terminology by the expression 'crossover'?

Will the economic turmoil of today affect the demand by patients for cosmetic dentistry beyond the necessary health requirements? I know that for me to find the answer regarding the male/female, left and right brain relationships, I should smilingly have to ask my wife.

_author info

cosmetic
dentistry



Dr David L. Hoexter is director of the International Academy for Dental Facial Esthetics, an organization that combines physicians and dentists with other related fields in research and relates its finding to clinical practice. He lectures throughout the world and has published internationally. He has been awarded 11 fellowships including FACD, FICD and Pierre Fauchard. He maintains a practice in New York City, limited to periodontics, implantology and aesthetic surgery. He can be reached at dr-davidlh@aol.com.

Ceramic instead of composite

Author_ Manfred Kern, Germany

Fig. 1 Dr Otto and his team have worked with CEREC for 18 years.
(Photo: Manfred Kern)

_Dr Tobias Otto, a dentist in private practice in Aarau in Switzerland, witnessed the 'death' of amalgam as a student at the University of Zurich. The University was reacting in response to the prohibition of amalgam in Sweden. Composites and the adhesive technique were the new hopefuls

for treatment with fillings. The tooth-coloured restorations met the patients' aesthetic desires. Dr Otto learned how to perform this time-consuming procedure, which includes rubber dam, dentine adhesives, the composite layering technique and light polymerisation. He also saw how two- to four-surface composite restorations soon fractured under masticatory loading due to insufficient contact points and porosities, became discoloured and abraded after longer service, or needed replacement because of recurrent caries.

Inspired by natural aesthetics, patients no longer found cast gold fillings attractive. The new alternative, such as laboratory-manufactured ceramic inlays, taught Dr Otto that this restoration technique too failed to provide the hoped-for, long-term survival quality and was too expensive. He found that the fracture resistance of the delicate edges of pressed silicate ceramic inlays left much to be desired, as did the colour stability of the surfaces. Dr Otto dreamt of an industrially sintered, dense, stable ceramic. But how could this be milled?

While he studied hard for his licensing exams, the first CEREC machine, which could mill an inlay from an industrially produced ceramic blank, was being developed in the clinic one floor above his office. The protagonists of this method were confronted by many sceptics who denied the new system their support because of the adhesive joint between ceramic and enamel. However, Dr Otto recognised that here was a highly resilient silicate ceramic, whose flexural strength surpassed that of both composites and laboratory-layered sintered ceramics.

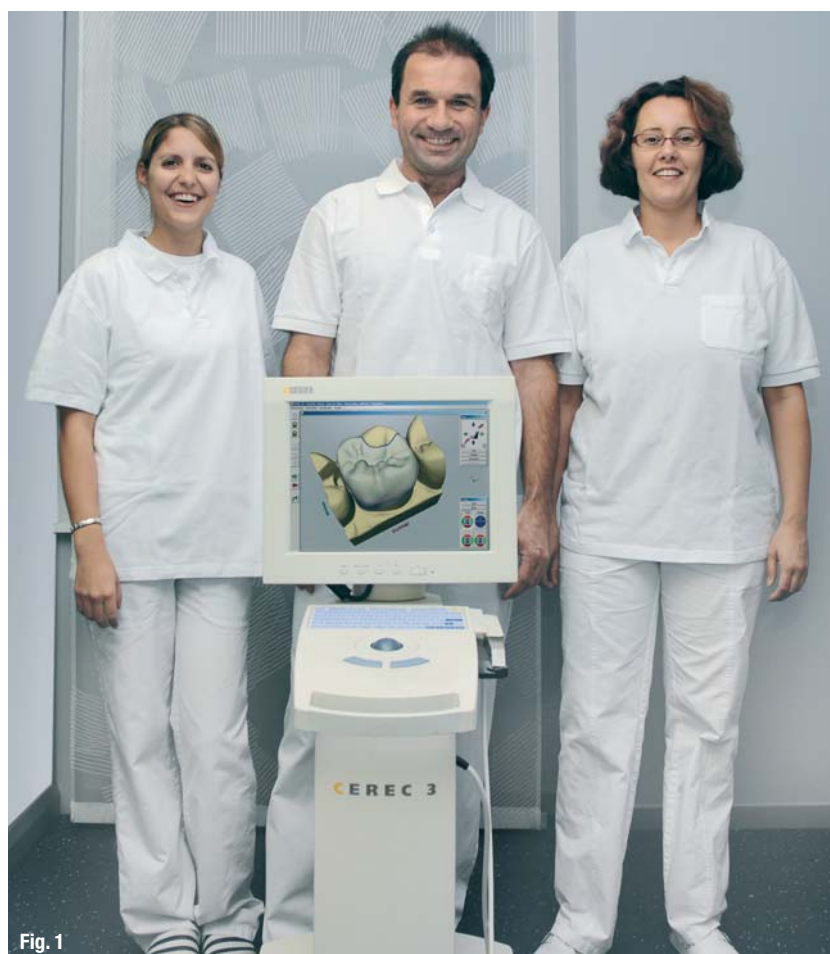

Fig. 1

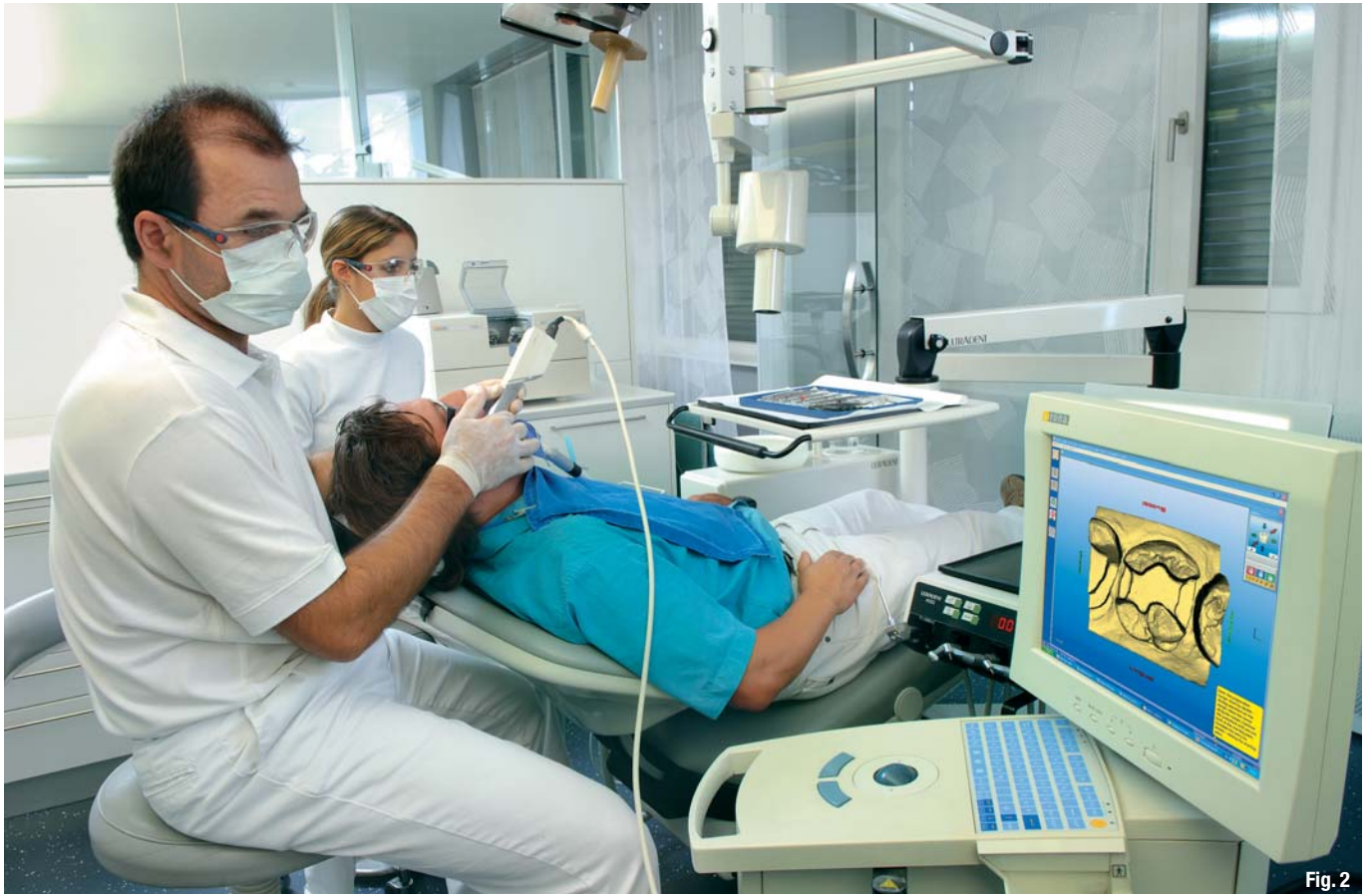

Fig. 2

He began working with CEREC 1 in 1989 in a partner practice in Zurich. He wished not only to provide his patients with aesthetic and long-lasting restorations, but also to prove to the hesitant university and the professional community that this method, together with adhesive bonding, was capable of providing the basis for highly resilient ceramic restorations. With typical Swiss thoroughness, he documented all of the CEREC treatments he performed and recorded all findings from recall appointments. "I was convinced that in the long run, ceramic would be more durable and economical than composite," remembers Dr Otto. "For three and more surfaces, composite is, in my opinion, a poor compromise and, if recurrent caries develops or the filling has to be replaced a short time later, the patients will consider me a bad dentist. In terms of long-lasting dental aesthetics, we Swiss are very particular; we don't accept compromises."

Time would prove him right. After ten years, data from his practice demonstrated a survival rate of 90.4% for CEREC inlays and onlays. Thus, these results corresponded to those of the gold standard, that is, cast gold fillings.¹ The study was published internationally and the media acknowledged the findings for ceramic restorations in private practice. Meanwhile, Dr Otto has been working with

a CEREC3 unit, and the study is now in its 18th year. The consistently applied multistep adhesive technique has proven to be sufficient, even with an adhesive joint of 150 μm . With a survival rate of 88.7 per cent after 17 years, Dr Otto has set the new gold standard with his restorations.²

He satisfies his patients' dental and aesthetic desires using CEREC thanks to the material, which combines excellent aesthetics with stability, and to the longevity, which makes the restoration economical. "What my patients appreciate about CEREC is that their tooth-coloured ceramic restoration is manufactured and inserted in one sitting, and for an average yearly cost of 47 Swiss Francs—based on the minimum expected service life—they really get tailor-made aesthetics."

Editorial note: A complete list of references is available from the publisher.

Fig. 2 Patients appreciate that the complete treatment requires just one sitting. (Photo: Dr Otto)

_ author info

cosmetic
dentistry

Manfred Kern, Wiesbaden, Germany
German Society of Computerized Dentistry –
International Society of Computerized Dentistry
secretariat@dgcz.org
www.dgcz.org

Temporaries: Perfect provisional restorations

Author_ Dr Hans Sellmann, Germany

Fig. 1_The initial situation: teeth 11, 21 and 22 cannot be preserved.

Fig. 2_Plaster model for making a formed component for the long-term temporary.

Fig. 3_The post-extraction alveoli after removing teeth 11, 21 and 22.

Fig. 4_Processing the miniplast tray.

Fig. 5a_Filling the shaped piece with a highly aesthetic provisional crown-and-bridge material (Structur Premium).

Fig. 5b_Structur Premium: complete set with dispenser (application gun) for fabricating perfect temporary restorations.

Temporaries are indeed only an interim solution. They do, however, fulfil important functions until the permanent restorative is available and thus have a lasting effect on the success of the treatment in restorative dentistry.

The quality of the temporary restorations has great importance with respect to their protective function until the integration of the permanent restoration. Temporary crowns and bridges combined with luting cements protect the dentine and pulp from thermal, chemical, mechanical and bacterial damage. Today, modern temporary crown-and-bridge materials facilitate the fabrication of temporary restorations that meet the highest medical standards of reliability and provide incredible, natural aesthetics.

The challenge of fabricating temporaries

The fabrication of temporary crowns and bridges that provide an accurate fit is not easy. Much effort goes into it, as building a perfectly integrated protection for the prepared abutment requires extreme precision. For the clinical success of a temporary, there are several aspects of the fabrication to consider.

One such aspect is the quality of the marginal seal; the temporary must sufficiently close the preparation border so that the patient does not suffer from sensitivity. Additionally, care must be given to provide a consistent occlusion and appropriate contact points to the neighbouring teeth; ultimately, the teeth should not wander until the definitive restoration is inserted.

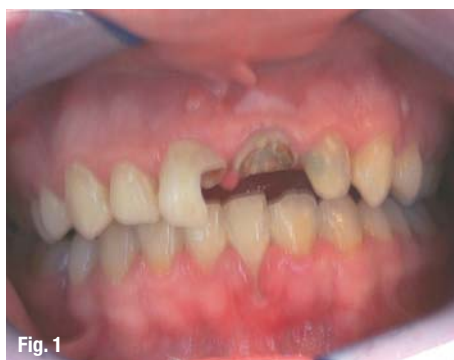

Fig. 1

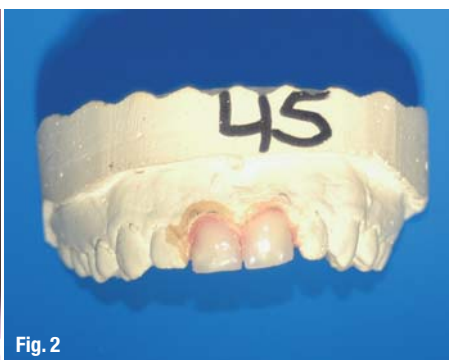

Fig. 2

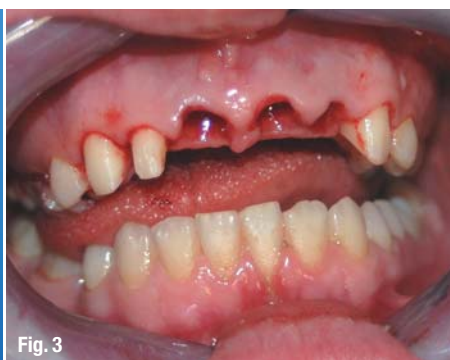

Fig. 3

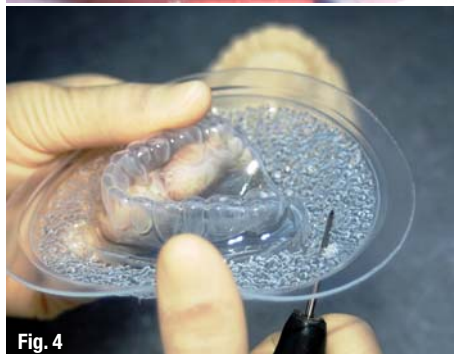

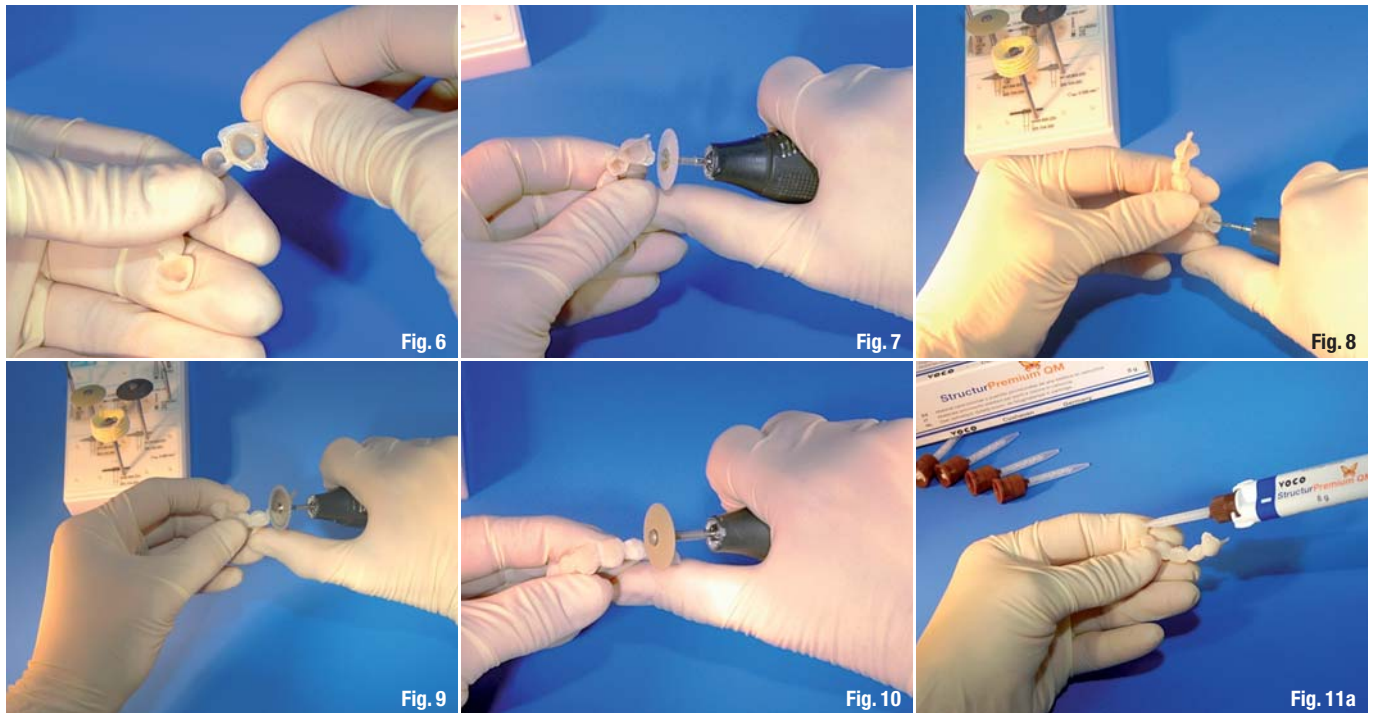
Fig. 4

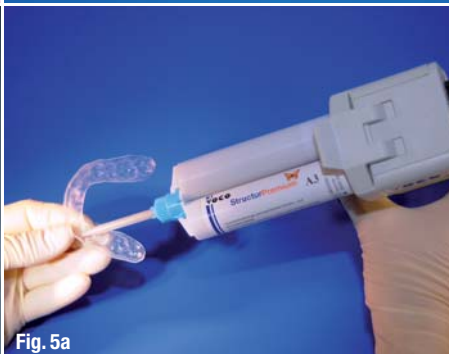

Fig. 5a

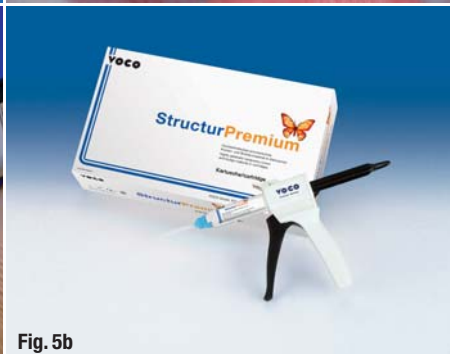

Fig. 5b



The temporary should also be easy to polish and exhibit good surface quality in the interdium and region of the crown boundary. The gingiva is already irritated from the preparation and shaping and should not become infected and retract because of a temporary's rough edge. Owing to these requirements, materials for the fabrication of temporaries should not only permit safe and quick handling, but also facilitate an optimal medical and aesthetic result.

The clinical case

A female patient presented who had to have her maxillary anterior teeth removed and a bridge had to be prepared for her. The initial situation showed that teeth 11, 21 and 22 could not be preserved (Fig. 1). Normally, we would extract the teeth, insert a removable temporary (or an expensive one made by a laboratory) and prepare accordingly, after the post-extraction alveoli have healed. This procedure, however, is accompanied by the problem that the pontics are always recognised as such, as there is no emergence profile or papilla formation typical of the natural tooth.

In contrast, a procedure is used in the following case that permits the fabrication of a bridge with the most naturally appearing bridge pontic area possible. To begin with, a plaster model is fabricated for making a formed component for the long-term temporary (Fig. 2). After the preparation and extraction of the teeth to be removed, we went with the fabrication of a long-term temporary with pontics for the formation of the alveoli, for which we use the post-extraction alveoli (Fig. 3). In this manner, the emer-

gence profile of the bridge pontics could be made so that it appears that they are emerging from the gingiva and thus have the appearance of natural teeth (keyword 'red aesthetics').

We used a deep-drawn miniplast splint made from a soft foil for the impression and processed it with an instrument especially for this purpose from the preparation kit (Komet; Fig. 4). The shaped piece offers the advantage that it is not sensitive to external influences (shrinkage etc.), can be stored longer and is more hygienic than a precast.

In the next work step, the mould was filled with a highly aesthetic provisional crown-and-bridge material (Structur Premium, VOCO; Figs. 5a & b). The quality of the margin was assessed after removing the temporary bridge from the formed component (Fig. 6). The temporary was subsequently finished with tools from the preparation kit. First, a one-sided sandpaper disc was used for rough finishing (Fig. 7), followed by the smooth finishing of the edges with a cross-cut carbide bur (Fig. 8). We segmented the pontics with the diamond disc from the finishing set (Fig. 9) and used a rubber cup for the pre-polish on the temporary (Fig. 10). Small irregularities or defects ('bubbles') were corrected with Structur Premium QM in incisal shade (Figs. 11a & b).

We carried out the subsequent high-gloss polish with the equally fast and effective fibre-buffing disc (Fig. 12). For a perfect finish, we applied a nano-filled protective varnish to seal the surface (Easy Glaze, VOCO; Figs. 13a & b), which we light-cured afterwards (Fig. 14). The protective varnish provides a

Fig. 6 Assessing the quality of the edge before finishing.

Fig. 7 Rough finishing of the temporary bridge with the one-sided sandpaper disc.

Fig. 8 Smooth finishing of the edges with the cross-cut carbide bur.

Fig. 9 Segmenting the pontics with the diamond disc.

Fig. 10 Pre-polishing with the rubber cup.

Fig. 11a Correcting small irregularities and defects with a highly aesthetic provisional crown-and-bridge material in incisal shade (Structur Premium QM).

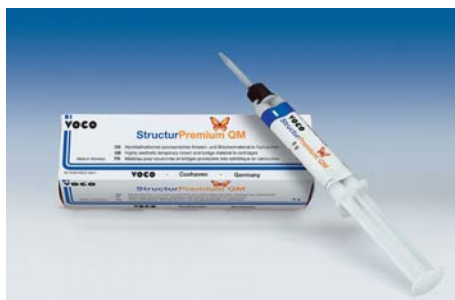

Fig. 11b

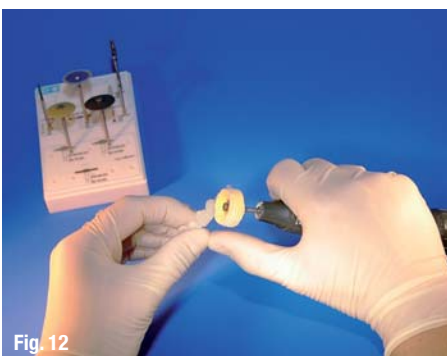


Fig. 12

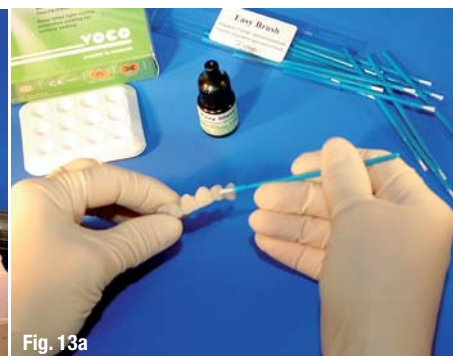

Fig. 13a



Fig. 13b

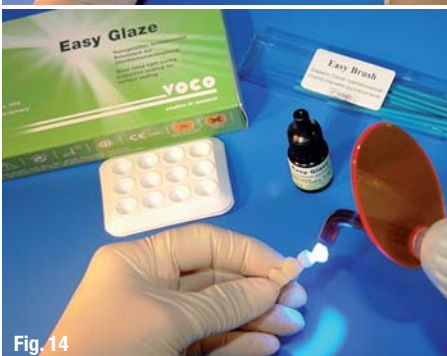

Fig. 14

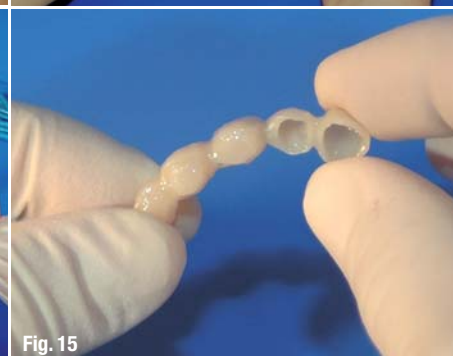

Fig. 15

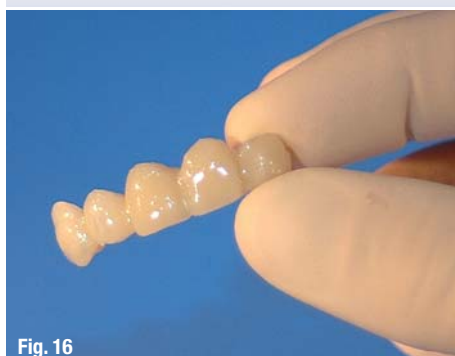

Fig. 16

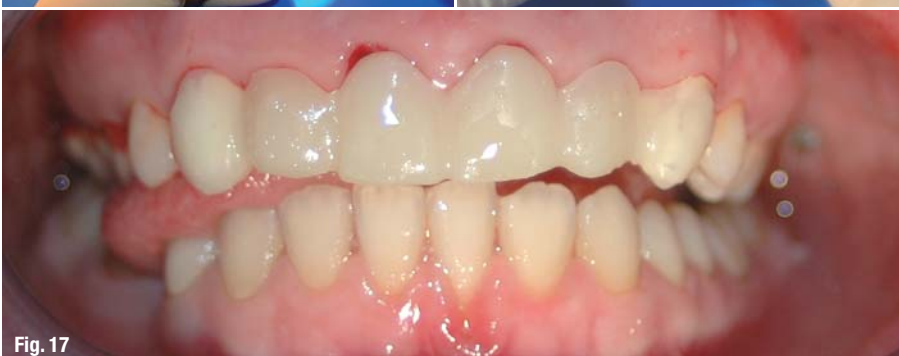

Fig. 17

Fig. 11b_Structur Premium QM: highly aesthetic provisional crown-and-bridge material in incisal shade. The QuickMix syringe permits perfect handling and exact application.

Fig. 12_High-gloss polish with the fibre-buffing disc.

Fig. 13a_A protective varnish (Easy Glaze) is applied for the perfect finish.

Fig. 13b_Easy Glaze: nano-filled, light-curing protective varnish for surface sealing.

Fig. 14_Light-curing the protective varnish.

Fig. 15_A smooth surface on the pontics is especially important for the alveoli because the temporary will rest on them.

Fig. 16_The finished long-term temporary.

Fig. 17_The integration of the temporary created an ideal initial situation for an aesthetic emergence profile for the future pontics.

naturally shiny, smooth and aesthetic surface that protects against more than just discolouration.

A smooth surface is especially important for the pontics that rest on the alveoli, in order to prevent plaque retention and the potential resulting inflammation (Fig. 15). The completed long-term temporary was finally integrated (Fig. 16). It created an ideal initial situation for an aesthetic emergence profile for the future pontics (Fig. 17).

_Billing for the long-term temporary

In contrast to a removable long-term temporary, a fixed long-term temporary is not covered by insurance. My patients gladly pay the difference, however, because of the increase in comfort. This is especially the case when I describe the positive aesthetic results to them.

Successful creation of durable long-term temporaries is ensured with the provisional crown-and-bridge material I used here. Structur Premium is not just for long-term temporaries, it is also my first choice for fabricating ordinary, routine temporaries.

_author info

cosmetic dentistry



Dr Hans Sellmann studied dentistry at Westfälische Wilhelms-Universität in Münster, Germany, and has practised as a general dentist since 1976. He is the author of books on dental entrepreneurship, managing problem patients and microbiological

diagnostic methods, and of DVDs for continuing professional development in the fields of anaesthetic treatment, cranio-mandibular dysfunction, halitosis, paedodontics and risk diagnosis in the dental practice. He has developed several instruments for dentistry, is an expert lecturer in CPD courses and has published over 100 articles.

Dr Hans Sellmann
Langehegge 330
45770 Marl, Germany
E-mail: dr.hans.sellmann@t.online.de
www.zahnarzt-sellmann.de

Structur Premium – The first choice for temporaries

Highly aesthetic provisional crown and bridge material from VOCO



Durable and naturally aesthetic

Structur Premium is characterised by its ingenious material composition. It has the proven material properties of a nano-particle composite and provides the temporaries with excellent stability and a brilliant shine. Structur Premium is available in seven shades (A1, A2, A3, A3.5, B1, B3 and BL). All shade versions exhibit natural fluorescence and thus provides the temporaries with exceptional brilliance in all lighting conditions. The optical properties of the temporaries in the anterior area can be improved even more with Structur Premium QM (QuickMix) in the shade I (incisal).

Simple and economical application

With its excellent product characteristics, Structur Premium permits a comfortable application and efficient finishing with simple grinding and subsequent polishing to a tooth-like shine. The proven 1:1 cartridge facilitates precise work with the especially small mixing tips and it provides an economical application and frugal use of the material. Structur Premium, the provisional crown and bridge material for perfect handling and perfect aesthetics.

Structur Premium – Prime advantages for users and patients

- Aesthetic like porcelain
- High stability of shape and shade
- Natural fluorescence
- Brilliant gloss
- As hard as enamel
- Extremely high fracture resistance
- Perfect handling
- Convenient work steps, easy to trim and polish
- Long-term use of temporary possible
- Very economical mixing tips
- Special incisal shade facilitates the fabrication of temporaries in two-layer technique

The expectations are increasing for highly aesthetic treatments. This equally applies to provisional crowns and bridges, especially in the anterior region. Temporary restorations must not only provide superior aesthetics, but also durable protection for the prepared teeth until the definitive restoration is inserted. Therefore, the mechanical stability is especially an important quality feature for crown and bridge materials. With Structur Premium, VOCO offers a highly aesthetic provisional crown and bridge material that equally fulfills all of the different requirements and it can also be used universally.



AESTHETIC LIKE PORCELAIN, AS HARD AS ENAMEL, EASY TO HANDLE – EXPERIENCE STRUCTUR PREMIUM!

Return this coupon by fax +49 4721 719-140 or by mail until 30 Sept, 2009 to enter the draw for **three free Intro Sets Structur Premium!**

Practice/Doctor's Name:

Street Address:


ZIP, City, Country:

E-Mail: Phone:

Signature:

By completing and submitting this coupon, I give VOCO GmbH permission to contact me using the information provided above. I understand that no purchase is necessary to participate in this sweepstakes promotion and I do not have to submit to a sales presentation. Check here to opt out of being contacted. Drawing held 30/09/2009. Void where prohibited. ©2009 VOCO GmbH – CD10309StrPre

VOCO GmbH
Dept. Marketing
P.O. Box 767
27457 CUXHAVEN
GERMANY



Customised abutments for long-term aesthetics— software tools to meet clinical and laboratory requirements

Authors_ Hans Geiselhöringer & Dr Stefan Holst, Germany

Figs. 1a & b_ Virtual design of an implant abutment (NobelProcera system software, Nobel Biocare).

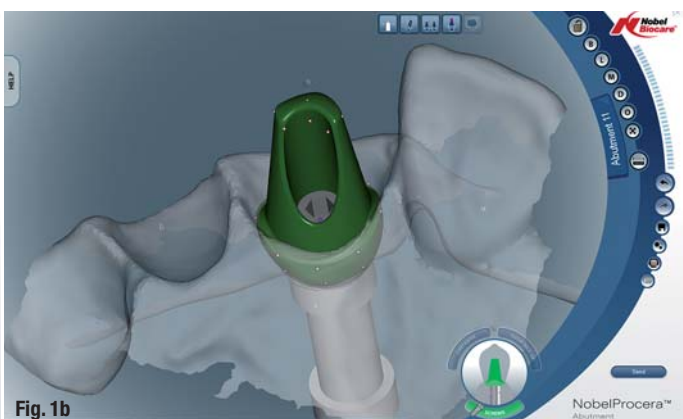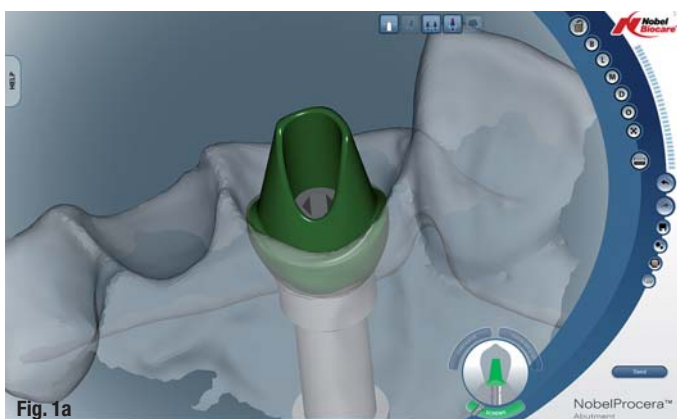The display of the surrounding anatomy provides detailed information on the ideal design and retentive contour. The abutment height and taper must be idealised to provide functional stability. Suggested contour by software (a) and customised height (b).

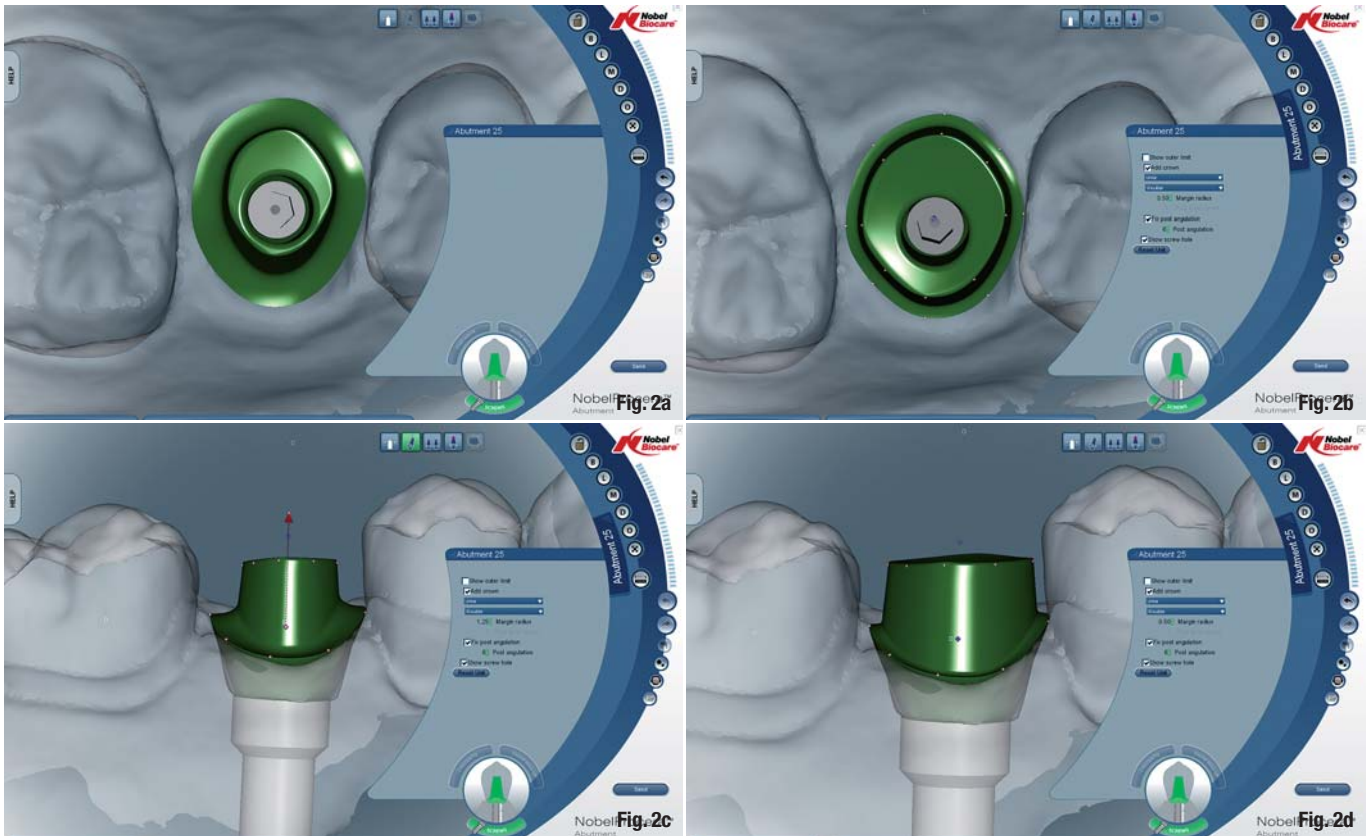
_Replacing missing single teeth with dental implants has become routine, yet restoring anterior teeth with implant-supported restorations is a technique-sensitive task for which aesthetic and functional success remains a challenge for the surgical-restorative team.

Indispensable factors for success are the amount of available alveolar bone, morphological soft-tissue type, correct positioning of the implant in all three dimensions, and a successful provisional phase. In addition to establishing an adequate implant recipient site and a harmonious

and natural blending of the restoration with the surrounding tissues and dentition, the long-term stability of the peri-implant tissue architecture is a significant challenge. The selection of suitable materials and an optimal design are paramount for the success of the definitive restoration. This is where the advantages of CAD/CAM technology and all-ceramic materials become evident.

These technological advancements have had a considerable impact in various areas of dentistry and will continue to do so into the future. Advantages related to material and manufacturing





processes will promote the ongoing adoption of CAD/CAM systems in preference to conventional casting and manufacturing techniques. This is because CAD/CAM technology offers numerous benefits compared to conventional framework fabrication, including reproducible precision, material homogeneity, individual customised design, and ease of fabrication. At the same time, industrialised fabrication methods guarantee standardised quality and reduce cost-intensive manual labour. In addition, the availability of homogeneous, bio-compatible materials will minimise material incompatibilities and corrosive phenomena arising from dissimilar metal alloys and interfaces between cast and machined components.

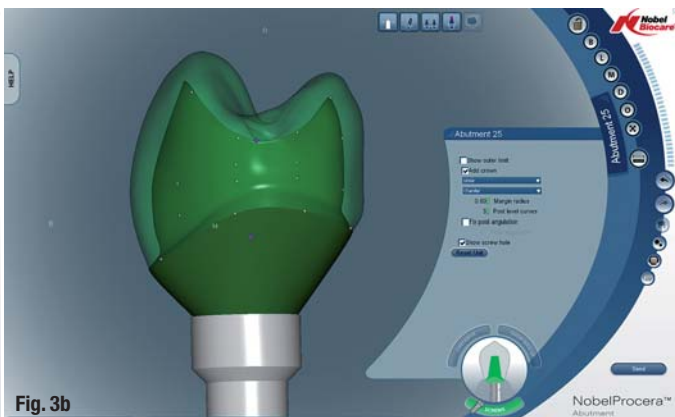
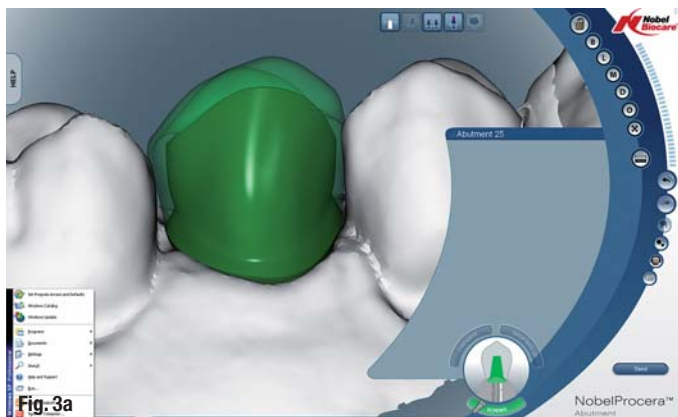
Ongoing research in ceramic materials development has led to the use of high-strength, non-silica-based ceramics in dentistry with beneficial properties in terms of bio-compatibility, aesthetics and long-term clinical function that have been investigated in numerous scientific investigations. Aluminium oxide (Al_2O_3) and zirconium dioxide (ZrO_2) ceramics are the most common oxide ceramic materials used today. Owing to its material properties and strength, ZrO_2 is applied whenever high loads are expected (e.g. posterior fixed dental prosthesis frameworks, implant abutments and multi-unit implant restorations). In addition to its strength, the greatest advantage

of ZrO_2 is its excellent tissue integration. Various studies have demonstrated the successful application of zirconia abutments in terms of stability of soft tissue and marginal bone. Results indicate that the type of material used affects both the amount and quality of the surrounding tissues (when comparing zirconia to cast alloys). Also, ceramic abutments minimise bacterial and plaque adhesion and prevent soft-tissue inflammation.

_Customised abutments: manufacturing options

The clinician may choose between prefabricated or customised abutments for implant-retained single or multi-unit restorations. The primary objective must always be proper support of the surrounding tissues, optimal morphology to support the restoration without impairing hygiene maintenance, and anatomic design to allow for proper support of the veneering ceramics in case of screw-retained restorations. These goals can easily be achieved if an abutment is custom-made. Using prefabricated abutments, on the contrary, has several disadvantages. Customising is a time-consuming and highly unpredictable process in the laboratory, requiring additional finishing procedures in the dental office. Post-sintering manipulation of oxide ceramic components significantly increases the risk of micro-cracks that could result in subsequent failure

Figs. 2a–d The intuitive software helps simplify the design process. Occlusal and lateral view of the margin radius that can be homogeneously adapted at the click of a button (a & b). Note the location of the abutment-crown margin at the cervical margin (c & d).



Figs. 3a & b The anatomic tooth library is an extremely useful tool that eliminates the need for a wax-up and ensures an homogenous veneering porcelain thickness using an automated reduction tool (see dark green contour of the definitive abutment and the transparent morphology of the anticipated final restoration).

under clinical function. Scientific investigations have revealed that the reaction of cells towards materials with a corrosive potential such as cast-alloy components or veneering porcelain is inferior to homogenous materials such as titanium or zirconia.

_Fast and intuitive design of implant abutments

Work processes to fabricate an individual abutment that in the past required significant amounts of time can be realised within minutes today. The newest generation of CAD software eliminates the need for a wax-up to achieve the desired definitive abutment shape. While an automated software

function suggests a superstructure or abutment following a model or impression scan, the dental technician can easily adapt the contour and form virtually to any desired shape (Figs. 1a & b). In addition, one software programme offering an intuitive software interface and the ability to restore using different implant systems is a very interesting alternative to conventional fabrication, for which cast-on components have to be ordered for the respective implant system and then customised.

_Virtual design of transgingival contour and positioning of the crown-abutment margin

When designing an abutment, the following two major criteria supporting long-term success should be considered: the contour and shape of the abutment in the sub-gingival area and the height, angulation and taper to provide adequate retention for a cement-retained crown. There is no scientific evidence that supports a more concave or a convex peri-implant abutment contour. Communication and close collaboration between the dental technician and the dentist are needed, taking the individual clinical situation into consideration. This includes the position of the implant in relation to the definitive crown contour, the thickness and biotype of the surrounding tissue, and location within the arch.

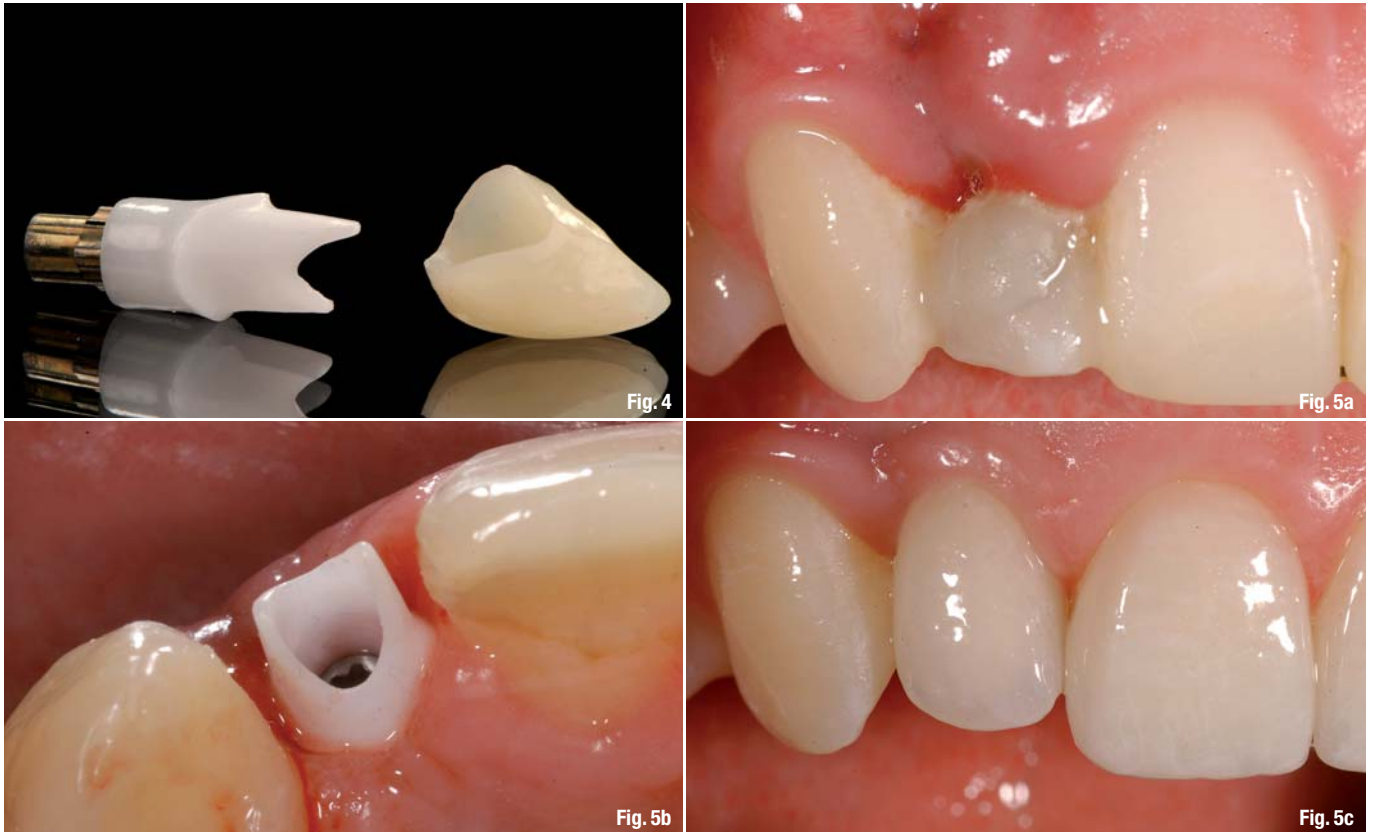
It is generally agreed that the abutment-crown margin should always be located at or slightly below the gingival crest in order to allow for complete removal of cement (Figs. 2a–d). If remnants of the cementation media remain, peri-implant inflammation and adverse tissue reactions are very likely. Here another advantage emerges. While metal abutments or porcelain-fused-to-metal crowns had to be positioned deep underneath the gingival margin in order to minimise the risk of discolouration, utilising oxide ceramic materials eliminates this concern and improves the aesthetic outcome.

Table 1_ Biological advantages of customised CAD/CAM abutments:

- formation of an intimate soft-tissue contact
- long-term clinical stability through bio-compatible and homogenous materials
- eliminates the risk of corrosion in contact areas of dissimilar metals and alloys
- maximises aesthetic results through application of shaded Zirconia

Table 2_ Customised CAD/CAM abutments: design advantages

- free-virtual design options
- screw- or cement-retained restorations
- optimal support of peri-implant soft tissue through individual abutment profile
- round contours, no sharp edges
- ideal positioning of cement line



Mechanism of retention

A significant disadvantage of screw-retained restorations in the past compared to cemented restorations was the aesthetic closure of the screw access channel. Using metal-based frameworks and composite resin for closure resulted in impaired aesthetic outcomes on the occlusal surface. Zirconium-dioxide-based frameworks eliminate this disadvantage. If white or shaded substructures are used, easy and fast closure of the screw access channel can be achieved with conventional composite resin materials. The retrievability and the absence of cement between the abutment and the crown are amongst the greatest advantages compared to cemented solutions or cast abutments.

Porcelain is fired directly onto the abutment and the abutment-crown complex can be screwed onto the implant. Here again CAD technology supports the dental technician in the design of the final abutment shape. Numerous publications emphasise the need for an homogeneous veneering material thickness in order to minimise the potential problem of chipping (Figs. 3a & b). Utilising a software system that makes use of an anatomic tooth library supports the user in designing the later contour of the final restoration (taking occlusal and functional aspects into consideration). Whether an implant-

retained crown is cemented or the abutment-crown complex is screw retained depends on the dentist's preference and the positioning of the implant (Figs. 4 & 5a-c). A cement-retained restoration on an individual ceramic abutment allows for simple compensation of misaligned implants and can be treated like a natural tooth. The main disadvantage of cemented prostheses is irretrievability.

The authors acknowledge Dr M. Thorwardt from Friedrich Schiller University Jena for conducting the implant surgery.

Editorial note: A complete list of references is available from the authors.

contact

cosmetic
dentistry

Hans Geiselhöringer

Dental Technician
Dental X Hans Geiselhöringer GmbH & Co. KG
Lachnerstraße 2
80639 Munich, Germany

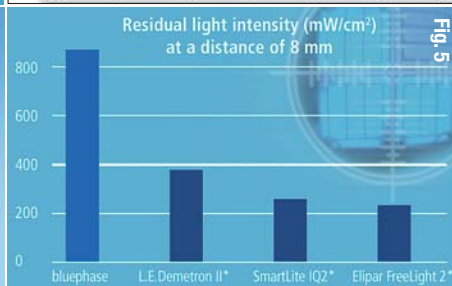
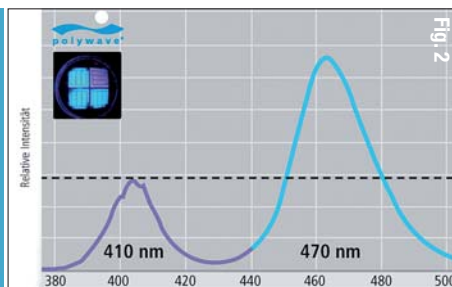
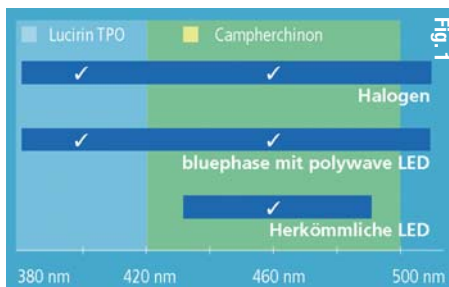
Dr Stefan Holst

University Clinic Erlangen
Dental Clinic 2 – Department of Prosthodontics
Glückstraße 11
91054 Erlangen, Germany

Fig. 4 The combination of the strength of a zirconia abutment and the aesthetic advantages of an alumina crown (NobelProcera crown alumina, Nobel Biocare) demonstrate the advantages and versatility of the NobelProcera system.

Fig. 5a-c The clinical advantages of custom-designed CAD/CAM abutments are unrivalled. Homogeneous and bio-compatible materials allow for correction of implant angulation and ensure long-term clinical tissue stability (NobelProcera zirconia abutment, Nobel Biocare); a) Initial clinical situation with an unacceptable provisional restoration replacing the lateral incisor (b). Definitive clinical outcome following implant treatment (c).

Progress knows no clinical limitations



Second generation LED lights are notorious for offering a much narrower emission spectrum than the gold standard halogen lights. For this reason, several bleach shade composites, adhesives and protective varnishes cannot be entirely cured owing to the photoinitiator used. This is where bluephase and its specifically developed poly-wave LED come into play.

power for polymerisation close to the pulp and soft start for stress-reduced polymerisation, is relatively cost-effective (Figs. 3 & 4). Owing to the 10 mm light probe, which offers an enlarged treatment field, time-consuming multiple polymerisations are a thing of the past. In addition, proximal boxes can easily be cured using this elegant light (Fig. 5).

Simply clever: The new poly-wave LED

Continuous cooling: A must-have for LED lights

Reliable polymerisation of composites and luting materials is a crucial step in the dental practice. This is exactly where the new bluephase family—bluephase C8, the classic bluephase and bluephase 20i—show their strength. The specifically developed poly-wave LED activates all photoinitiators. The four LEDs—three blue ones (dominant wavelength: approximately 410 nm) and a violet one (dominant wavelength: approximately 470 nm) that operate simultaneously—allow unlimited use in the dental practice and are thus suitable for all photoinitiators and materials (Figs. 1 & 2).

Does this sound familiar? If a certain temperature is exceeded, the LED light switches off in order to prevent damage. The light is only operational again after several minutes. The virtually noiseless, invisible fan of the bluephase family allows continuous operation without clinical limitations, even when used for extensive indirect restorations.

Bluephase C8: On an economical mission

Conclusion

The mains-operated curing light bluephase C8, featuring a light intensity of 800 mW/cm² and three programmes—high power for fast polymerisation, low

The cordless bluephase has proven its value with its functional properties and ergonomic concept (Fig. 6). The more compact basic edition bluephase C8 is a more economical option. Now the versatile bluephase model featuring a poly-wave LED is available for every practice.

_contact **cosmetic**
dentistry

Ivoclar Vivadent AG
Bendererstrasse 2
9494 Schaan
Liechtenstein
www.ivoclarvivadent.com.

Allow us to introduce ourselves:
Kettenbach. In Germany we are
world-famous.



It really would have been possible to meet each other much sooner, because in 1955 we were already the first company worldwide to supply elastomeric, condensation-curing impression materials. And by now the news has made the rounds internationally that our research department is responsible for ground-breaking developments in the A-silicone sector. Thus, our partners in laboratories and dental practices are always a bit ahead of their time. You don't know us yet? Then please invite us in and test the Kettenbach precision products.
www.Kettenbach.com

Enjoy your trip and indulge in the journey!

Author & Photographer_ Annemarie Fischer, Germany



*"The American Road Trip isn't just
a pastime; it's a birthright,
a necessity, a rite of passage,
it's a way of life."*

(Erin McHugh, The Little Road Trip Handbook)

The road trip is a constant narrative in US-American pop culture and is synonymous with escape, freedom, and independence from borders and boundaries. In the land of the free and the home of the mobile, the *Asphalt Nation* of America, as observed by Jane Holtz Kay, is built around automobiles and cherishes the ideal of mobility. Some road-enthusiasts, referring to themselves as road trippers—

have developed the science of a road trips, *roadology*, that explores the effects of roads on societies.

A true American road trip starts at the first crossroads, not knowing

if you would like to go straight, left or right, and not planning ahead too much. It is about impromptu 'moseying' down the road rather than following a strict schedule.

This road trip combines two routes, the hiker-favourite Appalachian Trail, starting in Pennsylvania and exploring Southern Atlanta, and the NYC-Miami Atlantic Coast Route to Florida. The routes explore the historical birthplace of the United States in Philadelphia, the impressive nature of the Shenandoah, Great Smoky Mountains and Everglades National Parks, Ivy League university campuses of Cornell, Princeton and Pennsylvania University, the cradle of the African-American civil rights movement and global news in Atlanta, the Kennedy Space Center in Cape Canaveral, and the colourful Miami.



For outlanders, a well-kept rental car, sufficient insurance coverage, a working mobile phone and a good map, as well as credit cards and some dollar bills to secure cash-flow are enough. In local supermarkets, one can get a regular supply of water, fresh fruit and chopped veggies. In some states, one might be lucky to find on-the-road selling stations of local produce. With most rentals nowadays, you get access to hundreds of digital radio stations that complete the road track with the perfect sound track. Jamie Jenson, author of *Road Trip USA*, offers a road trip blog and podcast at www.roadtripusa.com.

Motels are available easily down the road; with the Days Inn as well as Jamestown being on the (more) pleasant side. However, their early nutrition consists mostly of a crime called Con-

Going green

Nature parks in the States truly signify the gorgeousness of this country, and function as an oasis from civilization—no gigantomanic malls and no fast food restaurants disturb the scenic nature. A small entrance fee is valid for a couple days up to a week. Hotels or camping facilities offer a place to stay for the night.

Being thrown into nature, one is to respect the speed limit in order not to hurt an animal. A 35-mile-speed limit in Skyline Drive explores Shenandoah National Park. Down the Appalachian Trail, the fog-covered mountains name the Great Smoky Mountains National Park and amaze visitors in the most popular park in the United States. Alligators, pythons and vultures come close in the Florida Everglades Park, and protection from mosquitoes is mandatory!



tinental Breakfast. The Waffle House, for example, offers a more decent way to start the day and is open-all-night to savour fresh waffles with maple syrup, eggs'n'bacon and grits in enormous portion sizes. For a decent dinner, one should always ask for the best local diner on the way, and fast food branches offer a quick snack to go.

The concept of Park and Ride is not compulsory in most cities. Most downtown areas are quite car-friendly, with most sights offering free parking or at rates for a couple of dollars per hour. Park and Ride is only mandatory in city molochs like New York.

Going Ivy

American elite Ivy League Universities—Cornell, Pennsylvania University and Princeton—are always worth the trip, since their campuses blend in with the nature and offer an



impressive architecture. University bookstores are tea'n'coffee havens to indulge in the oeuvres of university lecturers, for instance novelists Vladimir Nabokov in Cornell, Philip Roth at PennU, and Jeffrey Eugenides at Princeton.





The campuses also own captivating museums: The University of Pennsylvania, that claims to be America's First University, possesses in Museum of Archaeology and Anthropology one of the finest ethnology collections in the world.

Shopping in the USA

Since consumption of goods has been elevated to a true art form in the United States of America, a typical road tripper goes shopping. In times of crisis, outlet shopping centres function as a holy grail for an almost guilt-free indulgence. It is more fun to explore the less-crowded centres in the South, such as in *nomen est omen* Commerce.



impressive art collections. Film legend Rocky Balboa turned its stairs into an American pop culture icon—to climb and conquer the stairs and to cheer on top has become a verb, "to do the Rocky (Balboa)". Cruising South Philly is even more amazing—it unravels graffiti buildings, outdoor neighbourhoods and family businesses. Geno's and Pat's just face each other to win the culinary competition over the Best Philly Cheese Steak, a sandwich filled with steak and cheese sauce.



Rocking Philly

Philly forms the perfect symbiosis between history and relaxation. The City of Brotherly Love is the historical birthplace of the United States and welcomes you with American historical sites in the Independence National Historical Park, home of the Liberty Bell, as well as the Betsy Ross House, where historians still debate if the first US-American flag had been indeed designed there. The Philadelphia Museum of Art offers one of the most



Hotlanta

Temperatures and heartiness rise as one reaches the capital of the Peach State Georgia, Atlanta. Hotlanta is the home of Coca-Cola and CNN, and of Martin Luther King Jr, who was born and raised here. The King Center and his birthplace blend in unpretentiously with the neighbourhood. King's powerful rhetoric accompanies insightful information on his life path that reflects the struggles of the civil rights movement, and on current human rights movements around the world in this living memorial.

When Hotlanta makes hungry, The Varsity is considered as the best Drive-In hot dogs, greeting the customers with the legendary "What'll ya have?".



The CNN Headquarters satisfies an appetite for information, where the longest escalator of the world guides one to the CNN studios, where visitors can see directly into studio windows. News is today a highly-complex and digitalised production. CNN anchormen and -women work directly from news bureaus, endowed with highly-sensitive microphones that block surrounding noises, and are digitally beamed into futuresque studio settings.



calypso sound. The Spanish churros pastry, along with hot chocolate, drench the night.

Going up

The Kennedy Space Center is financed uniquely with entrance fees, and is the most gigantic PR measure to promote aerospace. The space center is located in a gigantic



Bienvenidos a Miami!

Miami truly cites its *Miami Vice* pop culture reference, shimmering in pleasant pastel colours, and glowing as the vibrant and voluptuous as the eighties era. Pastel-blue daytime skies change into dramatic evening shades. The Art Déco district can be explored with guided tours, and it is the sight of a tragedy: Gianni Versace was murdered at Ocean Drive 1116 in his Casa Casuarina.

The Magic City merges into a true melting point and is the largest and most vibrant out-of-Latin America community, visible in Little Havana. Two-thirds of Miami people cite Spanish as their mother tongue. Those Latin, Caribbean, Central and South American as well as European influences melted into the unique New World, or Nuevo Latino, cuisine. In the Las Vegas Restaurant, one can get a taste of the Cuban Fusion cuisine. After sun-bathing at South Beach, synonymous to "showing what you've got", most restaurants turn into nightclubs. Coconut Grove offers after-dinner cocktails in outside cafés and bars, where one cannot only indulge in tastes, but also sounds of Latin America and the Caribbean. Cubans brought the conga and rumba to Miami from their homelands, instantly popularising it into US-American culture. Dominicans carried bachata, and merengue into the bars, while Caribbeans brought reggae, soca,



nature reserve and is not only a high-tech playground, visitors can witness work in progress on the working facilities.

For outlanders, an All-American road trip is the path to understand that the United States of America is a gathering of civilizations and cultures, flora and fauna, images and sounds, flavours and aromas, styles, and feelings; and "to get the feel of the road", notes Erin McHugh in *The Little Road Trip Handbook*, "remember that it's the journey, not the destination."



Cosmetic events

2009

FDI Annual World Dental Congress

Where: Singapore, Singapore
Date: 2-5 September 2009
Tel.: +33 450 4050 50
E-mail: congress@fdiworldental.org
Web site: www.fdiworldental.org

ESCD 6th Annual Meeting

Where: Paris, France
Date: 25-27 September 2009
Tel.: +33 495 09 38 00
Web site: www.escdonline.eu

ACE 2009 Symposium on Esthetic Dentistry

Where: Scottsdale, AZ, USA
Date: 11-14 November 2009
Tel.: +1 800 701 6223
E-mail: contact@ACEsthetics.com
Web site: www.acesthetics.com

SAAAD Aesthetic Dental Conference

Where: Kathmandu, Nepal
Date: 28-29 November 2009
Tel.: +977 142 425 64
Email: skoirala@wlink.com.np

Greater New York Dental Meeting

Where: New York, NY, USA
Date: 27 November-2 December 2009
Tel.: +1 212 398 6922
Web site: www.gnydm.org

2010

26th AACD Anniversary Scientific Session

Where: Grapevine, TX, USA
Date: 27 April-1 May 2010
Tel.: +1 800 543 9220
E-mail: pr@aacd.com
Web site: www.aacd.com

EAED Spring Meeting

Where: London, UK
Date: 27-29 May 2010
Tel.: +39 02 295 236 27
E-mail: info@eaed.org
Web site: www.eaed.org

IACA Annual Meeting

Where: Boston, MA, USA
Date: 22-24 July 2010
Tel.: +1 866 669 4222
E-mail: info@theIACA.com
Web site: www.theiaca.com

AAED 35th Annual Meeting

Where: Kapalua, HI, USA
Date: 3-6 August 2010
Tel.: +1 312 981 6770
E-mail: meetings@estheticacademy.org
Web site: www.estheticacademy.org



submissions:

formatting requirements

Please note that all the textual elements of your submission:

- _ the complete article,
- _ all the figure captions,
- _ the complete literature list, and
- _ the contact info (bio, mailing address, E-mail address, etc.)

must be combined into one Word document. Please do not submit multiple files for each of these items.

In addition, images (tables, charts, photographs, etc.) must not be embedded into the Word document. All images must be submitted separately, and details about how to do this appear below.

Text length

Article lengths can vary greatly—from a mere 1,500 to 5,500 words—depending on the subject matter. Our approach is that if you need more or less words to do the topic justice then please make the article as long or as short as necessary.

We can run an extra long article in multiple parts, but this is usually discussing a subject matter where each part can stand alone because it contains so much information. In addition, we do run multi-part series on various topics.

In short, we do not want to limit you in terms of article length, so please use the word count above as a general guideline and if you have specific questions, please do not hesitate to contact us.

Text formatting

Please use single spacing and un-indented paragraphs for your text. Just place an extra blank line between paragraphs.

We also ask that you forego any special formatting beyond the use of italics and boldface, and make sure that all text is left justified.

If you would like to emphasize certain words within the text, please only use italics (do not use underlining or a larger font size). Boldface is reserved for article headers.

Please do not 'center' text on the page, add special tab stops, or use underlining as all of this must be removed before layout. If you require a special layout, please let the word processing programme you are using help you to do this formatting rather than doing it by hand on your own.

If you need to make a list, or add footnotes or endnotes, please let the Word processing programme do it for you automatically. There are menus in every programme that will help you to do this. The fact is that no matter how careful one might be, errors have a way of creeping in when you try to hand number footnotes and literature lists.

Image requirements

Please number images consecutively throughout the article by using a new number for each image. If it is imperative that certain images are grouped together, then use lowercase letters to designate the images in a group (ie, 2a, 2b, 2c).

Please put figure references in your article wherever they are appropriate, whether that is in the middle or end of a sentence. If you are not directly mentioning the figure in the body of your article, when it appears at the end of the sentence the figure reference should be enclosed within parenthesis and be inside the sentence, meaning before the period.

In addition, please note:

- _ We require images in TIF or JPEG format.
- _ These images must be no smaller than 6 x 6 cm in size at 300 DPI.
- _ Images cannot be any smaller than 80 KB in size (or they will print the size of a postage stamp!).

Larger images are always better, and something on the order of 1 MB is best. Thus, if you have an image in a large size, do not bother sizing it down to meet our requirements but send us the largest file sizes available. (The larger the starting image is in terms of bytes, the more leeway the designer has in terms of resizing the image to fill up more space should there be room available).

Also, please remember that you should not embed the images into the body of the text document you submit. Images must be submitted separately from the textual submission.

You may submit images through a zipped file via E-mail, unzipped individual files via E-mail, or post a CD containing your images directly to us (please contact us for the mailing address as this will depend upon where in the world you will be mailing them from).

Please do not forget to send us a head shot photo of yourself that also fits the parameters above so that it can be printed along with your article.

Abstracts

An abstract of your article is not required. However, if you choose to provide us with one, we will print it in a separate box.

Contact info

At the end of every article is a Contact Info box with contact information along with a head shot of the author. Please note at the end of your article the exact information you would like to appear in this box and format it according to the previously mentioned standards. A short bio may precede the contact info if you provide us with the necessary information (60 words or less).

Questions?

Please contact us for our Author Kit, or if you have other questions:

Managing Editor

Claudia Salwiczek
c.salwiczek@dental-tribune.com

cosmetic dentistry

_ beauty & science

asia pacific edition

dti Dental
Tribune
International

Publisher

Torsten R. Oemus
t.oemus@dental-tribune.com

Editor-in-Chief

Dr Sushil Koirala
skoirala@wlink.com.np

Co-Editor-in-Chief

Dr So-Ran Kwon
smileksr@hotmail.com

Managing Editor

Claudia Salwiczek
c.salwiczek@dental-tribune.com

Product Manager

Bernhard Moldenhauer
b.moldenhauer@dental-tribune.com

Executive Producer

Gernot Meyer
g.meyer@dental-tribune.com

Designer

Nadine Ostermann
n.ostermann@dental-tribune.com

Copy Editors

Sabrina Raaff
Hans Motschmann

International Administration

President/CEO

Peter Witteczek
p.witteczek@dental-tribune.com

Executive Vice President

Finance

Dan Wunderlich
d.wunderlich@dental-tribune.com

International Media Sales

Europe
Antje Kahnt
a.kahnt@dental-tribune.com

Asia Pacific

Peter Witteczek
p.witteczek@dental-tribune.com

North America

Humberto Estrada
h.estrada@dtamerica.com

International Offices

Europe

Dental Tribune International GmbH
Contact: Nadine Parczyk
Holbeinstr. 29
04229 Leipzig, Germany
Tel.: +49 341 484 74 302
Fax: +49 341 484 74 173
www.dti-publishing.com

Asia Pacific

Dental Tribune Asia Pacific Ltd.
Contact: Tony Lo
Room A, 26/F, 389 King's Road
North Point, Hong Kong
Tel.: +852 3113 6177
Fax: +852 3113 6199
www.dti-publishing.com

The Americas

Dental Tribune America, LLC
Contact: Anna Wlodarczyk
213 West 35th Street, Suite # 801
New York, NY 10001, USA
Tel.: +1 212 244 7181
Fax: +1 212 244 7185
www.dti-publishing.com

Advisory Board

Dr Michael Miller, USA
Dr Seok-Hoon Ko, Korea

Editorial Board

Dr Anthony Au, Australia
Dr Bao Baicheng, China
Dr Helena Lee, Singapore
Dr Hisashi Hisamitsu, Japan
Dr Jiraporn Charudilaka, Thailand
Dr Mostaque H. Sattar, Bangladesh
Dr Ratnadeep Patil, India
Dr Sim Tang Eng, Malaysia
Dr Suhit Raj Adhikari, Nepal
Dr Takashi Nakamura, Japan
Dr Vijayaratnam Vijayakumaran, Sri Lanka

cosmetic dentistry Copyright Regulations

cosmetic dentistry asia pacific edition is published by Dental Tribune Asia Pacific Ltd. and will appear in 2009 with one issue every quarter. The magazine and all articles and illustrations therein are protected by copyright. Any utilisation without the prior consent of editor and publisher is inadmissible and liable to prosecution. This applies in particular to duplicate copies, translations, microfilms, and storage and processing in electronic systems.

Reproductions, including extracts, may only be made with the permission of the publisher. Given no statement to the contrary, any submissions to the editorial department are understood to be in agreement with a full or partial publishing of said submission. The editorial department reserves the right to check all submitted articles for formal errors and factual authority, and to make amendments if necessary. No responsibility shall be taken for unsolicited books and manuscripts. Articles bearing symbols other than that of the editorial department, or which are distinguished by the name of the author, represent the opinion of the afore-mentioned, and do not have to comply with the views of Dental Tribune Asia Pacific Ltd. Responsibility for such articles shall be borne by the author. Responsibility for advertisements and other specially labeled items shall not be borne by the editorial department. Likewise, no responsibility shall be assumed for information published about associations, companies and commercial markets. All cases of consequential liability arising from inaccurate or faulty representation are excluded. General terms and conditions apply, legal venue is North Point, Hong Kong.

Dental Tribune International GmbH | Contact: Nadine Parczyk
 Holbeinstraße 29 | 04229 Leipzig | Germany
 Tel.: +49 341 484 74 330 | Fax: +49 341 484 74 173
 n.parczyk@dental-tribune.com | www.dental-tribune.com



www.dental-tribune.com



I hereby order 4 issues of **COSMETIC DENTISTRY** for 35 € (1 year)*

I hereby order 4 issues of **ROOTS** for 35 € (1 year)*

I hereby order 20 issues of **DENTAL TRIBUNE GERMAN EDITION** for 70 € (1 year)*

I hereby order 10 issues of **DENTAL TRIBUNE ASIA PACIFIC EDITION** for 55 € (1 year)*

I hereby order 10 issues of **DENTAL TRIBUNE AUSTRIAN EDITION** for 55 € (1 year)*

PAYMENT OPTIONS

PayPal
 subscriptions@dental-tribune.com

Bank Transfer
 Commerzbank Leipzig
Account No.: 11 40 201
Bank Code: 860 400 00
BIC: COBADEFF
IBAN: DE57860400000114020100

*plus shipping and handling. Your personal data will be recorded and retained by Dental Tribune International GmbH, which has its registered office in Holbeinstr. 29, 04229 Leipzig, Germany. Your personal data is used for internal purposes only. After the payment has been made, the shipping process for the subscribed publication(s) will start. The subscription will be renewed automatically every year until it is cancelled six weeks in advance to the renewal date.

PERSONAL DETAILS/SHIPPING ADDRESS

Name _____
 Position _____
 Department _____
 Organisation _____
 Address _____
 Country _____
 Telephone _____
 Facsimile _____
 E-mail _____

Date/Signature _____

Fax form to: +49 341 484 74 173 or subscribe online at www.dental-tribune.com



AESTHETIC. DURABLE. PERFECT.

StructurPremium

Superior temporaries for the most ambitious demands

- Aesthetic like porcelain
high colour stability, natural fluorescence and brilliant gloss
- As hard as enamel
extremely high fracture resistance, material hardness and transverse strength
- Perfect handling
convenient work steps, easy to trim and polish

