

Permanent implant prostheses

Chairside manufacture of a hybrid abutment crown

Authors Dr Arzu Tuna, Dr Umut Baysal & Dr Rainer Valentin, Germany

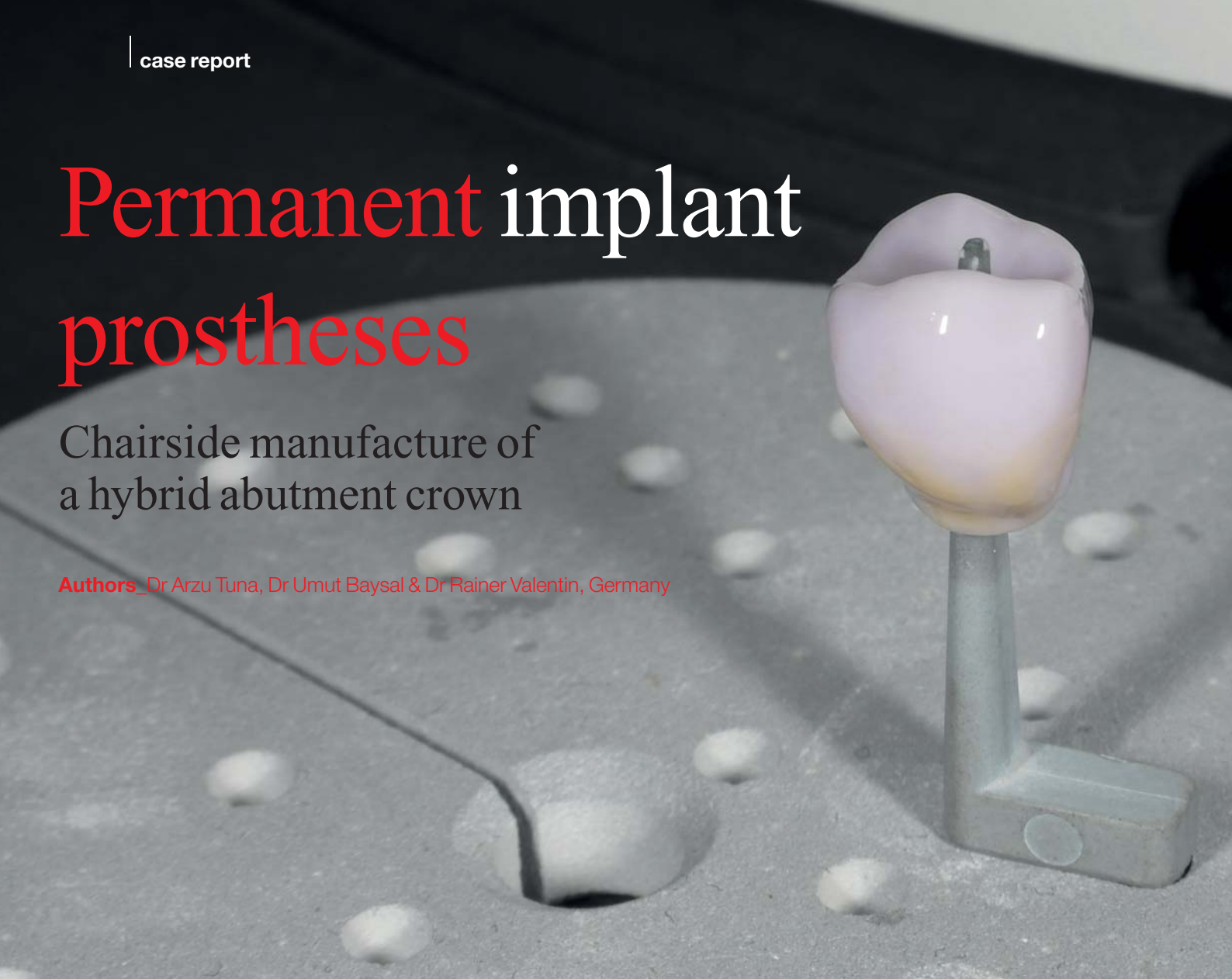

Fig. 1 Tooth 26, which proved not worth preserving, after root resection.

Fig. 2 The state of tooth 26 after extraction.

Fig. 3 Implantation after 12 weeks.

In the past ten years, CAD/CAM restorations have been established as standard in implant prostheses. The advantages of such restorations include the chairside use of full ceramics and digital impressions. Owing to the introduction of ceramic blocks with prefabricated twist-proof screw channels, the workflow for the chairside manufacture of individual hybrid abutments and hybrid abutment crowns can be applied in daily practice. By means of the cases reported in this article, the indications, suitable materials and attachments, and related studies are discussed.

Case reports

Case 1

In September 2013, a 35-year-old patient came into our practice for the first time. The general anamnesis found no peculiarities. She complained of pain in the second quadrant. The clinical and the radiological examination found that tooth 26 was not worth preserving (Fig. 1). The patient was subsequently informed of the treatment options, which were revision of the root canal filling, and a second root resection and extraction with subsequent im-

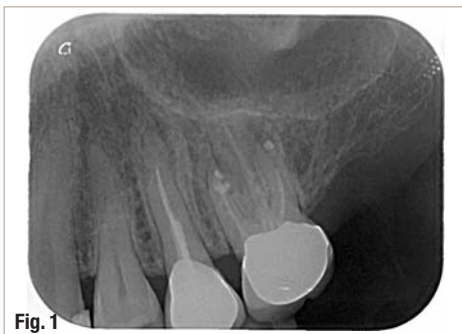

Fig. 1

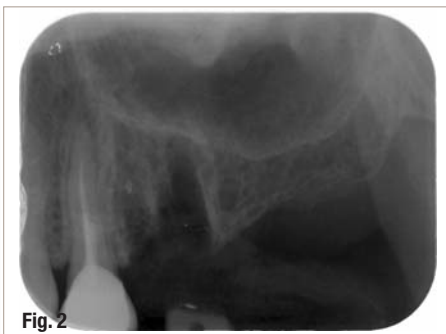

Fig. 2

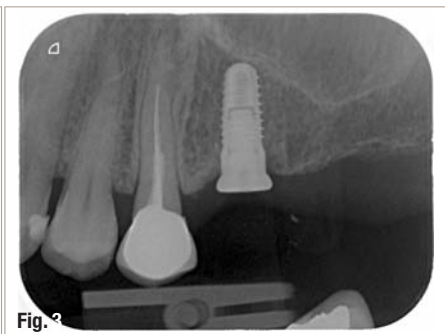

Fig. 3

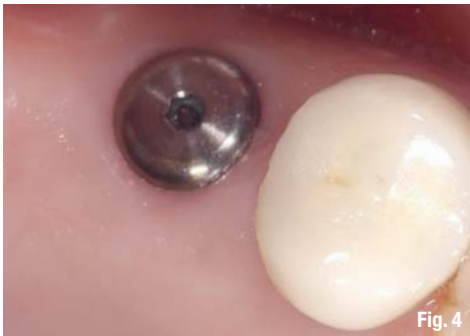

Fig. 4

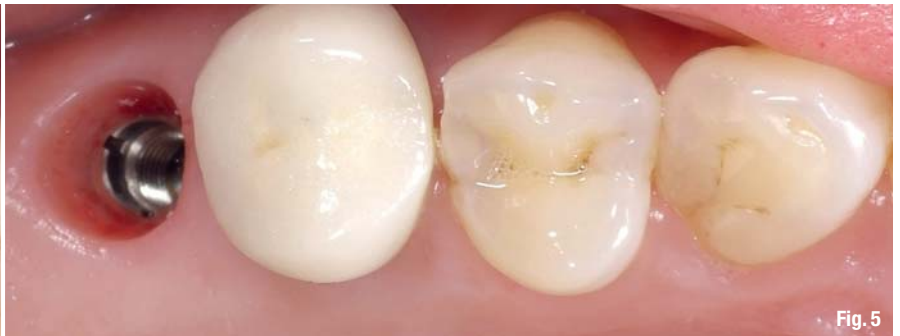

Fig. 5



Fig. 6

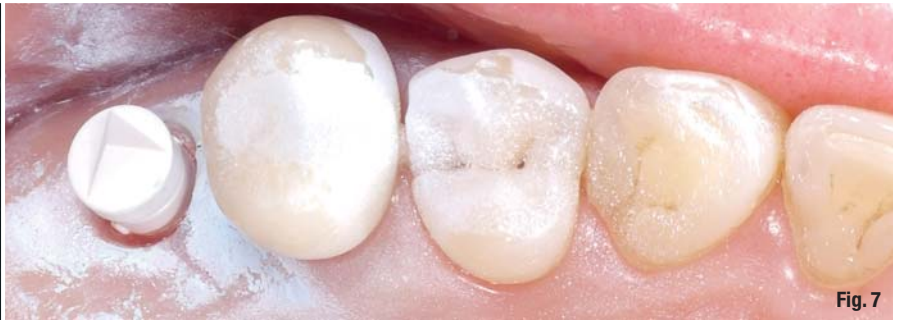

Fig. 7

plantation. Finally, tooth 26 was extracted and implantation followed 12 weeks later (4.3 mm x 9 mm CAMLOG implants; Figs. 2–4). We decided against closed healing and the implant was closed with a flat gingiva former (2 mm). With this, a further operation to expose the implant could be avoided.

Chairside workflow

Ten weeks after implantation, the prosthetic restoration was performed in one session without a physical model. A digital impression was taken by means of CEREC Bluecam (Sirona Dental Systems). Since no exposure of the implants was necessary and there were no open wound edges, we were able to use the powder for the scanning procedure without any concerns (Fig. 5). After the insertion of the CAMLOG TiBase (Sirona Dental Systems; Fig. 6), which served as the titanium adhesive abutment for the chairside-manufactured hybrid abutment crown made of lithium disilicate (IPS e.max, Ivoclar Vivadent), the appropriate scan body (Sirona Dental Systems; Fig. 7) was placed on the TiBase. Before taking the impression, the placement of the TiBase was radiologically controlled (Fig. 8).

The virtual construction was created by means of CEREC Software 4.2 (Sirona Dental Systems) and was built up similar to the crown's construction. An advantage of the virtual construction is the more flexible control of the emergence profile. The pressure on the gingiva can be adjusted individually, and displacements of about 5 mm have proven to be unproblematic.

Further parameters, such as minimum strength and position of the screw channels, should be adjusted and included in the construction according to the manufacturer's instructions. The manufacture of the hybrid abutment crown was achieved with the CEREC MC XL milling unit (Sirona Dental Systems; Fig. 9). After the colour determination, the low translucency A2 A16 (L) ceramic block was selected.

After glazing and colouring, the crystallisation or combination firing was done (Programat CS, Ivoclar Vivadent). The monolithic polished abutment crown was then extra-orally attached (Multilink Hybrid Abutment, Ivoclar Vivadent) to the TiBase (Fig. 10). The hybrid abutment crown was screwed in and the

- Fig. 4** Four weeks after implantation.
- Fig. 5** The situation before the digital impression.
- Fig. 6** CAMLOG TiBase.
- Fig. 7** Preparation for the digital impression.

- Fig. 8** Radiological control of the TiBase.
- Fig. 9** The hybrid abutment produced by the milling unit.
- Fig. 10** The hybrid abutment crown with luting composite.

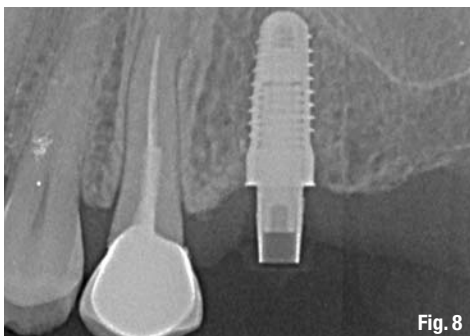


Fig. 8



Fig. 9

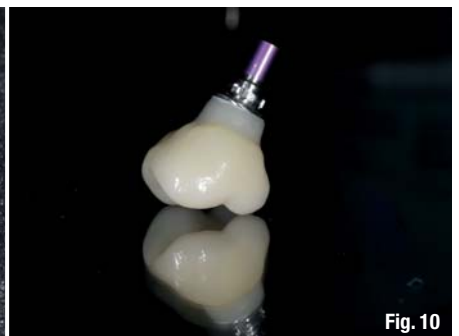

Fig. 10

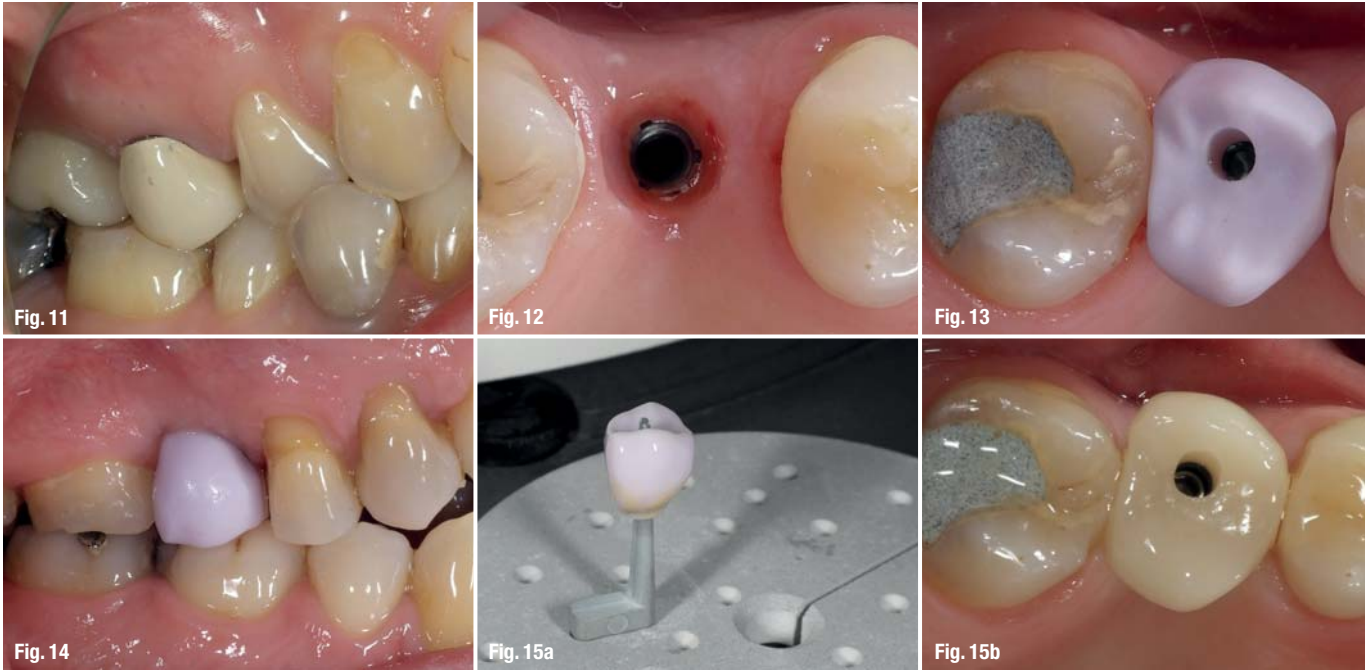


Fig. 11_Intraoral view after insertion.

Fig. 12_Case 2: three months after implantation.

Figs. 13& 14_Try-in of the hybrid abutment crown before crystallisation firing.

Fig. 15 a_The hybrid abutment crown on the firing tray before crystallisation firing.

screw channel was sealed with PTFE tape (3M ESPE) and composite (IPS Empress Direct, Ivoclar Vivadent; Fig. 11).

Cases 2 and 3

Figures 12 to 18 illustrate the cases of the second and third patients. Both patients were treated following the same treatment plan described in the first case.

show the try-in of the hybrid abutment crown before crystallisation firing. After the try-in, the polished ceramic crown was glazed, coloured and filled with auxiliary firing paste (IPS Object Fix Putty, Ivoclar Vivadent; Figs. 15a-c). Case 3 shows restoration in region 15 (Figs. 16-18).

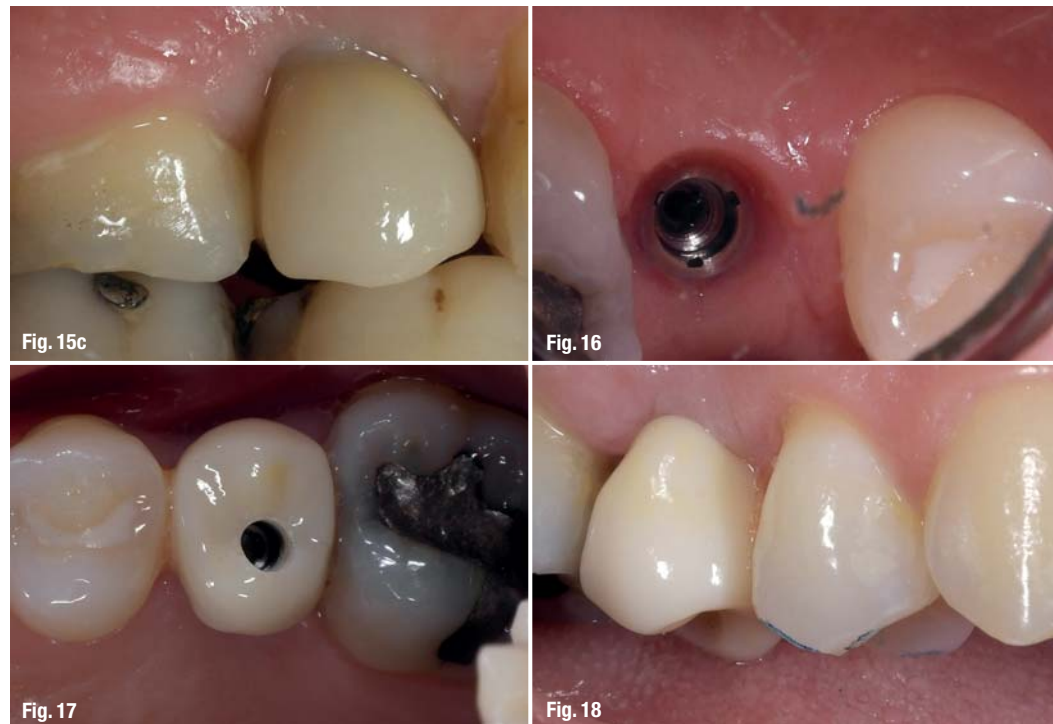_Discussion

Restoration using CAD/CAM methods has been established as standard in implant prostheses. Besides the industrial manufacture of materials and the

Case 2 demonstrates the prosthetic restoration of an implant in region 26 (Fig. 12). Figures 13 and 14

Figs. 15b & c_Intra-oral view of the crown.

Figs. 16-18_Case 3: implant restoration in regio 15.



consequent high quality, the individualised, tooth-coloured design of the emergence profile and flexibility regarding construction (angulation, dimension) are further advantages. Furthermore, digital treatment concepts offer the possibility of chairside restoration and shortened treatment duration without compromising the healing period. Systems that do not require the use of powder offer the possibility of detecting the implant position during implant insertion and thus the possibility of a prosthetic restoration during exposure. In this way, the design and dimensions of the superstructure can be ideally created without the need for individual gingiva formers. From an aesthetic aspect, it makes sense to have a natural and tooth-coloured emergence profile. In view of possible recession, the risk of exposed metallic elements can be avoided.

Conclusion

As described in the cases reported, the hybrid abutment and the hybrid abutment crown together offer a suitable alternative to full-ceramic abutments made of zirconium dioxide ceramic. Contrary to zirconium dioxide abutments, the mating surface to the implant body is made of titanium and not of zirconium dioxide ceramic. Since zirconium dioxide ceramic is harder than titanium, the implant body can be affected by material abrasion, which appears to be confirmed by recent studies. In addition, a dark discolouration of the surrounding gingiva can arise from the worn-off titanium particles, similar to amalgam tattoos. In aesthetically significant areas, such as the anterior maxillary zone, this would be a serious complication and could arise years after insertion. Regarding the adhesive bond between the TiBase and abutment body, the initial data is very promising. If adhesion is performed carefully according to manufacturer's instructions, it should not fail.

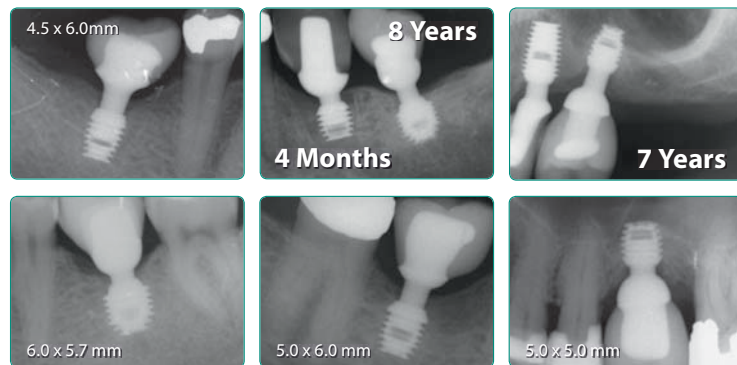
Finally, further studies are needed to clarify the biocompatibility of adhesive gaps with the surrounding tissue positioned 0.4 mm from the implant shoulder and ideally also from the bone.

contact

implants

Dr Arzu Tuna
Dr Umut Baysal
 Praxis am Nordwall
 Nordwall 2
 57439 Attendorn, Germany

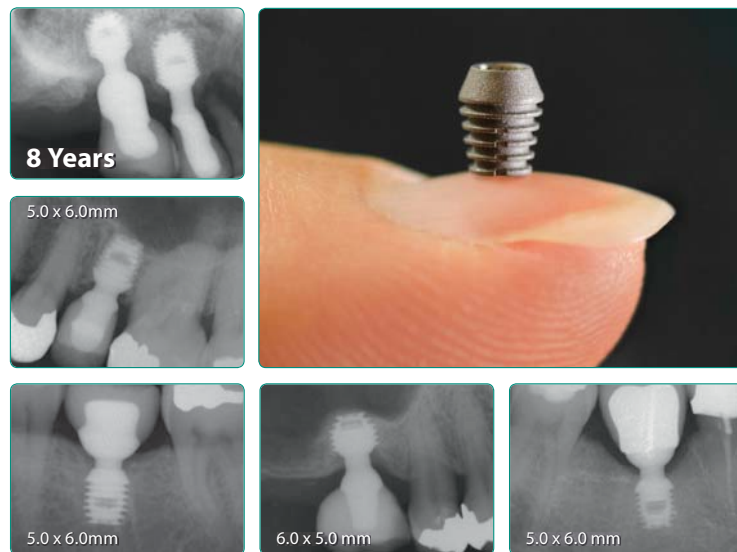
www.zahnarzt-attendorn.de



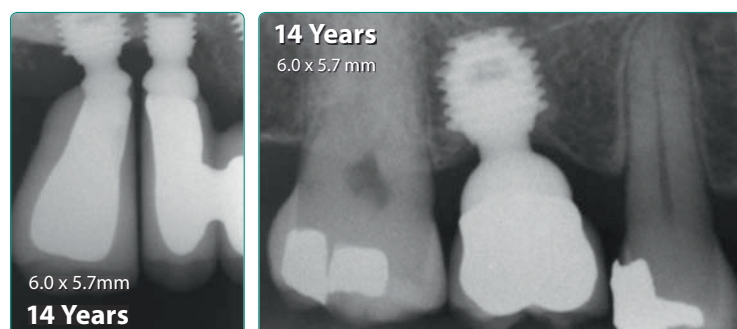
SHORT IMPLANTS

Since 1985

- » Simple.
- » Predictable.
- » Profitable.



**SHORTEST IMPLANTS
LONGEST HISTORY**



bicon[®]
DENTAL IMPLANTS

Bicon Europe Ltd. ■ Hauptstr. 1 ■ 55491 Buechenbeuren
 Germany ■ Phone +49 (0)65 43 / 81 82 00 ■ Fax +49 (0)65 43 / 81 82 01
germany@bicon.com ■ www.bicon.de.com