

Restoration of endodontic teeth: An engineering perspective

Author_ Dr Gregori M. Kurtzman, USA

_ce credit

roots



This article qualifies for CE credit. To take the CE quiz, log on to www.dtstudyclub.com. Click on 'CE articles' and search for this edition of the magazine. If you are not registered with the site, you will be asked to do so before taking the quiz. You may also access the quiz by using the QR code.

_Introduction

Identifying the canals and negotiating them to be able to instrument and obturate the tooth is necessary to clinical success. But restoration of the endodontically treated tooth is critical to long-term success. It does not matter if we can complete the endodontic portion of treatment if the tooth cannot be restored. With this in mind, we need to look at the restoration phase from an engineering perspective. What is needed to reinforce the remaining tooth so that it can manage the repetitive loading that occurs during mastication? This article will discuss the importance of ferrule in adhesive dentistry as well as when to use posts and what materials are best.

_Ferrule: How important is it today?

Ferrule was an important concept in dentistry but has been de-emphasized with the bonding evolution. Yet this concept is as important today as it was prior to dental bonding. But what is a ferrule? A ferrule is a band that encircles the external dimension of residual tooth structure, not unlike the metal bands that exist around a barrel to hold the slats together. Sufficient vertical height of tooth structure that will be grasped by the future crown is necessary to allow for a ferrule effect of the future prosthetic crown; it has been

shown to significantly reduce the incidence of fracture in the endodontically treated tooth.^{1,2}

Important to this concept is the margin design of the crown preparation, which may include a chamfer or a shoulder preparation. Because a chamfer margin has a bevelled area that is not parallel to the vertical axis of the tooth, it does not properly contribute to ferrule height. Therefore, when a chamfer is utilized it would require an additional 1 mm of height between the edge of the margin and the top aspect of the coronal portion of remaining tooth structure. Thus, use of a chamfer may not be the best margin design when restoring endodontically treated teeth or those teeth with significant portions of missing tooth structure. With today's movement toward scanning and milling for fixed prosthetics, whether done in the practitioner's office or at the laboratory, it should be noted that it is difficult to scan the internal aspect of a shoulder preparation and it has been uniformly recommended that a rounded shoulder be used. The rounded shoulder preparation provides the maximum vertical wall at the margin, with the internal aspect being slightly rounded versus at a 90-degree angle. This ensures better replication of the margins when scanned and milled.

Some studies suggest that while ferrule is certainly desirable, it should not be provided at the expense of the remaining tooth/root structure.³

Alternatively, it has also been shown that the difference between an effective, long-term restoration and restorative failure can be as small as 1 mm of additional tooth structure that, when encased by a ferrule, provides greater protection. When such a long-lasting, functional restoration cannot be predictably created, osseous crown lengthening should be considered to increase what tooth structure is available to achieve a ferrule, but this is also dependent on the periodontal status of the tooth, and

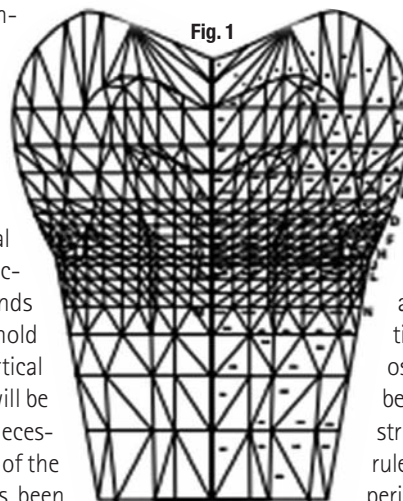


Fig. 1 Strain analysis of a posterior tooth demonstrating concentration of strain on loading at the cervical. (Image/Dr Gene McCoy)

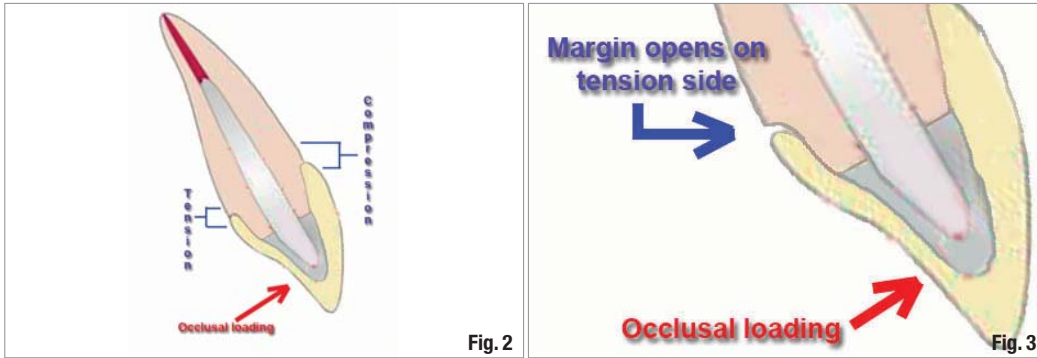


Fig. 2 As a maxillary anterior tooth is loaded during mastication, tension and compression occur at the crown's margins.

(Images/Dr Gregori M. Kurtzman)
Fig. 3 Opening of the margin on the tension side may lead in time to recurrent decay or restoration and endodontic failure.

when ferrule cannot be achieved then extraction should be considered.⁴ Ichim, et al, stated succinctly, "The study confirms that a ferrule increases the mechanical resistance of a post/core/crown restoration."⁵

How much ferrule is required?

When rebuilding an endodontically treated tooth, it is best to maintain all dentin that is available, even thin slivers. These thin slivers of dentin provide a strong connecting link between the core and tooth's root and between the crown and root.⁶ It is important to attempt to retain as much tooth structure as possible, and this aids in achieving ferrule as well as maintaining cervical strength of the tooth where loading concentrates. Under masticatory loading, strain concentrates at the cervical portion of teeth, thus it is important to avoid over-preparation of this portion of the tooth during endodontic treatment and preserve this area during restoration of the tooth (Fig. 1).

Multiple studies discussing how much ferrule is required have found that teeth with at least 2 mm of ferrule have significantly greater long-term prognosis from a restorative standpoint than those with less or no ferrule. Libman, et al, reported, "Fatigue loading of

cast post and cores with complete crowns of different ferrule designs provide evidence to support the need for at least a 1.5-mm to 2.0-mm ferrule length of a crown preparation. Crown preparation with a 0.5-mm and 1.0-mm ferrule failed at a significantly lower number of cycles than the 1.5-mm and 2.0-mm ferrules and control teeth."⁷ Libman further demonstrated when loading at an off-axis direction, which occurs in the maxillary anterior, at the restoration's margin the side where the load is originating is under tension, whereas the opposing side is under compression (Fig. 2). This repetitive loading and micro strain due to tension at the lingual margin leads to the margin opening, which may lead to recurrent decay and/or failure of the endodontic seal or restoration (Fig. 3).

Additionally, if we look at strain studies by Libman and others comparing ferrule of different heights, we observe that in a ferrule of 0.5 mm there is greater strain at the margin under tension and concentrates at mid tooth where the core or post is situated. Teeth with 2.0 mm of ferrule demonstrated significantly less strain loading at the margins or centre of the cervical aspect of the tooth. The lower the strain at the cervical midpoint, the less chance of overload and failure restoratively (Fig. 4).

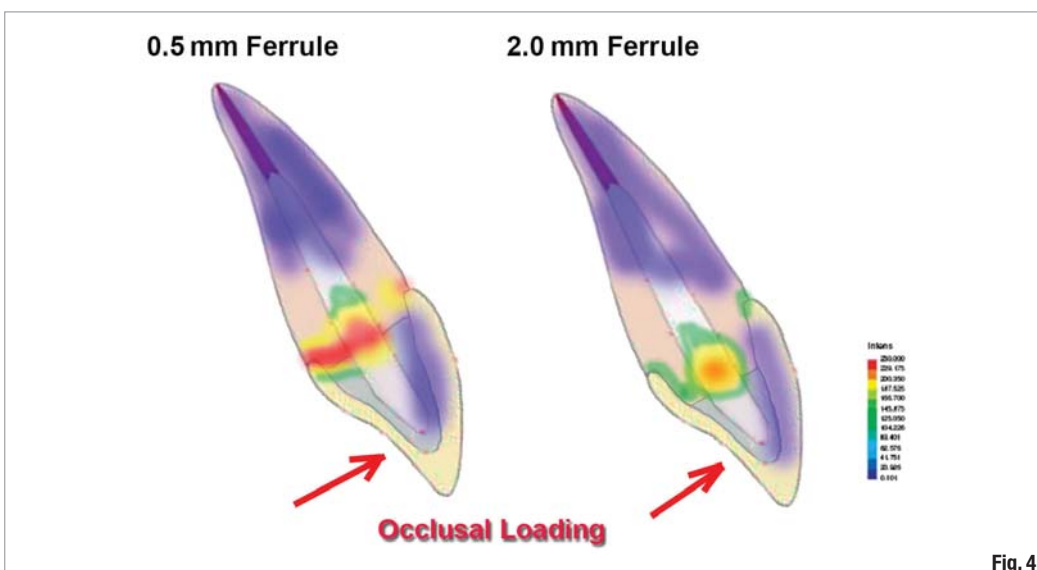


Fig. 4 Difference of intensity of strain and location related to ferrule height during occlusal loading (Libman).

Fig. 5_ Comparison of load distribution of fiber posts compared to a cast post and prefabricated metal post.

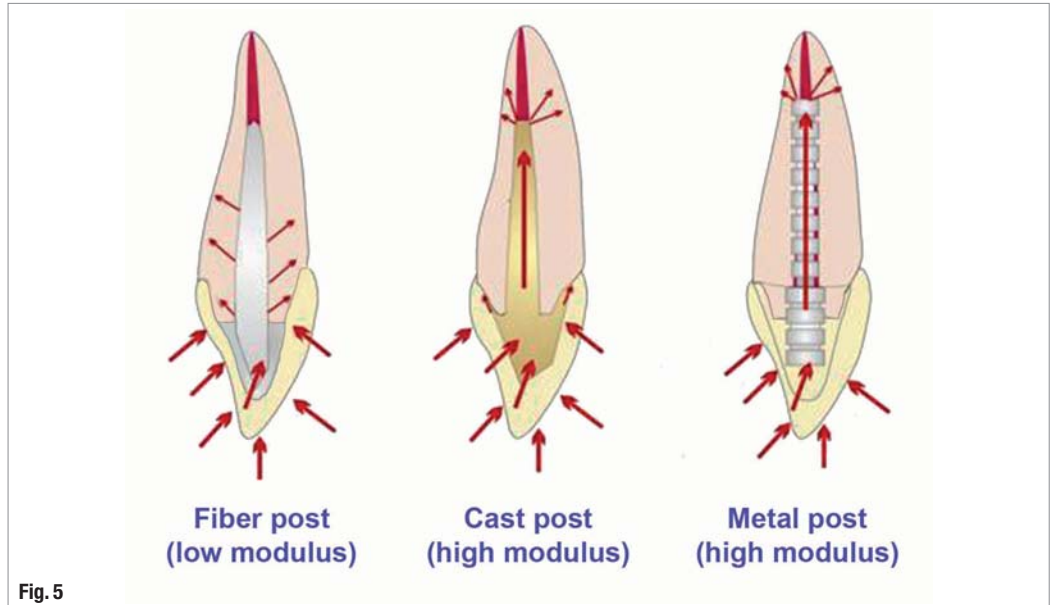


Fig. 5

_Detecting failure at the coronal seal

It is not unusual to have a patient present for a routine recall appointment and the clinician or hygienist note recurrent decay at a crown margin with the patient unaware of the issue. This becomes more complicated with teeth that have previously undergone endodontic treatment, as there is no pulp present that could warn the patient an issue is present until often extensive decay occurs or the crown dislodges from the remaining tooth. Freeman, et al, in their published study, stated, "Fatigue loading of three different post and core designs with the presence of a full cast crown leads to preliminary failure of leakage between the restoration and tooth that is clinically undetectable."⁸

The literature supports that coronal leakage may be a major factor in failure of endodontic treatment.⁹⁻¹¹ As previously discussed, when loaded during mastication, margins with inadequate ferrule may demonstrate micro opening on the tension side, leading to leakage over time. This initially may be observed as recurrent decay, but as it deepens and exposure of the obturation material results, failure of the endodontics may result due to apical migration of oral bacteria. This is minimized when a bonded core or post/core is present, but given sufficient time when a ferrule of sufficient height is not present the endodontics or the restoration will fail.

_Do all posts function the same?

Teeth function differently, depending on the material that the post is fabricated from, with loads distributed within the root relative to the modulus of elasticity of the post compared to the dentin of the root (Fig. 5).

When a tooth restored with a fiber post does fail due to overload, the mode of failure is coronal, protecting remaining root and tooth structure.¹² This mode of failure with fiber-post-restored teeth typically allows the tooth to be restored, as vertical root fracture is a rare occurrence. Bitter reported, "Compared to metal posts, FRC posts revealed reduced fracture resistance in vitro, along with a usually restorable failure mode"¹³ (Fig. 6). Whereas, with metal posts either prefabricated or cast, failure was at a higher value for cast post and core 91 per cent of the specimens had fractured roots, none of the specimens with a fiber post demonstrated root fracture; the post and core usually fractured at the tooth composite core interface.¹⁴ As stress concentrates at the apical tip of the metal post due to its higher modulus of elas-

Fig. 6_ Tooth restored with a fiber post demonstrating coronal horizontal fracture supracrestally typically seen with teeth restored with fiber posts when overloaded.

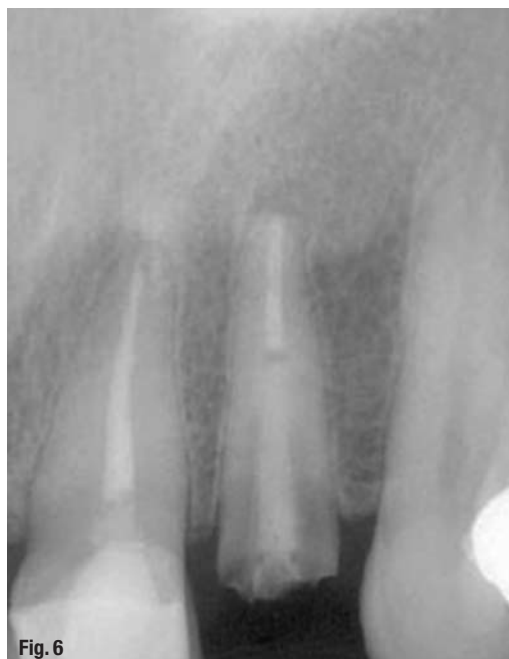

Fig. 6

ticity than the surrounding root, vertical root fracture is a frequent occurrence (Fig. 7). This may result also from breakdown of the cement luting the post to the root, allowing slippage microscopically of the post in the tooth under load, leading to torque at the cervical area and the resulting vertical root fracture.

As metal posts are stiffer (higher modulus of elasticity) than the dentin of the root, with metal posts stress concentrated at the posts apical leading to vertical root fracture and catastrophic loss of the tooth. Ansari reported, "The risk of failure was greater with metal-cast posts (nine out of 98 metal posts failed) than with carbon fiber posts (using which, none out of 97 failed) risk ratio."¹⁵ But with fiber posts having a flexibility equal or greater than the root (lower modulus of elasticity) stress concentrated at the cervical region leading to horizontal fracture of the post and core and typically the tooth can be salvaged.

The elastic modulus refers to the relative rigidity of the material. The stiffer the material, the higher its relative modulus. When two different materials are placed together, as an example, a post is placed into a tooth's root the elastic modulus is influenced by whichever of the materials is stiffest. Dentin averages a modulus of elasticity of 17.5 (+/- 3.8) GPa, with glass fiber posts at 24.4 (+/- 3.4) GPa, titanium prefabricated posts at 66.1 (+/- 9.6) GPa, prefabricated stainless steel at 108.6 (+/- 10.7) GPa and cast high noble gold posts at 53.4 (+/- 4.5) GPa. Cast posts fabricated from noble or base metals have higher modulus than high noble alloys and approach stainless-steel prefabricated posts in their relative stiffness. Fiber posts have an elastic modulus that more closely approaches that of dentin (Fig. 8). The flexural strength of fiber and metal posts was respectively four and seven times higher than root dentin, and there is still debate on whether a post strengthens the tooth.^{16,17} The basic purpose of a post is to aid in retention of the core.

The absence of a cervical ferrule has been found to be a determining negative factor, giving rise to considerably higher stress levels within the root. When no ferrule was present, the prefabricated metal post/composite combination generated greater cervical stress than cast post and cores. Yet, the ferrule seemed to cancel the mechanical effect of the reconstruction material on the intensity of the stresses. With a ferrule, the choice of reconstruction material had no impact on the level of cervical stress. The root canal post, the purpose of which is to protect the cervical region, was also shown to be beneficial even with sufficient residual coronal dentin. In the presence of a root canal post, cervical stress levels were lower than when no root canal post was present. Pierrisnard concluded that the higher the elasticity modulus, the lower the stress levels.¹⁸

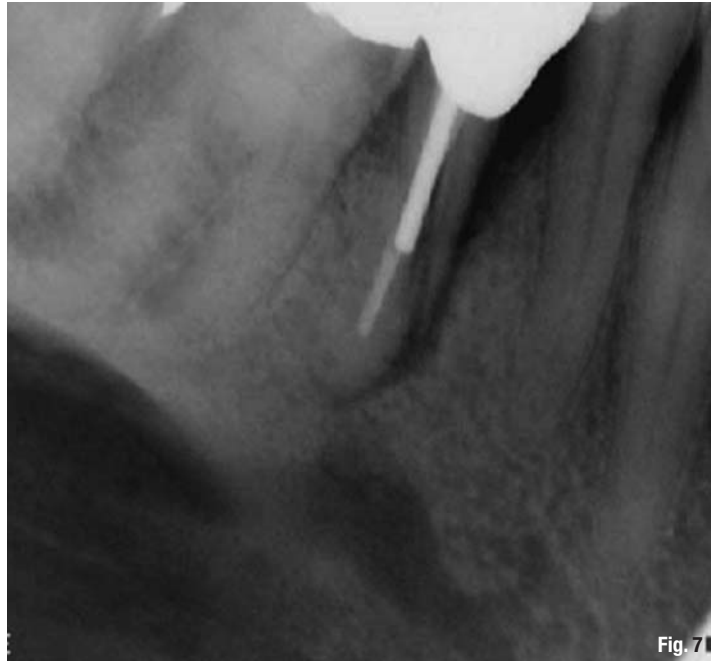
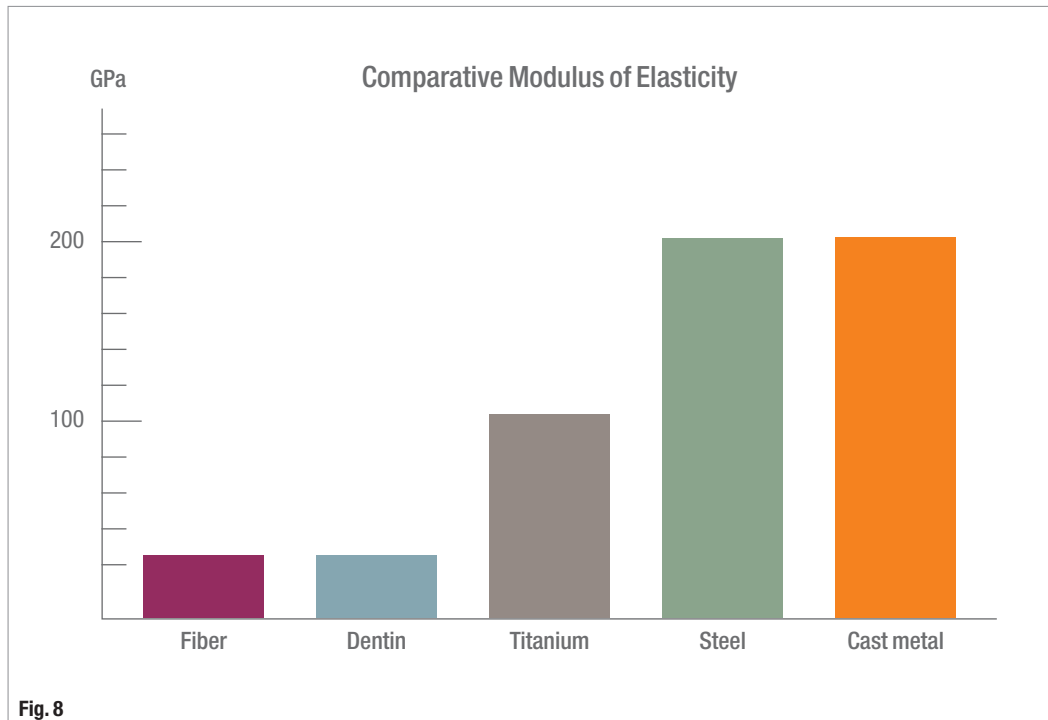


Fig. 7 Vertical root fracture of a tooth restored with a metal post.

The material the post is fabricated from should have the same modulus of elasticity as the root dentin to distribute the applied forces along the length of the post and the root and not concentrate them at the apical tip of the post. Studies have shown that when components of different rigidity are loaded, the more rigid component is capable of resisting forces without distortion. This stress is concentrated when the post is the stiffer material at the posts apical tip. The less-rigid component fails invariably when a post is used that is stiffer than the root's dentin.¹⁹ Posts with modulus of elasticity significantly greater than that of dentin create stresses at the tooth/cement/post interface, with the possibility of post separation and failure. As repetitive loading occurs on the endodontically restored tooth, the cement eventually fails at the interface between the metal post and root dentin, allowing microslippage of the post. This allows higher stresses to be exerted on the root, leading to vertical root fracture and catastrophic loss of the tooth. The higher modulus (rigidity) of the metallic posts makes it stiff and unable to absorb stresses. In addition, transmission of occlusal and lateral forces through a metallic core and post can concentrate stresses, resulting in the possibility of unfavorable fracture of the root.²⁰ Dentin's modulus of elasticity is approximately 14 to 18 GPa. Fiber posts have modulus that is approximately 9 to 50 GPa, depending on the manufacturer of the post. This provides a similarity in elasticity between the fiber post and dentin of the root, allowing post flexion to mimic tooth flexion. The fiber post absorbs and distributes the stresses and thus shows reduced stress transmission to the root.²¹ The longitudinal arrange-

Fig. 8 Comparative modulus of elasticity of different post materials.



ment of fibers in the fiber post and the modulus of elasticity of a post that is less than or equal to that of the dentin may redistribute the stress into the tooth and away from the chamfered shoulder to increase the likelihood of failure of the post core/root interface instead of root fractures. When failure does occur due to overloading, failure typically is in the coronal portion, frequently demonstrating fracture of the core at the tooth interface and leaving the possibility of re-restoring the tooth and not catastrophic loss.²²

The flexural properties of fiber posts were higher than the metal post and similar to dentin.²³

Whereas, pre-fabricated, stainless-steel post exhibited a significantly higher fracture resistance at failure when compared with the fiber posts. The mode of failure of the carbon fiber post was more favorable to the remaining tooth structure when compared with the pre-fabricated stainless steel post and the ceramic post.²⁴

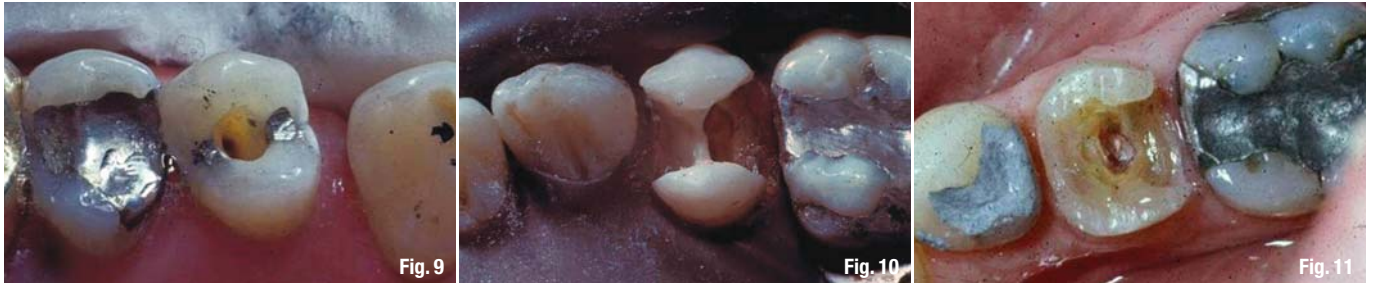Ceramic posts were introduced prior to fiber posts as a more esthetic alternative to prefabricated metal posts, and, although not widely used today, they are still available. Modulus of elasticity of ceramic posts is 170–213 GPa, which is approximately 15 times that of dentin. As these ceramic posts are too rigid and transmit more stress to the root canal than the fiber posts, which lead to irreversible root damage via vertical root fracture seen with metal posts, their use is not recommended in restoring endodontically treated teeth today.²⁵

Decision making for restoration of endodontically treated teeth

Restoration of endodontically treated teeth needs to take an engineering view of how best to reconstruct the remaining tooth for the best long-term survival. With this in mind, the practitioner needs to categorize the tooth based on how much native tooth structure is present following endodontic treatment and how much existing restorative material is currently present in the tooth.

Minimal tooth missing or previously restored:

Posterior teeth gain strength when the marginal ridge area and proximal surface is natural tooth structure and has not been restored. Teeth that have undergone endodontic treatment when either occlusal decay was present in the pits and fissures leading to pulpal involvement or a small- to moderate-sized previously placed amalgam or composite restoration is present require conservative restoration (Fig. 9). These teeth can be restored with removal of the existing restorative material and cleaning the pulp chamber of obturation material including 2 to 3 mm of the canal. Placement of a conventional composite bonded within the tooth provides a good long-term restorative solution to these teeth, and a crown is not needed typically. The access or existing restoration should leave most of the cuspal width present. When the preparation following removal of decay and existing restorative materials invades the width of the cusplaving half of this tooth structure missing, more extensive restoration is indicated.



Moderate tooth structure missing or previously restored:

When the tooth to be restored is missing one or both marginal ridges and these areas have been previously restored or will be restored, placement of a bonded composite will not suffice as the final restoration (Fig. 10). The marginal ridges provide resistance to cuspal flexure of the tooth, improving its strength. When these are missing, functional loading of the tooth will allow greater cuspal flexure and consequently a higher chance of fracture under masticatory function. Restoration of these teeth will require a core buildup with optional pins or other retentive elements for the core followed by a full coverage crown. Posts are often not needed, as the remaining tooth structure at the cusps after crown preparation is sufficient to retain the core and a ferrule can be achieved. A post may be considered in those patients who are bruxers or clenchers or whose occlusion may place higher forces on the restored tooth due to the tooth's position relative to the occlusal plane. When a ferrule cannot be achieved, the practitioner should consider osseous crown lengthening or forced eruption to improve the ferrule. Inlay restorations should be avoided in endodontically treated teeth because the access created to perform the endodontic treatment weakens the tooth from a cuspal flexure standpoint and the inlay even when bonded may act as a wedge forcing the cusps apart and leading to fracture of the tooth. An onlay restoration may be utilized, and its design should include shoeing of the cusps to limit cuspal flexure.

Significant tooth structure missing or previously restored:

These teeth are a challenge to restore, as they are after removal of the old restorative material and decay has left significant portions of the tooth needing replacement (Fig. 11). These teeth will require placement of posts to retain the core of the remaining tooth structure. As the purpose of posts is to retain the core, it is recommended that in multi-canal teeth a post be placed into each canal to cross-pin the core to the remaining tooth structure (Fig. 12). Projection of the posts in posterior teeth due to the angulation

of the canals leads to convergence of the posts in the coronal portion of the tooth. This locks the core in place and assists in preventing fracture of the post or dislodgement under function that is observed when only a single post is placed. Use of pins may also be considered to assist in retaining the core portion when cusps are missing and as an augment to posts being placed. These teeth require a full coverage crown to limit cuspal flexure under load. As with teeth with moderate missing tooth structure, use of inlays should be avoided as they do not restrict cuspal flexure. An onlay may be used if desired in some cases but should include shoeing the cusps as part of the preparation design to limit cuspal flexure. Again, when ferrule is not achievable, consider osseous crown lengthening or forced eruption to improve the ferrule.

Conclusion

For restoration of endodontically treated teeth, an engineering view is needed to ensure long-term survival. Ferrule is often overlooked in today's age of adhesive dentistry, but it is as critical today as it was in the past. Lack of ferrule has been shown to affect survival of the tooth, and the literature supports use

Fig. 9 Minimal tooth missing or previously restored following endodontic treatment.

Fig. 10 Moderate tooth missing or previously restored following endodontic treatment.

Fig. 11 Significant tooth missing or previously restored following endodontic treatment.

Fig. 12 Multiple fiber posts placed into a molar to lock the core to the remaining tooth structure.

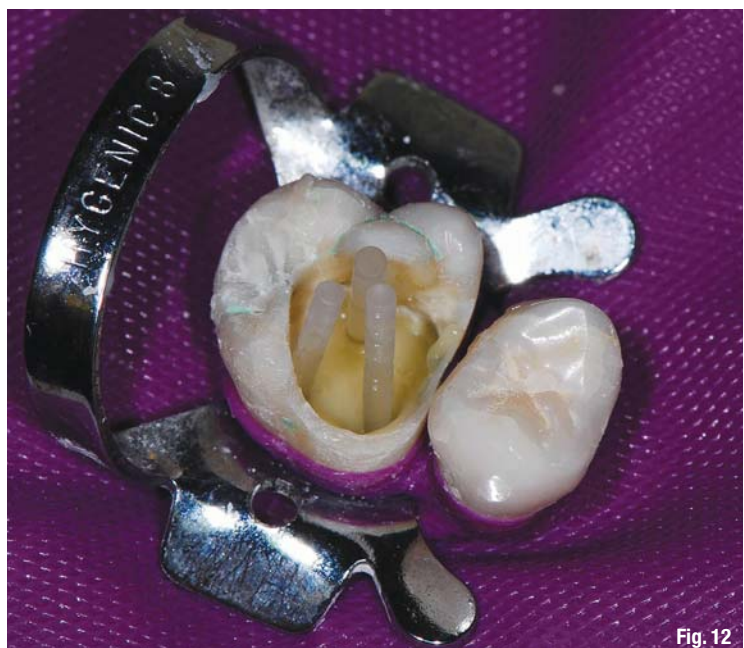

Fig. 12

of 2.0mm of ferrule, which is more critical in maxillary anterior teeth due to the direction of loading during mastication. Additionally, how we restore the remaining tooth plays a role in potential issues in the long term. Metal posts are being used less frequently due to vertical root fractures that can occur when the tooth is overloaded, and the direction has increasingly moved to the use of fiber posts, which mimic the roots modulus of elasticity. When teeth restored with a fiber post are overloaded, fracture typically occurs in the coronal (supragingival) portion, leaving sufficient tooth remaining to re-restore the tooth. Teeth rarely fail when they are over-engineered, but many fail due to under-engineering.

References

1. Barkhodar RA, Radke R, Abbasi J: Effect of metal collars on resistance of endodontically treated teeth to root fracture. *J Prosthet Dent* 61:676, 1989.
2. Galen WW, Muella K.: Restoration of the Endodontically Treated Tooth. In Cohen, S. Burns, RC., editors: *Pathways of the Pulp*, 10th Edition.
3. Stankiewicz NR, Wilson PR. The ferrule effect: a literature review. *Int Endod J*, 35:575–581, 2002.
4. Galen WW, Mueller KI: Restoration of the Endodontically Treated Tooth. In Cohen, S. Burns, RC, editors: *Pathways of the Pulp*, 8th Edition. St. Louis: Mosby, Inc. 2002, page 771.
5. Ichim I, Kuzmanovic DV, Love RM.: A finite element analysis of ferrule design on restoration resistance and distribution of stress within a root. *Int Endod J*. 2006 Jun;39(6):443–452.
6. Nicholls JI. An engineering approach to the rebuilding of endodontically treated teeth, *J Clin Dent*, 1:41–44, 1995.
7. Libman WJ, Nicholls JI: Load fatigue of teeth restored with cast posts and cores and complete crowns. *Int J Prosthodontics* 8:155–161, 1995.
8. Freeman MA, Nicholls JI, Kydd WL, Harrington GW: Leakage associated with load fatigue-induced preliminary failure of full crowns placed over three different post and core systems. *J Endod* 24:26–32, 1998.
9. Ricucci D, Siqueira JF Jr.: Recurrent apical periodontitis and late endodontic treatment failure related to coronal leakage: a case report. *J Endod*. 2011 Aug;37(8):1171–5. doi: 10.1016/j.joen.2011.05.025.
10. De Moor R1, Hommez G.: [The importance of apical and coronal leakage in the success or failure of endodontic treatment]. *Rev Belge Med Dent* (1984). 2000;55(4):334–344.
11. Sriharan A.: Discuss that the coronal seal is more important than the apical seal for endodontic success. *Aust Endod J*. 2002 Dec;28(3):112–115.
12. Jimenez MP, et al. Fracture resistance of endodontically treated teeth with fiber composite posts. IADR abstract no. 323, March, 2002.
13. Bitter K Kielbassa AM: Post-endodontic restorations with adhesively luted fiber-reinforced composite post systems: a review. *Am J Dent*. 2007 Dec;20(6):353–360.
14. Martinez-Insua A, et al. Comparison of the fracture resistances of pulpless teeth restored with a cast post and core or fiber post with a composite core. *J Prosthet Dent* 80(5), 1998.
15. Al-Ansari A.: Which type of post and core system should you use? *Evid Based Dent*. 2007;8(2):42.
16. Plotino G, Grande NM, Bedini R, Pameijer CH, Somma F.: Flexural properties of endodontic posts and human root dentin. *Dent Mater*. 2007 Sep;23(9):1129–35. Epub 2006 Nov 20.
17. Stewardson DA1, Shortall AC, Marquis PM, Lumley PJ.: The flexural properties of endodontic post materials. *Dent Mater*. 2010 Aug;26(8):730–6. doi: 10.1016/j.dental.2010.03.017. Epub 2010 Apr 21.
18. Pierrisnard L, Bohin F, Renault P, Barquins M.: Corono-radicular reconstruction of pulpless teeth: a mechanical study using finite element analysis. *J Prosthet Dent*. 2002 Oct; 88(4):442–448.
19. King PA, Setchell DJ. An in vitro evaluation of a prototype Carbon fiber reinforced prefabricated post developed for the restoration of pulpless teeth. *J Oral Rehabil* 1990;17: 599–609.
20. Purton DG, Chandler NP. Rigidity and retention of root canal posts. *Br Dent J* 1998;184:294–296.
21. Cormier CJ, Burns DR, Moon P. In vitro comparison of the fracture resistance and failure mode of fiber, ceramic and conventional post system at various stages of restoration. *J Prosthodont* 2001;10:26–36.
22. Martínez-Insua A, da Silva L, Rilo B, Santana U. Comparison of the fracture strength of pulpless teeth restored with a cast post and core or carbon fiber post with a composite core. *J Prosthet Dent* 1998;80:527–532.
23. Chieruzzi M, Pagano S, Pennacchi M, Lombardo G, D'Errico P, Kenny JM.: Compressive and flexural behaviour of fibre reinforced endodontic posts. *J Dent*. 2012 Nov;40(11):968–78. doi: 10.1016/j.jdent.2012.08.003. Epub 2012 Aug 21.
24. Padmanabhan P. A comparative evaluation of the fracture resistance of three different pre-fabricated posts in endodontically treated teeth: An in vitro study. *J conserve Dent* 2010;13:124–128.
25. Maccari PC, Conceição EN, Nunes MF. Fracture resistance of endodontically treated teeth restored with three different prefabricated esthetic posts. *J Esthet Restor Dent* 2003; 15:25–31.

_about the author

roots



Dr Gregori M. Kurtzman is in private general practice in Silver Spring, Md., and a former assistant clinical professor at University of Maryland. He has lectured internationally on the topics of restorative dentistry, endodontics and implant surgery and prosthetics, removable and fixed prosthetics, and periodontics and has over 350 published articles. He has earned fellowship in the AGD, AAIP, ACD, ICOI, Pierre Fauchard, ADI, mastership in the AGD and ICOI and diplomat status in the ICOI and American Dental Implant Association

(ADIA). Kurtzman has been honored to be included in the "Top Leaders in Continuing Education" by *Dentistry Today* annually since 2006 and was featured on their June 2012 cover. He can be reached at dr_kurtzman@maryland-implants.com

3rd ASIA - PACIFIC EDITION

CAD/CAM & Digital Dentistry International Conference

25-26 September 2015
SUNTEC SC&EC
Singapore



Other Industry Players

ORGANIZED BY



CO-ORGANIZER



HELD IN



SUPPORTED BY



ADA CER·P® | Continuing Education
Recognition Program

CENTRE APP ASIA PTE LTD (CAPP Asia) is an ADA CER·P Recognized Provider. ADA CER·P is a service of the American Dental Association to assist dental professionals in identifying quality providers of continuing dental education. ADA CER·P does not approve or endorse individual courses or instructors, nor does it imply acceptance of credit hours by boards of dentistry.

www.capp-asia.com
www.facebook.com/cappasiapacific