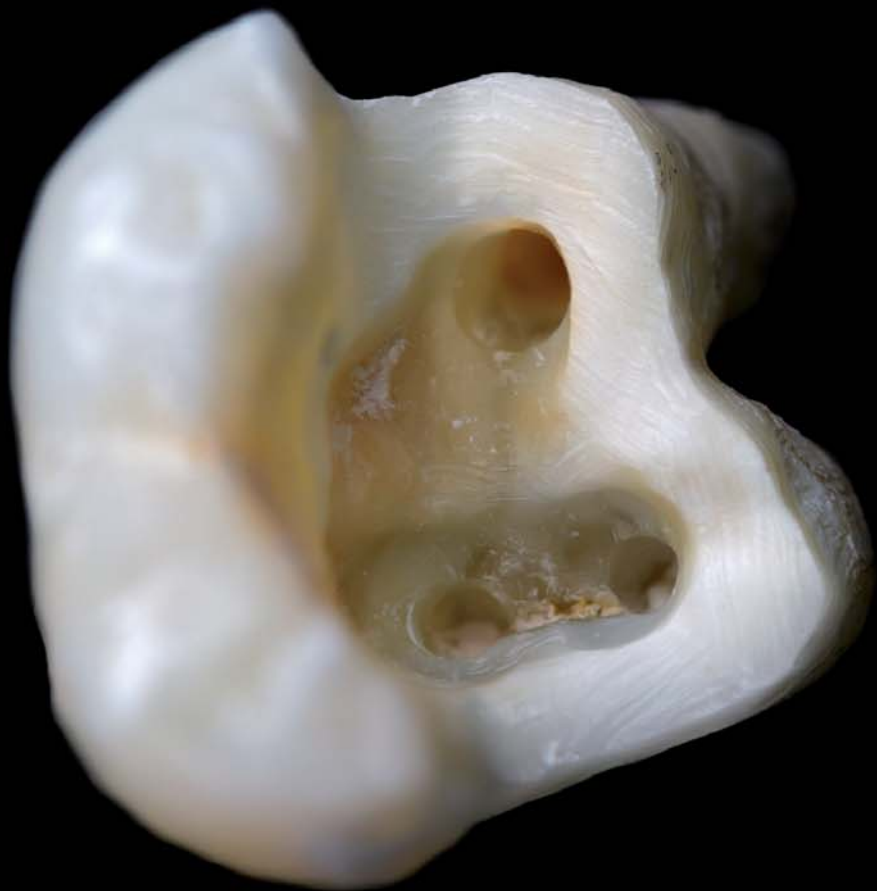

roots

international magazine of endodontology

3²⁰¹⁴



| **CE article**

Restoration of endodontic teeth:
An engineering perspective

| **trends**

PIPS and retreatment

| **special**

Daktari for Maasai –
Mobile Dental Care in the Serengeti



Dental Tribune International

The World's Largest News and Educational Network in Dentistry

dti] Dental Tribune International

www.dental-tribune.com



Dear Reader,



Dr Sekar Mahalaxmi

I have great pleasure in welcoming you to the first Roots Summit in India. After the stupendous success of the Roots Summit in Brazil in 2012, it is time for roots to travel all the way east to the beautiful country of India, with its rich culture, flora and fauna; where loads of enthusiastic rooters are eagerly awaiting this endodontic clinical and academic extravaganza.

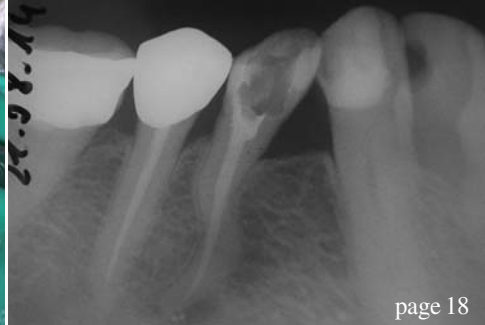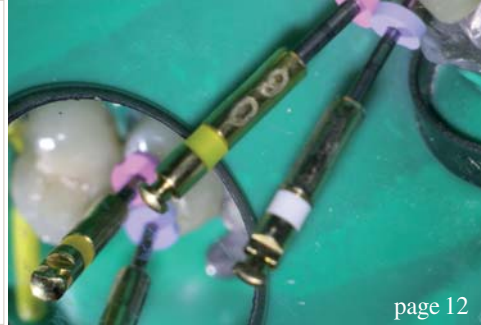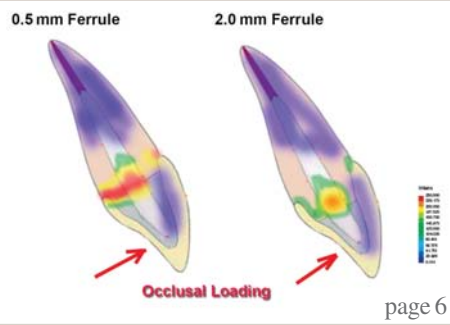
This year's Roots Summit is held in Mahabalipuram, a peaceful beach town near the southern city of Chennai. An array of national and international speakers will share their experiences on the complexities of the root canal, the management of separated instruments, and regenerative endodontics, which are critical areas in today's clinical scenario in endodontics. To add to this, there are more than a dozen pre-summit workshops to choose from for those who wish to gain first-hand experience. This is a golden opportunity for all dentists from Asian countries and from afar to meet in India to further enhance their knowledge and skills in a positive way.

Together with other members of the organising team, I invite you to your lifetime experience with stalwarts in the field of endodontics. The organising team will leave no stone unturned to make this Summit an event to remember by one and all. We look forward to three full days of pure knowledge, clinical skills and academic excellence that will keep the delegates glued to their seats.

Stay with us and enjoy the warm and vibrant Indian hospitality.

Yours faithfully,

Dr Sekar Mahalaxmi
Head of the Department of Conservative Dentistry and Endodontics
SRM University, College of Dentistry, Chennai, India



| editorial

03 **Dear Reader**
| Dr Sekar Mahalaxmi

| CE article

06 **Restoration of endodontic teeth:**
An engineering perspective
| Dr Gregori M. Kurtzman

| industry report

14 **Pressing endodontic issues**
| Dr Antonis Chaniotis

| case report

18 **S-shaped root—risks of a master challenge**
in endodontology
| Dr Friedrich Müller

| trends

20 **PIPS and retreatment**
| Dr Reid Pullen

| feature

24 **“Continuous Education is a top priority for us,**
first proof is our new Training Centers”
| Interview with Alexandre Mulhauser, FKG Dentaire Middle East
& Africa Director

| research

26 **Diclofenac, dexamethasone or laser** phototherapy? Part II
| Jan Tunér

| special

30 **Daktari for Maasai—**
Mobile Dental Care in the Serengeti
| Prof. Martin Jörgens

| industry news


38 **Planmeca and the University of Turku**
found Nordic Institute of Dental Education
| Planmeca

| events

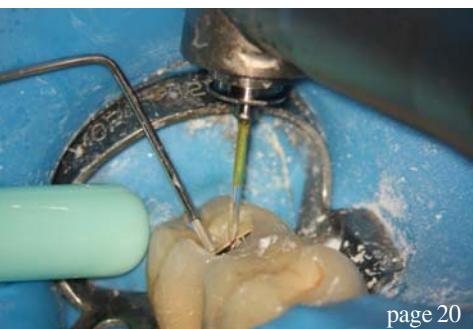40 **International Events**

| about the publisher

41 | submission guidelines
42 | imprint



Cover image courtesy: Ocskay Bence/shutterstock.com





CROIXTURE

PROFESSIONAL MEDICAL COUTURE



THE NEW 2014-2015 COLLECTION

EXPERIENCE OUR ENTIRE COLLECTION ON WWW.CROIXTURE.COM

Restoration of endodontic teeth: An engineering perspective

Author_Dr Gregori M. Kurtzman, USA

_ce credit

roots



This article qualifies for CE credit. To take the CE quiz, log on to www.dtstudyclub.com. Click on 'CE articles' and search for this edition of the magazine. If you are not registered with the site, you will be asked to do so before taking the quiz. You may also access the quiz by using the QR code.

_Introduction

Identifying the canals and negotiating them to be able to instrument and obturate the tooth is necessary to clinical success. But restoration of the endodontically treated tooth is critical to long-term success. It does not matter if we can complete the endodontic portion of treatment if the tooth cannot be restored. With this in mind, we need to look at the restoration phase from an engineering perspective. What is needed to reinforce the remaining tooth so that it can manage the repetitive loading that occurs during mastication? This article will discuss the importance of ferrule in adhesive dentistry as well as when to use posts and what materials are best.

_Ferrule: How important is it today?

Ferrule was an important concept in dentistry but has been de-emphasized with the bonding evolution. Yet this concept is as important today as it was prior to dental bonding. But what is a ferrule? A ferrule is a band that encircles the external dimension of residual tooth structure, not unlike the metal bands that exist around a barrel to hold the slats together. Sufficient vertical height of tooth structure that will be grasped by the future crown is necessary to allow for a ferrule effect of the future prosthetic crown; it has been

shown to significantly reduce the incidence of fracture in the endodontically treated tooth.^{1,2}

Important to this concept is the margin design of the crown preparation, which may include a chamfer or a shoulder preparation. Because a chamfer margin has a bevelled area that is not parallel to the vertical axis of the tooth, it does not properly contribute to ferrule height. Therefore, when a chamfer is utilized it would require an additional 1 mm of height between the edge of the margin and the top aspect of the coronal portion of remaining tooth structure. Thus, use of a chamfer may not be the best margin design when restoring endodontically treated teeth or those teeth with significant portions of missing tooth structure. With today's movement toward scanning and milling for fixed prosthetics, whether done in the practitioner's office or at the laboratory, it should be noted that it is difficult to scan the internal aspect of a shoulder preparation and it has been uniformly recommended that a rounded shoulder be used. The rounded shoulder preparation provides the maximum vertical wall at the margin, with the internal aspect being slightly rounded versus at a 90-degree angle. This ensures better replication of the margins when scanned and milled.

Some studies suggest that while ferrule is certainly desirable, it should not be provided at the expense of the remaining tooth/root structure.³

Alternatively, it has also been shown that the difference between an effective, long-term restoration and restorative failure can be as small as 1 mm of additional tooth structure that, when encased by a ferrule, provides greater protection. When such a long-lasting, functional restoration cannot be predictably created, osseous crown lengthening should be considered to increase what tooth structure is available to achieve a ferrule, but this is also dependent on the periodontal status of the tooth, and

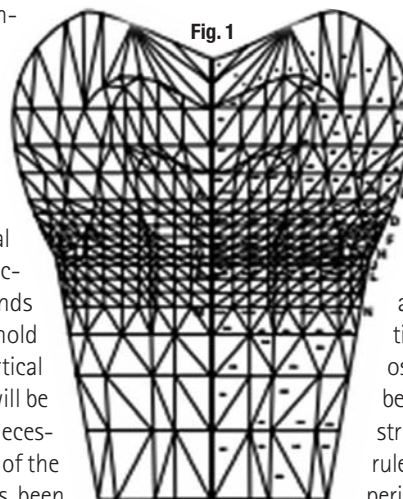


Fig. 1 Strain analysis of a posterior tooth demonstrating concentration of strain on loading at the cervical. (Image/Dr Gene McCoy)

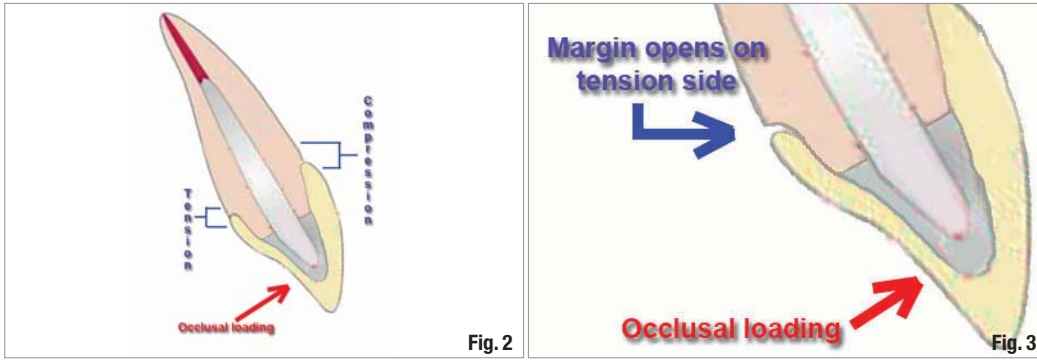


Fig. 2 As a maxillary anterior tooth is loaded during mastication, tension and compression occur at the crown's margins.

(Images/Dr Gregori M. Kurtzman)
Fig. 3 Opening of the margin on the tension side may lead in time to recurrent decay or restoration and endodontic failure.

when ferrule cannot be achieved then extraction should be considered.⁴ Ichim, et al, stated succinctly, "The study confirms that a ferrule increases the mechanical resistance of a post/core/crown restoration."⁵

How much ferrule is required?

When rebuilding an endodontically treated tooth, it is best to maintain all dentin that is available, even thin slivers. These thin slivers of dentin provide a strong connecting link between the core and tooth's root and between the crown and root.⁶ It is important to attempt to retain as much tooth structure as possible, and this aids in achieving ferrule as well as maintaining cervical strength of the tooth where loading concentrates. Under masticatory loading, strain concentrates at the cervical portion of teeth, thus it is important to avoid over-preparation of this portion of the tooth during endodontic treatment and preserve this area during restoration of the tooth (Fig. 1).

Multiple studies discussing how much ferrule is required have found that teeth with at least 2 mm of ferrule have significantly greater long-term prognosis from a restorative standpoint than those with less or no ferrule. Libman, et al, reported, "Fatigue loading of

cast post and cores with complete crowns of different ferrule designs provide evidence to support the need for at least a 1.5-mm to 2.0-mm ferrule length of a crown preparation. Crown preparation with a 0.5-mm and 1.0-mm ferrule failed at a significantly lower number of cycles than the 1.5-mm and 2.0-mm ferrules and control teeth."⁷ Libman further demonstrated when loading at an off-axis direction, which occurs in the maxillary anterior, at the restoration's margin the side where the load is originating is under tension, whereas the opposing side is under compression (Fig. 2). This repetitive loading and micro strain due to tension at the lingual margin leads to the margin opening, which may lead to recurrent decay and/or failure of the endodontic seal or restoration (Fig. 3).

Additionally, if we look at strain studies by Libman and others comparing ferrule of different heights, we observe that in a ferrule of 0.5 mm there is greater strain at the margin under tension and concentrates at mid tooth where the core or post is situated. Teeth with 2.0 mm of ferrule demonstrated significantly less strain loading at the margins or centre of the cervical aspect of the tooth. The lower the strain at the cervical midpoint, the less chance of overload and failure restoratively (Fig. 4).

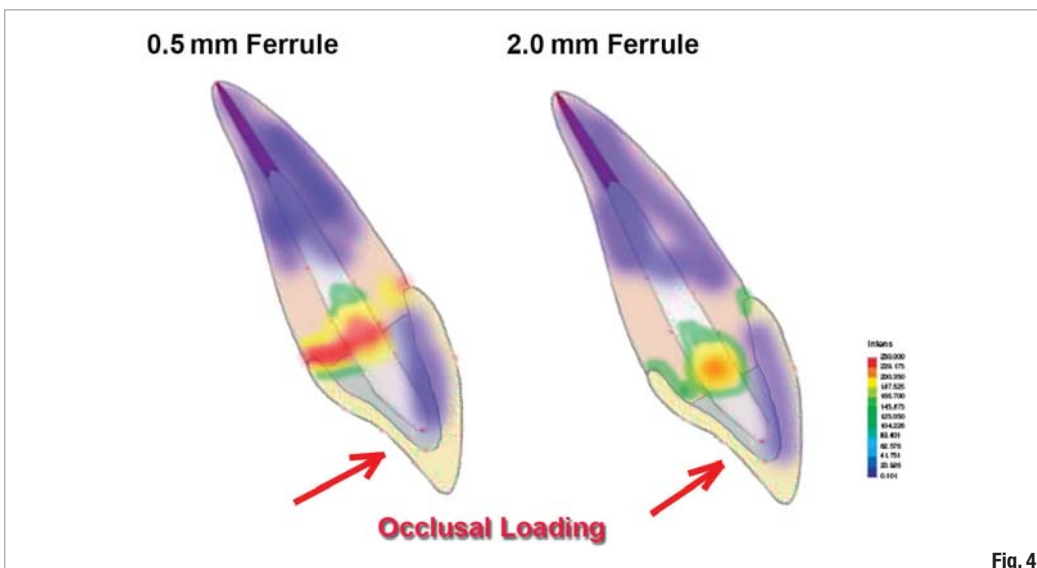


Fig. 4 Difference of intensity of strain and location related to ferrule height during occlusal loading (Libman).

Fig. 5_ Comparison of load distribution of fiber posts compared to a cast post and prefabricated metal post.

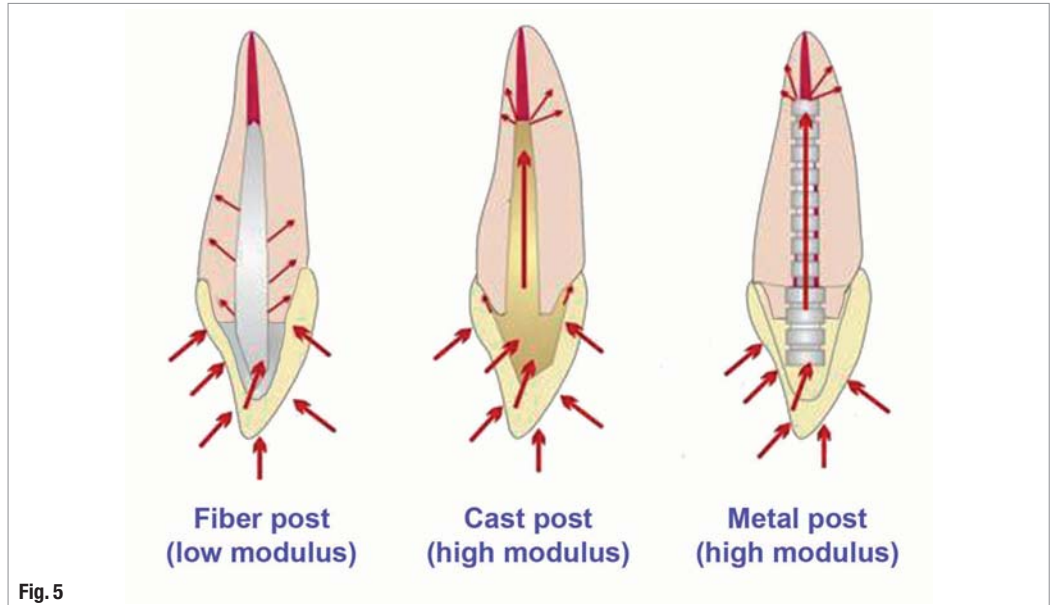


Fig. 5

_Detecting failure at the coronal seal

It is not unusual to have a patient present for a routine recall appointment and the clinician or hygienist note recurrent decay at a crown margin with the patient unaware of the issue. This becomes more complicated with teeth that have previously undergone endodontic treatment, as there is no pulp present that could warn the patient an issue is present until often extensive decay occurs or the crown dislodges from the remaining tooth. Freeman, et al, in their published study, stated, "Fatigue loading of three different post and core designs with the presence of a full cast crown leads to preliminary failure of leakage between the restoration and tooth that is clinically undetectable."⁸

The literature supports that coronal leakage may be a major factor in failure of endodontic treatment.⁹⁻¹¹ As previously discussed, when loaded during mastication, margins with inadequate ferrule may demonstrate micro opening on the tension side, leading to leakage over time. This initially may be observed as recurrent decay, but as it deepens and exposure of the obturation material results, failure of the endodontics may result due to apical migration of oral bacteria. This is minimized when a bonded core or post/core is present, but given sufficient time when a ferrule of sufficient height is not present the endodontics or the restoration will fail.

_Do all posts function the same?

Teeth function differently, depending on the material that the post is fabricated from, with loads distributed within the root relative to the modulus of elasticity of the post compared to the dentin of the root (Fig. 5).

When a tooth restored with a fiber post does fail due to overload, the mode of failure is coronal, protecting remaining root and tooth structure.¹² This mode of failure with fiber-post-restored teeth typically allows the tooth to be restored, as vertical root fracture is a rare occurrence. Bitter reported, "Compared to metal posts, FRC posts revealed reduced fracture resistance in vitro, along with a usually restorable failure mode"¹³ (Fig. 6). Whereas, with metal posts either prefabricated or cast, failure was at a higher value for cast post and core 91 per cent of the specimens had fractured roots, none of the specimens with a fiber post demonstrated root fracture; the post and core usually fractured at the tooth composite core interface.¹⁴ As stress concentrates at the apical tip of the metal post due to its higher modulus of elas-

Fig. 6_ Tooth restored with a fiber post demonstrating coronal horizontal fracture supracrestally typically seen with teeth restored with fiber posts when overloaded.

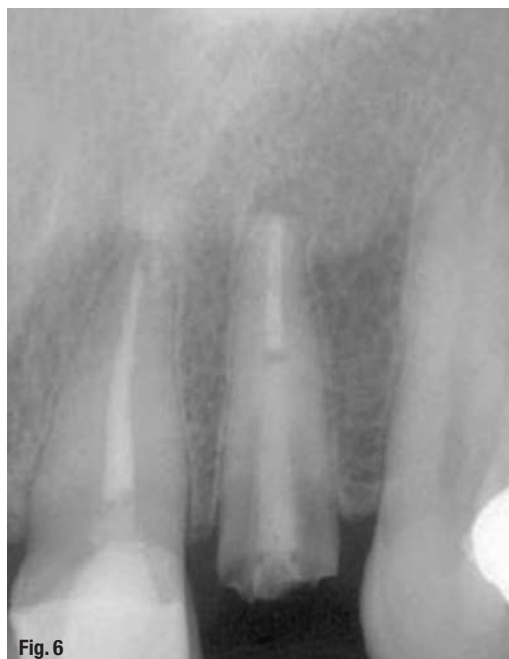

Fig. 6

ticity than the surrounding root, vertical root fracture is a frequent occurrence (Fig. 7). This may result also from breakdown of the cement luting the post to the root, allowing slippage microscopically of the post in the tooth under load, leading to torque at the cervical area and the resulting vertical root fracture.

As metal posts are stiffer (higher modulus of elasticity) than the dentin of the root, with metal posts stress concentrated at the posts apical leading to vertical root fracture and catastrophic loss of the tooth. Ansari reported, "The risk of failure was greater with metal-cast posts (nine out of 98 metal posts failed) than with carbon fiber posts (using which, none out of 97 failed) risk ratio."¹⁵ But with fiber posts having a flexibility equal or greater than the root (lower modulus of elasticity) stress concentrated at the cervical region leading to horizontal fracture of the post and core and typically the tooth can be salvaged.

The elastic modulus refers to the relative rigidity of the material. The stiffer the material, the higher its relative modulus. When two different materials are placed together, as an example, a post is placed into a tooth's root the elastic modulus is influenced by whichever of the materials is stiffest. Dentin averages a modulus of elasticity of 17.5 (+/- 3.8) GPa, with glass fiber posts at 24.4 (+/- 3.4) GPa, titanium prefabricated posts at 66.1 (+/- 9.6) GPa, prefabricated stainless steel at 108.6 (+/- 10.7) GPa and cast high noble gold posts at 53.4 (+/- 4.5) GPa. Cast posts fabricated from noble or base metals have higher modulus than high noble alloys and approach stainless-steel prefabricated posts in their relative stiffness. Fiber posts have an elastic modulus that more closely approaches that of dentin (Fig. 8). The flexural strength of fiber and metal posts was respectively four and seven times higher than root dentin, and there is still debate on whether a post strengthens the tooth.^{16,17} The basic purpose of a post is to aid in retention of the core.

The absence of a cervical ferrule has been found to be a determining negative factor, giving rise to considerably higher stress levels within the root. When no ferrule was present, the prefabricated metal post/composite combination generated greater cervical stress than cast post and cores. Yet, the ferrule seemed to cancel the mechanical effect of the reconstruction material on the intensity of the stresses. With a ferrule, the choice of reconstruction material had no impact on the level of cervical stress. The root canal post, the purpose of which is to protect the cervical region, was also shown to be beneficial even with sufficient residual coronal dentin. In the presence of a root canal post, cervical stress levels were lower than when no root canal post was present. Pierrisnard concluded that the higher the elasticity modulus, the lower the stress levels.¹⁸

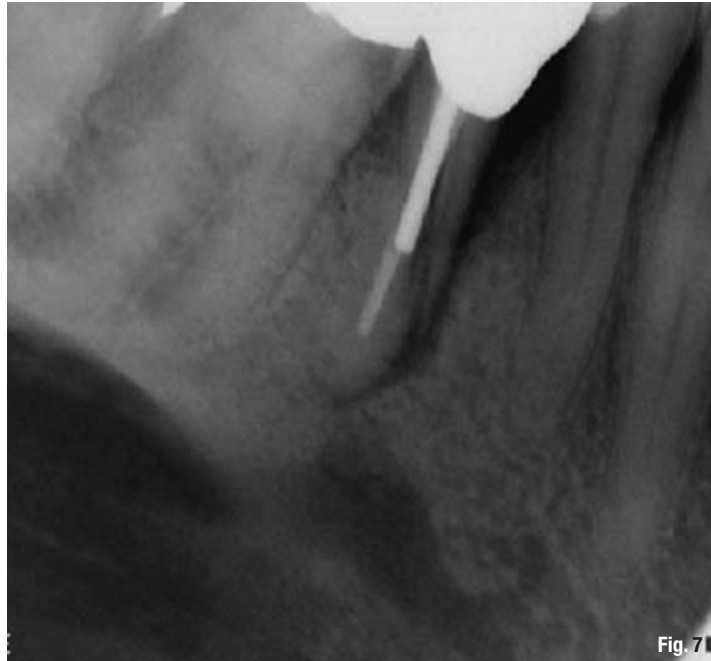
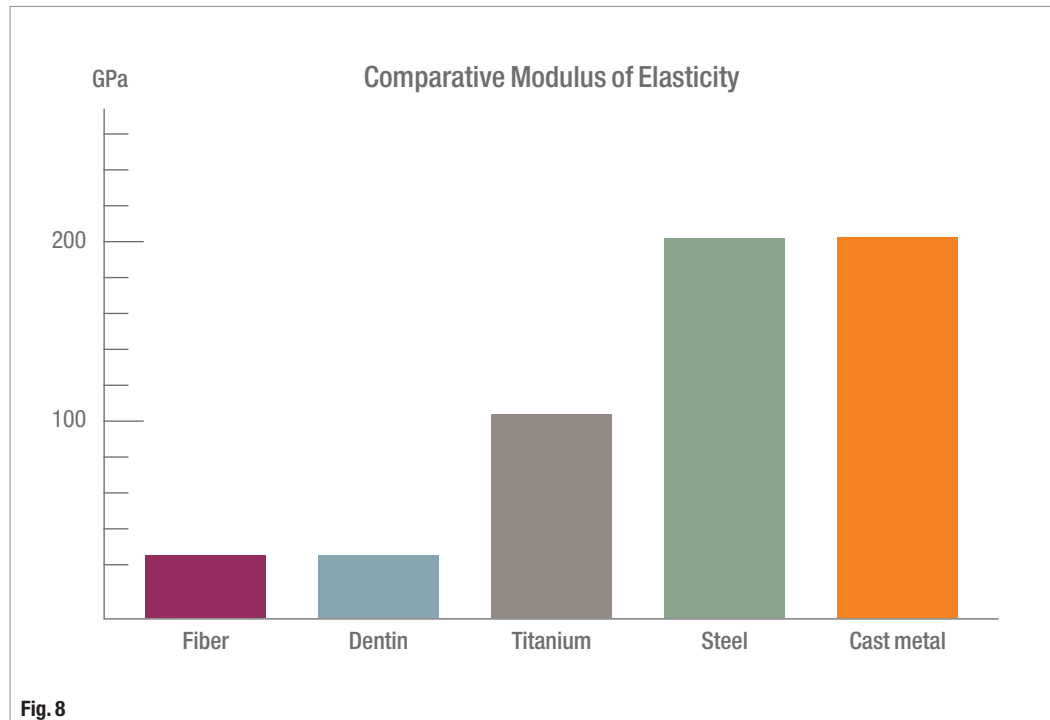


Fig. 7 Vertical root fracture of a tooth restored with a metal post.

The material the post is fabricated from should have the same modulus of elasticity as the root dentin to distribute the applied forces along the length of the post and the root and not concentrate them at the apical tip of the post. Studies have shown that when components of different rigidity are loaded, the more rigid component is capable of resisting forces without distortion. This stress is concentrated when the post is the stiffer material at the posts apical tip. The less-rigid component fails invariably when a post is used that is stiffer than the root's dentin.¹⁹ Posts with modulus of elasticity significantly greater than that of dentin create stresses at the tooth/cement/post interface, with the possibility of post separation and failure. As repetitive loading occurs on the endodontically restored tooth, the cement eventually fails at the interface between the metal post and root dentin, allowing microslippage of the post. This allows higher stresses to be exerted on the root, leading to vertical root fracture and catastrophic loss of the tooth. The higher modulus (rigidity) of the metallic posts makes it stiff and unable to absorb stresses. In addition, transmission of occlusal and lateral forces through a metallic core and post can concentrate stresses, resulting in the possibility of unfavorable fracture of the root.²⁰ Dentin's modulus of elasticity is approximately 14 to 18 GPa. Fiber posts have modulus that is approximately 9 to 50 GPa, depending on the manufacturer of the post. This provides a similarity in elasticity between the fiber post and dentin of the root, allowing post flexion to mimic tooth flexion. The fiber post absorbs and distributes the stresses and thus shows reduced stress transmission to the root.²¹ The longitudinal arrange-

Fig. 8 Comparative modulus of elasticity of different post materials.



ment of fibers in the fiber post and the modulus of elasticity of a post that is less than or equal to that of the dentin may redistribute the stress into the tooth and away from the chamfered shoulder to increase the likelihood of failure of the post core/root interface instead of root fractures. When failure does occur due to overloading, failure typically is in the coronal portion, frequently demonstrating fracture of the core at the tooth interface and leaving the possibility of re-restoring the tooth and not catastrophic loss.²²

The flexural properties of fiber posts were higher than the metal post and similar to dentin.²³

Whereas, pre-fabricated, stainless-steel post exhibited a significantly higher fracture resistance at failure when compared with the fiber posts. The mode of failure of the carbon fiber post was more favorable to the remaining tooth structure when compared with the pre-fabricated stainless steel post and the ceramic post.²⁴

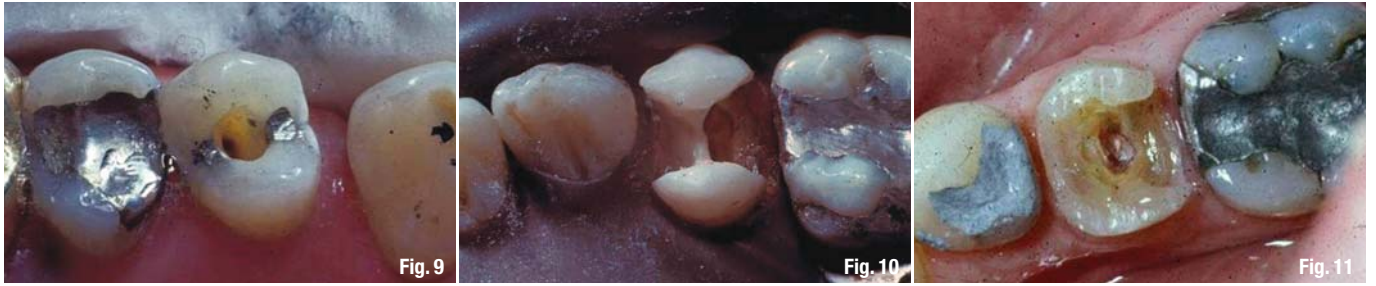Ceramic posts were introduced prior to fiber posts as a more esthetic alternative to prefabricated metal posts, and, although not widely used today, they are still available. Modulus of elasticity of ceramic posts is 170–213 GPa, which is approximately 15 times that of dentin. As these ceramic posts are too rigid and transmit more stress to the root canal than the fiber posts, which lead to irreversible root damage via vertical root fracture seen with metal posts, their use is not recommended in restoring endodontically treated teeth today.²⁵

Decision making for restoration of endodontically treated teeth

Restoration of endodontically treated teeth needs to take an engineering view of how best to reconstruct the remaining tooth for the best long-term survival. With this in mind, the practitioner needs to categorize the tooth based on how much native tooth structure is present following endodontic treatment and how much existing restorative material is currently present in the tooth.

Minimal tooth missing or previously restored:

Posterior teeth gain strength when the marginal ridge area and proximal surface is natural tooth structure and has not been restored. Teeth that have undergone endodontic treatment when either occlusal decay was present in the pits and fissures leading to pulpal involvement or a small- to moderate-sized previously placed amalgam or composite restoration is present require conservative restoration (Fig. 9). These teeth can be restored with removal of the existing restorative material and cleaning the pulp chamber of obturation material including 2 to 3 mm of the canal. Placement of a conventional composite bonded within the tooth provides a good long-term restorative solution to these teeth, and a crown is not needed typically. The access or existing restoration should leave most of the cuspal width present. When the preparation following removal of decay and existing restorative materials invades the width of the cusp leaving half of this tooth structure missing, more extensive restoration is indicated.



Moderate tooth structure missing or previously restored:

When the tooth to be restored is missing one or both marginal ridges and these areas have been previously restored or will be restored, placement of a bonded composite will not suffice as the final restoration (Fig. 10). The marginal ridges provide resistance to cuspal flexure of the tooth, improving its strength. When these are missing, functional loading of the tooth will allow greater cuspal flexure and consequently a higher chance of fracture under masticatory function. Restoration of these teeth will require a core buildup with optional pins or other retentive elements for the core followed by a full coverage crown. Posts are often not needed, as the remaining tooth structure at the cusps after crown preparation is sufficient to retain the core and a ferrule can be achieved. A post may be considered in those patients who are bruxers or clenchers or whose occlusion may place higher forces on the restored tooth due to the tooth's position relative to the occlusal plane. When a ferrule cannot be achieved, the practitioner should consider osseous crown lengthening or forced eruption to improve the ferrule. Inlay restorations should be avoided in endodontically treated teeth because the access created to perform the endodontic treatment weakens the tooth from a cuspal flexure standpoint and the inlay even when bonded may act as a wedge forcing the cusps apart and leading to fracture of the tooth. An onlay restoration may be utilized, and its design should include shoeing of the cusps to limit cuspal flexure.

Significant tooth structure missing or previously restored:

These teeth are a challenge to restore, as they are after removal of the old restorative material and decay has left significant portions of the tooth needing replacement (Fig. 11). These teeth will require placement of posts to retain the core of the remaining tooth structure. As the purpose of posts is to retain the core, it is recommended that in multi-canal teeth a post be placed into each canal to cross-pin the core to the remaining tooth structure (Fig. 12). Projection of the posts in posterior teeth due to the angulation

of the canals leads to convergence of the posts in the coronal portion of the tooth. This locks the core in place and assists in preventing fracture of the post or dislodgement under function that is observed when only a single post is placed. Use of pins may also be considered to assist in retaining the core portion when cusps are missing and as an augment to posts being placed. These teeth require a full coverage crown to limit cuspal flexure under load. As with teeth with moderate missing tooth structure, use of inlays should be avoided as they do not restrict cuspal flexure. An onlay may be used if desired in some cases but should include shoeing the cusps as part of the preparation design to limit cuspal flexure. Again, when ferrule is not achievable, consider osseous crown lengthening or forced eruption to improve the ferrule.

Conclusion

For restoration of endodontically treated teeth, an engineering view is needed to ensure long-term survival. Ferrule is often overlooked in today's age of adhesive dentistry, but it is as critical today as it was in the past. Lack of ferrule has been shown to affect survival of the tooth, and the literature supports use

Fig. 9 Minimal tooth missing or previously restored following endodontic treatment.

Fig. 10 Moderate tooth missing or previously restored following endodontic treatment.

Fig. 11 Significant tooth missing or previously restored following endodontic treatment.

Fig. 12 Multiple fiber posts placed into a molar to lock the core to the remaining tooth structure.

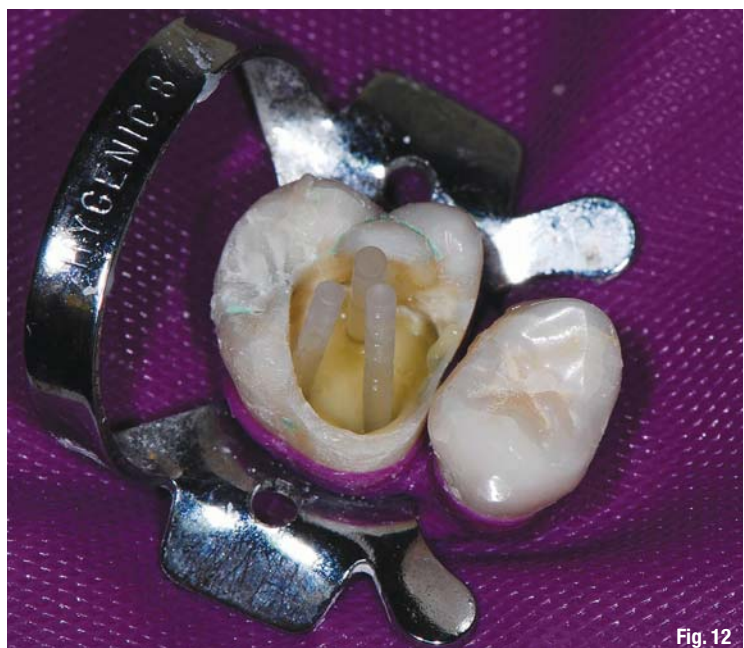

Fig. 12

of 2.0mm of ferrule, which is more critical in maxillary anterior teeth due to the direction of loading during mastication. Additionally, how we restore the remaining tooth plays a role in potential issues in the long term. Metal posts are being used less frequently due to vertical root fractures that can occur when the tooth is overloaded, and the direction has increasingly moved to the use of fiber posts, which mimic the roots modulus of elasticity. When teeth restored with a fiber post are overloaded, fracture typically occurs in the coronal (supragingival) portion, leaving sufficient tooth remaining to re-restore the tooth. Teeth rarely fail when they are over-engineered, but many fail due to under-engineering.

References

1. Barkhodar RA, Radke R, Abbasi J: Effect of metal collars on resistance of endodontically treated teeth to root fracture. *J Prosthet Dent* 61:676, 1989.
2. Galen WW, Muella K.: Restoration of the Endodontically Treated Tooth. In Cohen, S. Burns, RC., editors: *Pathways of the Pulp*, 10th Edition.
3. Stankiewicz NR, Wilson PR. The ferrule effect: a literature review. *Int Endod J*, 35:575–581, 2002.
4. Galen WW, Mueller KI: Restoration of the Endodontically Treated Tooth. In Cohen, S. Burns, RC, editors: *Pathways of the Pulp*, 8th Edition. St. Louis: Mosby, Inc. 2002, page 771.
5. Ichim I, Kuzmanovic DV, Love RM.: A finite element analysis of ferrule design on restoration resistance and distribution of stress within a root. *Int Endod J*. 2006 Jun;39(6):443–452.
6. Nicholls JI. An engineering approach to the rebuilding of endodontically treated teeth, *J Clin Dent*, 1:41–44, 1995.
7. Libman WJ, Nicholls JI: Load fatigue of teeth restored with cast posts and cores and complete crowns. *Int J Prosthodontics* 8:155–161, 1995.
8. Freeman MA, Nicholls JI, Kydd WL, Harrington GW: Leakage associated with load fatigue-induced preliminary failure of full crowns placed over three different post and core systems. *J Endod* 24:26–32, 1998.
9. Ricucci D, Siqueira JF Jr.: Recurrent apical periodontitis and late endodontic treatment failure related to coronal leakage: a case report. *J Endod*. 2011 Aug;37(8):1171–5. doi: 10.1016/j.joen.2011.05.025.
10. De Moor R1, Hommez G.: [The importance of apical and coronal leakage in the success or failure of endodontic treatment]. *Rev Belge Med Dent* (1984). 2000;55(4):334–344.
11. Sriharan A.: Discuss that the coronal seal is more important than the apical seal for endodontic success. *Aust Endod J*. 2002 Dec;28(3):112–115.
12. Jimenez MP, et al. Fracture resistance of endodontically treated teeth with fiber composite posts. IADR abstract no. 323, March, 2002.
13. Bitter K Kielbassa AM: Post-endodontic restorations with adhesively luted fiber-reinforced composite post systems: a review. *Am J Dent*. 2007 Dec;20(6):353–360.
14. Martínez-Insua A, et al. Comparison of the fracture resistances of pulpless teeth restored with a cast post and core or fiber post with a composite core. *J Prosthet Dent* 80(5), 1998.
15. Al-Ansari A.: Which type of post and core system should you use? *Evid Based Dent*. 2007;8(2):42.
16. Plotino G, Grande NM, Bedini R, Pameijer CH, Somma F.: Flexural properties of endodontic posts and human root dentin. *Dent Mater*. 2007 Sep;23(9):1129–35. Epub 2006 Nov 20.
17. Stewardson DA1, Shortall AC, Marquis PM, Lumley PJ.: The flexural properties of endodontic post materials. *Dent Mater*. 2010 Aug;26(8):730–6. doi: 10.1016/j.dental.2010.03.017. Epub 2010 Apr 21.
18. Pierrisnard L, Bohin F, Renault P, Barquins M.: Corono-radi- cular reconstruction of pulpless teeth: a mechanical study using finite element analysis. *J Prosthet Dent*. 2002 Oct; 88(4):442–448.
19. King PA, Setchell DJ. An in vitro evaluation of a prototype Carbon fiber reinforced prefabricated post developed for the restoration of pulpless teeth. *J Oral Rehabil* 1990;17: 599–609.
20. Purton DG, Chandler NP. Rigidity and retention of root canal posts. *Br Dent J* 1998;184:294–296.
21. Cormier CJ, Burns DR, Moon P. In vitro comparison of the fracture resistance and failure mode of fiber, ceramic and conventional post system at various stages of restoration. *J Prosthodont* 2001;10:26–36.
22. Martínez-Insua A, da Silva L, Rilo B, Santana U. Comparison of the fracture strength of pulpless teeth restored with a cast post and core or carbon fiber post with a composite core. *J Prosthet Dent* 1998;80:527–532.
23. Chieruzzi M, Pagano S, Pennacchi M, Lombardo G, D'Errico P, Kenny JM.: Compressive and flexural behaviour of fibre reinforced endodontic posts. *J Dent*. 2012 Nov;40(11):968–78. doi: 10.1016/j.jdent.2012.08.003. Epub 2012 Aug 21.
24. Padmanabhan P. A comparative evaluation of the fracture resistance of three different pre-fabricated posts in endo- dontically treated teeth: An in vitro study. *J conserve Dent* 2010;13:124–128.
25. Maccari PC, Conceição EN, Nunes MF. Fracture resistance of endodontically treated teeth restored with three different prefabricated esthetic posts. *J Esthet Restor Dent* 2003; 15:25–31.

_about the author

roots



Dr Gregori M. Kurtzman is in private general practice in Silver Spring, Md., and a former assistant clinical professor at University of Maryland. He has lectured internationally on the topics of restorative dentistry, endodontics and implant surgery and prosthetics, removable and fixed prosthetics, and periodontics and has over 350 published articles. He has earned fellowship in the AGD, AAIP, ACD, ICOI, Pierre Fauchard, ADI, mastership in the AGD and ICOI and diplomat status in the ICOI and American Dental Implant Association

(ADIA). Kurtzman has been honored to be included in the "Top Leaders in Continuing Education" by *Dentistry Today* annually since 2006 and was featured on their June 2012 cover. He can be reached at dr_kurtzman@maryland-implants.com

3rd ASIA - PACIFIC EDITION

CAD/CAM & Digital Dentistry International Conference

25-26 September 2015
SUNTEC SC&EC
Singapore



Other Industry Players

ORGANIZED BY



CO-ORGANIZER



HELD IN



SUPPORTED BY



ADA CER·P® | Continuing Education
Recognition Program

CENTRE APP ASIA PTE LTD (CAPP Asia) is an ADA CER·P Recognized Provider. ADA CER·P is a service of the American Dental Association to assist dental professionals in identifying quality providers of continuing dental education. ADA CER·P does not approve or endorse individual courses or instructors, nor does it imply acceptance of credit hours by boards of dentistry.

www.capp-asia.com
www.facebook.com/cappasiapacific

Pressing endodontic issues

Author_ Dr Antonis Chaniotis, Greece

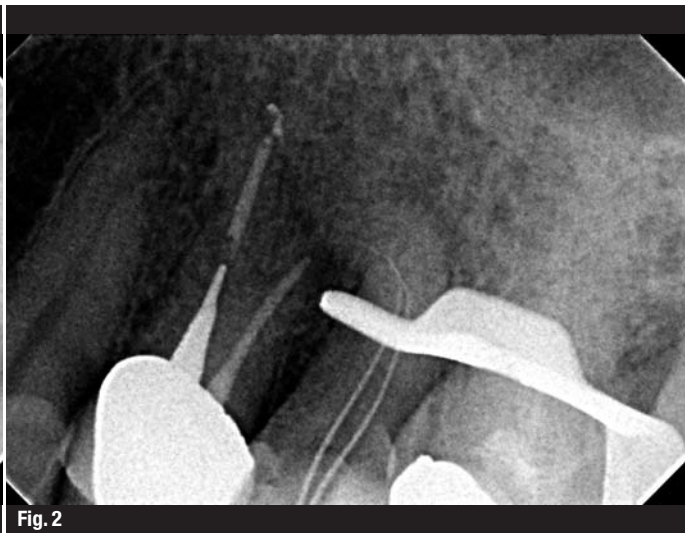
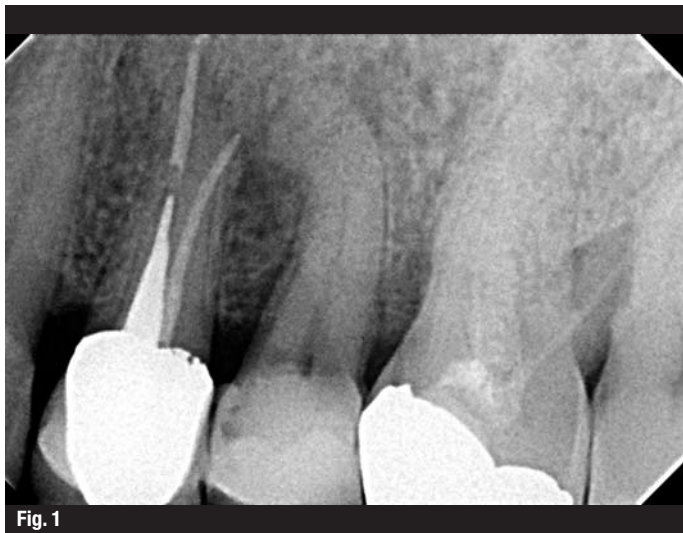
Fig. 1_Clinical situation.
Fig. 2_Periapical lesion in highly curved root.

_Sealing the root canal system with a durable and bacteria-tight material guarantees a successful endodontic treatment in the long run. Easier said than done, if you consider the complex nature of the given dental anatomy. The following case report demonstrates that a reliable obturation of the root canal system sometimes just needs a little unusual pressure, i.e. negative pressure.

fast flowing filling materials are already available on the market. However, multiple canals, hidden accessory canals or lateral branches make it difficult to create a permanent seal against bacteria and fluids that can just re-enter the root canal system. Irregularities like culs-de-sac or isthmi are not easy to spot, let alone to be filled properly. A new, simple technique using standard instruments can help practitioners to get the job done in no time. All you need is free-flow filling material and a new, special endodontic aspirating tip to create a bit of negative pressure, as my latest endodontic case shows.

Fig. 3_Confluent canals.
Fig. 4_Instrumentation with the HyFlex CM rotary files.

After having shaped and cleaned the canal, the endo specialist seeks to obturate the prepared space effectively. For this purpose, a number of innovative

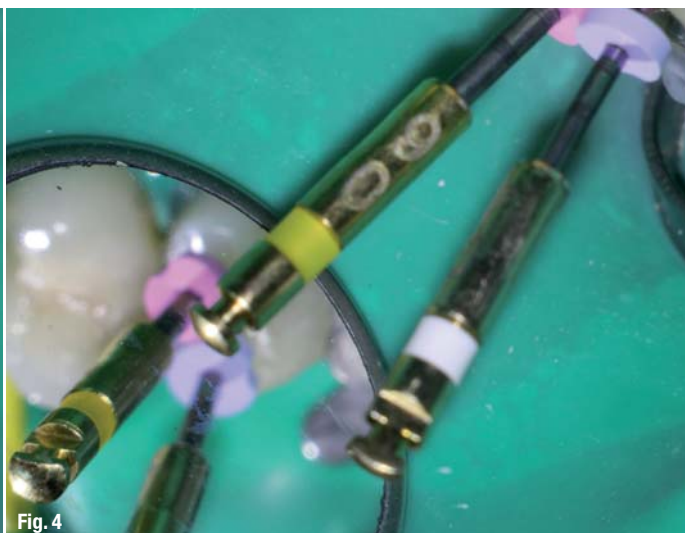
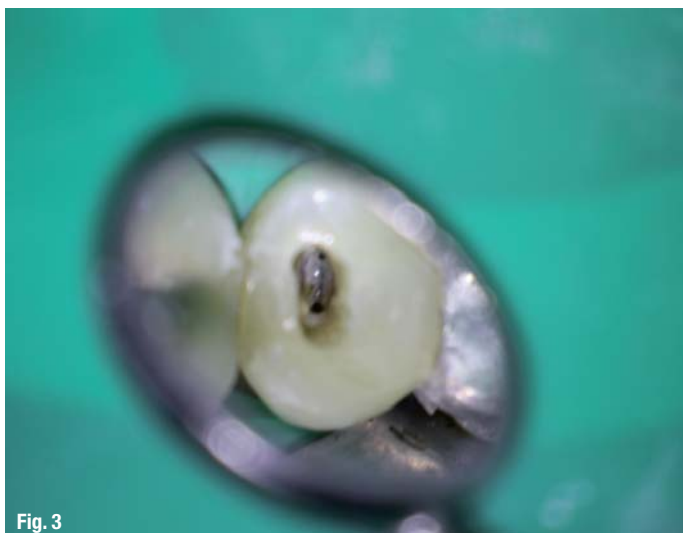
Fig. 3

Fig. 4

_Case Report

A 50-year-old male patient was referred to my endodontic practice for evaluation and possible treatment of his left maxillary second premolar. The tooth was percussion painful and a buccal swelling was evident. Endo-Ice cold vitality testing was negative. Radiographic examination, moreover, revealed a periapical lesion associated with a highly curved root (Figs. 1 & 2). The pulp was consequently diagnosed as necrotic and the periapical diagnosis was consistent with Symptomatic Apical Periodontitis (SAP).

After placing the rubber dam, the pulp chamber was accessed with a diamond DiaDent bur under microscopic visualisation. Two confluent canals were identified and length determination radiograph revealed the highly curved canal anatomy (Fig. 3). Length was verified using the CanalPro Apex Locator. Instrumentation was then achieved with the Hyflex CM rotary files used in a single length protocol. After flaring with 25/0.8, the rotary file sequence followed consisted of 15/0.4, 20/0.4, 25/0.4, 20/0.6 and 30/0.4 to length. After the instrumentation procedure a radiograph confirmed that the original trajectory was maintained (Fig. 4). The angulation of the aforementioned periapical radiograph revealed two lateral lesions

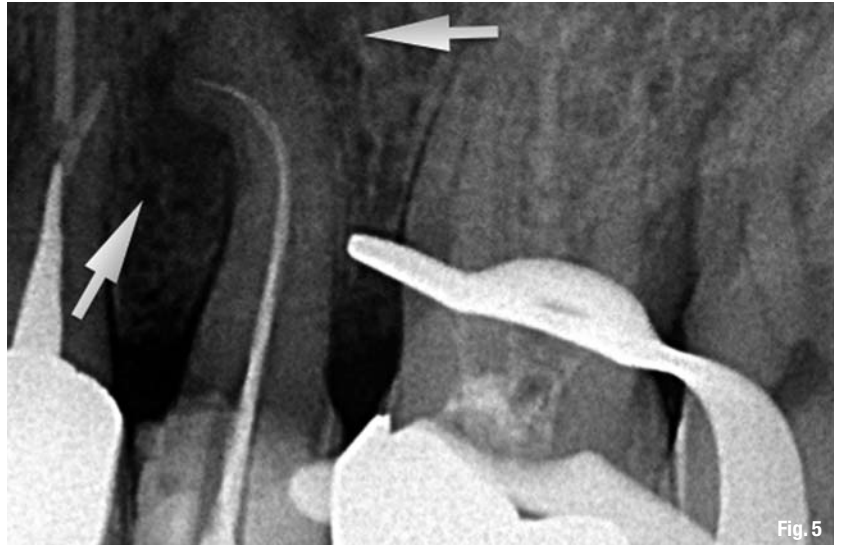


Fig. 5

suggesting two lateral portals of exit (Fig. 5). The canals were rinsed after each change of instruments according to a strict irrigation protocol. Two corresponding 30/0.4 gutta-percha master cones were then fitted to the canals. The rinsing solution was activated by using dynamic manual agitation with the master gutta-percha cones (holding the cone with tweezers to gently move it up and down).

Fig. 5 _Lateral lesions suggesting two lateral portals of exit.

During this process, an endodontic aspirator tip was used to dry the root canals. The Swiss dental specialist Coltène/Whaledent recently introduced an aspirating tip specially developed for drying root canals. With an outer diameter corresponding to ISO 60, the Surgitip-endo can be inserted directly into the prepared canal where it removes rinsing solutions and other moisture quickly and effectively at the same time. Thanks to a special fully rotating ball joint, the suction tip is highly flexible and collapsing of the tip is therefore avoided (Fig. 6). You can easily fit it into root canals that are normally hard to reach without having to bend the canal tip. After drying the confluent canals, the Surgitip-endo was fitted to the buccal canal orifice and the irrigation solution was injected in the lingual canal. Simultaneous negative and positive pressure irrigation from different orifices created a continuous current of fresh irrigant washing out all debris.

In the next step the preparation for negative pressure filling of the root canal system was taking place. This special filling system was created with the



Fig. 6

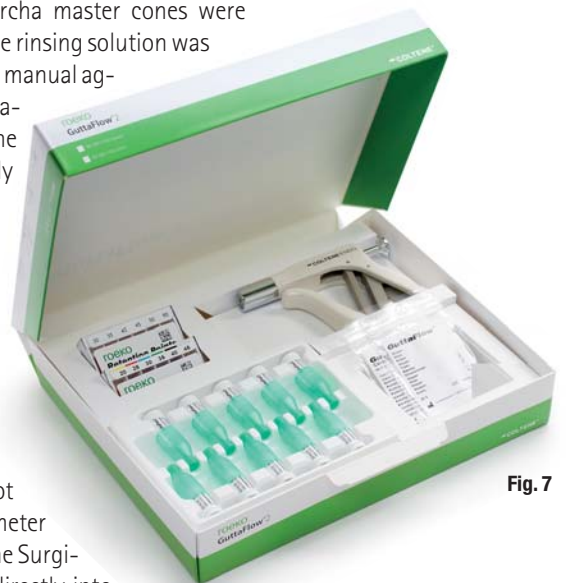

Fig. 7

Fig. 6 _Surgitip-endo aspirator tip.

Fig. 7 _Gutta Flow Introkit.

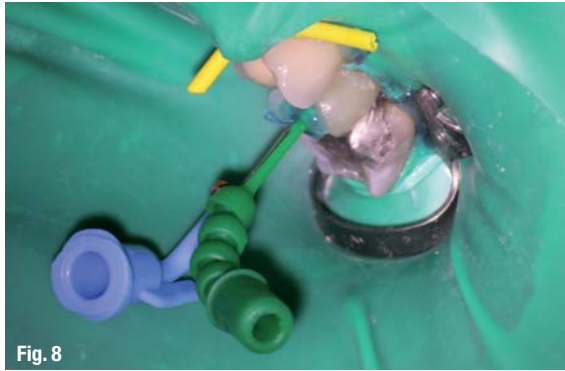

Fig. 8

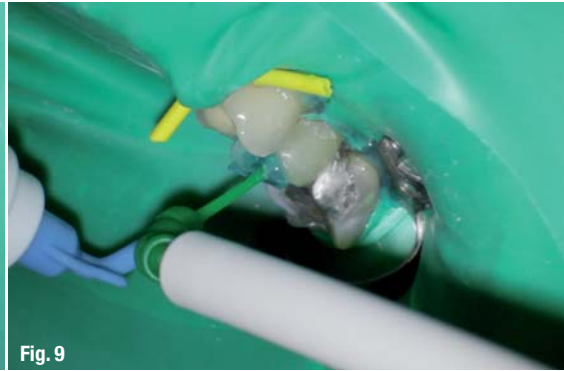

Fig. 9



Fig. 10

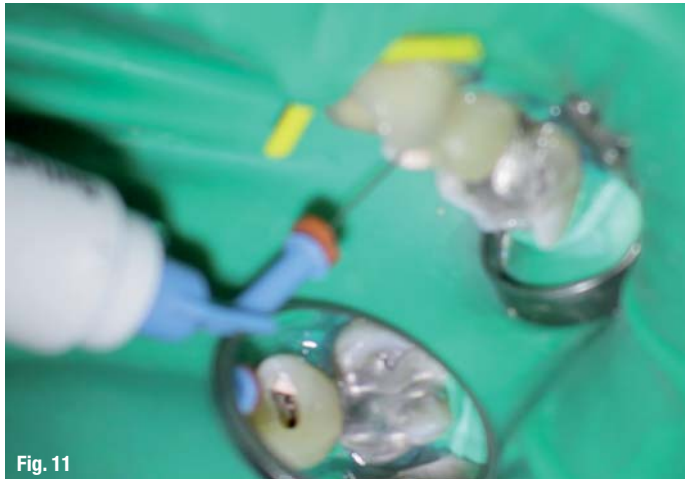

Fig. 11

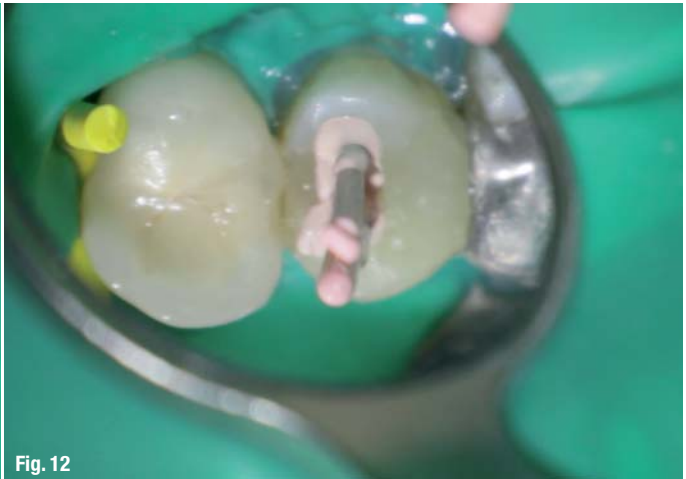


Fig. 12

Fig. 8_ Fixing both tips in the orifices by sealing material.

Fig. 9_ Attaching the Surgitip-endo and GuttaFlow 2 FAST capsule.

Fig. 10_ Visualisation of the technique in a plastic training block.

Fig. 11_ Classic backfill after removal of temporary seal.

Fig. 12_ Seating of pre-fitted master cones.

Fig. 13_ Position of the master cones.

use of the Surgitip-endo and the tight seal material GuttaFlow 2 (Fig. 7). This filling material combines cold free-flow gutta-percha and a sealer creating an easy to handle, fast flowing filling material, which has been proven as a reliable barrier against bacteria and liquids re-entering the root canal. Its working time takes approximately ten to fifteen minutes. Before the actual procedure starts, it is necessary to fix both the Surgitip-endo front part as well as the CanalTip of the GuttaFlow capsules at the entrance of both canals. Both the front part of Surgitip-endo and a

canal tip are firmly fixed in the different orifices by a sealing material that is polymerised for approximately 10 seconds (Fig. 8). The seal at the canal entrance works as a temporary cap to enable the establishment of negative pressure underneath it with the aid of the aspirating tip. With this special trick a negative pressure zone can be created, which allows literally to pull the gutta-percha filling material into smaller lateral canals and ramifications that were hardly detectable in the anamnesis before.

Now a GuttaFlow 2 FAST capsule was attached to the CanalTip as well as the Surgitip-endo to its front part (Fig. 9). While the air was sucked off with the Surgitip-endo above the filling, the gutta-percha material was released into the canal system simultaneously and quickly spread into the prepared root canal system. In general, the innovative design of the suction tip ensures unrestricted high suction performance at all angles, therefore the gutta-percha was evenly distributed and filled the confluent canals within seconds. Complete control of the material extrusion was consequently achieved (Fig. 10). After the injected GuttaFlow 2 had reached the Surgitip-endo, the temporary sealing material could be removed. The rest of the GuttaFlow 2 capsule was used for a classic backfill and the pre-fitted master cones were very slowly seated in place (Figs. 11–13). The tooth was restored with a fiber post, a composite built up and a PFM crown. In the final radiographic image of the

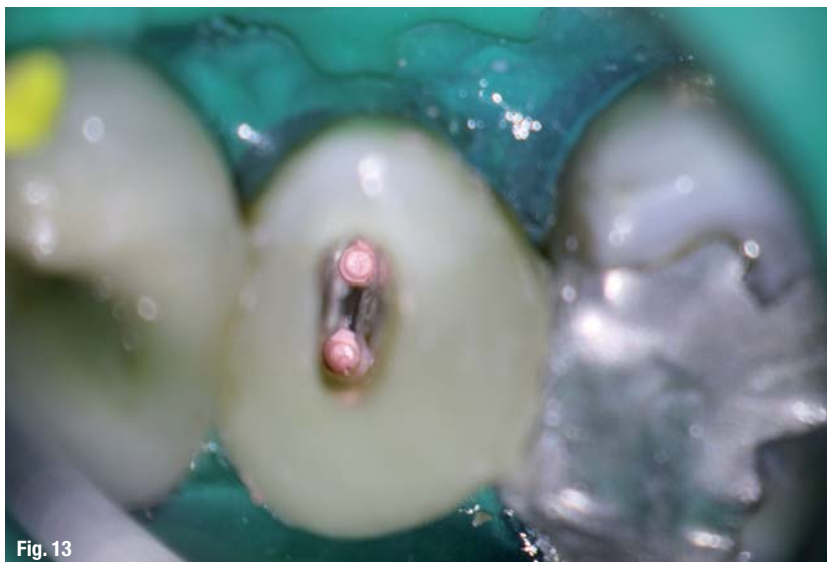
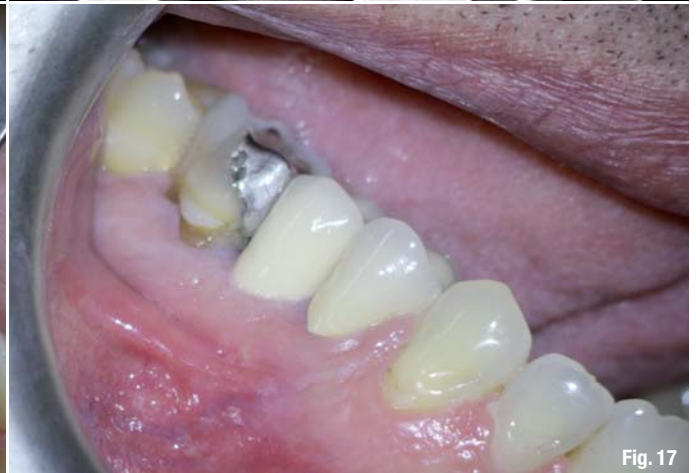
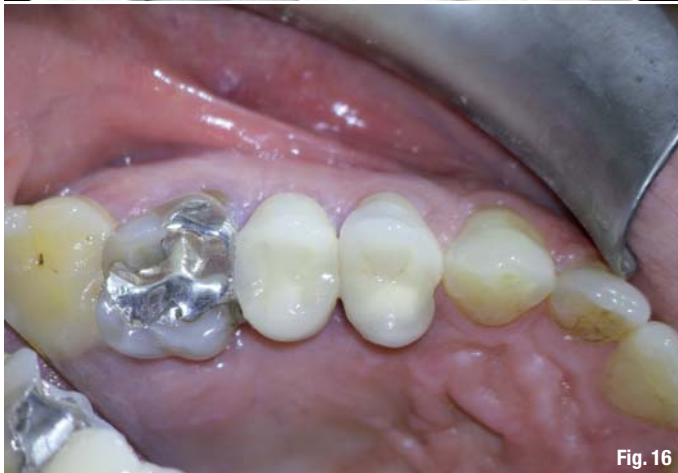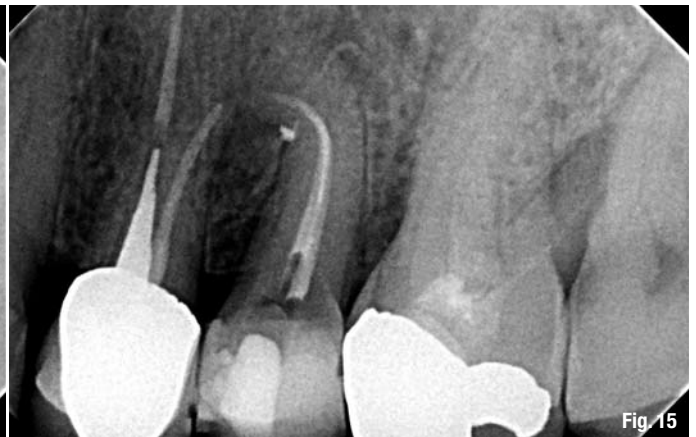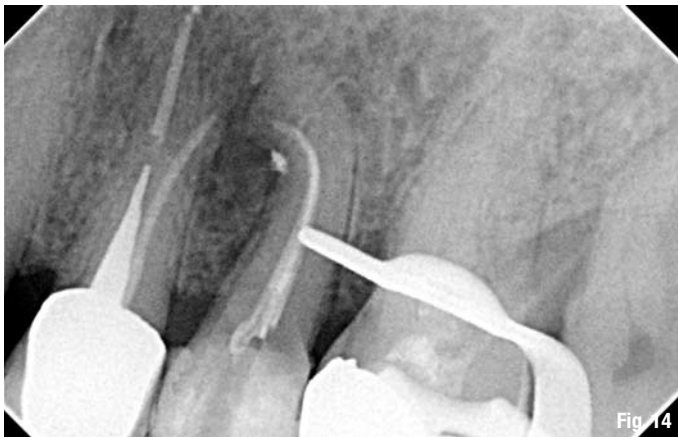Fig. 13



tooth right after the RCT, the lateral ports of exit could be visualised (Fig. 14). One year after the treatment, the follow-up radiograph revealed complete healing. The non-absorbable GuttaFlow 2 could be detected unaltered in the lateral portals of exit (Fig. 15). The buccal and occlusal clinical view of the tooth and soft tissues can be seen in Figures 16 and 17.

Conclusion

Innovative filling systems nowadays come with excellent flow properties. They are easy to handle and help to speed up treatment sessions, even more so if dentists make good use of their endodontic instruments. Creating a negative pressure zone with a special endodontic aspiratory tip is easy to learn, but saves additional time in the process. No extra material or instruments are needed. The gutta-percha is easily distributed to the root canal system, even in areas that are hardly detectable beforehand and often impossible to fill. The combination of modern equipment and individual craftsmanship thus guarantees a tight seal of the root canal for an optimum protection against re-infection. Negative pressure obturation with GuttaFlow 2 provides absolute material control and a fluid tight seal of the main root canal system and its lateral components.

about the author

roots



Dr Antonis Chaniotis graduated from the University of Athens Dental School in 1998. In 2003 he completed the three-year postgraduate program in Endodontics at the University of Athens Dental School.

He is a clinical instructor affiliated with the undergraduate and postgraduate programs in the Athens Dental School department of Endodontics. Dr. Chaniotis has published numerous articles in both local and international trade journals and has lectured at over 40 local and international congresses. Since 2011, he has served as administrator of the Endo-Implant-Algorithm video blog of the Dental Tribune Study Club.

Dr Antonis Chaniotis

140 EL. Venizelou Av., Stoa Karantinou,
17676 Kallithea, Athens
Greece

antch@otenet.gr

Fig. 14 Visualisation of lateral ports of exit.

Fig. 15 Radiograph one year after treatment with non resorbable GuttaFlow 2.

Fig. 16 Occlusal clinical view.

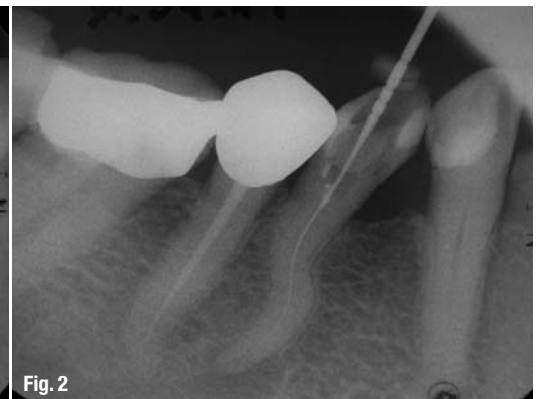
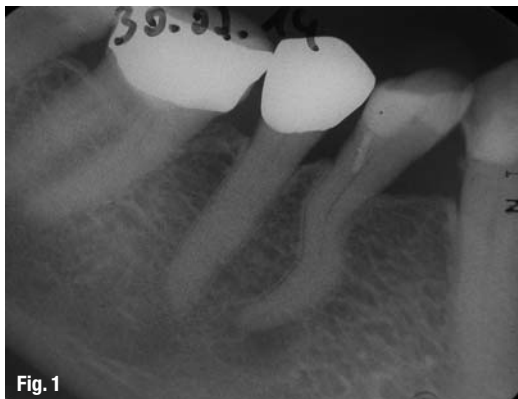Fig. 17 Buccal clinical view.

S-shaped root— risks of a master challenge in endodontology

Author_ Dr Friedrich Müller, Germany

Fig. 1_Diagnostic radiograph of tooth 45 and tooth 44.

Fig. 2_Radiograph with masterpoint in tooth 45 and Hedstrom file in tooth 44.



An 81-year-old female patient came with typical pulpitis pain in the right side lower mandible.

The sensitivity testing showed a prolonged positive result in tooth 45 and no result in tooth 44. The percussion testing showed contrary results; no result in tooth 45 and a slight positive result in tooth 44. A radiograph showed an apical lesion of endodontic origin in tooth 44 and no diagnostic findings in tooth 45.

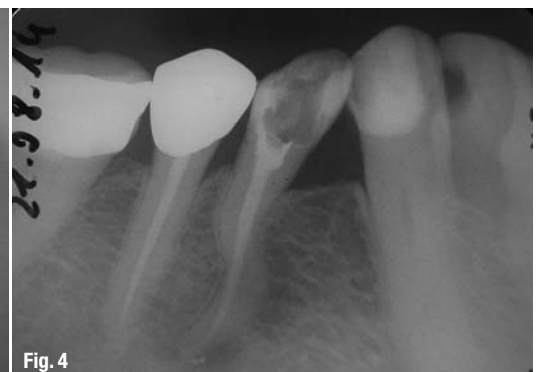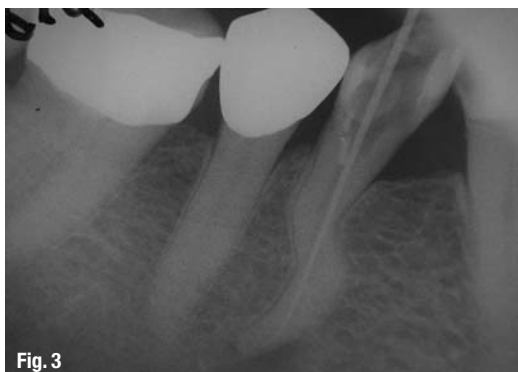Although the endodontic lesion in tooth 44 must have been present for several months due to its di-

mension, the cause of her acute pain was tooth 45. Furthermore, the radiograph showed an s-shaped root morphology in tooth 44 that made endodontic treatment not just difficult, but a real master challenge.

The pulp chamber of both teeth were opened after anaesthesia and the diagnosis of irreversible pulpitis in tooth 45 and infected necrosis in tooth 44 was confirmed by intracoronary inspection. While prolonged intracanal bleeding could be observed in tooth 45, there was upwelling pus in tooth 44.

Fig. 3_Radiograph with masterpoint in tooth 44.

Fig. 4_Radiograph of canal obturation in tooth 45 and tooth 44.



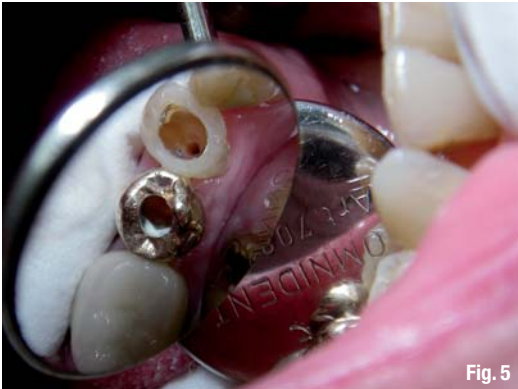

Fig. 5

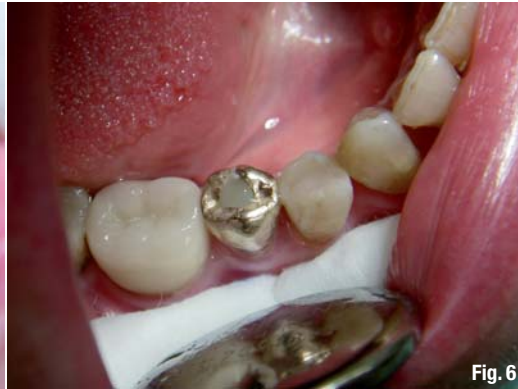

Fig. 6

Fig. 5_ Pulp opening and canal access.

Fig. 6_ Coronal closure with composite material.

After irrigation with 3% natriumhypochloride solution, the apex locator showed 21 mm working length in tooth 45. The cleaning and shaping of the root canal of tooth 45 was completed in the first appointment. A combination of tetracycline and cortisone was brought into the root canal reaching its depth. In tooth 44, probing was performed with a Hedström file (ISO 08/.02) to drain the pus. The second stage of treating tooth 44 also included probing and irrigation, as well as the exploration of the working length with an apex locator 21 mm in length.

After manual cleaning and shaping with Hedström files, subsequent irrigation followed by reciprocating preparation, a radiograph was taken to confirm the length of the root canal. In the third endodontic approach, the working length was reconfirmed and both root canals were obturated with gutta percha in a combination of cold and warm obturation. As it can be seen, one major risk in s-shaped roots is the straightening of the curvature wherefore the preparation of the root canal should not exceed ISO 25 to prevent accidental weakening or strip perforation of the inner bend.


_author	roots
<p>Dr Friedrich Müller Specialist in Periodontology, Implantology and Endodontology</p> <p>Private Dental Practice Dr Janine + Dr Friedrich Müller Tannenring 76 65207 Wiesbaden-Auringen Germany</p> <p>www.muellerzahnarzte.de</p>	

AD




"These products represent a major advance in bonded root filling restorations over traditional root canal sealers"

- Dr. Martin Trope, Clinical Professor, University of Pennsylvania




FKG
swiss endo

► **TotalFill®**, Premixed Bioceramic Endodontic Materials




TotalFill® BC Obturation kit

- Preloaded BC Sealer syringe for 3D obturation
- BC Points



TotalFill® BC RRM Paste

- Preloaded syringe for root repair needs



TotalFill® BC RRM Putty

- Ready to use for retro surgical

FKG Dentaire SA
www.fkg.ch

PIPS and retreatment

Author_ Dr Reid Pullen, USA

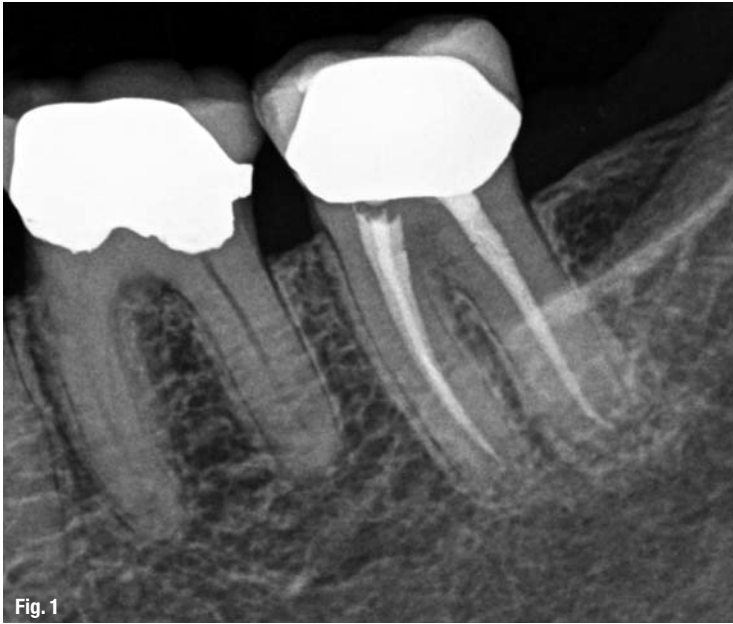

Fig. 1

Fig. 1_Pre-op #18.

Retreatment can be a difficult and time-consuming endeavour. The first order of business is to figure out why the primary root canal treatment is failing. Sometimes the answer will be evident after the patient interview, clinical exam and radiographic analysis, but other times the root canal failure is a mystery. Some of the questions I recommend thinking about are: Was a rubber dam used? Is there a root fracture? Is there a missed canal? Did the practitioner use sodium hypochlorite and use proper irrigation

methods? Is the root canal undefined and/or under condensed?

Is there periodontal involvement? If the supporting periodontium appears healthy and the root does not appear to be fractured, than typically the root canal failure is originating from inside the canal system. With all of these factors in play it is not surprising that the retreatment success in endodontics is lower than primary root canal success by 10 to 20 per cent. While retreatment success can vary from 70 to 90 per cent, non-surgical root canal treatment success hovers around 90 per cent. This article will review the Photon Induced Photoacoustic Streaming (PIPS) (Lightwalker Laser from Fotona) literature and discuss a retreatment case where the PIPS irrigation technique was instituted in hopes of increasing the success rate.

_PIPS introduction

PIPS is a technique that uses Erbium:YAG laser energy to agitate the irrigation solution inside a root canal system and cause a violent shockwave effect that can lyse bacteria cells and remove biofilm. By placing the tapered PIPS tip into the access and irrigation solution, subablative laser is used to push a tsunami of irrigation solution into the main root canal, the lateral, secondary and accessory canals, isthmuses and the deep complex apical anatomy of the treated tooth. PIPS creates an irrigant shockwave of bacterial destruction.

Fig. 2_Intact gutta-percha cone removal.

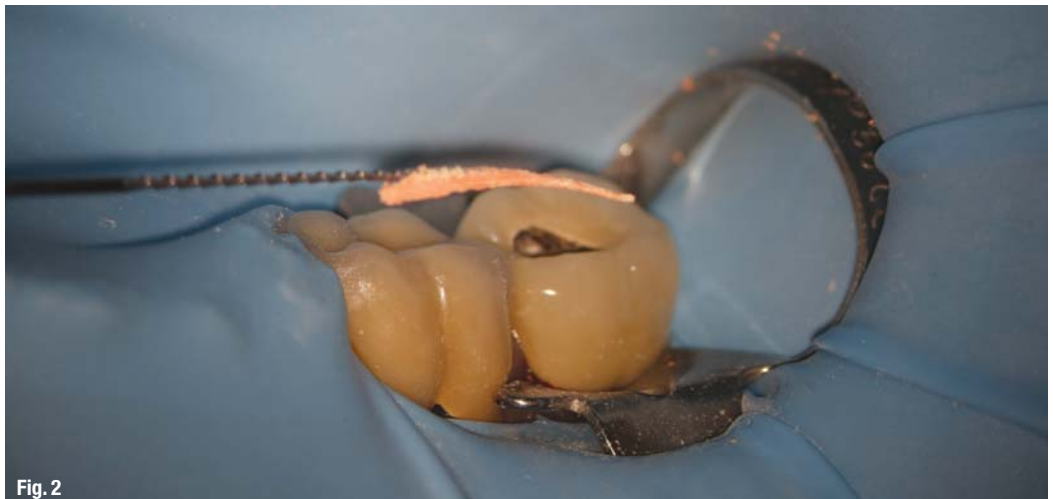

Fig. 2

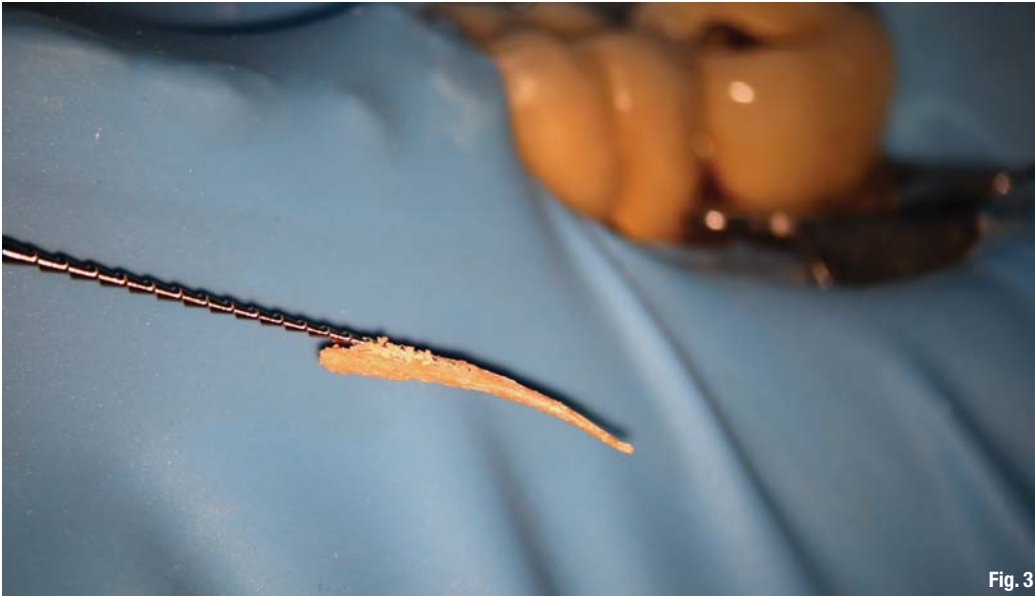


Fig. 3 Intact gutta-perchacone removal with Hedström file.

PIPS and research

An article in 2011 showed that the PIPS technique was superior in removing bacteria when compared to standard needle aspiration and passive ultrasonic irrigation when using 6 per cent sodium hypochlorite in an extracted premolar tooth prepped to a size 20 foramen with an 07 taper.¹ Another article shows 100 per cent inhibition of regrowth of *Enterococcus faecalis* after using the PIPS irrigation technique for 20 seconds with 6 per cent sodium hypochlorite in a single rooted tooth. These teeth had soaked in an *Enterococcus faecalis* broth for four weeks.² PIPS also effectively removed biofilm from within the root canal system. In a bovine study model, PIPS outperformed standard needle irrigation, the EndoActivator, and passive ultrasonic irrigation in removing biofilm from infected bovine dentin.³ In an article published this year, PIPS was shown to remove debris and increase canal space 2.6 times greater than standard needle irrigation in the isthmuses of lower molars.⁴

PIPS and retreatment

A 62-year-old female patient presents with a chronic, persisting pain in the mandibular left second molar (#18) duration two weeks. The tooth had been endodontically treated approximately two years prior. The patient was unable to bite on #18 without significant discomfort.

Clinical testing revealed that #18 was percussion- and bite-stick-sensitive, while #19 and #20 tested normal to all tests. Radiographic analysis revealed that #18 had an adequate root canal without a periapical lesion (Fig. 1). Because of the positive clinical tests, it was determined that #18 needed a non-surgical root canal retreatment.

The patient was anesthetized and a rubber dam was placed. The composite core access was removed with a 701 carbide and 557 surgical length carbide bur. Upon inspection of the gutta-percha it appeared an uncontaminated "healthy" pink and did not contain any odor. It did not look or smell like the majority of retreatments where the gutta-percha appeared to be a mixture of black and pink colour with a nefarious odour.

Before using chloroform, the ProTaper Retreatment #2 and #3 rotary files (DENTSPLY Tulsa) were used at 500 rpm to carefully remove the majority of the coronal and middle gutta-percha. In two of the three canals the #2 or the #3 retreatment rotary file removed the entire cone from the canal, making it an extremely efficient retreatment and allowing extra

Fig. 4 Post-op #18.

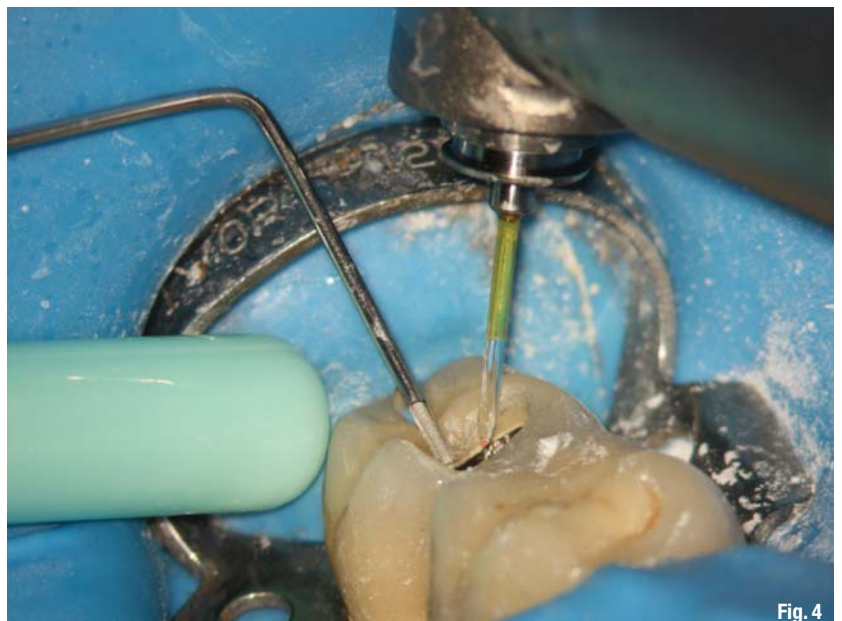

Fig. 4

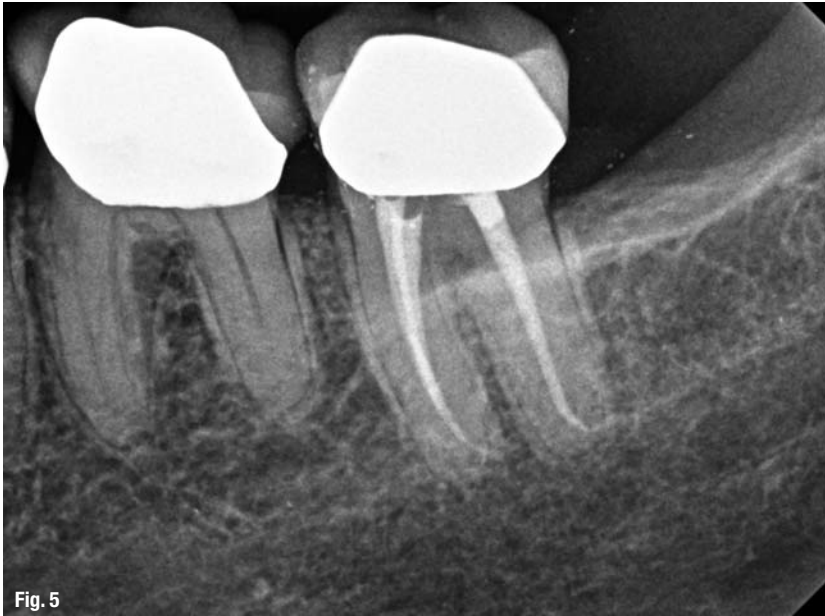

Fig. 5 PIPS in action. treatment time for 6 per cent NaOCl to soak inside the canal system.
(Photos: Provided by Technology4Medicine)

The technique was as follows: Carefully drill into the gutta-percha with the retreatment rotary file and after a 5- to 10-mm bite stop rotation. Let it cool for a few seconds and then with one hand pull up on the rotary hand piece head while the other hand is protecting the maxillary teeth from any blunt trauma in case the hand piece head pulls out of the canal with high velocity.

In some cases if a single cone has been used and/or if the sealer did not set or was inadequately placed, the entire cone will come out in one piece.

In this case, two of the three cones were extracted fully intact while using the rotary technique mentioned above. The third cone was removed intact with a #35 Hedström file (Figs. 2 & 3). The canals were then "PIPSed" for 30 seconds with 6 per cent NaOCl as the irrigation solution and then patency and working length were established using hand files and an electronic apex locator (EAL). The canals were then reshaped with a reciprocating WaveOne Primary file (DENTYPLY Tulsa) and a final PIPS protocol was followed using 6 per cent NaOCl, distilled water, 17 per cent EDTA and then distilled water (Fig. 5). Because it appeared that a single cone technique was used and that the resin sealer did not fully set, or was not adequately placed into the canal, the case was completed in one visit. The canals were obturated with Bioceramic Gutta Percha coated cones and Bioceramic Sealer (Brasseler USA). A modified warm vertical condensation technique was used to help condense and pack the gutta-percha and sealer. The canals were backfilled with warm gutta-percha (Fig. 4).

Conclusion

PIPS is a ER:YAG laser-enhanced irrigation technique where laser energy is used to violently agitate canal irrigant. Studies have shown that it is more effective in killing bacteria, removing biofilm, removing canal debris and increasing canal space than standard needle irrigation, sonic irrigation and passive ultrasonic irrigation.

In my experience of "PIPSing" over 2,000 cases, I see an increase in the obturation of lateral canals and deep complex apical anatomy. PIPS also aids in removing pulp stones, retreatment canal debris and separated files that have been loosened by ultrasonics. Photon induced photoacoustic streaming gives the clinician confidence that they are doing everything in their power to clean the entire root canal system.

References

1. Peters OA, Bardsley S, Fong J, Pandher G, Divito E. Disinfection of Root Canals with Photon-initiated Photoacoustic Streaming. *J Endod* 2011;37:1008–1012.
2. Jaramillo DE, Aprecio RM, Angelov N, Divito E, McClammy T. Efficacy of photon induced photoacoustic streaming (PIPS) on root canals infected with *Enterococcus faecalis*: A pilot study. *Endodontic Practice* 07/2012.
3. Ordinola-Zapata R, Bramante CM, Aprecio RM, Handsides D, Jaramillo DE. Biofilm removal by 6% sodium hypochlorite activated by different irrigation technique. *International Endodontic Journal*; 10/2013.
4. Lloyd A, Uhles JP, Clement DJ, Garcia-Godoy F. Elimination of Intracanal Tissue and Debris through a Novel Laser-activated System Assessed Using High-resolution Micro-computed Tomography: A Pilot Study. *J Endod* 2014;40:584–587.

about the author

roots




Dr Reid Pullen, DDS, FAGD, graduated from USC dental school in 1999 and served three years in the US Army as a dentist in Landstuhl, Germany. While in the Army, he completed a one-year advanced education in general dentistry residency.

After the military, Pullen practiced as a general dentist for two years in southern California, prior to attending the endodontic residency at the Long Beach Veterans Hospital in 2004. He graduated from the endodontic residency in 2006 and has maintained a private practice limited to endodontics in Brea, Calif., since 2007. Pullen obtained his endodontic board certification in 2012.

cone beam

international magazine of cone beam dentistry



 **Subscribe now!**

I would like to subscribe to **cone beam** (4 issues per year) for €44 including shipping and VAT for German customers, €46 including shipping and VAT for customers outside Germany, unless a written cancellation is sent within 14 days of the receipt of the trial subscription. The subscription will be renewed automatically every year until a written cancellation is sent to Dental Tribune International GmbH, Holbeinstr. 29, 04229 Leipzig, Germany, six weeks prior to the renewal date.

▶ **Reply** via Fax +49 341 48474-173 to Dental Tribune International GmbH or per E-mail to info@dental-tribune.com

Last Name, First Name

Company

Street

ZIP/City/County

E-mail

Signature

Notice of revocation: I am able to revoke the subscription within 14 days after my order by sending a written cancellation to Dental Tribune International GmbH, Holbeinstr. 29, 04229 Leipzig, Germany.

Signature

“Continuous Education is a top priority for us, first proof is our new Training Centers”

Interview with Alexandre Mulhauser, FKG Dentaire Middle East & Africa Director.



Fig. 1 _Alexandre Mulhauser, FKG Dentaire Middle East and Africa Director.

DTI: Can you introduce us FKG Dentaire?

Alexandre Mulhauser: Founded in 1931 in the heart of the watch valley, FKG Dentaire is a Swiss company internationally renowned for its high quality products for dentists, Endodontists and laboratories. The Swiss High Tech company is led by two visionaries namely Jean Claude Rouiller (Chairman) and his son Thierry Rouiller (CEO), who have a mission to always push Endo forward for the benefit of both the dentists and patients. This has been made possible thanks to the creation of one of the most modern Endo factories as well as the close collaboration between the teams of Research & Development, Sales, Marketing and a team of General Practitioners and Endodontists globally.

_FKG inaugurated its Regional Office and Training Centre around 6 months ago in Dubai. What were the reasons for this set up?

I joined the FKG team almost four years ago to build up a new strategy which was to develop FKG Dentaire in the Middle East and Africa Region. When I started this new challenge the FKG Dentaire name was known but the distribution network in the ME-A region was not operating properly with sales being below average compared to other regions. We are pleased to see that in a few years we were able to level up from the few countries where we were represented to over 30 countries today and we continue to increase monthly. This has been possible thanks to a new positioning, a complete reorganization of the distri-

bution channels, selection and training of serious Distributors that share our vision of quality and the service to customers. It has been a success also thanks to the reactivity and flexibility of the structure and a fluidity of information together with fast decision processes with our CEO, Thierry Rouiller. Even with all the effort and dedication, we believed being in the core of this market and tightening the links with our customers will be the key to success. The decision was finalized in December 2012 and by June 2013 the subsidiary was created and we moved to Dubai.

_Has the decision been good to choose UAE as your regional hub?

Companies that open a regional headquarter in the ME-A Region usually open it either in Egypt, Jordan, Lebanon or United Arab Emirates. Due to the number of meetings we have around the region, installing the ME-A office less than 45 minutes road of two major airports (Dubai and Abu Dhabi) was the best choice to manage efficiently our travels. We decided to create the first MEA Endo Training Center owned by an Endo manufacturer and fully equipped with microscopes. The UAE training center receives groups from Middle East, Africa but also now India and is open to all other countries. Dentists who would like to come for a training do not have time to lose in connections between airports and these two hubs and their great number of connections are very useful for us to organize trainings. In addition, many love to travel to Dubai for the trainings while enjoying a visit to the Emirates. In all cases the decision has proved a perfect choice.

_What are the plans for the nearest future and the Training Centre?

FKG Dentaire is already collaborating with international speakers (Dr Gilberto Debelian, Dr Martin Trope, Dr Bertrand Khayat and others). We are currently finalizing a team of highly skilled clinicians based in the ME-A Region passionate about FKG Instruments and ready to share their experiences and knowledge. Dentists are eager to test our technologies and we may increase the number of trainings in the UAE Office and around the ME-A Region. Regarding the training center, thanks to the growing number of top products in the FKG Dentaire range, along with partnerships with other companies we plan to also

diversify the subjects. This might be linked with the organization of trainings with partners managing high level Continuous Education Programs. Depending on your level, your points of interests or the skills you want to improve you will have a portfolio of dates and subjects to choose from. Following the success of the last months we also plan to increase the size of the FKG UAE training center to answer to the demand. The FKG Dentaire ME-A team is growing and we plan to focus on emerging markets where FKG has had a very small presence until now but with high demand from dentists that have had the opportunity to try our range during international conferences or that could read evidence based articles about Race. The FKG ME-A Division is currently opening Pakistan and as of recent is also in charge of India, a great and exciting new challenge for us. On the product side, 2013 has been a great year for FKG Dentaire and we are accelerating in 2014 and 2015. We have developed a new generation of Endo Motor called Rooter together with dentists, Endodontists and a French partner. These motors are the first wireless motors to come with a detachable and sterilizable LED Light. Rooter is extremely well balanced for the comfort of the Dentists and the programmable speed ranges from 250 to 1,200rpm to fit with all of rotary files needed by clinicians. Rooter should be available in the coming weeks in our distribution network throughout the ME-A region. We are currently launching FKG Dentaire BT-Race (a new single use and sterile 3 files sequence with a revolutionary tip) and TotalFill BC Sealer, a user friendly Hydrophilic Bioceramic filler that has already a lot of articles stating its fantastic results. The TotalFill range is completed with TotalFill RRM putty (Bioceramic Root Repair Material). The FKG Dentaire team has been working hard on the different states of the Nickel Titanium, clinical tests results are beyond expectation so a lot of great things are ahead with the launch of a new product in the near future. It will be a new breakthrough in Endo.

How does FKG separate itself from its competitors?

The Swiss Venture Club awarded FKG "Western Switzerland Company of the Year 2012", an award for the company's dynamism, high product quality, and its continuing innovation. The Race files are a real revolution in the Endodontic world, these files are opposite to most of the products on the market and it does not screw thanks to an alternating cutting edge design. This allows the dentist to be more confident using a precise file which the dentist controls. It also features the SMD (Safety Memo Disk), a patented daisy on all the instruments which is the only user friendly system allowing the clinicians to know exactly how many times a file has been used and help to monitor the file stress to reduce risk of file separation. FKG Dentaire has developed a sequence of scouting files years before any company on the market, the Scout

RaCe 10.02 is still today's smallest rotary file and now a new generation of tips are available with six blades (Available on BT Race). It is able to drill and follow the way in the canals without stressing the root unlike big tapered files. FKG Dentaire is not led by marketing and sales figures but by passion of precision, quality and pride of happiness of dentists and patients.

How important is Continual Medical Education for FKG and its clients?

Continuous Education is a top priority for us, first proof is our Training Centers in UAE, Switzerland and Norway, the second is the organization of trainings with CME providers such as Centre For Advanced Professional Practices (CAPP) and partnerships with private and public hospitals and clinics asking us to train their teams all throughout the year. We have also recently announced the start of a partnership with the Dental College in Lebanon. Prof. Roger Rebeiz and his team will use the FKG Dentaire MEA Training Center in Dubai for its Educational Program.

Where do you see FKG in a year from today?

In the hands of all dentists and Endodontist wishing to share our vision of conservative and biological Endo.

What are some of the regional events you are attending with FKG?

In United Arab Emirates we are present in most of the important conferences in the region such as the Dental Facial Cosmetic Int'l Conference, AEEDC, APDC, and even the CAD/CAM & Digital Dentistry Int'l Conference through our distributor Dubai Medical Equipment. We have been really active at the Pan Arab Endo Conference in Lebanon this year bringing Dr Gavin Williams, a very experienced South African Endodontist and Prof. Roger Rebeiz, Lebanon who provided a live retreatment with FKG Files D-Race and iRace. We are also represented in most of the congress and shows in the region through our distributors and partners.

You are a member of MEMA Association, can you tell us about it?

MEMA (Middle East Managers Association) has been created few years ago in Lebanon. It gathers today over 70 Middle East Managers of Top Dental companies. The goal of this association is to grow the dental market through the network and expertise of this team of skilled professionals. I believe all dental industry Middle East managers that are not already part of MEMA should join; it is a very respectful and friendly environment with great perspectives.

Editorial note: This interview has been registered at the Training Centre in Jumeirah Lake Towers in Dubai by Dental Tribune Middle East & Africa in 2014.

Diclofenac, dexamethasone or laser phototherapy?

Part II

Author_Jan Tunér, Sweden

[PICTURE: ©ROBERT KNESCHKE]

Introduction

In part I, the author informed about studies which investigated the effects of diclofenac and LPT. In the second part, they continue their investigation into the vast literature and studies on this topic and give their conclusion.

In the May 2013 edition of *Photomedicine and Laser Surgery*, the editorial written by Prof. Tina Karu is titled "Is it time to consider photobiomodulation as a drug equivalent?" Well, is it? Let us have a look and see what the literature has to say about two very popular drugs. Although the previously-mentioned studies indicate that LPT is as effective, or more effective as diclofenac, a potentiation of the effect of diclofenac by adding LPT is suggested in the following study:

The aim of the study by Markovic¹¹ was twofold: (1) to evaluate the postoperative analgesic efficacy, comparing long-acting and intermediate-acting local anaesthetics; and (2) to compare the use of laser irradiation and the non-steroid anti-inflammatory drug diclofenac, which are claimed to be among the most successful aids in postoperative pain control. A twofold study of 102 patients of both sexes undergoing surgical extraction of LTM was conducted. In the first part of the study, twelve patients with bilaterally impacted lower molars were treated in a double-blind crossover fashion; local anaesthesia was achieved with 0.5% bupivacaine plain or 2% lidocaine with 1:80,000 epinephrine. In the second part of the study, 90 pa-

tients undergoing lower molar surgical extraction with local anaesthesia received postoperative laser irradiation (30 patients) and a preoperative single dose of 100 mg diclofenac (30 patients), or only regular postoperative recommendations (30 patients). The results of the first part of the study showed a strikingly better postoperative analgesic effect of bupivacaine than lidocaine/epinephrine (eleven out of twelve; four out of twelve, respectively, patients without postoperative pain). In the second part of the study, LPT irradiation significantly reduced postoperative pain intensity in patients premedicated with diclofenac, compared with the controls. Provided that basic principles of surgical practice have been achieved, the use of long-acting local anaesthetics and LPT irradiation enables the best postoperative analgesic effect and the most comfortable postoperative course after the surgical extraction of lower molars.

Dexamethasone is a corticosteroid, thus not an NSAID, but the issue of replacing pharmaceuticals with long-term negative effects to a treatment with no side effect is urgent here as well.

A rabbit model of endophthalmitis was established by Ma¹² to evaluate the anti-inflammatory effect of LPT as an adjunct to treatment for *Staphylococcus epidermidis endophthalmitis*. Rabbits were randomly divided into three groups to receive intravitreal injections into their left eye: group A received 0.5 mg vancomycin (100 µl), group B received 0.5 mg vancomycin + 0.2 mg dexamethasone

(100 mcl), and group C received 0.5 mg vancomycin (100 mcl) and laser irradiation (10 mW, 632 nm) focused on the pupil. Slit lamp examination and B-mode ultrasonography were conducted to evaluate the symptoms of endophthalmitis. Polymorphonuclear cells and tumour necrosis factor alpha (TNF- α) in aqueous fluid were measured at 0 h, and one, two, three, seven and 15 days. A histology test was conducted at 15 days. B-mode ultrasonography and histology revealed that groups B and C had less inflammation than group A at 15 days. Groups B and C had fewer polymorphonuclear cells and lower levels of TNF- α in aqueous fluid than group A at two, three and seven days. There was no significant difference between groups B and C. There was no significant difference between groups A, B and C at 15 days. As an adjunct to vancomycin therapy to treat *S. epidermidis endophthalmitis*, LPT has an anti-inflammatory effect similar to that of dexamethasone.

Castano¹³ tested LPT on rats that had zymosan injected into their knee joints to induce inflammatory arthritis. The author compared illumination regimens consisting of a high and low fluence (3 and 30 J/cm²), delivered at high and low irradiance (5 and 50 mW/cm²) using 810 nm daily for five days, with the positive control of conventional corticosteroid (dexamethasone) therapy. Illumination with a 810 nm laser was highly effective (almost as good as dexamethasone) at reducing swelling, and a longer illumination time (10 or 100 minutes compared to 1 minute) was more important in determining effectiveness than either the total fluence delivered or the irradiance. LPT induced reduction of joint swelling correlated with reduction in the inflammatory marker serum prostaglandin E₂ (PGE₂).

Reis¹⁴ investigated the role of extracellular matrix elements and cells during the wound healing phases following the use of LPT and anti-inflammatory drugs. Thirty-two rats were submitted to a wound inflicted by a 6-mm-diameter punch. The animals were divided into four groups: sham treated, those treated with the LPT (4 J/cm², 9 mW, 670 nm), those treated with dexamethasone (2 mg/kg), and those treated with both LPT and dexamethasone. After three and five days, the cutaneous wounds were assessed by histopathology using polarised light and ultrastructural assessments by transmission electron microscopy. Changes seen in polymorphonuclear inflammatory cells, oedema, mononuclear cells, and collagen fibre deposition were semi-quantitatively evaluated. The laser-treated group demonstrated increased collagen content and better arrangement of the extracellular matrix. Fibroblasts in these tissues increased in number and were more synthetically active. In the

dexamethasone group, the collagen was shown to be non-homogenous and disorganised, with a scarcity of fibroblasts. In the group treated with both types of therapy, fibroblasts were more common and they exhibited vigorous rough endoplasmic reticulum, but they had less collagen production compared to those seen in the laser group. Thus, LPT alone accelerated post-surgical tissue repair and reduced oedema and the polymorphonuclear infiltrate, even in the presence of dexamethasone.

In a study by Jajarm¹⁵ thirty patients with erosive-atrophic OLP were randomly allocated into two groups. The experimental group consisted of patients treated with the 630 nm laser. The control group consisted of patients who used dexamethasone mouth wash. The response rate was defined based on changes in the appearance score and pain score (VAS) of the lesions before and after each treatment. Appearance score, pain score, and lesion severity was reduced in both groups. No significant differences were found between the treatment groups regarding the response rate and relapse. The study demonstrated that LPT was as effective as topical corticosteroid therapy without any adverse effects and it may be considered as an alternative treatment for erosive-atrophic OLP in the future.

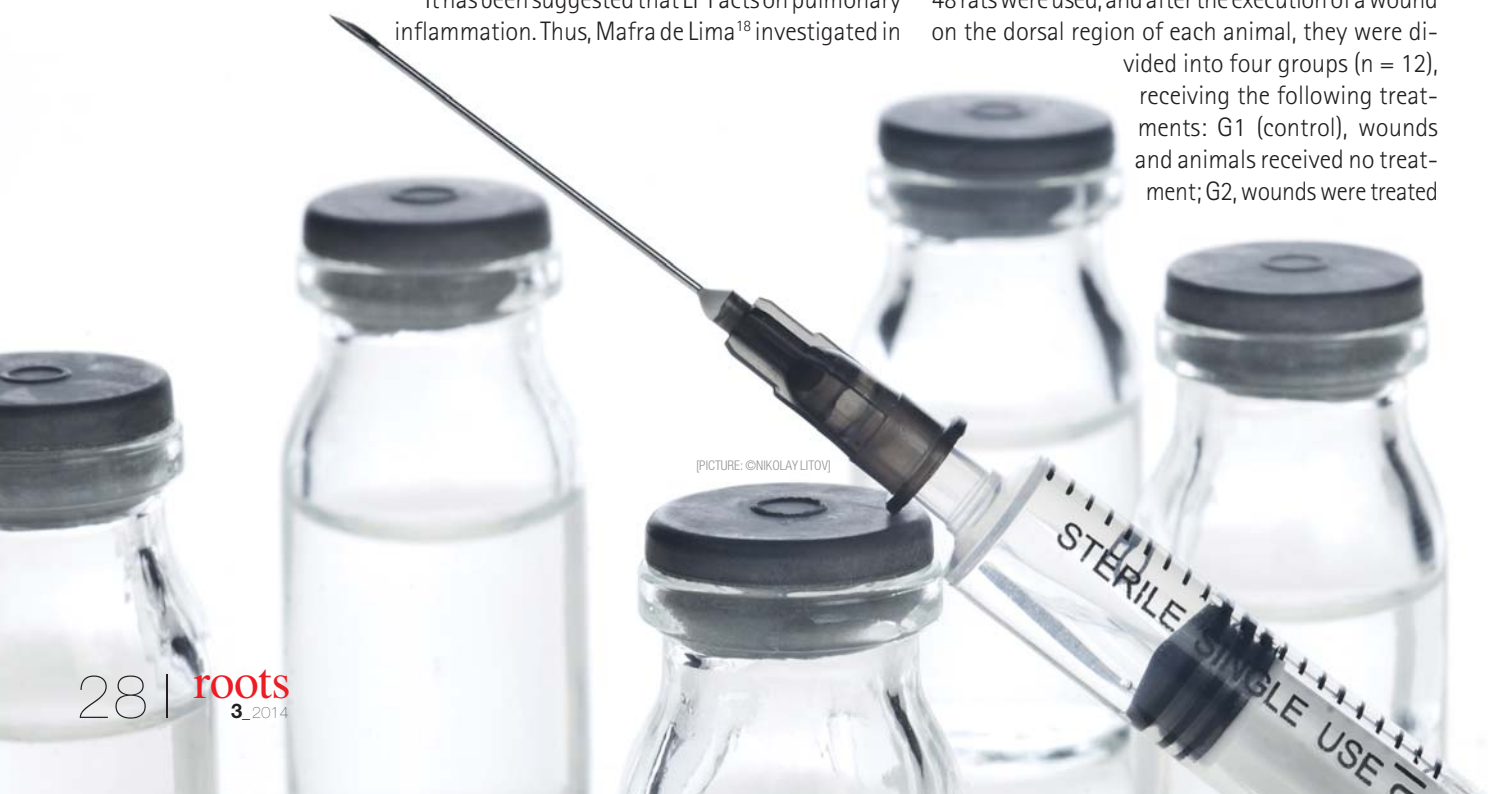The aim of a study by Aimbire¹⁶ was to investigate if LPT can modulate the formation of haemorrhagic lesions induced by immune complex, since there is a lack of information on LPT effects in haemorrhagic injuries of high perfusion organs, and the relative efficacy of LPT compared to anti-inflammatory drugs. A controlled animal study was undertaken with 49 rats, randomly divided into seven groups. Bovine serum albumin i.v. was injected through the trachea to induce an immune complex lung injury. The study compared the effect of irradiation by a 650 nm laser with doses of 2.6 J/cm² to celecoxib, dexamethasone, and control groups for haemorrhagic index (HI) and myeloperoxidase activity (MPO) at 24 h after injury. The HI for the control group was 4.0. Celecoxib, laser, and dexamethasone all induced significantly lower HI than in the control animals at 2.5, 1.8 and 1.5, respectively. Dexamethasone, but not celecoxib, induced a slightly, but significantly lower HI than laser. MPO activity was significantly decreased at 1.6 in groups receiving celecoxib at 0.87, dexamethasone at 0.50, and laser at 0.7 when compared to the control group, but there were no significant differences between any of the active treatments. In conclusion, LPT at a dose of 2.6 J/cm² induces a reduction of HI levels and MPO activity in haemorrhagic injury, which is not significantly different from that obtained by celecoxib. Dexamethasone is slightly more effective than LPT in reducing HI, but not MPO activity.

In an effort to clarify the molecular based mechanism of the anti-inflammatory effects of laser irradiation, Abiko¹⁷ used a rheumatoid arthritis (RA) rat model with human rheumatoid synoviocytes (MH-7) challenged with IL-1, treated with laser or dexamethasone (DEX), monitored by gene expressions and analysed by the signal pathway database. RA rats were generated by the immunisation of type-II collagen, after which foot paws and knee joints became significantly swollen. The animals were laser treated and the swelling rates measured. MH-7 was challenged with IL-1 β and gene expression levels monitored, using the Affymetrix Gene Chip system, and the signal pathway database analysed using the Ingenuity Pathway Analysis (IPA) tool. LPT significantly reduced swellings in the rats' foot paws and knee joints and made it possible for them to walk on their hind legs. LPT altered many gene expressions of cytokines, chemokines, growth factors and signal transduction factors in IL- β induced MH-7. IPA revealed that LPT as well as DEX kept the MH7A at a normal state to suppress mRNA levels of IL-8, IL-1 β , CXCL1, NF κ B1 and FGF13, which were enhanced by IL-1 β treatment. However, certain gene expression of inflammatory factors were reduced by LPT, but were enhanced by DEX. LPT reduced inflammatory factors through altering signal pathways by gene expression levels. Interestingly, LPT altered useful targeted gene expressions, whereas DEX randomly altered many gene expressions, including the unwanted genes for anti-inflammation. Dexamethasone is a steroid known for having a long range of serious side effects. Thus, genome-based gene expression monitored by the Gene Chip system together with a signal pathway based database provide unprecedented access to elucidate the mechanism of the biostimulatory effects of LPT.

It has been suggested that LPT acts on pulmonary inflammation. Thus, Mafrá de Lima¹⁸ investigated in

a work if LPT (650 nm, 2.5 mW, 31.2 mW/cm², 1.3 J/cm², spot size of 0.08 cm² and irradiation time of 42 s) can attenuate oedema, neutrophil recruitment and inflammatory mediators in acute lung inflammation. Thirty-five male Wistar rats (n = 7 per group) were distributed in the following experimental groups: control, laser, LPS, LPS+laser and dexamethasone+LPS. Airway inflammation was measured 4 h post-LPS challenge. Pulmonary microvascular leakage was used for measuring pulmonary oedema. Bronchoalveolar lavage fluid (BALF) cellularity and myeloperoxidase (MPO) were used for measuring neutrophil recruitment and activation. RT-PCR was performed in lung tissue to assess mRNA expression of tumour necrosis factor- α (TNF- α), interleukin-1 β (IL-1 β), interleukin (IL-10), cytokine-induced neutrophil chemoattractant-1 (CINC-1), macrophage inflammatory protein-2 (MIP-2) and intercellular adhesion molecule-1 (ICAM-1). Protein levels in both BALF and lung were determined by ELISA. LPT inhibited pulmonary oedema and endothelial cytoskeleton damage, as well as neutrophil influx and activation. Similarly, LPT reduced the TNF- α and IL-1 β , in lung and BALF. LPT prevented lung ICAM-1 up-regulation. The rise of CINC-1 and MIP-2 protein levels in both lung and BALF, and the lung mRNA expressions for IL-10, were unaffected. Data suggest that the LPT effect is due to the inhibition of ICAM-1 via the inhibition of TNF- α and IL-1 β .

Steroids are frequently used to treat inflammation. Some studies report a reduced effect of LPT in the presence of steroids, while others have found positive results of LPT even in the presence of steroids. However, steroids are known to delay wound healing through a reduction of leukocyte migration and a suppression of interleukins, while LPT is known to stimulate wound healing. In a study by Pessoa¹⁹, 48 rats were used, and after the execution of a wound on the dorsal region of each animal, they were divided into four groups (n = 12), receiving the following treatments: G1 (control), wounds and animals received no treatment; G2, wounds were treated



(PICTURE: ©NIKOLAY LITOV)

with laser; G3, animals received an intraperitoneal injection of sodium phosphate of dexamethasone, dosage 2 mg/kg of body weight; G4, animals received steroids and wounds were treated with laser. The laser emission device used was a 904 nm unit, in a contact mode, with 2.75 mW gated with 2,900 Hz during 120 sec. After a period of three, seven and 14 days, the animals were sacrificed. The results showed that the wounds treated with steroid had a delay in healing, while laser accelerated the wound healing process. Additionally, wounds treated with laser in the animals, also treated with steroids, presented a differentiated healing process with a larger collagen deposition as well as a decrease in both the inflammatory infiltrated and in the delay on the wound healing process. Laser accelerated healing, delayed by the steroids, acting as a biostimulative coadjuvant agent, balancing the undesirable effects of the steroids on the tissue's healing process. The effect of LPT is almost as potent as dexamethasone but, again, without side effects.

In a study by Lara²⁰, 44 rats were treated with fluorouracil and, in order to mimic the clinical effect of chronic irritation, the palatal mucosa was irritated by superficial scratching with an 18-gauge needle. When all of the rats presented oral ulcers of mucositis, they were randomly allocated to one of three groups: group I was treated with laser (GaAlAs), group II was treated with topical dexamethasone, and group III was not treated. Excisional biopsies of the palatal mucosa were then performed, and the rats were killed. Tissue sections were stained with haematoxylin and eosin for morphological analyses, and with toluidine blue for mast-cell counts. Group I specimens showed higher prevalence of ulcers, bacterial biofilm, necrosis and vascularisation, while group II specimens showed higher prevalence of granulation tissue formation. There were no significant statistical differences in the numbers of mast cells and epithelial thickness between groups. For the present model of mucositis, rats with palatal mucositis treated with laser showed characteristics compatible with the ulcerative phase of oral mucositis, and rats treated with topical dexamethasone showed characteristics compatible with the healing phase of mucositis. Topical dexamethasone was more efficient in the treatment of rats' oral mucositis than the laser.

It has been suggested that LPT and dexamethasone (DEX) in combination do not bring about any advantages. But the following study suggests that LPT works even in an environment with DEX.

The study by Marchionni²¹ aimed to assess the effect of LPT associated with and without dexamethasone on inflammation and wound healing in cutaneous surgical wounds. Limited studies are directed

at the possible interference of laser photobiomodulation on the formation of myofibroblasts, associated with an anti-inflammatory drug. Standard skin wounds were performed on 80 Wistar rats, distributed into four groups: no treatment (sham group), laser only (670 nm, 9 mW, 0.031 W/cm², 4 J/cm², single dose after surgery), dexamethasone only (2 mg/kg 1 h before surgery), and laser with dexamethasone. Tissue was examined histologically to evaluate oedema, presence of polymorphonuclear, mononuclear cells, and collagen. The analysis of myofibroblasts was assessed by immunohistochemistry and transmission electron microscopy. The intensity was rated semi-quantitatively. The results showed that laser and dexamethasone acted in a similar pattern to reduce acute inflammation. Collagen synthesis and myofibroblasts were more intense in the laser group, whereas animals treated with dexamethasone showed lower results for these variables. In a combination of therapies, the synthesis of collagen and actin as well as desmin-positive cells was less than laser group. Laser was effective in reducing swelling and polymorphonuclear cells and accelerated tissue repair, even in the presence of dexamethasone.

The aim of a study by Garcia²² was to compare LPT as adjuvant treatment for induced periodontitis with scaling and root planing (SRP) in dexamethasone-treated rats. One-hundred twenty rats were divided into groups: D group (n = 60), treated with dexamethasone; ND group (n = 60) treated with saline solution. In both groups, periodontal disease was induced by ligature at the left first mandibular molar. After seven days, the ligature was removed and all animals were subjected to SRP. They were divided according to the following treatments: SRP, irrigation with saline solution (SS); SRP + LPT, SS and laser irradiation (660 nm; 24 J; 0.428 W/cm²). Ten animals in each treatment were killed after seven days, 15 days and 30 days. The radiographic and histometric values were statistically analysed. In all groups, radiographic and histometric analysis showed less bone loss in animals treated with SRP + LPT in all experimental periods. SRP + LPT was an effective adjuvant conventional treatment for periodontitis in rats treated with dexamethasone.

Conclusion

From the above papers it is clear that LPT has an effect similar to that of dexamethasone. It is possibly not as strong as dexamethasone, but without the side effects. Thus, it is a promising alternative, especially for long term use. What still remains is a careful analysis about the optimal dosage windows for LPT.

Editorial note: A list of references is available from the publisher. Part I of this article has been published in roots 2/2014.

_contact	roots
<p>Jan Tunér Spjutvagen 11 772 32 Grängesberg Sweden</p> <p>jan.tuner@swipnet.se</p>	



Daktari for Maasai – Mobile Dental Care in the Serengeti

Author _ Prof. Martin Jörgens, Germany

Even as early as the 1950s, the Serengeti had already gained worldwide attention through the numerous documentary films produced by Professor Bernhard Grzimek. The images from *Serengeti darf nicht sterben* (*Don't let the Serengeti die*) were so powerful that he was awarded the Oscar for Best Documentary Film in 1960. Grzimek's film reporting and personal commitment eventually led to greater sensitivity in the handling of Tanzania's unique natural resources as well as the expansion and protection of Tanzania's most important national park: the Serengeti.

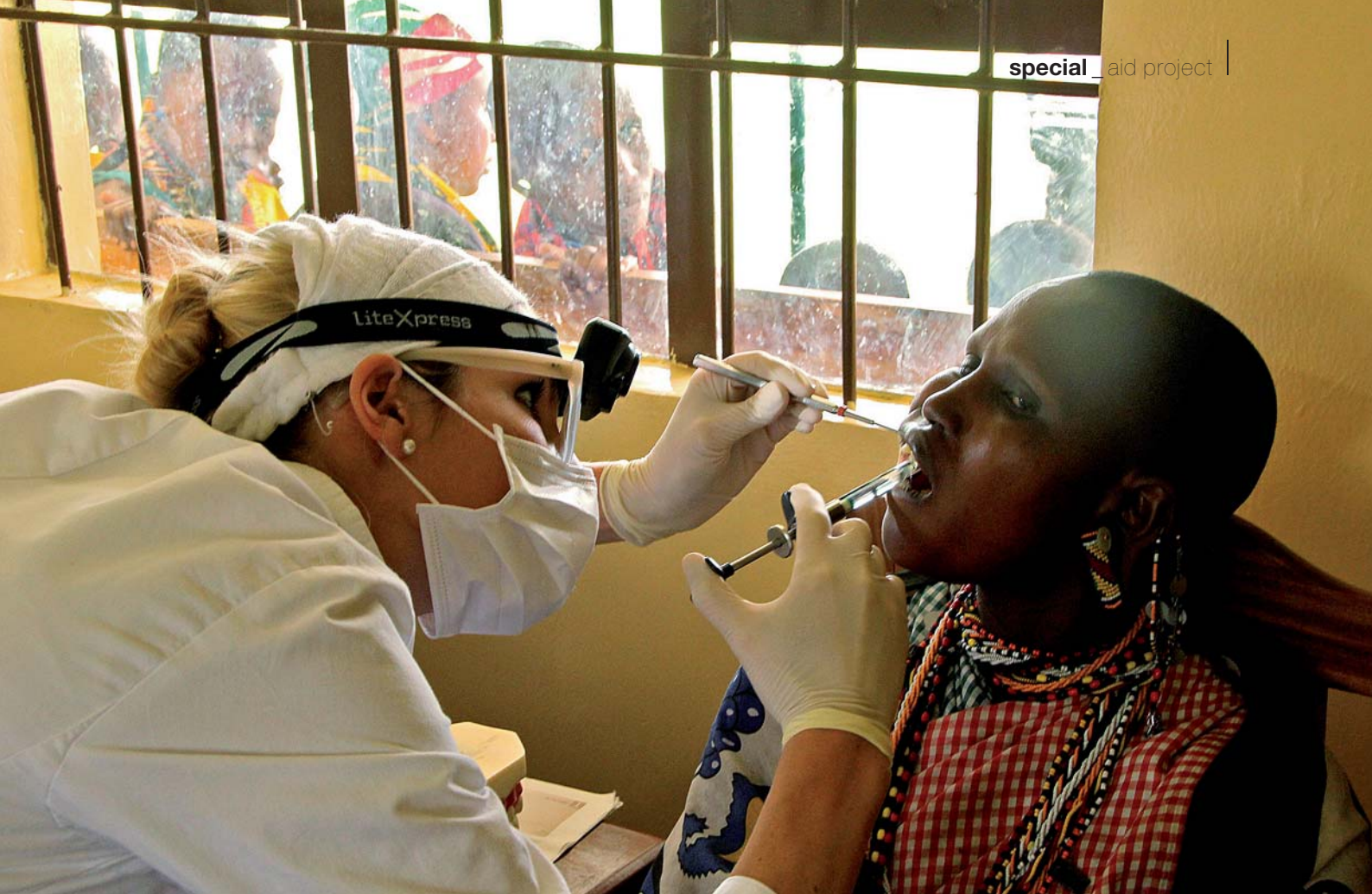Many naturalists consider it the most important national park in the world, given how the migration of wildlife depends on it to ensure their survival. It is the largest active mammalian eco-system, providing

living space for a total of up to six million animals. During their long migration, millions of animals continuously traverse the full breadth of the Serengeti in search of food, and in the process cross the Mara River in order to reach the Maasai Mara in neighbouring Kenya.

_Genesis of the project

A safari I took in connection with an expedition to Kilimanjaro in 2010 brought me to the heart of the Serengeti and from there northward to a small Maasai village named Ololosokwan on the border with Kenya. The very proud yet quite welcoming Maasai received me warmly. My guide, Seleu Kedoki, a local ranger with andBeyond who was well acquainted with the region, took me to the typical gath-






ering places for elephants, lions and leopards and also brought me to his village, where he proudly showed off a school and a small clinic. The clinic was a donation from andBeyond and Africafoundation and consisted of a well-built concrete building with seven rooms, two of which were furnished with equipment. A sign reading 'Daktari' that hung on the door to treatment room 4 had such a profound effect on me that right then and there I promised the resident physician, Dr Obed, to set up a dental care station there.

Conditions were perfect and I knew right from that first moment that we had found the location we'd been looking for so long, where we could establish a dental care project in Africa. After spending years working for Land Rover as a mobile dentist at off-road events like Camel Trophy, the Land Rover G4 Challenge and Land Rover Experience, I had long been interested in establishing a permanent site where we could reach out to provide medical services using off-road vehicles. Everywhere I went during my safari I was struck by the great lack of any kind of dental care.

Tanzania has a population of 52 million residents...but only 250 dentists. As a result, there are vast regions that must get by without any kind of dental care services. In general, patients have to walk great distances and undertake arduous journeys in order to get to a city for dental treatment. Moreover, the standards at most dental practices are still very underde-

veloped so that in general many people are afraid of being treated. And often other needs in many areas are so great that dental care has to be put aside simply for economic reasons.



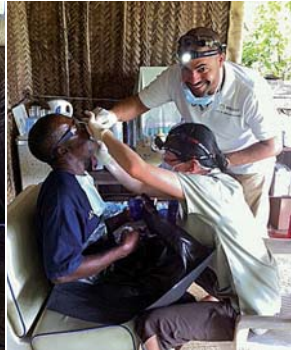_info

roots



&BEYOND

&BEYOND is the world's leading provider of adventure travel and safaris. The company has its roots in South Africa. The 2000 employees of &Beyond currently operate 33 lodges, mainly in premier national parks in both southern and eastern Africa as well as in Asia. In doing so, the company contributes to the preservation of hundreds of rural communities and millions of acres of valuable and sometimes endangered wilderness while also serving as number 1 partner to the Daktari Project for the Maasai.

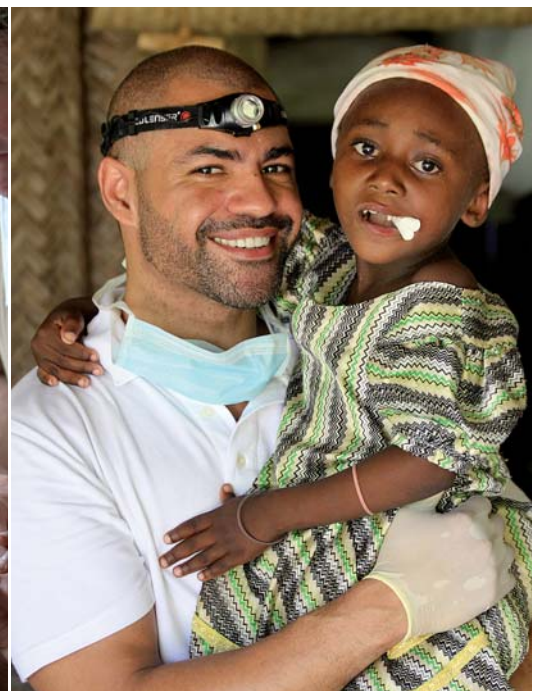
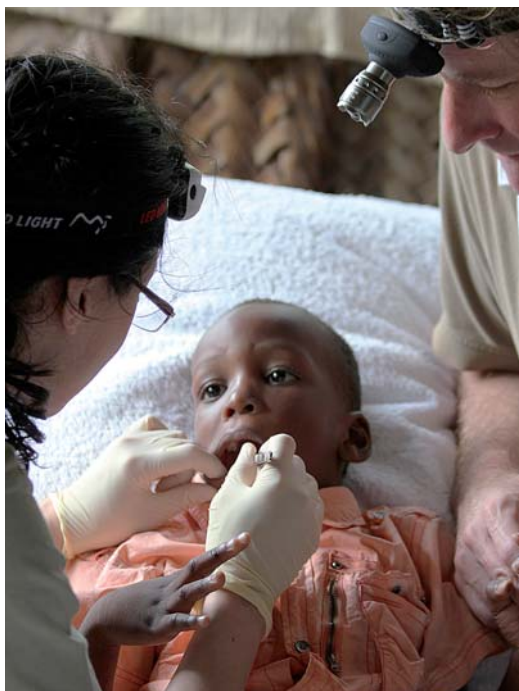
__The project gets under way

It took nearly a year before our practice, DentalSpecialists, was able to launch the 'Daktari for Maasai' project. 'Daktari for Maasai' is Swahili and means 'doctors for Maasai'. Furnished with the best in mobile equipment and full of enthusiasm and a spirit of adventure, we travelled to our objectives at Lake Manyara, the Ngorongoro Conservation Area and the Serengeti. We were able to win over &BEYOND as our primary sponsor. This South African group operates lodges in the regions where Daktari works on behalf of the Maasai and provides assistance to the project on a daily basis. On the one hand, this affords dental and medical aid to even the most remote parts of Tanzania. Depending on the region, up to 90% of lodge staff are themselves Maasai in origin. Their families and other residents from surrounding villages gratefully draw on the dental and medical aid we offer. To do so, they will often walk 200 kilometres—while Maasai from the neighbouring Masai Mara will cross the border with Kenya in order to receive dental treatment from us. At the same time, for a project like

'Daktari for Maasai' to function, it is vital that it has reliable local partners like andBeyond to draw on. Through this collaborative effort, the project receives logistical and communications support at every level, affording it the consistency, security and predictability that the local &Beyond staff provide on the ground. This also results in a high degree of confidence among all those involved. The philosophy at &BEYOND always places the preservation and development of nature and wildlife in the centre—along with providing practical support and development for the people in the regions where &BEYOND operates. This can come about by building schools and clinics, or it may well take the form of appointing doctors to the clinics in order to ensure primary health care services. This is also what we provide through our collaboration with 'Daktari for Maasai', as we are in a position to offer highly specialised treatments that normally would be unavailable.

At the time I headed out with my colleague at DentalSpecialists, Dr Caroline Kentsch, on our first pre-scouting trip to Tanzania, flying with CONDOR



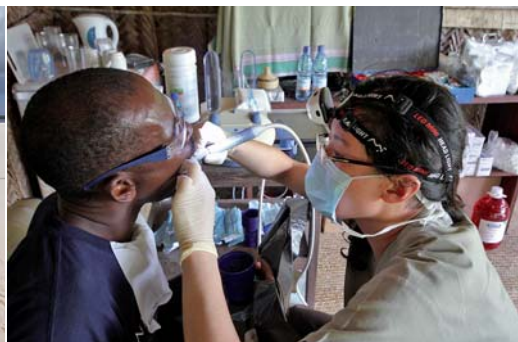

from Frankfurt/Main. On arrival at Kilimanjaro Airport, we acquired a long-chassis Toyota Land Cruiser 4X4 equipped for safari. It was the perfect vehicle, with excellent off-road capabilities and great load-hauling capacity. We first drove to Arusha to get additional medicines and instruments, since fifteen transport crates from Germany weren't enough for it all. In Arusha we obtained a great many medicines and other instruments from medeor that medeor Tanzania had ordered for us. We then continued on to Lake Manyara, where we worked for the next two days, first treating the lodge staff and their families. After that, curiosity drew in a large number of other villagers. Following an arduous Serengeti crossing, we arrived at Ololosokwan, where we worked every day at both the Kleins Camp Lodge and at the Ololosokwan clinic. We initially needed help at the clinic, which still lacks both electricity and running water. A more or less functioning generator was provided and we adjusted our operations to fit our new surroundings among the Maasai. We quickly learned to deal with the heat, tsetse flies, mosquitoes, flies and numerous other insects. A smut candle specially designed to repel insects performed well, but caused masks and clothing to turn black. At the time there were still no dental chairs, so we had to treat patients while standing up all day. The patients themselves were treated either

seated on an office chair or lying on a doctor's couch. We gained valuable experience during this pre-scouting trip in the Serengeti that helped us prepare for our next visit.

Since we did not take any support staff with us the first time, we planned differently for our second trip. My close friend Dr Axel Roschker from Cologne, who specialises in implantology and oral surgery, went along to provide active support, as did two members of the staff at our clinic, DentalSpecialists. Sandra Ahsan worked independently with us as a dental hygienist and Miriam Schorn transformed herself into a veritable tooth fairy in the jungle environment at Lake Manyara, assisting Dr Roschker with his work.

Using additional materials obtained from medeor, we were able to equip additional sites. Now there are surgical suction pumps and instruments in Lake Manyara and in Ololosokwan. With a team consisting of in effect three persons providing treatment, we were able to handle over 650 Maasai in 14 days. Bit by bit, the project gained acceptance among the local population. Classes from the primary and secondary schools in Ololosokwan now regularly visit our highly specialised clinic. For the most part, these children arrive together as a class to receive treatment at the clinic.

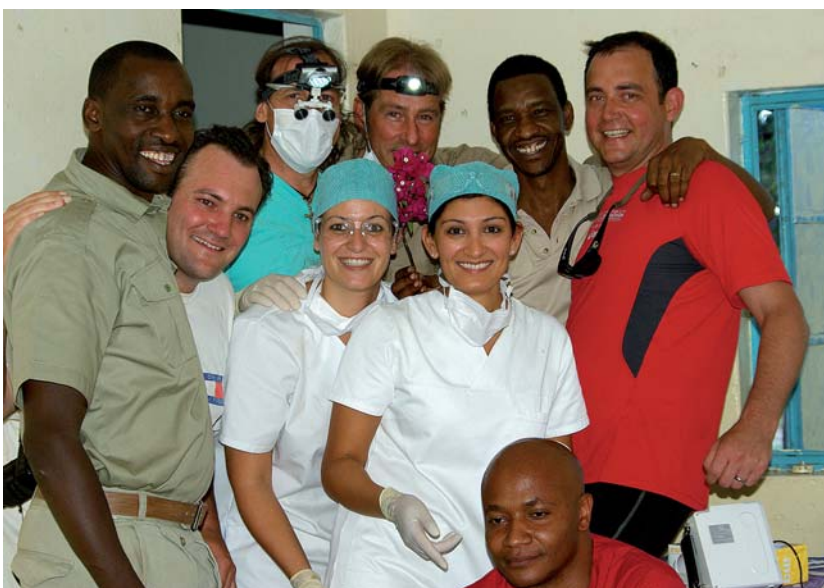



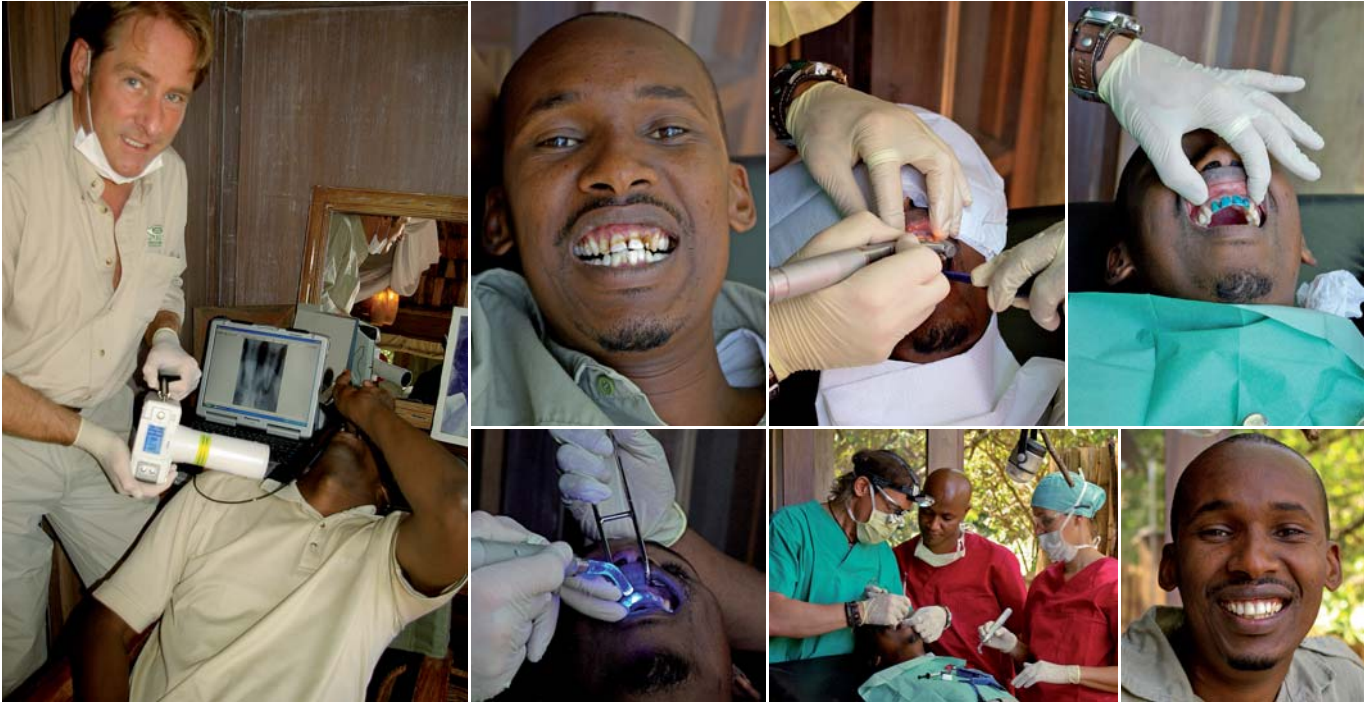Keeping the project going

During another project-related trip in January 2013, led by Dr Caroline Kentsch and Dr Axel Roschker, about 650 patients received treatment. Once again, two assistants accompanied three doctors on the trip. It is a welcome development that, owing to the technically advanced equipment available, we were able to provide treatments for pain that did not necessarily involve tooth extraction. Numerous glued synthetic bridges were produced to close gaps between front teeth. A great many cavities were filled in front teeth as part of treatment for tooth decay. And serious cases of fluorosis were treated in order to provide for a more aesthetically pleasing appearance.

Fluorosis is a wide-spread problem among the Tanzanian population. In the north, in the greater Arusha metropolitan area, up to 90 per cent of inhabitants suffer from serious cases of fluorosis. We also have been able to prevent tooth loss through root canal treatments. And we are able to preserve posterior teeth by putting in fillings. Using ultrasound equipment and mobile lasers, we are able to carry out comprehensive periodontal treatments. Korean-made digital X-ray machines by Dexcwin allow us to produce razor-sharp images in just seconds on a laptop in any kind of situation. These devices are absolutely vital in performing surgical procedures and root canal filling therapies.



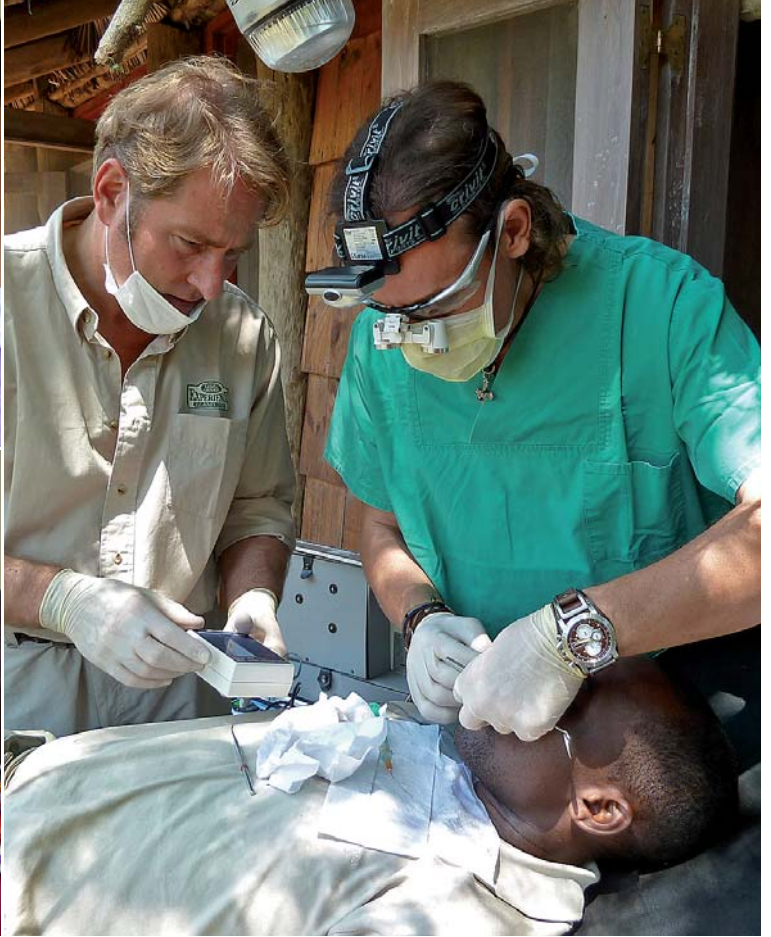In September 2013 the project achieved another milestone in its development when the University of Sevilla asked us to use the project as part of its training programme for oral surgeons. In September we travelled together with Dr Axel Roschker and two Spanish oral surgeons, Dr Roberto Garrido and Dr Francisco Azcarate, to Lake Manyara, Ngorongoro and Serengeti/Ololosokwan. Joining us from England was Dr Andrea Chan, who previously served for six years as a dentist with the British Navy. Though she was only able to be with us for just one week, her visit came off smoothly owing to the availability of daily flights between Arusha and Ololosokwan by small plane. Our multi-national team operated non-stop in every part of the Tanzanian mainland previously served. The international nature of the group spurred the project on immensely. The interactions of the individual specialists, despite never having worked together before, came off like a charm. This accomplished team of oral surgeons was even able to han-



de more involved surgical procedures. And one thing quickly became clear: it was substantially more efficient to offer treatment as part of a larger team, since it meant that many activities could be shifted around so that highly specialised professionals were also available to serve as assistants. In February 2014 our path once again took us back to Zanzibar, where we had initiated a pilot project in February of the previous year. This time my other colleague at DentalSpecialists, Professor Michael Wainwright, went with us as well. Local conditions and climate on Zanzibar, however, pose greater difficulties in providing dental care than on the mainland. Daytime temperatures can easily climb above 33°C and the high humidity does its part to make any kind of physical activity

difficult. We adjusted our treatment times and work habits to better suit this new environment. Because our facilities and equipment were located on a small offshore island, our patients reached us by boat. Life on the island made us feel a little like Robinson Crusoe. But the treatment we provided was affected by our underlying circumstances in other ways as well. While surgical procedures predominated on the Tanzanian mainland, on Zanzibar we treated a disproportionate number of serious cases of periodontitis. This is due, on the one hand, to a genetic predisposition to these types of diseases, but also to differences in diet. People on Zanzibar consume more fish and vegetables and sweets are harder to come by than on the mainland. Fluorosis is practically unheard of here





too. After extensive preparations while still in Germany, we had significantly expanded the equipment available to us. Along with our tried-and-tested surgical suction pump, medeor Tanzania made available to us a new Chinese treatment unit. It turned out to be a real adventure getting this equipment, however, given the great number of administrative hurdles and impediments we had to overcome before the unit was finally delivered.

DHL sent us daily assurances that the units would be arriving on schedule. But each and every time the African authorities put up another unexpected hurdle.

One time the shipping documents were arbitrarily altered by a customs official; another time the equipment was removed from the flight, ostensibly because the plane was too heavy for the flight from Dar-es-Salaam to Zanzibar. Thank God we had another treatment unit to use in handling our daily flow of patients. It was only with help from the folks at medeor Tanzania and &BEYOND that we were able to find a solution to our administrative nightmare.

When the Chinese unit finally reached us, we were surprised at how compact and efficient it was. A highly efficient, integrated compressor makes the unit ready to use in just five seconds and it can be used for every kind of procedure, from putting in synthetic fillings to performing complex surgical operations. It makes for a very practical treatment tool that can even be checked in at the airport along with standard 23 kg luggage.

The unit constitutes the basis for all future mobile treatments undertaken by Daktaris for Maasai. And we would like to take a moment here to extend thanks to our third primary partner, Condor Contribute, for their help in transporting medical and dental aid supplies. Without their support a dental project as adventurous as this would scarcely have been possible. The thanks we got from the people of Tanzania receiving free treatment was indescribable and cannot be compared with any other experience in medicine. Sincerest thanks from the Daktaris for Maasai... Bon Voyage! – Na safari nzuri!_

_contact

roots



Prof. Martin Jörgens

DentalSpecialist
Kaiserwerther Markt 25
40489 Düsseldorf-
Kaiserwerth
Germany
Tel.: +49 211 4790079

info@dental specialists.de

_info

roots



medeor has produced medications on a non-profit basis for the past 50 years and provides crisis regions with medical supplies

of all types. Europe's largest medical aid organisation is our second primary sponsor and maintains a donations account of its own:

2-46-0170 Daktari for Maasai
Account no.: 100 596 2285
Sort code: 300 501 10
(Stadtsparkasse Düsseldorf)

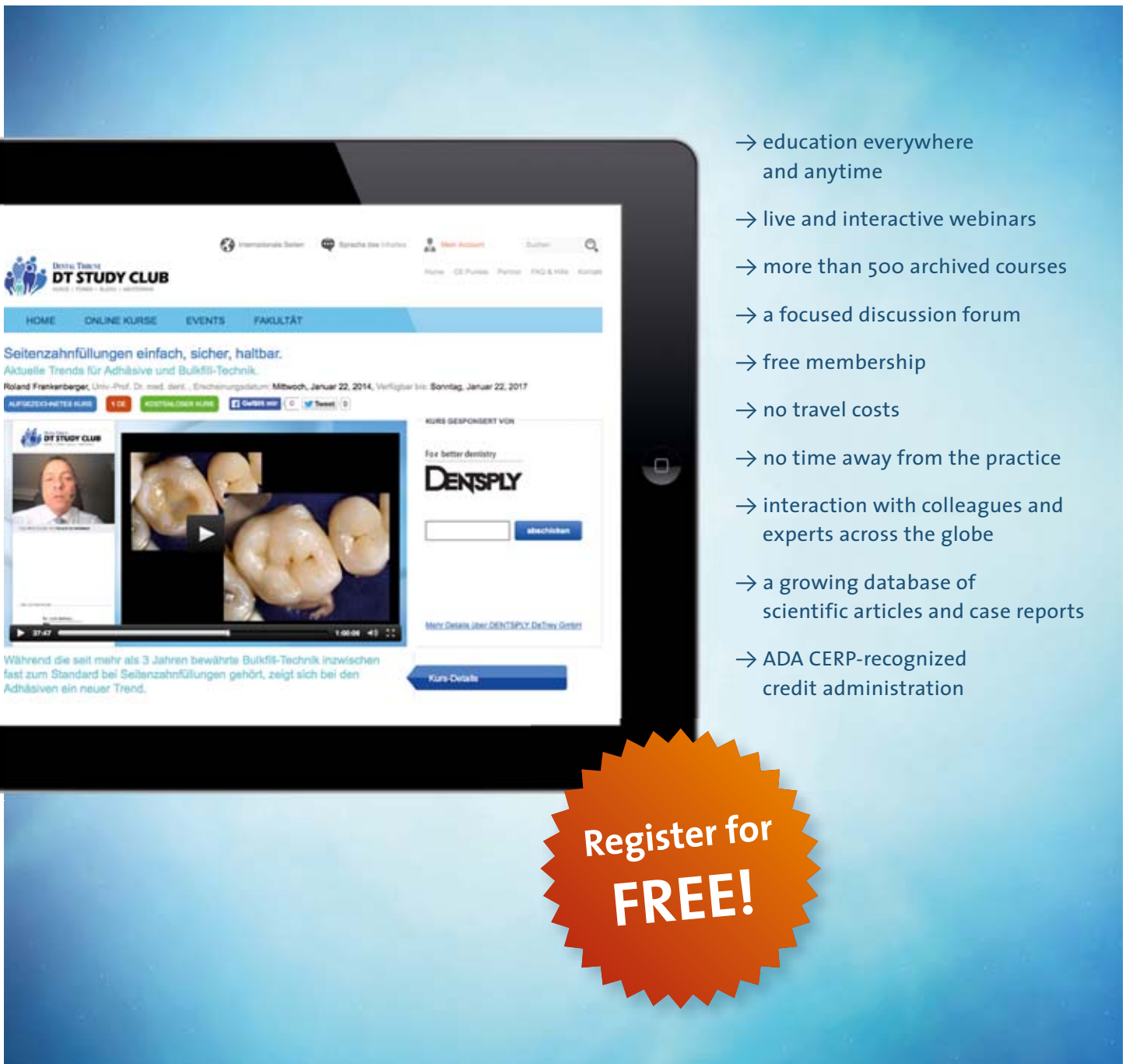
IBAN: DE97 3005 0110 1005 9622 85
BIC: DUSSEDDXXX

Join the largest educational network in dentistry!



DT STUDY CLUB
COURSES | DISCUSSIONS | BLOGS | MENTORING

www.DTStudyClub.com

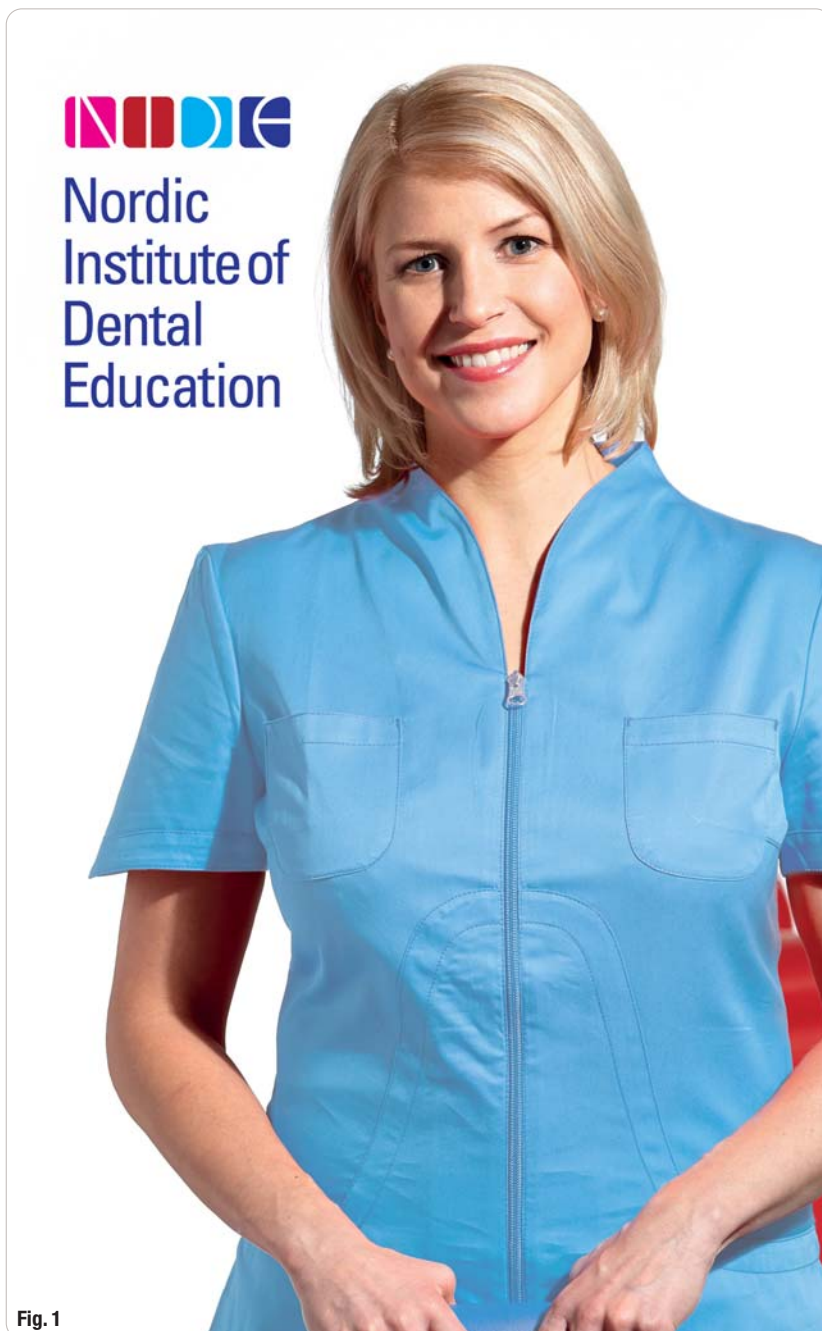


- education everywhere and anytime
- live and interactive webinars
- more than 500 archived courses
- a focused discussion forum
- free membership
- no travel costs
- no time away from the practice
- interaction with colleagues and experts across the globe
- a growing database of scientific articles and case reports
- ADA CERP-recognized credit administration

Register for
FREE!

Planmeca and the University of Turku found Nordic Institute of Dental Education

Fig. 1 _The objective of the new institute is to export and share Nordic expertise in digital dentistry on the basis of academic knowledge and technologies. (Photo: Planmeca)



_Dental technology company Planmeca and the University of Turku have founded a joint venture company, the Nordic Institute of Dental Education. The institute will offer high-quality continuing education courses to dental professionals.

The objective is to export and share Nordic expertise in digital dentistry on the basis of the academic knowledge of the University of Turku and the technologies developed by Planmeca, as well as their global dental networks.

The courses will be held at the University of Turku and at Planmeca's headquarters in Helsinki from autumn 2014. The course topics cover rapidly evolving dental technologies and their application in modern dentistry, including 3-D imaging, prosthodontics, endodontics, biomaterials science, orthodontics and CAD/CAM technologies.

The University of Turku awards ECTS credits (a standard for higher education in Europe) and course certificates to the students. The joint venture company complements Planmeca's broad range of training activities and collaboration with universities around the world.

The University of Turku is an active participant in the export of education. "We have now established a partnership with one of the world's leading companies in dental technology. Together with Planmeca we are a strong education provider globally," stated Prof. Kalervo Väänänen, Rector of the University of Turku.

_contact	roots
Course registrations: www.nordicdented.com	
More information: Jenni Pajunen, Chief Executive Officer (CEO) Nordic Institute of Dental Education Tel. +358 20 779 5348 jenni.pajunen@nordicdented.com	

Fig. 1



Tribune CME



1 Year Clinical Masters™ Program in Endodontics

November 19-22, 2014, a total of 4 days in Rome (IT)

Participants will master techniques that are repeatable, predictable and have the ability to create different but always excellent results!

Learn from the Masters of Endodontics:



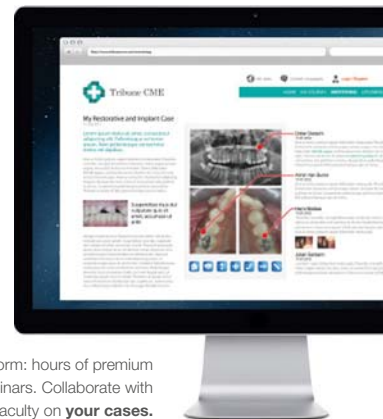
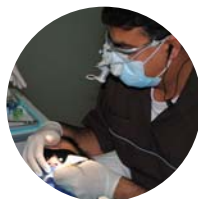Dr. Gianluca Gambarini



Dr. Nicola M. Grande



Dr. Gianluca Plotino



Access our online learning platform: hours of premium video training and live webinars. Collaborate with peers and faculty on **your cases**.

Registration information:

November 19-22, 2014

a total of 4 days in Rome (IT)

Session fee: € 3,300

(you can decide at any time to complete the entire Clinical Masters Program and take the remaining sessions)

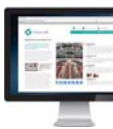Details on www.TribuneCME.com

contact us at tel.: +49-341-484-74134

email: request@tribunecme.com

Collaborate on your cases

and access hours of premium video training and live webinars



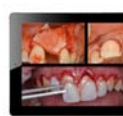Sapienza University of Rome

you will receive a certificate from the University of the Pacific



Latest iPad with courses

all registrants receive an iPad preloaded with premium dental courses



33 C.E. CREDITS



ADA CERP®
Continuing Education Recognition Program

Tribune Group GmbH is the ADA CERP provider. ADA CERP is a service of the American Dental Association to assist dental professionals in identifying quality providers of continuing dental education. ADA CERP does not approve or endorse individual courses or instructors, nor does it imply acceptance of credit hours by boards of dentistry.



Tribune Group GmbH is designated as an Approved PACE Program Provider by the Academy of General Dentistry. The formal continuing dental education programs of this program provider are accepted by AGD for Fellowship, Mastership, and membership maintenance credit. Approval does not imply acceptance by a state or provincial board of dentistry or AGD endorsement.

International Events

2014

ROOTS Summit

7–9 November 2014
Chennai, India
www.rootssummit2014.com

BES: 2014 Regional Meeting

14–15 November 2014
Manchester, UK
www.britishendodonticsociety.org.uk

ADF Meeting

25–29 November 2014
Paris, France
www.adf.asso.fr

ENDO BALTIC 2014 – Lithuanian Society of Endodontology Meeting

28–29 November 2014
Vilnius, Lithuania
www.endodontologija.lt

Greater New York Dental Meeting

28 November–3 December 2014
New York, USA
www.gnydm.com

Austrian Society of Endodontology Annual Meeting & PENN ENDO Global Symposium

4–6 December 2014
Vienna, Austria
www.pennglobalvienna2014.at/

2015

AEEDC – UAE International Dental Conference & Arab Dental Exhibition

17–19 February
Dubai, UAE
www.aeedc.com

36th International Dental Show

10–14 March 2015
Cologne, Germany
www.ids-cologne.de

18th APEC Congress & 4th Jordanian Endodontic Conference

9–10 April 2015
Amman, Jordan
www.apec2015.jo

AAE15 – American Association of Endodontists Annual Meeting


6–9 May 2015
Seattle, USA
www.aae.org

CAE 51st – Canadian Academy of Endodontics Annual General Meeting

26–29 August 2015
Banff, Alberta, Canada
www.caendo.ca

ESE 17th Biennial Congress

16–19 September 2015
Barcelona, Spain
www.e-s-e.eu



© S.Borisov/Shutterstock.com

submission guidelines:

Please note that all the textual components of your submission must be combined into one MS Word document. Please do not submit multiple files for each of these items:

- _ the complete article;
- _ all the image (tables, charts, photographs, etc.) captions;
- _ the complete list of sources consulted; and
- _ the author or contact information (biographical sketch, mailing address, e-mail address, etc.).

In addition, images must not be embedded into the MS Word document. All images must be submitted separately, and details about such submission follow below under image requirements.

Text length

Article lengths can vary greatly—from 1,500 to 5,500 words—depending on the subject matter. Our approach is that if you need more or less words to do the topic justice, then please make the article as long or as short as necessary.

We can run an unusually long article in multiple parts, but this usually entails a topic for which each part can stand alone because it contains so much information.

In short, we do not want to limit you in terms of article length, so please use the word count above as a general guideline and if you have specific questions, please do not hesitate to contact us.

Text formatting

We also ask that you forego any special formatting beyond the use of italics and boldface. If you would like to emphasise certain words within the text, please only use italics (do not use underlining or a larger font size). Boldface is reserved for article headers. Please do not use underlining.

Please use single spacing and make sure that the text is left justified. Please do not centre text on the page. Do not indent paragraphs, rather place a blank line between paragraphs. Please do not add tab stops.

Should you require a special layout, please let the word processing programme you are using help you do this formatting automatically. Similarly, should you need to make a list, or add footnotes or endnotes, please let the word processing programme do it for you automatically. There are menus in every programme that will enable you to do so. The fact is that no matter how carefully done, errors can creep in when you try to number footnotes yourself.

Any formatting contrary to stated above will require us to remove such formatting before layout, which is very time-consuming. Please consider this when formatting your document.

Image requirements

Please number images consecutively throughout the article by using a new number for each image. If it is imperative that certain images are grouped together, then use lowercase letters to designate these in a group (for example, 2a, 2b, 2c).

Please place image references in your article wherever they are appropriate, whether in the middle or at the end of a sentence. If you do not directly refer to the image, place the reference at the end of the sentence to which it relates enclosed within brackets and before the period.

In addition, please note:

- _ We require images in TIF or JPEG format.
- _ These images must be no smaller than 6x6 cm in size at 300 DPI.
- _ These image files must be no smaller than 80 KB in size (or they will print the size of a postage stamp!).

Larger image files are always better, and those approximately the size of 1 MB are best. Thus, do not size large image files down to meet our requirements but send us the largest files available. (The larger the starting image is in terms of bytes, the more leeway the designer has for resizing the image in order to fill up more space should there be room available.)

Also, please remember that images must not be embedded into the body of the article submitted. Images must be submitted separately to the textual submission.

You may submit images via e-mail, via our FTP server or post a CD containing your images directly to us (please contact us for the mailing address, as this will depend upon the country from which you will be mailing).

Please also send us a head shot of yourself that is in accordance with the requirements stated above so that it can be printed with your article.

Abstracts

An abstract of your article is not required.

Author or contact information

The author's contact information and a head shot of the author are included at the end of every article. Please note the exact information you would like to appear in this section and format it according to the requirements stated above. A short biographical sketch may precede the contact information if you provide us with the necessary information (60 words or less).

Questions?

Magda Wojtkiewicz (Managing Editor)
m.wojtkiewicz@oemus-media.de

roots

international magazine of endodontology

Publisher

Torsten R. Oemus
oemus@oemus-media.de

CEO

Ingolf Döbbecke
doebbecke@oemus-media.de

Members of the Board

Jürgen Isbaner
isbaner@oemus-media.de

Lutz V. Hiller

hiller@oemus-media.de

Managing Editor

Magda Wojtkiewicz
m.wojtkiewicz@oemus-media.de

Executive Producer

Gernot Meyer
meyer@oemus-media.de

Designer

Josephine Ritter
j.ritter@oemus-media.de

Copy Editors

Sabrina Raaff
Hans Motschmann

Published by

Oemus Media AG
Holbeinstraße 29
04229 Leipzig, Germany
Tel.: +49 341 48474-0
Fax: +49 341 48474-290
kontakt@oemus-media.de
www.oemus.com

Printed by

Silber Druck oHG
Am Waldstrauch 1
34266 Niestetal, Germany

Editorial Board

Fernando Goldberg, Argentina
Markus Haapasalo, Canada
Ken Serota, Canada
Clemens Bargholz, Germany
Michael Baumann, Germany
Benjamin Briseno, Germany
Asgeir Sigurdsson, Iceland
Adam Stabholz, Israel
Heike Steffen, Germany
Gary Cheung, Hong Kong
Unni Endal, Norway
Roman Borczyk, Poland
Bartosz Cerkaski, Poland
Esteban Brau, Spain
José Pumarola, Spain
Kishor Gulabivala, United Kingdom
William P. Saunders, United Kingdom
Fred Barnett, USA
L. Stephan Buchanan, USA
Jo Dovgan, USA
Vladimir Gorokhovskiy, USA
James Gutmann, USA
Ben Johnson, USA
Kenneth Koch, USA
Sergio Kuttler, USA
John Nusstein, USA
Ove Peters, USA
Jorge Vera, Mexico



Magda Wojtkiewicz, Managing Editor

roots

Copyright Regulations

_roots international magazine of endodontology is published by Oemus Media AG and will appear in 2014 with one issue every quarter. The magazine and all articles and illustrations therein are protected by copyright. Any utilisation without the prior consent of editor and publisher is inadmissible and liable to prosecution. This applies in particular to duplicate copies, translations, microfilms, and storage and processing in electronic systems.

Reproductions, including extracts, may only be made with the permission of the publisher. Given no statement to the contrary, any submissions to the editorial department are understood to be in agreement with a full or partial publishing of said submission. The editorial department reserves the right to check all submitted articles for formal errors and factual authority, and to make amendments if necessary. No responsibility shall be taken for unsolicited books and manuscripts. Articles bearing symbols other than that of the editorial department, or which are distinguished by the name of the author, represent the opinion of the afore-mentioned, and do not have to comply with the views of Oemus Media AG. Responsibility for such articles shall be borne by the author. Responsibility for advertisements and other specially labeled items shall not be borne by the editorial department. Likewise, no responsibility shall be assumed for information published about associations, companies and commercial markets. All cases of consequential liability arising from inaccurate or faulty representation are excluded. General terms and conditions apply, legal venue is Leipzig, Germany.

roots

international magazine of endodontology



You can also subscribe via www.oemus.com/abo

 **Subscribe now!**

I would like to subscribe to **roots** for € 44 including shipping and VAT for German customers, € 46 including shipping and VAT for customers outside Germany, unless a written cancellation is sent within 14 days of the receipt of the trial subscription. The subscription will be renewed automatically every year until a written cancellation is sent to OEMUS MEDIA AG, Holbeinstr. 29, 04229 Leipzig, Germany, six weeks prior to the renewal date.

▶ **Reply** via Fax to +49 341 48474-290 to OEMUS MEDIA AG or via E-mail to grasse@oemus-media.de

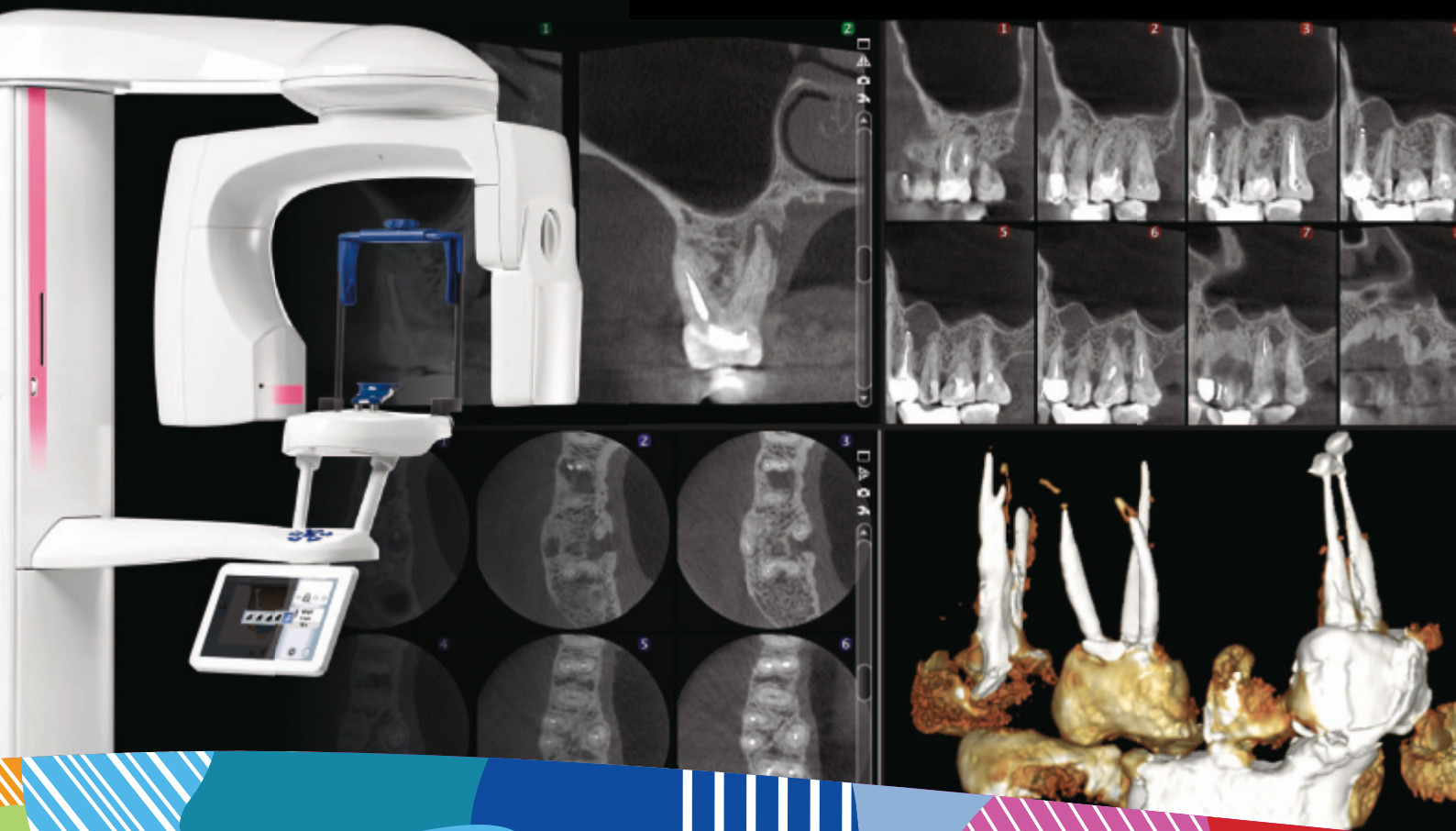
Last Name, First Name	
Company	
Street	
ZIP/City/Country	
E-mail	Signature

Notice of revocation: I am able to revoke the subscription within 14 days after my order by sending a written cancellation to OEMUS MEDIA AG, Holbeinstr. 29, 04229 Leipzig, Germany.

Signature

Planmeca ProMax[®] 3D

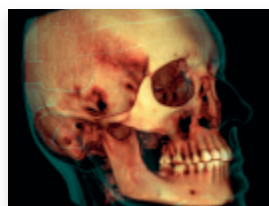Endodontic imaging mode – a new era in precision



Perfect visualisation of the finest details

- Extremely high resolution with 75 μm voxel size
- Noise-free images with intelligent **Planmeca AINO[™]** filter
- Artefact-free images with efficient **Planmeca ARA[™]** algorithm

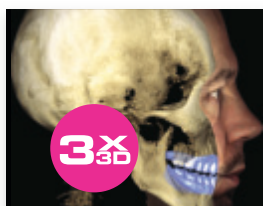Other unique features in Planmeca ProMax[®] 3D family units:



Ultra low dose imaging

CBCT imaging with an even lower patient dose than panoramic imaging.

Adult female, FOV $\varnothing 200 \times 170$ mm
Effective dose **14.7 μSv**
Planmeca ProMax[®] 3D Mid



Create your virtual patient

A world first:
One imaging unit,
three types of 3D data.
All in one software.

CBCT + 3D model scan + 3D face photo

Find more info and your local dealer

www.planmeca.com

PLANMECA



Planmeca Oy Asentajankatu 6, 00880 Helsinki, Finland. Tel. +358 20 7795 500, fax +358 20 7795 555, sales@planmeca.com