

# The Use of an Er:YAG Laser in Periodontal Surgery: Clinical Cases with Long-Term Follow-Up

author\_Frank Y.W. Yung, DDS, Canada

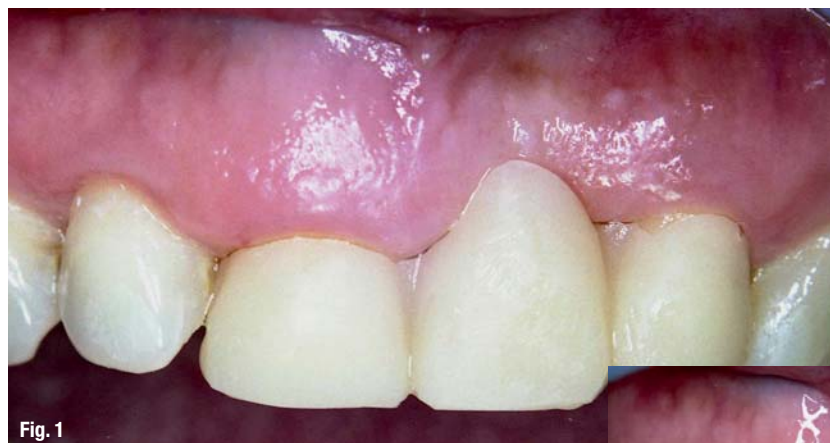

Fig. 1

**Fig. 1** An intraoral view of patient #1 with a transitional acrylic bridge (teeth #8 to 10) before laser crown lengthening.

**Fig. 2** The initial outline of the new gingival level for tooth #8 was prepared with the Er:YAG laser.

**Fig. 3** The attached gingiva was excised and the underlying alveolar crest modified.

## Introduction

While the regimen of scaling and root planing (SRP) remains an essential part of any management of periodontal diseases, there are clinical situations in which the surgical excision of infected tissues or modifications of healthy structures is required after the initial mechanical debridement.

Conventional surgical techniques, such as curettage, gingivectomy, full- or split-thickness flap, and other procedures, have been proven to be effective in treating moderate-to-advanced periodontitis,<sup>1,2</sup> but the need to improve postoperative morbidity and control over-treatment outcome have provided the impetus to explore further for better surgical techniques and treatment alternatives. The principle behind laser surgery is the selective absorption of optical energy delivered by a specific laser wavelength to produce thermal effects on the target tissues to be excised or modified. The advantages of utilizing a laser for surgery over "cold steel" or electrosurgery are well documented in the literature, with some specific benefit differences among wavelengths.<sup>3-5</sup> The overall recovery experiences and surgical results are so much more

pleasant and predictable than those of conventional surgery so that for some surgical procedures, such as in the fields of ophthalmology<sup>6</sup>, otolaryngology<sup>7</sup>, and dermatology<sup>8</sup>, the use of lasers have replaced other modalities in many instances. During the 1960s and 1970s, different kinds of lasers with different wavelengths were invented, and they were studied subsequently for possible dental applications. Laser instruments, including carbon dioxide (CO<sub>2</sub>), neodymium:yttrium, aluminum, garnet (Nd:YAG),

argon, gallium arsenide (diode), and erbium:yttrium, aluminum, garnet (Er:YAG) were found to be effective for soft tissue surgery, including periodontics.<sup>9, 10</sup> The Er:YAG laser, which was developed in the early 1970s,<sup>11</sup> also offered hard tissue applications. The 2,940 nm wavelength of the Er:YAG laser has absorption characteristics completely different from Nd:YAG, argon, and diode lasers; it is very highly absorbed by water and moderately so by dental enamel.<sup>12, 13</sup> This specific and selective laser en-

ergy absorption by water causes rapid micro-explosions of the water molecules initiated by the selective energy absorption within the target tissue, and provides the foundation for the water-mediated, photo-thermal-mechanical ablation of the Er:YAG laser.<sup>14</sup> Whereas the optical energy is very strongly absorbed by the water molecules within the superficial layers of the target tissue, the penetration depth of this laser beam is limited to a few micrometers close to the surface. Based on this unique combination of strong superficial absorption and shallow penetration, tissues with high water content, such as dentin or gingival tissues, can be ablated or excised precisely by these microexplosions with almost nonexistent thermal damage to the underlying tissues as long as there is proper water irrigation at the site. An Er:YAG laser de-

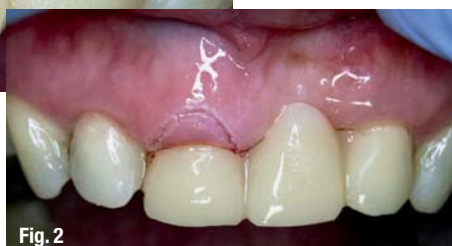

Fig. 2

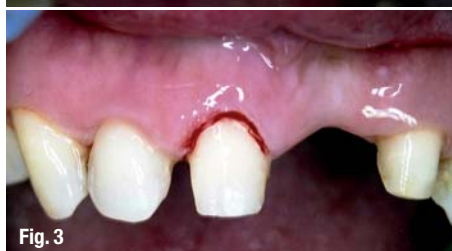

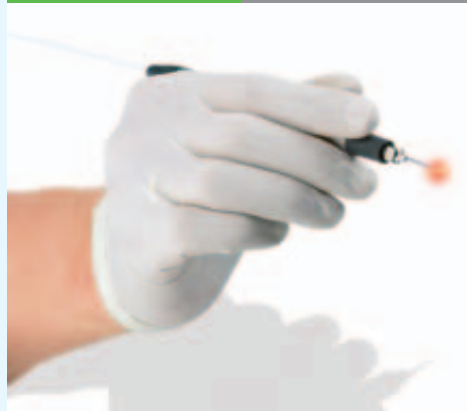Fig. 3



KaVo GENTLEray 980 Diode LASER

# Small but amazing.

**The hygienic solution:  
Re-sterilisable fibres.**



100 KaVo

The KaVo GENTLEray 980.

The most gentle of all diode LASERs.

- Pain-reduced soft tissue surgery, without use of a scalpel
- Effective decontamination in root canals and periodontal pockets
- Significantly increased, postoperative patient comfort
- Safety and security for those "at risk" patients

[www.100-years-kavo.com](http://www.100-years-kavo.com)



*Simple. Logic. GENTLEray*

*KaVo. Over 100 years of dental experience and innovation.*



## KaVo. Dental Excellence.

vice was cleared for marketing by the US FDA in 1997 for certain hard and soft tissue procedures, such as caries removal and cavity preparation, as well as incision and excision of intraoral soft tissues. Other Er:YAG laser instruments were then cleared for sulcular debridement in 1999, and in 2004 for osseous surgery. Animal studies have shown that this laser wavelength demonstrates suitability for vaporizing bone with minimal thermal damage and good postoperative healing.<sup>15-18</sup> While the use of this laser wavelength for dental hard tissue is relatively well-established in contemporary dentistry, there is some debate about its usefulness for soft tissue or periodon-

## Materials and Methods

In this study, 60 patients (33 males and 27 females with a mean age of 49 years) were treated for various periodontal conditions, such as acute periodontitis, refractory periodontitis, gingival naevi, pre-prosthetic and orthodontic periodontal surgery. The patients were selected based on the following criteria: (1) no existing systemic diseases such as diabetes<sup>28</sup> or hemorrhagic disorder that could affect the treatment outcome, (2) no history of antibiotic therapy one month prior to the surgical procedures, and (3) teeth directly related to the surgical site should be vital and their periodontal conditions were, if possible stabilized with conventional scaling, root planing, and prophylaxis. Consent for periodontal and especially laser treatment was obtained. Provisions of the Helsinki Declaration of 1975, ethical principles in medical research involving human subjects, as revised in 2000, were observed throughout this study. Surgical interventions, such as surgical curettage, gingivectomy, gingivoplasty, osteoectomy, and osteoplasty, were considered only in cases of acute periodontitis or when the periodontal inflammation failed to improve in three months after conventional mechanical de-

bridement. Documentation, such as clinical attachment levels, tooth vitality tests, intraoral photographs, and panoramic and periapical radiographs, were collected before the laser treatment. The surgical sites were locally infiltrated with Xylocaine (lidocaine HCl, with 1:100,000 epinephrine (DENTSPLY Canada Ltd., Woodbridge, Ontario, Canada), and no nerve block was used. All of the laser surgical procedures were performed with Er:YAG (2,940 nm) lasers (DELIGHT™ and VersaWave®, HOYA Con-

Bio, Fremont, CA, USA), and strict laser safety requirements in the operatories were observed.<sup>29-30</sup> The surgical sites were irradiated with multiple laser pulses, with individual pulse energies varying between 30 and 120 mJ, pulse repetition rates between 10 and 30 Hz, and pulse duration of approximately 250–300 μs. The laser beam was delivered through an optical fiber connected to a round-exit contact tip 600 μm in diameter. The exit power at the contact tip was monitored by a power meter (PowerMax 600™, Molelectron Detector, Inc., Portland, OR, USA) before each procedure. This contact tip was kept in near or direct contact with the target tissues, with variations of spot diameters between 0.6 and 1 mm. Power densities of 162 to 12 W/cm<sup>2</sup>, based on the 600 μm contact tip and power output measured by the power meter, were applied;

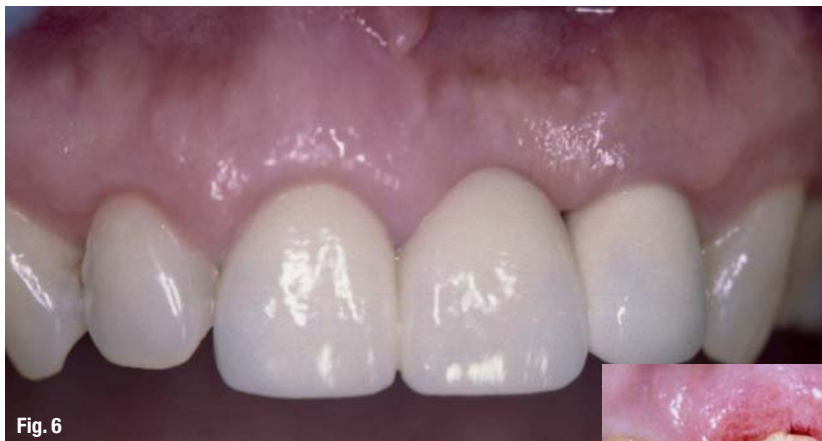

Fig. 6

**Fig. 4** Laser gingivoplasty or festooning of the new gingival margin completed.

**Fig. 5** Two-week postoperative view, before the final insertion and after the abutments were etched with the same Er:YAG laser.

**Fig. 6** Four-month recall with healthy gingival margin.

tal procedures.<sup>19,20</sup> On the one hand, the Er:YAG laser's radiation has been found to be strongly absorbed by many pathogenic bacteria that are related to periodontal infections,<sup>21-23</sup> and it has been shown to be effective in removing root-bound calculus without damage to the cementum and dentin.<sup>24</sup> Therefore, it has been studied for nonsurgical periodontal therapy, and significant gains in clinical attachments have been reported.<sup>19, 25-27</sup> However, for periodontal surgery, there are two common concerns for the use of this laser wavelength: (1) there is a lack of selective energy absorption between the target tissues and the contiguous nontarget tissues, such as the root and bone surfaces, and (2) the shallow energy penetration provides coagulation that is not as profound, and hemostasis is not concurrent with tissue ablation as the other soft tissue lasers, such as CO<sub>2</sub>, argon, diode, or Nd:YAG. The purpose of this study, therefore, was to evaluate these concerns clinically and determine whether the Er:YAG laser with full-time water irrigation was suitable for periodontal surgery in a safe and effective manner.

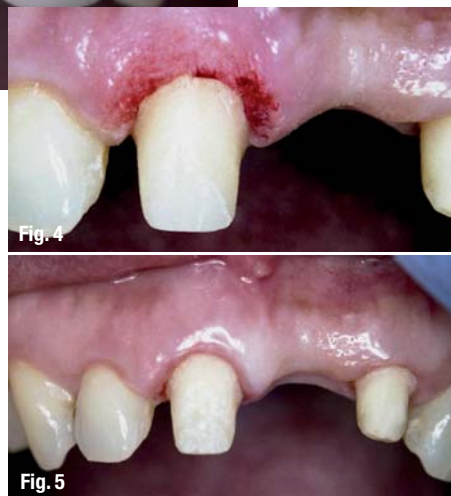

Fig. 4

Fig. 5



higher density was used for tissue ablation and lower setting for bacterial reduction and tissue coagulation. The surgical site was irrigated throughout the laser procedures with filtered water emitted from the contact tip itself and from an external air-and-water syringe. At the completion of the surgical procedure, hemostatic cotton pellets (Racellet #3, Pascal Co., Inc., Bellevue, WA, USA) and/or 4-0 silk sutures were used as necessary. The patients were instructed to follow the postsurgical care protocol, and no prescriptions for analgesics or antibiotics were prescribed. No special mouthrinse was given, and regular home care except at the surgical site was suggested. All of the patients

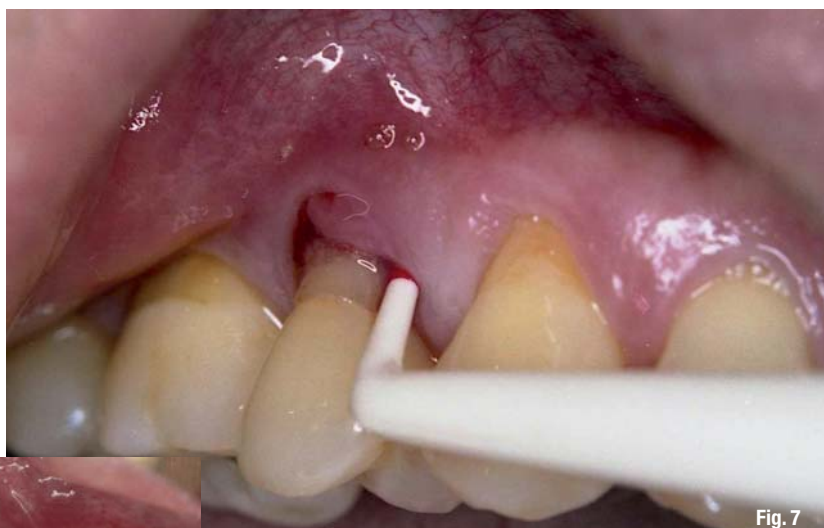

Fig. 7

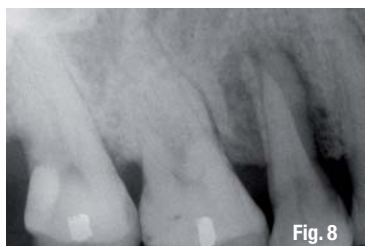

Fig. 8

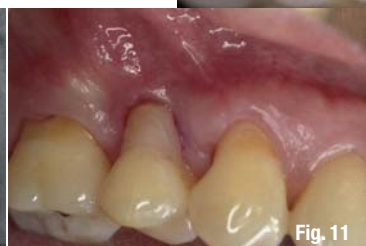

Fig. 11

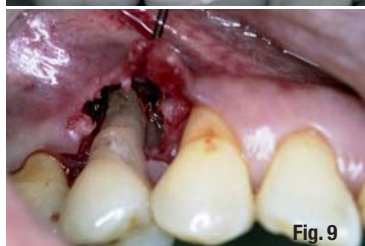

Fig. 9

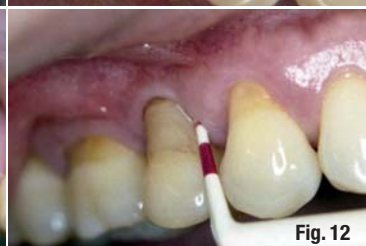

Fig. 12

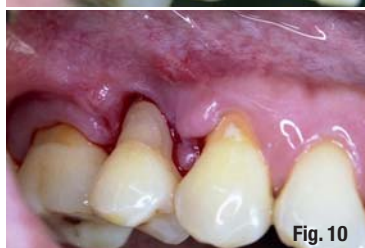

Fig. 10

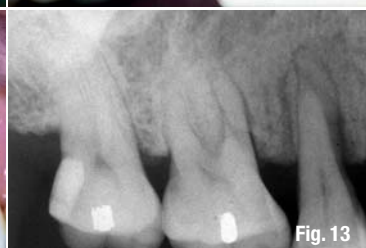

Fig. 13

posterior mandible ( $n = 24$ ). The most common indication for laser periodontal surgery (24 out of 60 procedures) was moderate-to-severe acute periodontitis. The average amount of local anesthetic used was 0.5 ml; only local infiltration was used and no nerve block was required. Despite the extensive nature of some of these procedures, there were only two cases in which conventional full periosteal flaps were raised; sutures were required for these two cases, as well as for five other surgical sites. The blood clotting process was enhanced through the use of

**Fig. 7** An intraoral photograph of patient #2 showing buccal swelling and deep mesial pocket at tooth #4.

**Fig. 8** A pretreatment periapical radiograph illustrating severe bone loss.

**Fig. 9** A periosteal flap was raised, and the underlying granulation tissues on the roots, the adjacent alveolar bone, and the flap itself were ablated with the laser.

**Fig. 10** One-week recall with no sign of complications.

**Fig. 11** One-month recall on the same site with good periodontal recovery.

**Fig. 12** Six-month recall with new buccal attached gingiva and reduced mesial pocket.

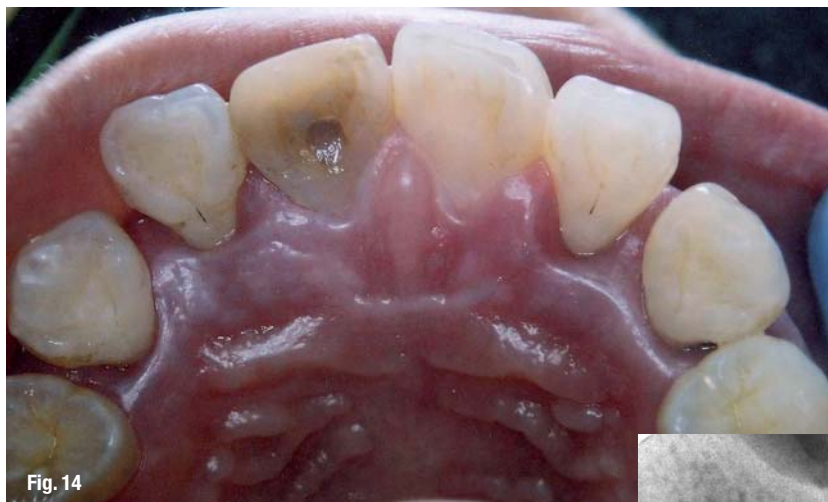**Fig. 13** A periapical radiograph with signs of bone regeneration six months later.

were contacted the next day for postoperative assessment. Regular home maintenance resumed after the surgical sites were re-examined, and the sutures were removed at the one-week recall appointments. All of the clinical observations, along with the patients' assessments, were collected one week, one month, three months, and up to four years later. It is important to note that this study made no attempt to gather statistics that would be analyzed for probability significance; rather it attempted to show that the use of the laser was beneficial in the treatment of the patients' periodontal disease.

## Results

A total of 67 vital teeth were directly treated with a combination of 104 individual surgical procedures for this group of patients. The most common procedures were surgical curettage ( $n = 52$ ), followed by gingivectomy ( $n = 47$ ). The most common surgical site was the posterior maxilla ( $n = 29$ ), followed by the

the hemostatic cotton pellets in 16 sites. There was no report of air emphysema at any of the surgical sites. After the laser treatments, one of the patients was prescribed a course of antibiotics as a precaution due to the severity of the initial infection, and because the surgical site was very close to the maxillary sinus; otherwise no medication was prescribed for the other patients. They were contacted the next day and no bleeding or swelling was reported. One of the patients took an over-the-counter analgesic, and another complained of soreness but did not require any medication; mild soreness to no discomfort were reported by the rest of the group. One patient did complain of sensitivity to temperature which required one week for the symptoms to be resolved. Follow-up periods ranged from 6 to 54 months, with an average mean follow-up period of 2.4 years. The probing depths were normal, and there were signs of clinical attachment improvements. All of the treated teeth remained vital and functional during the follow-up period.



connective tissues, extracellular components, and high water content (approximately 70% for gingiva and 10 to 20% for bone), through selective laser energy absorption and by keeping the contact tip either angled away from the root and bone surfaces for the selective gingivectomy or along the edges of the alveolar bone for marginal osteoectomy, both the soft and hard tissues were ablated and modified with the same laser. With proper water irrigation, there was no surface carbonization, smoke formation, or tissue shrinkage. The treatment outcome of this procedure was relatively predictable, and hemostasis was stable enough that

**Fig. 14** Patient #3, a 26-year-old healthy female patient with generalized chronic periodontitis.

**Fig. 15** Apical radiograph of the upper right lateral incisor.

**Fig. 16** Seven months later, after conventional nonsurgical debridement and prophylaxis.

**Fig. 17** Seven-month postoperative probing of the lingual pocket of the right lateral incisor still demonstrates significant depth.

**Fig. 18** Exposure of the lingual pocket followed by laser removal of granulation tissue and bacterial reduction.

**Fig. 19** Surgical closure with sutures.

**Fig. 20** One-week postoperative view.

**Fig. 21** Thirty-month postoperative probing, showing reattachment.

**Fig. 22** Thirty-month postoperative Radiograph.

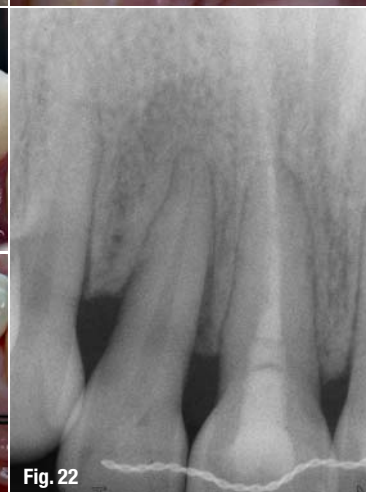
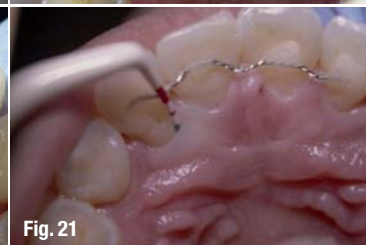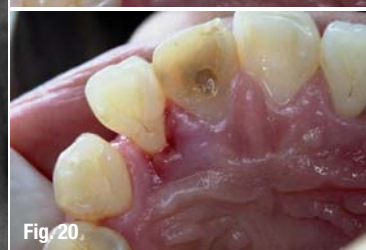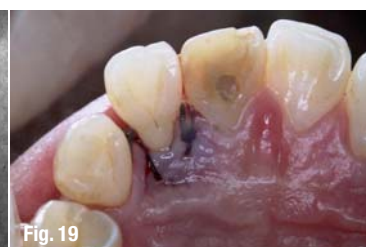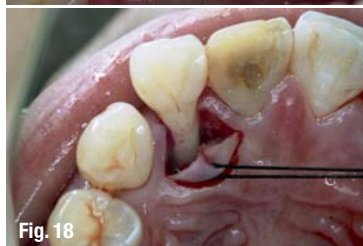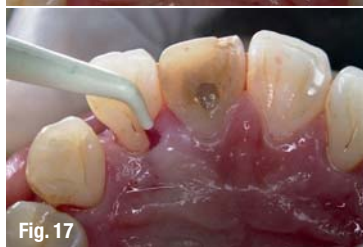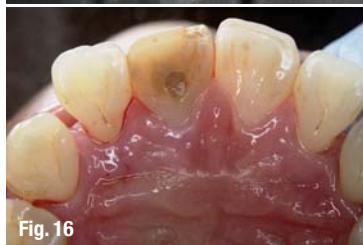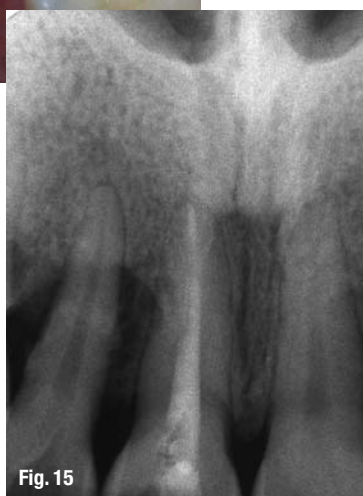## Clinical Cases

### Patient #1

The patient was a 63-year-old female recovering from breast cancer treatment. Although her medical history was not ideal, she was selected because her last chemotherapy treatment had been more than three months prior, and her periodontal health was excellent. For this patient to have a more balanced gingival appearance, crown lengthening was required (Fig. 1). After the surgical area was anesthetized and the new parabolic level was initially designed with superficial lasing (Fig. 2), the excess gingival tissues were removed with the Er:YAG laser. To achieve normal biological width at the new gingival level, the underlying dental alveolar bone was reduced (Fig. 3). Laser gingivoplasty, or festooning, was used to bevel the surface geometry of the new attached gingiva (Fig. 4), and the final impression was taken after the abutment was prepared. The subsequent healing was uneventful, mild sensitivity was reported, but she did not require any medication.

The gingival margin was stable and healthy enough for the final insertion in two weeks (Fig. 5). The surgical results remained stable, and the central incisor was asymptomatic six months later (Fig. 6). Because gingiva and bone are composed of varying densities of fibrous

the final impression was taken at the end of the surgical procedure. There was a safety concern when this hard tissue laser was employed in such close proximity to the root surface and the alveolar bone. As demonstrated, if the intention and the direction of the energy





elexxion


powered by technology

elexxion  
claros

elexxion  
duros

elexxion  
delos

elexxion  
claros nano



# Four laser specialists for a wide range of applications

- Highest cutting performance
- Short pulse duration guarantees smooth soft-tissue application
- Compliance to all hygienic standards through autoclavable handpieces and fibres

elexxion AG

Schützenstraße 84 · D-78315 Radolfzell · Germany  
Tel. +49 7732-822 99 0 · Fax +49 7732-822 99 77  
info@elexxion.com · www.elexxion.com

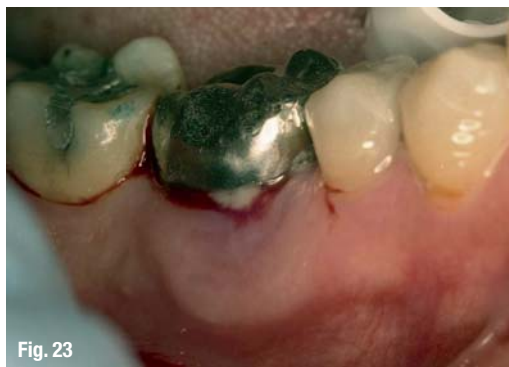

Fig. 23

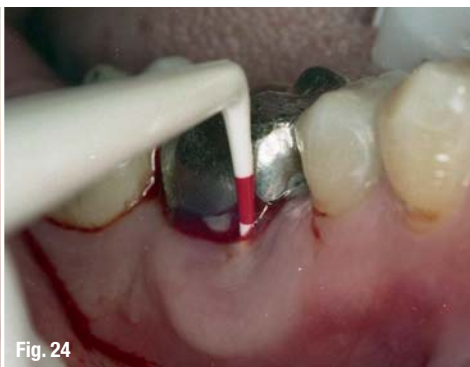

Fig. 24

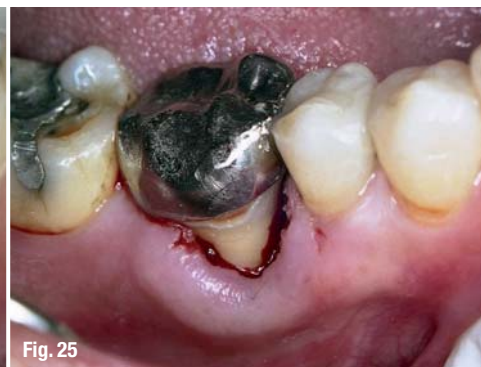

Fig. 25

**Fig. 23**\_Initial view of periodontal abscess on the facial aspect of tooth #30 of patient #4.

**Fig. 24**\_Periodontal probe being used to ascertain extensions of the pocket.

**Fig. 25**\_Immediate postoperative view after laser ablation of granulation tissue

application are carefully planned ahead, this laser may be used safely for selective ablations, even in such a confined surgical site. In spite of the initial concern over her possible weakened immune response and healing capacity for which conventional treatment had been refused, as noted before, the wound healing was uneventful and took place without the assistance of medication.

#### Patient #2

For this patient, surgical periodontal treatment was also refused because the prognosis for his infected premolar was deemed hopeless. For this 66-year-old male patient, who was taking antihypertensive medication, it was recommended that his upper right second premolar be extracted because of acute periodontitis and severe bone loss (Figs. 7 and 8). The patient's blood pressure was stable and under control, and the rest of his dentition was functional and normal. After the buccal and lingual areas were anesthetized, a buccal mucoperiosteal flap was raised. The infected granulation tissues were removed around the root surfaces and on the raised flap (Fig. 9). Granulation tissues usually carry much higher water content than healthy fibrous tissues such as the attached gingiva, a fact that can be exploited quite well by the strong water-affinity of erbium lasers.

With water irrigation, the exposed bone surfaces were lightly irradiated in noncontact mode with the lowest power density setting. Once stable hemostasis was accomplished, the surgical wound was closed with a 4-0 silk suture. Despite the initial infection and gingival swelling, no antibiotics or analgesic medications were prescribed. There was no report of any swelling or pain, and, most importantly, there was no bleeding at the day-after reassessment. The surgical area was monitored further for one week (Fig. 10), one month (Fig. 11), and six months (Fig. 12). Clinically, the premolar was asymptomatic and functional in two months, and there were radiographic signs of bone regeneration in six months (Fig. 13).

#### Patient #3

This patient was only 26 years old when the extraction of her periodontally weakened right lateral incisor (Fig. 14) was recommended (Fig. 15).

Although her overall periodontal condition improved after sessions of conventional debridement (Fig. 16), this extensive periodontal pocket (Fig. 17) became an urgent concern when orthodontic treatment was considered. The surgical approach was very similar to the one taken for patient #5 in terms of controlled access, granulation tissue removal, root surface irradiation (Fig. 18) and suturing (Fig. 19). The recovery of her surgical site was uneventful one week later (Fig. 20) and remained asymptomatic throughout her ensuing orthodontic treatment. Two-and-a-half years later, both the periodontal probing (Fig. 21) and radiograph (Fig. 22) show quite satisfactory clinical reattachment (Fig. 21) and bone remodeling around the initially 'hopeless' incisor.

#### Patient #4

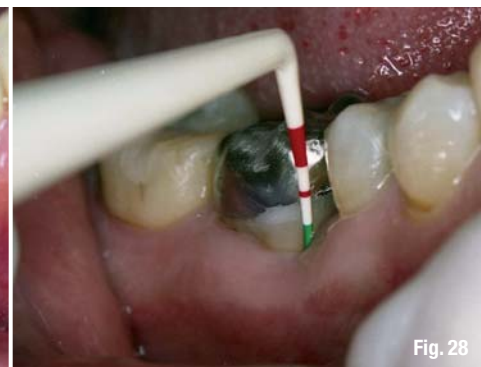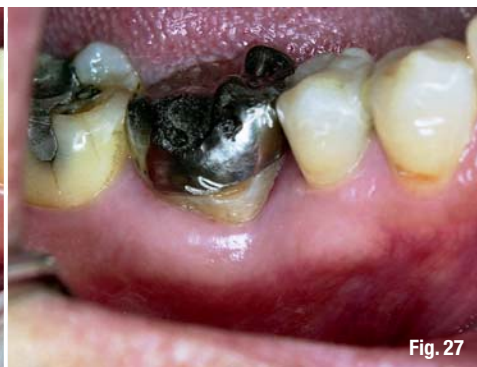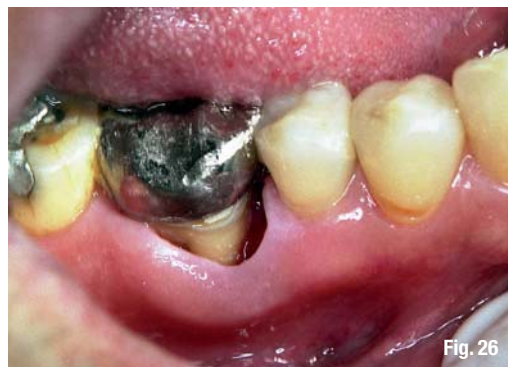This patient was a healthy 58-year-old male who presented with an infected periodontal pocket (Fig. 23). After it was probed and calibrated (Fig. 24), the inflamed granulation tissues were selectively separated from the remaining healthy attached gingiva and within the periodontal pocket (Fig. 25).

Although infection was initially present, no medication was prescribed and the patient reported no need for any; the surgical site recovered without any incident (Fig. 26). Clinical attachment was eventually reestablished in a month (Fig. 27) and remained stable two years later (Fig. 28).

#### Discussion

There were 23 similar clinical scenarios in the study. The patients typically presented with varying degrees of symptoms and contributing factors, which would normally require invasive conventional open-flap surgery and prescriptions for antibiotics and analgesics, followed by a long period of convalescence. With the flexibility of the Er:YAG laser contact tip, the surgical sites were carefully and precisely designed, the subsequent instrumentations were less invasive, and laser energy transfer was finely controlled. As a result, the healing experiences of these patients were much more pleasant, and the surgical outcomes were more controlled.





Although there were signs of clinical reattachments for all of the treated areas consistent with Gaspirc and Skaleric<sup>38</sup> in their fiveyear, 25-patient study, there was no attempt to compare the quantitative assessment of the clinical attachment levels, since the gold standard for surgical reassessment of the actual bone level is not appropriate for clinical studies of this nature. Then, again, if the main objective of periodontal surgery is the establishment of a new connective tissue attachment to a root surface previously exposed to periodontal disease, the collective clinical and radiographic observations are quite supportive of the effectiveness of this new treatment modality. With the ablation of both hard<sup>26</sup> (alveolar bone) and soft tissue<sup>32</sup> (granulation and gingival tissue) precisely controlled, periodontal tissue reshaping or recontouring can be planned and performed efficiently with the Er:YAG laser. The bactericidal<sup>21-23</sup> and possible biostimulation<sup>33</sup> effects of this radiation with no carbonization or intense coagulation allow faster wound healing without any major postoperative swelling, pain, or bleeding. By allowing the various growth factors involved in wound healing to work soon after the surgery, the less-than-profound hemostasis from the Er:YAG lasers compared with other intense coagulation, can be beneficial and, in many situations, preferable. While these laser surgical benefits can be helpful in certain aspects of periodontal surgery, it is important to note that the use of lasers should be considered as an addition to our present armamentarium, not as a replacement for the well-established surgical principles and techniques that have been developed since the first gingivectomy was reported.<sup>1</sup> Because of the nontouch to light-touch requirements, the use of lasers is technique-sensitive, and due to the proximity of the irradiation to dental and bone tissues, proper training and understanding of basic laser physics is required. Appropriate laser parameters, such as power density, pulse duration, exposure time, and water irrigation, should be carefully considered. Although the laser treatments in this study have been successfully carried out, one cannot ignore an enormous contributing factor to success: the patient's compliance with respect to his or her daily bacterial plaque control. It is normal to expect a better treatment outcome, or

at least better control of it, when we incorporate any new technology into our operatory. The object of this study was to document tissue responses to Er:YAG laser radiation use in surgical periodontal procedures. In particular, we wanted to evaluate whether it was safe and effective to operate the laser in close proximity to root and bone surfaces with less profound coagulation. In the present study, there were no reports of any postoperative hemorrhagic complications or side effects among the 60 patients, and the dental hard tissues that surrounded the target sites remained vital, functional, and asymptomatic. The average amount of anesthetics that were reported and the way the anesthetics were used seem to suggest that the demand for anesthetics was reduced. This may be related to the more confined and superficial surgical sites, which, in turn, reduced the possibility of bacteremia and the demand for antibiotics and analgesics. This was of benefit to some of the patients in this study who had significant medical history.

### Conclusion

This is an uncontrolled clinical study that has evolved from a private practice setting; however, the potential benefits of using an Er:YAG laser for periodontal surgery are quite evident. Based on the clinical observations collected, it is both safe and effective to use this laser wavelength in the manner described for periodontal surgery. Further investigation, ideally in the form of a randomized, controlled clinical study, will be required to validate these clinical results.

Disclosure: Dr. Yung lectures for the Institute for Laser Dentistry and receives honoraria as compensation.

This article is reprinted for educational purposes with permission from the Academy of Laser Dentistry, Journal of Laser Dentistry 2009, Volume 17, Issue 1. It's original publication appears in J Laser Dent 2009;17(1) 13-20. For additional information contact the Academy of Laser Dentistry [www.laserdentistry.org](http://www.laserdentistry.org)

*The Literature list can be requested from the editorial office.*

**Fig. 26** One-week postoperative view.

**Fig. 27** One-month postoperative view.

**Fig. 28** Two-year postoperative probing.

**\_contact** **laser**

**Dr Frank Yung DDS**

E-mail:  
[drfrankyung@gmail.com](mailto:drfrankyung@gmail.com)  
[www.drfrankyung.com](http://www.drfrankyung.com)