

Prevention of deep periodontal diseases using Er:YAG laser

Author_Dr Fabrice Baudot, France

Periodontal maintenance is an integral part of successful periodontal therapy (Axelsson & Lindhe, 1981). The objective is to stabilise the microbial balance restored after an initial periodontal therapy (Kornman, 1997). A systematic surgical approach following an initial therapy is no longer necessary as it is with standard treatment (Heitz-Mayfield, 2005). Over the past few years, periodontics has been shifting towards a non-invasive or non-surgical approach to access the deep cleaning of the periodontium, as part of the development of all medical surgical techniques in general.

Non-surgical procedures, most respectful non-surgical periodontal tissue protocols have proven to be efficient (Badersten & Egelberg, 1990, 1987, 1985, 1984, 1981), but force us to leave risky sites that can be difficult to manage in periodontal maintenance (Cobb, 2002; Becker et al.). Root furcation defects and residual periodontal pockets deeper than 4 mm are the daily reality faced by periodontists and hygienists responsible for their patients' maintenances.

By means of a literature review of the physical and biological properties of the Er:YAG laser, we would like to demonstrate the relevance this device may have as a preventive tool in maintenance procedures on at-risk periodontal sites (Fig. 1).

Aetiology and diagnosis of periodontal disease

Periodontitis is an inflammatory disease affecting the periodontium. The inflammation arises as a result of imbalance between the oral microbial flora and defence system of the host (Kornman, 1997). Microbial involvement is a major factor in the development of the disease, but other risk factors including but not limited to smoking, stress and genetic predisposition contribute to the aetiology of periodontitis (Genco et al., 2013). For the sake of simplicity, we can distinguish between two variants of periodontitis (Page, 1997):

1) Aggressive periodontitis (Figs. 2a & b), which occurs before the age of 45.

Fig. 1 Clinical situation following initial therapy. Some deep pockets need long-term care.

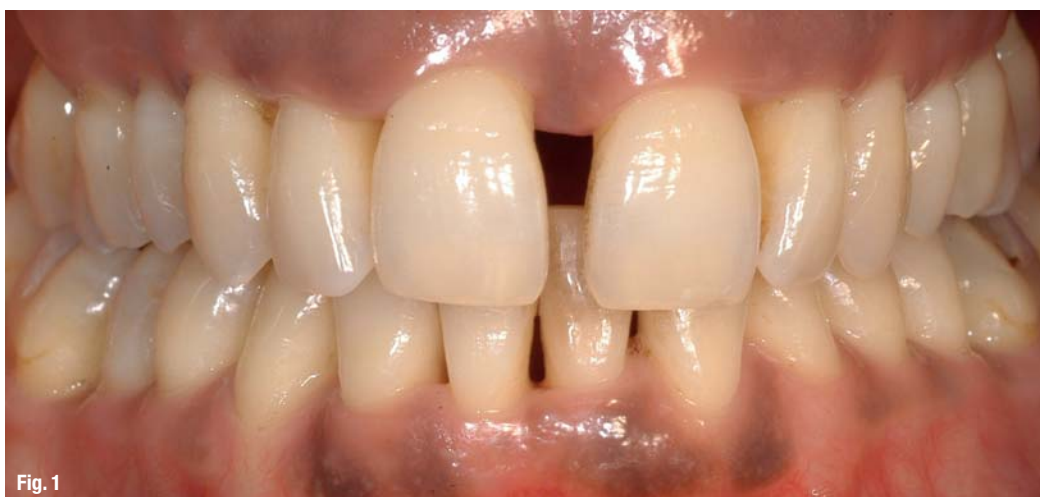

Fig. 1

2) Chronic periodontitis (Figs. 3a & b), which develops after the age of 45.

Major risk factors associated with chronic periodontitis include bacteria and tartar. General risk factors such as diabetes, smoking or others also aggravate the disease. Local risk factors do not play a major role regarding aggressive periodontitis; a periodontal imbalance seems to be related primarily to general risk factors.

In both cases, the imbalance results in an inflammatory reaction, rendering the periodontium porous to microbes. Subsequently, the polymicrobial flora becomes embedded in the biofilm and invades the deep periodontium and even the inner tissue, leading to the destruction of the periodontium. The origin of periodontal destruction seems to be more related to the inflammatory reaction than to the microbial flora (Barthold, 2010).

The radiography of both clinical situations depicts an advanced stage of the disease, with similar skeletal deterioration. These two cases differ primarily in terms of the patient's age, which is 25 in the case of an aggressive periodontitis (Figs. 2a & b) and 68 years in that of a chronic periodontitis (Figs. 3a & b).

Periodontitis treatment protocols

Treating periodontitis involves the restoration of the periodontal balance. The key instrument used here is infection-control through the reduction and modification of the microbial mass. The elimination of inflamed tissue helps to trigger the periodontal healing process (Lindhe & Nyman, 1985). The treatment strategy consists in encouraging the immune system to fight the microbial flora by destabilising the significant protective biofilms in which they are hosted (Sanz & Van Winkelhoff, 2011, 7th European Workshop).

Today, the widely accepted treatment protocols for periodontitis are centred on two phases (Dentino, 2013):

- 1) An initial treatment that serves to control the infection, reduces inflammation and restores the periodontal homeostasis.
- 2) Periodontal maintenance treatment or supportive therapy. This phase focuses on the maintenance of the periodontal balance achieved during the initial therapy in the longer term.

Several initial treatment protocols have been described in the literature (Lindhe & Nyman, 1985):

–Surgical protocol: The use of "blind" scaling and root planning, which is aimed at controlling the in-

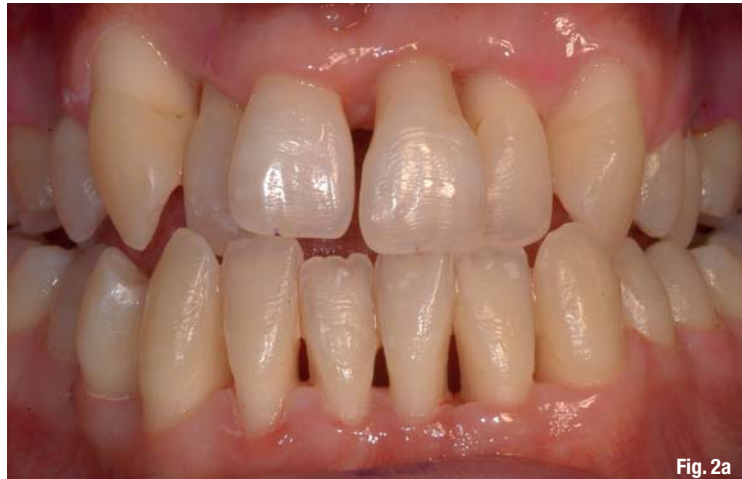

Fig. 2a

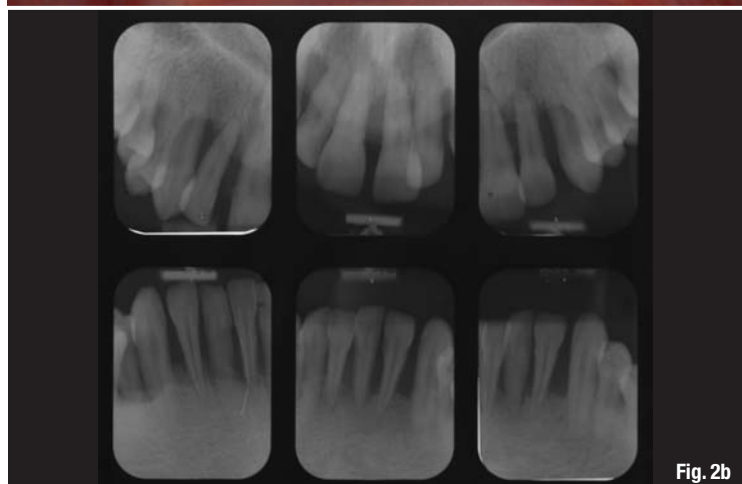


Fig. 2b

fection and reducing inflammation. This first step is followed by periodontal surgery for the purposes of decontaminating the four sites and eliminating residual periodontal pockets: the Widman Flap (Ramfjord & Nissle, 1974).

- Non-surgical protocol: This protocol preserves the periodontal tissues more effectively. It consists of only one scaling and root planning without access flap to decontaminate the periodontium. Residual pockets are numerous and are controlled as part of a strict maintenance programme (Badersten & Egelberg, 1984).
- Minimally invasive periodontal regenerative surgery (Cortellini & Tonetti, 2007): Here, the periodontium is cleaned up to a surgical level but without an access flap. Special therapeutic means such as optical aids and lasers can also improve these non-invasive procedures. A surgical technique inspired by the Canadian University of Public Administration ENAP published in 1976 by Yukna allows patients to benefit from the surgical approach and non-surgical techniques without suffering the disadvantages.

Periodontics follows the preferred route taken in medicine which is minimum intervention. This is one

Figs. 2a & b Aggressive periodontitis and pre-operative radiography.

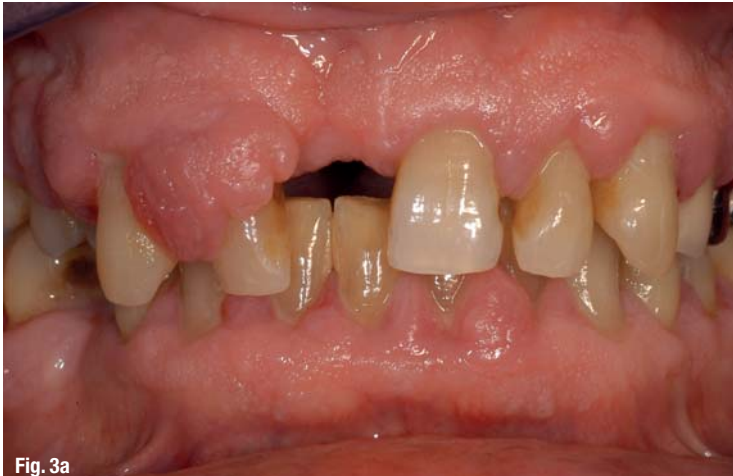

Fig. 3a

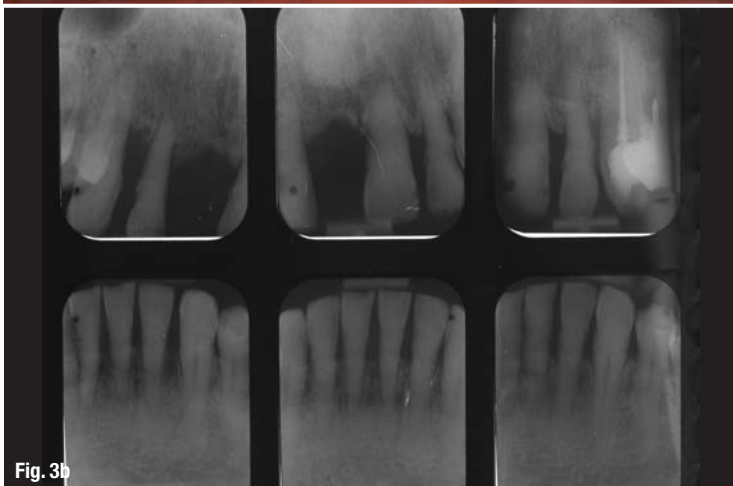

Fig. 3b

Fig. 3a & b_Chronic periodontitis and pre-operative radiography.

of the reasons why non-surgical and minimally invasive techniques have been developed within the field. The surgical approach is long, highly invasive and does not shy away from a strict maintenance protocol to prevent recurrence (Badersten, 1984; Teles, 2012; Westfelt et al. 1983; Lindhe & Nyman, 1984; Harper & Robinson, 1987; van Winkelhoff et al., 1988; Renvert et al., 1990a; Shiloah & Patters, 1996).

Within cases of periodontitis, the heart of the problem is related to microbial and immunological factors. Periodontal maintenance is intended to stabilise the balance recovered through initial therapy, regardless of the initial protocol used (Ebersole, 2013).

In view of the biological consequences, the risk-benefit ratio of performing invasive surgery does not seem favourable today (Heitz-Mayfield & Lang, 2013; Walsh & Waite, 1978; Badersten et al., 1984a, 1984b; Leon & Vogel, 1987; Oosterwaal et al., 1987; Cobb, 1996). Our knowledge of microbiology and immunology has evolved, as have the technical platforms use. This also enables us to offer alternative therapies for the treatment of periodontitis. The Er:YAG laser may be central to this strategy (Figs. 4–6).

Physical and biological properties of the Er:YAG laser

Er:YAG is a laser that emits radiation at a wavelength of 2,940 nm (Robertson, 1971). At this wavelength, one of the physical properties of the energy emitted is that it has double the peak absorption in water and hydroxyapatite (Ishikawa, 2004). This is a fundamental property that distinguishes Er:YAG from other lasers used in dentistry and singles-out as the wavelength of choice in non-surgical periodontal debridement applications (Schwarz et al., 2008).

Photothermal properties

Due to very strong water absorption, the Er:YAG laser has a therapeutic effect at low energy levels and limits the thermal effects on tissue adjacent to the targeted areas. Tissues subjected to Er:YAG radiation are vaporised by means of a huge increase in temperature upon impact, which is instantly reduced to a great extent by massive water absorption (Aoki, 1994; Eberhard, 2003; Schwarz, 2003). Clinically, this effect is manifested in the form of a micro-tissue ablation on a few microns of material (Walsh, 1989).

Photomechanical properties

These properties are as follows:

- Shockwave: the emission of laser radiation causes a shock wave at each impact.
- When radiation is emitted in a hydrated solution, the energy released in the water molecules produces multiple micro-explosions that allow for a deep agitation of the solution (Roca, ongoing study).

Biological effects of the Er:YAG laser

The physical properties of the Er:YAG laser have anti-inflammatory and antiseptic effects, which are highly useful in periodontal therapy. Periodontal tissues are not homogeneous in terms of water load. They can be characterised by a gradient of water load. The water load in the cement is higher than that in the bone, which is in turn lower than that in the ligament and gum or inflamed tissue.

The photothermal properties of the Er:YAG laser allow the tissue to be vaporised in accordance with its water load. The Er:YAG laser has proven to be a very effective and selective micro-surgical tool in situations where there is a decreasing water load gradient (soft tissue vs. hard tissue), since the laser eliminates the most hydrated tissue while preserving the surrounding, less hydrated tissues.

Antiseptic effects

The photothermal and photomechanical properties of the Er:YAG laser have antiseptic effects. Bacte-

rial biofilms are highly hydrated gels in which bacteria live and grow (Marsh & Bradshaw, 1995). Due to their very nature, they perfectly absorb the energy emitted by the Er:YAG laser. Where they are directly exposed to Er:YAG radiation, vaporisation will target primarily the biofilms and bacteria with the highest water load in periodontal pockets.

Although no vaporisation occurs in deep layers or areas where radiation is attenuated, biofilms will be destabilised in these areas. Bacteria will be rendered soluble and therefore are accessible to the immune defence system, which can then help to restore the periodontal balance (Marsh, 2011).

The photomechanical properties also produce antiseptic effects by helping to destabilise microbial biofilms within the periodontal pockets. Two photomechanical mechanisms produce this kind of effect: the shockwave generated by the radiation and the micro-explosions of the molecules. These two phenomena agitate the solutions and give the radiation antiseptic properties, as observed in clinical applications of the Er:YAG laser in endodontics (Roca, ongoing study).

Agitation of irrigation solutions is more intense and more rapid when using an Er:YAG laser than it is when using ultrasonic tools. The propagation of the shock wave is highly effective in the agitation of irrigation solutions in hard-to-reach areas (side ducts, intra-ductal isthmus). In drawing a parallel with periodontics, we see the potential relevance of the Er:YAG laser with regard to antiseptic action in areas such as furcations or deep periodontal pockets, which cannot be accessed easily using conventional means.

Anti-inflammatory effects

These effects are the result of a selective micro-tissue ablation associated with the direct irradiation of inflamed tissue using an Er:YAG laser. Here too, the decreasing water load gradient between the inflamed tissue and the adjacent and underlying structures allows for selective vaporisation: The inflamed tissues are eliminated. The laser energy is highly reduced upon reaching the healthy tissue, which helps to preserve the latter. This mechanism allows the Er:YAG laser to have an instant, powerful anti-inflammatory effect (Dominguez et al., 2010). In periodontal pockets, radiation acts as an ultra-precise optical curette.

Therapeutic benefits of the Er:YAG laser in periodontics

As we have already seen, the therapeutic strategy for periodontal treatment is aimed at restoring and

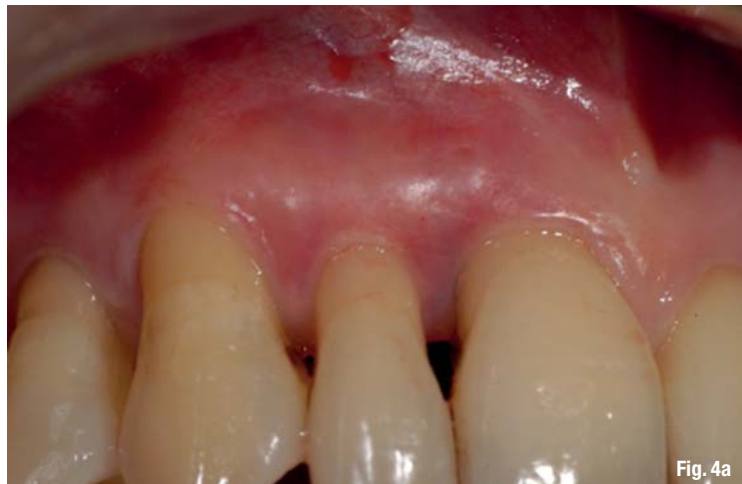

Fig. 4a

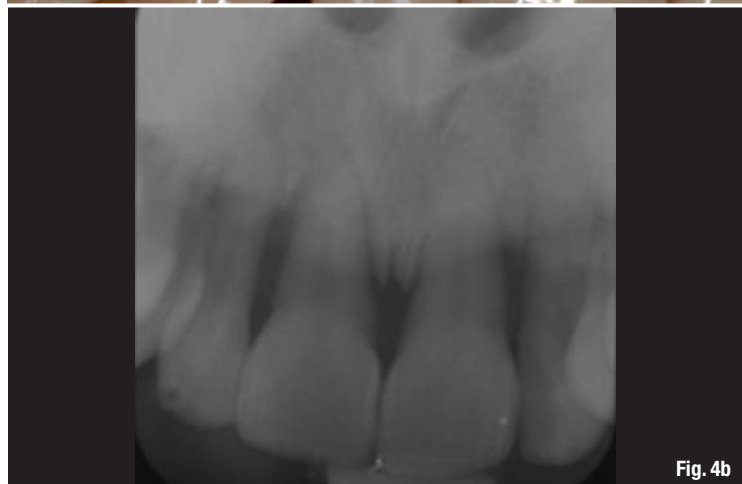

Fig. 4b

maintaining the balance between the immune system and the periodontal micro flora. By its antiseptic and anti-inflammatory properties, the Er:YAG laser seems like an interesting tool that can be integrated with the existing therapeutic arsenal. We can design its use in the initial periodontal therapy and periodontal maintenance. When compared to the mechanical instrumentation in a non-surgical periodontal debridement, the Er:YAG laser achieves better results in the short and long term (24 months) of chronic periodontitis (Schwarz, Aoki et al., 2008).

Er:YAG laser in initial periodontal treatment

The Er:YAG laser can be used to complement or even replace conventional tools in surgical or non-surgical periodontal decontamination procedures. As we have already seen, its biological effects enable it to act as a highly selective and therefore highly accurate optical curette that meets non-invasive intervention criteria to remove inflamed tissue. Its antiseptic action is used to clean root and bone surfaces by direct exposure to laser radiation (Yoshino, 2009).

The ergonomic design of the optic-fibre makes it a very fine tool that can be used to deliver treatment in areas that are often inaccessible to conventional

Figs. 4a & b Clinical situation and pre-operative radiography of an aggressive periodontitis.

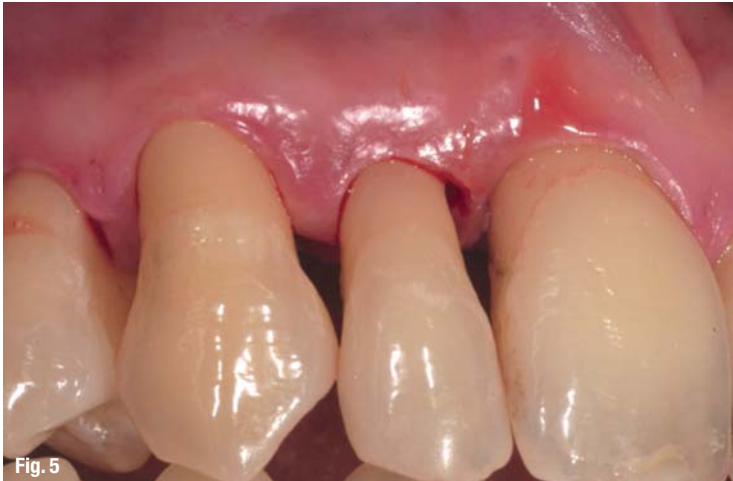

Fig. 5

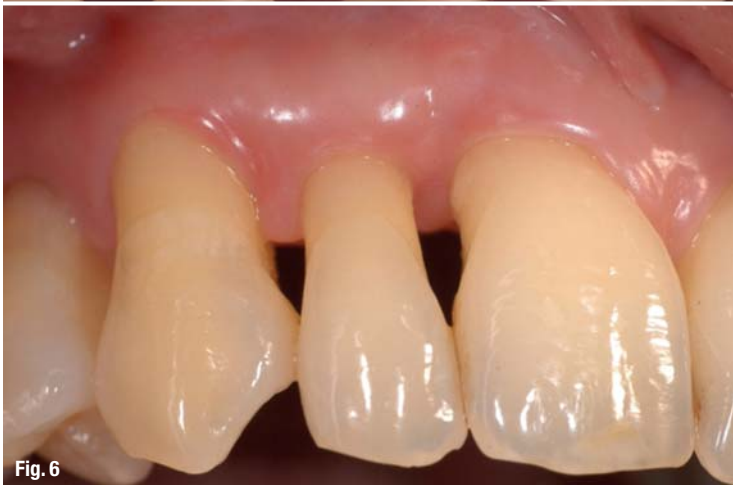

Fig. 6

Fig. 5 Micro-surgical intervention by use of Er:YAG laser.

Fig. 6 Two-month postoperative result. Note the stability of the periodontal tissue.

tools (Sahar-Helft & Stabholtz 2013). Due to photo-mechanical phenomena processes (micro-explosions and agitation of solutions by shockwave) the antiseptic effect of the Er:YAG laser is shown and affect areas beyond those that are accessible by direct radiation. The Er:YAG laser is a real surgical tool, but due to its extreme precision it reaches its full potential when used in minimally invasive or non-surgical interventions to promote healing (Schwarz, 2007).

Er:YAG laser in periodontal maintenance

Despite the interesting properties outlined above, in the literature the Er:YAG laser is not significantly distinguished from conventional tools with regard to therapeutic effectiveness and intervention times in periodontal maintenance procedures: The effects are similar (Tomassi, 2006; Derdilopoulou, 2007; Sculean, 2004). In contrast, Braun et al. (2010), who compared the Er:YAG laser with sonic tools used in periodontal maintenance, have clearly shown that the pain experienced by patients during maintenance sessions using the Er:YAG laser was less significant compared to conventional sonic tools. The use of an Er:YAG laser in periodontal maintenance is more comfortable for the patient than conventional tools, as already anticipated by Tomassi et al. in 2006.

In the literature currently available, the Er:YAG laser has been tested on shallow pockets only (4–6 mm maximum) in periodontal maintenance. It would be interesting to test this laser in maintenance procedures that include periodontal pockets larger than 6 mm and compare the laser with manual tools. The therapeutic properties of the Er:YAG laser offer minimally invasive surgical efficiency, particularly in inaccessible areas (Eberhard, 2003). In comparison, significant limitations are associated with the use of manual instrumentations in these hard-to-reach areas to ensure periodontal maintenance (Matuliene & Lang, 2008).

The Er:YAG laser should allow a more effective control of biofilms in furcations and in periodontal pockets larger than 6 mm. The treatment of periodontal surfaces using the Er:YAG laser promotes periodontal healing. Fibroblast attachment on root surfaces that is treated by using an Er:YAG laser is higher than those treated by using traditional sonic tools (Schwarz, 2003; Crespi et al., 2006).

Alternative to local antibiotics

The local application of antibiotic gels has generated much interest since it allows significant local concentrations of active ingredients to be achieved in periodontal pockets (Ciancio, 1995). However, the problems of a possible resistance and side effects caused by the repeated use of these products still remain. Applying clinical doses of antibiotics to extra-periodontal sites such as the tongue or the tonsils may induce resistance in the bacterial flora (Roberts, 2002).

The bactericidal effects of the Er:YAG laser are likely to make it a beneficial alternative to these medicines. In any case, even though the topical application of antiseptic or antibiotic molecules is a useful therapeutic method (Quang et al., 2002), the destruction of significant biofilms and solubilisation of micro-organisms made possible by the use of an Er:YAG laser can only be beneficial in potentiating this treatment strategy.

Er:YAG laser in periodontal maintenance protocols

As we have already seen, the Er:YAG laser has a significant and effective impact, identical to that of conventional instrumentations, when used in the initial periodontal decontamination therapy. Its photomechanical properties and the ergonomic design allow for a minimally invasive treatment. Therefore, the Er:YAG laser can be integrated into periodontal maintenance treatments as a preventive tool for deep sites that are inaccessible to conventional tools.

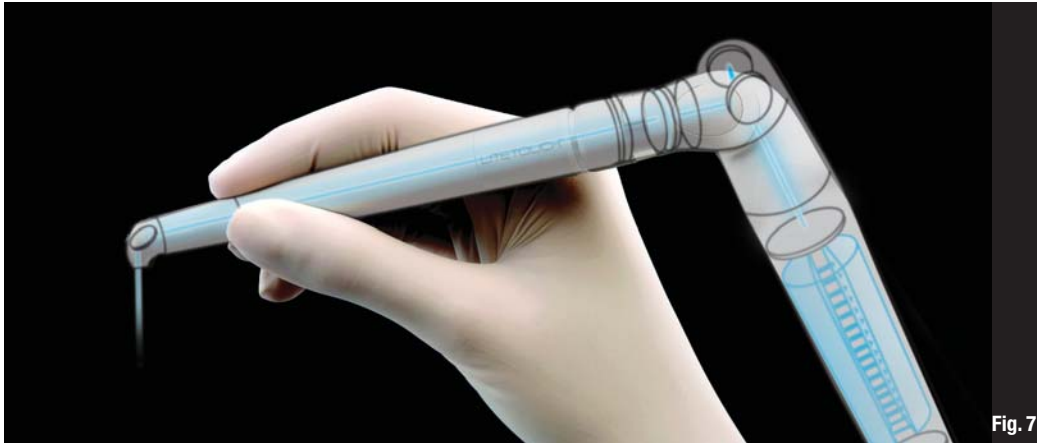


Fig. 7_LiteTouch Er:YAG, "Laser-in-the-Handpiece".

Mousques et al. (1980), Magnusson et al. (1984) and Van Winkelhoff (1988) have demonstrated the recolonisation of cleaned sites 2–8 weeks after the initial therapy. They highlight the need for a regular and deep cleansing to stabilise the periodontal balance. Eccheveria et al. (gingival attachment loss, 1983), Gantes et al. (tooth substance loss, 1992) and Zappa et al. (pulp trauma, 1991) have demonstrated the trauma related to repeated subgingival use of mechanical tools.

Hemrev et al. (2006) point out the usefulness of solubilising biofilms during periodontal maintenance to expose bacteria that are isolated from the immune system. To respond to these requirements and overcome the disadvantages associated with repeated subgingival intervention, the Er:YAG laser offers an alternative for periodontal maintenance of at-risk sites, thanks to its photothermal and photomechanical properties. Therefore, we propose that this tool will be integrated into periodontal maintenance protocols, alongside conventional tools.

Such a maintenance session could be described as follows:

- Application of plaque-disclosing agent to identify areas of dental plaque retention.
- Supra-gingival and subgingival scaling (if necessary) using sonic tools. Side remark: In theory, if the maintenance programme is well scheduled and respects the required frequency, there will be no subgingival tartar.
- Supra-gingival and subgingival polishing and air polishing on areas deeper than 4 mm.
- Conventional tools using manual curettes on areas deeper than 4 mm.
- Use of Er:YAG laser to irradiate furcation areas, areas inaccessible to conventional tools and sites that are higher than 4 mm.

Laser settings

It is the energy delivered by a laser beam which produces the therapeutic effect. To limit side effects and particularly thermal effects, the energy applied in periodontal maintenance should be low as long as the

Testimonial



In the past 15 years, I have been focusing on periodontology in my work. But at the beginning of my career, I practised endodontics exclusively and have also resumed the practice of implantology during the past seven years.

Endodontics allowed me to discover the surgical microscope, which in turn made it possible for me to develop a non-invasive periodontal decontamination technique which is an intermediate route between the surgical approach and non-surgical techniques. Optical aids are key elements of this surgical concept. However, I have already been using an integrated Er:YAG laser in my clinical protocol for five years. This technology has provided me with a tool that offers the level of precision required for decontamination microsurgery.

The ergonomic design and exceptional performance of the LiteTouch laser allows me to work in a highly efficient manner with optical aids, achieving tissue micro-ablation under a visual check and by destabilising the biofilms. Its anti-inflammatory and antiseptic effects are fundamentally important for periodontology.

The strong water absorption for which the Er:YAG laser is known means that it is suitable for multiple surgical applications particularly in the area of gingival microsurgery and in assisted pre-implant bone regeneration procedures. In my opinion, the Er:YAG laser has become an indispensable tool for non-invasive procedures.

In addition to its **effectiveness** on inflamed tissues and biofilms, the Er:YAG laser offers **surgical comfort** that is **fundamental** for the observance of periodontal maintenance **treatment**.

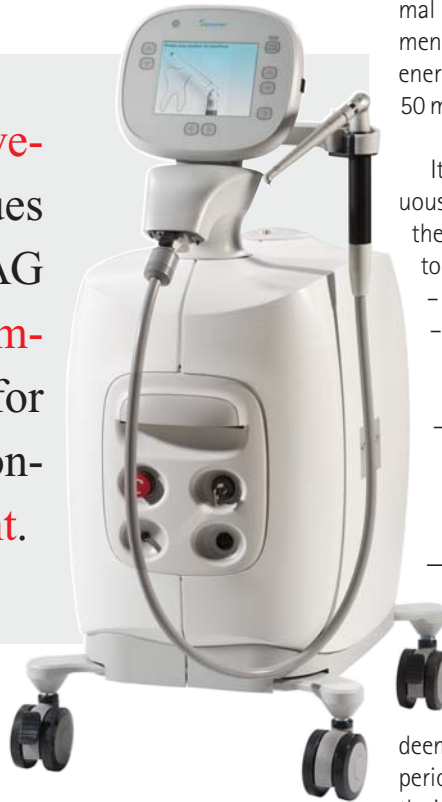


Fig. 8_LiteTouch, Er:YAG laser device.

treatment is not performed under direct visual control like it is performed in surgery. As we have already seen, the energy delivered by the Er:YAG laser at 2,940 nm has a very high water absorption rate. This physical property makes the Er:YAG highly efficient at low energy levels and has allowed it to establish itself as a standard in the field of periodontal maintenance among the various laser wavelengths used in dentistry (Walsh et al., 1989).

The objective is not to eliminate tissue, but rather only to break down biofilms and solubilise micro-organisms so as to make them accessible to the immune system. 1-2 watt of power will be sufficient to achieve these results with the Er:YAG. To avoid ther-

mal elevation by repeated applications, we recommend a frequency of approximately 20 Hz. Thus, the energy delivered upon each impact may be between 50 mJ and 100 mJ.

It is preferable to apply the laser beam in a continuous scanning motion inside and at the entrance of the periodontal pockets, moving towards the bottom. This motion will have three advantages:

- Limitation of possible thermal effects.
- Agitation of the water delivered to the inside of the periodontal pockets using the laser hand-piece.
- Maximisation of the treatment on all surfaces of the pocket by means of direct irradiation from the beam.

Conclusions

Periodontal maintenance after initial (surgical or non-surgical) periodontal therapy is an integral part of the periodontitis-management strategy; indeed, it could even be deemed to be essential. It consists of stabilising the periodontal balance between the microbial flora and the immune system established in the initial step. This objective can be only achieved through gentle, efficient and repeated application at a frequency that is adapted to the patient's needs. We have seen that there are a number of gaps in the range of conventional mechanical tools that are currently in use, although this is still somewhat efficient. Thanks to its physical and biological properties, the Er:YAG laser can be integrated into the currently used maintenance protocols.

In addition to its effectiveness on inflamed tissues and biofilms, the Er:YAG laser offers surgical comfort that is fundamental for the observance of periodontal maintenance treatment as already suggested by Sanz et al. in 2008 during the 6th European Workshop on Periodontology.

Fig. 9_Dr Fabrice Baudot working in his clinical practice.

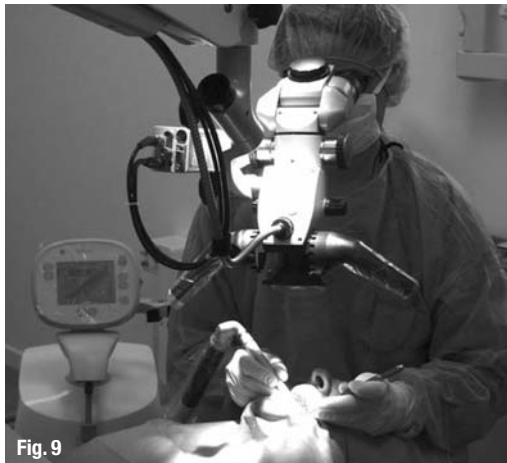
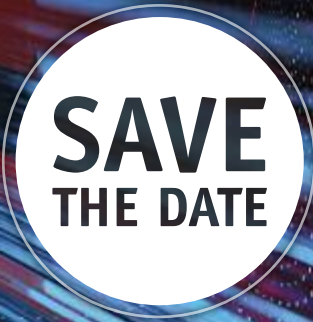
Fig. 9


_contact	laser
<p>Dr Fabrice Baudot Parodontologie et Implantologie 65, impasse des 3 pointes 34980 Saint Gély du Fesc</p> <p>fabrice.baudot@me.com</p>	



27. und 28. November 2015
in Berlin
Hotel Palace

24. JAHRESTAGUNG DER DGL

LASER START UP 2015



Impressionen
23. Jahrestagung der DGL
LASER START UP 2014

Programm anfordern!



Faxantwort
0341 48474-290

Bitte senden Sie mir das Programm zum/zur

LASER START UP 2015 24. JAHRESTAGUNG DER DGL

am 27. und 28. November 2015 in Berlin zu.

Name/E-Mail

Praxisstempel

LJ 8/14