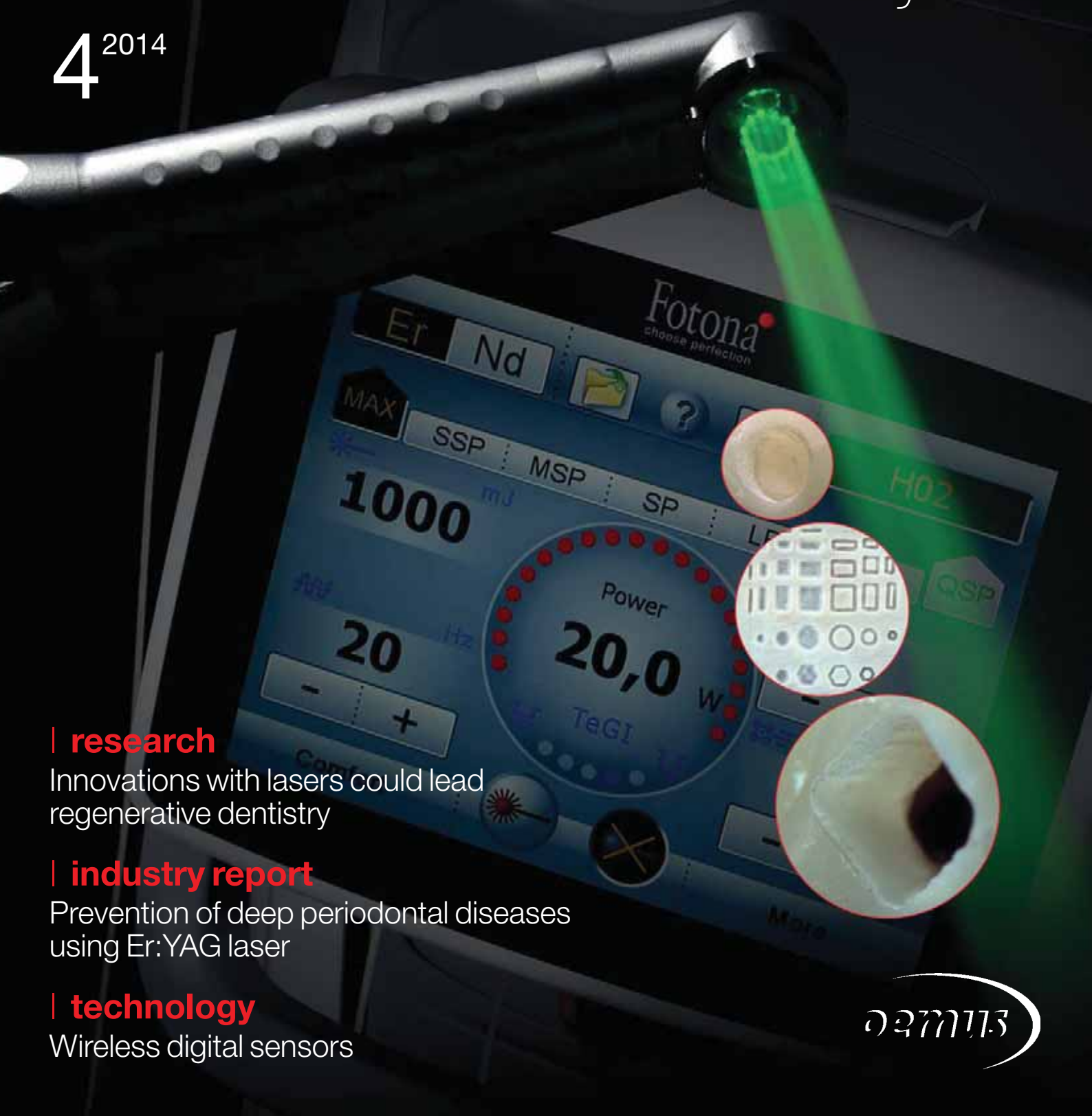

# laser

international magazine of laser dentistry

4<sup>2014</sup>



## | research

Innovations with lasers could lead regenerative dentistry

## | industry report

Prevention of deep periodontal diseases using Er:YAG laser

## | technology

Wireless digital sensors



# Master of Science (M.Sc.) in Lasers in Dentistry

Batch: EN2014 - Fulltime (new) or Module based

Next Start: **21<sup>st</sup> September 2015**

Aachen, Germany

4 semesters

## Become part of the International Dental Elite

- Create new economic potential for your practice
- Two year career-accompanying postgraduate programme at the University of Excellence RWTH Aachen
- Combination of lectures, skill training sessions, live ops, tutorials, and practical workshops
- Internationally accepted and accredited by the German Government, the European Union, the Washington Accord and the Bologna Process
- Science-based and practice-orientated on highest national and international level
- Increased patient satisfaction: minimal contact reduced vibration and pain



**RWTH INTERNATIONAL  
ACADEMY  
AACHEN UNIVERSITY**

RWTH International Academy  
Kackertstraße 10 | 52072 Aachen | Germany  
phone +49 241 80 23543 | fax +49 241 80 92525  
info@academy.rwth-aachen.de  
www.academy.rwth-aachen.de

**PROFESSIONAL EDUCATION PROGRAMMES**

**AALZ**

Aachen Dental Laser Center

AALZ GmbH  
Pauwelsstraße 17 | 52074 Aachen | Germany  
phone +49 241 47 57 13 10 | fax +49 241 47 57 13 29  
info@aalz.de  
www.aalz.de

# 2014 **Champion** year for **laser** comes to an end



Prof. Dr Norbert Gutknecht  
Editor-in-Chief

Dear colleagues,

Laser users and laser researchers have never had so many opportunities to attend congresses nationally and internationally as they have had this year. At these numerous events, established knowledge and clinical applications have been confirmed, and new research findings and clinical treatment protocols have been introduced. The increase in high-quality scientific publications has been exponential, demonstrating that the applications of laser technology in dentistry are being seriously explored.

For 2015, I would like to see similar developments in the area of evidence-based education worldwide, so that this valuable technology can be increasingly placed into the hands of responsible, well-trained colleagues.

I would like to thank our members and all other readers who have actively participated at congresses or attended conferences and training events in the field of laser for their commitment. I look forward to seeing you again at one of the various laser events in 2015.

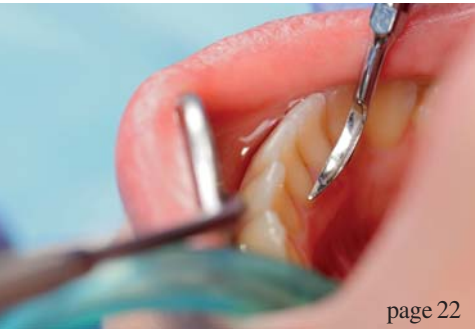Thus, it only remains for me to wish you a peaceful Christmas and a happy, prosperous and healthy New Year.

Yours sincerely,

A handwritten signature in black ink, which appears to read 'Norbert Gutknecht'.

Prof. Dr Norbert Gutknecht  
Editor and CEO WFLD





## | editorial

- 03 2014 **Champion** year for **laser** comes to an end  
| Prof. Dr Norbert Gutknecht

## | research

- 06 **Innovations** with **lasers** could lead **regenerative** dentistry  
| Praveen R. Arany
- 10 **Treatment** of vascular **lip** lesions with **laser**  
| Prof. Ass. Merita Bardhoshi *et al.*

## | industry report

- 14 **Prevention** of deep **periodontal** diseases using **Er:YAG** laser  
| Dr Fabrice Baudot
- 22 **Comparing** the **effects** of manual, **ultrasonic** & **Er:YAG** **laser** treatment  
| Dr Zulala Tasneem *et al.*

## | technology

- 26 **Wireless** **digital** sensors  
| George Freedman

## | economy

- 30 **Staying** ahead in **dentistry**  
| Simon Beeston *et al.*

- 34 **Gain power** at your **laser** clinics!

| Dr Anna Maria Yiannikos

- 36 **Regulatory** system for **medicines** can be **used** more **effectively**

| Escher

## | education

- 40 **Dental School** of Aristotle **University** enters **laser** family  
| Dr Dimitris Strakas

## | meetings

- 42 **Focus** on **laser**: Annual **Congress** of the **DGL** and **LASER START UP** 2014  
| Katrin Maiterth

## | news


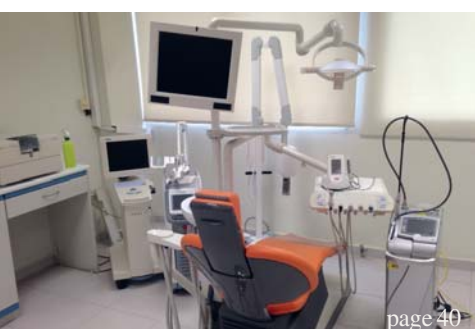
- 38 **Manufacturer** News
- 46 **News**

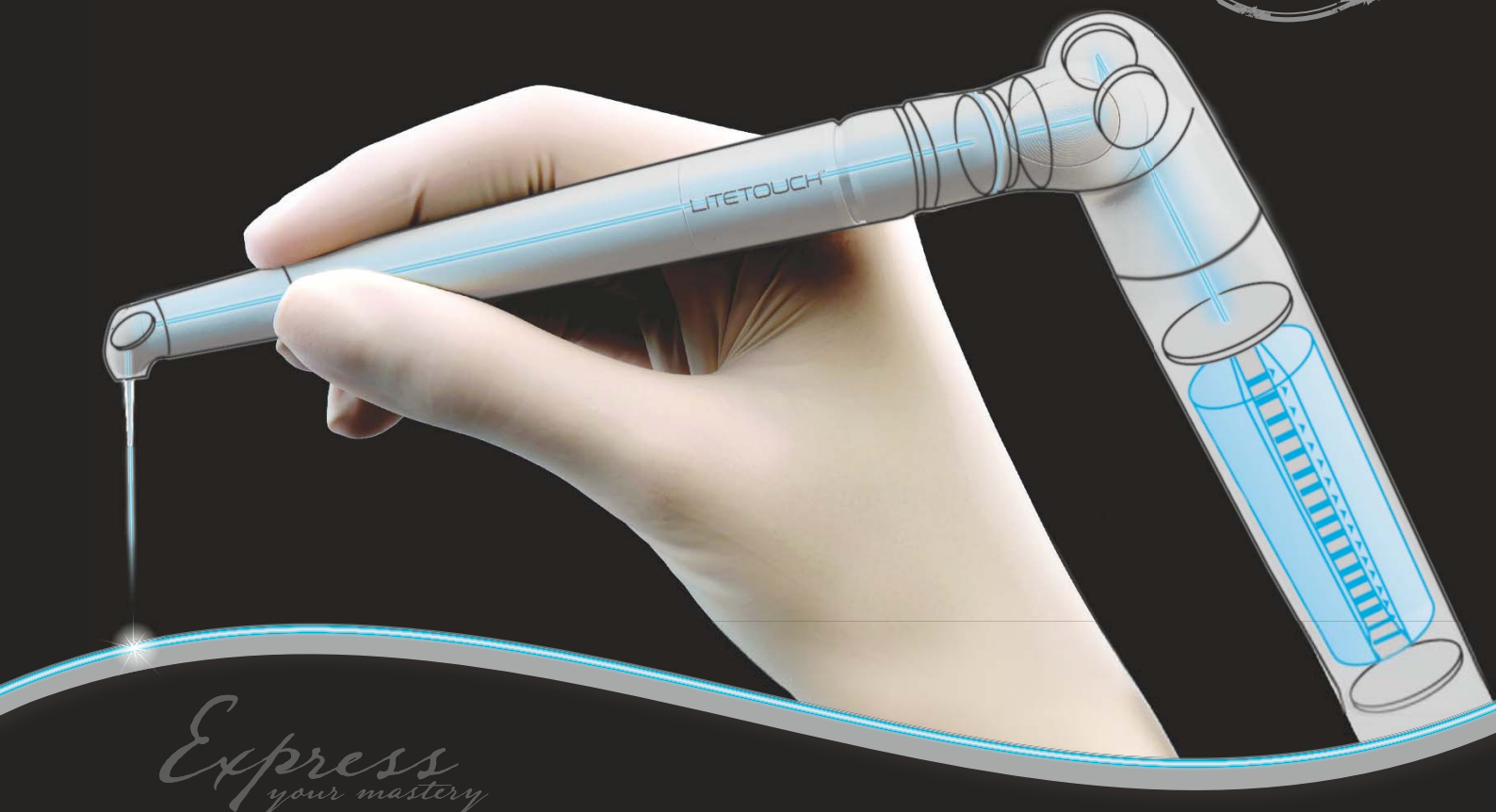
## | about the publisher

- 50 | imprint



Cover image courtesy of Fotona,  
[www.fotona.com](http://www.fotona.com)





*Express  
your mastery*

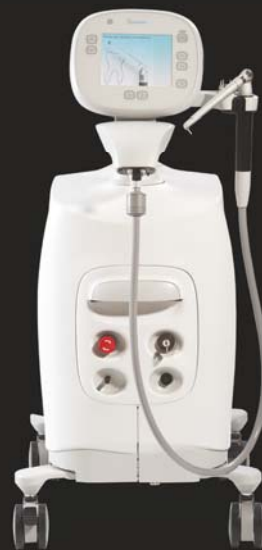Education. Technology. Family.

Join the Light Instruments Family

presenting

LITETOUGH™

The unique fiber-free Er:YAG laser  
that has changed the face of laser dentistry



LPB77693EN



Live presentations every hour at our booth 4L02AB during November 26-29, 2014  
At ADF International Exhibition, Palais des Congrès de Paris, Place de la Porte Maillot, Paris, France



Please reserve your personal consultation at  
[scdistribution@orange.fr](mailto:scdistribution@orange.fr) , [www.synerondental.fr](http://www.synerondental.fr)



# Innovations with lasers could lead regenerative dentistry

Author\_Praveen R. Arany, USA

**Fig. 1** The use of various wavelengths at different doses can be used for various clinical applications. The following acronyms are used in this figure PBM—Photobiomodulation; enPDT—Photodynamic therapy with endogenous chromophores and exPDT—Photodynamic therapy with exogenous chromophores (dyes).

With the upcoming year, 2015, being designated as the year of light, the acknowledgment for the key role of light in multitude areas of our very existence and more specifically, in areas of human health are being widely promulgated.<sup>1</sup> Many references to the beneficial effects of light and specifically sunlight are replete in the literature across ancient civilisations.

Notably, the ability of concentrated light radiation in the management of lupus vulgaris by Niels Ryberg Finsen received the Nobel Prize in Medicine and Physiology in 1903.<sup>2</sup> The all-pervasive nature of opto-photoelectronics in our current society is readily evident such as the simplest supermarket laser scanners and optical communications to precision medical lasers and more recent laser weapon

systems. This is also perhaps best highlighted by this year's Nobel Prize in Physics to the inventors of the blue light emitting diodes (LEDs), a simple invention with profound impact on our current society.<sup>3</sup>

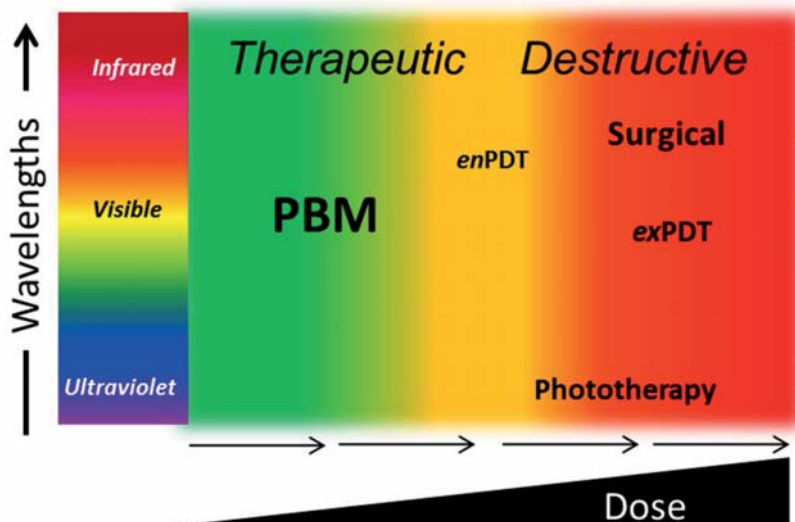
## Clinical laser application

Dentistry has historically been a leading clinical specialty in adoption of new technologies. Light has been a central part of clinical dentistry from evolutions of operating lights and fibre optic illuminations to light cured restorations and more recently, optical imaging. Although lasers were commercially available since 1960's, the first dental laser for hard tissue applications was approved by the US FDA in 1997. Adoption for high power soft tissue applications has always been popular in many medical fields such as surgery, oncology, dermatology and ophthalmology.

### First discoveries

Following the invention of this exciting new tool, early biological concerns focused around the safety of this new device with natural comparisons being drawn to ionizing forms of electromagnetic radiation. Among the early pioneering studies, Andre Mester reported a peculiar phenomenon—high doses destroyed tissue in a precise and predictable manner but very low doses produced a startling improvement in wound healing and promoted hair growth.<sup>4,5</sup> This was a surprising discovery on many accounts.

While high energy electromagnetic radiation, such as Gamma, X-rays and Ultraviolet, were able



to achieve significant linear energy transfer generating biological damage (nucleic acid strand breaks), the effects of visible (and later infra-red) lasers did not appear to fall within these routine biological responses (Fig. 1). With much excitement, these initial observations spurred many investigations for the use of low powered lasers and other light devices (including filter-based broad light sources and LEDs) in many clinical and lab research studies.

### Barriers in application

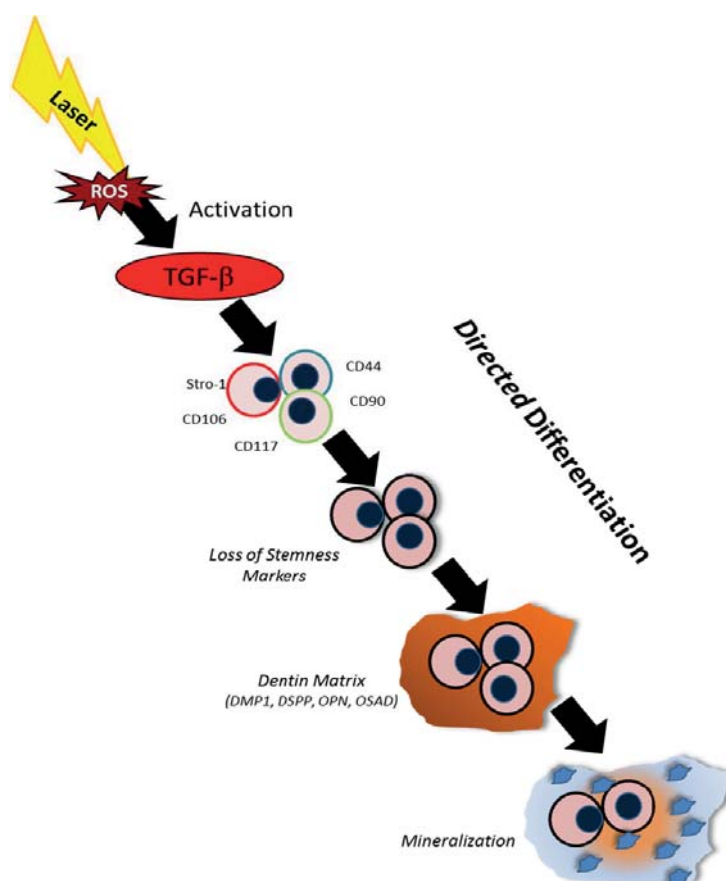
Unfortunately, a combination of the complexity of the early technology and a lack of understanding of its biological mechanisms has resulted in significant discrepancies in their reported therapeutic benefits. Hence, the lack of robust clinical efficacy has largely relegated the field to being side-lined as a pseudo-scientific and alternative medicine field. Current problems in the field from its basic terminology that prevents accurate indexing of the literature, to appropriate disease or biological response-specific clinical dose recommendations appear to be major barriers. Nonetheless, development of low power applications has also shown significant progress specifically in the areas of traumatic brain injury, post-traumatic stress disorders, reversal of methanol toxicity and wound healing.<sup>6-15</sup> In more recent years, mechanistic insights into light-biological tissue interactions have contributed to our better understanding for the therapeutic applications of laser therapy.<sup>16-18</sup>

### Defining photobiomodulation

Our operational definition for Photobiomodulation (PBM) is a form of phototherapy that utilises non-ionizing sources (including broad light, LEDs and Lasers) in the visible and infrared spectrum that result in therapeutic benefits such as alleviation of pain or inflammation, immunomodulation and promotion of wound healing and tissue regeneration. PBM is a non-thermal process involving photophysical and photochemical events at various length scales resulting in beneficial photobiological responses. Its clinical applications could be appended as PBM therapy.

### Study 1: Activating TGF- $\beta$ 1

Based on prior reports, we began studies in 1999 to establish the parameters of the near infrared laser to effectively promote oral wound healing at low doses (3 J/cm<sup>2</sup>, 10 mW/cm<sup>2</sup>, 5 minutes). We performed a thorough literature search to evaluate possible biological pathways involved in promoting wound healing. There appeared to be distinct correlations with reported use of exogenous TGF- $\beta$ 1 and laser treatments in wound healing.



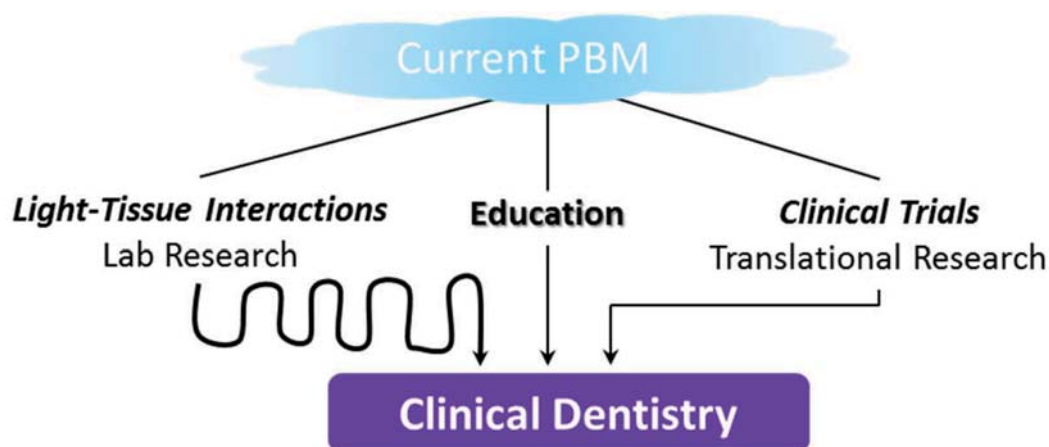
**Fig. 2** Therapeutic outline utilizing laser-generated ROS activated TGF- $\beta$ 1 to direct differentiation of dental stem cells and pre-odontoblasts to induce dentin matrix and subsequent mineralization.

Based on these observations, we assessed the laser-treated healing response of oral tissues for TGF- $\beta$ 1 expression and noted increased expression immediately post treatment and at 14 days.<sup>19</sup> The increase at 14 days correlated well with an increase in monocyte-macrophage influx, well-known cellular sources of TGF- $\beta$ 1. We next looked into the increased early expression of active TGF- $\beta$ 1 in these wounds. TGF- $\beta$ 1 is secreted as a latent growth factor complex when associated with a Latency Associated Peptide (LAP). The activation process involves dissociation of LAP from active TGF- $\beta$ 1 dimer that is well-documented with a wide range of physio-chemical modalities such as proteases, extreme pH, heat, ionizing radiation and integrin binding among others. The early wound has abundant latent TGF- $\beta$  from degranulating platelets present in the early wounds.

We observed low power laser treatments were capable of activating the latent TGF- $\beta$ 1 complex. To further pursue this observation mechanistically, we noted that near infra-red laser was capable of generating reactive oxygen species (ROS). This highly reactive, transient chemical intermediate was sensed by a key methionine residue on the latent TGF- $\beta$ 1 complex that resulted in a change in its conformation, resulting in its activation.<sup>20</sup>



**Fig. 3** Potential routes to move the field of PBM towards mainstream clinical dentistry. The wavy path from lab research to clinics is meant to reflect the multistep, tortuous basic science explorations in a wide range of topics that need to come together to aid in clinical translation.



## Study 2: Dentin regeneration

Having noted the effects of low power lasers on promoting oral mucosal wound healing in the prior study, we extended our clinical applications to dentin regeneration where TGF- $\beta$ 1 has been shown to play a pivotal role in dentin physiology.<sup>21-25</sup> We noted the ability of low power lasers to promote dentin regeneration using human dental stem cells. To validate these observations, rodent pre-odontoblasts (MDPC-23) cells grown in a polymeric scaffold, simulating a 3-D niche were treated with low power lasers.

Laser treatments were able to induce dentin differentiation as evident by increased dentin-specific matrix deposition and mineralisation. To confirm the role of TGF- $\beta$  *in vivo*, transgenic mice with lack of TGF- $\beta$  receptor in all cells capable of inducing dentin (utilising a Dentin Sialophosphoprotein specific transgene) were generated. Experiments in these mice did not demonstrate any significant dentin induction following laser treatment validating the critical role of TGF- $\beta$  activation in mediating its effects.

Previous studies have shown the therapeutic benefits of supplementing exogenous (recombinant) TGF- $\beta$  for reparative dentin, this study suggests the use of low power lasers can activate endogenous latent TGF- $\beta$ 1 present naturally in the pulp-dentin complex to drive differentiation of resident dental stem cells (Fig. 2). Thus, this therapy can utilise the inherent repair-regenerative responses naturally present in native tissues.

## Clinical Applications of Laser-Dentin induction

These observations have potent clinical implications where dentin would need to be therapeutically generated. The two directly relevant clinical

scenarios are for pulp capping following deep carious lesions and for dentin desensitisation. In the former case, removal of decayed or damaged tooth structure approximating the pulp (close to or clear exposure) that require the use of pulp capping agents (such as Calcium hydroxide) could be potentially replaced with low power laser treatments.

In the second scenario, the use of low power laser treatments on exposed dentinal tubules could potentially generate an intrinsic dentin barrier that would relieve tooth sensitivity. This would be more effective than our current approach to extrinsically occlude exposed tubules modes.

The two major limitations of the current study were that we noted calcifications interspersed throughout the pulp chamber, spatially distinct from the laser-biological tissue interface. We believe this is perhaps a combination of the inherent near-infrared laser wavelength that readily permeates throughout biological tissue as well as the soluble nature of the activated molecules. This could be potentially addressed by better optical focusing techniques and use of specific reagents that absorb the radiant energy and spatially restrict the biological interphase.

A second limitation in this study was the observation that laser-generated dentin was a tertiary or reparative form that lacks pristine tubular structure. It appears that additional cues both biophysical (architecture) and biochemical (soluble, organizational), are likely necessary to promote morpho-differentiation of the newly induced dentin.

In attempts to further explore these molecular mechanisms, we have more recently extended developed a polymeric scaffold system with precise morphogen fields.<sup>26</sup> Using this model, we were able to extend our observations with dental stem cells and laser-activated TGF- $\beta$ 1 mediated dentin dif-



ferentiation to mesenchymal stem cells suggesting this approach could have significant potential with other stem cell types as well.

## Conclusion

Both ROS and TGF- $\beta$  are central biological mediators in a wide range of biological responses.<sup>27-29</sup> The ability to selectively activate them in a spatio-temporally defined manner in vivo using low power lasers provides a significant clinical tool for various therapeutic interventions.

Questions on precise wavelengths, clinical protocol (delivery and dose ranges) and context of the pathophysiological response are all critical issues that need to be explored rigorously to enable further effective clinical translation of this therapy.<sup>30</sup> Further, the ability to effectively move this therapy into mainstream clinical dentistry will require more basic research, development of robust clinical standards and education at various levels (basic dental training and continued education) (Fig. 3).

In the current era of personalised medicine and strategies to utilise sophisticated technologies and pharmaceuticals to individualise health care, the significant promise of lasers in clinical dentistry may indeed be the leading, pivotal technology that ushers in the new era of regenerative dentistry.

## Acknowledgement

This work was supported by the intramural research program of the National Institute of Dental and Craniofacial research, National Institutes of the Health.

*Editorial note: A list of references is available from the publisher.*

## contact

## laser

### **Praveen R. Arany DDS, PhD**

Cell Regulation and Control Unit,  
National Institute of Dental and Craniofacial  
Research, National Institutes of Health

30 Convent Drive Room 3A-301,  
Bethesda MD 20892, USA

Tel.: +1 301 496 3561  
praveenarany@gmail.com

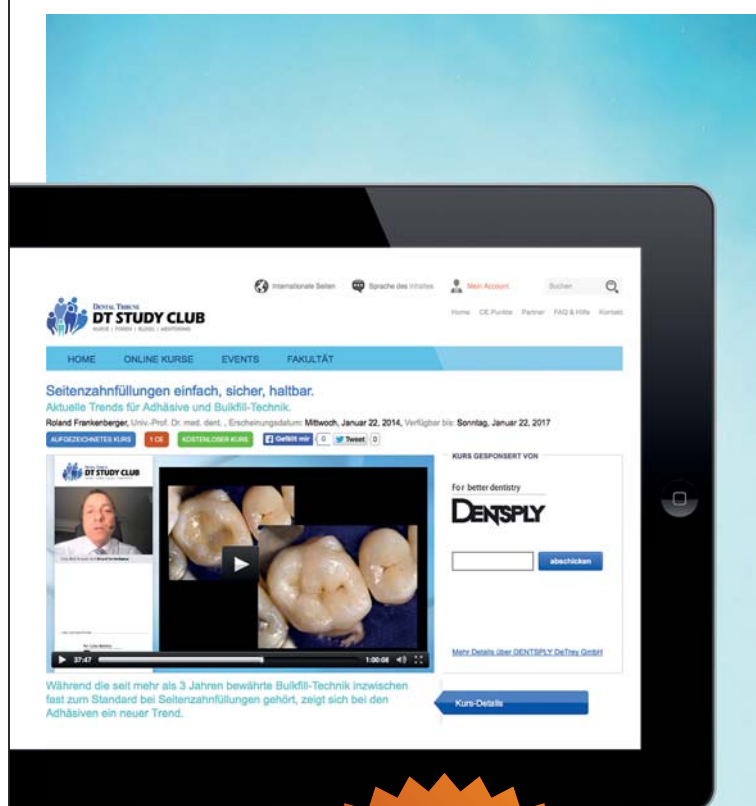
# Join the largest educational network in dentistry!

[www.DTStudyClub.com](http://www.DTStudyClub.com)



**DT STUDY CLUB**

COURSES | DISCUSSIONS | BLOGS | MENTORING



# Treatment of vascular lip lesions with laser

**Authors** Prof. Ass. Merita Bardhoshi, Prof. Dr Norbert Gutknecht, Prof. Ass. Edit Xhajanka, Dr Esat Bardhoshi, Dr Alketa Qafmolla, Dritan Gjini & Elda Gjini, Albania & Germany

[PICTURE: © VERYULISSA]

In 1982, Mulliken and Glowacki introduced a simple classification that was based on the clinical, histochemical and cellular criteria to distinguish between the various vascular anomalies (Genovese et al., 2010). They described two distinct entities—hemangiomas and vascular malformations. Acquired lesions may be traumatic or idiopathic in origin. Hemangiomas present with a variable morphology: Some are small and hardly noticeable whereas others are large and disfiguring. Hemangiomas that are flat and appear reddish are considered superficial. Those that are deep beneath the skin and appear bluish are called deep hemangiomas (Thurnherr et al., 2000). When a hemangioma is superficial and deep it is called "compound hemangioma".

The correct diagnosis is critical for a proper treatment than. Vascular malformations are always present at birth though some may not be apparent until a later stage. Furthermore, they never proliferate or involute. Instead they expand slowly and relentlessly throughout life, in pace with the growth of the patient. Thereby, trauma, puberty and pregnancy can cause an accelerated growth. These lesions are sub-classified according to the predominant type of the vessel and the characteristics of flow like capillary malformation, venous malformation and arteriovenous malformation. Initially, they

present as flat pink macules and are usually soft, compressible and enlarge in size when venous pressure is increased.

Some lesions such as venous lakes and varicosities are part of the normal ageing process. The congenital anomalies may be further subdivided according to the vessel type. They can be situated in different areas of the oromaxillofacial region: tongue, lips, palate, buccal mucosa or gingiva (Romanos, 2012). One option of managing these lesions is the application of laser. Because of the aesthetic importance of the lips, the discrete anatomic borders such as the vermillion border and their functional importance, laser treatment in this region has some important benefits (Romanos, 2012). Several laser systems have been developed using principles of selective photothermolysis (DeBiase et al., 2006). The targeted chromophore in case of a vascular lesion is oxyhemoglobin present in the red blood corpuscles which circulate in the blood vessels. Laser therapy is a good method to treat such a lesion. Among different laser systems, we choose the application of a 980 nm diode laser for the management of a vascular lip lesion since the wavelength of 980 nm is well absorbed by haemoglobin. This characteristic makes it possible to achieve a very good coagulation and haemostasis that is very important for treating vascular lesions.



## **\_Patients and methods**

### *Patients*

This study comprised 60 patients (32 males and 28 females) aged 10 to 80 years treated for vascular lesions of the lip (Figs. 1–3). The research protocol was performed in two groups: The first group with 30 patients was treated with a 980 nm diode laser whereas the second group, the control group with 30 patients, was treated with a cold scalpel. The treatment was conducted from May 2007 to May 2012 at the Department of Oral Surgery, Dental Clinic of the University of Tirana, Albania. All pa-

tients were provided with clinical files. In the laser group, 20 patients were medically free and 10 were compromised (each 3 patients with diabetic and cardiopathy and 4 patients under anticoagulant therapy). In the control group, 18 patients were medically free and 12 were compromised (each 4 patients with diabetic, cardiopathy and under coagulant therapy).

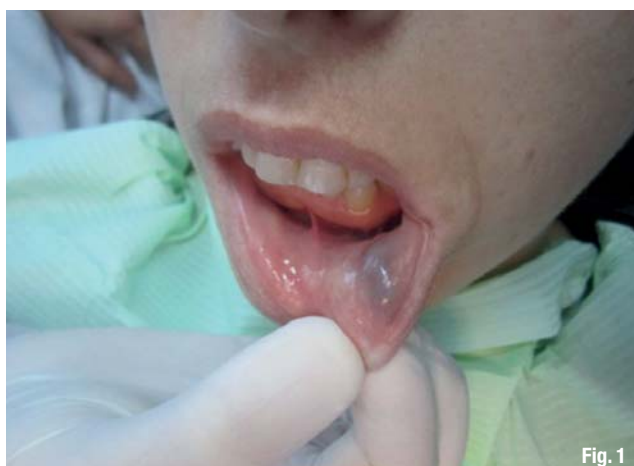In all patients, the lesions were considered to be vascular lesions based on their medical history, age, thorough extra- and intraoral examination and findings of ultrasonography. All patients were given written and verbal information on the nature of laser treatment and were asked to sign informed consent forms prior to the treatment. The follow-up periods were defined one month, six months, one year and three years after treatment in order to evaluate the characteristics of wound healing as early and long term results. All stages of treatment and follow-ups are photographically documented for a comparative long-term evaluation.

### *Method*

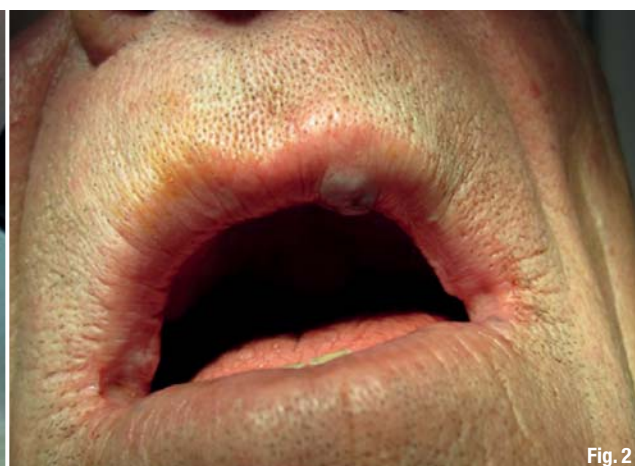Treatments were performed on an outpatient basis under local anaesthesia. For the laser group a 980 nm diode laser was used. The laser energy was delivered through a fibre optic with a gauge of 300 micrometre and an average power of 3 W in a continuous mode from 10 to 60 seconds according to the size of the lesion in contact and non-contact mode. The laser tip was placed in a non-contact mode 2 mm away from the treated area.

The actual treatment started with working around the border of each lesion by circling around it several times all in one direction. Changes in colour and visible shrinkage were taken as signals for the end point of the treatment, until blanching of the treated area and photocoagulation was completed. In the contact mode, the fibre was in contact with the mucosal surface of the lesion using gentle

**Figs. 1–3** Vascular lip lesions.



**Fig. 1**



**Fig. 2**



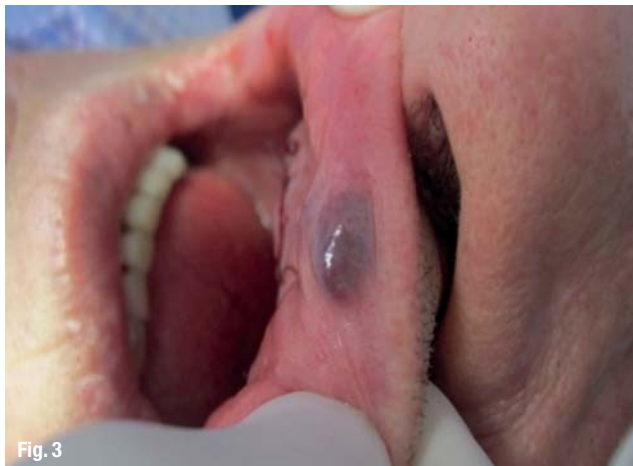

Fig. 3

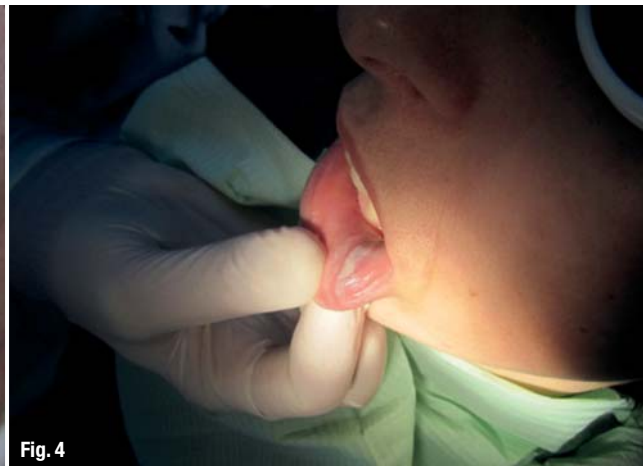


Fig. 4

**Fig. 4\_** The treated surgical area was bloodless and the intralesional photocoagulation was completed.

pressure. It was extended into the substance of vascular lesion to the periphery for such passes are required.

The treated surgical area was bloodless and the intralesional photocoagulation was completed (Fig. 4). The treated areas were iced for 3 to 5 minutes. After treatment (Fig. 5), an analgesic medication was prescribed to be used if necessary—no antibiotics were given. Instructions for post-surgical behaviour treatment consisted of an ice compress for 2 hours, abstention of warm food and drinks intake, placement of a vitamin E ointment on the lased area and avoidance of sun exposure for one month.

The patients of the control group were treated with conventional removal techniques by means of blades. Excision as surgical technique was performed to fully enucleate the lesion and the wounds were sutured. Antibiotics were prescribed for all patients—those patients who were under anticoagulant therapy had interrupted their therapy prior to the surgery. The follow-up visits for the research protocol for both groups (laser and control group) were scheduled in intervals of 10 days, one month, six months, one year and three years after treatment. Hereby, pain, bleeding, swelling, scar forma-

tion, functional disturbance, aesthetic result, recurrence as well as wound healing characteristics were evaluated.

## Results

In this study, according to the research protocol the results from two groups were compared. The first one was a group of 30 patients with different vascular lip lesions treated with 980 nm diode laser (Sirona Dental Lasers). A second group considered as the control group was treated with conventional surgical blade techniques. The results were evaluated as early and long-term results. The patients of the laser group were treated in one session. In this study, a case with a vascular lesion of the entire lower lip was included in which different sections were treated in five sessions.

Another special case within the laser group was a patient with a vascular lesion at the lower and upper lip which was treated in different sessions with a distance of 2–3 weeks each. The surgery time for the laser group was very short—for the benefit of the patients. Furthermore, no sutures were required and the wounds healed in two or three weeks depending on the lesion size. During the wound healing, none of the patients reported complications, which also included the compromised patients. In contrast, 3 to 30 patients of the control group showed delay times in the wound healing due to local problems particularly among the compromised patients. The parameters evaluated are the following:

### Bleeding

Bleeding during the surgical removal of vascular lesions can be considered a typical feature of such treatments. During the laser treatment, no bleeding was observed in all patients. In the control group, after the excision with scalpel a prolonged packing was needed and sutures were used to close the surgical wound.

**Fig. 5\_** Immediately after the treatment.

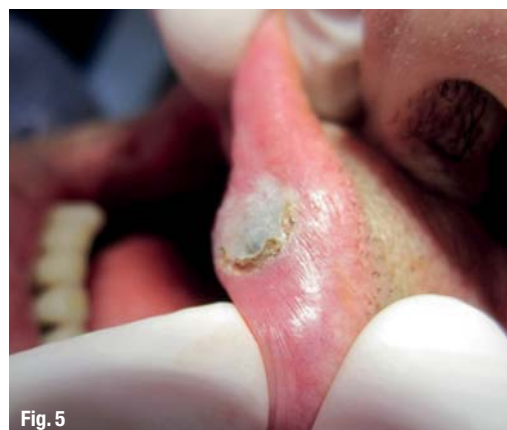

Fig. 5



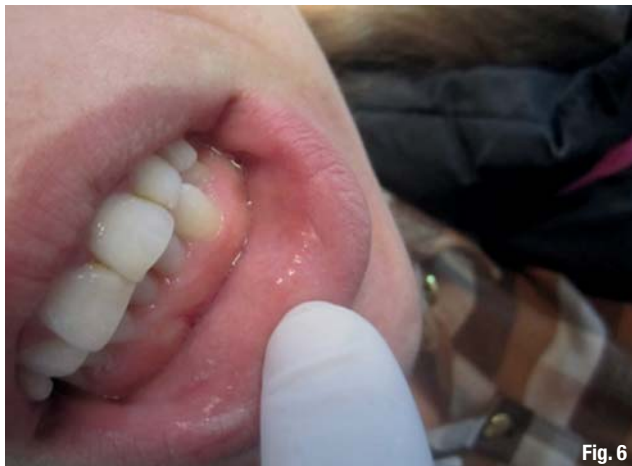

Fig. 6

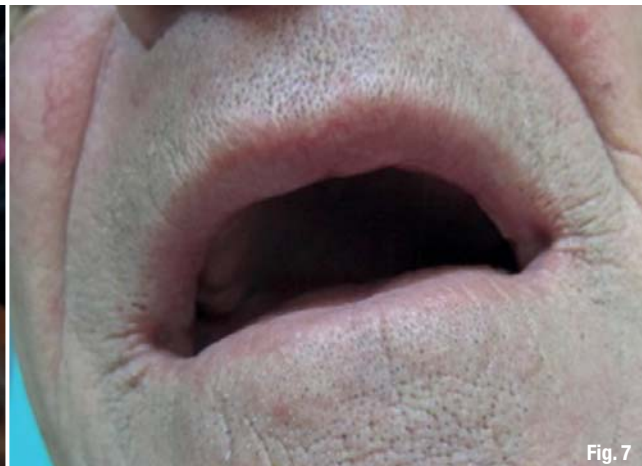

Fig. 7

### *Pain*

The second parameter evaluated was the pain post-surgery. Out of 30 patients treated with laser only one patient reported pain after the effect of local anaesthesia had stopped. The other patients had an optimal post-surgical comfort and did not refer pain at all. Among the patients treated with conventional blade surgery 22 out of 30 (70 per cent of the patients) referred pain which was solved with analgesic drugs for some days.

### *Swelling*

Another parameter evaluated in the follow-up visits during the first week after treatment was swelling. None of the patients treated with laser reported swelling. In contrast, 20 patients out of 30 (66 per cent of the patients) from the control group referred swelling in the first week after the surgical excision.

### *Scarring*

A common problem related to lip lesions is scar formation. Scar formation was evaluated within the control visit one month after the treatment. In all patients treated with a 980 nm diode laser scar formation was not observed (Figs. 6 & 7) whereas in all patients treated with conventional blade surgery scar formation was observed on the site of the performed excision.

### *Functional disturbance*

The parameter functional disturbance was evaluated six months after the treatment. For the laser group, no functional disturbance was recorded and the lip looked normal in colour and consistence. In contrast, in the control group 6 cases out of 30 (20 per cent of the patients) reported a functional disturbance.

### *Recurrence*

Recurrence was evaluated as long term result in the follow-ups one year, two years and three years

after the treatment. According to the clinical data reported by patients treated with laser, no recurrences were observed. In the control group only one case reported recurrence of the lesion during the first year after the excision.

## **Conclusion**

The clinical application of a 980 nm diode laser for the management of vascular lesions of the lip has some beneficial effects due to the good absorption of haemoglobin. Laser treatment versus scalpel surgery provides minimal invasive and minimal aesthetic results. Compared to the patients treated with conventional methods, the laser treated patients felt more comfortable in the post-operative phase due to less pain and swelling. Patients under anticoagulant therapy were treated without substitution prior to laser surgery. During the treatment, there was no bleeding in this patient group. The laser application was performed comparatively fast and was also well-accepted in all age groups. The surgically lased wounds healed within a short time without scar formation and functional disturbance.

**Figs. 6 & 7** Four weeks after the treatment with 980 diode laser. Wound healing was completed without scarring.

### **\_contact**

### **laser**

**Prof. Ass. Merita Bardhoshi**

Medicine University  
Department of Oral Surgery  
Dibra Street 63, Tirana, Albania

Tel.: +355 674150102

Fax: +355 42253675

meritabardhoshi@yahoo.com

# Prevention of deep periodontal diseases using Er:YAG laser

Author\_Dr Fabrice Baudot, France

**Periodontal maintenance is an integral part of successful periodontal therapy** (Axelsson & Lindhe, 1981). The objective is to stabilise the microbial balance restored after an initial periodontal therapy (Kornman, 1997). A systematic surgical approach following an initial therapy is no longer necessary as it is with standard treatment (Heitz-Mayfield, 2005). Over the past few years, periodontics has been shifting towards a non-invasive or non-surgical approach to access the deep cleaning of the periodontium, as part of the development of all medical surgical techniques in general.

Non-surgical procedures, most respectful non-surgical periodontal tissue protocols have proven to be efficient (Badersten & Egelberg, 1990, 1987, 1985, 1984, 1981), but force us to leave risky sites that can be difficult to manage in periodontal maintenance (Cobb, 2002; Becker et al.). Root furcation defects and residual periodontal pockets deeper than 4 mm are the daily reality faced by periodontists and hygienists responsible for their patients' maintenances.

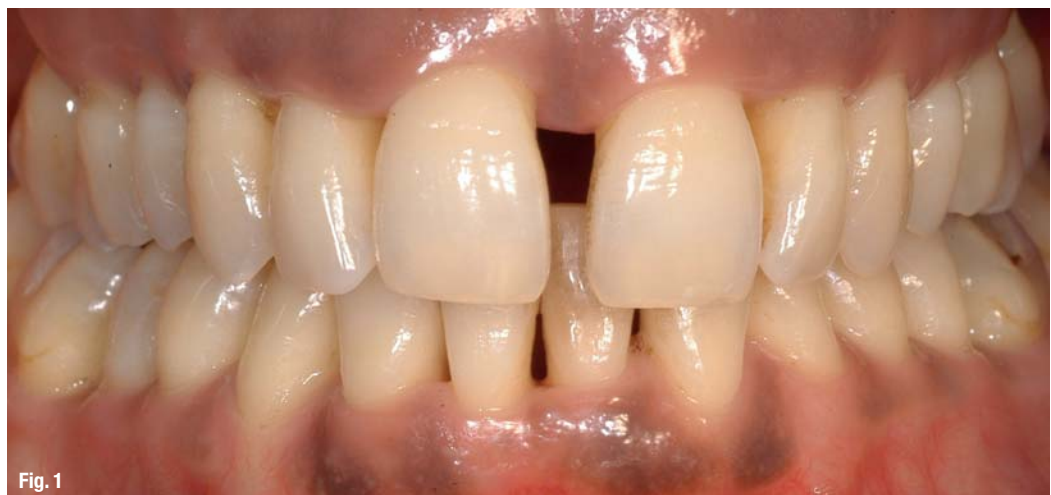By means of a literature review of the physical and biological properties of the Er:YAG laser, we would like to demonstrate the relevance this device may have as a preventive tool in maintenance procedures on at-risk periodontal sites (Fig. 1).

## Aetiology and diagnosis of periodontal disease

Periodontitis is an inflammatory disease affecting the periodontium. The inflammation arises as a result of imbalance between the oral microbial flora and defence system of the host (Kornman, 1997). Microbial involvement is a major factor in the development of the disease, but other risk factors including but not limited to smoking, stress and genetic predisposition contribute to the aetiology of periodontitis (Genco et al., 2013). For the sake of simplicity, we can distinguish between two variants of periodontitis (Page, 1997):

1) Aggressive periodontitis (Figs. 2a & b), which occurs before the age of 45.

**Fig. 1** Clinical situation following initial therapy. Some deep pockets need long-term care.



**Fig. 1**

2) Chronic periodontitis (Figs. 3a & b), which develops after the age of 45.

Major risk factors associated with chronic periodontitis include bacteria and tartar. General risk factors such as diabetes, smoking or others also aggravate the disease. Local risk factors do not play a major role regarding aggressive periodontitis; a periodontal imbalance seems to be related primarily to general risk factors.

In both cases, the imbalance results in an inflammatory reaction, rendering the periodontium porous to microbes. Subsequently, the polymicrobial flora becomes embedded in the biofilm and invades the deep periodontium and even the inner tissue, leading to the destruction of the periodontium. The origin of periodontal destruction seems to be more related to the inflammatory reaction than to the microbial flora (Barthold, 2010).

The radiography of both clinical situations depicts an advanced stage of the disease, with similar skeletal deterioration. These two cases differ primarily in terms of the patient's age, which is 25 in the case of an aggressive periodontitis (Figs. 2a & b) and 68 years in that of a chronic periodontitis (Figs. 3a & b).

### Periodontitis treatment protocols

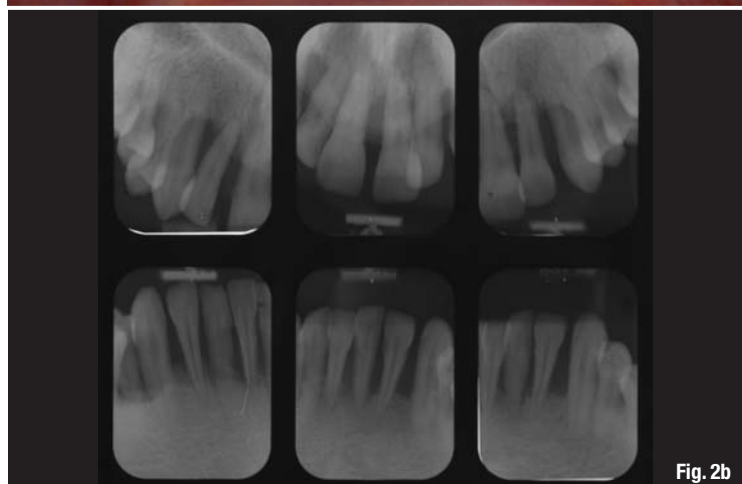
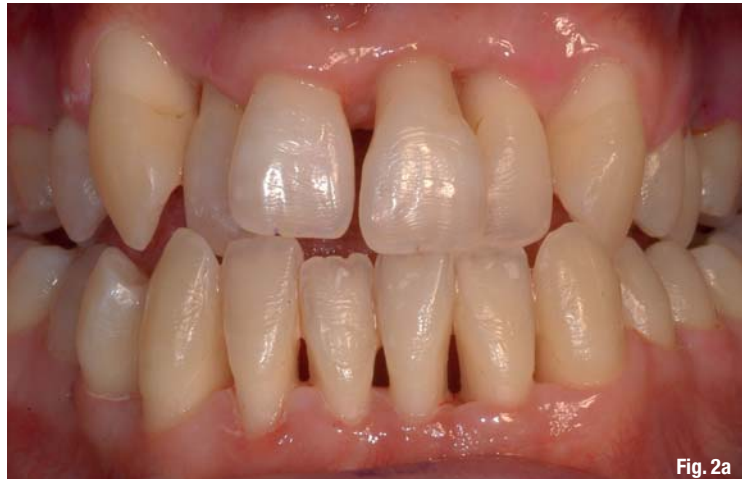Treating periodontitis involves the restoration of the periodontal balance. The key instrument used here is infection-control through the reduction and modification of the microbial mass. The elimination of inflamed tissue helps to trigger the periodontal healing process (Lindhe & Nyman, 1985). The treatment strategy consists in encouraging the immune system to fight the microbial flora by destabilising the significant protective biofilms in which they are hosted (Sanz & Van Winkelhoff, 2011, 7<sup>th</sup> European Workshop).

Today, the widely accepted treatment protocols for periodontitis are centred on two phases (Dentino, 2013):

- 1) An initial treatment that serves to control the infection, reduces inflammation and restores the periodontal homeostasis.
- 2) Periodontal maintenance treatment or supportive therapy. This phase focuses on the maintenance of the periodontal balance achieved during the initial therapy in the longer term.

Several initial treatment protocols have been described in the literature (Lindhe & Nyman, 1985):

- Surgical protocol: The use of "blind" scaling and root planning, which is aimed at controlling the in-



fection and reducing inflammation. This first step is followed by periodontal surgery for the purposes of decontaminating the four sites and eliminating residual periodontal pockets: the Widman Flap (Ramfjord & Nissle, 1974).

- Non-surgical protocol: This protocol preserves the periodontal tissues more effectively. It consists of only one scaling and root planning without access flap to decontaminate the periodontium. Residual pockets are numerous and are controlled as part of a strict maintenance programme (Badersten & Egelberg, 1984).
- Minimally invasive periodontal regenerative surgery (Cortellini & Tonetti, 2007): Here, the periodontium is cleaned up to a surgical level but without an access flap. Special therapeutic means such as optical aids and lasers can also improve these non-invasive procedures. A surgical technique inspired by the Canadian University of Public Administration ENAP published in 1976 by Yukna allows patients to benefit from the surgical approach and non-surgical techniques without suffering the disadvantages.

Periodontics follows the preferred route taken in medicine which is minimum intervention. This is one

**Figs. 2a & b** Aggressive periodontitis and pre-operative radiography.

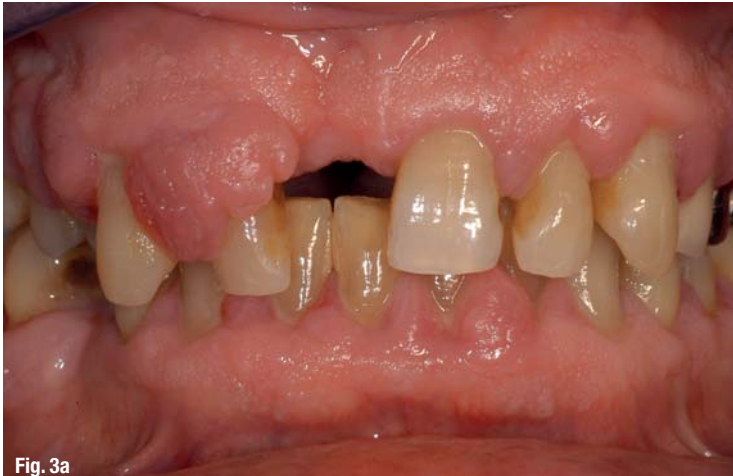

Fig. 3a

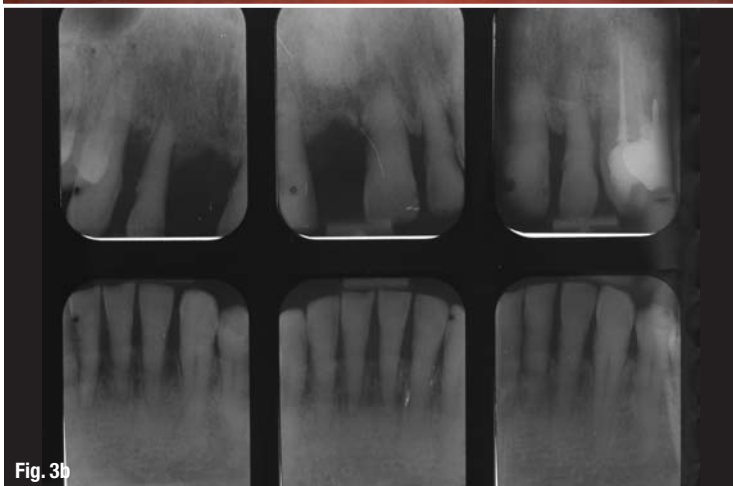

Fig. 3b

**Fig. 3a & b** Chronic periodontitis and pre-operative radiography.

of the reasons why non-surgical and minimally invasive techniques have been developed within the field. The surgical approach is long, highly invasive and does not shy away from a strict maintenance protocol to prevent recurrence (Badersten, 1984; Teles, 2012; Westfelt et al. 1983; Lindhe & Nyman, 1984; Harper & Robinson, 1987; van Winkelhoff et al., 1988; Renvert et al., 1990a; Shiloah & Patters, 1996).

Within cases of periodontitis, the heart of the problem is related to microbial and immunological factors. Periodontal maintenance is intended to stabilise the balance recovered through initial therapy, regardless of the initial protocol used (Ebersole, 2013).

In view of the biological consequences, the risk-benefit ratio of performing invasive surgery does not seem favourable today (Heitz-Mayfield & Lang, 2013; Walsh & Waite, 1978; Badersten et al., 1984a, 1984b; Leon & Vogel, 1987; Oosterwaal et al., 1987; Cobb, 1996). Our knowledge of microbiology and immunology has evolved, as have the technical platforms use. This also enables us to offer alternative therapies for the treatment of periodontitis. The Er:YAG laser may be central to this strategy (Figs. 4–6).

## Physical and biological properties of the Er:YAG laser

Er:YAG is a laser that emits radiation at a wavelength of 2,940 nm (Robertson, 1971). At this wavelength, one of the physical properties of the energy emitted is that it has double the peak absorption in water and hydroxyapatite (Ishikawa, 2004). This is a fundamental property that distinguishes Er:YAG from other lasers used in dentistry and singles-out as the wavelength of choice in non-surgical periodontal debridement applications (Schwarz et al., 2008).

### Photothermal properties

Due to very strong water absorption, the Er:YAG laser has a therapeutic effect at low energy levels and limits the thermal effects on tissue adjacent to the targeted areas. Tissues subjected to Er:YAG radiation are vaporised by means of a huge increase in temperature upon impact, which is instantly reduced to a great extent by massive water absorption (Aoki, 1994; Eberhard, 2003; Schwarz, 2003). Clinically, this effect is manifested in the form of a micro-tissue ablation on a few microns of material (Walsh, 1989).

### Photomechanical properties

These properties are as follows:

- Shockwave: the emission of laser radiation causes a shock wave at each impact.
- When radiation is emitted in a hydrated solution, the energy released in the water molecules produces multiple micro-explosions that allow for a deep agitation of the solution (Roca, ongoing study).

### Biological effects of the Er:YAG laser

The physical properties of the Er:YAG laser have anti-inflammatory and antiseptic effects, which are highly useful in periodontal therapy. Periodontal tissues are not homogeneous in terms of water load. They can be characterised by a gradient of water load. The water load in the cement is higher than that in the bone, which is in turn lower than that in the ligament and gum or inflamed tissue.

The photothermal properties of the Er:YAG laser allow the tissue to be vaporised in accordance with its water load. The Er:YAG laser has proven to be a very effective and selective micro-surgical tool in situations where there is a decreasing water load gradient (soft tissue vs. hard tissue), since the laser eliminates the most hydrated tissue while preserving the surrounding, less hydrated tissues.

### Antiseptic effects

The photothermal and photomechanical properties of the Er:YAG laser have antiseptic effects. Bacte-



rial biofilms are highly hydrated gels in which bacteria live and grow (Marsh & Bradshaw, 1995). Due to their very nature, they perfectly absorb the energy emitted by the Er:YAG laser. Where they are directly exposed to Er:YAG radiation, vaporisation will target primarily the biofilms and bacteria with the highest water load in periodontal pockets.

Although no vaporisation occurs in deep layers or areas where radiation is attenuated, biofilms will be destabilised in these areas. Bacteria will be rendered soluble and therefore are accessible to the immune defence system, which can then help to restore the periodontal balance (Marsh, 2011).

The photomechanical properties also produce antiseptic effects by helping to destabilise microbial biofilms within the periodontal pockets. Two photomechanical mechanisms produce this kind of effect: the shockwave generated by the radiation and the micro-explosions of the molecules. These two phenomena agitate the solutions and give the radiation antiseptic properties, as observed in clinical applications of the Er:YAG laser in endodontics (Roca, ongoing study).

Agitation of irrigation solutions is more intense and more rapid when using an Er:YAG laser than it is when using ultrasonic tools. The propagation of the shock wave is highly effective in the agitation of irrigation solutions in hard-to-reach areas (side ducts, intra-ductal isthmus). In drawing a parallel with periodontics, we see the potential relevance of the Er:YAG laser with regard to antiseptic action in areas such as furcations or deep periodontal pockets, which cannot be accessed easily using conventional means.

#### *Anti-inflammatory effects*

These effects are the result of a selective micro-tissue ablation associated with the direct irradiation of inflamed tissue using an Er:YAG laser. Here too, the decreasing water load gradient between the inflamed tissue and the adjacent and underlying structures allows for selective vaporisation: The inflamed tissues are eliminated. The laser energy is highly reduced upon reaching the healthy tissue, which helps to preserve the latter. This mechanism allows the Er:YAG laser to have an instant, powerful anti-inflammatory effect (Dominguez et al., 2010). In periodontal pockets, radiation acts as an ultra-precise optical curette.

### **Therapeutic benefits of the Er:YAG laser in periodontics**

As we have already seen, the therapeutic strategy for periodontal treatment is aimed at restoring and

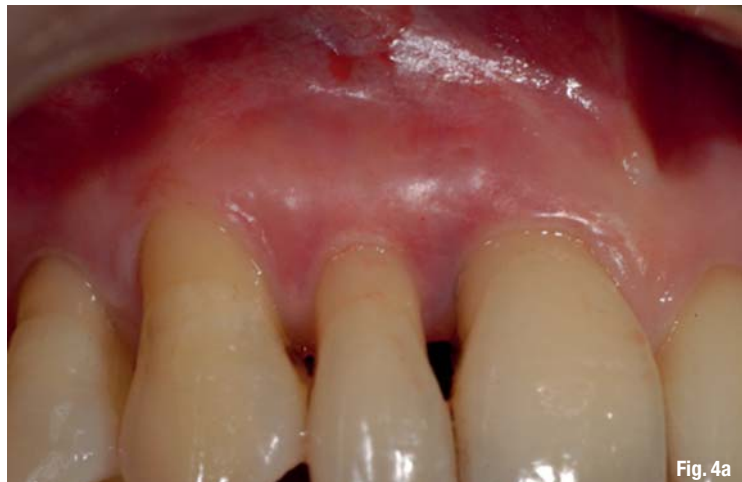

Fig. 4a

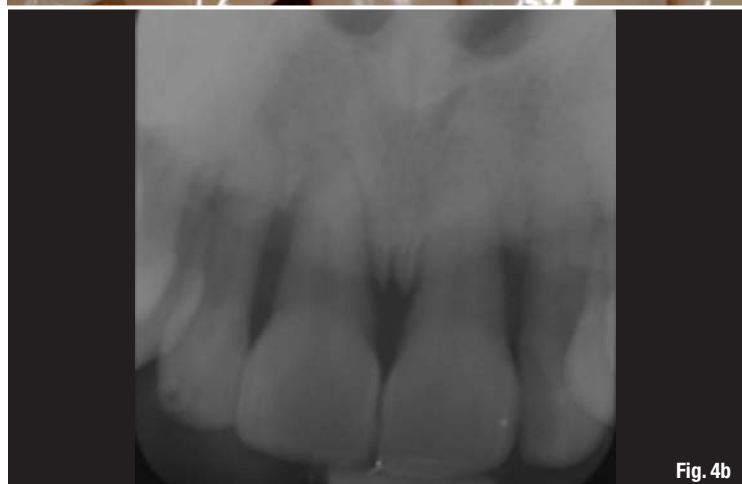

Fig. 4b

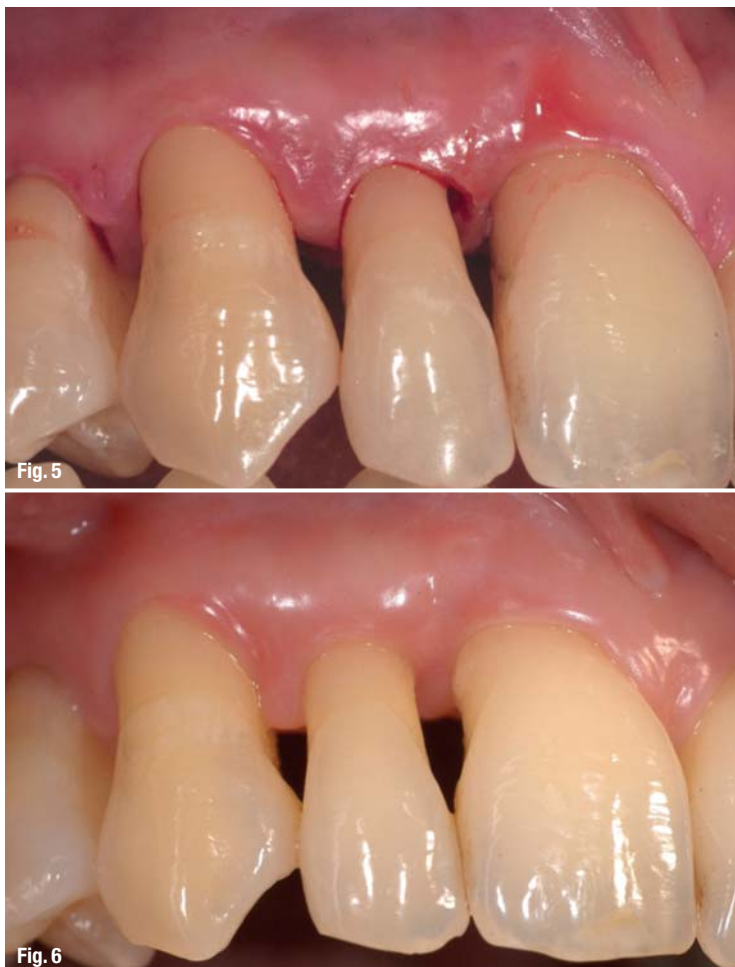maintaining the balance between the immune system and the periodontal micro flora. By its antiseptic and anti-inflammatory properties, the Er:YAG laser seems like an interesting tool that can be integrated with the existing therapeutic arsenal. We can design its use in the initial periodontal therapy and periodontal maintenance. When compared to the mechanical instrumentation in a non-surgical periodontal debridement, the Er:YAG laser achieves better results in the short and long term (24 months) of chronic periodontitis (Schwarz, Aoki et al., 2008).

#### *Er:YAG laser in initial periodontal treatment*

The Er:YAG laser can be used to complement or even replace conventional tools in surgical or non-surgical periodontal decontamination procedures. As we have already seen, its biological effects enable it to act as a highly selective and therefore highly accurate optical curette that meets non-invasive intervention criteria to remove inflamed tissue. Its antiseptic action is used to clean root and bone surfaces by direct exposure to laser radiation (Yoshino, 2009).

The ergonomic design of the optic-fibre makes it a very fine tool that can be used to deliver treatment in areas that are often inaccessible to conventional

**Figs. 4a & b** Clinical situation and pre-operative radiography of an aggressive periodontitis.



**Fig. 5** Micro-surgical intervention by use of Er:YAG laser.

**Fig. 6** Two-month postoperative result. Note the stability of the periodontal tissue.

tools (Sahar-Helft & Stabholtz 2013). Due to photo-mechanical phenomena processes (micro-explosions and agitation of solutions by shockwave) the antiseptic effect of the Er:YAG laser is shown and affect areas beyond those that are accessible by direct radiation. The Er:YAG laser is a real surgical tool, but due to its extreme precision it reaches its full potential when used in minimally invasive or non-surgical interventions to promote healing (Schwarz, 2007).

#### *Er:YAG laser in periodontal maintenance*

Despite the interesting properties outlined above, in the literature the Er:YAG laser is not significantly distinguished from conventional tools with regard to therapeutic effectiveness and intervention times in periodontal maintenance procedures: The effects are similar (Tomassi, 2006; Derdilopoulou, 2007; Sculean, 2004). In contrast, Braun et al. (2010), who compared the Er:YAG laser with sonic tools used in periodontal maintenance, have clearly shown that the pain experienced by patients during maintenance sessions using the Er:YAG laser was less significant compared to conventional sonic tools. The use of an Er:YAG laser in periodontal maintenance is more comfortable for the patient than conventional tools, as already anticipated by Tomassi et al. in 2006.

In the literature currently available, the Er:YAG laser has been tested on shallow pockets only (4–6 mm maximum) in periodontal maintenance. It would be interesting to test this laser in maintenance procedures that include periodontal pockets larger than 6 mm and compare the laser with manual tools. The therapeutic properties of the Er:YAG laser offer minimally invasive surgical efficiency, particularly in inaccessible areas (Eberhard, 2003). In comparison, significant limitations are associated with the use of manual instrumentations in these hard-to-reach areas to ensure periodontal maintenance (Matuliene & Lang, 2008).

The Er:YAG laser should allow a more effective control of biofilms in furcations and in periodontal pockets larger than 6 mm. The treatment of periodontal surfaces using the Er:YAG laser promotes periodontal healing. Fibroblast attachment on root surfaces that is treated by using an Er:YAG laser is higher than those treated by using traditional sonic tools (Schwarz, 2003; Crespi et al., 2006).

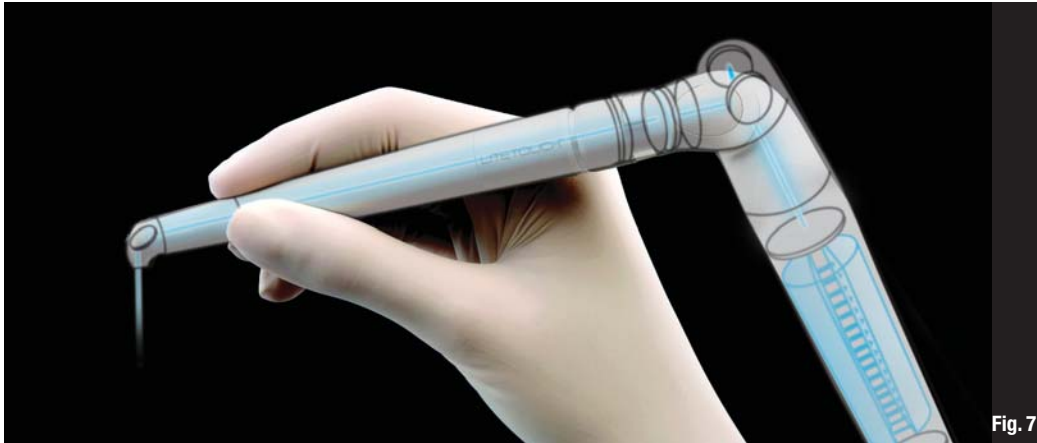#### *Alternative to local antibiotics*

The local application of antibiotic gels has generated much interest since it allows significant local concentrations of active ingredients to be achieved in periodontal pockets (Ciancio, 1995). However, the problems of a possible resistance and side effects caused by the repeated use of these products still remain. Applying clinical doses of antibiotics to extra-periodontal sites such as the tongue or the tonsils may induce resistance in the bacterial flora (Roberts, 2002).

The bactericidal effects of the Er:YAG laser are likely to make it a beneficial alternative to these medicines. In any case, even though the topical application of antiseptic or antibiotic molecules is a useful therapeutic method (Quang et al., 2002), the destruction of significant biofilms and solubilisation of micro-organisms made possible by the use of an Er:YAG laser can only be beneficial in potentiating this treatment strategy.

#### **Er:YAG laser in periodontal maintenance protocols**

As we have already seen, the Er:YAG laser has a significant and effective impact, identical to that of conventional instrumentations, when used in the initial periodontal decontamination therapy. Its photomechanical properties and the ergonomic design allow for a minimally invasive treatment. Therefore, the Er:YAG laser can be integrated into periodontal maintenance treatments as a preventive tool for deep sites that are inaccessible to conventional tools.



**Fig. 7** LiteTouch Er:YAG, "Laser-in-the-Handpiece".

Mousques et al. (1980), Magnusson et al. (1984) and Van Winkelhoff (1988) have demonstrated the recolonisation of cleaned sites 2–8 weeks after the initial therapy. They highlight the need for a regular and deep cleansing to stabilise the periodontal balance. Eccheveria et al. (gingival attachment loss, 1983), Gantes et al. (tooth substance loss, 1992) and Zappa et al. (pulp trauma, 1991) have demonstrated the trauma related to repeated subgingival use of mechanical tools.

Hemrev et al. (2006) point out the usefulness of solubilising biofilms during periodontal maintenance to expose bacteria that are isolated from the immune system. To respond to these requirements and overcome the disadvantages associated with repeated subgingival intervention, the Er:YAG laser offers an alternative for periodontal maintenance of at-risk sites, thanks to its photothermal and photomechanical properties. Therefore, we propose that this tool will be integrated into periodontal maintenance protocols, alongside conventional tools.

Such a maintenance session could be described as follows:

- Application of plaque-disclosing agent to identify areas of dental plaque retention.
- Supra-gingival and subgingival scaling (if necessary) using sonic tools. Side remark: In theory, if the maintenance programme is well scheduled and respects the required frequency, there will be no subgingival tartar.
- Supra-gingival and subgingival polishing and air polishing on areas deeper than 4 mm.
- Conventional tools using manual curettes on areas deeper than 4 mm.
- Use of Er:YAG laser to irradiate furcation areas, areas inaccessible to conventional tools and sites that are higher than 4 mm.

#### *Laser settings*

It is the energy delivered by a laser beam which produces the therapeutic effect. To limit side effects and particularly thermal effects, the energy applied in periodontal maintenance should be low as long as the

## Testimonial



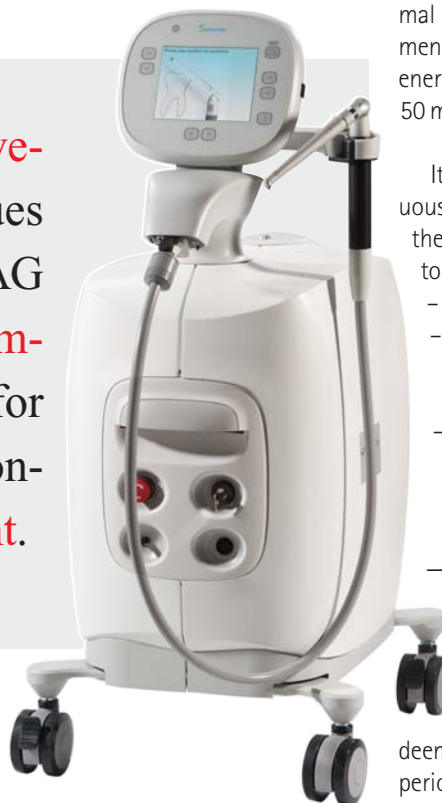
In the past 15 years, I have been focusing on periodontology in my work. But at the beginning of my career, I practised endodontics exclusively and have also resumed the practice of implantology during the past seven years.

Endodontics allowed me to discover the surgical microscope, which in turn made it possible for me to develop a non-invasive periodontal decontamination technique which is an intermediate route between the surgical approach and non-surgical techniques. Optical aids are key elements of this surgical concept. However, I have already been using an integrated Er:YAG laser in my clinical protocol for five years. This technology has provided me with a tool that offers the level of precision required for decontamination microsurgery.

The ergonomic design and exceptional performance of the LiteTouch laser allows me to work in a highly efficient manner with optical aids, achieving tissue micro-ablation under a visual check and by destabilising the biofilms. Its anti-inflammatory and antiseptic effects are fundamentally important for periodontology.

The strong water absorption for which the Er:YAG laser is known means that it is suitable for multiple surgical applications particularly in the area of gingival microsurgery and in assisted pre-implant bone regeneration procedures. In my opinion, the Er:YAG laser has become an indispensable tool for non-invasive procedures.

In addition to its **effectiveness** on inflamed tissues and biofilms, the Er:YAG laser offers **surgical comfort** that is **fundamental** for the observance of periodontal maintenance **treatment**.



**Fig. 8** LiteTouch, Er:YAG laser device.

treatment is not performed under direct visual control like it is performed in surgery. As we have already seen, the energy delivered by the Er:YAG laser at 2,940 nm has a very high water absorption rate. This physical property makes the Er:YAG highly efficient at low energy levels and has allowed it to establish itself as a standard in the field of periodontal maintenance among the various laser wavelengths used in dentistry (Walsh et al., 1989).

The objective is not to eliminate tissue, but rather only to break down biofilms and solubilise micro-organisms so as to make them accessible to the immune system. 1–2 watt of power will be sufficient to achieve these results with the Er:YAG. To avoid ther-

mal elevation by repeated applications, we recommend a frequency of approximately 20 Hz. Thus, the energy delivered upon each impact may be between 50 mJ and 100 mJ.

It is preferable to apply the laser beam in a continuous scanning motion inside and at the entrance of the periodontal pockets, moving towards the bottom. This motion will have three advantages:

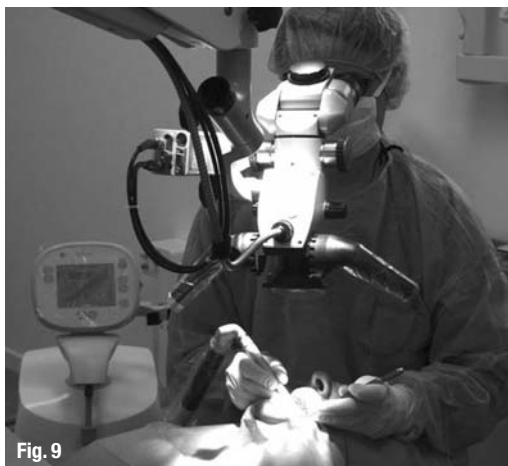- Limitation of possible thermal effects.
- Agitation of the water delivered to the inside of the periodontal pockets using the laser hand-piece.
- Maximisation of the treatment on all surfaces of the pocket by means of direct irradiation from the beam.

### Conclusions

Periodontal maintenance after initial (surgical or non-surgical) periodontal therapy is an integral part of the periodontitis-management strategy; indeed, it could even be deemed to be essential. It consists of stabilising the periodontal balance between the microbial flora and the immune system established in the initial step. This objective can be only achieved through gentle, efficient and repeated application at a frequency that is adapted to the patient's needs. We have seen that there are a number of gaps in the range of conventional mechanical tools that are currently in use, although this is still somewhat efficient. Thanks to its physical and biological properties, the Er:YAG laser can be integrated into the currently used maintenance protocols.

In addition to its effectiveness on inflamed tissues and biofilms, the Er:YAG laser offers surgical comfort that is fundamental for the observance of periodontal maintenance treatment as already suggested by Sanz et al. in 2008 during the 6<sup>th</sup> European Workshop on Periodontology.

**Fig. 9** Dr Fabrice Baudot working in his clinical practice.



**Fig. 9**

### contact

### laser

#### **Dr Fabrice Baudot**

Parodontologie et Implantologie  
65, impasse des 3 pointes  
34980 Saint Gély du Fesc

fabrice.baudot@me.com




**SAVE  
THE DATE**

27. und 28. November 2015  
in Berlin  
Hotel Palace

**24. JAHRESTAGUNG DER DGL**

**LASER START UP 2015**



Impressionen  
23. Jahrestagung der DGL  
LASER START UP 2014

**Programm anfordern!**

0277113

**Faxantwort**

0341 48474-290

Bitte senden Sie mir das Programm zum/zur

☐ **LASER START UP 2015** ☐ **24. JAHRESTAGUNG DER DGL**

am 27. und 28. November 2015 in Berlin zu.

Name/E-Mail

Praxisstempel

LJ 8/14

# Comparing the effects of manual, ultrasonic & Er:YAG laser treatment

## An *in-vitro* study on chronical periodontitis patients

**Authors**\_Dr Zulala Tasneem, Dr Salika Sheikh, Dr. Rahul Kale, Dr Naresh Thukral & Dr Sangeeta Muglikar, India

The elimination of calculus and bacterial micro-flora has been a time-tested modality in treating chronic periodontitis. To date, several approaches have been introduced to achieve a complete elimination of calculus, plaque and necrotic cementum. Hand and ultrasonic instrumentation has long been considered as the most effective and convenient method of plaque and calculus removal. These conventional treatments, however, leave the root surface covered with a smear layer that contains germs and bacterial endotoxins. Also, with ultrasonic instrumentation, more damaged and rougher surfaces have been seen.<sup>1,2</sup>

Of late, research on the use of different lasers for calculus removal such as CO<sub>2</sub>, Nd:YAG and Er:YAG has

been conducted. Of these, the Er:YAG laser is believed to be the most effective due to its absorption capacity by water. It induces root surface changes which are more biocompatible for soft tissue attachment and thus improves the treatment outcome of periodontal disease.<sup>3,4</sup> Thus the aim of the present study was to analyse the effects of the Er:YAG laser as compared to hand and ultrasonic scaling on fibroblast attachment to periodontal diseased root surfaces.

### Materials and Methods

Patients with chronic periodontitis reporting to the M.A. Rangoonwala College of Dental Sciences and Research Centre in Pune were selected for the study. The patients included in the study were non-smokers, systemically healthy and were of age  $\geq 35$  years. Patients selected presented with at least one periodontal involved single-rooted teeth indicated for extraction. 15 such teeth extracted from different selected patients were used in the study. Patients with a history of antibiotic treatment in the past four months were excluded from the study.

Immediately after extraction, blood, saliva and soft-tissue debris were removed by light scrubbing with a sterile scrub and by rinsing with sterile saline solution. Two specimens were obtained from each tooth by cutting with a sterile diamond disk running at low speed with sterile water coolant.

The coronal sectioning was done 1 mm below the CEJ and the apical sectioning was done 4 mm from the root apex. Longitudinal buccolingual sectioning was




Fig. 1

Fig. 1 Different shapes and lengths of laser fiber tips.



done to expose the pulpal wall and to obtain two specimens from each root. To avoid contamination from the pulp, the pulpal wall was separated from the remaining outer portion of root dentin using a bur running at low speed. A total of 30 specimens thus obtained from all selected teeth were randomly assigned to three groups:

Group A (n = 10 treated with hand scaling)

Group B (n = 10 treated with ultrasonic)

Group C (n = 10 treated with Er:YAG laser)

Specimens of Group A were hand scaled using Gracey curettes 1–2, 3–4, 5–6, 7–8 until all the visible calculus was removed. Specimens of Group B were scaled with ultrasonic for 60 sec until all the visible calculus was removed.

Specimens of Group C were treated with an Er:YAG laser system (wavelength = 2.94  $\mu\text{m}$ , Fotona, Slovenia) used at 160 mJ/pulse at 10 Hz, equivalent to the energy densities of 94 J/cm<sup>2</sup> per pulse. The laser was used in contact mode under water irrigation. A laser sapphire tip was used in a parallel direction along the root surface with an angulation of 20 degree for 40 sec for each sample. Root specimens were then placed in a petri dish containing anti-bacterial and anti-fungal solution to avoid contamination for 1 hour. Specimens were then thoroughly rinsed in Dulbecco's Phosphate Buffered Saline and covered with 2 ml fibroblast L929 suspension. Cell culturing was done at 37 degrees in a humidified atmosphere of 95% air and 5% CO<sub>2</sub> for 3 days.

5ml of cell suspension was seeded into the tissue culture containing root samples and incubated for 3 days. At the end, the cells were rinsed with Dulbecco's Buffered Saline (DPBS) and fixed by DPBS solution containing 4% glutaraldehyde. Fixed samples dehydrated by passing through ethanol/water solution were immersed in hexamethyldisilazane for 30 min to complete the dehydration. Dehydrated cells were spluttered with gold and were observed by scanning electron microscopy to view fibroblast attachment to the root surfaces of the specimens.

## Results

Fibroblast morphology on all treated surfaces was observed and was found to be different following different treatment modalities. In the Groups treated with hand scaling and ultrasonic scaling, scattered flat and healthy fibroblasts with a low number of lamellipodia and attachment extensions into the wavy surfaces, covered with smear layer, were observed. In the Er:YAG laser group, the treated surfaces were observed to be covered by a confluent monolayer of flat, spindle-shaped fibroblasts, which were firmly attached to the root surface by means of many lamellipodia and attachment extensions.

[PICTURE: © PASHIN GEORGIY]

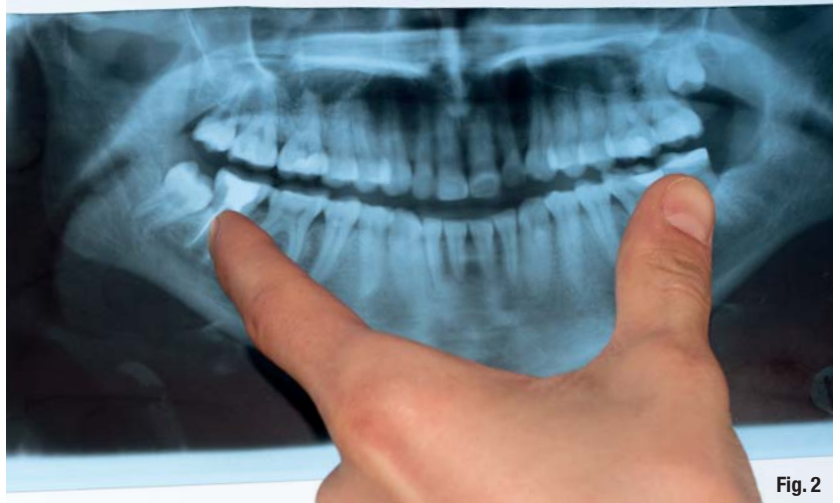

Fig. 2

## Discussion

In periodontal treatment, mechanical removal of plaque and calculus is mandatory to control and prevent inflammatory processes. When ultrasonic and hand instrumentation were compared in clinical studies<sup>5,6</sup>, results showed reductions in probing depth and bleeding on probing. However, mechanical instrumentation leaves the root surfaces covered with smear layer that obliterates the orifices of the dentinal tubules and contains germs, bacterial endotoxins and residual contaminated root cementum that hampers good periodontal healing and regeneration of connective tissue attachment.<sup>7</sup>

Er:YAG laser, however, is shown to induce a root surface that has better biocompatibility for soft-tissue attachment. It removes lipopolysaccharides, calculus, smear layer and cementum, providing high bactericidal potential at a low energy level on the root-infected dentin layer.<sup>8,9</sup> In the present study we found

Fig. 2\_Dental X-ray picture.

Fig. 3\_Close up of a dental calculus removing.

[PICTURE: © OCSKAY MARK]

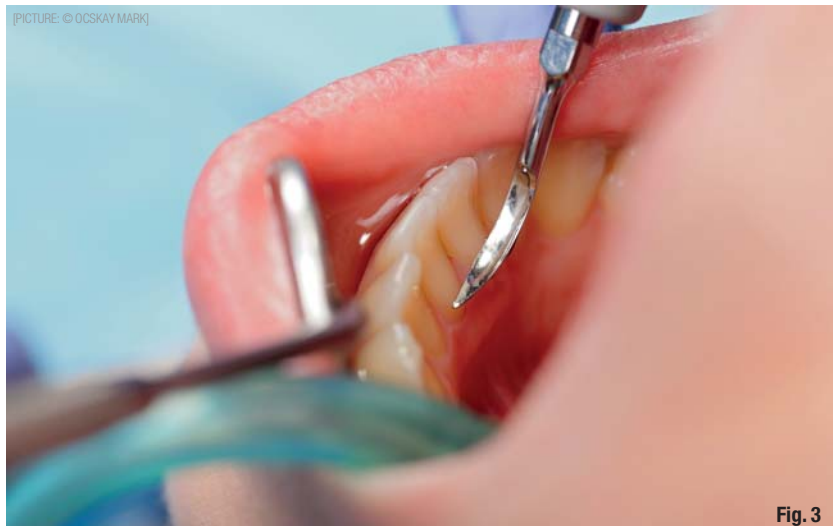

Fig. 3

**Fig. 4** Periodontal treatment parameters, presaved in Fotona laser.

SOFT TISSUE-PERIO: Procedure Open		
1	Nd:YAG PERIO EPITHELIUM	300
2	Er:YAG PERIO CALCULUS	H14
3	Nd:YAG PERIO CLOT CREATION	300
4	Er:YAG FLAP SURGERY	H14
5	Er:YAG GINGIVECTOMY	H14
Previous      Back      Next		

**Fig. 4**

that the fibroblasts were tightly attached to specimens treated with Er:YAG laser as compared to specimens treated with hand and ultrasonic instruments.

Frentzen et al.<sup>10</sup>, in a histologic study compared the effects of Er:YAG instrumentation of diseased root surfaces to mechanical removal of plaque and calculus with ultrasonic instrumentation. The results showed that ultrasonic debridement resulted in a smooth surface covered by a smear layer<sup>11</sup> containing remnants of dental debris, contaminated root cementum, bacterial endotoxin and subgingival plaque<sup>12, 13</sup> whereas Er:YAG laser irradiation induced a glazed microstructure presenting a rough aspect to the root surface.

Babay<sup>14</sup> evaluated fibroblast attachment to periodontal involved root surfaces, which were either root planed with curette, ultrasonic scaler or acid chelated by different agents such as citric acid, tetracycline hydrochloride or EDTA to produce different surface textures. The results demonstrated that there was a significantly greater number of fibroblasts attached to specimens treated with citric acid, tetracycline, and EDTA than those scaled only, which means

**Fig. 5** Ultrasonic scanner.



**Fig. 5**

that fibroblasts were more likely to attach to rough-surfaced than to smooth-surfaced specimens.

Er:YAG laser induced a homogenous roughness to the root surfaces<sup>15-17</sup>; this morphological roughness of lased surfaces enhances the adhesion and proliferation of fibroblasts, which are present in higher numbers than those of the ultrasonically treated specimens. This surface transformation obtained by the Er:YAG laser probably exposes chemical root substances that are highly selective for chemotaxis to fibroblasts.<sup>18</sup>

It has been suggested that the biochemical modifications of the root surface induced by the use of an Er:YAG laser are responsible for an increase in fibroblast attachment. These modifications could be either a direct consequence of root conditioning by the exposure of some of the extracellular matrix constituents acting on the attachment mechanism of fibroblasts or an indirect effect of biochemical factors, from increased fixation on the demineralised root surface. The results of the present study concurred with the previous studies.<sup>19</sup>

Study results were similar to those obtained by Feist et al.<sup>20</sup>, who studied fibroblast adhesion and growth on cultured human gingival fibroblasts on root surfaces treated by both Er:YAG laser and curette. He found that fibroblasts adhered to and grew on all treated surfaces, but the group lased at 60 mJ/pulse, 10 Hz, presented a significantly higher cell count than the other groups.

## Conclusion

Thus the present study suggests that laser treatment could be an important and useful tool to induce a modification of root surface morphology with a complete elimination of the presence of the smear layer, improving fibroblast attachment. Future extensive and well-controlled studies are needed to confirm this hypothesis.

*Editorial note: A list of references is available from the publisher.*

## contact

## laser

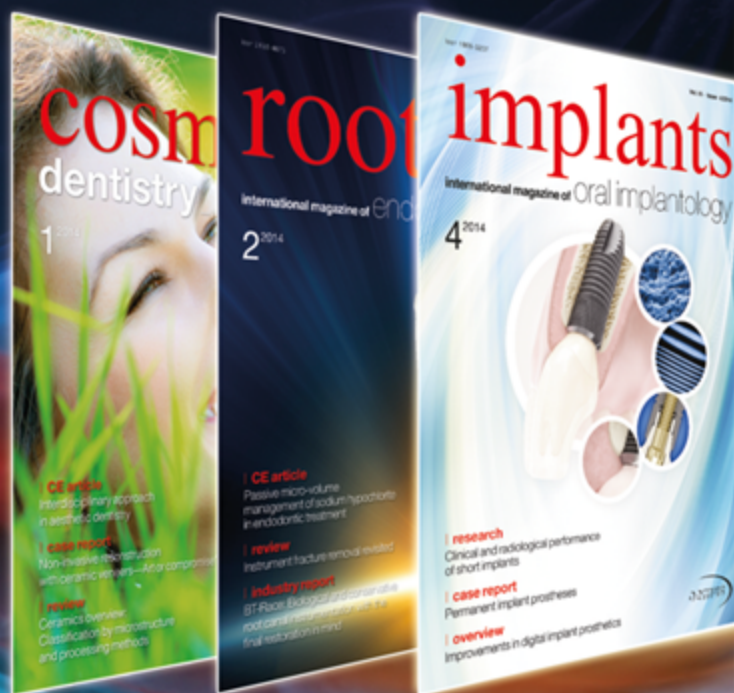### Dr Zulala Tasneem

M. A. Rangoonwala College Of Dental Science & Research Centre  
2390-B, K.B. Hidayatullah Road  
Azam Campus  
Camp Pune 411001  
Maharashtra, India



# laser

international magazine of laser dentistry



**Subscribe now!**

You can also subscribe via  
[www.oemus.com/abo](http://www.oemus.com/abo)

■ I would like to subscribe to **laser** international magazine of laser dentistry (4 issues per year) for € 44 including shipping and VAT for German customers, € 46 including shipping and VAT for customers outside Germany, unless a written cancellation is sent within 14 days of the receipt of the trial subscription. The subscription will be renewed automatically every year until a written cancellation is sent to OEMUS MEDIA AG, Holbeinstr. 29, 04229 Leipzig, Germany, six weeks prior to the renewal date.

► **Reply** via Fax +49 341 48474-290 to OEMUS MEDIA AG or per E-mail to [grasse@oemus-media.de](mailto:grasse@oemus-media.de)

Last Name, First Name

Company

Street

ZIP/City/County

E-mail

Signature

Notice of revocation: I am able to revoke the subscription within 14 days after my order by sending a written cancellation to OEMUS MEDIA AG, Holbeinstr. 29, 04229 Leipzig, Germany.

Signature



# Wireless digital sensors

Author\_George Freedman, Canada

[PICTURE: © GONCHARUK MAKSIM]

**Fig. 1** Wireless digital sensor technology is the most popular digital radiography process worldwide.

**Fig. 2** Wired chip sensors with bitewing images.

**Fig. 3** The PSP sensor is quite pliable and has a reasonable flex upon insertion into the mouth.

\_When digital dental radiography was first introduced in the late 1980s, conventional X-rays had been in use for almost a century. The radiograph had, over the years, expanded the dentist's investigative capacity in many ways; it was possible to confirm health, or to detect disease, in many previously invisible areas of concern to the profession, including coronally, pariapically, and periodontally. Visual access, complemented by radi-

ographic interpretation, provided a comprehensive environment for earlier and more accurate diagnosis.

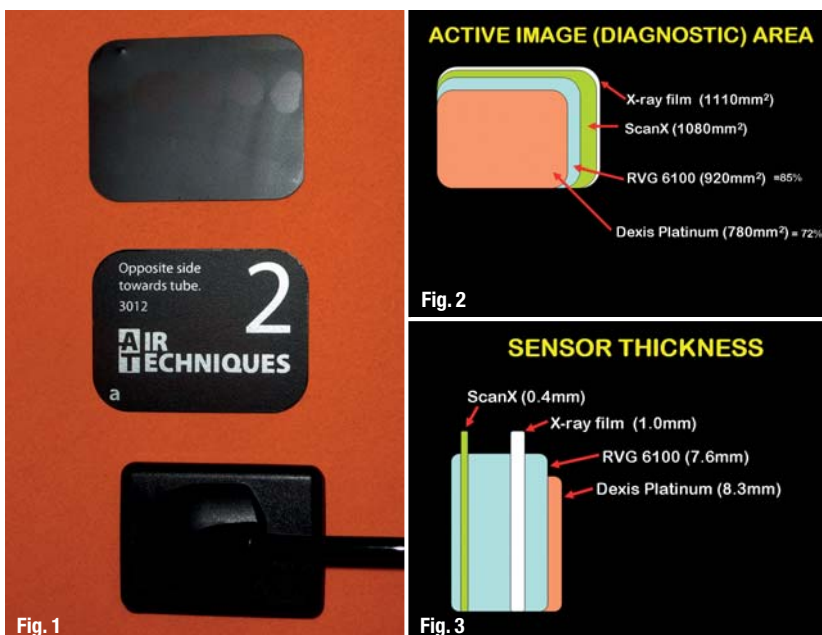
## \_Advantages of digital radiography

For the practitioner, the lost production of the conventional X-ray's developing downtime (5 to 10 minutes) has always been a very costly break in the production day. The virtually immediate computer-generated radiographic image eliminates this irritating issue. For the dental team, the elimination of the darkroom, its chemicals, solution replenishment routines, foul odours, and increasingly complicated environmental liabilities are welcome changes.

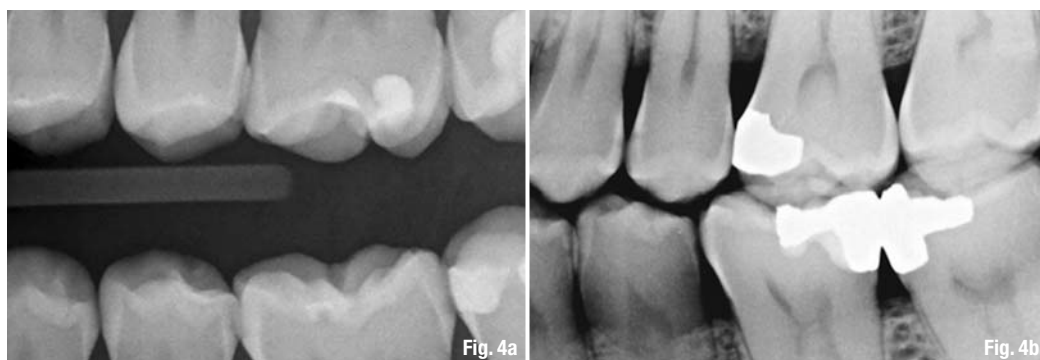
Modern digital radiographic systems today provide highly accurate and clinically relevant diagnostic information. Their many advantages include: virtually immediate results, clinical accuracy, expanded diagnostic options, decreased patient radiation, convenient data storage and communication, ease of clinical use by auxiliaries, decreased consumable costs, and a more environmentally friendly profile.

## \_Digital radiography options

Several categories of innovative dental radiographic imaging technologies have been intro-







**Fig. 4a & b** In some cases, effective imaging requires a greater radiation exposure for the patient.

duced into the dental marketplace. In general, they can be used with existing X-ray units. As a major benefit to dental patients, a significant decrease in radiation emission is required. Practitioners looking to update and upgrade their traditional (silver halide) radiographic systems have excellent clinical options. One of the most important selection criteria is the sensor-to-computer data transfer mode. Some digital chip sensors, such as the CCD (Charge Coupled Device) and CMOS (Complementary Metal Oxide Sensor), are hardwired to the computer through a USB or utilise a Bluetooth connection. The digital PSP (Phosphor Storage Plate) sensors (ScanX, Air Techniques, Melville NY) are wireless, and are most similar in appearance, function and convenience to traditional radiographic film. Wireless digital sensor technology (Fig. 1) is the most popular digital radiography process worldwide, with more than 50,000 dentists having incorporated PSP into their practices. The three types of sensors, CMOS, CCD, and PSP are equivalent in terms of the data that they accumulate per square millimetre during their very brief exposure to ionizing radiation, and then transfer to a digital image format.

#### Sensor diagnostic surface area

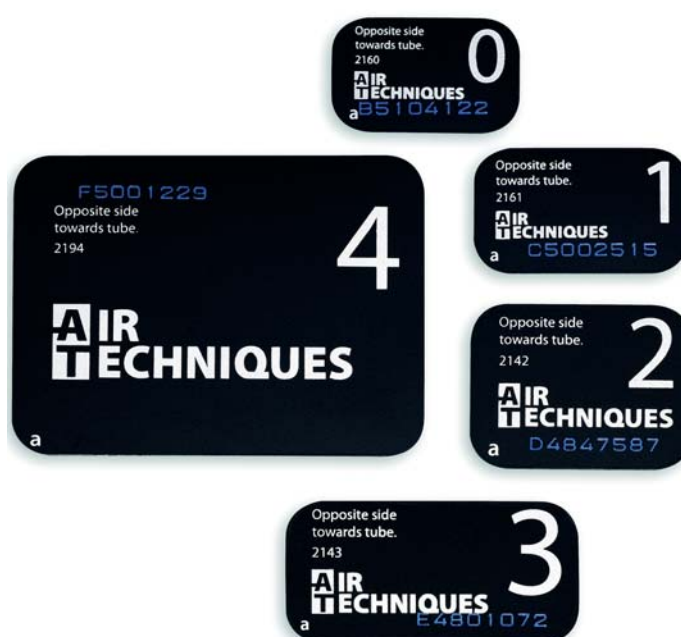Sensor dimensions are crucial to diagnostic utility. The larger the active surface (or image) area, the greater the amount of information the sensor provides to the practitioner. A traditional size 2 film provides about 1,100 mm<sup>2</sup> of diagnostic area. Similarly, a size 2 ScanX wireless digital sensor offers 1,080 mm<sup>2</sup> of diagnostic area. Digital chip sensors typically have a smaller active area, providing correspondingly less diagnostic information. There is a further complication for the wired chip sensors with bitewing images (Fig. 2). The sensor wire must be placed between the posterior teeth, preventing their complete intercuspation. Unlike a thin cardboard or plastic bitewing tab, the wire is 4–6 mm in diameter, leaving the teeth that distance apart. The resulting empty interocclusal space is non-diagnostic for dental structures, and in fact, prevents the effective imaging of the gingival areas and the

crestal bone. This often necessitates a vertical re-orientation of the sensor and/or more radiographs, requiring a greater radiation exposure for the patient (Fig. 3).

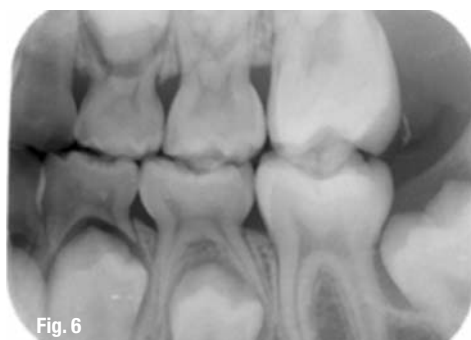#### Sensor thickness

The thickness of the sensor can be a major barrier to patient comfort and proper positioning of the sensor. A traditional size 2 film, at approximately 1.0 mm of thickness, can be rather uncomfortable for some patients, particularly individuals with small mouths or conditions such as lingual tori. Wired digital sensors range from 5.5–8.3 mm in thickness. Their thickness makes them more difficult position in the mouth and more difficult for the patient to retain comfortably. The ScanX wireless digital sensor is less than half as thick as a conventional X-ray film at 0.4 mm. Furthermore, unlike the rigid, wired sensors, the PSP sensor is quite pliable and has a reasonable flex upon insertion into the mouth (Fig. 4), significantly increasing patient comfort.

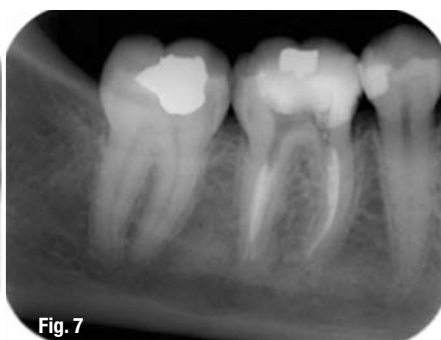**Fig. 5** ScanX wireless digital sensors are available in different sizes.



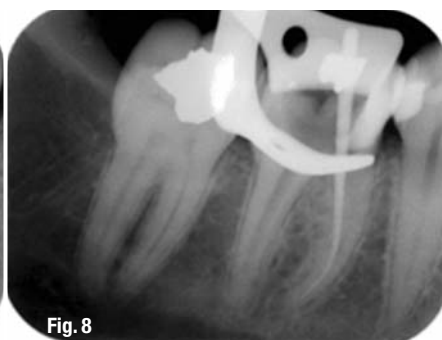**Fig. 5**



**Fig. 6**\_ScanX wireless digital sensors for standard bitewing.



**Fig. 7**\_ScanX wireless digital sensors periapical.



**Fig. 8**\_ScanX wireless digital sensors endodontic.

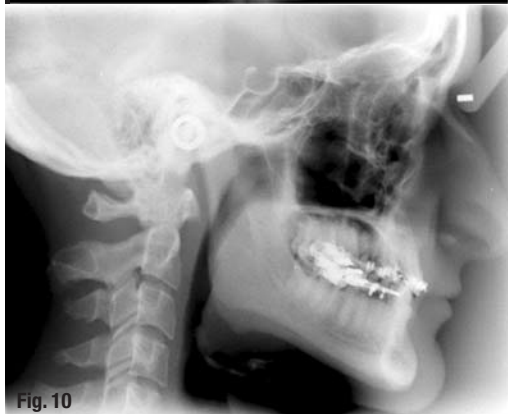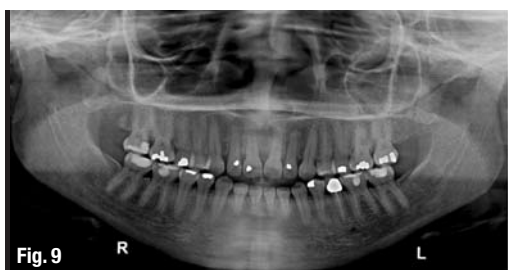#### *Wireless sensor size range*

ScanX wireless digital sensors are available in a range of sizes (Fig. 5): #0 and #1 for smaller and/or constrained mouths, #2 for standard bitewing, (Fig. 6) periapical, (Fig. 7) and endodontic (Fig. 8) images, #3 for long bite wings, #4 for occlusals, panoramic, (Fig. 9) cephalometric, (Fig. 10) and TMJ. Each sensor is a reusable plate that is inserted into a disposable protective barrier sleeve, positioned as required, briefly exposed, scanned and the data is immediately transmitted to the computer for image display. During the scanning, the data is automatically erased from the sensor, preparing it for immediate re-use in a new protective barrier sleeve.

The intraoral sizes are fabricated of a flexibly soft, reusable plastic that can be curved extensively to better fit the patient's mouth. If the digital sensor is bent to the point where the surface cracks, the broken portion of the sensor surface can no longer provide diagnostic information. With reasonable care, each sensor should last for thousands of images.

**Fig. 9**\_ScanX wireless digital sensors panoramic.

**Fig. 10**\_ScanX wireless digital sensors cephalometric.



#### **\_Digital sensor replacement cost**

Most breakdowns of chip sensors occur at the wire-sensor interface. While this should be easily (and inexpensively) repairable, there is a general reluctance to refurbish this connection, and the dentist is placed in a position where new sensors must be acquired. Whether the problem is a crushed chip or a frayed lead cable, wired digital sensors are very expensive to replace (often US\$ 5,000–10,000 or more).

In fact, it is highly advisable to have a replacement (insurance) policy with the manufacturer or dealer to cover these eventualities. The replacement warrantee is typically more than US\$1,000 per year per sensor. Wireless sensors, on the other hand, are far less costly; a size #2 replacement sensor costs about US\$40. Moreover, there are no wires to break. Considering a lifespan of thousands of exposures, the per-use cost of a PSP digital sensor is negligible.

#### **\_Developing/scanning time**

Conventional X-rays were developed to image viewability through chemical baths, water rinses and air dryers. The process was long and frustrating, particularly if the results were needed quickly. After intraoral exposure, a single film might be ready in 5–6 minutes, but a full mouth series took 10 minutes or longer. Wired digital sensors transmit the ionization data to the software immediately, and the images are ready for viewing as soon as they are processed (typically a very minimal delay).

ScanX wireless digital sensors are placed in the small footprint scanning unit, ScanX Swift (Fig. 11) and the images are available for viewing momentarily. The first PSP image is ready within 11 seconds, and subsequent one take 4 seconds each. Thus, a 4-bitewing series is ready for viewing in less than 30 seconds, and a full mouth series within 2 minutes. The unit automatically erases all the data on each wireless sensor, readying it for the next radiograph.



## \_Image enhancement

Digital radiographs have higher resolution than conventional film, and are thus clearer and more accurately diagnostic. The ScanX software has additional image enhancement tools that allow dentist to manipulate the acquired raw images (brightness, contrast, false colour, reversal) for additional analytic data without re-exposing the patient to additional radiation. These investigative tools are very valuable in pinpointing issues more specifically and far earlier than ever before. The software is intuitive and easy to use.

Viewing digital images on a screen has significantly improved both the way that practitioners diagnose their patients and the means whereby they develop simple and extensive treatment planning. The size of the monitor offers on-screen co-diagnosis and co-treatment planning that actively involve the patient in the dental treatment process.

## \_Data storage

The practice's radiographic data is ideally stored in a single location on the office server computer from where it is readily accessible to all the operator. Since radiographic image files are rather large (and compression may cause the loss of important details), it is important to dedicate adequate storage space that can accumulate at least 3 years' worth of data. Cephalometric and panorex images are particularly space consuming. Off-site and multiple location backups are good safe-computing practices that eliminate the unlikely, but potentially disastrous results of fire, flood, or a total irreversible failure of the storage drive.



Fig. 11

**Fig. 11** ScanX wireless digital sensors are placed in the small footprint scanning unit, ScanX Swift.

## \_Conclusion

Digital dental radiography is faster, cleaner, more effective and better than silver-based film. More than 99 per cent of dentists who use digital radiography recognize that it was a good investment. The obvious advantages include: immediacy of the images, decreased radiation exposure, image enhancement, digital storage, and the elimination of chemicals. The mainstream acceptance of digital radiography has been slowed by high start-up costs, however. Some of the earlier objections such as rigidity and bulkiness of sensors, sensor cord damage, and ongoing maintenance and repair have been eliminated by the PSP wireless digital sensors. While the initial costs of conversion to digital radiography may be high at first, the long-and short-term clinical and financial benefits of digital radiography are well worth the investment.

## \_about the author



**Dr George Freedman** is a founder and past president of the American Academy of Cosmetic Dentistry, a co-founder of the Canadian Academy for Aesthetic Dentistry and a Diplomate of the American Board of Aesthetic Dentistry. His most recent textbook, "Contemporary Aesthetic Dentistry" is published by Elsevier. Dr Freedman is the author or co-author of 12 textbooks, more than 700 dental articles, and numerous webinars and CDs and is a Team Mem-

ber of REALITY. Dr Freedman was recently awarded the Irwin Smigel Prize in Aesthetic Dentistry presented by NYU College of Dentistry. He lectures internationally on dental aesthetics, adhesion, desensitization, composites, impression materials and porcelain veneers. A graduate of McGill University in Montreal, Dr Freedman is a Regent and Fellow of the International Academy for Dental Facial Aesthetics and maintains a private practice limited to Aesthetic Dentistry in Toronto, Canada.

epdot@rogers.com

laser

# Staying ahead in dentistry

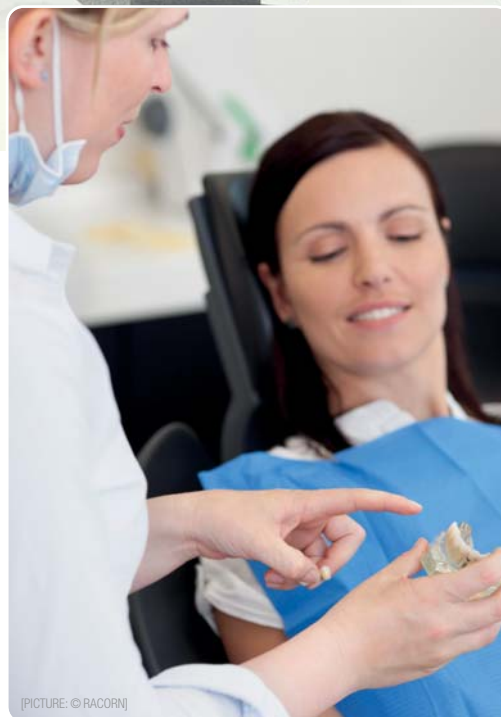Pleading for language competency and communication skills

**Authors** Simon Beeston & Dr Ross King, UK & Australia



**Language competency can mean different things** to different people. A dentist and dental nurse for example, will use a completely different vocabulary to discuss the care of a patient to the one they will use when explaining the treatment and prognosis to the patient and his or her family. A different approach also needs to be adopted when giving emotional and palliative support to the patient and his or her relatives.

Socio-economic change over the past 65 years has allowed international migration and led to multicultural societies that would have been unthinkable two generations ago. Improvements in transport links, combined with changes in political and social attitudes towards professional and skilled migrant workers, have presented significant opportunities to those wanting to work abroad. There are a number of professional qualifications that are accepted globally, allowing dental practitioners to work without having to retrain before applying for new overseas posts.



## **What about language skills?**

It is widely acknowledged that it is only a matter of time before all members of our profession, not

just those from outside the EU, will have to demonstrate that they are proficient in English if they wish to practise in the UK. A dentist needs to be able to communicate on social, palliative and clinical levels using appropriate language for all three. For example, good social English is not specific enough when having to ask a patient appropriate questions during a consultation, and a dentist and dental nurse need to use specific clinical vocabulary to communicate effectively during a procedure.

Dentistry differs from other health professions in that much of what a dentist does is procedural. It does not just entail consultation: it also entails explaining to every patient what is being done, why it is being done and what the experience is likely to be. Treatment plans and alternatives need to be clearly explained and understood. Records have to be maintained accurately and be fully comprehensible to another dentist if it is a group practice. Letters of referral must be comprehensive and unambiguous.

Another factor that is relevant to the UK, Australia and New Zealand is that all three countries have a large number of immigrants, so it is not at all uncommon to have the situation in which neither dentist nor patient has English as his or her first language. In this situation, competency has to be at a high level. Workarounds such as telephone-based interpreter services have been trialled but often dismissed as unsuitable, as they rely on the interpreter having profession-specific vocabulary in multiple languages.

### **— Demonstrating English proficiency with IELTS and ORE**

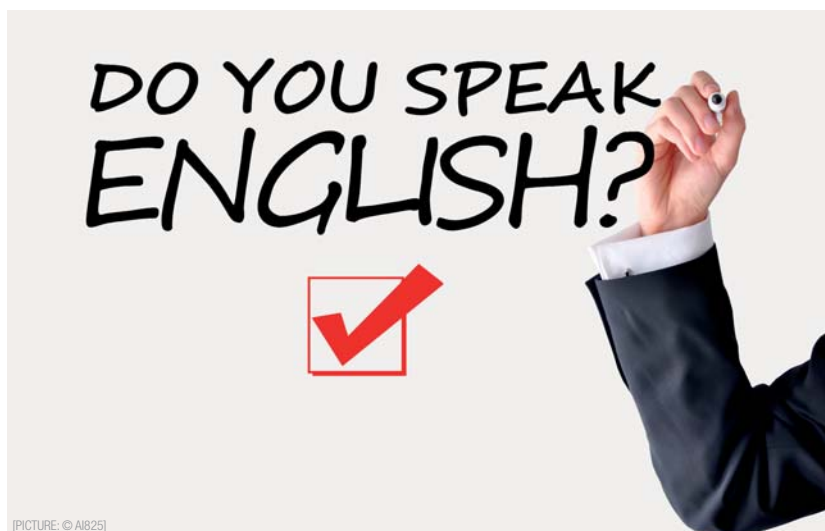In order to work in many English-speaking countries, dental professionals whose first language is not English and have not trained on a course taught in English often need to demonstrate a level of competency by way of an International English Language Testing System (IELTS)\* examination or similar. However, the required IELTS score varies from governing body to governing body and from country to country. Overseas-qualified dentists from outside the European Economic Area whose qualifications are not eligible for full registration with the General Dental Council (GDC) in the UK are required to pass the Overseas Registration Examination (ORE). Successful completion of the ORE allows these dentists to register with the GDC and practise unsupervised in the UK. Prior to taking the two-part examination to demonstrate their clinical skills and knowledge, applicants must submit details of their clinical experience and a single academic IELTS test report form less than two years old with a minimum overall band score of 7.0 and no score lower than 6.5 in any section.

However, overseas-qualified dentists from within the European Economic Area are currently exempt from submitting an IELTS test report form as part of the ORE, although this might change within the next several years. The UK government is currently consulting on changes to the Medical Act 1983 that would introduce legislation to "seek to stop foreign healthcare professionals working in the NHS unless they have passed robust language and competence tests". The proposed amendment is more comprehensive and includes both EU nationals and non-EU nationals. While the proposed amendment does not currently affect dentistry, it is highly likely that the GDC would follow suit and tighten its English language competency requirements further still.

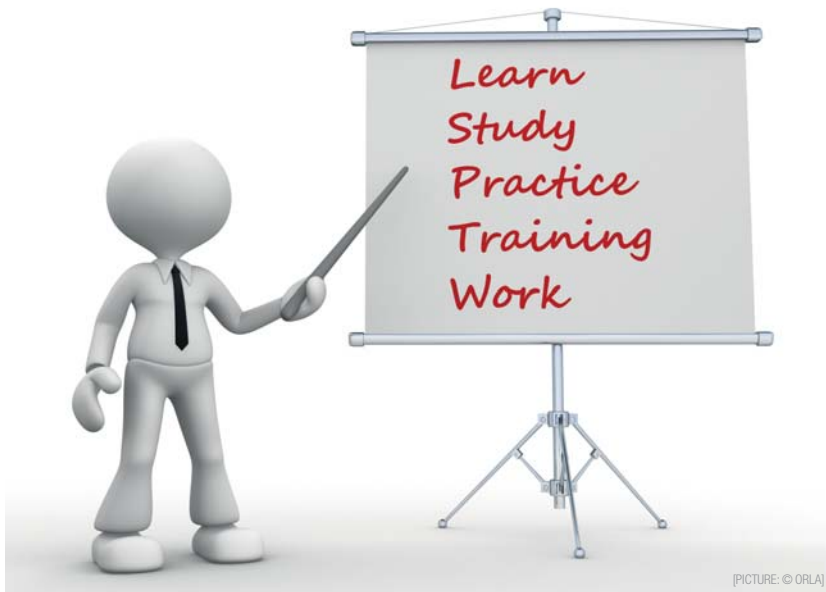The GDC should be applauded for setting the bar on language assessment with UK dentistry and going beyond what is currently required by the Medical Act 1983. The very fact that candidates must demonstrate their language proficiency before sitting an examination demonstrates the importance of good communication. Any change in legislation or desire to improve language practice would be an opportunity to make language proficiency requirements at entry more industry-specific.

### **— Profession-specific examination with OET**

With this in mind, it is instructive to review how tighter English language controls have already been implemented in Australia. The Australian Dental Council (ADC) requires overseas-trained dental practitioners to complete a three-part exam, one part being proficiency in English. As well as IELTS, the ADC recognises Cambridge English Language Assessment's Occupational English Test (OET)\*\*, which differs from IELTS in providing a profession-specific,



[PICTURE: © A1825]



fit for purpose assessment that uses typical clinical scenarios to test knowledge and use of language. OET includes four subtests (on listening, reading, writing and speaking) and, uniquely, all of these tests are rooted in the context of working as a dentist and using specific language that is relevant to being effective as a dentist. A typical example in the dentistry speaking examination presents the candidate (who plays the role of a dentist) with the scenario of a parent of a six-year-old boy who grinds his teeth at night, asking for advice about this problem. The parent is on a limited income and is very concerned about the extent of possible treatment. In this example, the candidate is required to explain the boy's problem, tell the parent ways of dealing with the problem, and reassure the parent about his or her concerns.

In the context of the clinical scenario, the candidate must demonstrate that he or she not only understands the vocabulary, but also can recognise the context and subtle variations of the conversation and respond accordingly. This particular scenario includes language functions concerning asking for advice, expressing concern, and looking for reassurance that would be common in a clinical communication event. The candidate's use of language must demonstrate that he or she understands that he or she is not a friend putting an arm around the parent's shoulder but a professional giving advice tailored to the parent's circumstances in a competent and authoritative manner.

### Lack of confidence is common cause of failure

Several years ago, the ADC identified that a lack of confidence in English was by far the most com-

mon cause of failure among candidates. As a result, the ADC raised the entry requirement from OET Grade C to Grade B in each of the OET subtests. Subsequently, the requirement has been raised further to grades of A or B. Personal experience also highlights cases in which, despite demonstrating the required language skills prior to entry, clinically excellent fifth-year dental students had English language skills that were inadequate and not fit for purpose. Rather than indicating any failure in teaching, this simply reinforces the need to provide specific training in clinical communication skills.

By introducing enhanced language testing requirements, it is vitally important to ensure that examinations are not only fit for purpose, but easily administered, fair and secure. Cambridge English Language Assessment's experience in running global, high-stakes, secure examinations, such as IELTS and OET is the best and meets very high standards in terms of authentication, security, reliability and validity. The organisation's expertise and reputation can help provide regulators with a high level of confidence.

One issue that we are very aware of in the UK is increasing pressure on limited resources leading to restructuring within the National Health Service. With global issues of an ageing population, people living longer and a greater need for health care, there is going to be more scrutiny on regulators to recruit internationally to meet the resourcing needs. Testing language competency and communication skills is fundamental to this changing landscape in health care, and examinations such as OET are becoming increasingly important in this, in terms of not just regulation, but also ensuring patient safety and patient outcomes.

\*IELTS is jointly managed by the British Council, IDP: IELTS Australia and Cambridge English Language Assessment.

\*\*OET is owned by Cambridge Boxhill Language Assessment Pty Ltd. It is a joint venture between Cambridge English Language Assessment and Box Hill Institute.

### \_contact

laser

#### **Simon Beeston**

Director of Admissions Testing Service  
University of Cambridge in the UK  
thenetwork@cambridgeassessment.org.uk.

#### **Dr Ross King**

Executive Secretary  
Australian Dental Council  
info@dentalcouncil.net.au.





# 33<sup>rd</sup> CIOSP

São Paulo International  
Dental Meeting

**January 22-25, 2015**

São Paulo - Brazil



**Integration, Knowledge and Technology in the same place!**

Organizer



SÃO PAULO DENTAL ASSOCIATION

Support



International Media



**Exhibit Inquiry:** SUVISON, a sole  
world agent, [sp2015@suvison.com](mailto:sp2015@suvison.com)

**[CIOSP.com.br](http://CIOSP.com.br)**



[PICTURE: © ASLYSUN]

# Gain power at your laser clinics!

**Author\_**Dr Anna Maria Yiannikos, Germany & Cyprus

In order to gain power at your laser clinics, a coherent marketing strategy is of need. In the previous issues of laser, we already discussed components of the "Seven P Formula" which are product, price, promotion, place, packaging, positioning and people. The next P in my list is "people". This is the most important element that will ensure our clinic's success or failure! Therefore let's stick to two maxims:

1. Hire for the attitude, knowing that we can train to develop the technical skills. Before we start the whole process of selecting our candidates, we should make a list of the attributes of the 'best' employee. This list will assist us in having a clear picture of what we are looking for.
2. After the job posting, the resume screening process starts in which we can select our star.

Let's think of the whole process as a movie in four scenes.

## How to find your perfect candidate

### *Scene 1*

We get the resume, we screen them and in the meanwhile we send thank-you letters to all interested candidates.

### *Scene 2*

We continue with the second screening which is calling the candidates and asking each the same questions to avoid biases. We can check their responses and behaviour by means of their way of answering.

### *Scene 3*

The selected candidates arrive on the day of the first interview. Here are some useful screening tips:

- We could give them an application form and ask them to fill in the required information. Some of the candidates cannot comply with this request or might even miss out some paragraphs or questions asked. With this, we can check how well they act, write and spell on spot.
- Do not permit any interruptions; show your respect and importance to the process.
- Mind the 30-70% rule, which means letting the interviewee do 70% of the talking and you as the interviewer do the remaining 30%. We need to learn as much as possible about every individual.
- Ask 'open questions' to allow the candidate to share his thoughts and ideas. Additionally, we can use situational interviews. Studies show that these are 50% more effective than the common ones and can be more predictive of the candidate's success to the post-

ing. We can ask them, for example, to describe how they would handle an angry patient when he shouts at the reception area due to our 20 minute delay. Instead of asking whether they are good in customer service, let's prefer the following question: "Give me an example of a situation you remember that you gave a 'wow service experience' to a client or the time that you received one." These are the so-called behavioural questions and we can use them for a more effective interview.

- What is the optimal duration of an interview? It should last until we are satisfied with the whole procedure, until we do not have any doubts about our decision.
- We must be the master of the interview. This means, we must be well prepared and be the one who is ruling the process.

#### Scene 4

After choosing the best candidates, we ask them for a testing period, which is paid. More specific, if there are about three candidates, we can ask them for a work trial of 3-5 days each. This gives us the opportunity to see how they act in our environment. By this, we can also find out more about their skills, or if their personalities do not match with ours.

"Find the best employee not the best candidate" – What is the difference? There are some candidates that are more experienced in an interview or better prepared and trained in answering interview questions than others. But this does not mean that they are also the best employees. We are not going to hire the best candidate that applied for the job but we are going to select the best – period! Remember to send thank-you letters to those candidates that have not been selected.

#### Scene 5

After the testing period, we continue with the second interview. Here, we can explore fields that we hadn't discussed before and can thus gain a complete picture of our candidate. In order to get a reliable picture, just mind the following rules:

Remember to avoid mistakes! Therefore, mind the "14 seconds"-mistake: A study which was carried out at the University of Chicago revealed that most interviewers decide on a candidate within the first 14 seconds. After that, interviewers try to support this impression even subconsciously. This means, in case of a candidate the interviewer dislikes, he asks difficult questions, while in the other case (interviewer likes candidate) he helps their candidate with the posed questions. Be prepared – ask clever questions to get clever answers! Know what you want from the start – for this, we have already prepared a short description for the best person for this job. Avoid copy/paste questions or you will get copy/paste answers! Instead of following the same old questions, be creative, be spontaneous. Listen to the candidate and

ask him questions that really reveal his character and personality. After all, at the end of the day we tend to spend more time with our colleagues and associates than with our own family and friends. Surprisingly, as a result of this habit (copy/paste interviews) we tend to hire people for their skills and fire them for their character. Therefore, hire a candidate for his personality and not for his skills!

Always check references! The only way to avoid negligent hiring processes and bad hiring decisions is to verify the information the applicant gives you against every reference. We can request a copy of the performance appraisal or we can ask a co-worker or a friend of the applicant to rank our candidate. An application form gives a clearer picture of a candidate than a CV. As a study found out, 40% of the information given in a resume might be misleading (example one of my candidates has send two different CVs). Thus, mind the sentence: "Application blanks tell you what you want to know – CVs tell you what the applicant wants you to know".

Finally, ask your candidates to tell their story from the beginning – by starting with their first job instead of the current one. This teaches us about their development and their way of thinking. The goal is to hire the best employees, but often we end up with hiring the "best applicants".

#### If we still have hired the wrong person...

If you feel like having hired the wrong person, then fire him as soon as possible before he disturbs your or your team's or the patient's peace. I remember once I hired a receptionist who in two days earned two big complaints from two very good patients of our clinic – because towards them she behaved in a childish and annoying way! Thus, I propose the idea of using the word "trial" in the beginning: This makes us feel better if we want to fire our newly hired employee since we prepare him for the "unexpected" without a big fuss. But what is next? We could call our best alternative or we could go for a new hiring process, which is of course time and money consuming. Thus, it is always better to focus on an efficient hiring process in the first run. \_

#### \_contact

laser



#### **Dr Anna Maria Yiannikos**

Adjunct Faculty Member of  
AALZ at RWTH Aachen Uni-  
versity Campus, Germany  
DDS, LSO, MSc, MBA

dba@yiannikso dental.com  
www.dba-aalz.com





# Regulatory system for medicines can be used more effectively

Source\_Escher, Netherlands

A new report from Escher, the independent TI Pharma platform for regulatory innovation, shows that the current regulatory system for medicines in Europe can be used in a more efficient and effective manner. André Broekmans, chairman of Escher: "Overall, the EU regulatory system operates well, however important recent changes had not yet been evaluated. One of our conclusions is that pathways that were intended to bring important new medicines faster to the market are not used in the right way. We are therefore missing opportunities to make medicines available to patients earlier."

Escher collaborated with researchers from Utrecht University to look into a number of areas that might be improved: pharmacovigilance, conditional approval, paediatric investigation plans and decentralized authorisation procedures. The research shows that some parts of the regulations are not yet fully achieving the effects they were intended to have. For example, the conditional marketing authorisation pathway was intended to bring much-needed products, for example for cancer treatment, to the market faster. The researchers found, however, that in practice it has often been used as a back-up for the 'normal' approval pathway, because requesting conditional approval had some perceived drawbacks (e.g. potential reimbursement issues and the level of post-marketing obligations). The researchers also identified opportunities for making the regulatory system more efficient, without compromising public health, for example by adjusting the timing of the submission and the level of detail of plans for the investigation of medicines in children."

Broekmans states that these discrepancies between the initial objectives of legislation and the effects of regulatory instruments in real-world practice should be better monitored. One of the main messages from the report is that the effectiveness of regulatory instruments can be increased by reflecting on the interpretation and implementation of the primary legislation. Companies and authorities need to learn together how to better use the opportunities that the current system provides.

Richard Bergström, Director General of the European Federation of Pharmaceutical Industries and Associations (EFPIA), notes: "Our latest learning from genomics and our improved understanding of human biology have resulted in a record number of promising break-through medicines in development. Entering a new era of personalised medicine, the current model for medicines development and approval may not be appropriate. Against this background EFPIA decided to provide an unrestricted research grant to the Escher platform to explore if the model is fit for purpose."

## \_contact

## implants

### Escher—The TI Pharma platform for regulatory innovation

Galileiweg 8  
2333 BD Leiden, Netherlands

Tel.: +31 71 332 2030  
Fax: +31 71 332 2031  
[www.escher.tipharma.com](http://www.escher.tipharma.com)



Under the Patronage of  
**H. H. Sheikh Hamdan Bin Rashid Al Maktoum**  
Deputy Ruler of Dubai, Minister of Finance  
President of the Dubai Health Authority

تحت رعاية  
سمو الشيخ حمدان بن راشد آل مكتوم  
نائب حاكم دبي، وزير المالية  
رئيس هيئة الصحة بدبي

19<sup>th</sup> مؤتمر الإمارات الدولي لطب الأسنان ومعرض طب الأسنان العربي  
UAE INTERNATIONAL DENTAL CONFERENCE & ARAB DENTAL EXHIBITION



Delivering Science & Technology

17 - 19 February, 2015

مركز دبي الدولي للمؤتمرات والمعارض  
Dubai International Convention & Exhibition Centre

[www.aeedc.com](http://www.aeedc.com)

Organised by



In Cooperation with



Strategic Partner



Supported by



INDEX® Conferences & Exhibitions Organisation Est.

Dubai Healthcare City, Ibn Sina Medical Complex #27, Block B, Office 203 | P.O. Box: 13636, Dubai, United Arab Emirates  
Tel: +971 4 3624717, Fax: +971 4 3624718 | E-mail: [info@aeedc.com](mailto:info@aeedc.com), Website: [www.index.ae](http://www.index.ae)

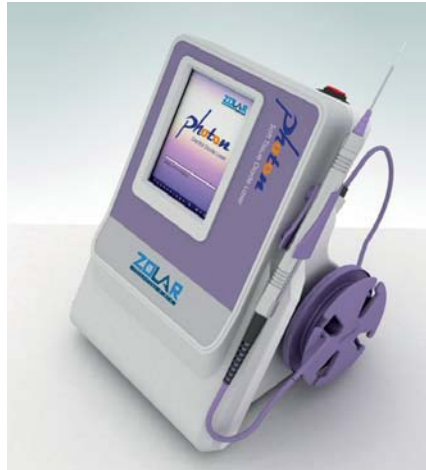# Manufacturer News

## Zolar Technology

### Aspiring dental laser company seeks international distributors

Zolar Technology, a Canadian-based dental equipment manufacturer specialising in dental diode lasers, has announced that it is looking for new dealers worldwide in order to expand its international business. The company's Photon laser series is certified by the Food and Drug Administration and according to European standards. In addition, the products received market clearance in Canada only recently. Zolar's Photon and Photon Plus soft-tissue dental diode lasers became available in the US in July last year. Only a few months later, Zolar was granted a license from Health Canada's Medical Devices Bureau to sell its Photon soft-tissue dental diode laser system with low-level laser therapy (LLLT) throughout Canada. The Photon series features a long-lasting battery pack for optimal portability, advanced software with a large touch-screen display, password security and a wide range of built-in treatment procedures, backed up by a three-year warranty.

Zolar's executive officer, Paul Atkins, said: "With the Photon diode laser now available with LLLT the dentist no longer has to purchase two separate devices to con-



duct soft tissue and dental pain therapy applications. The Photon now equipped with an LLLT option combines both applications in one device. This approval is an important milestone for Zolar, as the Photon remains the only soft tissue diode laser on the market equipped with LLLT dental applications."

Although low-level lasers are being used successfully in many dental clinics, the wide range of applications is still largely unknown to many practitioners, especially dental specialists, according to the company. LLLT offers dental practitioners a noninvasive treatment option that can be used as an adjunct to traditional therapies or as a therapeutic tool on its own. Examples of clinical applications include dental analgesia, treatment of dentin hypersensitivity, healing of soft-tissue lesions, reduction of pain and swelling after surgical procedures, better integration of implants into bone, and faster movement of teeth during orthodontic procedures. Zolar will be exhibiting its dental laser product portfolio at the Chicago Dental Society Midwinter Meeting (Booth 619) from Feb. 26 to 28, 2015, and at the International Dental Show (Booth A060), which will take place from March 10 to 14, 2015.

#### Zolar Technology & Mfg Co. Inc

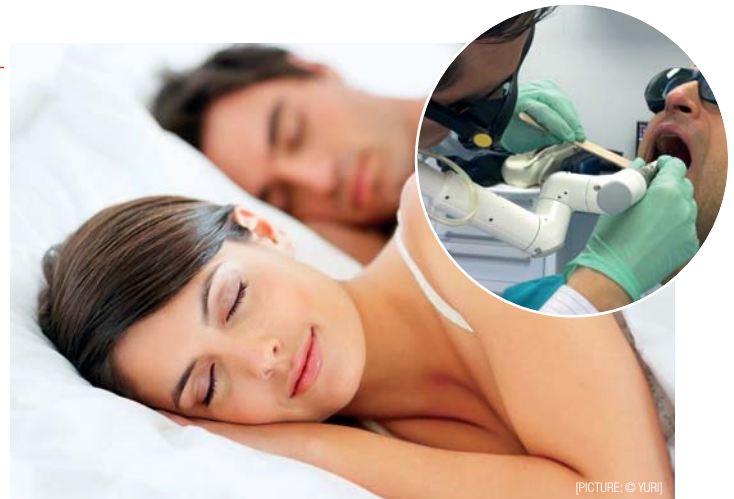6315 Shawson Drive, Unit 7-8,  
Mississauga, Ont.  
Canada, L5T 1J2

## Fotona

### Lasers treat snoring and apnea

It is not uncommon for dental practitioners to receive patients who suffer from snoring or sleep apnea. Snoring affects millions of people worldwide, more than half of which may also experience sleep apnea. Fortunately, dentists are highly qualified to diagnose and even treat these problems, and thereby help their patients to improve their sleep as well as health, wellbeing and quality of life. Fotona's NightLase therapy is easy for dental practitioners to perform and has a high success rate in producing a positive change in sleep patterns. Research has shown that this therapy reduces the effects of sleep apnea and decreases the amplitude of snoring by means of a gentle, laser-induced tightening effect caused by the contraction of collagen in the oral mucosa tissue.

The company's award-winning LightWalker laser systems enable the safe penetration of heat into the oral mucosa tissue. It is gentle enough to be used on the sensitive tissue inside the mouth, but strong enough to provide clinically efficacious heating. The heat generated by the Erbium laser allows collagen to re-form, resulting in a tightening of the soft palate and surrounding tissues. This causes a rise of the soft palate and tightening the tissues of the oropharynx, resulting in improved airflow. A full course of NightLase consists of three separate treatment sessions over a six week period. The final results of the treatment have been shown to last up to a year, and the therapy can be repeated. Patients find this therapy to be a highly comfort-



able and satisfying solution. It requires no devices or appliances to be worn during sleep and involves no chemical treatment. It's a gentle and easy way for your patients to regain a good night's sleep.

#### Fotona d.d.

Stegne 7  
1000 Ljubljana, Slovenia  
[www.fotona.com](http://www.fotona.com)



# THE FUTURE IS HERE

## ► The 36th Australian Dental Congress

Brisbane Convention and Exhibition Centre - *an AEG 1EARTH venue*   
Wednesday 25th to Sunday 29th March 2015

### Invitation from the Congress Chairman

On behalf of the Local Organising Committee of the 36th Australian Dental Congress, it is with great pleasure that I invite you to attend Congress and enjoy the river city of Brisbane.

Over three and a half days, highly acclaimed International and Australian speakers supported by contemporary research, will present a wide range of subjects relevant to practice. These presentations will be complimented by hands on workshops, Lunch and Learn sessions, specific programmes for members of the dental team. Social activities will be available for relaxation purposes.

The Brisbane Convention and Exhibition Centre is adjacent to the Southbank Precinct on the banks of the Brisbane River. Nearby is the Queensland Performing Arts Complex, the Queensland Museum and the Queensland Art Gallery and Gallery of Modern Art. A comprehensive industry exhibition will be held alongside the Congress enabling delegates access between scientific sessions to view the latest in equipment and materials.

Come and join us for the scientific programme, the opportunity to meet colleagues and the experience Brisbane has to offer.

Dr David H Thomson



Congress Chairman  
36th Australian Dental Congress

Titanium sponsor:



**BOQ  
SPECIALIST**

Distinctive banking



36th Australian Dental  
**CONGRESS**

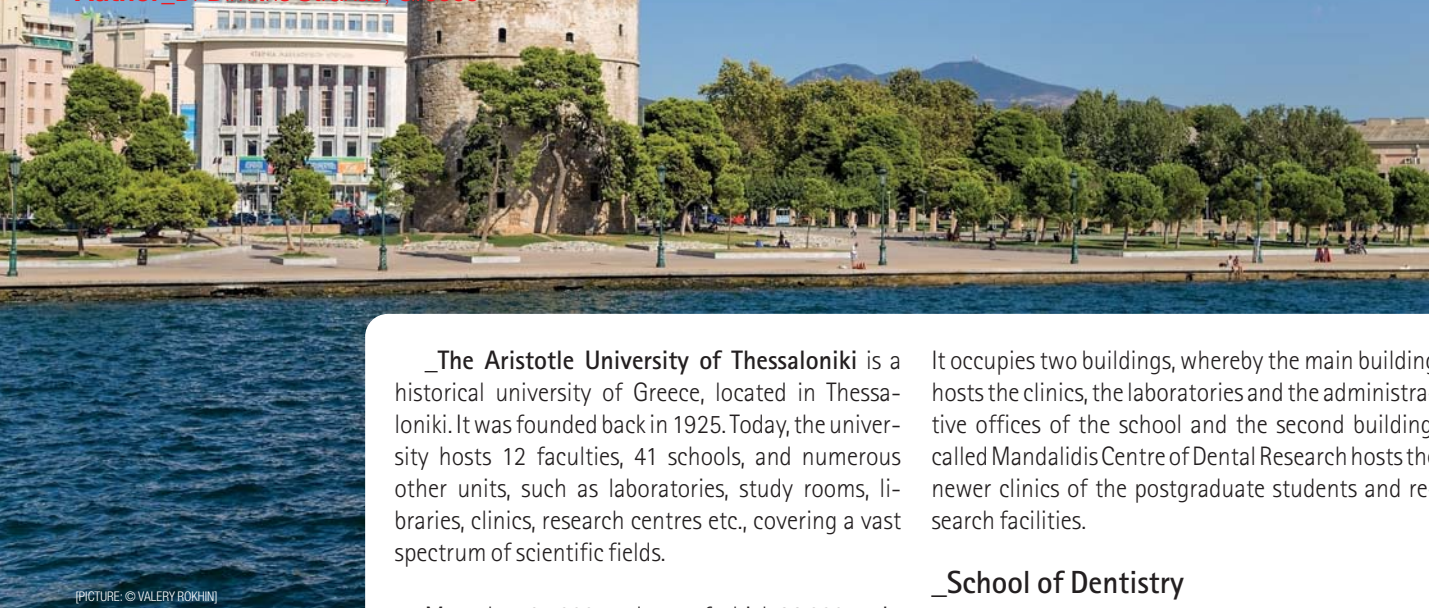
**Educating for Dental Excellence**

► [facebook.com/adacongress](https://facebook.com/adacongress) ► [twitter.com/adacongress](https://twitter.com/adacongress) ► [youtube.com/adacongress](https://youtube.com/adacongress) ► [adc2015.com](http://adc2015.com)



# Dental School of Aristotle University enters laser family

Author\_Dr Dimitris Strakas, Greece



(PICTURE: © VALERY ROKHIN)

**\_The Aristotle University of Thessaloniki** is a historical university of Greece, located in Thessaloniki. It was founded back in 1925. Today, the university hosts 12 faculties, 41 schools, and numerous other units, such as laboratories, study rooms, libraries, clinics, research centres etc., covering a vast spectrum of scientific fields.

More than 95,000 students, of which 86,000 are in undergraduate programmes and 9,000 in postgraduate programmes, study at the Aristotle University. The teaching and research staff consists of 2,248 people with 716 professors, 506 associate professors, 576 assistant professors and 450 lecturers. The scientific teaching staff has 84 and the special laboratory teaching staff 275 employees.

This staff is supported by 309 members of the special technical laboratory for teaching services and administrative personnel with 1,028 people. In terms of number of staff, undergraduate and postgraduate students and the facilities offered, the University is the largest university in Greece and South East Europe. According to the Academic Ranking of World Universities, the University is ranked in places 301 to 400 amongst the 500 best universities worldwide in 2010. In 2012, it was ranked as the best University in Greece and in 2013 on the 194<sup>th</sup> place in the world which is 62<sup>nd</sup> in Europe. The School of Dentistry, belonging to the Faculty of Health Sciences, is located in the north-western part of the University Campus.

It occupies two buildings, whereby the main building hosts the clinics, the laboratories and the administrative offices of the school and the second building, called Mandalidis Centre of Dental Research hosts the newer clinics of the postgraduate students and research facilities.

## **\_School of Dentistry**

6,992 dentists have graduated from the school of dentistry already, while today the number of students keeps on growing. The graduates have been working not only in Greece but worldwide, being sought after as highly educated professionals. With such history and reputation, the school of Dentistry at Aristotle University of Thessaloniki is always trying to offer the highest education and research standards possible for their students. With this in mind, Prof. Kosmas Tolidis started the modern and innovative technology clinic with a laser and a CAD/CAM division in 2012. It was a breakthrough for laser dentistry in Greece. The vision of bringing future dentists closer to the latest developments and becoming the first school in Greece to treat patients and producing fundamental and clinical research in laser dentistry had finally become real.

As Prof. Tolidis explains: "It is my strong belief that it is of paramount importance that education and research foundations, such as our school, incorporate latest dental technology into every day usage. I consider that the best way for a student or even a dentist to familiarise with such procedures is a well-organised curriculum in such institutions. This is why I tried to get the



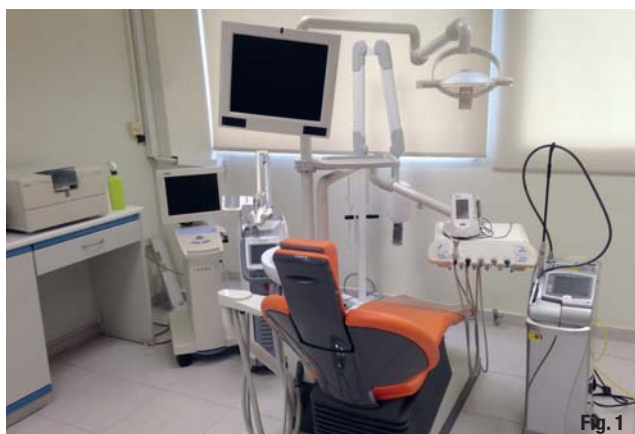

Fig. 1



Fig. 2

infrastructure as well as the appropriate manpower to perform such a demanding task. Laser procedures are already part of our postgraduate programme in Operative Dentistry and very soon an elective programme will start for our senior undergraduate students. Concurrently, in close cooperation with RWTH Aachen University in Germany, the world leading University in the field of Laser in Dentistry, and personally Prof. Norbert Gutknecht, the world opinion leader in this field, we are working on laser's research within the context of two PhD theses as well as on a number of research papers. I am pretty certain that despite difficulties (especially financial) the dental school of Aristotle University will very soon be considered as part of the group of dental schools leading the way in dental technology for the benefit of both our students as well as our patients."

Inevitably, a co-operation with the highest quality education institute of AALZ and RWTH Aachen University has started. Prof. Norbert Gutknecht, director of AALZ-Aachen Dental Laser Centre, has fully supported Prof. Tolidis' vision from the very beginning.

Prof. Gutknecht states: "Since Greek students have been the first students in our MSc programme which started at RWTH Aachen University in 2004, I am very proud and happy that out of these first Greek students Dr Dimitris Strakas became a faculty member of Aristotle University. With his capacity, being a Master of Science in Lasers in Dentistry achieved at RWTH Aachen University, he was appointed as the head of the high-tech department, giving first introduction lectures on lasers in dentistry to undergraduate students, as well as cooperating with AALZ and RWTH Aachen University in the master degree programme Laser Therapy in Dentistry in Greece.

Furthermore, I am happy that out of this collaboration we will have our first common PhD candidate working on the aspect of aesthetic dentistry with the use of different laser devices. It is of great importance that Prof. Tolidis is leading his department into the modern world of laser dentistry with us."

The general manager of AALZ, Mr Leon Vanweersch, comments on this collaboration: "I am very happy and excited that my very good friend Dr Dimitris Strakas became this very prestigious position as the first head of the new established high tech centre at the dental faculty of Aristotle University in Thessaloniki. In my opinion, this is an important milestone to impart knowledge about the therapeutic use of lasers in dentistry to all existing and future dentists in Greece. With Dr Strakas, being also the president of the Greek Society of Laser Dentistry and president elect of the European Division of WFLD, Aristotle University and AALZ are having the right person to push forward the scientifically approved use of lasers in dentistry! Having met in person both Prof. Tolidis and Prof. Gerasimou, I strongly believe that the cooperation with us will be more than fruitful, also providing us the means to organise and complete more multi-centre studies on laser therapy."

This initiation has been supported by many laser companies as Biolase, Fotona, Sirona, Lambda, A.R.C. and Lasotronic that has provided us with a number of laser devices of various wavelengths already. With their help and support many future dentists will be introduced to the world of laser dentistry and many more publications on both high-power and LLLT laser systems will be published. The dental school of Aristotle University is leading the way in Greece towards the future in modern dentistry and is empowering its reputation amongst European faculties.

## \_contact

## laser

### Dr Dimitris Strakas

DDS, MSc in Lasers in Dentistry,  
RWTH-Aachen University  
PhD cand. Department of Operative Dentistry  
Aristotle University of Thessaloniki  
[www.auth.gr/en/dent](http://www.auth.gr/en/dent)



# Focus on laser: Annual Congress of the DGL and LASER START UP 2014

Author: Katrin Maiterth

(PICTURE: © MIKHAIL MARKOVSKIY)

**Fig. 1** \_DGL president Prof. Dr Norbert Gutknecht opened the 23<sup>rd</sup> annual congress.



**Fig. 1**

On 26 and 27 September, members of the Deutsche Gesellschaft für Laserzahnheilkunde (German Association of Laser Dentistry, DGL) met for the association's 23<sup>rd</sup> Annual Congress in Duesseldorf in Germany. Parallel to the congress, LASER START UP 2014 was held in collaboration with and under the scientific guidance of the DGL. At both events, novices in the field of laser dentistry, as well as experienced users, learnt about the technical possibilities of current lasers and their integration into various dental treatment procedures. More than 500 people

attended the joint event, which combined the annual congresses of the DGL and of the German Association of Dental Implantology, LASER START UP 2014, and Oral Hygiene Day 2014, in the Rhine metropolis.

The use of technology has permeated many aspects of daily practice in dentistry; nevertheless, minimally invasive technologies, such as laser, are not yet widely used in dentistry. During the annual meeting, the DGL and LASER START UP informed participants about laser technology and its applications. The theme of the meeting was "Microinvasive—minimally invasive: Integrative laser technology", and Prof. Norbert Gutknecht (Aachen, Germany) and Dr Georg Bach (Freiburg/Breisgau, Germany) chaired the scientific programme committee for both events.

## \_Lasers in dentistry

On Friday morning, Prof. Gutknecht, President of the DGL, opened the two-day congress with a lecture on bundled light. He was followed by top-class speakers, including Prof. Hendrik Meyer-Lueckel (Aachen), Dr Michael Hopp (Berlin, Germany), Prof. Matthias Frentzen (Bonn, Germany), Dr Collin Jacobs (Mainz, Germany), Prof. Andreas Braun (Marburg, Germany), Dr Michael Krech (Marburg) and Ruth Schulte-Luenzum (Aachen). The researchers offered





Fig. 2



Fig. 3



Fig. 4



Fig. 5

**Fig. 2** The scientific programme offered a lot of interesting presentations. – **Fig. 3** At the information booth of the DGL. – **Fig. 4** At the dental exhibition, participants learnt about the latest products. – **Fig. 5** Dr Georg Bach at LASER START UP 2014.



Fig. 6



Fig. 7

**Fig. 6\_** Prof. Gilles Chaumanet from Nice, France.

**Fig. 7\_** The DGL board at the members meeting, from left: Dr Thorsten Kleinert, Dr Matthias Frentzen, Dr Detlef Klotz, Prof. Dr Norbert Gutknecht, Dr Stefan Grümer.

insights into their current work, demonstrating the various application possibilities of laser.

In the afternoon, the DGL held its members' meeting. Directly afterwards, the scientific programme continued with interesting presentations by Prof. Gilles Chaumanet (Nice, France), Dr Michael Schaefer (Duesseldorf), Dr Rene Franzen (Aachen), Dr Darius Moghtader (Oppenheim, Germany), Dr Claudia Dehn (Bonn), Dr Florian Stelzle (Erlangen, Germany) and Dr Thorsten Kuypers (Cologne, Germany). Prof. Merita Bardhoshi (Tirana, Albania) finished the first day of the congress with a comparison of the treatment of vascular lesions in the oral and maxillofacial area with a 980 nm diode laser and with a conventional method. Participants of LASER START UP had the opportunity to learn about the fundamentals of laser and its various applications. In his welcome speech on Friday afternoon, Dr Bach addressed laser from a scientific perspective and from the viewpoint of established dentists. The topics of the presentations that followed included physical fundamentals of laser, and its application in implantology, oral surgery and endodontics. Speakers included well-known experts Dr Joerg Meister (Bonn) and Prof. Herbert Deppe (Munich, Germany).

On both congress days, participants were able to visit the dental exhibition during the breaks to learn about the latest developments in laser dentistry. On Friday evening, the first congress day ended with a social gathering at the dental exhibition, where participants further discussed the topics of the day in a relaxed atmosphere.

### Selecting the correct laser

On Saturday, the congress participants were offered another interesting programme. Dr Ralf Borchers (Buende, Germany) started the second day

off with a lecture on clinical experiences with perio green (elexxion). Afterwards, Dr Gottfried Gisler (Maennedorf, Switzerland) spoke about the use of laser in clinical emergency cases. He was followed by Prof. Gerd Volland (Heilsbronn, Germany), Giannis Papadimitriou (Duesseldorf), Dr Simona Baur (Zirndorf, Germany), Dr Carsten Philipp (Berlin) and Dr Michael Bauer (Kiel, Germany). In a workshop by Drs Detlef Klotz (Duisburg, Germany) and Peter Esser (Simmerath, Germany), the participants were advised on the correct billing of laser treatments.

Billing and the profitability of laser treatment were topics at LASER START UP too and the focus of a presentation by Dr Kuypers. The second day of the event also dealt with laser types and wavelengths, and selecting the correct laser in a panel discussion under the guidance of Dr Bach and Prof. Frentzen. In practical workshops led by Dr Moghtader, Dr Kresimir Simunovic (Zurich, Switzerland) and Prof. Volland, participants had the opportunity to learn about the practical application of laser systems offered by different companies.

Finally, participants of the DGL meeting and LASER START UP were brought together for a joint programme on Saturday afternoon, which included a lecture and panel discussion. The lecture covered laser as an interdisciplinary interface in dentistry from the perspective of a practice owner and was complemented by a panel discussion, which prompted lively professional exchange among the participants.

In 2015, the two events, which have been combined since 2009, will again take place jointly. On 27 and 28 November, the 24<sup>th</sup> Annual Congress of the DGL and LASER START UP 2015 will be held in Berlin.

[www.dgl-online.de](http://www.dgl-online.de)





PROFESSIONAL MEDICAL COUTURE



THE NEW 2014-2015 COLLECTION

EXPERIENCE OUR ENTIRE COLLECTION ON [WWW.CROIXTURE.COM](http://WWW.CROIXTURE.COM)



Henry Schein celebrates

## Opening of new UK headquarters



Almost a year after construction started, Henry Schein opened its new headquarters in the Gillingham Business Park at the beginning of October. The new state-of-the-art and energy-efficient facility, which includes two floors of office space and a warehouse, will serve as the main office and distribution centre for the company's dental and medical customers in the UK.

The new facility was built adjacent to the existing Henry Schein UK facility at the site, which was established in 1991. Its new warehouse includes an education centre with a showroom for product

demonstrations featuring a wide range of innovative high-tech digital technology. The company is also planning to develop additional warehouse space if more storage capacity is needed.

"This new, outstanding facility is a source of great pride for our company, underscoring our commitment to environmental sustainability, as the project's planning and construction has taken into account the impact on the surrounding environment," said Stanley M. Bergman, Chairman of the Board and CEO of Henry Schein, at the opening on 8 October, which was attended by over 500 people.

FDI opens online

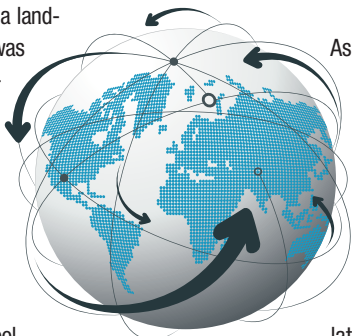
## Hub for global oral data

The FDI has opened its 'data hub for global oral health', an evolving online database of oral health statistics and indicators. It has started out with a limited amount of information but it is anticipated that the content will expand and deepen in the coming months.

The 'hub' has been developed under the guidance of the FDI Oral Health Atlas Task Team. The Oral Health Atlas has proved to be a landmark achievement since it was published in 2009; nevertheless, with data dating back, in some cases, to the 1990s, and only a limited number of indicators available, its information is now in need of an update.

From the perspective of health policy, the lack of oral health data has ham-

pered the World Health Organisation's (WHO) efforts to develop, for oral health, a comprehensive global monitoring framework including a set of indicators to monitor trends and to assess progress in the implementation of health care strategies and plans. Thus, it is anticipated that the 'data hub for global oral health' created by FDI will also help to provide a sound basis for a future global oral health monitoring framework.



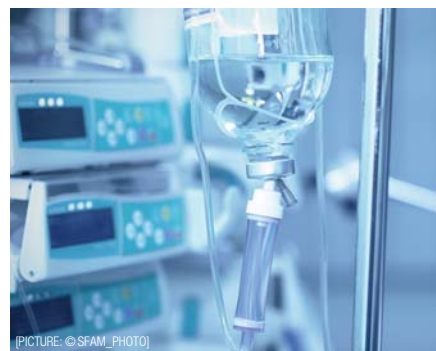(PICTURE: © SARUNYU\_FOTO)

As for content, the 'data hub' will cast the net much wider for information. For example, the crucial role of social determinants in oral health will make socio-economic data a key component. So will the data on incidence of Non-Communicable Diseases such as diabetes where a close relationship with oral disease has been clearly established.

Dental care may reduce

## Respiratory infection risk in ICU patients

In order to evaluate whether dental treatment may enhance oral antisepsis, thus preventing lower respiratory tract infections among critically ill patients more effectively, researchers at the University of São Paulo analysed data from 294 adult patients who had spent at least 48 hours in a general ICU. In addition to routine oral hygiene care, half of the patients in the study received enhanced dental care provided by a dental surgeon four to five times a week, while the control group received routine oral care only, which included the use of chlorhexidine as a mouth-rinse and was performed by ICU nursing staff three times a day. Enhanced dental care included tooth-brushing, tongue scraping, the removal of calculus, atraumatic restorative treatment of caries, and tooth extraction.



(PICTURE: © SFAM\_PHOTO)

Overall, dental treatment was considered to be safe and effective for the prevention of lower respiratory tract infections. The researchers suggested that the treatment provided by the dental surgeon helped prevent 56 per cent of infection episodes in the experimental group. In addition, the advent of death related to such infections was 38.1 per cent less in the experimental group than in the control group (3.9 per cent compared with 6.3 per cent).

Usually, oral care in ICUs around the world is performed by nursing staff. However, they do not have sufficient training or the legal authority to treat caries, remove calculus, drain intraoral abscesses, or perform tooth extractions, the researchers stated.

"This study suggests that having a dentist provide weekly care as part of the ICU team may improve outcomes for vulnerable patients in this setting," concluded lead author Dr. Fernando Bellissimo-Rodrigues.

UK dental industry pushes

## Campaign to contain influx of fake products



According to figures from the Medicines and Healthcare Products Regulatory Agency (MHRA) in London, over 12,000 individual pieces of counterfeit and unapproved dental products were seized in the UK up to April this year. At the BDIA Dental Showcase in October, the British Dental Industry Association (BDIA) announced that it will partner with major dental and general media outlets, including the BBC, to heighten awareness among dental professionals and the general public of the dangers these products can potentially pose. While they still represent a small market share, the number of substandard devices pur-

chased by dental professionals has steadily grown in recent years across all segments.

"We are now seeing copies and substandard versions of more complex devices, such as dental X-ray machines and handpieces, being increasingly purchased through the Internet and other sources," Bruce Petrie from the MHRA said. In order to address the situation, the agency in partnership with the BDIA launched the Counterfeit and substandard Instruments and Devices Initiative earlier this year, which aims to make more dentists aware of the problem and to report questionable products to the relevant authorities.

BDIA Executive Director Tony Reed commented, "We are pleased with the very positive reception that our initiative has received and the next step in growing awareness amongst the dental team is the launch of our advertising campaign."

BPA exposure may contribute to

## Asthma development in children

In the past, bisphenol A (BPA), an endocrine-disrupting chemical that can also be found in dental composites and sealants, has been linked to a number of health conditions, including obesity, allergies and cancer. Now, researchers have found evidence that prenatal exposure to BPA is associated with diminished lung function and the development of persistent wheeze in children, which are indicators for asthma, one of the most common chronic childhood disorders.

In order to examine the effect of BPA on lung function and wheeze in children, researchers at the University of Maryland School of Medicine followed women through pregnancy and their children through age 5. In total, the study included 398 mother-infant dyads. They collected maternal urine samples at 16 and 26 weeks of pregnancy and maternal urine samples annually to assess BPA exposure.

According to the study, prenatal BPA exposure during early pregnancy was associated with diminished lung function, increased likelihood of wheeze, and a persistent wheeze phenotype in young children.

According to estimates by the Centres for Disease Control and Prevention, about 7 million children under the



age of 18 are affected. Although secondhand smoke and air pollution have been identified as factors for the development of asthma in children, the reasons for increasing rates of the disease in the past decades are still poorly understood by scientists. The present study thus provides new evidence that BPA may contribute to this development.

Sirona and Boston University form

## First all-digital dental school

Sirona, the world's largest manufacturer of dental technology, has announced that it has recently entered into a unique digital dentistry partnership with the Boston University Henry M. Goldman School of Dental Medicine. Through the agreement, the school will become the first all-digital dentistry school in the US, providing dental students with the opportunity to learn about the current digital dentistry landscape in fully equipped operatories. The university will purchase digital equipment exclusively from Sirona in order to provide its dental students with access to a complete digital dentistry workflow, including both dental and laboratory techniques and applications. In addition, the school's Patient Treatment Centre, at which students provide affordable dental treatment, will be furnished with equipment from Sirona's CEREC, Schick, GALILEOS and inLab product lines.



In May 2013, the university established a special task force to implement digital dentistry at the dental school. With the goal of providing students with the tools to deliver the highest level of oral health care using digital dental technologies, the task force evaluated the facilities, equipment and technical support required to create a seamless all-inclusive system. Sirona was chosen as a partner in this project because the company offers a comprehensive product portfolio, strong technical support and seamless technology integration capabilities, the university stated.

"We are honoured to enter into this first of its kind endeavour with Boston University," said Sirona president and CEO Jeffrey Slovin. "Students will get to experience the true workings of a current dental practice environment and we commend the University for leading the way towards educating its students on using digital dentistry techniques. We are pleased to collaborate with Boston University in setting the stage for the future of dental education."



## FDI launches World Oral Health Day “Smile for life” campaign




Over 90 per cent of the world's population will suffer from some form of dental disease in their lifetime, but many of these diseases can easily be treated or prevented with a good oral care routine. The WOH 2015 “Smile for life” campaign includes a call to action (“It’s time to ...”), which campaigners can adapt to their local needs and circumstances.

Dentists at the FDI Annual World Dental Congress in New Delhi in September endorsed the “Smile for life” campaign both literally and figuratively when they

took turns to “Smile for life” in front of WOH 2015 campaign poster. FDI President Dr Tin Chun Wong commented, “The ‘Smile for life’ campaign reminds us that oral disease can be prevented by practising good oral hygiene throughout life, from childhood to mature adulthood. After tripling the number of countries celebrating World Oral Health Day between 2013 and 2014, we are now looking to reach an even larger audience in even more countries, as well as online.”

FDI Executive Director Jean-Luc Eiselé added, “We want to encourage everyone to celebrate this important day. Participants can download materials such as logos, posters and toolkits to plan their activities from the ‘Smile for life’ campaign website—where they can also read inspiring stories from last year’s campaign to help them plan their World Oral Health Day 2015.”

## First dental laser multi-centric research agreement Signed between dental schools from China and Israel



November 14, 2014, the first dental laser multi-centric research agreement was signed between Peking University School of Stomatology in China and The Hebrew University, Hadassah School of Dental Medicine the leading Dental University from Jerusalem, Israel. Initiated by Prof. Adam Stabholz, Prof. Chuanbin Guo and Mr. Ira Prigat, with a strong vision to offer better dentistry to patients, reduce dental fear, enhance prevention awareness and improve overall health of human being, the research collaboration between two coun-

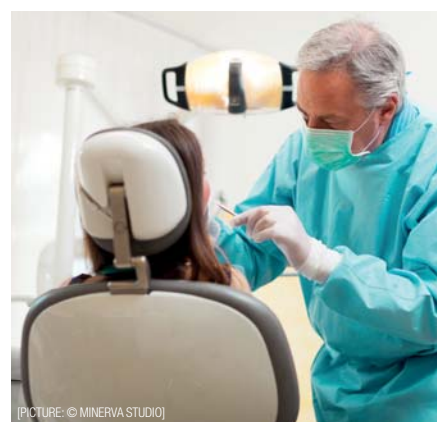
tries will bring significant impact on both dental and healthcare industry.

A special ceremony was hosted in the PKU School of Stomatology VIP reception room, Dean Prof. Chuanbin Guo and Dean Prof. Aharon Palmon signed the agreement. After the signing ceremony, an impressive academic symposium on dental laser application was held with outstanding lectures from both Israeli and Chinese dental laser professionals.



## Massive patient recall after Breach by dentist in Nottinghamshire

Thousands of patients treated by a dentist at Daybrook Dental Surgery in Gedling near Nottingham have been recalled by NHS England in Nottinghamshire to be tested for blood-borne viruses. Dr Desmond Jude D’Mello was recently suspended for 18 months by the General Dental Council for violation of cross-infection control standards in multiple cases.



Police are also investigating the death of a woman believed to have been treated by the dentist and who died of viral acute myocarditis last year. Charges against D’Mello arose after a whistle-blower sent secretly filmed footage to the NHS. Overall, he is believed to have treated more than 20,000 patients since he started practising at the clinic in the early 1980s.

While NHS investigations found that he did not carry blood-borne viruses himself, the patients he saw could have been placed at low risk of being exposed to Hepatitis B or C and HIV, Medical Director for NHS England in Nottinghamshire Dr Doug Black said. He said that his organisation is currently working with Public Health England and the General Dental Council to resolve the issue. Support is also being provided by Southern Dental, which has been running D’Mello’s former practice since August, according to Black. Patients believed to have been treated by the dentist are advised to contact the authorities for further advice. NHS has set up a community clinic at the health centre in Arnold, as well as a telephone line, to support patients treated by the dentist.

“Effective treatments are available for all blood-borne viruses,” Dr Vanessa MacGregor, Consultant in Communicable Disease Control for Public Health England in the East Midlands, said.

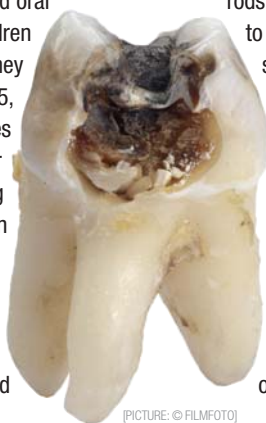

People with hair disorders

## May be prone to dental caries

US researchers have found that certain variants of keratin, proteins that are key structural components of hair, also help in the formation of tooth enamel. In order to establish a connection between hair disorders and susceptibility to dental caries, the researchers used genetic and oral examination data from 386 children and 706 adults. For their study, they focused on the protein keratin 75, because mutations in its genes have been linked to certain hair disorders, such as shaving bumps, persistent irritation caused by shaving.

The researchers observed that participants carrying mutations in keratin 75 had an increased



[PICTURE: © FILMFOTO]

number of cavities. In addition, they found that these participants had altered enamel structures and showed a marked reduction in enamel hardness, suggesting that hair keratins stabilise enamel tufts and rod sheaths to support enamel rods during their formation, which is similar to their function in supporting the hair shaft. Thus, they concluded that tufts and rods destabilised by the presence of the mutant protein have a reduced capacity to protect against caries.

These insights may help in the development of new strategies for combating tooth decay, the scientists believe. The disease affects 60–90 per cent of schoolchildren and nearly 100 per cent of adults worldwide.

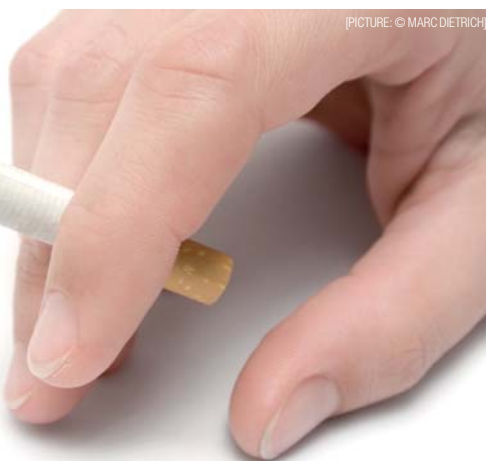Location of oral cancer

## Varies in smokers and non-smokers

Smoking and alcohol abuse are the most recognised factors in the causation of cancers of the oral cavity. However, a new 10-year study has shown that non-smokers too are at significant risk of oral squamous cell carcinoma. The study suggests that chronic dental or denture irritation in particular could be an important causative factor.

In order to determine whether oral cavity cancers occurred more commonly at sites of dental trauma, a comprehensive analysis of the medical records of 334 patients diagnosed with oropharyngeal cancer and 390 with oral cavity cancer was undertaken at Princess Alexandra Hospital in Brisbane between 2001 and 2011. Of the oropharyngeal cancer patients, almost 86 per cent were smokers or ex-smokers and about 14 per cent were non-smokers. Of the 390 patients with mouth cancer, 80 per cent were current or ex-smokers and about 20 per cent were non-smokers.

The researchers found that overall most mouth cancers occurred on the edge of the tongue.



[PICTURE: © MARC DIETRICH]

A significantly higher proportion of non-smokers (66 per cent, compared with 33 per cent in smokers), however, had mouth cancer in this location. In addition, they observed a higher incidence of mouth cancer in female non-smokers compared with male non-smokers.

As oral cavity cancers occurred predominantly at sites of potential dental and denture trauma, especially in non-smokers without other risk factors, the researchers concluded that the irritant effect of chronic dental trauma may induce the development of oral cavity cancers on the lateral tongue.

Google Glass may

## Obstruct peripheral vision

Interest in wearable head-mounted display systems such as Google Glass is increasing, even in the dental setting. However, their effect on vision is still largely unknown. Now, researchers from the University of California, San Francisco, have found that the glasses partially obstructed peripheral vision.

In order to assess the effect of the head-mounted device on visual function compared with regular eyewear, the researchers performed perimetric visual field tests with three healthy individuals who used Google Glass in accordance with the manufacturer's instructions for 60 minutes. Afterwards, the test was repeated with the participants wearing a control frame of similar colour and temple width.



[PICTURE: © HATTANAS KUMCHAI]

According to the researchers, the testing demonstrated significant scotomas, also known as blind spots, in all three participants while wearing the device, creating a visual field obstruction in the upper right quadrant. The scotomas were due to the frame design only and not to software-related interference, they said.

In addition, 132 photographs of people wearing Google Glass were analysed to assess how the device is worn by general consumers. The researchers stated that many wear the device almost overlapping their pupillary axis, which may induce scotomas and thus interfere with daily activities (such as driving), pedestrian safety, and sports.

# laser

international magazine of laser dentistry



## Publisher

Torsten R. Oemus  
[oemus@oemus-media.de](mailto:oemus@oemus-media.de)

## CEO

Ingolf Döbbecke  
[doebbecke@oemus-media.de](mailto:doebbecke@oemus-media.de)

## Members of the Board

Jürgen Isbaner  
[isbaner@oemus-media.de](mailto:isbaner@oemus-media.de)

Lutz V. Hiller  
[hiller@oemus-media.de](mailto:hiller@oemus-media.de)

## Editor in Chief

Norbert Gutknecht  
[ngutknecht@ukaachen.de](mailto:ngutknecht@ukaachen.de)

## Coeeditors in Chief

Samir Nammour  
Jean Paul Rocca

## Managing Editors

Georg Bach  
Leon Vanweersch

## Division Editors

Matthias Frentzen  
*European Division*

George Romanos  
*North America Division*

Carlos de Paula Eduardo  
*South America Division*

Toni Zeinoun  
*Middle East & Africa Division*

Loh Hong Sai  
*Asia & Pacific Division*

## Senior Editors

Aldo Brugniera Junior  
Yoshimitsu Abiko  
Lynn Powell  
John Featherstone  
Adam Stabholz  
Jan Tuner  
Anton Sculean

## Editorial Board

Marcia Martins Marques, Leonardo Silberman, Emina Ibrahimi, Igor Cernavin, Daniel Heysselaer, Roeland de Moor, Julia Kamenova, T. Dostalova, Christliebe Pasini, Peter Steen Hansen, Aisha Sultan, Ahmed A Hassan, Marita Luomanen, Patrick Maher, Marie France Bertrand, Frederic Gaultier, Antonis Kallis, Dimitris Strakas, Kenneth Luk, Mukul Jain, Reza Fekrazad, Sharonit Sahar-Helft, Lajos Gaspar, Paolo Vescovi, Marina Vitale, Carlo Fornaini, Kenji Yoshida, Hideaki Suda, Ki-Suk Kim, Liang Ling Seow, Shaymant Singh Makhan, Enrique Trevino, Ahmed Kabir, Blanca de Grande, José Correia de Campos, Carmen Todea, Saleh Ghabban Stephen Hsu, Antoni Espana Tost, Josep Arnabat, Ahmed Abdullah, Boris Gaspirc, Peter Fahlstedt, Claes Larsson, Michel Vock, Hsin-Cheng Liu, Sajee Sattayut, Ferda Tasar, Sevil Gurgan, Cem Sener, Christopher Mercer, Valentin Preve, Ali Obeidi, Anna-Maria Yannikou, Suchetan Pradhan, Ryan Seto, Joyce Fong, Ingmar Ingenegeren, Peter Kleemann, Iris Brader, Masoud Mojahedi, Gerd Volland, Gabriele Schindler, Ralf Borchers, Stefan Grümer, Joachim Schiffer, Detlef Klotz, Herbert Deppe, Friedrich Lampert, Jörg Meister, Rene Franzen, Andreas Braun, Sabine Sennhenn-Kirchner, Siegfried Jänicke, Olaf Oberhofer, Thorsten Kleinert

## Editorial Office

Georg Isbaner  
[g.isbaner@oemus-media.de](mailto:g.isbaner@oemus-media.de)

Claudia Jahn  
[c.jahn@oemus-media.de](mailto:c.jahn@oemus-media.de)

Katrin Maiterth  
[k.maiterth@oemus-media.de](mailto:k.maiterth@oemus-media.de)

## Executive Producer

Gernot Meyer  
[meyer@oemus-media.de](mailto:meyer@oemus-media.de)

## Designer

Sarah Fuhrmann  
[s.fuhrmann@oemus-media.de](mailto:s.fuhrmann@oemus-media.de)

## Customer Service

Marius Mezger  
[m.mezger@oemus-media.de](mailto:m.mezger@oemus-media.de)

## Published by

OEMUS MEDIA AG  
Holbeinstraße 29  
04229 Leipzig, Germany  
Tel.: +49 341 48474-0  
Fax: +49 341 48474-290  
[kontakt@oemus-media.de](mailto:kontakt@oemus-media.de)  
[www.oemus.com](http://www.oemus.com)

## Printed by

Silber Druck oHG  
Am Waldstrauch 1  
34266 Niestetal, Germany

**laser** international magazine of laser dentistry  
is published in cooperation with the World  
Federation for Laser Dentistry (WFLD).

## WFLD Headquarters

University of Aachen Medical Faculty  
Clinic of Conservative Dentistry  
Pauwelsstr. 30, 52074 Aachen, Germany  
Tel.: +49 241 808964  
Fax: +49 241 803389644  
[ngutknecht@ukaachen.de](mailto:ngutknecht@ukaachen.de)  
[www.wfld-org.info](http://www.wfld-org.info)


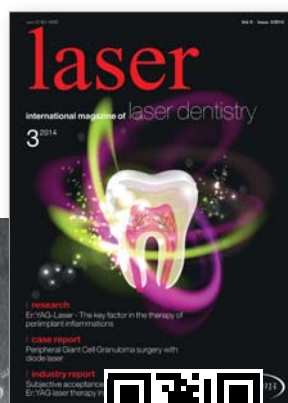

[www.laser-magazine.com](http://www.laser-magazine.com)

## Copyright Regulations

**laser** international magazine of laser dentistry is published by OEMUS MEDIA AG and will appear in 2014 with one issue every quarter. The magazine and all articles and illustrations therein are protected by copyright. Any utilization without the prior consent of editor and publisher is inadmissible and liable to prosecution. This applies in particular to duplicate copies, translations, microfilms, and storage and processing in electronic systems.

Reproductions, including extracts, may only be made with the permission of the publisher. Given no statement to the contrary, any submissions to the editorial department are understood to be in agreement with a full or partial publishing of said submission. The editorial department reserves the right to check all submitted articles for formal errors and factual authority, and to make amendments if necessary. No responsibility shall be taken for unsolicited books and manuscripts. Articles bearing symbols other than that of the editorial department, or which are distinguished by the name of the author, represent the opinion of the afore-mentioned, and do not have to comply with the views of OEMUS MEDIA AG. Responsibility for such articles shall be borne by the author. Responsibility for advertisements and other specially labeled items shall not be borne by the editorial department. Likewise, no responsibility shall be assumed for information published about associations, companies and commercial markets. All cases of consequential liability arising from inaccurate or faulty representation are excluded. General terms and conditions apply, legal venue is Leipzig, Germany.

# The editors of laser would like to thank all authors for dedicating their time and efforts to this year's issues.



## Issue 1/2014

Prof. Dr Nobert Gutknecht, Germany  
 Prof. Dr Aslan Yaşar Gokbuget, Turkey  
 Necla Aslı Kocak, Turkey  
 Dr MeritaBardhoshi, Albania  
 Dr. Esat Bardhoshi, Albania  
 Jan Tunér, Sweden  
 Dr Carlo Fornaini, Italy  
 Dr Maziar Mir, Germany  
 Dr Masoud Mojahedi, Germany  
 Dr Hassan Adalatkhah  
 Dr Amir Mansour Shirani, Iran  
 Dr Masoud Shabani, Iran  
 Giovanni Olivi, Italy  
 Matteo Olivi, Italy  
 Maria Daniela Genovese, Italy  
 Dr Anna Maria Yiannikos, Germany & Cyprus

## Issue 2/2014

Jan Tunér, Sweden  
 Prof. Dr Nobert Gutknecht, Germany  
 Roeland Jozef Gentil De Moor, Belgium  
 Maarten Meire, Belgium  
 Dr Christina Boutsiouki, Germany  
 Dr Dimitris Strakas, Greece  
 Dr Fabrice Baudot, France  
 Dr Kresimir Simunovic, Switzerland  
 Assoc. Prof Dr Sajee Sattayut, Thailand  
 Assist. Prof Dr Piyachat Pacharanuchat, Thailand  
 Assoc. Prof Suwit Undompanich, Thailand  
 Dr Anna Maria Yiannikos, Germany & Cyprus

## Issue 3/2014

Dr Frank Liebaug  
 Dr Ning Wu, China  
 Prof. Dr Nobert Gutknecht, Germany  
 Dr Brice Savard, France  
 Roeland Jozef Gentil De Moor, Belgium  
 Maarten Meire, Belgium  
 Dr Maziar Mir, Germany  
 Dr Masoud Mojahedi, Germany  
 Jan Tunér, Sweden  
 Dr Amir Mansour Shirani, Iran  
 Dr Masoud Shabani, Iran  
 Ass. Prof. Ani Belcheva, Bulgaria  
 Maria Shindova, Bulgaria  
 Prof Dr Jean-Paul Rocca, France  
 Dr Sylvaine Lesnik-Cannavo, France  
 Prof Dr Carlo Fornaini, Italy

## Issue 4/2014

Prof. Dr Nobert Gutknecht, Germany  
 Prof. Dr Praveen R. Arany, USA  
 Prof. Ass. Merita Bardhoshi, Albania  
 Prof. Ass. Edit Xhajanka, Albania  
 Dr Esat Bardhoshi, Albania  
 Dr Alketa Qafmolla, Albania  
 Dritan Gjini, Albania  
 Elda Gjini, Albania  
 Dr Fabrice Baudot, France  
 Dr Zulala Tasneem, India  
 Dr Salika Sheikh, India  
 Dr Rahul Kale, India  
 Dr Naresh Thukral, India  
 Dr Sangeeta Muglikar, India  
 Dr Anna Maria Yiannikos, Germany & Cyprus  
 Dr Dimitris Strakas, Greece  
 Dr George Freedman, Canada

PICTURE: ©SERGEY NIKENIS

# Publish -your- expertise

Hand in your article.

Please contact:

Editorial manager  
 Georg Isbaner  
[g.isbaner@oemus-media.de](mailto:g.isbaner@oemus-media.de)

Editor  
 Katrin Maiterth  
[k.maiterth@oemus-media.de](mailto:k.maiterth@oemus-media.de)



Fotona<sup>®</sup>  
choose perfection




The first digitally controlled  
dental laser handpiece

## X-Runner<sup>TM</sup>

- instantly adjustable spot size and shape
- precise coverage of large areas
- lightweight, ergonomic design
- for Fotona LightWalker AT laser systems

50 years  
of Fotona laser innovations



The universe at your fingertips.

• LightWalker<sup>®</sup>