

Use of a **full-arch** bridge in the **maxilla**

A case report

Author_Dr Dr Richard Marcelat, France

_In dental implantology, optimal and truly passive fit of the framework is mandatory due to the physiology of bone tissue around implants.

Actually, it is key to the long-term success of a restoration. As a matter of fact, for a multiple-unit implant-supported restoration, a traditional pouring technique is rather complex and challenging. The difficulty to achieve a passive fit is directly correlated with the number of components used and the volume of the framework. In contrast, CAD/CAM technology provides such a high level of accuracy that it has revolutionised the field of restorative dentistry. Today, many implant

manufacturers partner with industrial companies to develop state-of-the-art machining solutions for their implant-supported frameworks. In that regard, the concept developed by Simeda® is innovative and yet supported by many years of proven success in the fabrication of CAD/CAM dental restorations. The major advantage of CAD/CAM technology is that it guarantees a highly accurate and predictable fit (<10 microns). This clinical case is very representative of the high potential of this novel digital solution.

_Patient Presentation

This male former smoker patient was 51 years old when the treatment was initiated. He presented with high blood pressure and took Tahor® on a daily basis. In addition, he had been on Kardegic® therapy since his heart attack in 2005. For functional and aesthetic reasons, he wanted a fixed prosthesis in his maxillary arch (Figs. 1a & b).

_Debridement and pre-implant surgery

Due to the periodontal condition of his remaining maxillary teeth, all of them were atraumatically removed. Then, an alveolar curettage was performed

Fig. 1a_Initial status.

Fig. 1b_Preoperative panoramic X-ray.

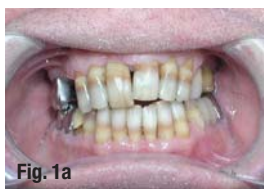

Fig. 1a

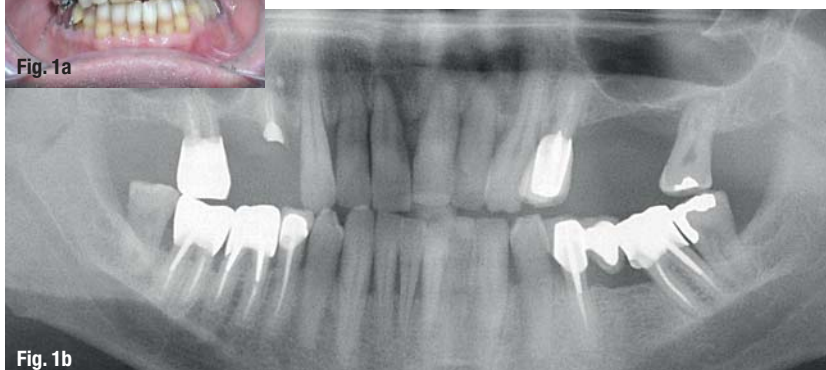

Fig. 1b

through mechanical debridement and copious irrigation with Betadine®. A maxillary complete overdenture was fabricated and placed on the same day of the extractions.

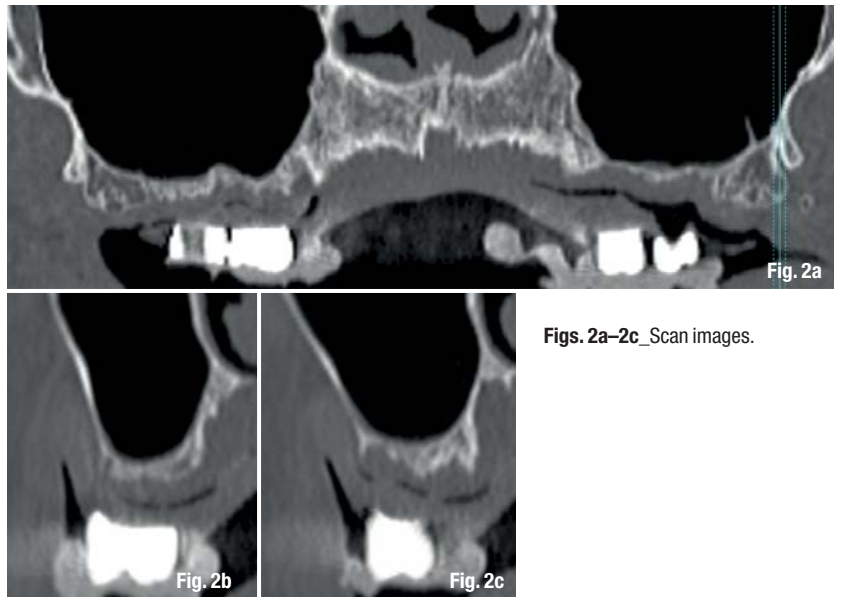After a healing period of 4 months, Dentascans were obtained to evaluate the bone heights. The scans showed significant bone resorption in the posterior sectors of the maxilla (Figs. 2a–c): SA-4 according to the Misch classification, since classification was a residual ridge height less than 5 mm. Sinus grafting was necessary and implant placement had to be delayed by 5–6 months, until complete healing and good initial stability were achieved. Bilateral sinus lift was performed under local anaesthesia from a lateral approach using the technique described by Tatum. The Schneider membrane was gently lifted. As there were no perforations, PRF was used for coverage of the sinus floor. Maxgraft® allografts were placed to elevate the maxillary sinus floor, and then coated with a Bio-Gide® collagen membrane and PRF. After a healing period of 5 months, the patient underwent CT scan, wearing the scan prosthesis that consisted in acrylic resin and commercially available teeth for visibility of the desired tooth location in CT images (Fig. 3). CT examination showed an adequate bone volume in the grafted posterior regions, and an even sinus floor with homogeneous allografted areas. The dome-like shape of the vestibulo-lingual cross-sections was indicative of the absence of material leakage into the maxillary sinuses (Fig. 5a).

Osteogenic activation

I performed an osteogenic activation of the processed Maxgraft® bone used for sinus lift elevation using the technique described by Scortecchi. A transparietal approach was used for insertion of the matrix osteotensors following a minimally-invasive flapless protocol (Fig. 4). Endosteal stimulation results in osteogenic activation and allows the evaluation of the mechanical strength of the grafted areas to probing. Thanks to this simple and minimally-invasive technique, the initial quality of the future recipient bone site is easily assessed. These techniques have been successfully used in orthopaedics for ten years. In view of the excellent response to osteogenic activation, it was decided that implants would be placed 45 days later.

Treatment planning

The case was planned in the SIMPLANT® treatment planning software. The scan prosthesis is critical for determination of the correct position and axial alignment of the implants, visualisation of the emergence profile, and determination of the size, position and axial alignment of the abutments. Furthermore, it allows making the most use of the available bone height. At this stage, special attention should be paid to 3-D positioning of



Figs. 2a–2c Scan images.

the implants and more particularly to the emergence profile in order to facilitate the fabrication process of the final restoration. Straight or angled conical abutments are now clearly visible on the vestibulo-lingual cross-sections. Ten Anthogyr AX-IOM® PX implants were planned for a maxillary screw-retained bridge restoration (Figs. 5a–c).

Implant placement

Implant placement was performed under local anaesthesia using the case-specific surgical guide. For this patient, I used a specific implant design (Axiom® PX) with symmetrical double-lead threads (self-drilling and self-tapping) and a reverse conical neck (Fig. 6). Its unique design combined with a special drilling protocol promotes bone condensation even in soft bone, which ensures excellent initial fixation. The BCP (biphasic calcium phosphate) sandblasting technique provides an implant surface with superior osteoconductive properties which positively influence the development of osteoblastic cells in the early stage of osseointegration. A flapless technique was used for implant placement. The flapless technique has clear-cut advantages: preservation of the subperiosteal blood vessels.

Temporary bridge and immediate loading

It was agreed with the patient that the implants would be immediately loaded provided that good initial stability was obtained. This way, the temporary removable prosthesis would be worn for a limited time. Fortunately, adequate stability was achieved, allowing for immediate loading. Each implant (except number 27) was torqued to ≥ 35 Ncm or more. The same day, an impression was made using the pick-up technique, with a previously prepared impression tray. First, the final straight conical abutments were hand-tightened into the im-

Fig. 3_Scan prosthesis.

Fig. 4_Osteotensor.

Figs. 5a & b_Implant placement planning in SIMPLANT® software.

Figs. 5c-d_CT cross-sections.

Fig. 6_Anthogyr AXIOM® PX implant.

Fig. 8_Healing status at 6 months postoperative.

Fig. 7a_Panoramic X-ray showing the temporary bridge placed 48 hours earlier.

Figs. 7b & c_High-rigidity temporary bridge made of CoCr and Resin.

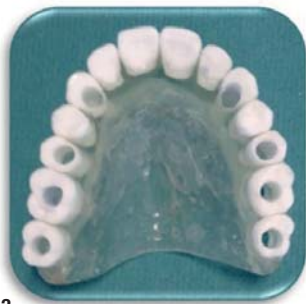

Fig. 3

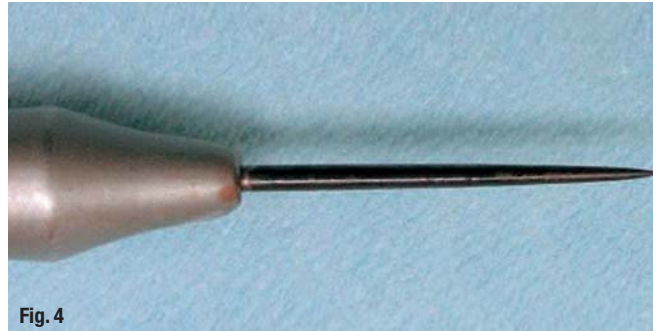


Fig. 4

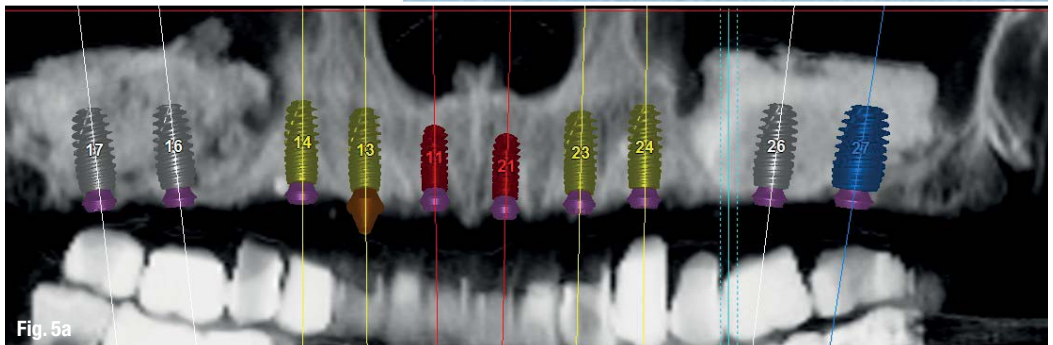


Fig. 5a

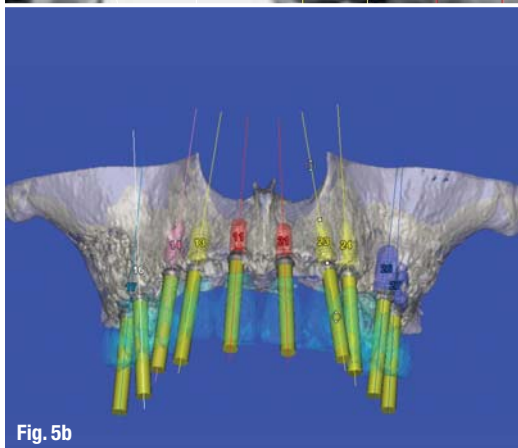


Fig. 5b

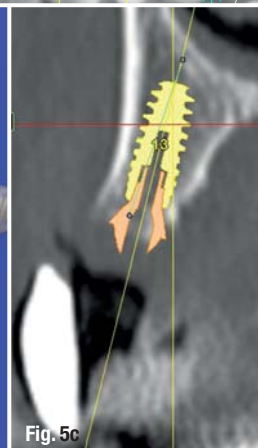

Fig. 5c

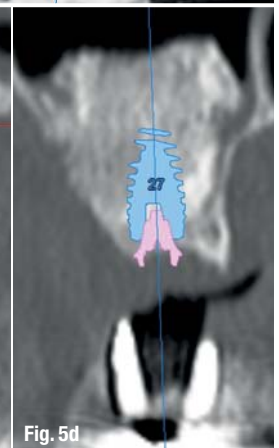


Fig. 5d



Fig. 6

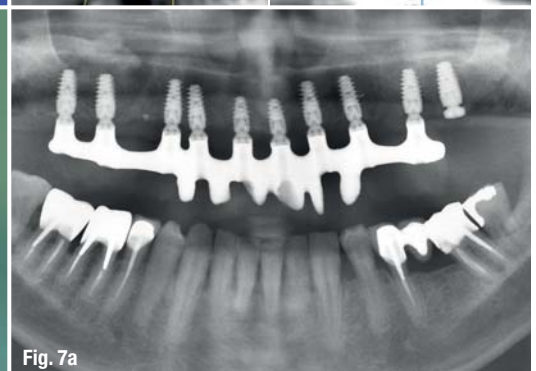

Fig. 7a

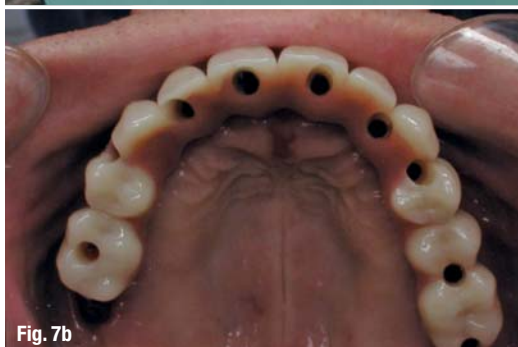

Fig. 7b

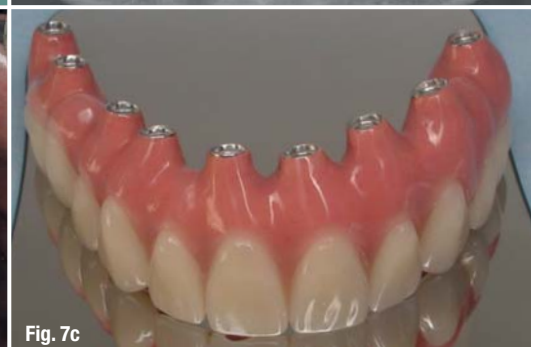
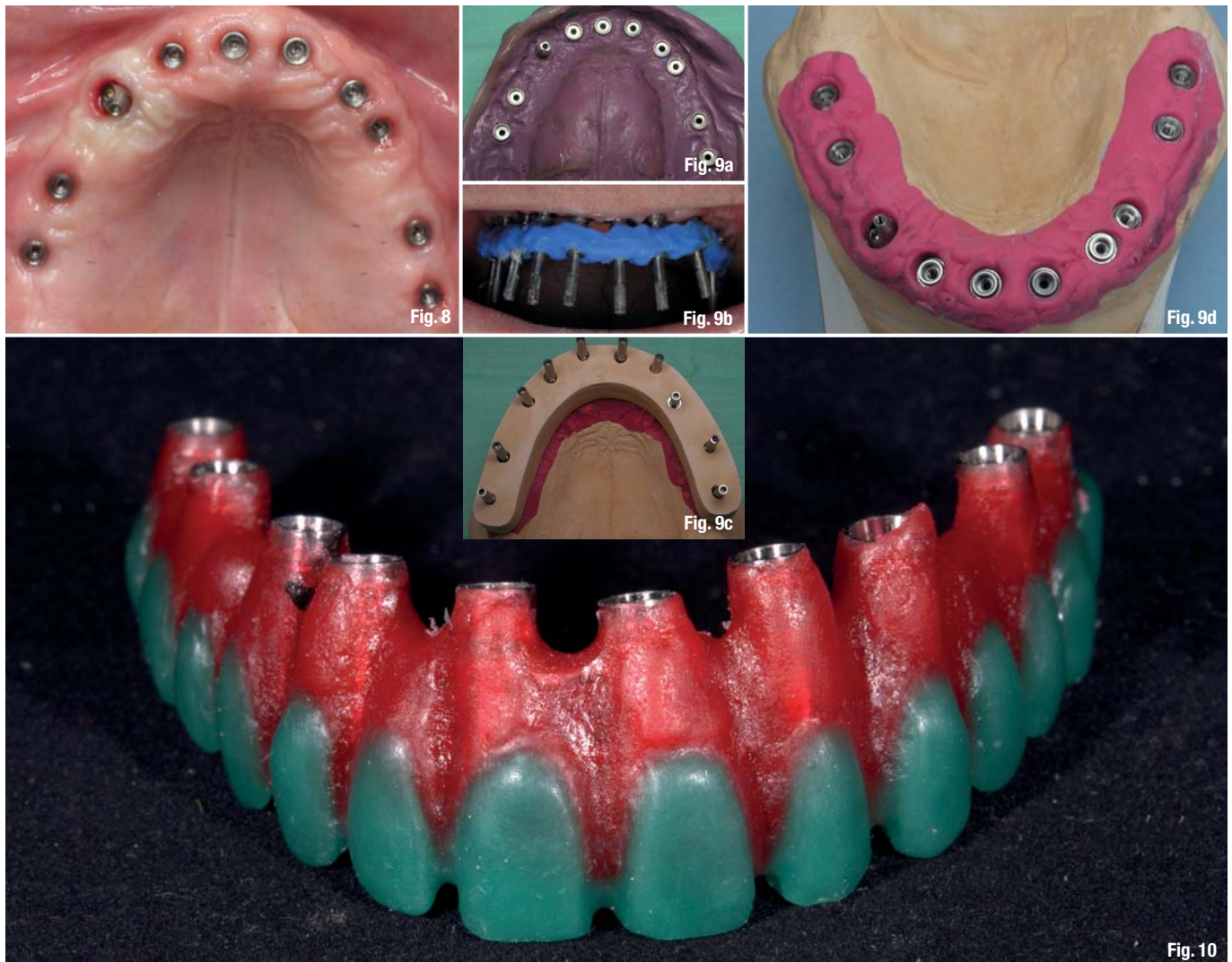
Fig. 7c



plants using a torque of 15 Ncm. They were intended to accommodate the screw-retained provisional, then the final screw-retained prosthesis. The AXIOM® PX implant system offers two major advantages: platform switching and indexing trilobe Morse taper connection. The latter greatly facilitates abutment placement. A tight stable connection guarantees integrity of the soft tissue (Fig. 8). In the laboratory, the master model with the embedded analogs was used to fabricate a master plaster cast. A high-rigidity CoCr/resin temporary bridge was fabricated, tried in, and transferred to the patient's mouth 48 hours after the implants had been placed. This provisional device would serve as an external fixator during osseointegration of the implants. A control X-ray was taken to confirm the passive fit of the framework. The temporary bridge was hand-tightened to a torque of 10 Ncm. Occlusion was accurately adjusted (Figs. 7a-c). The patient wore the temporary bridge for 6 months. During that period, a number of parameters were evaluated, including: occlusion, osseointe-

gration status, oral hygiene, mastication, phonetics, aesthetics, lip support etc. The temporary bridge should be rigid (framework) while easily removable (screw fixation). Site 27 healed uneventfully, protected as it was from mechanical stress.

Final bridge

At the end of the 6-month healing period, preparation for the final restoration could start. Wearing the temporary bridge had allowed adjustment of the above mentioned parameters (i.e. aesthetics, phonetics, lip support) and validation of the vertical dimension and intermaxillary relationship. The temporary bridge was removed, an implant stability percussion test was performed, and control X-rays were taken. The straight conical abutments that had been placed concomitantly with the implants were tightened to 25 Ncm (as recommended by the manufacturer), except abutment 23,

Fig. 8 Healing status at 6 months postoperative.

Fig. 9a Impression.

Fig. 9b Pick-up transfer copings interconnected.

Fig. 9c Wax bite block.

Fig. 9d Master model.

Fig. 10 Wax-up of the framework.



Fig. 11a SimedaScan.

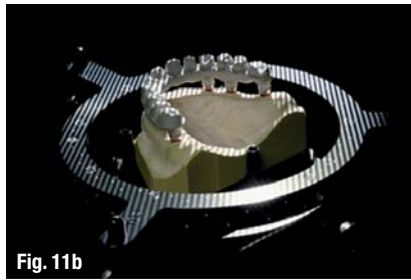


Fig. 11b

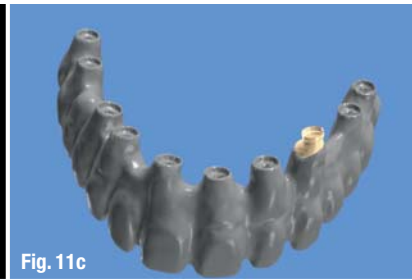


Fig. 11c

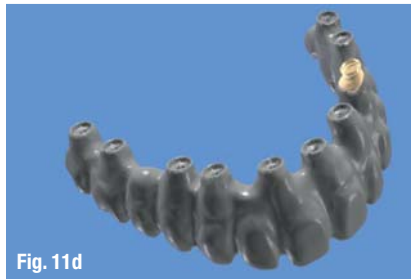


Fig. 11d



Fig. 12a




Fig. 12b

Fig. 12c

Fig. 11b_Master Model Scanning.

Figs. 11c & d_CAD model.

Figs. 12a-c_Machined from a titanium block.

which was angled (Fig. 8). Impression of the final bridge was taken with the same impression tray as for the temporary bridge. Pick-up transfer copings were interconnected using Luxabite® resin, and the impression was made using Impregum®. The master model including the conical abutment analogs and silicone soft tissue (representing the patient's gingiva) was fabricated, then validated in the dentist's office via a wax bite block (into which extra hard plaster material was poured). Then, the wax bite was tried in (Figs. 9a-d). Using silicone indexes (vestibular, occlusal, palatal) from the temporary bridge, a wax-up was fabricated in the laboratory (Fig. 10). The wax-up must meet the aesthetic demand of the patient and should be the exact replica of the temporary bridge (both anatomically and aesthetically). The validated master model and wax-up were forwarded to the Sameda® machining centre where the master model was scanned. Then, a CAD model was designed (Figs. 11a-d). A PDF3D file is used to validate the design, after which the manufacturing process can be initiated. All

pieces are machined from titanium blocks using high-precision 5-axis milling machines (Figs. 12a-c).

Titanium is a lightweight material, and more importantly, it is highly biocompatible and has superior mechanical properties. It is four times lighter than commonly used semi-precious alloys. Actually, it is the lightest metal used in dentistry. Furthermore, titanium is a self-passivating metal: it readily reacts with oxygen in air to form a tough layer of oxide which protects from corrosion. Titanium is known to resist extremely well to corrosion and chemical attacks. It also has an additional key advantage for a dental implant: it is bactericidal. Material density is a crucial factor in implantology. We believe that the weight of a maxillary implant-supported prosthesis is the most important factor in influencing the outcome of the restoration.

A few days later, we received the framework for a try-in. It had a perfect passive fit and was returned to the laboratory for veneering. First lab steps are metal preparation: sandblasting, titanium etching and application of opaquer porcelain to conceal the metal core. Then, the bisque bake was tried in to allow the patient to validate the aesthetics of the restoration. This step is necessary to assess static and dynamic occlusion and perform minor adjustments (Figs. 13a & g). The bisque bake was then returned to the laboratory for fine-tuning and glazing.

_CAD/CAM benefits

Although conventional casting techniques have evolved, they are still fraught with inaccuracies due to the nature itself of the materials and to their handling. This includes: risk of errors during investment processing, risk of metal deformation, poor metal homogeneity etc. The CAD (computer-aided design) and CAM (computer-aided manufacturing) technologies used

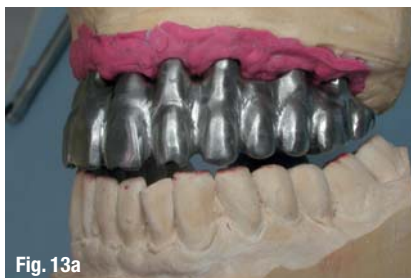

Fig. 13a

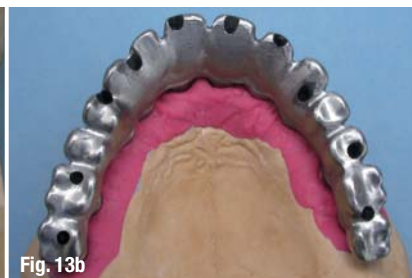

Fig. 13b

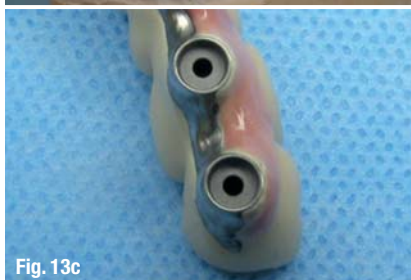

Fig. 13c

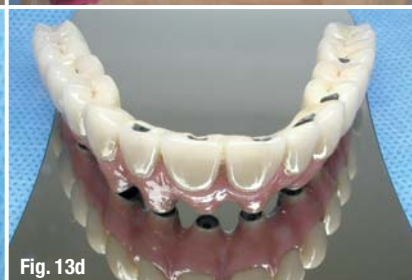

Fig. 13d

YES!



2015
Years
Implantology.

I WANT THE COMPLETE CAD/CAM SOLUTION.

Innovation has a name: **tioLogic® digital**. Your step towards digital implantology. Say yes!

Visit us!
10. – 14. March 2015
Hall 10.1 Stand E10/F11

IDS
2015



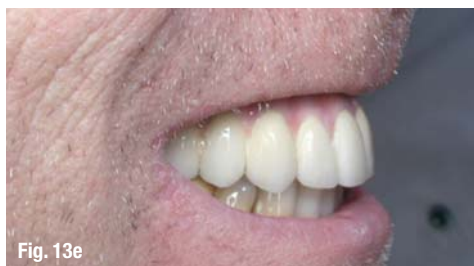

Fig. 13e

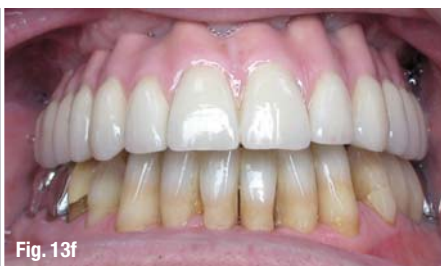

Fig. 13f

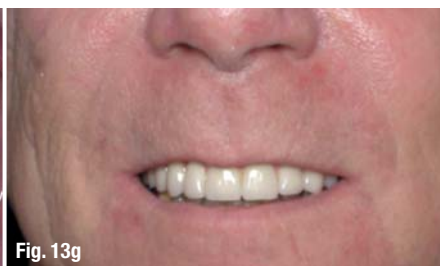

Fig. 13g

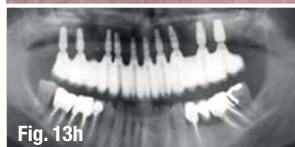

Fig. 13h

Fig. 13g_Patient's new smile.

Fig. 13h_Postoperative panoramic X-ray with bridge in place.

for metal frameworks are key to the quality of the final restoration (Fig. 13i). The CT scan data is converted into a format that allows the 3-D images to be utilised by the selected treatment planning software. The case is then planned in the software. CAD softwares have databases that allow creating virtual models of the desired restoration using different materials: zirconia, titanium, CoCr, E-max, PMMA etc. If the dental laboratory has its own scanner, an STL file is sent directly to the production centre by email. Otherwise, both the model and the wax-up are forwarded to the production centre via UPS. If computer settings are correct, you are ensured of a perfect reproducibility of the manufacturing process and consistency of the result (i.e. a truly passive framework fit). Optimal setting of the coping thickness parameter or the pontic connection parameter may prevent torsion or deformation of the framework during firing (baking) of the ceramic.

Subtractive manufacturing combined with digital modelling eliminates the risk of alteration of the material structure. The resulting metal framework will have optimal homogeneity and density. As regards fabrication of implant suprastructures, machining is definitely the technique of choice to achieve high precision and near passive fit. Practitioners can expect consistent and reproducible results, excellent framework fit, and regular, accurate prosthetic seals.

Conclusion

Today, dental laboratories are using high-tech scanning equipment, which allows digitisation of the master model (to determine the implant index) and the wax-up. CAD/CAM offers a level of quality and accuracy yet unsurpassed by any of the traditional techniques. Pas-

sive fit which is critical to the outcome of an implant-supported prosthesis is a determinant of the long-term success of a restoration. Passive fit of the framework for a long-span restoration is much easier to achieve and reproduce with CAD/CAM than with the traditional pouring techniques.

The use of CAD/CAM machining for implant-supported restorations guarantees a highly accurate and predictable framework fit (<10 microns). In addition, machining centres can produce fully biocompatible materials such as titanium and zirconia. To take advantage of the accuracy of CAD/CAM, it's required to use safe and reliable implant systems with superior biological and biomechanical characteristics.

CAD/CAM will soon be a must-have. Current CAD/CAM solutions are easily accessible to any dentist while not changing fundamentally their work habits.

Thanks to G. Nauzes and J. Bellany, Laboratory Technicians (Socalab® laboratory).

contact

Dr Dr Richard Marcelat

Post-graduate Certificate in Implantology, CURAIO, Lyon

Academic Degree in Oral Implantology, Corte
Academic Degree in Basal Implantology, Nice
11 cours des Platanes

26130 Saint Paul trois châteaux, France

Tel: +33 475960011

richard.marcelat@orange.fr

Fig. 13i_Overview of Simeda® process stages.

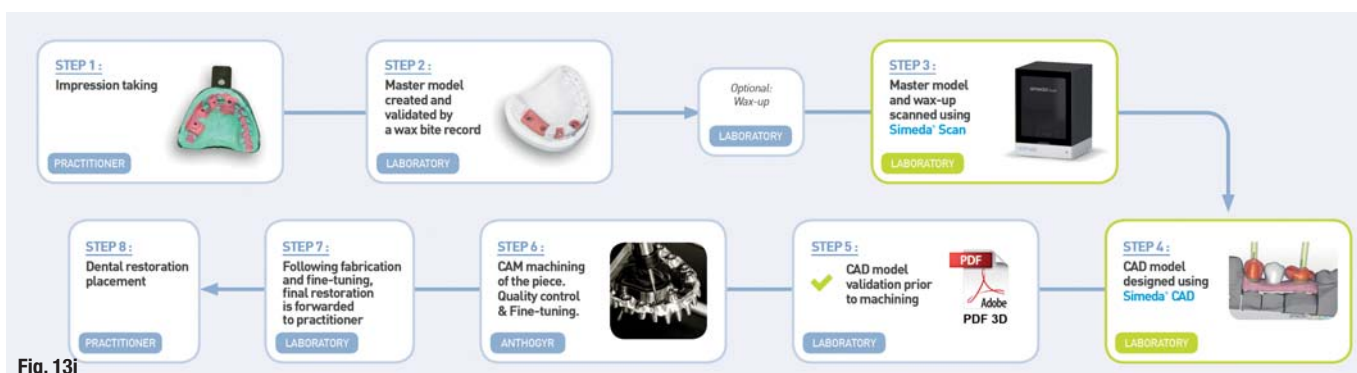
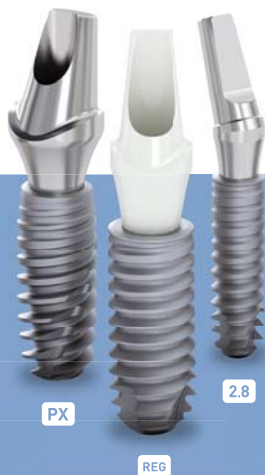

Fig. 13i

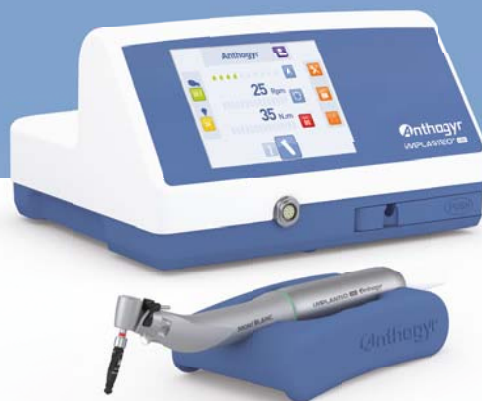axiom®



simeda®
customized
& digital
solutions



iMPLANTEO® LED



→ **IMPLANTS:**

Axiom®, a comprehensive solution for all clinical indications.

→ **DIGITAL:**

Simeda® **CAD-CAM** solution, guided surgery.

→ **EQUIPMENT:**

Motors, contra-angles, surgery and implantology handpieces, dynamometric wrench, bone collector, automatic crown and bridges remover.

→ **SERVICES:**

Dental implantology seminars, patient education program.

