

# Modification of tooth neck dentin with a diode laser for desensitisation

**Author\_**Dr Ute Ulrike Botzenhart, Germany

“Cervical dentin hypersensitivity is a common phenomenon of discomfort, which affects an increasing number of young adults.”



[PICTURE: ©VLADIMIR GJORGIEV]

Cervical dentin hypersensitivity is a common phenomenon and affects an increasing number of young adults. Today, more than 30% of the adult population in industrialised nations is affected, but the number of unreported cases is presumably much higher and treatment demand is increasing.<sup>1</sup> Patients who are affected report intense and sharp pain of short duration during eating or dental hygiene, for example, that cannot be ascribed to any other form of dental defect or disease.<sup>2</sup> Dentine hypersensitivity is associated with exposure of dentine at the cemento-enamel junction and can be explained by the combined effect of several aetiological factors, such as erosion, abrasion and attrition

with erosion as the main factor.<sup>3,4</sup> Other factors, like microbiological invasion of exposed dentinal tubules with accompanying inflammation of pulpal tissue, functional overload, traumatic toothbrushing and whitening of vital teeth, also appear to be involved.<sup>5,6</sup>

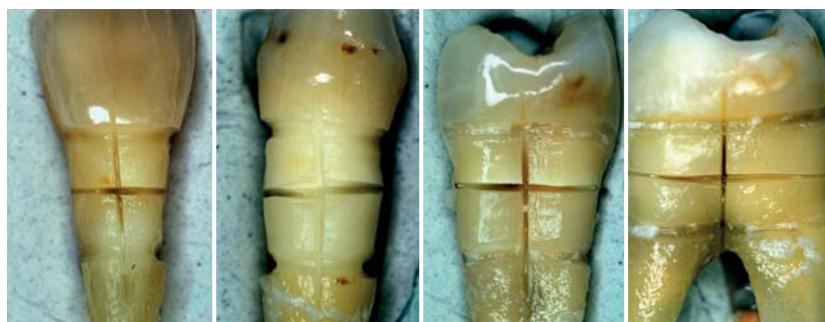To date, the commonly accepted theory of pain transmission is still Brännström's hydrodynamic theory.<sup>7</sup> It states that chemical, mechanical, osmotic and thermal stimuli induce fluid flow in exposed dentinal tubules, activation of mechanoreceptors at the pulp-dentine border and finally activation of pain fibres. The structure of the dentinal surface is

an important factor of this mechanism.<sup>8</sup> Examination of tooth necks under a scanning electron microscope (SEM) has shown that affected teeth had eight times as many exposed tubules with a diameter twice the size compared with non-sensitive dentine.<sup>8</sup> By demonstrating that the density of sensitive nerve fibres is correlated to pain intensity of a sensitive tooth,<sup>9</sup> it is also assumed that, in addition to the hydrodynamic theory, other mechanisms, such as nerve stimulation, could be involved. Thus, inflammation mediators could make nerve endings more sensitive to mild stimuli, which could induce pain.<sup>10</sup> Nevertheless, the precise physiological mechanisms underlying dentine hypersensitivity are not clearly understood yet,<sup>11, 12</sup> and despite intensive research, constant improvement of therapy methods and active substances, reports still show that there is difficulty controlling this painful condition.<sup>11</sup>

Laser treatment of dentine hypersensitivity alone or in combination with conventional treatments is a new promising option for rapid and durable pain relief.<sup>13</sup> Depending on the laser type and energy settings used, the actual reported effects of laser desensitisation are morphological alteration of the dentinal structure, for example a closure of the dentinal tubules by melting and resolidification of the dentinal structure; laser dehydration with protein deposition or deposition of insoluble salts in the dentinal tubules; as well as bio-stimulation, for example nerve analgesia, induction of sclerosis and secondary dentine formation; and placebo effects. Recently, great effort has also been made to integrate tooth structure-like components into the tooth surface with the help of laser radiation.<sup>11, 14–17</sup>

However, on account of the high temperature increase, these methods are not suitable for clinical application<sup>11, 16</sup> and too little is known about the long-term morphological and clinical effects of laser application to recommend the therapy.

The aim of our study was to examine the effects of a diode laser with a wavelength of 809 nm in the treatment of dentine hypersensitivity in terms of morphological changes. The ability of this type of laser to close open dentinal tubules, its suitability as a method for dentinal sealing, as well as the induction of recognisable morphological side-effects in the dentinal structure using this laser, were tested *in vitro*. Furthermore, the effect of laser–fluoride application was compared with single treatment options, and the acid resistance of the tested treatment modalities (fluorides, laser, and laser–fluoride treatment) was evaluated by the method of pH-cycling.



## Material and methods

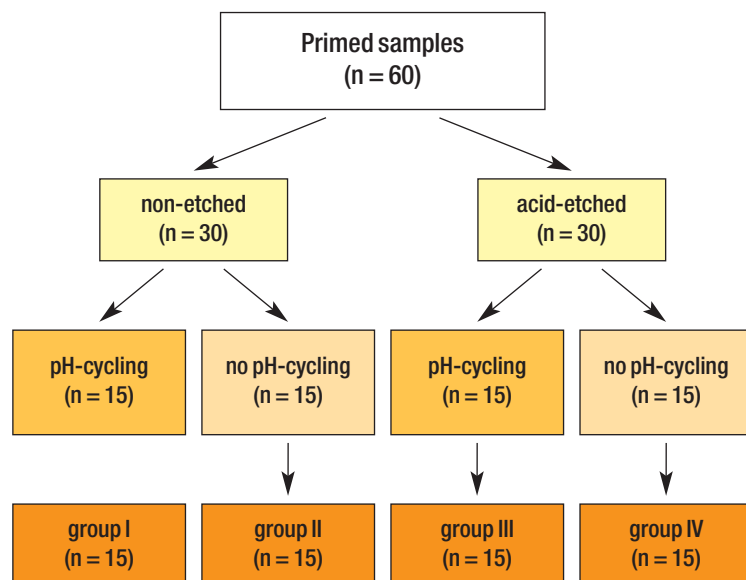
The samples used were extracted human teeth drawn from a pool of extracted teeth collected for dental research at the University Bonn, Dental Clinic once informed consent had been obtained. Surgical treatment was not linked to research in any way. All experiments were *in vitro*; hence, there were no potential risk factors to human health.

Immediately after extraction, the teeth were stored in a sodium chloride solution (0.9% NaCl, Delta-Pharma) with 0.01‰ sodium acid added and kept refrigerated at 5 °C to prevent the teeth drying out and to minimise bacterial and chemical decomposition. Teeth without carious lesions at the tooth neck and root surface ( $n = 60$ ) were divided into four groups of 15 teeth by random selection. Every test group had the same number of incisors, canines, premolars and molars from the maxillae and mandible (four maxillary incisors, one maxillary canine, two maxillary premolars, two maxillary molars, one mandibular canine, three mandibular molars and two mandibular third molars). The incisors of the mandibular arch were exchanged for third molars because the small root surface did not allow preparation of a quadrangle. The experimental surface was located at the vestibular, mesial or distal side of the root surface. Four quadrants were marked in the cervical area (Fig. 1).

Enamel and root cementum were completely removed with diamond burs under water-cooling (INTRAmatic LUX 24, KaVo) by one operator to simulate hypersensitive dentine. With removal of a 1 mm layer, we assumed that all dentinal tubules had been totally exposed. The sample surface was smoothed with a Gracey curette (#7–8; Thico-dent) and divided into quadrangles with a diamond separating disc (0.5 mm thick) under water-cooling (INTRAmatic 10 C, KaVo; Fig. 1).

Groups 3 and 4 underwent a pretreatment (acid etching with 50% citric acid for 2 minutes, rinsing with distilled water for 30 seconds) to remove the smear layer created by preparation.

**Fig. 1** Samples of (a) Incisor, (b) Canine, (c) Premolar and (d) Molar after quadrangle preparation in the tooth neck area.



**Fig. 2** Flow chart to illustrate group assignment with the help of test procedure.

The test groups were as follows (Fig. 2): Groups 1 and 2 with smear layer and Groups 3 and 4 with removal of the smear layer. Quadrant 1 of each sample underwent laser application. Quadrant 2 underwent laser application followed by fluoridation. Quadrant 3 underwent fluoridation exclusively. Quadrant 4 was left untreated as a control.

The diode laser used had a wavelength of 809 nm (ORA-Laser 01 I.S.T., ORALIA). The parameters were chosen according to Gutknecht et al.,<sup>18</sup> who used an Nd:YAG laser for cervical desensitisation, because the action mechanism of both laser types is approximately similar.<sup>19</sup> The laser parameters were 1 W, 10 Hz and 60 seconds in contact mode with a 400 µm fibre in an overlapping flap. The surface of each quadrant was approximately 3–5 mm<sup>2</sup>. Owing to the penetration depth of the laser radiation used, an absorber (Contactin CO) was also used in 50 % of the samples. For fluoridation, we used Bifluorid 12 (VOCO), which was left to react for 1 minute and afterwards rinsed with water spray.

**Tab.1** Results of statistical analysis of the histological examination of group I (with smear layer, with pH-cycling) and group III (without smear layer, with pH-cycling);  $p = 0.05$ .

After the treatment, all teeth of Groups 1 and 3 underwent pH-cycling for ten days according to Ten Cate et al.<sup>20</sup> as a post-treatment to simulate the conditions of the oral cavity. The teeth subsequently underwent histological and SEM examination.

	Mann-Whitney-U-Test (laser with absorber – laser without absorber)	Friedmann-Test
group I	$p > 0.05$	$p < 0.05$
group III	$p > 0.05$	$p > 0.05$

### SEM examination

Six samples from each group ( $n = 6$ ), three with and three without absorber application prior to laser treatment, were prepared for SEM examination. We used the replica technique to evaluate morphological changes and to make it possible to perform histological examination of the samples afterwards. For the replica technique, we took impressions of the samples with a light-body silicone (PRESIDENT PLUS JET light body, Coltène AG), allowed them to dry for four weeks and cast them in epoxy resin (Stycast 1266, Part A + B, T-E-Klebertechnik). The resin samples were attached to a table for SEM examination, sputter coated with a thin layer of platinum (15 W and 22 mA for 70 seconds) and mounted on the specimen stub with a conductive bridge using a special adhesive for SEM examination (Leit-C nach Görke, Neubauer Chemikalien) to ensure electrical grounding.

The observation of the samples was performed under high vacuum and in direct mode at an angle of 40 degrees, an accelerating voltage of 10 kV and 3 A, and at a magnification of 2,000x.

### Histological examination

All samples ( $n = 60$ ) were prepared for histological examination by formalin fixation (4 %, pH of 6.9), followed by dehydration in alcohol of progressive concentrations, embedding in Technovit 7200 VLC (Heraeus Kulzer), cutting, grinding (EXAKT grinding unit), fixation to an object plate (Technovit 4000 VLC, Heraeus Kulzer) and burnishing to a thickness of 20–30 µm each, so that every preparation contained two quadrants of each sample. The sections were dyed with toluidine blue according to Donath et al.<sup>21</sup> and analysed with the DIALUX 20 EB (LEITZ) light microscope at a magnification of 25x. Four samples had to be excluded afterwards because of artificial alterations or incomplete removal of the enamel or root dentine, which could only be detected with light microscopy. Therefore, 56 samples with four quadrants each were examined histologically.

### Statistical analysis

For histological examination, we used non-parametric tests (Mann-Whitney test, Friedman test and Wilcoxon signed-rank test). The various morphological effects we found under SEM examination were first analysed qualitatively by one operator and then analysed using the chi-square test. For all statistical analyses, we used SPSS (IBM Software) and the significance level was  $p = 0.05$ .

### Results

#### Histological examination

In the histological examination, major structural changes in the dentine were not observed, regard-

less of the treatment modality we used. After laser irradiation, no carbonisation, cracks or other side-effects could be detected.

In Groups 2 and 4 (without pH-cycling), no structural effects were observed, whereas changes of different width indicated by staining were recorded in Groups 1 and 3 (with pH-cycling). These patterns were measured at three points and the average value was calculated (Fig. 3). With the help of a measuring scale, the width of these patterns was converted into micrometres. There was no statistically significant difference between the effect of the laser with or without absorber application in Groups 1 and 3 (Mann-Whitney test,  $p > 0.05$ ; Table 1). In Group 3 (without a smear layer), no statistically significant differences between the different surface treatments and the width of the pattern were observed (Friedman test,  $p > 0.05$ ; Table 1), whereas statistically significant differences in Group 1 (with a smear layer) in the width of the pattern were found (Friedman test,  $p < 0.05$ ; Table 1) after fluoridation and after laser irradiation (Wilcoxon signed-rank test,  $p < 0.05$ ; Mann-Whitney test,  $p < 0.05$ ; Table 2). After fluoridation, the average width of these patterns was approximately 43  $\mu\text{m}$  compared with 60  $\mu\text{m}$  after laser irradiation.

#### SEM examination

Under SEM examination, ultrastructural changes in the dentinal structure were observed. Six different structural and morphological markers were recorded:

1. Wide-open tubules (Fig. 4a)
2. Partly occluded or narrowed tubules (Fig. 4b)
3. Surfaces with impressions of tubule orifices (Fig. 4c)
4. Smooth and unstructured surfaces (Fig. 4d)
5. Surfaces with superficial precipitation (Fig. 4e)
6. Melted surfaces (Fig. 4f).

In a few cases, cracks and superficial pellets were observed, but the results were not predictable. After qualitative analysis of these structural changes, statistical analysis was performed using the chi-square test ( $p = 0.05$  significance level).

No statistically significant differences between laser application in Groups 1–4 with or without absorber application (chi-square test,  $p > 0.05$ ) and in Groups 1, 2, 3 and 4 with and without absorber application prior to laser treatment combined (chi-square test,  $p > 0.05$ ) were observed (Table 3).

AD

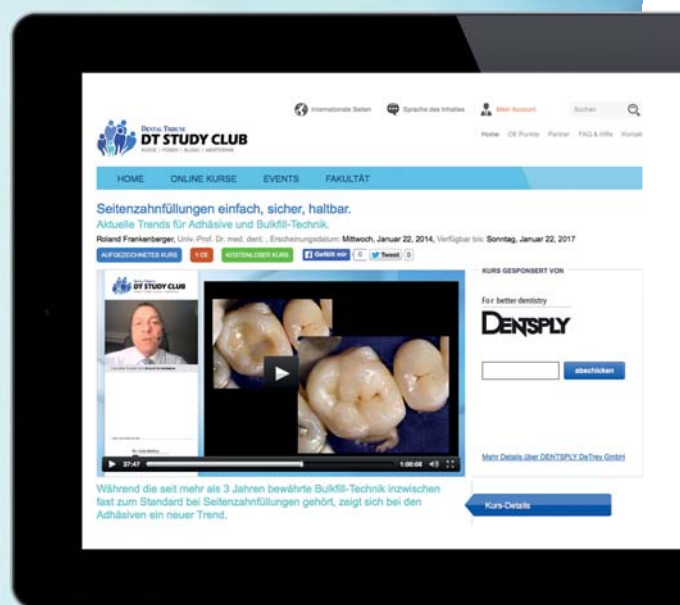
# Join the largest educational network in dentistry!

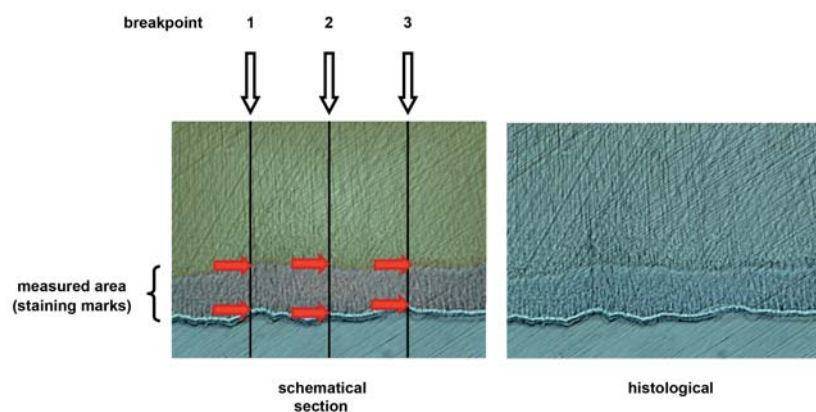


Register for  
**FREE!**

- education everywhere and anytime
- live and interactive webinars
- more than 500 archived courses
- a focused discussion forum
- free membership
- no travel costs
- no time away from the practice
- interaction with colleagues and experts across the globe
- a growing database of scientific articles and case reports
- ADA CERP-recognized credit administration

[www.DTStudyClub.com](http://www.DTStudyClub.com)





**Fig. 3** Left side: Schematic illustration of the detected pattern with breakpoints. White arrows are showing the measure points (black lines); red arrows illustrate the width of the pattern (red band); deep dentin is marked in yellow. Right side: Original specimen.

Furthermore, we analysed samples in relation to pre- and post-treatment, that is, with smear layer removal and pH-cycling. Figure 2 provides an overview of the pre- and post-treatment classification of the groups. In all samples with a smear layer (Groups 1 and 2 combined), no statistically significant differences were observed (chi-square test,  $p > 0.05$ ; Table 3), whereas statistically significant differences between the treated quadrants in all samples with the smear layer removed (Groups 3 and 4 combined) were detected (chi-square test,  $p < 0.05$ ; Table 3). After laser application and after laser-fluoride application, fewer wide-open and partly occluded tubules, and smooth and unstructured surfaces were observed. Melted surfaces predominantly were detected after laser and after laser-fluoride application. Regarding all samples with pH-cycling (Groups 1 and 3 combined) and without pH-cycling (Groups 2 and 4 combined), no statistically significant differences were observed (chi-square test,  $p > 0.05$ ; Table 3).

## Discussion

The histological and SEM examinations demonstrated that the application of a diode laser (809 nm, 1 W, 10 Hz, 60 seconds) did not induce harmful mor-

phological changes in the dentinal structure, but led to ultrastructural modification of the superficial dentinal layer. Since the degree of pain is strongly correlated to the number of open tubules at the dentinal surface<sup>10</sup>, removal of the smear layer prior to treatment best simulated hypersensitive dentine. Accordingly, under SEM examination, a great number of open tubules were observed in the control quadrants in Groups 3 and 4.

### Results after laser-fluoride treatment

Laser-treated surfaces with a smear layer showed narrowing or complete closure of the dentinal tubules, but the results were not statistically significant. In comparison to the control and fluoridation, a statistically significant reduction in the number of open tubules was found after laser and laser-fluoride treatment of acid-etched surfaces. This demonstrated that laser application can induce sealing of hypersensitive dentine to some extent. These results are in accordance with those of Umana et al.,<sup>19</sup> who evaluated the effect of 810 nm, among others, diode laser application (Claros Nano, Elxxion) at different energy settings on human dentinal surfaces after removal of the smear layer. With an energy setting of between 0.8 W and 1 W (continuous wave, non-contact mode for 10 seconds), they found a narrowing of dentinal tubule orifices, and hence deduced that the diode laser was able to seal dentinal tubules.

In our study, melted surfaces predominantly were detected after laser application with statistical significance in Groups 1 and 3. Laser application followed by fluoridation appeared to enhance the occluding effects, but this was not of statistical significance. Melting of dentinal surfaces after laser application using different parameters with or without fluoridation has also been described previously.<sup>22-24</sup> Marchesan et al.<sup>25</sup> too demonstrated such a melting

**Tab. 2** Results of statistical analysis of the histological examination of group I (with smear layer, with pH-cycling);  $p = 0.05$ .

	Wilcoxon-Test	Mann-Whitney-U-Test
laser + fluoridation – laser (with/ without absorber)	$p > 0.05$	$p > 0.05$
fluorides – laser (with/ without absorber)	$p > 0.05$	$p > 0.05$
control – laser (with/ without absorber)	$p > 0.05$	$p > 0.05$
fluorides – laser + fluorides (with/ without absorber)	$p > 0.05$	$p > 0.05$
control – laser + fluorides (with/ without absorber)	$p > 0.05$	$p > 0.05$
control – fluorides (with/ without absorber)	$p > 0.05$	$p > 0.05$



# Master of Science (M.Sc.) in Lasers in Dentistry

**Next Start:**      **21<sup>st</sup> September 2015**  
Aachen, Germany  
4 semesters

## Become part of the International Dental Elite

- Create new economic potential for your practice
- Two year career-accompanying postgraduate programme at the University of Excellence RWTH Aachen
- Combination of lectures, skill training sessions, live ops, tutorials, and practical workshops
- Internationally accepted and accredited by the German Government, the European Union, the Washington Accord and the Bologna Process
- Science-based and practice-orientated on highest national and international level
- Increased patient satisfaction: minimal contact reduced vibration and pain



**RWTH INTERNATIONAL  
ACADEMY  
AACHEN UNIVERSITY**

RWTH International Academy  
Kackertstraße 10 | 52072 Aachen | Germany  
phone +49 241 80 23543 | fax +49 241 80 92525  
info@academy.rwth-aachen.de  
www.academy.rwth-aachen.de

**PROFESSIONAL EDUCATION PROGRAMMES**

**AALZ**

**Aachen Dental Laser Center**

AALZ GmbH  
Pauwelsstraße 17 | 52074 Aachen | Germany  
phone +49 241 47 57 13 10 | fax +49 241 47 57 13 29  
info@aalz.de  
www.aalz.de

effect after laser irradiation of water-filled root canals with a diode laser (980 nm).

#### Comparison with Nd:YAG laser application

The appearance of a smooth, unstructured surface with few wide-open or partly occluded tubule orifices after diode laser application and diode laser–fluoride treatment is comparable to the effects of Nd:YAG laser application, which is already known for its ability to close dentinal tubules<sup>26</sup> and for its sealing effects on root dentine.<sup>23</sup> A direct comparison of these two laser types by irradiating root canal dentine found morphological changes, such as melting and setting of the dentinal surface, but without any statistically significant differences between both laser types.<sup>27</sup>

In our study, laser–fluoride application was not found to be statistically significantly superior to laser irradiation alone. However, such a tendency could be seen. In the literature, we can also find no clear results concerning this, but a combined treatment is preferred in most cases.<sup>28,29</sup> A combined *in vivo* application of Nd:YAG laser and fluoridation, for example, achieved an improvement of symptoms that correlates to the *in vitro* reduction of open tubule orifices.<sup>30</sup>

#### Effects after additional absorber application

Although the application of an absorber prior to laser treatment enhanced the absorption at the sur-

face,<sup>31</sup> in some cases under SEM examination after laser application isolated side-effects, such as cracks, were detected, and this phenomenon could possibly be traced back to the absorber effect. In their study, Umana et al.<sup>19</sup> proved that the additional application of an absorber enhanced the laser effects, resulting in areas of fusion, melting and narrowing of the tubules, when energy settings of 0.8 W and 1 W were used. At higher energy settings (1.6 W and 2 W), not only complete occlusion of the tubules, but also cracks, dental ablation, craters and loss of substance could be seen.<sup>19</sup> The occurrence of side-effects with the 1 W output power used in our study could probably be explained by the longer exposure time of 60 seconds compared with 10 seconds in Umana et al.'s study.

Since we only observed superficial effects, we could not evaluate the penetration depth of the detected cracks. Concerning the histological examination, no cracks were found, so we assumed that they were only located in the very superficial dentinal layer and therefore of negligible clinical relevance. Concerning safety and clinical effectiveness, the energy setting of 1 W does not exceed the safety level of 3 °C for pulp injury and is harmless for pulp vitality.<sup>19</sup> Human *in vivo* studies have shown that the diode laser can be a useful instrument in clinical dentine desensitisation.<sup>32–36</sup>


The clinical effectiveness was approximately 86–88% with no differences between the different laser parameters used.<sup>36</sup> An exposure time of 60 seconds, compared with shorter irradiation times, clinically results in immediate pain relief.<sup>33</sup> No side-effects were observed<sup>34</sup> and a persistent clinical reduction of dentine hypersensitivity after laser use was observed during the follow-up period of up to six months.<sup>32,34</sup>

#### Results with and without pH-cycling

With the energy settings used in our study, side-effects were neither predictable nor statistically significant. In general in our study for all treatment groups, no statistically significant improvement was achieved by the additional use of an absorber prior to laser application or with laser–fluoride application, and absorber application did not induce additional detectable morphological effects at the surface in the majority of cases.

Under SEM examination, no statistically significant morphological differences between cycled and non-cycled groups were observed, whereas patterns of different width were detected after pH-cycling of non-etched and acid-etched samples under histological examination. The acid resistance of tooth surfaces can be detected with pH-cycling. From other studies, it is known that the application of fluorides can enhance the acid resistance of dental surfaces.<sup>37,38</sup>

**Fig. 4** Overview of the detected morphological effects in SEM examination after experimental setup (2000x, 40°). (a) wide opened tubuli, (b) partly opened tubuli, (c) impressions of tubuli orifices, (d) unstructured and smooth surface, (e) precipitates, (f) melted surface.



	Chi-square-Test (laser application with absorber) n = 3	Chi-square-Test (laser application without absorber) n = 3	Chi-square-Test (laser application with/without absorber) n = 6	Chi-square-Test n = 12
group I	p > 0.05	p > 0.05	p > 0.05	
group II	p > 0.05	p > 0.05	p > 0.05	
group III	p > 0.05	p > 0.05	p > 0.05	
group IV	p > 0.05	p > 0.05	p > 0.05	
group I+II (with smear layer)				p > 0.05
group III+IV (without smear layer)				p < 0.05
group I+III (with pH-cycling)				p > 0.05
group II+IV (without pH-cycling)				p > 0.05
group I-IV (with absorber)				p > 0.05
group I-IV (without absorber)				p > 0.05

The dimension of the pattern we detected after pH-cycling in Groups 1 and 3 was not dependent on removal of the smear layer. In fact, it was dependent on pH-cycling, because without pH-cycling (Groups 2 and 4) such a pattern could not be detected. Concerning these facts, the width of detected patterns in this study could be associated with demineralisation and remineralisation and be connected to the acid resistance of the treated dentinal samples. We assumed that the width of the pattern was inversely proportional to acid resistance; that is, it is consistent with the amount of demineralisation. Thus, an enhancement of acid resistance was demonstrated with reduced pattern width. This was the statistically significant finding after fluoridation compared with laser application in Group 1. We assumed that on surfaces with a smear layer fluorides were more easily incorporated into the dentinal surface and served as a depot. This was first used up after acid contact. In the histological examination, reduced demineralisation width was observed for this reason. In patients with hypersensitive tooth necks, in most cases, a relatively uniform and amorphous smear layer is missing, there are more areas with wider tubule orifices and sometimes even loss of intertubular dentine compared with non-sensitive tooth necks.<sup>39</sup>

Clinical observations have demonstrated at least a temporary reduction of pain after a single fluoride application.<sup>32</sup> So the question is, whether the effects detected after pH-cycling and fluoridation can enhance and sustain acid resistance *in vivo*.

#### *Acid resistance after fluoride application*

Our study demonstrated a statistically significant association between fluoride application and an enhancement of acid resistance on smear layer-afflicted surfaces only. With removal of the smear layer, no differences between the treatment modalities were observed. We assumed that fluoridation of a surface without a smear layer did not exceed the effects achieved with laser application or laser-fluoride treatment. Clinical investigations of such a combined treatment with fluoridation found no additional positive effect,<sup>34</sup> and this result is in agreement with the morphological findings of our *in vitro* study. Furthermore, laser application or a combined treatment on acid-etched surfaces was not inferior to fluoridation alone. An improvement in acid resistance has been observed when fluorides are applied prior to laser application.<sup>40</sup> Hsu et al.<sup>22</sup> demonstrated such a combined treatment with melting and setting of the dentinal surface in an *in vitro* study. Further

**Tab. 3** Results of statistical analysis of morphological effects depending on surface treatment in SEM examination; p = 0.05.

analysis demonstrated that laser application could stove constituents of the smear layer to the dentinal surface so that there was an integration of fluorides and of parts of the smear layer.<sup>24</sup>

In our study, we applied fluorides after laser irradiation; therefore, stoving was not likely. Nevertheless, we assumed that fluorides were more easily integrated into the lased surface, which served as a depot and improved acid resistance to some extent.

## Conclusion

Diode laser desensitisation of exposed tooth necks following the treatment protocol we used was not accompanied by major side-effects and led to a variety of morphological effects, which appear to be useful for sealing hypersensitive dentine and increasing acid resistance in some areas. In light of possible additional biostimulatory effects, it may even offer a treatment alternative to the application of fluorides only. However, further studies are necessary to prove the quality of the described morphological effects under clinical conditions.

## Acknowledgments

I would like to thank the AMLaReBO (Centre of Applied Medical Laser Research and Biomedical Optics, Bonn), the research platform RIsources (The research Infrastructure Portal) funded by the DFG (Deutsche Forschungsgemeinschaft) for material support and the consistent professional support and helpful hints by Prof. Dr M. Frentzen, PD Dr A. Braun during the experiments and realisation of the study as well as Mrs M. Lange for technical support. This work had not been possible without their help. The authors claim no conflict of interests.

## contact

### Dr Ute Ulrike Botzenhart

Fetscherstr. 74  
01307 Dresden, Germany  
Tel.: +49 351 4584481  
Fax: +49 351 4585318

Ute.Botzenhart@uniklinikum-dresden.de

## Kurz & bündig

Zahnfleischüberempfindlichkeit ist ein allgemeines Problem und stellt eine der häufigsten schmerzverursachenden Symptomatik dar.<sup>1</sup> In vorliegender Studie wurden morphologische und histologische Effekte sowie eine mögliche Dentinversiegelung nach *In-vitro*-Anwendung eines 809-nm-Diodenlasers zum Verschluss offener Dentintubuli im Zahnhalsbereich evaluiert.

Als Versuchspräparate dienten dabei extrahierte menschliche Zähne, die in 4 Gruppen aufgeteilt wurden. Zur Simulation überempfindlichen Dentins wurden im Zahnhalsbereich Schmelz und Zement mit einem Diamantbohrer abgetragen und ein Versuchsfeld mit je 4 Quadranten präpariert. In Gruppe I und II wurde die entstandene Schmierschicht belassen, während diese in Gruppe III und IV mittels Säureätzung entfernt wurde. Quadrant 1 und 2 wurden mit einem Diodenlaser bestrahlt. Quadrant 2 und 3 wurden anschließend fluoridiert. Quadrant 4 blieb als Kontrolle unbehandelt. Bei 50 Prozent der Proben wurde vor der Laserapplikation zusätzlich ein Absorber appliziert. Alle Proben der Gruppe I und III wurden anschließend zur Überprüfung der Säurefestigkeit für zehn Tage einer Wechselbehandlung unterzogen. Die histologische und rasterelektronenmikroskopische Auswertung erfolgte sowohl qualitativ als auch mittels Chi-Quadrat-, Mann-Whitney U- und Friedman-Test.

Wie die histologische Untersuchung zeigte, wurden keine Risse, Karbonisierungen oder andere Laser-Nebeneffekte festgestellt. Verglichen mit den Gruppen ohne Wechselbehandlung, die keine Effekte erkennen ließen, zeigten die Gruppen mit Wechselbehandlung Veränderungen unterschiedlichen Ausmaßes im Dentin, die sich in Form eines Bandenmusters darstellten und in Verbindung mit einer reduzierten Säureresistenz gebracht werden konnten. Nach Laserbestrahlung konnte in der rasterelektronenmikroskopischen Darstellung in Gruppe III und IV eine statistisch signifikante Reduktion offener Dentintubuli festgestellt werden.


Bezogen auf morphologische Effekte kann eine Laserbestrahlung exponierter Dentintubuli im Zahnhalsbereich zu einer ultrastrukturellen Veränderung oberflächlichen Dentins mit einem teilweisen Anstieg der Säureresistenz führen. Ausgehend von den Untersuchungen können aber für den Diodenlaser als Desensibilisierungsmittel keine direkten Rückschlüsse auf die klinische Situation, insbesondere bezogen auf mögliche biostimulative Effekte, die diesem Lasertyp ebenfalls zugesprochen werden, getroffen werden. Die Ergebnisse der vorliegenden Arbeit liefern aber eine Orientierung der Auswahl geeigneter Laserparameter für die klinische Anwendung. Weitere Studien sind notwendig, um die beschriebenen morphologischen Effekte dieses Lasertyps auch im Hinblick auf einen langfristigen Therapieeffekt zu untersuchen.



Bio-Emulation™



Tribune CME



# Bio-Emulation™ Colloquium 360°

4-5 July, 2015, Berlin, Germany

## Mentors



Ed McLaren



Michel Magne



Pascal Magne

## Emulators



Akinobu  
Ogata (guest)



Andrea  
Fabianelli



Antonio  
Saiz-Pardo Pinos



August  
Bruguera



David  
Gerdolle



Fernando  
Rey



Gianfranco  
Politano



Jason  
Smithson



Javier  
Tapia



Jungo  
Endo



Leandro  
Pereira



Marco  
Gresnigt



Oliver  
Brix



Panos  
Bazos



Sascha  
Hein



Stephane  
Browet



Thomas  
Singh

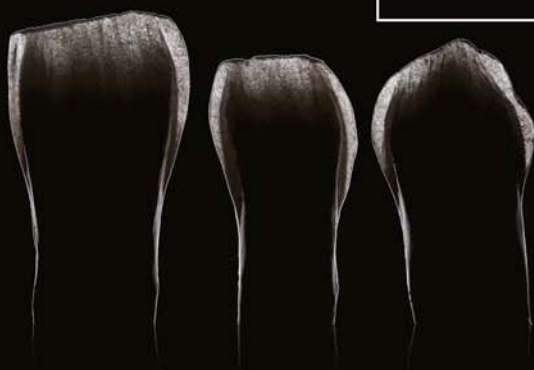

Walter  
Gebhard (guest)

Details & Online Registration

[www.BioEmulationCampus.com](http://www.BioEmulationCampus.com)

Registration fee: 599 EUR +VAT



**ADA CERP®**  
Continuing Education Recognition Program



Tribune Group is an ADA CERP Recognized Provider. ADA CERP is a service of the American Dental Association to assist dental professionals in identifying quality providers of continuing dental education. ADA CERP does not approve or endorse individual courses or instructors, nor does it imply acceptance of credit hours by boards of dentistry.

Tribune Group GmbH is designated as an Approved PACE Program Provider by the Academy of General Dentistry. The formal continuing dental education programs of this program provider are accepted by AGD for Fellowship, Mastership, and membership maintenance credit. Approval does not imply acceptance by a state or provincial board of dentistry or AGD endorsement.

Main Sponsor

