

The challenge of aesthetic implant restoration

Authors_Dr Jan Spieckermann & Jörg Wildenhain, Germany

The demands of treatment with implants are high, particularly in the aesthetically relevant areas. In the case of difficult morphological conditions, the individual wishes of patients regarding their natural appearance represent a major challenge for the treatment team. A host of materials and techniques for crowns and abutments allow for perfect imitation of the tooth structure. However, aesthetic restoration is only successful if a natural periimplant hard and soft tissue profile can be preserved or reconstructed. The following case study illustrates the complexity of implant treatment for combined horizontal and vertical bone resorption after the traumatic loss of the left central incisor.

Dental history and treatment plan

The most predictable, stable long-term aesthetic results are achieved through a synergistic process for di-

agnosis and therapy involving the various dental specialties. Science-based therapies need to be implemented with surgical and prosthetic precision and require the active participation of the patient both during and after treatment. A 29-year-old patient was referred to our oral surgery practice with the request for implant therapy in the anterior maxilla. He had lost the upper left incisor in an accident some months before. The gap had been treated with a flipper by the referring dentist. The removable restoration strongly affected the social well-being of the young man.

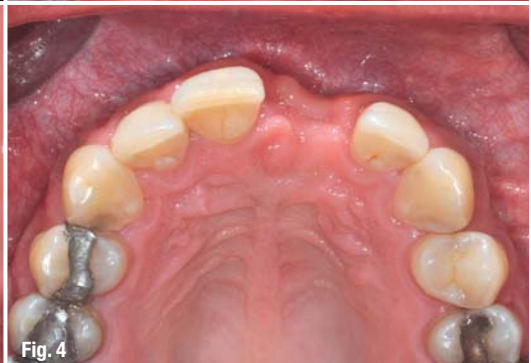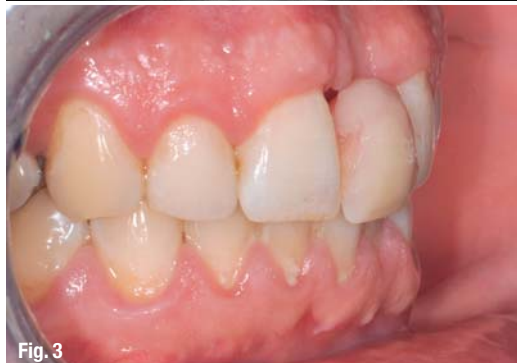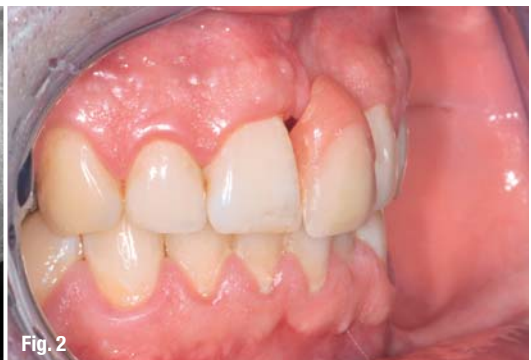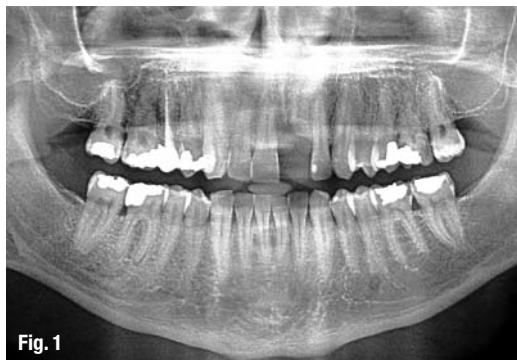Examination showed advanced horizontal and vertical bone resorption (Fig. 1). An extended plastic shield on the flipper was to visually compensate for bone loss (Fig. 2). This untoward design of the flipper exerted continuous pressure on the alveolar ridge owing to the rotary freedom around the clamping axis, particularly during removal but also during chewing motions. The

Fig. 1_The X-ray shows progressive horizontal and vertical bone resorption.

Fig. 2_The too long gingiva shield contributes to resorption due to the rotational freedom of the flipper.

Fig. 3_To avoid further traumatisation of the soft tissue, the flipper shield was shortened.

Fig. 4_The occlusal top view shows the horizontal hard and soft tissue deficit in the implant region.



Implant planning made easy

Planmeca PlanScan®

Planmeca ProMax® 3D

3^x
3D

Planmeca Romexis® software offers a completely integrated and digital workflow for modern implantology. From intraoral scanning to easy prosthetic design and realistic implant libraries, the most sophisticated implant planning tools are just a few clicks away.

- All the scanned and design data for prosthetic works is immediately available and can be mapped with the patient's CBCT data
- Use crown library or patient-specific crown from CAD system
- Verify the implant plan with verification tool
- Order surgical guide directly from the software
- Share data easily with partners through **Planmeca Romexis® Cloud** image transfer service



Find more info and your local dealer

www.planmeca.com



Planmeca Oy Asentajankatu 6, 00880 Helsinki, Finland
Tel. +358 20 7795 500, fax +358 20 7795 555, sales@planmeca.com

PLANMECA

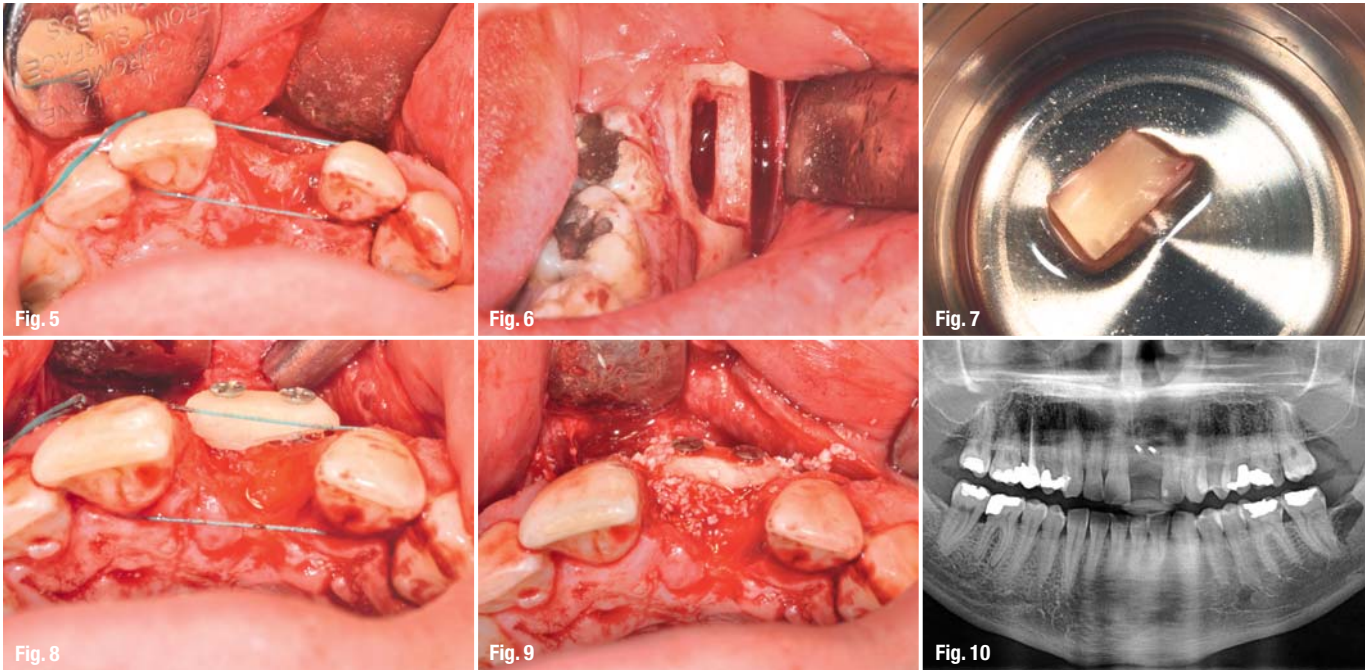


Fig. 5 A loop thread around the adjacent teeth illustrates the bone deficit.

Fig. 6 The bone block was harvested in sufficient size from the Corpus/Ramus mandibulae.

Fig. 7 The bone graft was stored in physiological solution until further processing.

Fig. 8 The autologous bone block was adapted to the shape of the host site. The focus was on the forming of the juga alveolaris.

Fig. 9 The cavities were filled with ground autologous bone chips and Bio Oss® was applied to the bone edges to protect against resorption.

Fig. 10 The X-ray control image shows the fixated bone block in the upper jaw and the donor site in the lower jaw.

unphysiological force induction influences the progression of bone resorption. To avoid further traumatization of the hard and soft tissue, we removed the gingival plate of the flipper and created a pontic-like design for region #21 (Fig. 3). With the exception of the pronounced bone deficit in region 21, there were no negative findings during examination of the anterior tooth region (Fig. 4).

We took impressions of the situation, prepared models and performed articulations. Then all therapeutic options were weighed against each other. We prepared a biological and financial cost-benefit analysis for each solution.^{1,2} We discussed all options in-depth with the patient. The justification for implantation was that both adjacent teeth were free of caries and should not be ground. Knowing that a correctly placed implant would prevent further resorption of the jaw bone, we prepared the most suitable treatment plan for the patient in our view.

The challenge of every treatment is the natural appearance of the restoration. The aesthetic characteristics proposed by Magne and Belser³ are part of our pre-prosthetic planning and are discussed by the team. The focus is on the condition and colour of the gingiva, achieving closed interdental spaces, a balanced profile of the gingiva, interdental contact points, the shape of the teeth, characterisation of the teeth and their texture, the alignment and position of the teeth, as well as the symmetry of the smile. The design of the convex structure of the alveolar bone ridge and the reshaping of the jugae alveolaris in the "red" area are just as important for a natural appearance as the perfect "white" crown reconstruction. Reconstruction of the bone deficit, both vertically and horizontally, requires a bone

block graft. In order to ensure the success of the surgical intervention for the 3-D placement of the implant, we opted for a two-stage procedure. In other words, the planned implant is inserted after regeneration of the bone.

Reconstruction of the bone defect

After administering local anaesthetic in both the donor and the host regions, a mediocrestal incision with vertical relieving incisions was performed in the anterior maxilla, distal to the adjacent teeth. In order to allow sufficient mobilisation of the mucoperiosteal flap and tension-free adaptation of the margins, the relieving incisions were extended over the mucogingival margin. Care was also taken to ensure that the flap edges were positioned on the local bone as this is where the growth factors for marginal regeneration originate. The mucoperiosteum/mucosal flap was prepared. To ensure blood supply to the flap, this was opened 5 mm apical to the mucogingival margin. The degree of bone deficit was demonstrated visually using a thread loop (Fig. 5).

A sufficiently large bone graft was harvested from the Corpus/Ramus mandibulae. This was preserved in physiological solution until the soft tissue at the donor site had been sutured (Figs. 6 & 7). We then adapted the cortical bone block as precisely as possible to the host site. In order to achieve an aesthetic overall outcome, attention was paid to the shaping of the juga alveolaris in the later implant region. The bone block was fixated with two osteosynthesis screws (Fig. 8). The remaining autologous bone material was ground and then used to fill the spaces between the block graft and the local bone (Fig. 9). Bio Oss® was added around the graft to



To experience something truly evolutionarily, you are cordially invited to attend our sponsor session lecture on June 4 & 5, at 10:30-12:00. Capital Suite 14-16. See our mini-site: v-implant.com

MIS Implants at the EUROPERIO8 in London: Capital Hall, Booth No 7 - so much to see!

... By *mis*[®]

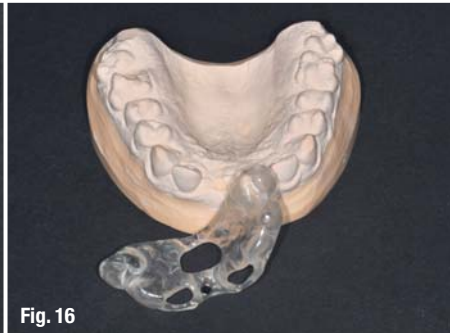
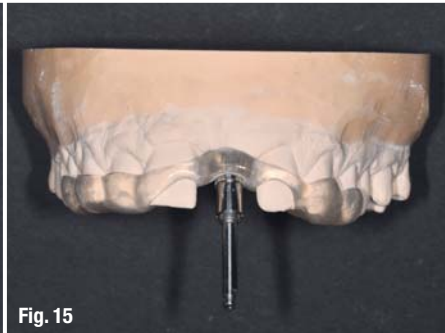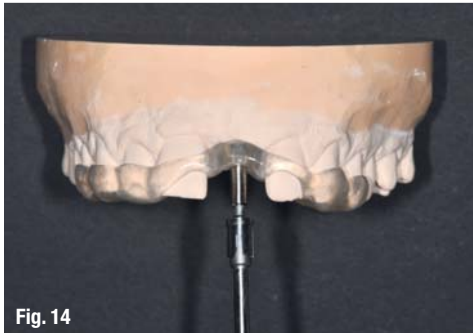

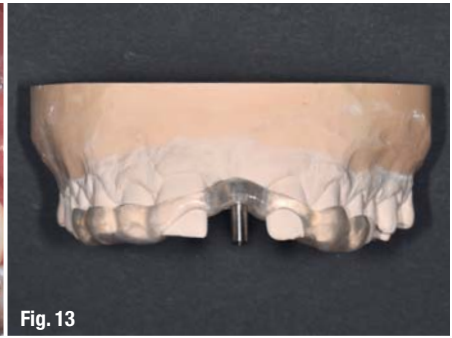
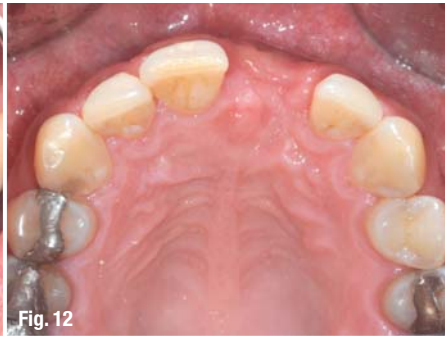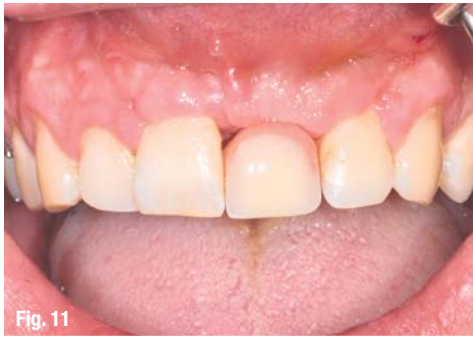Fig. 11 Three months post-op: frontal anatomical shaping of the jaw, sufficiently thick attached gingiva.

Fig. 12 Occlusal view: reconstructed hard and soft tissue, ready for implant insertion.

Fig. 13 Two-component sleeve for CT-planning incorporated in the prosthetically correct implant position.

Fig. 14 Full length of the Ø 2.2 mm sleeve was utilised initially.

Fig. 15 Pilot drilling is deepened through the 4 mm high sleeve section.

Fig. 16 Skeletonised implant template creates the largest possible space for the head of the angled handpiece for pilot drilling.

Fig. 17 Exposure of jaw bone and removal of two osteosynthesis screws.

Fig. 18 Insertion of skeletonised implant template.

protect against resorption. The bone augmentation was covered with a resorbable Bio-Gide membrane (Geistlich) cut to size. A periosteal slit allowed maximum mobilisation of the flap which was shifted coronally. Using horizontal mattress sutures it was adapted tension-free to the wound edges and sutured tightly with individual button sutures. Precise wound edge adaptation is a precondition for interference-free wound healing.⁴⁻⁶ The radiographic control image (Fig. 10) shows the fixated bone block in region 21 and the donor site on the Corpus/Ramus mandibulae. The flipper with the shortened plastic tooth was inserted as temporary restoration (Fig. 11). Only little pressure was to be exerted on the tissue during bone healing. This required understanding by the patient and modified (eating) behaviour. After ten days the patient visited for a check-up and removal of the sutures. Three months after surgery, the natural alveolar bone profile was stable and with a sufficiently keratinised gingiva (Fig. 12). An impression of this situation was taken and an implant template prepared.

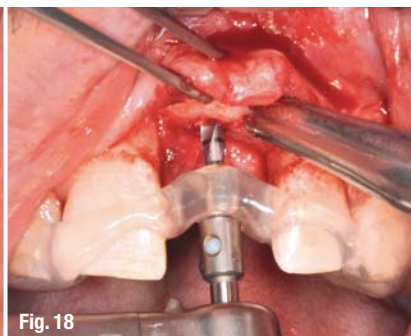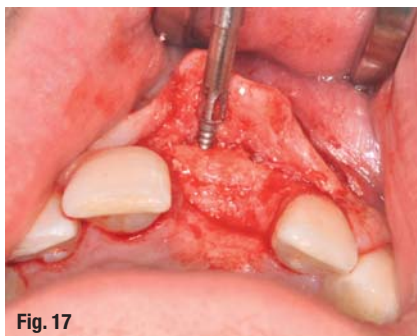The dental technician fabricated a skeletonised template. A two-component sleeve for CT-planning

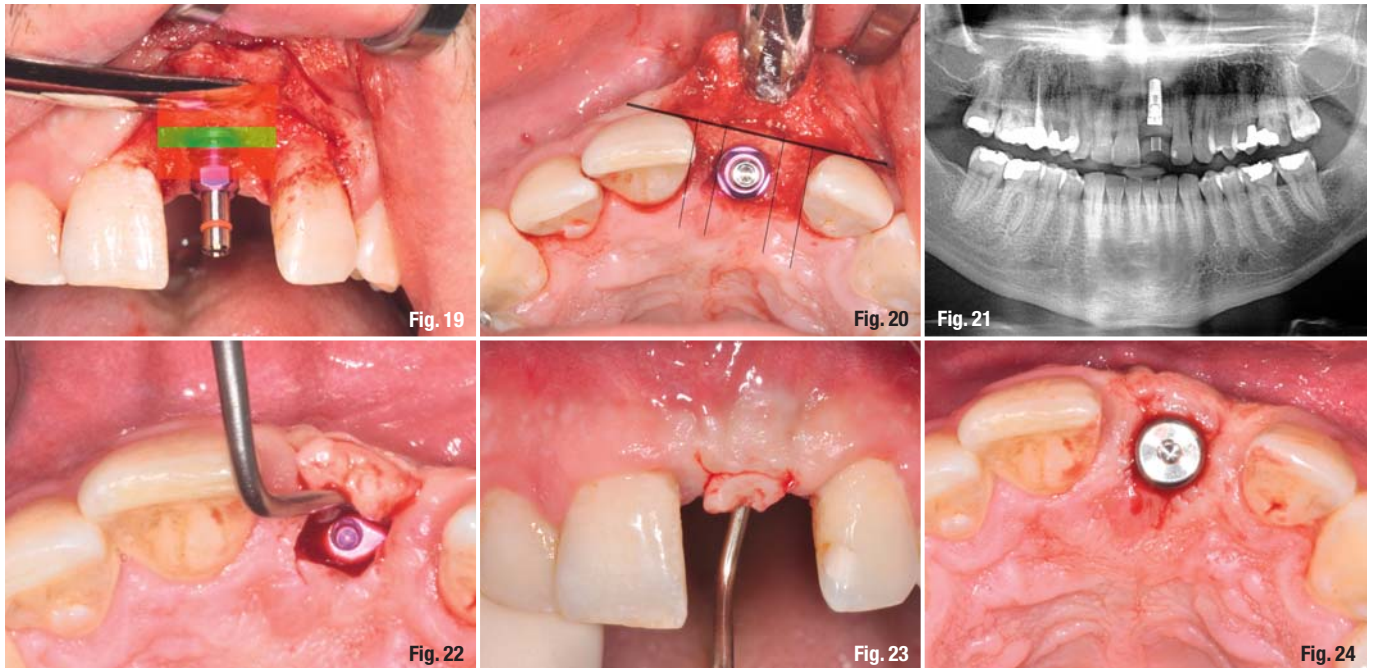
was incorporated at the prosthetically correct implant position^{7,8} and the plastic reduced as far as possible between the adjacent teeth. This reduction also enables placing of the template during the surgical procedure with mucoperiosteal flaps and provides maximum space for the angled handpiece during preparation of the implant bed (Figs. 13–16).

_Implantation

Implantation was performed four months after bone augmentation. Following local anaesthesia, a vestibular flap was prepared, the jaw bone exposed and the two osteosynthesis screws removed (Fig. 17). Pilot drilling was performed with the aid of a drilling template through the two-component CAMLOG sleeve for CT planning (2.2 mm diameter; Fig. 18). All other drilling steps to prepare the implant site for the CAMLOG® SCREW-LINE implant, length 13 mm and diameter 4.3 mm, were performed without a template.

Placement of the implant was performed three-dimensionally following the criteria for the anatomic window according to Gomez and taking into account the biological conversion processes associated with implant restorations. In this patient case the implant shoulder rested 1–2 mm below the cemento-enamel junction of the adjacent teeth. The implant shoulder was placed approximately 2 mm palatal to the dental arch in oro/vestibular direction. Apical placement compensates for differences between the anatomical emergence profile of the crown and the implant diameter. The mesio/distal distance between the outer edge of the implant to the adjacent tooth should be approximately 2 mm (Figs. 19 & 20). The





implant was sealed with a cover screw, the soft tissue sutured and an radiograph taken for checking purposes (Fig. 21).

Implant exposure with thickening of the soft tissue

In order to ensure successful restoration with the implant, we paid particular attention to the soft tissue management when exposing the implant. For this purpose we employed the modified roll flap technique for thickening of the soft tissue (Fig. 22). Using a diamond drill, the epithelium layer over the implant was removed and a pedicle flap prepared vestibularly after palatal preparation, surrounding the de-epithelised tissue with cut-outs for the papillae (Fig. 23). The roll flaps were folded, pushed into the prepared tunnel, and after removing the cover screw a 4mm high healing cap was inserted into the implant (Fig. 24). We thickened the marginal soft tissue as a matter of principle as it could migrate in the apical direction during remodelling. The periimplant tissue restructures itself during insertion of the healing cap or the prosthetic restoration and the biological scope develops anew.⁹ For cost reasons we were unable to utilise the option of shaping the soft tissue using a temporary implant crown.

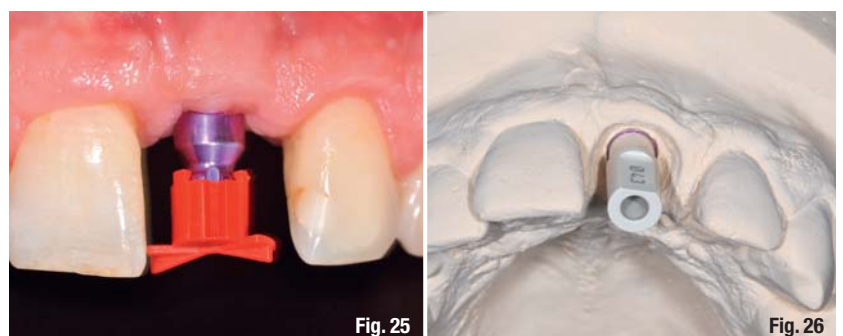
The prosthetic restoration

Four weeks after exposure, the tissue was stable and irritation-free and an impression of the situation was taken. We removed the healing cap and placed the impression post for the closed tray technique into the implant (Fig. 25). The impression cap was attached to the post and an impression of the upper jaw taken with polyether. Once the models had been fabricated and ar-

ticulated, the dental technician fabricated a customised zirconium dioxide abutment, bonded to a CAMLOG® Titanium base CAD/CAM. The customised shaping of the crown emergence profile is key to the natural appearance of a prosthetic reconstruction.

A zirconium dioxide cap was fabricated over the hybrid abutment, which was veneered with a glass ceramic (Figs. 26–28). On the day of insertion, the healing cap was removed, the implant interface cleaned, and the hybrid abutment inserted (Fig. 29). The surrounding soft tissue was displaced by the customised crown emergence profile into the shape of the planned emergence profile. After approximately 3 minutes the soft tissue had revascularised and was evenly coloured red. The crown was seated and the overall appearance, shape of the tooth, colour and position evaluated critically. The shaping of the papillae was not yet perfect (Fig. 30). Therefore, the positions of the contact points were checked. The vertical distance between the crestal bone and the approximal contact points to the adjacent dental crowns was 4 mm. Here we referred to the investigations on papillae formation by Tarnow et al. for aesthetic interdental papillae that remain stable long-term.¹⁰

- Fig. 19** Placement of implant shoulder 2 mm below enamel cement margin of adjacent teeth.
- Fig. 20** Placement of the implant according to the criteria of the aesthetic window.
- Fig. 21** Anatomical shaping of the emergence profile of the crown.
- Fig. 22** Preparation of a roll flap by means of palatal incision.
- Fig. 23** The flap was folded and pushed into the prepared tunnel using a special instrument.
- Fig. 24** Insertion of a 4 mm high cylindrical CAMLOG® healing cap, suturing of soft tissue.
- Fig. 25** Impression four weeks after implant exposure.
- Fig. 26** The model prior to digitalisation with Scanbody.



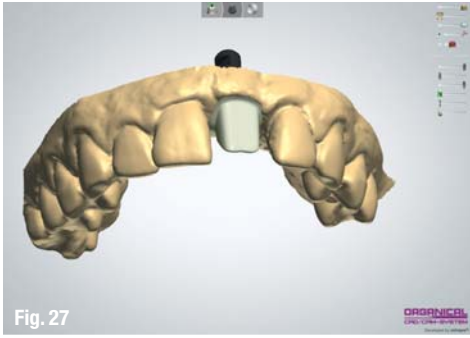


Fig. 27

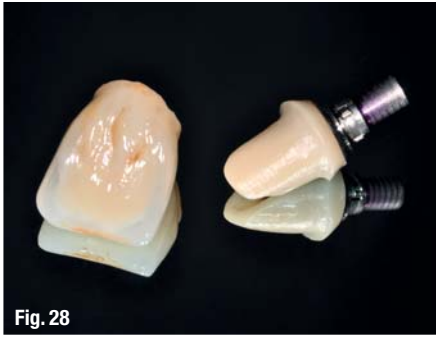

Fig. 28

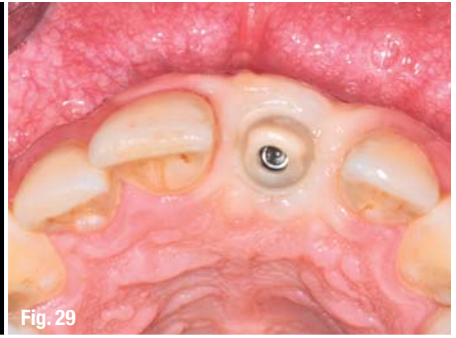


Fig. 29

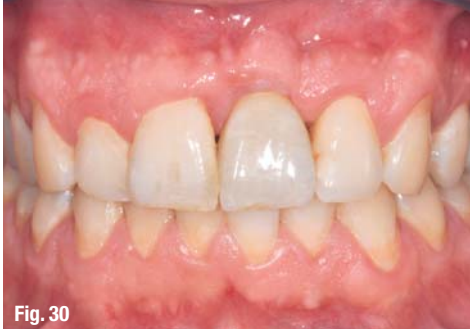

Fig. 30

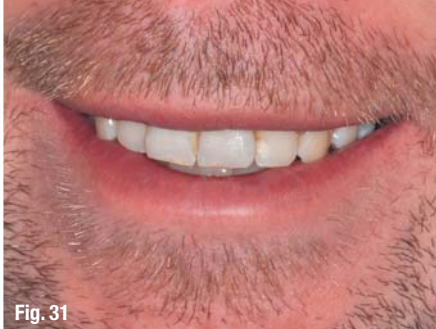

Fig. 31

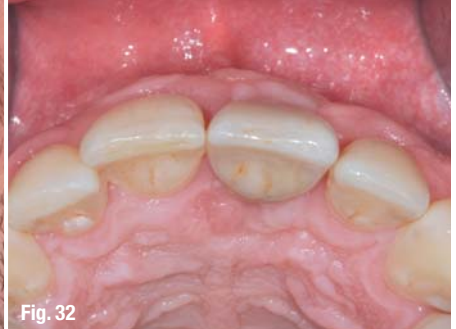

Fig. 32

Fig. 27 The abutment was created with the 3Shape® abutment designer.

Fig. 28 The customised zirconium oxide abutment was bonded to the titanium bonding base and the zirconium crown was veneered individually.

Fig. 29 The individual hybrid abutment shapes the desired emergence profile. The gingiva is revascularised after approximately three minutes.

Fig. 30 Immediately after insertion, the crown appears to be somewhat too long in the cervical region and the papillae are not shaped optimally.

Fig. 31 The patient displayed an aesthetic lip appearance.

The position, colour and shape of the restoration blend in harmoniously with the dental arch.

Fig. 32 At the follow-up, good reconstruction of the oro-vestibular dimension is observed.

Fig. 33 At the follow-up after two years, the interdental papillae were fully shaped and the gaps closed.

The intact surrounding support structure of the adjacent teeth helps in the realisation of a naturally shaped papilla. The zirconium dioxide crown was cemented with Durelon, the cement residue was carefully removed, and the patient left the dental practice with a permanent aesthetic prosthesis (Fig. 31). Twelve months after insertion, the patient presented in our practice for a follow-up. The images show a stable peri-implant hard and soft tissue situation (Fig. 32). The migration of the gingiva had led to considerably more natural shaping of the interdental papillae, and the gaps had virtually closed. The aesthetic outcome of the 3-D implant insertion in combination with the intact approximal bone level of the adjacent teeth and adequate height and width of the periimplant hard and soft tissue was again confirmed at the 24-month follow-up (Fig. 33).

Discussion

The prospective implant status demonstrated insufficient alveolar ridge tissue. Aesthetic implant restoration was therefore only possible with bone and soft tissue augmentation. As a single-step surgical

procedure did not allow for a prosthetically correct placement of the implant, a two-step procedure was indicated. Perfect red-white aesthetics place great demands on the periimplant hard and soft tissue.

Conclusion

In the aesthetically demanding anterior region, implant therapy represents both a valuable and challenging alternative for replacing lost teeth. The surgical treatment plan based on the patient's wishes, prosthetic analysis and a wax-up, should be compiled on the basis of the existing hard and soft tissue. The individual treatment steps, as well as treatment times and costs should be discussed in depth with the patient.

Editorial note: A list of references is available from the publisher.

contact

Dr Jan Spieckermann
 Joint practice for oral surgery
 Specialists for oral surgery,
 Focus on implantology
 An der Markthalle 3
 09111 Chemnitz, Germany
 info@oralchirurgie-chemnitz.de

Jörg Wildenhain
 Kauzentrum Dentallabor Chemnitz
 Dental laboratory
 Gießerstr. 13
 09130 Chemnitz, Germany

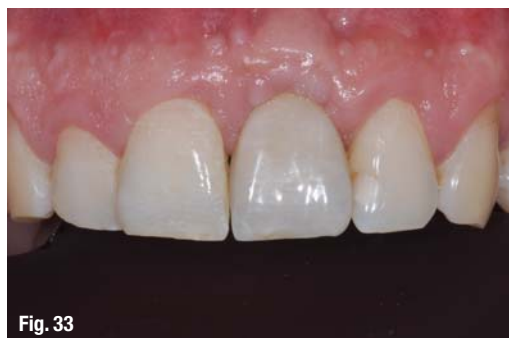

Fig. 33

axiom[®] CONCEPT



The new dimension

1 GLOBAL CONCEPT

3 COMPLEMENTARY SOLUTIONS FOR ALL CLINICAL INDICATIONS

- Conical, strong and hermetic connection.
- “Platform switching” - Optimized biomechanical behaviour.
- **BCP[®]** osteoconductive surface - Efficient bone stimulation.
- Common surgical kit for a flexibility of use.
- **Multi-Unit** abutments for Axiom[®] REG/PX.
- **Serenity[®]** Warranty Program.



▶ Watch the video

www.anthogyr.com

2 237, Avenue André Lasquin - 74700 Sallanches - FRANCE
Phone: +33 (0)4 50 58 02 37 - Fax: +33 (0)4 50 93 78 60

Anthogyr
PRIME MOVER IN IMPLANTOLOGY