

implants

international magazine of oral implantology

2²⁰¹⁵

| **case report**

The challenge of aesthetic
implant restoration

| **research**

Mixed picture:
The state of periodontology in the UK

| **industry**

“It is our mission to simplify dental implantology”



More than
primary stability.
The new tapered standard.



The perfect symbiosis of design, material and surface –
the Straumann® Bone Level Tapered Implant:

- Roxolid® material – Reducing invasiveness with smaller implants
- SLActive® surface – Designed to maximize your treatment success and predictability
- Apically tapered – Excellent primary stability even in compromised bone situations
- CrossFit® connection – Simplified handling, legacy of Bone Level System

In combination with:





Dr Georg Bach

Wind of change

Dear reader,

Times are changing—with their song "Wind of Change", the Scorpions recognised the changing political situation in Europe already in 1990 and captured the spirit of the time. Our profession as implantologists is evolving currently in nearly as vehement a manner as these changes in the past. This assessment is not related to the political situation that affects our profession and work; it is due to the shift from analogue to digital dentistry.

A walk through the most recent International Dental Show in Cologne in Germany confirmed this impression. It is fascinating and surprising how rapidly and radically the new digital options are displacing traditional methods and ultimately replacing them entirely. In dental technology, this development is considerably more advanced.

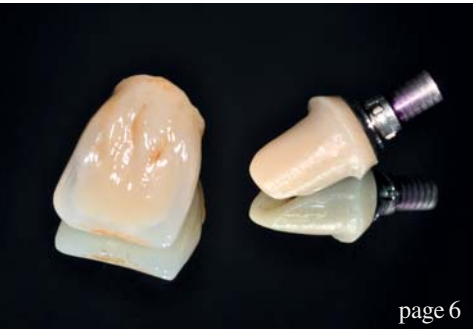These developments have already changed our profession and work and will continue to do so even more in the near future. As implantologists, we each have to face this transition in our own practice. As the German Association of Dental Implantology (DGZI), we are seeking to respond to these changes as well.

This objective will form a clear thread running through all the activities of the DGZI this year, beginning with the further expansion of our collaboration with dental technicians through our educational activities in the curriculum and study groups to our annual congress in Wiesbaden in October. There, you can experience the wind of change yourself, obtain information and engage in discussions.

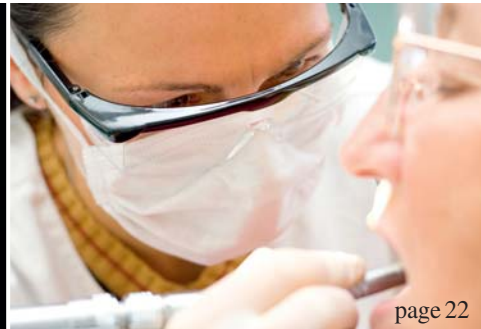Times are changing and we are well prepared.

Yours sincerely,

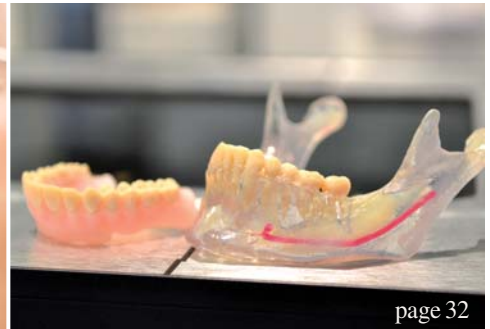Dr Georg Bach



page 6



page 22



page 32

| editorial

03 **Wind of change**

| Dr Georg Bach

| case report

06 **The challenge of aesthetic implant restoration**

| Dr Jan Spieckermann *et al.*

14 **Quality of implant surfaces and deficient osseointegration — Part I**

| Dr Nikolaos Papagiannoulis

18 **Treatment of an unusual presentation of radicular cysts**

| Dr Manthan Desai

| research

22 **Mixed picture: The state of periodontology in the UK**

| Prof. Francis Hughes

| industry

28 **“It is our mission to simplify dental implantology”**

30 **ClaroNav introduces new device for navigated surgery**

| Timo Krause

32 **3-D printing: Next generation of dental modelling**

| Georg Isbaner

| events

38 **Biggest IDS of all time in Cologne**

42 **6th International CAMLOG Congress**

44 **“We are planning to be the best and biggest EuroPerio to date”**

| laudatio

46 **Pioneer of implantology celebrates 90th birthday**

| Jürgen Isbaner

| news

26 **Manufacturer News**

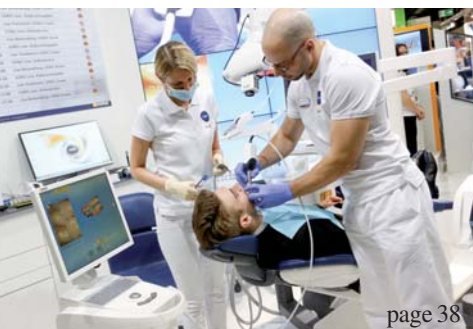48 **News**

| about the publisher

50 | imprint



Cover image courtesy of MIS Implants Technologies Ltd., www.mis-implants.com



page 38



page 44



page 46

Restoring happiness

Patients rely on you in order to eat, speak, and smile with confidence. It can be said, you are actually restoring quality of life and happiness.

To succeed, you need technology that is well founded and documented in science. That is why we only deliver premium solutions for all phases of implant therapy, which have been extensively tested and clinically proven to provide lifelong function and esthetics.

Moreover, with an open-minded approach, we partner with our customers and offer services that go beyond products, such as educational opportunities and practice development programs so you can rest assured that you have the support you need.

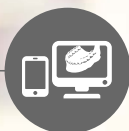
Reliable solutions and partnership for restoring happiness—because it matters.

Comprehensive solutions for all phases of implant dentistry



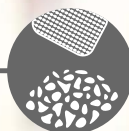
Professional and practice development

STEPPS™



Digital planning

SIMPLANT™



Regenerative solutions

SYMBIOS™



Implants

ANKYLOS™

**ASTRA TECH
IMPLANT SYSTEM**

XiVE™



Restorations

ATLANTIS™

The challenge of aesthetic implant restoration

Authors_Dr Jan Spieckermann & Jörg Wildenhain, Germany

The demands of treatment with implants are high, particularly in the aesthetically relevant areas. In the case of difficult morphological conditions, the individual wishes of patients regarding their natural appearance represent a major challenge for the treatment team. A host of materials and techniques for crowns and abutments allow for perfect imitation of the tooth structure. However, aesthetic restoration is only successful if a natural periimplant hard and soft tissue profile can be preserved or reconstructed. The following case study illustrates the complexity of implant treatment for combined horizontal and vertical bone resorption after the traumatic loss of the left central incisor.

Dental history and treatment plan

The most predictable, stable long-term aesthetic results are achieved through a synergistic process for di-

agnosis and therapy involving the various dental specialties. Science-based therapies need to be implemented with surgical and prosthetic precision and require the active participation of the patient both during and after treatment. A 29-year-old patient was referred to our oral surgery practice with the request for implant therapy in the anterior maxilla. He had lost the upper left incisor in an accident some months before. The gap had been treated with a flipper by the referring dentist. The removable restoration strongly affected the social well-being of the young man.

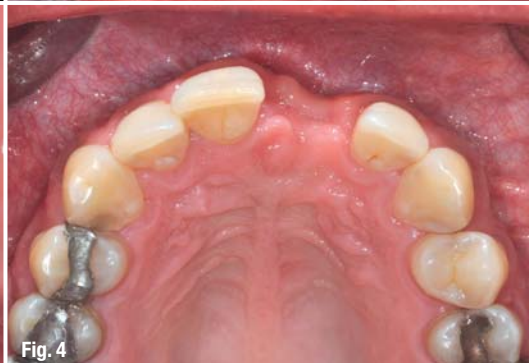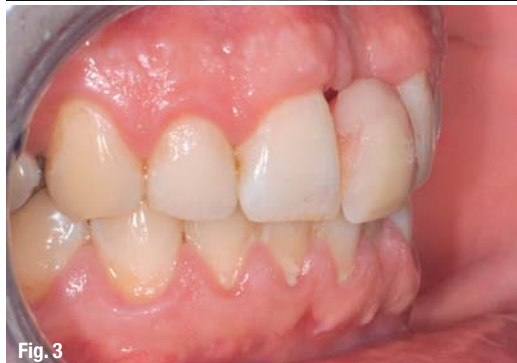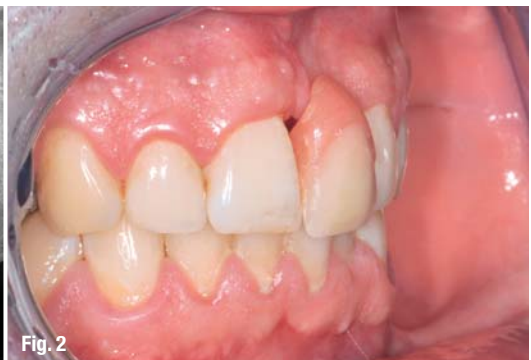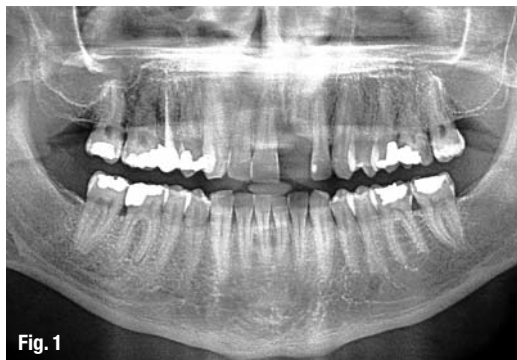Examination showed advanced horizontal and vertical bone resorption (Fig. 1). An extended plastic shield on the flipper was to visually compensate for bone loss (Fig. 2). This untoward design of the flipper exerted continuous pressure on the alveolar ridge owing to the rotary freedom around the clamping axis, particularly during removal but also during chewing motions. The

Fig. 1_The X-ray shows progressive horizontal and vertical bone resorption.

Fig. 2_The too long gingiva shield contributes to resorption due to the rotational freedom of the flipper.

Fig. 3_To avoid further traumatisation of the soft tissue, the flipper shield was shortened.

Fig. 4_The occlusal top view shows the horizontal hard and soft tissue deficit in the implant region.



Implant planning made easy

Planmeca PlanScan®

Planmeca ProMax® 3D

3^x
3D

Planmeca Romexis® software offers a completely integrated and digital workflow for modern implantology. From intraoral scanning to easy prosthetic design and realistic implant libraries, the most sophisticated implant planning tools are just a few clicks away.

- All the scanned and design data for prosthetic works is immediately available and can be mapped with the patient's CBCT data
- Use crown library or patient-specific crown from CAD system
- Verify the implant plan with verification tool
- Order surgical guide directly from the software
- Share data easily with partners through **Planmeca Romexis® Cloud** image transfer service



Find more info and your local dealer

www.planmeca.com



Planmeca Oy Asentajankatu 6, 00880 Helsinki, Finland
Tel. +358 20 7795 500, fax +358 20 7795 555, sales@planmeca.com

PLANMECA

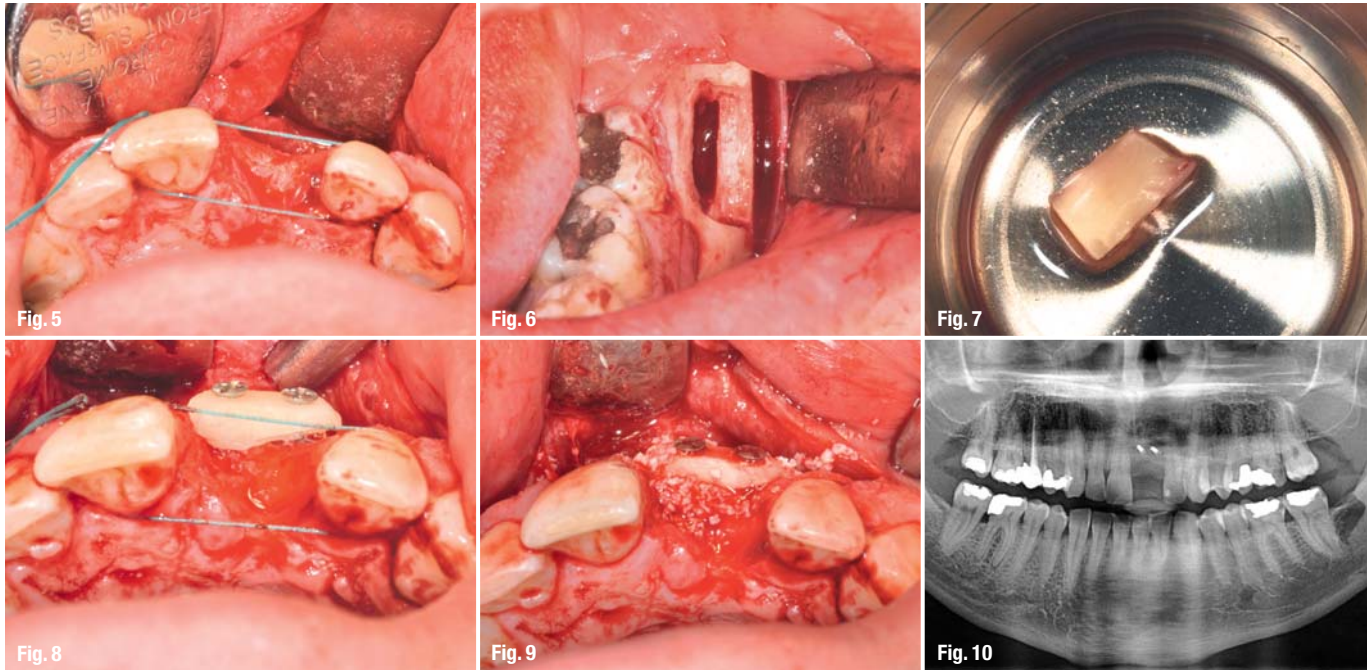


Fig. 5 A loop thread around the adjacent teeth illustrates the bone deficit.

Fig. 6 The bone block was harvested in sufficient size from the Corpus/Ramus mandibulae.

Fig. 7 The bone graft was stored in physiological solution until further processing.

Fig. 8 The autologous bone block was adapted to the shape of the host site. The focus was on the forming of the juga alveolaris.

Fig. 9 The cavities were filled with ground autologous bone chips and Bio Oss® was applied to the bone edges to protect against resorption.

Fig. 10 The X-ray control image shows the fixated bone block in the upper jaw and the donor site in the lower jaw.

unphysiological force induction influences the progression of bone resorption. To avoid further traumatization of the hard and soft tissue, we removed the gingival plate of the flipper and created a pontic-like design for region #21 (Fig. 3). With the exception of the pronounced bone deficit in region 21, there were no negative findings during examination of the anterior tooth region (Fig. 4).

We took impressions of the situation, prepared models and performed articulations. Then all therapeutic options were weighed against each other. We prepared a biological and financial cost-benefit analysis for each solution.^{1,2} We discussed all options in-depth with the patient. The justification for implantation was that both adjacent teeth were free of caries and should not be ground. Knowing that a correctly placed implant would prevent further resorption of the jaw bone, we prepared the most suitable treatment plan for the patient in our view.

The challenge of every treatment is the natural appearance of the restoration. The aesthetic characteristics proposed by Magne and Belser³ are part of our pre-prosthetic planning and are discussed by the team. The focus is on the condition and colour of the gingiva, achieving closed interdental spaces, a balanced profile of the gingiva, interdental contact points, the shape of the teeth, characterisation of the teeth and their texture, the alignment and position of the teeth, as well as the symmetry of the smile. The design of the convex structure of the alveolar bone ridge and the reshaping of the jugae alveolaris in the "red" area are just as important for a natural appearance as the perfect "white" crown reconstruction. Reconstruction of the bone deficit, both vertically and horizontally, requires a bone

block graft. In order to ensure the success of the surgical intervention for the 3-D placement of the implant, we opted for a two-stage procedure. In other words, the planned implant is inserted after regeneration of the bone.

Reconstruction of the bone defect

After administering local anaesthetic in both the donor and the host regions, a mediocrestal incision with vertical relieving incisions was performed in the anterior maxilla, distal to the adjacent teeth. In order to allow sufficient mobilisation of the mucoperiosteal flap and tension-free adaptation of the margins, the relieving incisions were extended over the mucogingival margin. Care was also taken to ensure that the flap edges were positioned on the local bone as this is where the growth factors for marginal regeneration originate. The mucoperiosteum/mucosal flap was prepared. To ensure blood supply to the flap, this was opened 5 mm apical to the mucogingival margin. The degree of bone deficit was demonstrated visually using a thread loop (Fig. 5).

A sufficiently large bone graft was harvested from the Corpus/Ramus mandibulae. This was preserved in physiological solution until the soft tissue at the donor site had been sutured (Figs. 6 & 7). We then adapted the cortical bone block as precisely as possible to the host site. In order to achieve an aesthetic overall outcome, attention was paid to the shaping of the juga alveolaris in the later implant region. The bone block was fixated with two osteosynthesis screws (Fig. 8). The remaining autologous bone material was ground and then used to fill the spaces between the block graft and the local bone (Fig. 9). Bio Oss® was added around the graft to



To experience something truly evolutionarily, you are cordially invited to attend our sponsor session lecture on June 4 & 5, at 10:30-12:00. Capital Suite 14-16. See our mini-site: v-implant.com

MIS Implants at the EUROPERIO8 in London: Capital Hall, Booth No 7 - so much to see!

... By *mis*[®]

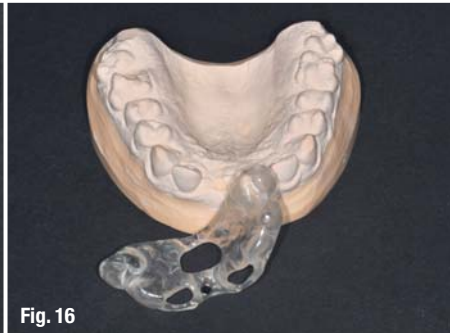
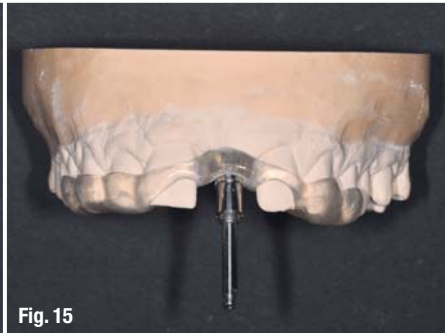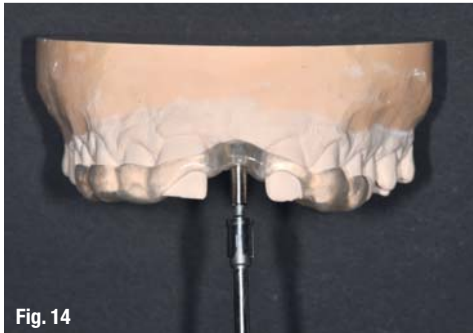

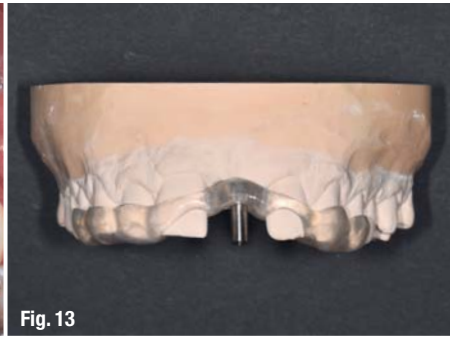
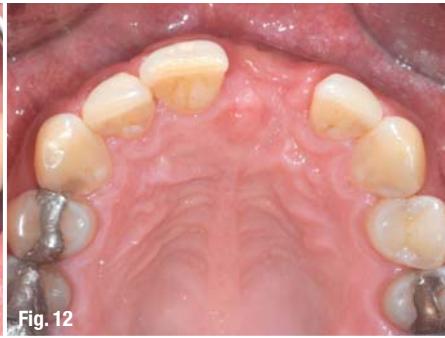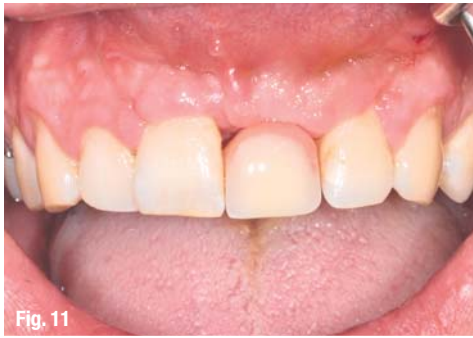Fig. 11 Three months post-op: frontal anatomical shaping of the jaw, sufficiently thick attached gingiva.

Fig. 12 Occlusal view: reconstructed hard and soft tissue, ready for implant insertion.

Fig. 13 Two-component sleeve for CT-planning incorporated in the prosthetically correct implant position.

Fig. 14 Full length of the Ø 2.2 mm sleeve was utilised initially.

Fig. 15 Pilot drilling is deepened through the 4 mm high sleeve section.

Fig. 16 Skeletonised implant template creates the largest possible space for the head of the angled handpiece for pilot drilling.

Fig. 17 Exposure of jaw bone and removal of two osteosynthesis screws.

Fig. 18 Insertion of skeletonised implant template.

protect against resorption. The bone augmentation was covered with a resorbable Bio-Gide membrane (Geistlich) cut to size. A periosteal slit allowed maximum mobilisation of the flap which was shifted coronally. Using horizontal mattress sutures it was adapted tension-free to the wound edges and sutured tightly with individual button sutures. Precise wound edge adaptation is a precondition for interference-free wound healing.⁴⁻⁶ The radiographic control image (Fig. 10) shows the fixated bone block in region 21 and the donor site on the Corpus/Ramus mandibulae. The flipper with the shortened plastic tooth was inserted as temporary restoration (Fig. 11). Only little pressure was to be exerted on the tissue during bone healing. This required understanding by the patient and modified (eating) behaviour. After ten days the patient visited for a check-up and removal of the sutures. Three months after surgery, the natural alveolar bone profile was stable and with a sufficiently keratinised gingiva (Fig. 12). An impression of this situation was taken and an implant template prepared.

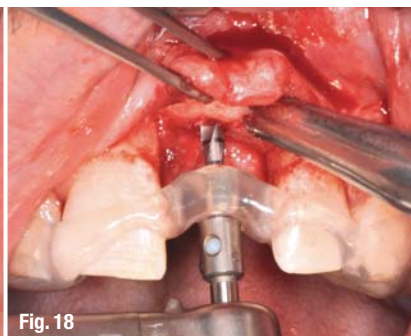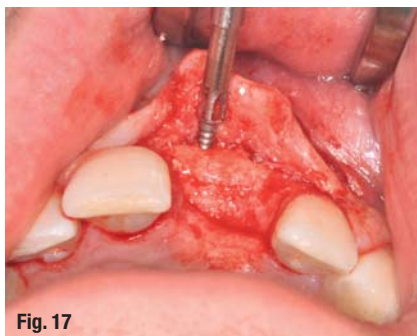The dental technician fabricated a skeletonised template. A two-component sleeve for CT-planning

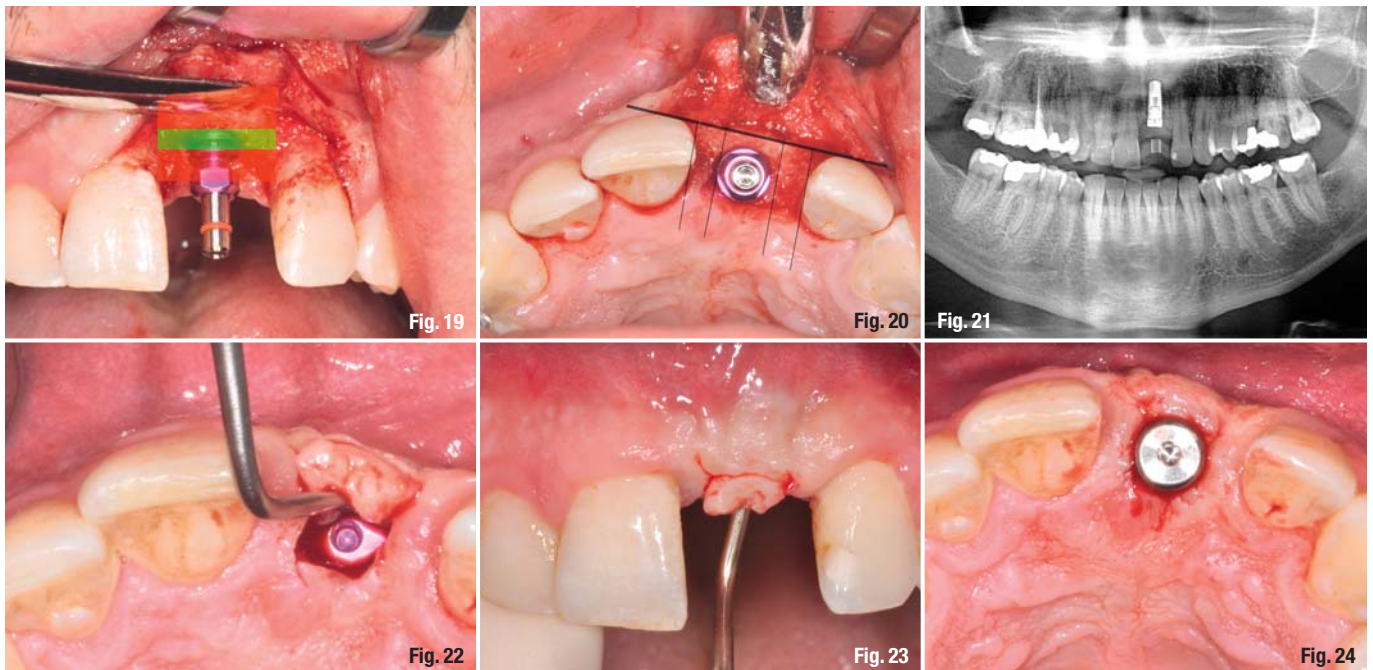
was incorporated at the prosthetically correct implant position^{7,8} and the plastic reduced as far as possible between the adjacent teeth. This reduction also enables placing of the template during the surgical procedure with mucoperiosteal flaps and provides maximum space for the angled handpiece during preparation of the implant bed (Figs. 13–16).

_Implantation

Implantation was performed four months after bone augmentation. Following local anaesthesia, a vestibular flap was prepared, the jaw bone exposed and the two osteosynthesis screws removed (Fig. 17). Pilot drilling was performed with the aid of a drilling template through the two-component CAMLOG sleeve for CT planning (2.2 mm diameter; Fig. 18). All other drilling steps to prepare the implant site for the CAMLOG® SCREW-LINE implant, length 13 mm and diameter 4.3 mm, were performed without a template.

Placement of the implant was performed three-dimensionally following the criteria for the anatomic window according to Gomez and taking into account the biological conversion processes associated with implant restorations. In this patient case the implant shoulder rested 1–2 mm below the cemento-enamel junction of the adjacent teeth. The implant shoulder was placed approximately 2 mm palatal to the dental arch in oro/vestibular direction. Apical placement compensates for differences between the anatomical emergence profile of the crown and the implant diameter. The mesio/distal distance between the outer edge of the implant to the adjacent tooth should be approximately 2 mm (Figs. 19 & 20). The





implant was sealed with a cover screw, the soft tissue sutured and an radiograph taken for checking purposes (Fig. 21).

Implant exposure with thickening of the soft tissue

In order to ensure successful restoration with the implant, we paid particular attention to the soft tissue management when exposing the implant. For this purpose we employed the modified roll flap technique for thickening of the soft tissue (Fig. 22). Using a diamond drill, the epithelium layer over the implant was removed and a pedicle flap prepared vestibularly after palatal preparation, surrounding the de-epithelised tissue with cut-outs for the papillae (Fig. 23). The roll flaps were folded, pushed into the prepared tunnel, and after removing the cover screw a 4 mm high healing cap was inserted into the implant (Fig. 24). We thickened the marginal soft tissue as a matter of principle as it could migrate in the apical direction during remodelling. The periimplant tissue restructures itself during insertion of the healing cap or the prosthetic restoration and the biological scope develops anew.⁹ For cost reasons we were unable to utilise the option of shaping the soft tissue using a temporary implant crown.

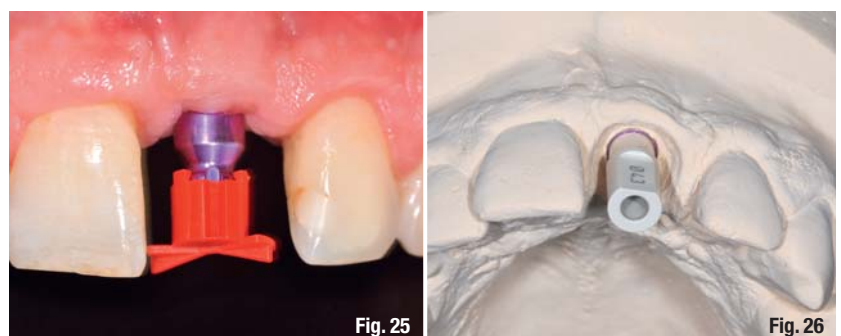
The prosthetic restoration

Four weeks after exposure, the tissue was stable and irritation-free and an impression of the situation was taken. We removed the healing cap and placed the impression post for the closed tray technique into the implant (Fig. 25). The impression cap was attached to the post and an impression of the upper jaw taken with polyether. Once the models had been fabricated and ar-

ticulated, the dental technician fabricated a customised zirconium dioxide abutment, bonded to a CAMLOG® Titanium base CAD/CAM. The customised shaping of the crown emergence profile is key to the natural appearance of a prosthetic reconstruction.

A zirconium dioxide cap was fabricated over the hybrid abutment, which was veneered with a glass ceramic (Figs. 26–28). On the day of insertion, the healing cap was removed, the implant interface cleaned, and the hybrid abutment inserted (Fig. 29). The surrounding soft tissue was displaced by the customised crown emergence profile into the shape of the planned emergence profile. After approximately 3 minutes the soft tissue had revascularised and was evenly coloured red. The crown was seated and the overall appearance, shape of the tooth, colour and position evaluated critically. The shaping of the papillae was not yet perfect (Fig. 30). Therefore, the positions of the contact points were checked. The vertical distance between the crestal bone and the approximal contact points to the adjacent dental crowns was 4 mm. Here we referred to the investigations on papillae formation by Tarnow et al. for aesthetic interdental papillae that remain stable long-term.¹⁰

Fig. 19 Placement of implant shoulder 2 mm below enamel cement margin of adjacent teeth.
Fig. 20 Placement of the implant according to the criteria of the aesthetic window.
Fig. 21 Anatomical shaping of the emergence profile of the crown.
Fig. 22 Preparation of a roll flap by means of palatal incision.
Fig. 23 The flap was folded and pushed into the prepared tunnel using a special instrument.
Fig. 24 Insertion of a 4 mm high cylindrical CAMLOG® healing cap, suturing of soft tissue.
Fig. 25 Impression four weeks after implant exposure.
Fig. 26 The model prior to digitalisation with Scanbody.



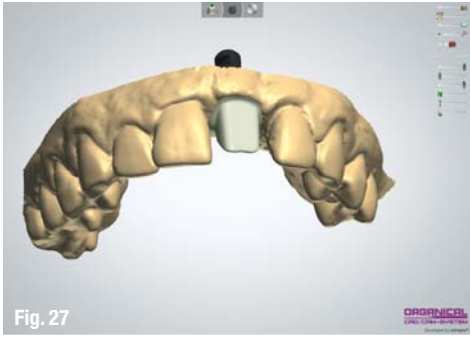


Fig. 27

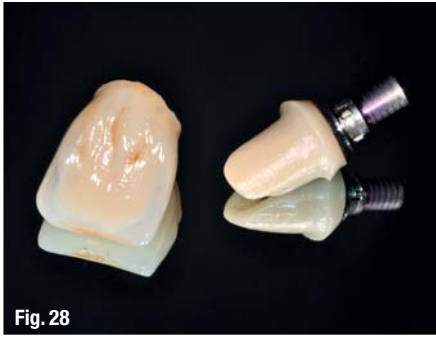

Fig. 28

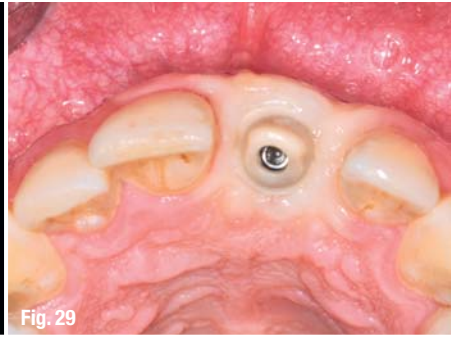


Fig. 29

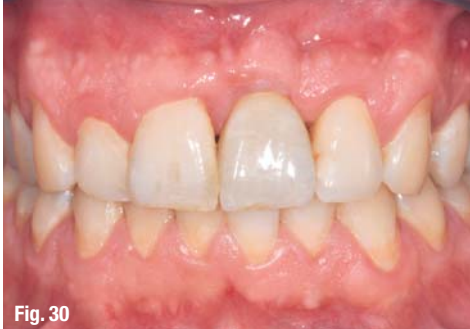

Fig. 30

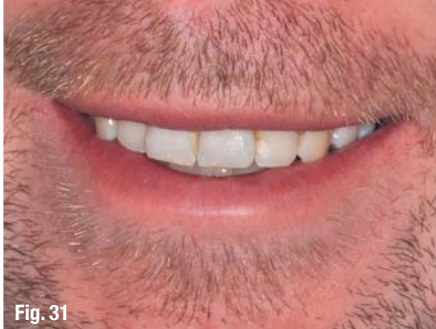

Fig. 31

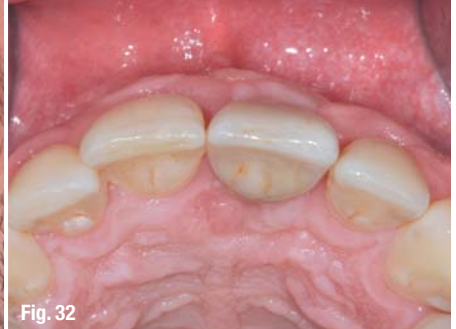

Fig. 32

Fig. 27 The abutment was created with the 3Shape® abutment designer.

Fig. 28 The customised zirconium oxide abutment was bonded to the titanium bonding base and the zirconium crown was veneered individually.

Fig. 29 The individual hybrid abutment shapes the desired emergence profile. The gingiva is revascularised after approximately three minutes.

Fig. 30 Immediately after insertion, the crown appears to be somewhat too long in the cervical region and the papillae are not shaped optimally.

Fig. 31 The patient displayed an aesthetic lip appearance.

The position, colour and shape of the restoration blend in harmoniously with the dental arch.

Fig. 32 At the follow-up, good reconstruction of the oro-vestibular dimension is observed.

Fig. 33 At the follow-up after two years, the interdental papillae were fully shaped and the gaps closed.

The intact surrounding support structure of the adjacent teeth helps in the realisation of a naturally shaped papilla. The zirconium dioxide crown was cemented with Durelon, the cement residue was carefully removed, and the patient left the dental practice with a permanent aesthetic prosthesis (Fig. 31). Twelve months after insertion, the patient presented in our practice for a follow-up. The images show a stable peri-implant hard and soft tissue situation (Fig. 32). The migration of the gingiva had led to considerably more natural shaping of the interdental papillae, and the gaps had virtually closed. The aesthetic outcome of the 3-D implant insertion in combination with the intact approximal bone level of the adjacent teeth and adequate height and width of the periimplant hard and soft tissue was again confirmed at the 24-month follow-up (Fig. 33).

Discussion

The prospective implant status demonstrated insufficient alveolar ridge tissue. Aesthetic implant restoration was therefore only possible with bone and soft tissue augmentation. As a single-step surgical

procedure did not allow for a prosthetically correct placement of the implant, a two-step procedure was indicated. Perfect red-white aesthetics place great demands on the periimplant hard and soft tissue.

Conclusion

In the aesthetically demanding anterior region, implant therapy represents both a valuable and challenging alternative for replacing lost teeth. The surgical treatment plan based on the patient's wishes, prosthetic analysis and a wax-up, should be compiled on the basis of the existing hard and soft tissue. The individual treatment steps, as well as treatment times and costs should be discussed in depth with the patient.

Editorial note: A list of references is available from the publisher.

contact

Dr Jan Spieckermann
 Joint practice for oral surgery
 Specialists for oral surgery,
 Focus on implantology
 An der Markthalle 3
 09111 Chemnitz, Germany
 info@oralchirurgie-chemnitz.de

Jörg Wildenhain
 Kauzentrum Dentallabor Chemnitz
 Dental laboratory
 Gießerstr. 13
 09130 Chemnitz, Germany

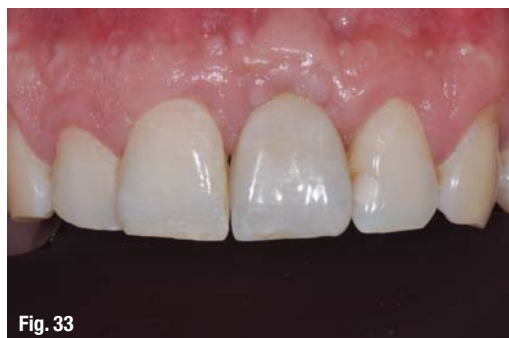

Fig. 33

axiom[®] CONCEPT



The new dimension

1 GLOBAL CONCEPT

3 COMPLEMENTARY SOLUTIONS FOR ALL CLINICAL INDICATIONS

- Conical, strong and hermetic connection.
- “Platform switching” - Optimized biomechanical behaviour.
- **BCP[®]** osteoconductive surface - Efficient bone stimulation.
- Common surgical kit for a flexibility of use.
- **Multi-Unit** abutments for Axiom[®] REG/PX.
- **Serenity[®]** Warranty Program.



▶ Watch the video

www.anthogyr.com

2 237, Avenue André Lasquin - 74700 Sallanches - FRANCE
Phone: +33 (0)4 50 58 02 37 - Fax: +33 (0)4 50 93 78 60

Anthogyr
PRIME MOVER IN IMPLANTOLOGY

Quality of implant surfaces and deficient osseointegration

Part I: Deficient implant surfaces and production processes

Author_Dr Nikolaos Papagiannoulis

Implant failures occur regularly and are thus part of everyday practice. Manufacturers claim success rates above 99 per cent. As experience has shown, however, such rates seldom correlate with practice. They are perfect for marketing purposes, but do not give any feedback about the true reason for implant failure. Often, data from independent studies is lacking or analysis from the manufacturer is classified.¹⁻⁹

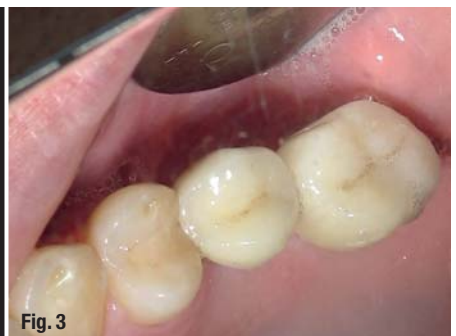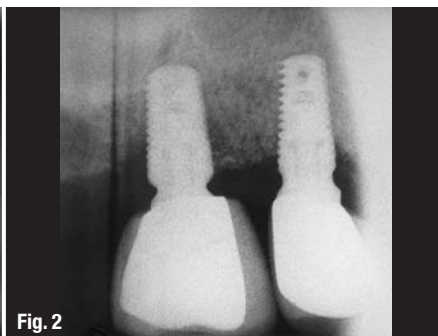
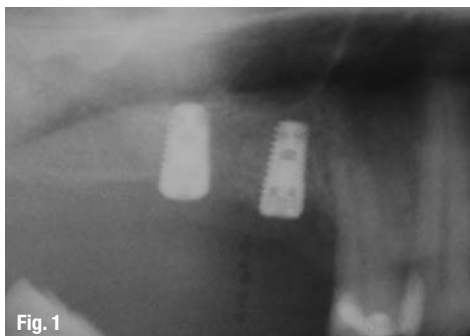First, it is necessary to define implant failure in therapy. Since the principle of osseointegration has been established for many years, implant healing nowadays is expected to simply be successful. However, implant therapy is only reasonable if it is considered to be superior to conventional therapies, such as bridgework and dentures, in each specific case. Implant therapy should be applied only if long-term stability is guaranteed and higher comfort, as well as superior aesthetics, can be achieved. If we consider which of these factors can be realized in practice, suc-

cess rates of implant therapy are often lower than claimed by manufacturers.

Regarding the success of implant therapy, practitioners bear a major responsibility: tissue quality and quantity, implant positioning, prostheses, surgical protocols, mouth hygiene and surgical techniques endanger the success of therapy if performed wrongly. Besides all these factors, we as practitioners have to trust that the product has been accurately manufactured without deficiencies, impurities or faults. This is exactly the issue we want to control and analyse. As recent studies have shown, numerous implants lack accuracy and harbour surface impurities. Such findings, combined with specific clinical situations, raise the logical questions of if and how failures in production processes influence osseointegration.

Dental implants are manufactured workpieces; thus, faults and defects do occur. Such incidences can

Figs. 1-3 The clinical examination found a mesial rotation of implant #16 of approximately 10 degrees and implant mobility. The radiograph showed bone resorption around implant #16 (4.7 mm × 8 mm) of 2 mm distally and around implant #15 (4.1 mm × 8 mm) of 1 mm mesially.





Experience CAMLOG live!
www.camlog.com



Excellent Tube-in-Tube™
connection

Fast, secure positioning through
three grooves and cams

Millionfold proven SCREW-LINE
outer geometry

Alternatively with
platform-switching

High radial
position precision

Template-guided implantation
as an option

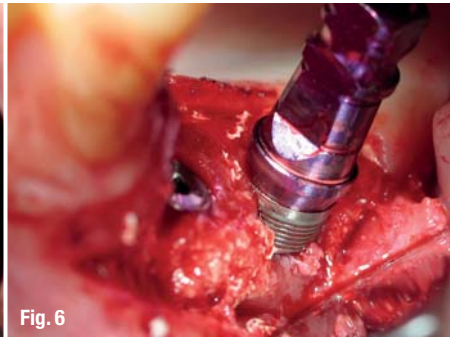
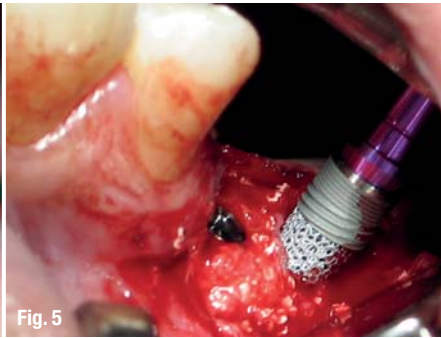
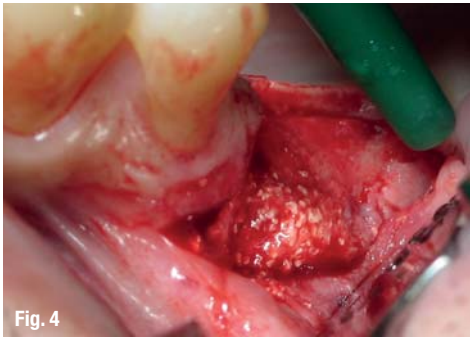SUCCESS

The CAMLOG® Implant System has been a genuine success story since 1999. Its outstanding user-friendliness, first-rate precision, and coherent prosthetic orientation have convinced more and more users. Rounding off its overall offer with an exceptional price-performance ratio, CAMLOG has become the trusted supplier of choice for numerous implant professionals. Go and see for yourself: www.camlog.com

CAMLOG stands for success.

a perfect fit™

camlog



Figs. 4–7 Insertion of two implants with a modern design and a porous tantalum cylinder, as well as promising osseo-incorporation.

only be avoided by means of a detailed quality control system. Apart from the problems already mentioned, further issues to consider include implant body design, compatibility between thread designs and implant surface treatment, implant cleaning procedure, as well as macro- and micro-roughness.

While many of the production defects lead to implant fracture, surface problems remain initially undetected. Implant surface problems can be observed at re-entry when, for example, the removal of the cover screw leads to implant removal or rotation. Such implants become mobile and fail; if not at this stage, this failure will be seen after several weeks of implant loading at the latest.

Case description

In this case, the clinical situation was similar to that described above. The patient received four implants in the maxillae in regions #15, 16, 24 and 26. Implant placement was delayed for all four implants and bone augmentation with a maxillary sinus lift limited in extent was performed at #16 and 26. The re-entry was performed five months postoperatively and prosthetic treatment two weeks later.

Two weeks after loading, the patient complained about occlusal malfunction in region #16. The clinical examination found a mesial rotation of #16 of approximately 10 degrees. A closer look revealed implant mobility. On the radiograph, we could detect bone resorption around implant #16 (4.7 mm × 8 mm) of 2 mm distally and around implant #15 (4.1 mm × 8 mm) of 1 mm mesially. Nonetheless, these observations were insufficient to explain the clinical findings (Figs. 1–3).

Healing period without complications

The mobility of #16 was identified as rotation. Separating the crowns from each other and the adjacent tooth, #14, led to explantation at zero torque. The macroscopic examination of the implants found a clean implant surface on the coronal half and some indications of tissue on-growth on the apical half. The

osteotomy in the bone showed no signs of soft-tissue ingrowth, as is often seen in cases of implant mobility caused by peri-implantitis. Further signs of inflammation were not evident.

Since we could not explain the reason for this implant failure, we decided against immediate implantation and to allow healing of the sockets. After a collagen fleece had been applied to the sockets, the wound was fixed with single sutures.

Implant #15 was sent back to the manufacturer for reclamation and analysis. Implant #16 was sent to a university for further examination, microscopy and reflection electron microscope morphometry. Our focus was on the analysis of defects and determination of the implant surface roughness in order to compare this analysis with the manufacturer's data.

Three months after the implant failure, the surgical was repeated. Since we had not received a statement from the manufacturer yet, we decided on a different implant type. We inserted two implants with a modern design and a porous tantalum cylinder, as well as promising osseo-incorporation (Figs. 4–7). In order to reduce risk and prevent any further complications, we allowed a healing phase of four months, taking into consideration that the rest of the implant body had shown standard surface characteristics.

During surgery, we determined after raising the flap that no bone loss resulting from the explantation had occurred. Also all of the bone augmented buccally during the first surgery (region #15) remained. These findings solidified our strong suspicion that the first implant probably had surface defects that had influenced osseointegration. Guided bone regeneration at region #16 to ensure 2 mm of bone buccally (sandwich technique with autologous bone, allograft and xenograft; Figs. 8&9) was performed. The implants inserted had a diameter of 4.1 mm and 4.7 mm, respectively.

The implants' healing occurred without any complications. After implant loading, we performed another radiograph to observe peri-implant tissue and

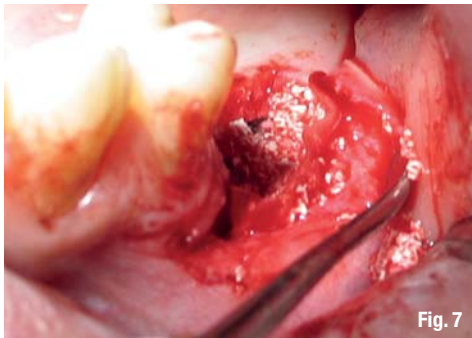


Fig. 7

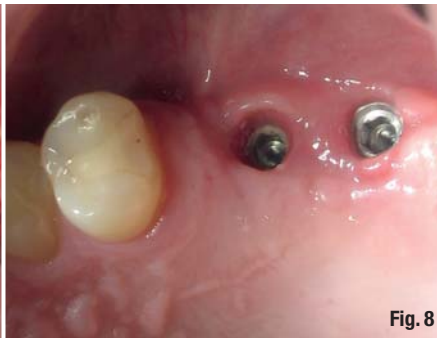

Fig. 8

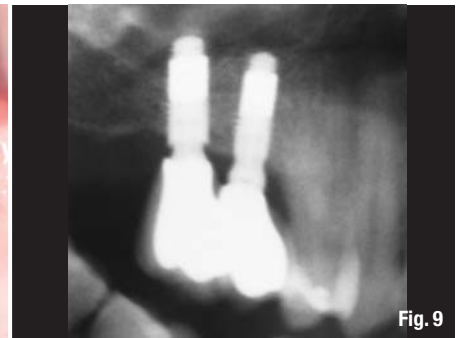

Fig. 9

ensure that there was no cement around the emergence profile.

Discussion

In recent decades, numerous reviews have shown how osseointegration works and what roughness and surface characteristics promote the desired tissue response. These studies have also investigated how a suitable microstructure advances bone regeneration around implant surfaces. Furthermore, independent from additive or subtractive production processes, production faults, inaccuracies, impurities, residue, and incompatibility of design and roughness methods do not influence osseointegration positively.¹⁰⁻¹⁶

Findings like the above are currently the subject of controversial debate. Their influence on osseointegration has not been proven yet. Nonetheless, such production issues cannot promote implant healing. As we will see in the next part of this case series, debris and residue on the surface reduce implant-bone contact and thus endanger osseointegration. The same negative progress can be observed when surface roughness is reduced, for example, by an incomplete and inhomogeneous surface treatment.¹⁷⁻²⁰ It would be interesting to investigate how often implant failures can be ascribed to production failures by the manufacturer.

There are numerous steps that performed wrongly could lead to implant failures, from surgery to prostheses, and including mouth hygiene, medicaments and habits. If we eliminate iatrogenic and hygienic factors, dental implants will remain workpieces that are abundantly defective.

Implant manufacturers are responsible for the product they market, just as we bear the responsibility for our treatment of our patients. Good quality control is not random, but deals with each component systematically. In this case, the patient received implants with the same serial number in regions #24 and 26. Implants #15 and 16 were from the same manufacturer but with different serial numbers. A recall of implants with specific serial numbers, three months

postoperatively, was declared a documentation fault. For those implants that had been inserted, operators were recalled, although implants with those specific serial numbers began to fail in succession.

Recalls must be justified honestly, so that imperfections can be corrected. The relationship between manufacturers and users is based on confidence. Openness and frankness solidify this confidence. Visits to the production site and close contact with service staff and colleagues are important utilities for the user.

Finally, it is important to understand that not every surface and surface treatment is compatible with every macro and thread design. Combining good features in a product does not automatically result in a superior product. It is rather the consequence of the underlying research and development that has evolved the product or a feature to a reliably performing workpiece. A deeper understanding of mechanics, physics and material science will allow us to evaluate dental implants and their components during the healing period and in the long term when interacting with the organism and the stomatognathic system.

Conclusion

In Part II of this series, macro-images of various implants that failed and the corresponding sterile-packaged ones will be shown. In Part III, failed and sterile-packaged implants from the various manufacturers will be compared under a scanning electron microscope.

contact

Dr Nikolaos Papagiannoulis

Dental Esthetics
Bahnhofstr. 64
69151 Neckargemünd
Germany

www.fsde.com.gr
info@fsde.com.gr

Figs. 8 & 9 Sandwich technique with autologous bone, allograft and xenograft.

Treatment of an unusual presentation of radicular cysts

Author_Dr Manthan Desai, India

_Radicular cysts are the most common (52–68 per cent) cystic lesions affecting the jaw.¹ They are commonly found at the apices of involved teeth and sometimes lateral to accessory root canals. They are a direct sequel of chronic periapical infection.¹ Most of them are asymptomatic and are discovered when periapical radiographs are taken of teeth with non-vital pulps. Patients often complain of slowly enlarging swellings. Radiographically, most radicular cysts appear as round or pear-shaped unilocular radiolucent lesions in the periapical region. The cyst may displace adjacent teeth or cause mild root resorption.²

riosteum and platelet-rich fibrin (PRF) with demineralised freeze-dried bone allograft (DFDBA).

_Case Report

A 17-year-old female patient reported to the Department of Periodontics, HKES's S. Nijalingappa Institute of Dental Sciences and Research, Gulbarga, India, with a chief complaint of pain, swelling ongoing and pus discharge in the lower anterior region since two months. Past history revealed trauma in the lower anterior region five years ago with recurrent swelling and pus discharge.

On intraoral examination, inflamed and swollen gingiva was seen in relation to 41, 42, and 43 (FDI notation). A draining fistula was seen on the labial aspect in relation to 41 (Fig. 1). 42 had grade I mobility, whereas no mobility was noticed with 31, 41, and 43. A pulp vitality test was negative with 41, 42, and 43, while adjacent teeth showed normal response. Periodontal probing depth was ≤ 3 mm for concerned teeth, and no clinical attachment loss was seen. They were also painless on vertical percussion. On radiographic examination, two radiolucent areas of size approximately 2 x 2 mm were seen in relation to 41, 42, and 43 (Fig. 2). No root resorption was seen.

The treatment plan comprised of endodontic treatment of non-vital teeth followed by surgical enucleation of cystic lesions if necessary. The treatment plan was explained to the patient, and a written informed consent was obtained. In the same visit, root canal treatment was started under rubber dam application followed by working length determina-

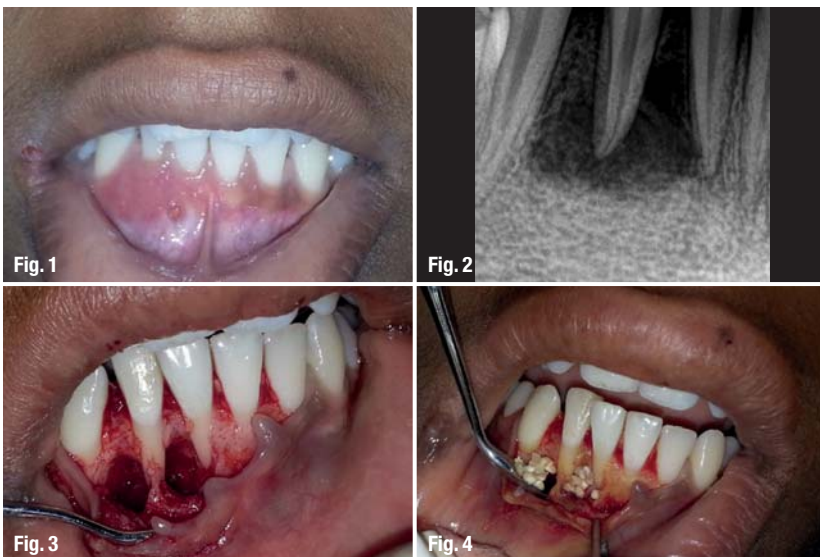
The following case report presents the successful treatment of radicular cysts using autologous pe-

Fig. 1 Preoperative view of the lesion.

Fig. 2 Preoperative radiograph.

Fig. 3 Debridement of the lesions.

Fig. 4 DFDBA graft placement.



tion. After complete biomechanical preparation, 2 per cent chlorhexidine gluconate was used as an irrigant and intracanal medicament. In the subsequent visits, root canal treatment was completed. Persistent pus discharge was observed at three months after endodontic treatment, and surgical enucleation was planned.

The procedure was as follows: local anaesthesia was administered, crevicular incisions were given, and a full thickness mucoperiosteal flap from 41 to 43 and a split thickness flap in regio 31 and 32 were reflected. The area was degranulated revealing two small perforations of the buccal cortical plate in the regions of 41 to 43 of size 1 x 1 x 1 mm. The remaining buccal cortical covering was carefully removed with rotary and hand instruments to expose the rest of the lesions of size 3 x 3 x 2 mm. Fragmented pieces of the lesion were freed from the bone, and a complete curettage of the cystic lesions was done (Fig. 3). The cystic cavities were thoroughly irrigated, and a root biomodification of involved teeth was done using tetracycline. DFDBA was mixed with sterile saline solution and grafted in an attempt to close the defect via osteoconduction (Fig. 4). Autologous healthy periosteum was harvested from regio 31–32 (Fig. 5), and PRF was prepared from the patient's blood, as described by Choukroun et al.³ The lesion was covered with periosteum, over which PRF was placed as a second layer of barrier membrane covering the graft (Figs. 6 & 7).

The flap was coronally advanced and closed with interrupted sutures using 3-0 black braided silk (Fig. 8). A periodontal dressing was applied at the surgical site. The patient was prescribed amoxicillin 500 mg

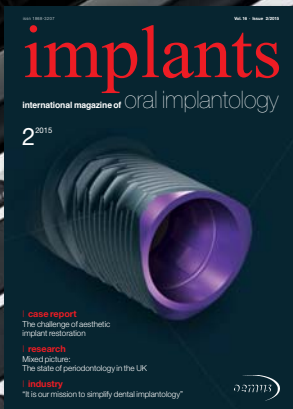TID and diclofenac sodium 50 mg TID both for 5 days with 0.12 per cent chlorhexidine gluconate rinse BD for seven days. The patient was asked to report after a week for suture removal, and the curetted tissue was submitted for histopathological examination. The patient returned for the postoperative visit, and the healing was uneventful.

Histopathology revealed the presence of a varying thickness of epithelium with fibrocellular connective stroma. The epithelium was disrupted with infiltration of chronic inflammatory cells along with vacuolations within the epithelium. The connective tissue showed dense infiltration of lymphocytes and plasma cells with few macrophages (Fig. 9). A diagnosis of radicular cyst was given. The patient was followed up for nine months. A radiograph at six months shows a healing lesion (Fig. 10). A subsequent radiograph nine months after operation (Fig. 11) reveals increased radiopacity where the bone graft was placed, and no evidence of recurrence of the lesion was seen (Fig. 12).

Discussion

A radicular cyst is an odontogenic cyst of inflammatory origin preceded by a chronic periapical granuloma and stimulation of cell rests of Malassez found in the periodontal membrane. The pathogenesis of radicular cysts comprises of three distinct phases: the phase of initiation, the phase of cyst formation, and the phase of enlargement.⁴ The initial swellings of these radicular cysts are usually bony hard, but as they increase in size, the covering bone may become very thin despite initial subperiosteal bone deposition. With progressive bone resorption, the swellings

AD



PUBLISH YOUR
EXPERTISE!

Become an author for
implants—international
magazine of oral
implantology

Please contact:

Georg Isbaner
Editorial manager
g.isbaner@oemus-media.de



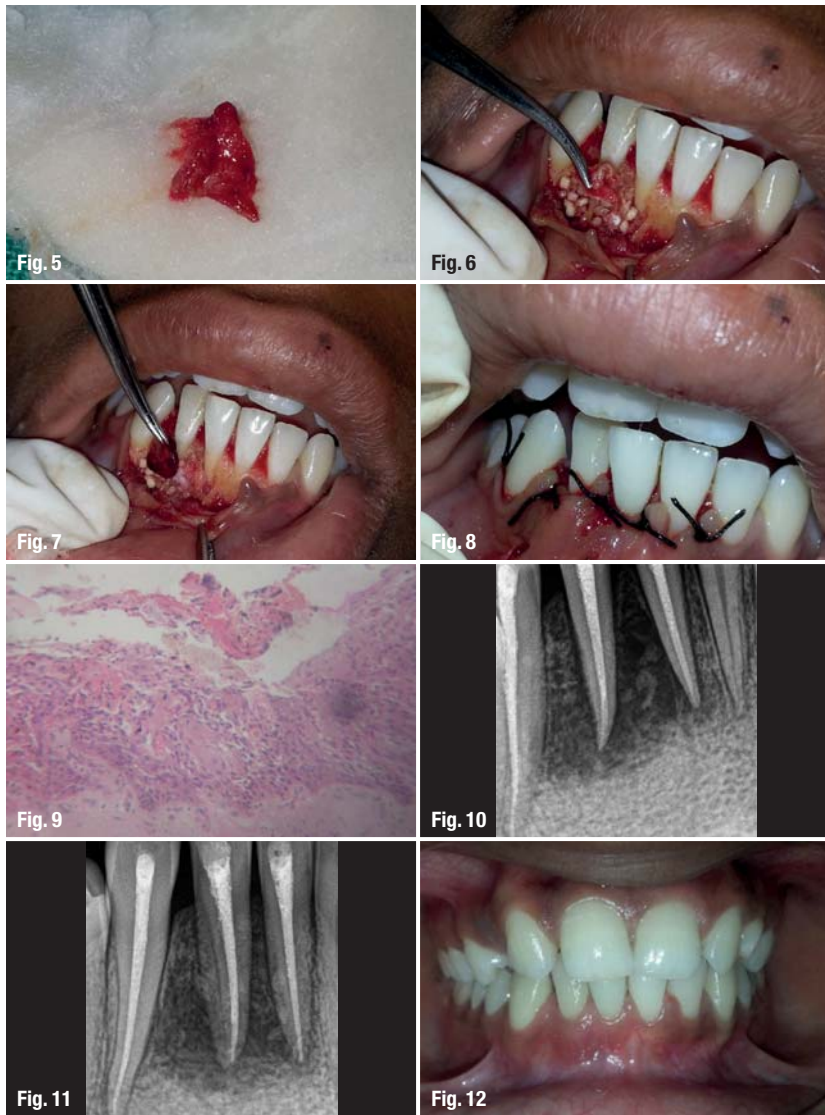

Fig. 5 Harvested autologous periosteum.
Fig. 6 Autologous periosteum placed as a barrier membrane.
Fig. 7 PRF placed as a barrier membrane.
Fig. 8 Sutured flap with 3-0 silk suture.
Fig. 9 Histopathology of excised cyst.
Fig. 10 Six months postoperative radiograph.
Fig. 11 Nine months postoperative radiograph.
Fig. 12 Healing at nine months after operation.

exhibit "egg shell crackling". The associated teeth are always non-vital and may show discolouration. Although the associated teeth usually show no root resorption, there may be smooth resorption of root apices. When cysts are intact, cyst cavities may be filled with brown- or straw-coloured fluid, giving them a shimmering gold appearance.⁴ Radicular cysts are inflammatory lesions leading to bone resorption and can reach great dimensions and become symptomatic when infected or with great size due to nerve compression. The main cause of failure of endodontic treatment is generally accepted to be the continuing presence of microorganisms in the root canal system that have either resisted treatment or have reinfected the root canal system. *E. faecalis* was the most frequently found microbe in such cases.⁵ Chlorhexidine gluconate has been proposed for use both as an irrigant and as a medicament especially in endodontic retreatment. As a medicament, it is more effective than calcium hydroxide in eliminating *E. faecalis* infection inside dentinal tubules.⁶ As an irrigant, it appears as effective or superior to sodium

hypochlorite in the elimination of *E. faecalis*.⁷ The adult human periosteum is highly vascular and is known to contain fibroblasts, osteoblasts, and stem cells. Skoog⁸ subsequently introduced the use of periosteal flaps for closure of maxillary cleft defects in humans; he reported the presence of new bone in cleft defects within 3–6 months following surgery. Furthermore, animal studies have reported heterotopic ossification in different organs after implantation of free periosteal grafts.^{9,10} In all age groups, the cells of the periosteum retain the ability to differentiate into various cells.¹¹ On the basis of these observations, it can be hypothesised that the periosteal membrane can contribute to the stimulation of new bone formation and has an immense potential for regeneration.

PRF belongs to the new generation of platelet concentrates with simplified processing. PRF contains a variety of growth factors, which enhance healing by increasing angiogenesis and matrix biosynthesis.¹² The immense osteoinductive capability of DFDBA is well-described in the periodontal literature.¹³

The treatments of these cysts are still under discussion, and many professionals opt for a conservative treatment by means of endodontic technique.¹⁴ However, in large or non-healing lesions, the endodontic treatment alone is not efficient and surgical treatments like marsupialisation or enucleation should be considered.¹⁵ In this case, surgical enucleation was preferred and was performed uneventfully.

Conclusion

To conclude, a radicular cyst is a common condition found in the oral cavity. However, it usually goes unnoticed and rarely exceeds the palpable dimension. This case report illustrates the successful management of a radicular cyst with enucleation and endodontic treatment. The use of autologous periosteum and PRF has a promising future in periodontal regeneration.

Editorial notes: A list of references is available at the publishers.

The authors declare that they have no conflict of interest. This article was first published in: Case Reports in Dentistry, vol. 2013, Article ID 893791, 5 pages, 2013. doi:10.1155/2013/893791

contact

Dr Manthan Desai MDS
 Consultant Periodontist and Implantologist
 Mumbai, India
 manthandesai.md@gmail.com

45TH

DGZI INTERNATIONAL ANNUAL CONGRESS

**SAVE
THE DATE**
October 2–3,
2015

October 2–3, 2015

Wiesbaden, Germany | Dorint Hotel Pallas

Scientific Director: Prof. (CAI) Dr Roland Hille/DE

Dental technology and implantology–
Interface to reach success



www.dgzi-jahreskongress.de

Gold Sponsor



Silver Sponsor



Bronze Sponsor



FAX REPLY // +49 341 48474-290

I would like to receive further information on the
45TH DGZI INTERNATIONAL ANNUAL CONGRESS
on October 2–3, 2015, in Wiesbaden, Germany.

Practice Stamp

implants 2/15

Mixed picture: The state of periodontology in the UK

Author_Prof. Francis Hughes, London

The UK is gearing up to host the largest conference in Periodontology and Implant Dentistry ever held with EuroPerio8 taking place on 3–6 June at London ExCel. Over 100 speakers will contribute to the main scientific programme and there are many additional sponsor sessions. Over 1,500 abstracts have been accepted. Already over 7,000 periodontists, implantologists, general dentists and dental hygienists from 96 different countries have confirmed their attendance. We expect to have nearly 10,000 people at the conference in total, a new record for a conference in this field, and it is still not too late to register.

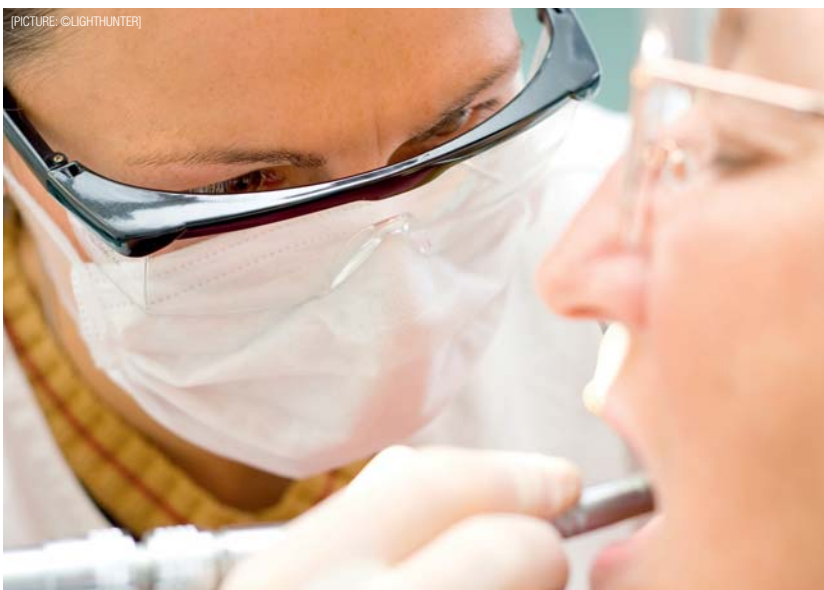
Given the huge popularity of this event, it is perhaps a perfect time to reflect on the state of periodontology in the UK. It is clear that periodontal disease is not going to go away any time soon. Although there is a lack of detailed epidemiology of the disease

in the UK, the Adult Dental Health Survey provides a useful indicator of trends in the epidemiology of the disease, even if it probably seriously underestimates true prevalence rates, owing to the limited methodology used in this survey.

The good news is that there has been significant reductions in the number of people with visible plaque and calculus present, (but this is still reported as 45 per cent of the population) and concomitant reductions in the amount of mild periodontal disease, consisting of gingivitis and those with low levels of attachment loss. However, perhaps unexpectedly, this has not been associated with similar reductions in moderate and severe periodontitis. In fact, the number of adults with severe periodontitis (pocketing of 6 mm+) has increased from 6 per cent in 1998 to 9 per cent in 2009. The reasons for this may be complex but are likely to include the fact that we have an increasingly aging population, and that dentists are (rightly) taking out fewer teeth even when judged to have poor long term prognoses.

This disconnection between trends in plaque control to more severe destructive periodontitis is a common finding in a number of recent epidemiological surveys in different populations and underlines the complexity of aetiological factors which determine susceptibility to destructive periodontitis. Although plaque tends to correlate directly with gingival disease, in the majority of people this may not necessarily result in the progression to more severe periodontitis. The major risk factors which are implicated in this process including smoking, genetic factors, and medical factors, particularly diabetes and medications such as calcium channel blocker antihypertensive drugs.

The impact of the well documented rise in the numbers of older people may be particularly impor-



Access to specialist treatment services within the NHS remain very patchy.

“ **Periodontal disease** has typically been seen as a “**silent disease**” which might have few consequences unless resulting in **tooth loss**. ”

[PICTURE: ©RA2STUDIO]



tant for future treatment needs. The over 65-year olds are often fit and well and have high expectations for their continued health needs, even though they may also suffer from common medical conditions such as type 2 diabetes and hypertension and may take multiple medications.

Impact of periodontal disease

Periodontal disease has typically been seen as a “silent disease” which might have few consequences unless resulting in tooth loss. However, there is now lots of evidence to refute this concept. Patients with periodontitis consistently report significant impacts of the condition on their quality of life, particularly impacting on function, aesthetics, comfort and self-esteem. Furthermore, even mild disease resulting in gingival bleeding and perhaps halitosis impact on social acceptability and remain highly legitimate reasons for treatment need. Prevention of more severe disease is of course best achieved by primary prevention and early disease control by achievement of high levels of plaque control together with management of modifiable risk factors, particularly smoking cessation.

Periodontal disease has now been associated with risk of a number of other systemic conditions, most notably cardiovascular and cerebrovascular disease, among many other conditions. It has been clearly shown that periodontal disease causes a measurable systemic inflammatory response but it is not at all clear that periodontal treatment actually reduces the risk of these conditions, or whether the conditions are associated through common factors such as genetic predisposition. Nevertheless, given the importance of these systemic conditions it is recommended that periodontal health should be regarded as part of general health.

Manpower

Clearly there remains a major, often unmet, periodontal treatment need within the UK population, which represent a significant challenge for dental health professionals. There are currently over 30,000 registered dentists and over 6,000 dental hygienists in the country. In addition, there are approximately 300 periodontists on the specialist list, who work mainly in private specialist practices or in the hospital and university services. Given that there are an estimated five million cases of moderate to severe periodontitis, and perhaps 20 to 30 million with some signs of periodontal disease, it would appear that these relative proportions of dental manpower are not currently ideally suited for the provision of primary and secondary periodontal care according to actual clinical needs. There are of course a significant but unknown number of general dentists who provide a degree of periodontal treatments that might otherwise considered to be at secondary care level.

The number of specialist periodontists in training is small (certainly less than 20 every year), which is probably insufficient to maintain the total number on the specialist list over time. There is considerable interest and some commitment to providing a group of dentists with additional skills in specific restorative specialties including periodontology, who could potentially meet much of the treatment need for secondary care periodontal treatment, but this group does not really exist at the present time. It should also be commented that this model of periodontal care provision does remain essentially untested on a large scale at present.

Overall the picture of periodontal care provision in the UK at present is mixed at best. In most areas of the

country, those choosing to seek their periodontal care from the private sector, are able to access specialist care from highly trained periodontists and their teams, who often provide a wide range of effective and sophisticated treatment options. However, outside the dental schools there is little or very patchy access to specialist treatment services within the NHS. Recognition of this manpower deficit and a move to address it through intermediate level training in periodontal therapy is an encouraging but still unproven development.

Possibly the most important health professional for the implementation of primary prevention are dental hygienists. Although there is little evidence on deployment of hygienists within primary care, anecdote suggests that they may spend much of their time removing supragingival calculus (as prescribed by their employing dentists) without any routine attention to properly targeted attempts to provide adequate personalised oral hygiene instruction. Indeed the whole issue of the routine "scale and polish" as a therapeutic intervention has been questioned and is the subject of current research projects whose findings are yet to be reported.

Implantology

Many aspects of implantology, including surgical management, management of soft and hard tissues, and management of peri-implant health and disease, are squarely within the realm of periodontal treatments, and implantology is indeed a substantial component of specialist training in periodontology. Whilst the growth in implant treatments has been markedly slower than in many other European countries, there is now a large and ever growing use of dental implants in UK dental practice and a wider acceptance from significant numbers of patients of the value of implants and their potential cost/benefits. It is quite clear that the potential for implant treatment could never be met within the National Health Services as the costs could potentially swallow much of the total NHS budget. However some recognition of the clinical needs and cost/benefits on a more individual basis even within the NHS dental services would appear to be inevitable in the future.

There are two major developing issues, which are partly related to each other, which may particularly affect the periodontist practicing implant dentistry. Firstly, there is the growing problem of peri-implantitis. Reported prevalence rates of long standing implants do vary but are typically on the region of 30 per cent. This progressive destructive condition creates particular problems as it appears to be much more difficult to manage than its first cousin, periodontitis. As many more implants have been placed for a

number of years there is great concern about the growth of this condition.

Secondly, apparently oblivious to the above problems and an understanding of long term survival rates of teeth and implants, there is a disturbing trend amongst some to advocate early removal of diseased teeth and replacement by implants. There may be some short term gains for the dentist and/or patient to be had from this approach but it is a sure way to store up major new problems for the future.

So there remains a lot to do tackle periodontal disease in the UK. One of the most encouraging developments in the near future is the development of care pathways within the General Dental Services which place considerable emphasis on prevention, risk factor management and tackling early periodontal disease, as well as mapping out appropriate care pathways for those in need of more involved periodontal treatment. This will inevitably be painful for some as it represents a new way of service delivery based on evidence based outcomes. However it also carries with it the prospects for better provision of higher level periodontal care, particularly if the planned development of dentists with some specialist skills is successful.

Challenges remain

The challenge of managing periodontal disease in an increasingly aging population are likely to become a major issue going forward, and at time the profession will have to consider how it interacts with general medical services, for example in screening and detection of the currently estimated 750,000 people in the UK who may have undiagnosed diabetes. The private sector looks set to increase its provision of specialist periodontal care and implant provision. The challenges of long term implant survival and management of peri-implant disease will present new challenges for many. There will undoubtedly be novel treatments and developments which we can only speculate on. Interesting times indeed but there is lots to do.

about the author



Francis Hughes is Professor of Periodontology at Kings College London and Chair of the EuroPerio8 conference in London.


He can be contacted at: francis.hughes@kcl.ac.uk.



Bio-Emulation™



Tribune CME



Bio-Emulation™ Colloquium 360°

4-5 July, 2015, Berlin, Germany

Mentors



Ed McLaren



Michel Magne



Pascal Magne

Emulators



Akinobu Ogata (guest)



Andrea Fabianelli



Antonio Saiz-Pardo Pinos



August Bruguera



David Gerdolle



Fernando Rey



Gianfranco Politano



Jason Smithson



Javier Tapia



Jungo Endo



Leandro Pereira



Marco Gresnigt



Oliver Brix



Panos Bazos



Sascha Hein



Stephane Browet



Thomas Singh



Walter Gebhard (guest)

Details & Online Registration

www.BioEmulationCampus.com

Registration fee: 599 EUR +VAT



ADA CERP®
Continuing Education Recognition Program



Tribune Group is an ADA CERP Recognized Provider. ADA CERP is a service of the American Dental Association to assist dental professionals in identifying quality providers of continuing dental education. ADA CERP does not approve or endorse individual courses or instructors, nor does it imply acceptance of credit hours by boards of dentistry.

Tribune Group GmbH is designated as an Approved PACE Program Provider by the Academy of General Dentistry. The formal continuing dental education programs of this program provider are accepted by AGD for Fellowship, Mastership, and membership maintenance credit. Approval does not imply acceptance by a state or provincial board of dentistry or AGD endorsement.

Main Sponsor



Manufacturer News

Bicon

30 years of clinical success and innovation

This year, Bicon Dental Implants celebrates 30 years of clinical success and innovation. Its implant design has offered dentists a time-proven solution for missing dentition by incorporating plateaus, sloping shoulders, and a bacterially-sealed, 1.5° locking taper implant to abutment connection.



With the plateau design, cortical like bone forms around and between each plateau. This Haversian bone allows for the routine use of 5.0 mm short implants. The sloping shoulder provides the necessary room for bone to support interdental papillae that are gingivally aesthetic.

These same features have made restorative advancements possible by allowing clinicians to capitalise on the aesthetic benefits of the implant design. Bicon's 360° of universal abutment positioning, for example, provides for the cementless and screwless Integrated Abutment Crown™, which consistently provides for a non-metallic aesthetic gingival margin. Most recently, Bicon has introduced TRINIA—the next generation CAD/CAM material for metal free substructures.

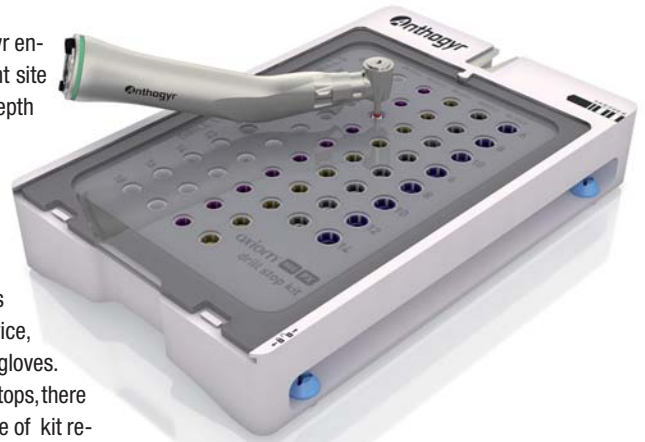Bicon Dental Implants

Arborway 501
Boston, MA 02130, USA
www.bicon.com

Anthogyr

Performance built on ergonomics

The drill stop kit* developed by Anthogyr enables the success and safety of implant site preparation to be guaranteed thanks to depth control. With the convenient and smart kit daily work is made easier. It is ergonomic with a direct connection to the contra-angle. The integrated error-prevention mechanism helps to avoid inversion during the storage step. What is unique is the no-contact removal device, thus there is no risk of perforating gloves. Thanks to the locking feature of the drill stops, there is a "fall prevention" function in the case of kit reversal. Furthermore, the kit is sterilisable at 135 °C.



**Not available in all countries. Please contact the Anthogyr local representative.*

With the drill stop kit, dentist save valuable time since the drill sequence can be prepared before surgery. Finally, the drilling protocol is simplified by allowing a better concentration on the drilling axis and depth, thereby guaranteeing a safer procedure.

Anthogyr SAS

2237, avenue André Lasquin
74700 Sallanches, France
www.anthogyr.com

Nobel Biocare

New wide-platform implant



NobelActive is known as 'an implant like no other', and the new 5.5 mm wide-platform variant has all the qualities that make the implant system unique. To condense bone gradually, its tapered body has threads that narrow towards the apex, while the apex itself features drilling blades to preserve bone by allowing a smaller osteotomy. This is all designed for high primary stability, even in soft bone and extraction sockets. The implant gives clinicians the option to adjust the implant position during insertion. Reverse cutting flutes on the apex make it possible to control the desired angulation following final drilling. It can also be partially reversed and then redirected to achieve the best possible restorative orientation.

Restorative flexibility comes from NobelActive WP's* conical connection, which is compatible with Nobel Biocare's innovative restorative solutions. These include cement-free options such as the NobelProcera FCZ (Full-Contour Zirconia) Implant Crown, which offers high strength and avoids veneer chipping, and the ASC (angulated screw channel) Abutment for easier access and increased aesthetic possibilities.

* References are available upon request.

Nobel Biocare Services AG

P.O. Box
8058 Zurich-Airport, Switzerland
www.nobelbiocare.com

CAMLOG

More opportunities, greater flexibility

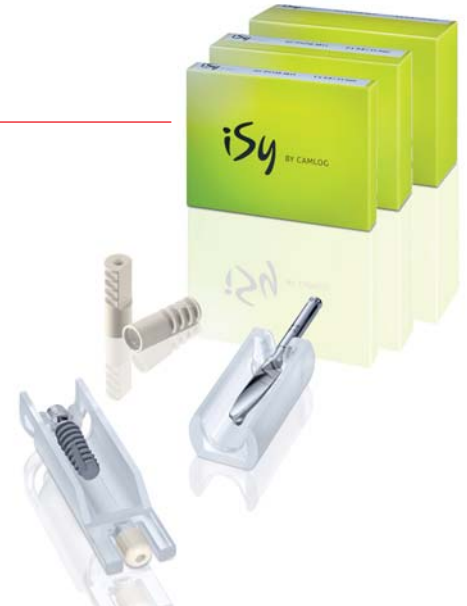The iSy Implant System has found numerous supporters who had waited for a cost-efficient solution from a renowned manufacturer. Among other things, those using the iSy concept benefit from the fact that implants, healing caps, multi-function caps and a single patient form drill are included in a single set. So far, the concept is based solely on transgingival healing and is used by many customers to gain more patients for restorations with implants.

As of July 2015, the prosthetic portfolio of the implant system will be extended by several prefabricated abutments. The new iSy Esthomic® Abutments allow aesthetically cemented reconstructions. Screw-retained healing caps adapted to the emergence profiles of the abutments will become available in a variety of profile diameters and heights. Final restoration directly on the implant base will become possible and offers the clinician a cost-effective restoration option and even greater flexibility in the course of treatment.

CAMLOG treads a new path with the free provision of open STL data sets of the iSy Abutment connection. This enables the milling centers to fabricate self-manufactured abutments and retain value creation fully in-house.

In addition to the existing impression taking method from the implant base with the multi-function caps, the new impression posts can be used for impression taking directly from the implant shoulder with an open or closed tray. Scanning can be performed either from the implant shoulder with screw-retained scanbodies or from the implant base with the multi-function caps which are included in the iSy Implant Set.

The iSy standard range with so far three implant diameters and lengths will be extended by a short implant (7.3 mm). A major advantage of this short implant is that it can also be used if limited bone is available. This can avoid bone grafts, for example, in sinus floor elevation. The short iSy Implant will be



available as of July 2015 and will at first be supplied in the single implant set, including a healing cap, a single patient form drill and two multi-function caps.

CAMLOG Biotechnologies AG

Margarethenstrasse 38
4053 Basel, Switzerland
www.camlog.com

AD

Bicon Europe Ltd. ■ Hauptstr. 1 ■ 55491 Buechenbeuren ■ Germany ■ Phone +49 (0)65 43 / 81 82 00 ■ Fax 81 82 01
germany@bicon.com ■ www.bicon.de.com

Shortest Implants –
Longest History

“It is our mission to simplify dental implantology”

Source_DTI

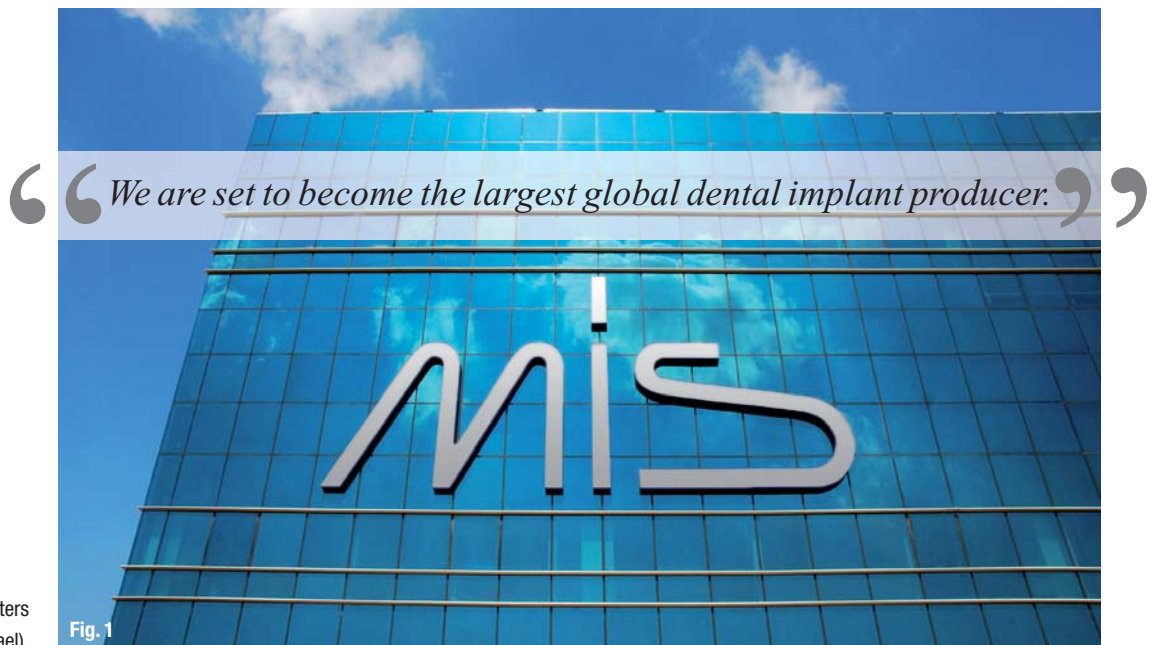

Fig. 1 MIS headquarters
(Photos courtesy of MIS, Israel).

MIS Implants Technologies is a global specialist in the development and production of advanced dental implantology products and solutions. The company, which started as a family-run business, was founded in 1995—a time when not many people understood the potential of dental implants, CEO Idan Kleifeld told Dental Tribune International (DTI) at a meeting at the beginning of 2015.

Since its beginnings, MIS has seen significant growth, especially within the past ten years. “Today, the company has succeeded in building a recognised global brand in the market and is the only non-premium company operating on a global scale,” Kleifeld said. Headquartered in Israel, MIS currently has operations in 65 countries worldwide, covering major dental markets, such as the US, China and Germany, through a well-established network of local distributors.

In 2009, MIS moved operations to a large purpose-built production complex located in a new high-tech industrial park in northern Israel. “Our location adds to our uniqueness. Israel is a country of high innovation and offers particularly favourable conditions for manufacturing, because of the quality of education and people’s high levels of motivation. Furthermore, salaries are much lower than in competitor countries, making manufacturing especially profitable,” he stated.

The MIS building in the Bar-Lev Industrial Park spans about 10,000 m² and has two production floors with 50 Swiss high-precision machines running 24 hours a day from Sunday to Friday. “The facility was designed and built for growth. In the near future, our automatic warehouse, which currently covers only half of its potential total area, will double in size,” Kleifeld explained.



Fig. 2



Fig. 3

DTI further learnt that MIS primarily produces for stock, as products must be shipped to local distributors within two working days. For increased efficiency, processes controlling quality, sterilisation, packaging and storage are largely automated. This allows MIS to produce over 800,000 implants per year.

The production site in Israel has a dedicated training centre with a fully equipped dental clinic for live surgeries. Kleifeld said, "We see education as an important tool to acquire new customers, especially in developing markets. It is an important driver in this business, and we offer doctors both fundamental and advanced training courses on MIS products and protocols."

In 2015, MIS will be introducing some important innovations. Only recently, the company officially opened its MCENTER Europe, the new MIS digital dentistry hub in Berlin in Germany, in order to meet the needs of its growing customer base in central Europe. The centre offers direct services provided by locals to local customers, bringing all MIS digital dentistry products together in one location. It is aimed at providing a comprehensive range of services to clinicians through advanced digital dentistry and CAD/CAM technologies that facilitate fast and accurate surgical implant procedures with reduced chair-side time and greater predictability in outcomes.

"We are extremely excited about the opening of the new MCENTER Europe facility, and especially proud to be able to offer MIS quality and simplicity in providing our customers throughout the region with highly accurate and efficient guided implant placement procedures and CAD/CAM solutions," said Christian Hebbeker, MCENTER Europe Manager.

In addition to the new MCENTER Europe, the company will be entering the premium segment for dental implants with the launch of a new implant system

later this year. It has a truly innovative design and consists of high-quality implants that are completely new in the market and will fit within the premium segment. MIS plans to offer this new implant system to its global distributors at the end of the second quarter of 2015, for local distribution worldwide.

The name MIS originally stood for "Medical Implant Systems". However, it is also an acronym that reflects the company's main maxim to "Make it Simple". "It is our mission to simplify dental implantology and, in order to become the preferred choice of dentists worldwide, we offer new and innovative products based on simple, creative solutions. Design and handling are made simpler, and all products are engineered to allow efficient, time-saving surgical procedures," Kleifeld said. "With this simplified approach, we are set to become the largest global dental implant producer," he added.

However, the "Make It Simple" motto appears to apply to more than the company's products. The MIS philosophy defines almost all areas of the business (from human resources to production), and the organisational structure is simple and characterised by flat hierarchies. "Make it Simple" embodies the start-up mentality that remains vibrant in a company that has become one of the largest in the global dental implant market.

contact

MIS Implants Technologies Ltd.

P.O. Box 7, Bar Lev Industrial Park
20156, Israel

Tel.: +972 4 9016800

Fax: +972 4 9918623

service@misimplants.com

www.mis-implants.com

Fig. 2_Production.

Fig. 3_MIS Implants Technologies CEO Idan Kleifeld.

ClaroNav introduces new device for navigated surgery

Author_Timo Krause, Germany

ClaroNav is dedicated to the development of surgical navigation solutions. At current IDS, ClaroNav introduced its new device Navident, which is an affordable and practical dynamic navigator for dental surgeons. Timo Krause spoke to Tom Tilmans, Director of Sales & Marketing EMEA, about the new developments.

_Timo Krause: Navident promises a completely new approach of image-guided implant navigation. What was the initial idea for the development?

Tom Tilmans: The inclusion of the CBCT scan as part of the standard of care for dental implant planning and placement has been of great benefit to the surgeon, the restorative dentist and of course to the patients. A logical next step would seem to be dynamic surgical navigation utilising that CBCT scan as a map.

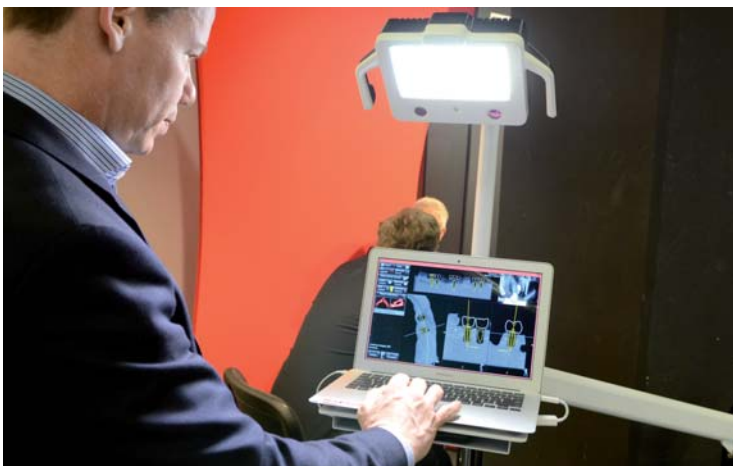
Dynamic navigation combines the advantages of performing highly accurate and minimally invasive surgery with the flexibility to make changes to the digital plan at any time during that surgery. Independent of any implant specific surgical kit, dynamic navigation offers the promise of a simple workflow, easily adapted to the freehand surgical techniques currently employed.

Dynamic navigation systems have been successfully tested since the early 2000s, and proven to provide these benefits in numerous papers. They have not gained widespread use, however, mainly due to their high purchase price and to usage difficulties caused by their immature design. Navident is different. It is affordable, practical and robust.

_What are the advantages of using Navident?

Using the CBCT image as a map, Navident guides surgeons just like a GPS guides drivers. The dental surgeon plans where implants should be placed. Navident, dynamically tracking the drill and the patient's jaw, provides guidance and visual feedback to ensure the implants are placed according to plan. This provides a range of benefits:

- Reduces errors. With Navident, implants are typically placed 3 times more accurately than freehand.
- Enables flapless drilling, which reduces chair-time, patient trauma, pain, and recovery time.
- Increases surgeon's confidence and maximises flexibility.
- The plan can be modified at any time, even during operation.
- The device attracts patients by providing a clear and visible competitive advantage.



Navident is designed to simplify the implant dentistry workflow and provides accurate guidance more effectively than rival solutions, including static guides. A single one-hour appointment may be sufficient, in uncomplicated cases, for a complete Navident-guided procedure, including NaviStent fitting, scanning (on site), planning, flapless guided drilling and implants insertion.

How long does it take to get familiar with the use of the system? Is a special training necessary/required?

For optimal patient outcome, we provide our customers the detailed knowledge required to become competent at using Navident.

The Navident workflow exists of four easy steps. Before getting started, people get an overview from patient diagnosis to navigated implant treatment, including hands-on drilling. We aim to be very practically oriented and focus on each step in the workflow.

You have introduced the Navident system to a worldwide audience at recent IDS 2015 in Cologne. Were you satisfied with the traffic and interest at your booth?

The IDS is a great place for companies as ClaroNav to demonstrate its innovative power. People showed great interest in new technology and we received a high number of particularly qualified trade visitors. We experienced a high level of internationality and decision-making competence. This proves the growing interest in dynamic navigation and its benefits.

Let's have an outlook into the future: Which trends do you see in the field of implantology?

The overall demand for implantology is projected to increase by 10 per cent for the next years, due to lifestyle influences and higher life expectancy. To handle the growing number of patients, clinicians need a solution that increases operational efficiency in their practice or hospital, which supports team collaboration and improves patient care.

Referring to implant navigation, the use of surgical templates often only complicates the workflow because it increases the complexity and the duration of the implantation procedure. Clinicians end up investing in expensive technology and not integrating it completely because of problems in work-



Tom Tilmans, Director of Sales & Marketing EMEA.

flow and accuracy or because of clinical issues.

Looking back at the IDS, it's unbelievable so many different vendors are offering so many different products for treating just one small part of the human body. The industry is dynamic, and successful innovations addressing the clinicians' needs have the potential to become standard of care. Navident is designed for clinicians who want the most accurate and reliable technology, and achieving time and cost savings at the same time. This is why

Navident will change your perspective on progressive dentistry.

ClaroNav is a young company within the dental market—speaking about the future: where do you see the further development of Navident?

Navident provides a comprehensive 3-D software package which allows the dental surgeon to import (CB)CT images, prepare 3-D visualisations of the ideal teeth setup and plan where implants should be placed. The navigation functionalities are tightly integrated and provide guidance and visual feedback to ensure the implants are placed according to plan.

We aim to release product updates, upgrades with new and improved features on both the planning and navigation side. Our current roadmap includes the following three priorities: First, additional prosthetic-driven planning features; second, documentation functions which include pre-op planning and post-op outcome; and third, dedicated versions for other specialties, such as orthodontics and endodontics.

Where and how can the dental specialist purchase Navident, already? And which are the new focus markets that you want to provide with this new system?

We are interested in spreading the technology all over the world and we have had interest from all over the world. We are in the process of qualifying potential distributors in different markets for this purpose. If doctors or dealers are interested in Navident, contact our head office in Canada or our European office in Belgium to inquire about importation rules and representation in their area.

Thank you for this interview.



3-D printing: Next generation of dental modelling

Author Georg Isbaner, Germany

With 3-D colour scans and colour prints, dentistry has made some significant advancements in digitalization in recent years. At the 2015 International Dental Show (IDS), manufacturer of 3-D printers and production systems Stratasys presented a new system to the dental industry: Objet260 Dental Selection. With this printer, practitioners are able to create models with lifelike textures for precise evaluation and a wide range of shades for customized shade matching. Georg Isbaner, editorial manager of *implants*, spoke with Avi Cohen, Director of Global Dental at Stratasys, about the company's latest development.



Avi Cohen, Director of Global Dental at Stratasys.

Georg Isbaner: Mr Cohen, what is your company's expertise? What is your product offering to customers?

Avi Cohen: In the dental market, in which I essentially established our products over five years ago, we are by far the leading provider of overall solutions. When we initially began serving this industry, we came up with a printer that prints stone models directly from intra-oral scans. At the 2013 IDS, we released the Objet30 OrthoDesk, a small, low-cost desktop printer. For us, every idea is an opportunity to release a new product. We are very much committed to the dental market and release one or two machines every year.

Could you tell us about the product you presented at this year's IDS?

At the 2015 IDS, we presented the Objet260 Dental Selection 3-D printer, which is a new system that enables printing of a full-colour lifelike model—instead of a regular stone model or a one-colour model—from a colour intra-oral scan. The printer brings advanced triple-jetting technology to dental and orthodontic laboratories, allowing 3-D printing of impressively realistic models with a true-to-life look and feel.

You can, for example, print jaw models directly from CBCT scan data, with high-definition tooth, root and nerve canal anatomy rendered in contrasting materials and colours. Holding the printed model in your hands, you can feel and touch the surface, the smoothness and the resolution. Everything from the CBCT scan data is presented here. So when designing a denture for which implants are to be placed, you know exactly where the nerve is and how to avoid it.

In addition to that, when scanning a patient's mouth, you have the option to do this in colour be-

cause the new standard in scanning is colour, and the standard in printing models from the scans will be colour as well, with the ability to print hundreds different colour shades and properties. With our printer, you can also create models with different levels of smoothness, so that, for example, a model of the gingiva is as soft and of the same colour as it is naturally.

For which stage of treatment does the dentist need such a colour model?

With our device, there are 90 different selection possibilities and 11 options for a printed model, so imagine how many you could print. If, for example, you touch your jaw model at the teeth, it is very hard; if you touch it at the gingiva, it is very soft. Using a mixture of soft and other materials enables us to print the real softness of the gingiva.

Now let us talk about the practical usage. You are doing an implant model and you need to determine the emergence profile of the crown that sits on an implant screw. This requires a gingival mask. Today, this is done manually. Everything is digital, but the gingival mask is still manual. With our technology, you can print the gingiva, select the colour and Shore A value, and test how the crown emerges from the rubber and thus the gingiva. We lend realism with materials, properties, textures. This is the only machine in the market that can do this.

Do you think that 3-D printing is an advantage for dentist-patient communication?

Absolutely. Imagine that when the dentist scans the patient's oral cavity he obtains a full model of what the patient's mouth looks like, every broken tooth and every problem, allowing diagnosis and identification of the treatment required. With this, the dentist can explain how he or she is going to treat the teeth. You see this tooth is broken, that one has moved. The model offers a full understanding of what the patient's mouth looks like and it does not look like a stone model; it looks like the patient's own mouth, in realistic colour. So, it is like the patient looking at himself or herself. With this, the dentist involves the patient in understanding what the dental process will be.

How long does it take from capturing the oral scan to receiving the 3-D model?

We print at a speed of about 1 cm in height per hour. In printing, the size is less relevant than the height. You can print 1 cm of enamel in 1 hour or even 2 cm in the same time. Relatively, this is considered to be very fast.

I presume you can also slow down or speed up the printing process in respect of the quality you want to achieve?

Correct.

This concept is the missing link in high-end dentistry and implantology. Where do you see this going in the future? At the moment, we are still talking about models only.

This is the million-dollar question. We have the ability to print real-life models, dentures, crowns, bridges—everything that you see in the human organs. Now, what is the next step? I am not talking specifically about Stratasys or about dentistry. The next step is that you are going to be able to print any end-user part. It could be anything. This is just to show you what a significant advancement we have achieved. Issues from here onwards are materials, properties, medical approvals, and US Food and Drug Administration approvals. But this shows the direction that the market is going in. It could take one year, two years, five or ten.

The dental industry has existed for many hundreds of years already, and now take a look around: in only a few years, we have developed scanning in colour and printing in colour. What comes next? Use this as an end-product in colour. With our technology, not only can you print in colour, but you can also print every pixel of a tooth in a different colour tint. If, for example, you have a missing tooth, I could make you one with every pixel of it the same as one in your mouth. That is really the future that lies ahead for the industry. The day will come, maybe in three, five or even ten years, when everything that is needed in the dental industry can be printed and put in—it is around the corner.



Fig. 2 The new Objet260 Dental Selection.

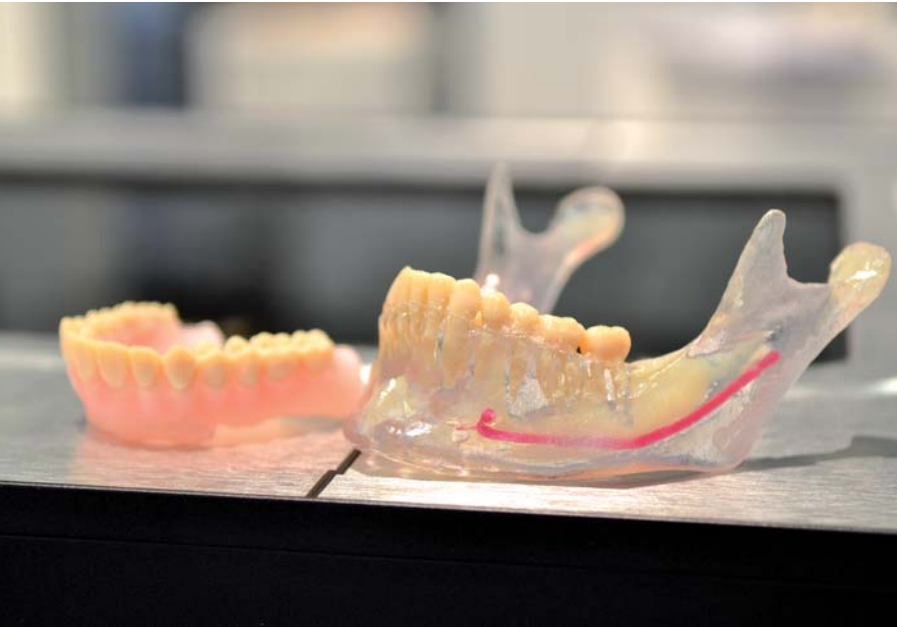

Fig. 3 Printed jaw model with high-definition tooth, root and nerve canal anatomy rendered in contrasting materials and colours.

3-D printing takes the efficiencies of digital design to the production stage. By combining oral scanning, CAD/CAM design and 3-D printing, dental laboratories can accurately and rapidly produce crowns, bridges, stone models and a range of orthodontic appliances. With a 3-D printer doing the hard work, dental laboratories eliminate the bottleneck of manual modelling and help the business grow. For those eager for the day when everything from scheduling to finished restorations can be achieved digitally and automatically, the future is here.

Fig. 4 Avi Cohen in the interview.



And it could probably enhance quality for people who cannot afford or do not have access to this kind of treatment.

Correct! Those are my thoughts exactly. Let us take, for example, the production of a digital denture. A printed full denture would be so cheap. The digital file is saved, so that instead of €500 it would cost €50. Should you lose your denture, you could just call the dentist, go to his or her practice and your new denture would be ready. It would be similar to glasses: today they are so cheap that you can buy glasses for €5 and change them every day. With dentistry, it will be like this one day. Okay, I broke my denture; I want a new one with even brighter teeth. Have it printed in the dental office and come back in an hour and put it in.

Do you think there might even be a kind of tooth fashion? Maybe wearing a different set of teeth for an evening out?

That is a funny idea. For going to a club, you could have a brilliant set of teeth; for Halloween, you could wear vampire teeth—you could select the type of teeth just as you want. That definitely could be possible.

The wear or the abrasion of prostheses is considered to be a difficult matter. At the moment, implant prostheses are made of very strong and hard material. However, Prof. Daniel Edelhoff, for example, promotes the notion that the crown should wear within a period of four or five years and then be replaced, because he considers it to be more natural and more protective regarding the natural dentition. Do you see an advantage in this respect with printed models?

You can definitely control the softness. You can also control that only the top occlusal area will be soft, and you can control how long it will last, two years or ten. This is, of course, in theory in the future. Also, the price is going to be so much affordable, as we said earlier. You could have different types of dentures at home; for example, if you want to eat peanuts tonight, just put in the appropriate unit; if you want to drink soup, put in the soft one. What I like about the Objet260 Dental Selection 3-D printer is that it creates new possibilities. People come up with ideas that I had never thought of. They approach us with suggestions for printing in new directions that our developers had not even thought of. This is not just a machine; it is a dream machine, a tool. From this, you can go in any direction you want to.

So, it brings engineering directly to the people who really need to work with it?

Correct! It brings engineering and innovation, new ideas and maybe some intellectual properties of what this should look like to dentists and laboratories, definitely.

Thank you very much for the conversation.



CROIXTURE

PROFESSIONAL MEDICAL COUTURE



THE NEW 2014-2015 COLLECTION

EXPERIENCE OUR ENTIRE COLLECTION ON WWW.CROIXTURE.COM

1ST ANNUAL MEETING OF

ISMI | INT. SOCIETY OF METAL FREE IMPLANTOLOGY



Ceramic implants – biological and technological fundamentals, latest standards and visions

June 12–13, 2015 in Constance, Germany
hedicke's Terracotta

UP TO
16
CREDIT HOURS AVAILABLE

FRIDAY, JUNE 12, 2015 (CONGRESS LANGUAGE GERMAN)

➤ SYMPOSIUM SWISS DENTAL SOLUTIONS

- 10.00 – 11.00 a.m. **Dr. Karl Ulrich Volz/Constance (DE)**
New products, concepts and protocols at SDS Swiss Dental Solutions
- 11.00 – 11.30 a.m. **Prof. Dr. Marcel Wainwright/Dusseldorf (DE)**
Intralift and ceramic implants – the perfect symbiosis
- 11.30 – 12.00 a.m. **Dr. Josef Vizkelety/Constance (DE)**
Biological and immunological protocols to boost the immune system and avoid antibiotic treatment
- 12.00 – 12.30 p.m. **Dr. Dominik Nischwitz/Tübingen (DE)**
What is Biological dentistry?
- 12.30 – 1.30 p.m. Break/Visit of the Dental Exhibition

➤ LIVE SURGERIES

- 01.30 – 02.30 p.m. **LIVE SURGERY ①**
Surgical procedure for one-piece Straumann Pure Ceramic Implants
Prof. Dr. Dr. Frank Palm/Constance (DE)
- 02.30 – 03.00 p.m. Break/Visit of the Dental Exhibition
- 03.00 – 04.30 p.m. **LIVE SURGERY ②**
The SCC Short Cut Concept: immediate implantation combined with immediate temporary restoration – made possible by special ceramic thread designs and in consideration of biological and immunological principles
Dr. Karl Ulrich Volz/Constance (DE)



8.00 p.m. **EVENING EVENT** Hotel and restaurant VILLA BARLEBEN AM SEE
BBQ, barbecue specialties and good wine in the beautiful garden of the historic Villa Barleben – open end ... Price per person: 120,- € plus VAT
Registration is mandatory (limited attendance). Please indicate on the registration form.

SATURDAY, JUNE 13, 2015 (CONGRESS LANGUAGE GERMAN/ENGLISH)

- 09.00 – 09.20 a.m. Welcome and opening | Ceramic implants: development, current standard and visions
Dr. Karl Ulrich Volz/Constance (DE)
- 09.20 – 09.50 a.m. **Prof. Dr. John Ionescu/Neukirchen (DE)**
Chronical heavy-metal load at skin and environmental diseases. Diagnosis and therapy
- 09.50 – 10.20 a.m. **Prof. Dr. Vera Stejskal/Stockholm (SE)**
Lecture in English
Allergy and autoimmunity caused by dental metals
- 10.20 – 10.50 a.m. **Prof. Dr. Jose Mendonça-Caridad/Santiago di Compostela (ES)**
Lecture in English
Principles of biological surgery: adult stem cells and ceramic implants
- 10.50 – 11.00 a.m. Discussion
- 11.00 – 11.30 a.m. Break/Visit of the Dental Exhibition
- 11.30 – 12.00 a.m. **Dr. Karl Ulrich Volz/Constance (DE)**
The SCC Short Cut Concept: immediate implantation combined with immediate temporary restoration – made possible by special ceramic thread designs and in consideration of biological and immunological principles
- 12.00 – 12.30 p.m. **Dr. Sammy Noubissi/Silver Spring, MD (US)**
Lecture in English
Pre- and post-restorative clinical implant stability assessment of zirconia ceramic implants submitted to two different methods of surface modification. Results of a clinical 2 year retrospective study
- 12.30 – 12.45 p.m. Discussion
- 12.45 – 13.45 p.m. Break/Visit of the Dental Exhibition
- 13.45 – 14.25 p.m. **Dr. Pascal Eppe/Etalle (BE)**
Lecture in English
Electromagnetic fields and dental metals – the infernal couple
- 14.25 – 14.55 p.m. **Prof. Dr. Marcel Wainwright/Dusseldorf (DE)**
Hyaluronic acid and PRGF – modern tools for biological treatment
- 14.55 – 15.25 p.m. **Dr. Ernst Fuchs Schaller/Bäch (CH)**
Lateral augmentation made easy
- 15.25 – 15.30 p.m. Discussion
- 15.30 – 16.00 p.m. Break/Visit of the Dental Exhibition
- 16.00 – 16.30 p.m. **Dr. Ralf Lüttmann/Eckernförde (DE)**
17 years experience with ceramic implants: one-piece, two-piece – what is important for long-term success?
- 16.30 – 17.00 p.m. **Dr. Oliver Zernial/Kiel (DE)**
MARKETING. SCORNED, LIVED, PLANNED? Is the future white?
- 17.00 – 17.30 p.m. **Dr. Bernd Giesenhausen/Kassel (DE)**
Bone-ring technique and ceramic implants
- 17.30 – 17.45 p.m. Discussion

Congress Fees

Friday, June 12, 2015 > Pre-Congress

Symposium SDS (Lectures)	150,- € plus VAT
Live surgery ① (Straumann)	50,- € plus VAT
Live surgery ② (SDS)	50,- € plus VAT
Live surgery 2 (SDS) is free of charge for participants of the symposium SDS	
Conference charge*	49,- € plus VAT

Saturday, June 13, 2015 > Main Congress

Dentists	250,- € plus VAT
Assistants	125,- € plus VAT
Conference charge*	49,- € plus VAT

ISMI members receive 20% discount on the congress fee on Saturday!

* The Conference Charge is to be paid by each participant and includes coffee breaks, conference drinks and lunch.

Evening event (limited attendance)

Friday, June 12, 2015, Hotel and restaurant VILLA BARLEBEN AM SEE BBQ, barbecue specialties and good wine in the beautiful garden of the historic Villa Barleben – open end...

Price per person 120,- € plus VAT

Scientific Director

Dr. Karl Ulrich Volz/Constance (DE)

Venue

hedicke's Terracotta (on the grounds of Klinikum Konstanz)
Luisenstraße 9, 78464 Constance, Germany
Tel.: +49 7531 94234-0
www.terracotta-konstanz.de

Organizer

ISMI – International Society of Metal Free Implantology
Lohnerhofstraße 2, 78467 Constance, Germany
Tel.: 0800 4764-000, Fax: 0800 4764-100
office@ismi.me, www.ismi.me

Organization/Registration

OEMUS MEDIA AG
Holbeinstraße 29, 04229 Leipzig, Germany
Tel.: +49 341 48474-308, Fax: +49 341 48474-290
event@oemus-media.de, www.oemus.com

Online registration

www.ismi-meeting.com

Room booking in various categories

PRIMECON

Tel.: +49 211 49767-20, Fax: +49 211 49767-29
info@prime-con.eu, www.primcon.eu

Terms & Conditions

- The application for the congress is made in written form on the event website or informally. For setup reasons, the application is to be made as early as possible. The congress approvals are made by the order of the date of application.
- Upon receipt of your registration with the OEMUS MEDIA AG the congress application is binding. You will receive a confirmation and invoice. For OEMUS MEDIA AG the liability will only occur with actual date of payment.
- The total amount of invoice is to be transferred to the account stated on the registration or will be debited from your credit card at least two weeks before the congress (receipt at OEMUS MEDIA AG). For payment you have to indicate the name of the participant, the seminar number and invoice number.
- Until six weeks before the congress a written resignation from congress is possible in exceptional cases. In this case, an administrative fee of 25,- € is to be paid. This does not apply if the cancellation is associated with a substitute application.
- In case of cancellation until 14 days before the congress the registration fee and half the conference fee will be refunded. In case of a later cancellation the registration fee and the conference fee will not be refunded. Congress reservation is of course transferable to another person.
- With the registration confirmation you get a map to the hotel and, if necessary, separate information for participation.
- In case of under- or overbooking of the congress, short-term cancellation of the congress, in case of cancellation of a lecture by the speakers or change of the congress host you will be notified as soon as possible. Therefore, please give in your private phone number and your fax number. For losses resulting from the cancellation of the conference OEMUS MEDIA AG is not liable. The invoice amount already paid by you will be refunded immediately.
- Photographs, sound, video and film recordings are not permitted during lectures of the congress, unless the speaker declares his written consent.
- OEMUS MEDIA AG is not liable for the content, implementation and other conditions of the congress.
- With registration the participant accepts the terms and conditions of OEMUS MEDIA.
- The reported fees for students are granted only for students of medicine/dentistry in undergraduate education with verification letter. This is not for master's courses in postgraduate education (eg University Krems).
- Jurisdiction is Leipzig/Germany.



Please fax this registration form to

+49 341 48474-290

or send it via e-mail to

event@oemus-media.de

OEMUS MEDIA AG
Holbeinstraße 29
04229 Leipzig
Germany

I hereby register the following person for the **1st Annual Meeting of ISMI** from June 12–13, 2015 in Constance, Germany: (Please fill out/tick as appropriate)

Symposium SDS
Live surgery ① ② Lectures

Title, First Name, Last Name, Occupation Pre-Congress (Friday) Main Congress (Saturday)

ISMI member yes no

Evening event on Friday, June 12 _____ (Please enter number of persons)

Stamp/Address

I hereby accept the terms and conditions of the **1st Annual Meeting of ISMI**.

Date/Signature

E-mail address



Biggest IDS of all time in Cologne

Growth in the number of visitors, exhibitors and exhibition space

Author_Koelnmesse



After achieving a record result, the 36th International Dental Show (IDS) that was characterised by an excellent atmosphere closed its doors in Cologne after five days. Around 138,500 trade visitors from 151 countries attended the world's leading trade fair of the dental industry, which corresponded to an increase of almost eleven per cent compared to the previous event. IDS also achieved new records in terms of the number of exhibitors and the exhibition space sold.

2,201 companies (+6.9 per cent) from 56 countries presented a wealth of innovations, product developments and services on exhibition space covering 157,000 square meters (+6.2 per cent). With an over 70 per cent share of foreign exhibitors (2013:

68 per cent) and a 17 per cent increase in the number of trade visitors from abroad the level of internationality of the event was once again significantly increased. At the same time, the number of trade visitors from Germany also increased markedly in comparison to 2013 (+4.3 per cent).

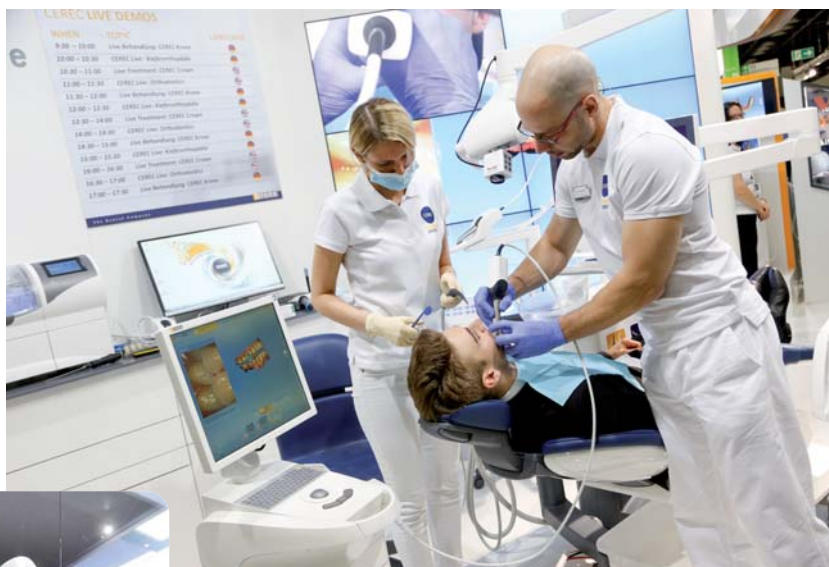"We succeeded in making the International Dental Show in Cologne even more attractive, on both a national and international basis. It is thus the most successful IDS of all time," summed up Dr Martin Rickert, Chairman of the Association of German Dental Manufacturers (VDDI). "The quality of the business contacts between the industry and the trade as well as between the industry, dentists and dental technicians was extremely high. The number of orders placed at IDS rose once again and we are reckoning with sustainable impulses for the post-fair follow-up business," added Katharina C. Hamma, Chief Operating Officer of Koelnmesse GmbH.

Furthermore she said: "In addition to the growth in the number of German trade visitors, the high international response once again underlines the character of IDS as the world's leading trade fair of the dental industry. The International Dental Show particularly recorded strong growth in the number of visitors from the Near and Middle East, the United States and Canada, Brazil as well as from China, Japan and Korea. The business in the South East European market, especially Italy and Spain, has also increased noticeably."

_Strong interest in innovations

The trade and the users were extremely interested in innovative products and technologies. "In this respect, staged every two years, IDS fits in perfectly with the innovation cycles of the industry regarding the development and further development of products, materials and services," emphasised Dr Markus Heibach, Executive Director of VDDI. "This applies for both breakthrough innovations and further developments of existing products, but also for development progress in smaller phases that are however significant in terms of quality."

IDS 2015 focused on the intelligent networking of components for computer-controlled dentistry. Today, the world of digital systems in diagnostics and production encompasses the entire workflow from




the practise through to the laboratory. The computer-controlled process chains are in the meantime complete and are putting their enormous flexibility to use.

_Fantastic outcome of the trade fair and excellent mood

The hustle and bustle in the halls made the high attendance at IDS very apparent. By all accounts, representatives from all relevant professional groups—from dentists' surgeries, dental laboratories, from the dental trade, but also from the higher education sector—from all over the world had visited the exhibition stands. The exhibitors were especially pleased about the high level of internationality of the trade visitors. In terms of business, IDS was very successful for many companies, because orders were placed—by both national and international customers.

Numerous companies were pleased to announce full order books. Aspects such as grooming contacts, customer bonding, winning over new customers or penetrating new foreign markets were at least equally important for the exhibitors. These goals were also achieved to complete satisfaction at the 36th International Dental Show. The exhibitors evaluated the quality of the visitors very positively. This finding is confirmed by the initial results of an independent visitor survey: 83 per cent of all of the visitors are involved in purchasing decisions at their company.

"The world meets up at IDS in Cologne," summed up Sebastian Voss, managing partner of Hager &



Meisinger GmbH. "More international customer contacts visited our stand this year than in 2013. Visitors from Latin America were particularly well represented, but also from Asia." "We were able to establish countless new contacts at IDS and also met up with our existing customers." Martin Dürrstein, Chairman of Dürr Dental AG, was also extremely satisfied: "The trade fair went very well for us, it was fantastic. We received a high number of particularly qualified trade visitors. We are totally satisfied with the fair, because we were able to welcome many new customers from Asia, Arabia, Latin America and South Africa."

Christian Scheu, Executive Director of Scheu-Dental GmbH also praised the further increased internationality of IDS: "In comparison to 2013, we were able to further increase the number of visitors at our stand, in particular visitors from abroad. The Asiatic region, for instance China and Korea, were

especially well represented, but we also registered an increase in the number of customers from Southern Europe." As well as the high frequency of visitors at his stand, Axel Klarmeyer, Executive Director of BEGO, also reported, "that the customers were well informed and that they showed great interest in new technologies."

Walter Petersohn, Vice President Sales of Sirona Dental Systems, was also pleased "about the vast numbers of international visitors, the buying interest and as always about the large number of attending German dentists and dental technicians." Michael Tuber, Executive Director of A. Titan also awarded IDS 2015 top marks. "This is the seventh time we have exhibited at IDS and we have optimally achieved the goal we set ourselves, namely further expanding our international sales network. The trade fair offers us the perfect platform for meeting up with our existing customers from all over the world, but at the same time, we were able to establish many new customer contacts. This is why the International Dental Show is an absolute must for every American manufacturer from the dental industry."

IDS 2015 was also a success for Andrew Parker, CEO of Mydent International: "We met up with our international customers here in Cologne and were additionally able to make over 100 interesting new contacts to dental dealers. No other event in the world has such international appeal."

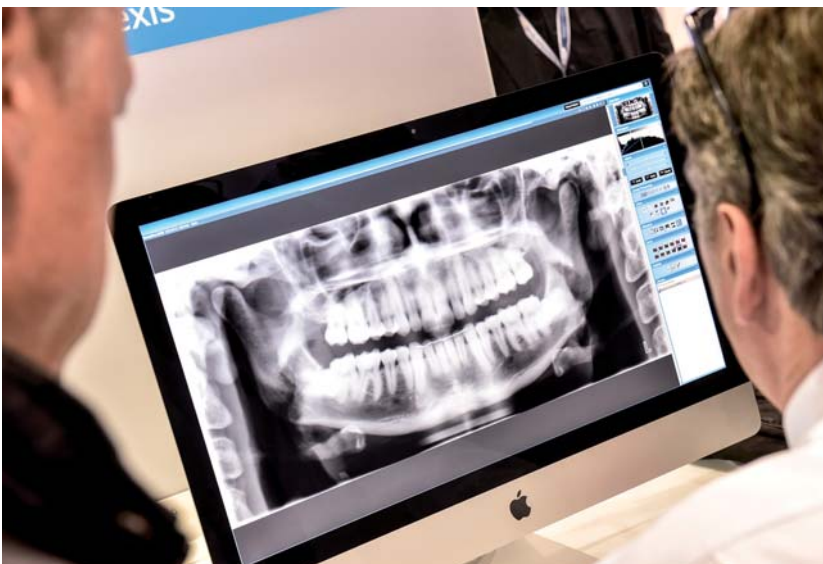Satisfied visitors all round

The visitor survey revealed that over 75 per cent of the respondents were (very) satisfied with IDS. The fair's comprehensive spectrum of products and new products ensured that 81 per cent of visitors rated the product range as being (very) good. 74 per cent of the exhibitors were (very) satisfied in terms of reaching the goals they had set themselves for the fair. Overall, 95 per cent of the visitors questioned would recommend visiting IDS to business partners and 77 per cent also intend to visit IDS 2017.

The International Dental Show (IDS) takes place in Cologne every two years and is organised by the GFDI Gesellschaft zur Förderung der Dental-Industrie mbH, the commercial enterprise of the Association of German Dental Manufacturers (VDDI) and is staged by Koelnmesse GmbH, Cologne.

The next IDS—the 37th International Dental Show—is scheduled to take place from 21 to 25 March 2017.

www.ids-cologne.de



PRINT
DIGITAL
EDUCATION
EVENTS

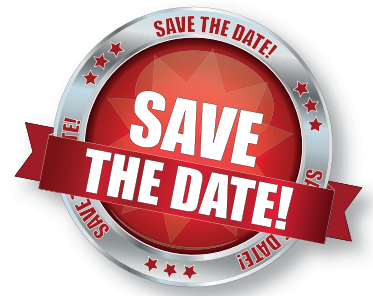ESSENTIAL DENTAL MEDIA

www.dental-tribune.com



The DTI publishing group is composed of the world's leading dental trade publishers that reach more than 650,000 dentists in more than 90 countries.

dti Dental
Tribune
International



6th International CAMLOG Congress



From 9 to 11 June 2016, the 6th International CAMLOG Congress organised by the CAMLOG Foundation takes place in the beautiful city of Krakow, Poland. The congress will be held under the motto "Tackling everyday challenges" and will incorporate practical aspects coupled with science for immediate implementation into the workplace.

The scientific committee chaired by Prof. Frank Schwarz, Germany, and Prof. Piotr Majewski, Poland, as Co-presidents is composed of well-known experts who combine scientific knowledge with practical background.

mechanics standards. Already now, the ICE is ranked among the most prestigious and exclusive congress centres in Europe.

Krakow—a UNESCO world heritage site

Krakow, famous for its priceless historical monuments of culture and art, is Poland's former royal capital and one of the most attractive spots on the tourist map of Europe. The 13th-century merchants' town has Europe's largest market square and numerous historical houses, palaces and churches with magnificent interiors. Besides history, art and an atmosphere all of its own, Krakow offers visitors plentiful entertainment and leisure possibilities. Krakow is the second largest city in Poland. It has traditionally been one of the leading centres of Polish academic, cultural, and artistic life and is one of Poland's most important economic hubs.

CAMLOG is looking forward to welcoming you to the 6th International CAMLOG Congress in Poland.

The scientific committee

Dr Krzysztof Awillo (PL)
Prof. Dr Fernando Guerra (PT)
Prof. Dr Piotr Majewski (PL)
Prof. Dr Katja Nelson (DE)
Prof. Dr Irena Sailer (CH)
Dr Alex Schär (CH)
Prof. Dr Thomas Taylor (US)
Prof. Dr Fumihiko Watanabe (JP)

Prof. Dr Jürgen Becker (DE)
Prof. Dr Gerald Krennmair (AT)
Dr Ralf Masur (DE)
Dr Giano Ricci (IT)
Prof. Dr Mariano Sanz (ES)
Prof. Dr Frank Schwarz (DE)
Dr Pascal Valentini (FR)

ICE—the Krakow Congress Centre

Built in 2014, the ICE (Int. Conferences and Entertainment) brand-new state-of-the-art congress centre provides the perfect setting for the 6th International CAMLOG Congress and offers much more than an average conference venue. This modern world class building, meets all the requirements of upscale architecture as well as the highest acoustic and stage

contact

CAMLOG Foundation
Margarethenstr. 38
4053 Basel, Switzerland
Tel.: +41 61 565 41 00
Fax: +41 61 565 41 01
info@camlogfoundation.org
www.camlogfoundation.org

Membership Application Form

IM 2/15

I hereby to apply for membership of the DGZI – German Association of Dental Implantology (Deutschen Gesellschaft für Zahnärztliche Implantologie e.V.).
Please send this form via FAX to +49 211 16970-66.

Do you have experience in implantology? (mandatory)

Yes No

I hereby agree to have my personal data processed for all purposes of the DGZI.

Full membership (outside Germany) Assistant doctors (outside Germany) Students/auxiliaries (outside Germany)
⇒ 125 Euro p.a. ⇒ 60 Euro p.a. ⇒ 60 Euro p.a.

I have transferred the annual fee to the DGZI bank account c/o Dr Rolf Vollmer:
IBAN: DE33 5735 1030 0050 0304 36 | KSK Altenkirchen | SWIFT/BIC: MALADE51AKI

Personal Data

Name	First name	Date of birth
Title	Citizenship	
Street	City, ZIP code	Country
Phone, Country and Area code	Fax	
E-Mail	Homepage	
Special qualification	Spoken languages	

Payment (by credit card)

Please use your: (Please mark as appropriate)

Visa MasterCard

Card holder's name	Card number
Expiry date	
Signature	Place, Date

Please complete this application form in block letters.

FOR FURTHER INFORMATION PLEASE CONTACT



Deutsche Gesellschaft für Zahnärztliche Implantologie e.V.
Central Office: Paulusstraße 1, 40237 Düsseldorf, Germany
Phone: +49 211 16970-77 | FAX: +49 211 16970-66 | office@dgzi-info.de | www.dgzi.de



“We are planning to be the best and biggest EuroPerio to date”

PICTURE: ©007



_The event's programme

This is a carefully conceived programme offering cutting edge updates in such areas as reconstructive surgery, periodontal regeneration, bioengineering and the vital links between periodontal disease and conditions such as diabetes and cardiovascular disease. It is balanced by many presentations on basic information for clinicians, hygienists and members of the wider medical community. Indeed, GPs are targeted in a special section on 'Practical Periodontics'. Prevention, patient management, aetiology and oral microbiology are covered. Emphasis is also placed on patient perspectives—a key area for periodontology as technology increases patient comfort and practitioners embrace multidisciplinary approaches. Also covered is peri-implantitis and presentations focusing on the aetio-pathogenesis and therapies of this major downside of implant therapy are expected to draw huge audiences.

_Compulsary for followers of oral care

EuroPerio8 Scientific Chairman Prof. Mariano Sanz is calling on all followers of oral care, even those outside dentistry, to attend the event: "I think that anybody interested in oral science and the evolution of dental therapy should come to London for EuroPerio8. This is a three-day conference which takes place only every three years and it will cover everything we now know in 2015 from the most basic concepts to the most recently mastered sophisticated surgical procedures and reconstructive techniques."

"We will cover the whole scope of perio, from the simple ways to treat periodontal disease for the general practitioner, how the whole oral team should interact in treating and managing periodontal patients and, very importantly, how periodontal diseases can affect

The science at the heart of periodontology and dental therapy will be the focus for thousands of delegates travelling to London's ExCeL Centre this June 3–6, 2015, for the 8th EuroPerio8 congress, held every three years. Over 100 of the world's leading international researchers, clinicians and oral health specialists have been commissioned by the organisers of this global periodontology conference to deliver an impressive programme aimed at imparting the current knowledge in the fields of periodontology and implant dentistry.

our body and what reactions exist with other systemic diseases," continued Sanz.

Three main sections

The EuroPerio8 programme is divided into three main sections, of which periodontology is central, featuring:

- Critical factors in periodontal regeneration.
- Understanding periodontitis: current base knowledge.
- Periodontal specialist forum and keynote lectures.

The implant dentistry section will be rich in presentations. It features seven in-depth sessions covering the mastery of techniques and outcome improvement under three main headings:

- Master clinician forum implants.
- Critical factors in aesthetic outcomes for implant placement, and
- Critical factors in bone regenerative therapies in the anterior.

Throughout the congress, the latest scientific breakthroughs will be presented at the Research and Clinical Innovation sessions.

Highlights on Saturday

Some of the highlights of EuroPerio8 are reserved for the final day, Saturday 6 June, with three outstanding keynote lectures to be given by Prof. Jan Lindhe, Niklaus Lang and Paul Sharp. Complementing the programme's state-of-the-art coverage in science, the Final Session: 25 Years of Periodontology will bring EuroPerio8 to a close with a European slant on the crucial developments in the field since the late 20th century, the current position in research and teaching and a look forward into what the future of perio might hold. This session will provide EuroPerio8 with its most complete overview of the evolution of European periodontology.

There will also be an immense exhibition space where participants will be able to study all the latest products and technologies. Furthermore the industry presence will be complemented with a busy schedule of sponsored workshops offering the latest research and development behind the innovations and technologies on show. The Chairman of EuroPerio8, Francis Hughes, said: "It is an honour and delight to be able to bring this meeting to London, to be hosted by the British Society of Periodontology for the European Federation of Periodontology. Taking into account the feedback from Vienna and previous EuroPerio conferences we are planning for EuroPerio8 to be the best and biggest EuroPerio to date." —

www.efp.org





Fig. 1

Pioneer of implantology celebrates 90th birthday

Author_Jürgen Isbaner

On 16 February, Prof. Dr Hans L. Grafelmann, a pioneer of implantology and the founding president of the German Association of Dental Implantology (DGZI), celebrated his 90th birthday.

Traditionally, round-number anniversaries such as this one are used to list all achievements in chronological order and honour them accordingly—which will be done as it deserves below. In congratulating him, I would like to take a more personal look back at the accomplishments of a man whom I have known from my work as an editor and organiser of numerous implantology congresses for 22 years.

In 1994, when OEMUS MEDIA first organized an implantology congress—the first IEC Implantologie-Einsteiger-Congress (which this year is being held under the name IMPLANTOLOGIE START UP in Düsseldorf for the 22nd time)—implantology in Germany was still at its beginning. Although, in 1970 already, some enthusiasts around the then 45-year-old dentist from Bremen established the DGZI, which was the first European organisation for dental implantology.

Today, in Germany alone, there are three professional associations for dentists working in implant dentistry, in addition to the DGZI, with several thousand members. From a handful of implant systems worldwide, an overwhelmingly large implantology market

Figs. 1 & 2_Prof. Dr Dr Grafelmann now and then.



Fig. 2



Fig. 3



Fig. 4



Fig. 5



Fig. 6



Fig. 7

has sprung up with about one million implants placed per year in Germany alone. This area of dentistry, which was once greatly mistrusted, has not only found its way into the mainstream, but also evolved into a central interface of modern dentistry in the course of digitalisation.

Since success has many fathers, the next generations of implantologists, especially in implantology societies, have at times been very depreciatory about those practitioners who paved the way for implantology in Germany—with a great deal of personal commitment, securing private funding for their study visits to the US, and against considerable resistance from universities. They recognized opportunities and utilized them to build up their own successful business. However, from the very beginning, they also strove to establish a sound scientific basis for their empirical experiences.

In 1970, Grafelmann, in collaboration with New York pioneer of implantology Prof. Leonard I. Linkow, as well as 85 interested colleagues, organized the first implantology congress at the Park Hotel Bremen, which resulted in the establishment of the DGZI as mentioned. Subsequently, the Bremen Implantology Seminars, which offered the first ongoing further education opportunity in the area of implantology, were held.

From 1970 onwards, the DGZI published its own scientific publication, called *Orale Implantologie*, which contained case reports and studies—it was the forerunner of today's *Implantologie Journal*. At that time, the first statistical data published by the DGZI showed that more than 3,341 blade implants inserted in a period of five years (1970–1975) had yielded a success rate of 92.9 per cent. According to Grafelmann, the failures were mainly due to mistakes in the indication for the atrophic jaw, insertion techniques, as well as an inappropriate

prosthetic restoration. Blade implants have long since made way for highly modern implants. In the *Implantologie Journal*, former DGZI President Prof. Gyula Takacs once, regarding implantology pioneer Prof. Ernst Bauer and his Bauer screw, likened implants in the hands of Grafelmann and his colleagues to bumblebees: according to the laws of physics, bumblebees cannot fly; in the hands of Bauer, implants work.

After his term as President of the DGZI and after retiring as a practising implantologist, Grafelmann supported the work of the DGZI by means of his foundation, the Prof. Dr Grafelmann Stiftung, among others. Several years ago, for example, he made a donation towards the promotion of research, further development and education activities to the association at its 42nd annual congress in Hamburg. To this, he linked the hope of improving peoples' quality of life, also in old age, thereby following the goal of the DGZI.

I have experienced Grafelmann, along with his wife Barbara—who managed Oraltronic (now Sybron Implant Solutions), the company founded by Grafelmann, for many years—as a charming and humorous contemporary. I remember when we placed his lectures in the final programme slot because of his never-ending talks at our beginners' congresses. I have experienced and reported for the *Implantologie Journal* the honest appreciation and professional attention he received from his colleagues at a congress in Shanghai in China (1997) and at world congresses held by the International Congress of Oral Implantologists.

Prof. Dr Dr Grafelmann not only shaped former generations of implantologists, but also supported us as a young publishing house in our publishing activities from the very beginning. There remains but one thing to say: many thanks!_

Fig. 3 Jürgen Isbaner, Prof. Dr Dr Hans L. Grafelmann and his wife Barbara (former manager of Oraltronic).

Fig. 4 Dr Andreas Lindemann (practice successor of Prof. Dr Dr Grafelmann), Heike Isbaner (former sales force Oraltronic) and Claudia Lindemann (OT medical).

Fig. 5 Prof. Dr Dr Hans L. Grafelmann at his birthday speech.

Fig. 6 The couple Prof. Dr Dr Hans L. Grafelmann with Shiho Miyake, daughter of a Japanese colleague Dr Yasumasa Miyake, and her partner.

Fig. 7 DGZI past president Prof. Dr Dr Hans L. Grafelmann and Dr Friedhelm Heinemann at the 40th annual DGZI congress 2010 in Berlin.

Straumann increases

Ownership of Neodent to 100 per cent

Straumann has signed an agreement to increase its ownership of Neodent, Latin America's leading dental implant company, from 49% to 100% in 2015, three years earlier than foreseen in a previous option agreement. The purchase price for the outstanding 51% is BRL 680 million (approximately CHF 210 million) paid in cash to the company's founding shareholders, Drs Clemilda de Paula Thomé and Geninho Thomé. The acquisition extends Straumann's overall leadership in implant dentistry and makes the Group a substantial contender in the global value segment.

Neodent specialises primarily in the design, development, and manufacture of dental implants and related prosthetic components. Under the entrepreneurial leadership of its founders, the company has expanded rapidly over the past 22 years and has a leading share of the world's second largest market for implant dentistry, Brazil. This success has been achieved through a philosophy of making tested implant solutions more affordable to a broader population.



In 2014, the company achieved revenues of BRL 258 million, generated predominantly in its domestic market, where revenue grew 8%. Neodent is highly profitable and the acquisition will be accretive to Straumann's reported EBIT margin from 2016.

Straumann acquired 49% of Neodent in 2012 for BRL 549 million (CHF 260 million), with an option to increase to 75% in 2015 and up to 100% by 2018. This option has been renegotiated to enable a full acquisition in 2015.

Opposing pricing trends to influence

Asia Pacific dental implant market

The various countries in the Asia Pacific region are all expected to demonstrate an increasing demand for dental implant treatments as a result of growing consumer awareness, the ageing population, growing accessibility (such as through the National Health Insurance Service coverage in South Korea), as well as greater product availability and other influencing factors. Traditionally, premium

implant companies have dominated the dental implant market globally. However, in recent years, discounted implants have become increasingly popular, especially in the Asia Pacific region.

The growing acceptance of discount implants has been driven by Korean companies. The regional market leader, OSSTEM IMPLANT, held a 21.9% share of the total dental implant market for the Asia Pacific region in 2014. The company has invested significantly in marketing efforts, which has led to the growing popularity of its products. Throughout the forecast period, OSSTEM IMPLANT and other discount implant companies, such as MegaGen, Dentium and Neobiotech, are expected to capitalise on the growing popularity of discount implants. In contrast, premium implant companies, such as Straumann and Nobel Biocare, are expected to face increasing competitive pressures, especially in China and Australia.

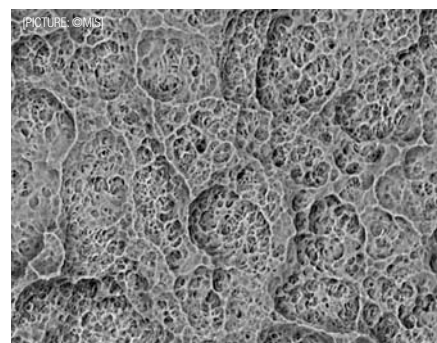


[PICTURE: ©MMAXER]

MIS outclasses competitors in

New implant surface quality study

SEM examined and qualitatively/quantitatively analysed 65 implant systems in a new intermediate report titled "Surface analysis of sterile-packaged implants" by Dr Dirk Duddeck and Dr Jorg Neugebauer, PhD, in cooperation with the European Association of Dental implantologists BDIZ-EDI. The report, which was conducted at the University of Cologne in Germany, ranked MIS as one of the top competitors in a list of implant providers. As a continuance to previous works, the aim of the study was to verify improvements of manufacturing and quality management as well as to demonstrate the high quality level of the participating manufacturers and implant companies.



"MIS goes to great lengths to ensure the surface purity of our implants", says Dr Tal Reiner PhD, MIS Materials Discipline Manager, "and this is the second such independent study published within the past 12 months that verifies our claims."

"I'm very pleased with the results of this study; however it doesn't really surprise us," she confides. "Maintaining the highest standards in both implant surface topography and chemical composition are of vital importance at MIS. Our aim is to consistently produce implants with an ideal surface roughness; micro and nanoporosity, using advanced sand-blasting and acid-etching techniques, and to attain a near flawless surface purity."

Putting things into perspective, Dr Reiner concludes, "The reason for investing all this time and effort isn't just to look good in research studies. It's to supply our customers, implantology professionals around the world, with the highest quality implants in the market — implants that are exceptionally biocompatible and encourage quick reliable integration into bone, for long-term predictable results."

Successful IDS for the

German Association of Dental Implantology

At this year's IDS, the German Association of Dental Implantology (Deutsche Gesellschaft für Zahnärztliche Implantologie DGZI e.V.) presented themselves at the booth of the company Schütz Dental. During the six-day event in Cologne, the DGZI could make numerous new contacts and consultations with dentists and dental technicians interested in further education. Dr Rolf Vollmer, 1st Vice-President: "We are very satisfied with our contacts made. The different curricula—especially those with E-learning possibilities—are of great interest to young dentists who are enthusiastic about implantology."

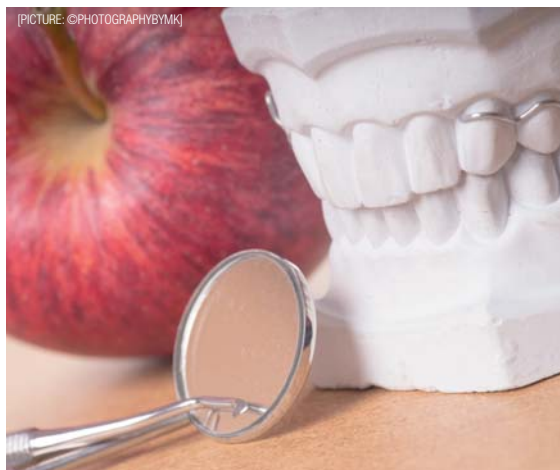

Since the introduction of the new curriculum implantology the association has already registered a rising number of participants. "The courses are very well attended since some months. We assume that we have to extend our further education capacities after the IDS", Prof. (CAI) Dr Roland Hille, 2nd Vice-President, said. In their conversations with trade visitors, the DGZI board simultaneously discussed the

collaboration of implantology and dental labs. "With our curriculum Implant Prosthetics and our annual congress on 2nd and 3rd October we want to discuss and promote the collaboration between dentistry and dental technology", Prof. Dr Hille said. The topic of the DGZI's congress in this year is: Dental technology and implantology—interface to reach success.

German dental health care system is

Outstanding in European comparison



The Institute of German Dentists has conducted a study to compare different European health care systems based on selected dental treatment scenarios. The health economics study, called EURO-Z-II, found that—compared with six other European countries—the German health care system delivers top dental care and responds well to crises.

The researchers compared several national health care systems, among them the classic Bismarckian social security system in Germany, France and the Netherlands; the tax-funded Beveridge system in Denmark and the UK; the young social security system in Hungary based on the Semashko model; and the mixed system in Switzerland. "The outstanding oral health of the German population, which has been established in various studies, has now been put into the context of the health care system. From this, it is apparent that the majority of the population is statutorily insured (86 per cent) with 11 per cent of the population privately insured. This creates a system that is well equipped to manage crises and has an innovative and investment-friendly foundation, thereby assuring secure and modern dental care for the general public," stated Dr Peter Engel, President of the German Dental Association.

DENTSPLY Implants

Invites to attend DIKON in Berlin

The 3rd DENTSPLY Implants Congress (DIKON) will take place on 18th to 19th September 2015 in Berlin. According to the motto "Make good decisions—inspire patients" the two-day event provides exciting scientific discourses and practice-oriented workshops. The exceptional design hotel andel's serves as the conferences' venue.



Dr Karsten Wagner, Managing Director at DENTSPLY Implants Germany, is looking forward to the vibrant city of Berlin as well as the 3rd DIKON:



"It really impresses me at what rate implant therapy is currently developing. With 45 renowned experts DIKON offers the perfect platform to stay up to date. In the field of implantology continuous education is truly imperative." DIKON is in line with BZÄK guidelines and recommendations. Participating in the whole event is rewarded with 8 medical education credit points. For registrations before the 30th June 2015, DENTSPLY Implants offers an early bird special: Standard tickets cost 129 instead of 199 EUR and reduced tickets 75 instead of 100 EUR. Students pay 35 instead of 50 EUR.

Please find additional information as well as the agenda and the registration form here: www.dentsplyimplants.de/Fortbildung/DIKON.

implants
international magazine of oral implantology



Publisher

Torsten R. Oemus
oemus@oemus-media.de

CEO

Ingolf Döbbecke
doebbecke@oemus-media.de

Members of the Board

Jürgen Isbaner
isbaner@oemus-media.de

Lutz V. Hiller
hiller@oemus-media.de

Chief Editorial Manager

Dr Torsten Hartmann (V. i. S. d. P.)
hartmann@dentalnet.de

Editorial Council

Dr Ralf Vollmer
info.vollmer@t-online.de

Prof. Dr Kurt Vinzenz
kurt.vinzenz@aon.at

Dr Torsten Hartmann
hartmann@dentalnet.de

Dr Suheil Boutros
SMBoutros@aol.com

Editorial Office

Georg Isbaner
g.isbaner@oemus-media.de

Katrin Maiterth
k.maiterth@oemus-media.de

Claudia Jahn
c.jahn@oemus-media.de

Executive Producer

Gernot Meyer
meyer@oemus-media.de

Designer

Sarah Fuhrmann
s.fuhrmann@oemus-media.de

Customer Service

Marius Mezger
m.mezger@oemus-media.de

Published by

OEMUS MEDIA AG
Holbeinstraße 29
04229 Leipzig, Germany
Tel.: +49 341 48474-0
Fax: +49 341 48474-290
kontakt@oemus-media.de

Printed by

Silber Druck oHG
Am Waldstrauch 1
34266 Niestetal, Germany

implants

international magazine of oral implantology
is published in cooperation with the German
Association of Dental Implantology (DGZI).

DGZI

Prof. Dr Herbert Deppe
DGZI Central Office
Paulusstraße 1, 40237 Düsseldorf, Germany
Tel.: +49 211 16970-77
Fax: +49 211 16970-66
office@dgzi-info.de

www.dgzi.de
www.oemus.com
www.implants.de

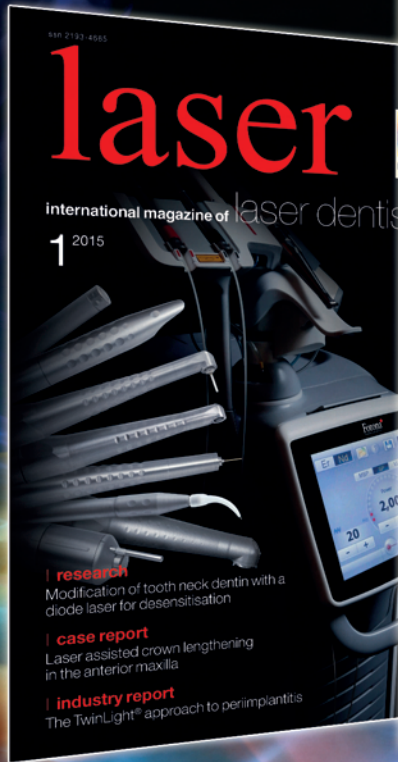Copyright Regulations

implants international magazine of oral implantology is published by OEMUS MEDIA AG and will appear in 2015 with one issue every quarter. The magazine and all articles and illustrations therein are protected by copyright. Any utilization without the prior consent of editor and publisher is inadmissible and liable to prosecution. This applies in particular to duplicate copies, translations, microfilms, and storage and processing in electronic systems.

Reproductions, including extracts, may only be made with the permission of the publisher. Given no statement to the contrary, any submissions to the editorial department are understood to be in agreement with a full or partial publishing of said submission. The editorial department reserves the right to check all submitted articles for formal errors and factual authority, and to make amendments if necessary. No responsibility shall be taken for unsolicited books and manuscripts. Articles bearing symbols other than that of the editorial department, or which are distinguished by the name of the author, represent the opinion of the afore-mentioned, and do not have to comply with the views of OEMUS MEDIA AG. Responsibility for such articles shall be borne by the author. Responsibility for advertisements and other specially labeled items shall not be borne by the editorial department. Likewise, no responsibility shall be assumed for information published about associations, companies and commercial markets. All cases of consequential liability arising from inaccurate or faulty representation are excluded. General terms and conditions apply, legal venue is Leipzig, Germany.

implants

international magazine of oral implantology



Subscribe now!

I would like to subscribe to **implants international magazine of oral implantology** (4 issues per year) for €44 including shipping and VAT for German customers, €46 including shipping and VAT for customers outside Germany, unless a written cancellation is sent within 14 days of the receipt of the trial subscription. The subscription will be renewed automatically every year until a written cancellation is sent to OEMUS MEDIA AG, Holbeinstr. 29, 04229 Leipzig, Germany, six weeks prior to the renewal date.

▶ Reply via Fax +49 341 48474-290 to OEMUS MEDIA AG or per E-mail to grasse@oemus-media.de

You can also subscribe via www.oemus.com/abo

Last Name, First Name

Company

Street

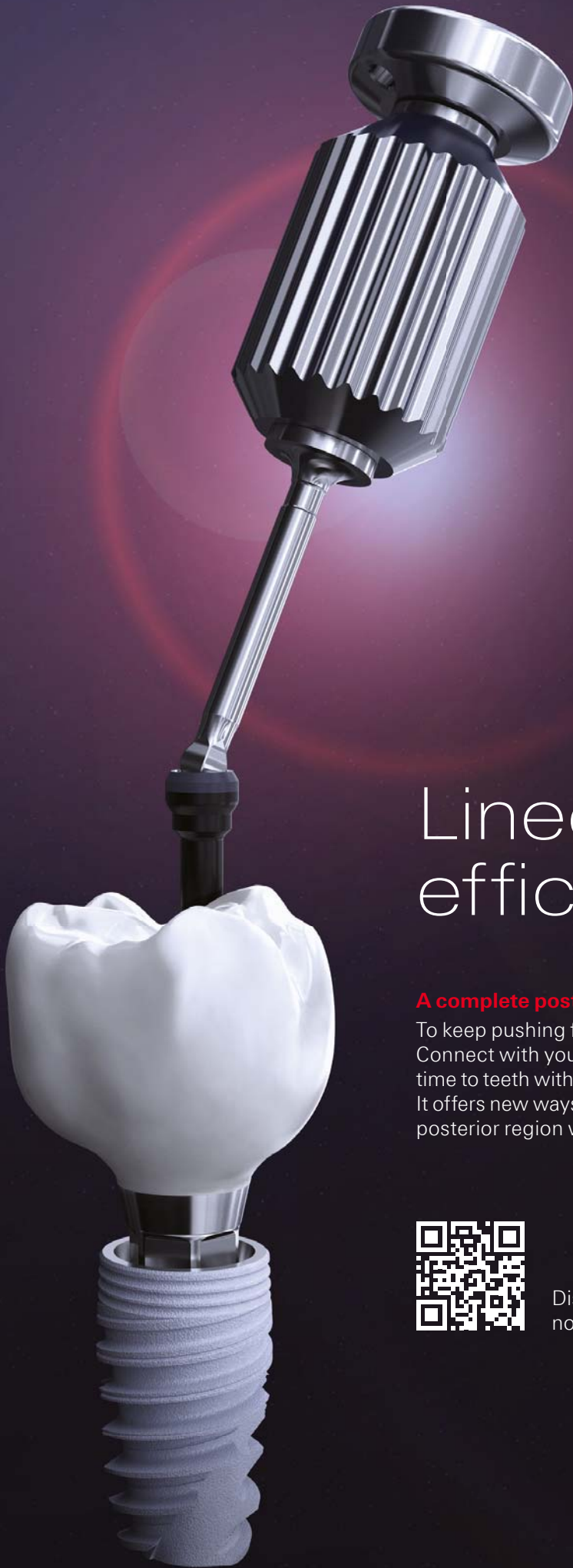ZIP/City/County

E-mail

Signature

Notice of revocation: I am able to revoke the subscription within 14 days after my order by sending a written cancellation to OEMUS MEDIA AG, Holbeinstr. 29, 04229 Leipzig, Germany.

Signature



Lined up for efficiency

A complete posterior solution

To keep pushing forward, we're bringing innovation to the back. Connect with your entire treatment team and achieve shorter time to teeth with Nobel Biocare's complete posterior solution. It offers new ways to overcome the challenges of working in the posterior region while reducing complexity and risks.



Discover the complete posterior solution:
nobelbiocare.com/bringinginnovationback

