

Abutment fracture in a bridge supported by natural teeth and implants

Authors Dr Gregory-George Zafiropoulos, Dr Giorgio Deli & Dr Rainer Valentin, Germany/Italy

Introduction

Implant treatment has evolved into a reliable modality for the replacement of missing teeth. Although rare, complications may occur, and some uncertainty surrounds the treatment of some of these events, especially when restorations are supported by a combination of natural teeth and implants.¹ Often the fabrication of an entirely new restoration is necessary if one or several of the natural teeth need to be removed. Here, we report two cases in which a natural tooth abutment of a restoration supported by implants and natural teeth fractured. We describe the

technique used to replace the fractured tooth with an implant, which allowed the re-use of the existing restoration.

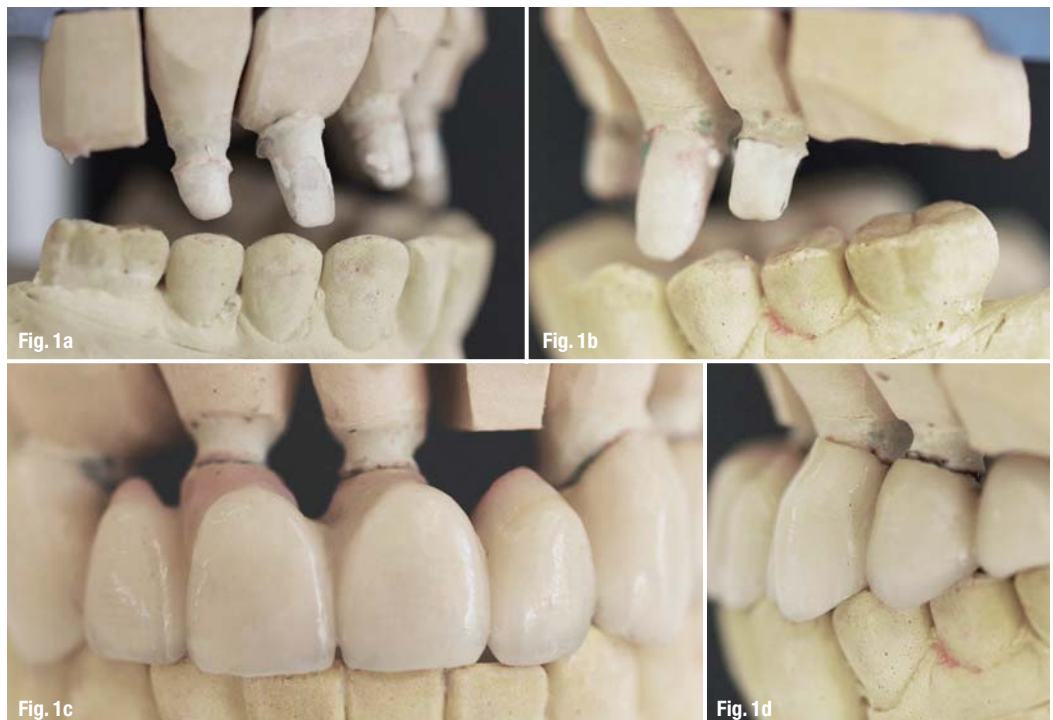
Cases

Case 1

The patient was a 62-year-old male non-smoker in good general health, who was taking no medication and had received implant treatment at the author's office six years before developing the complications described in this article. The mandible was restored with fixed crowns and implant retained bridges. The maxilla

Figs. 1a–d Casts placed in the articulator;

- a) right side, restoration not in place;
- b) left side, restoration not in place;
- c) anterior view, restoration in place;
- d) left side with restoration in place.



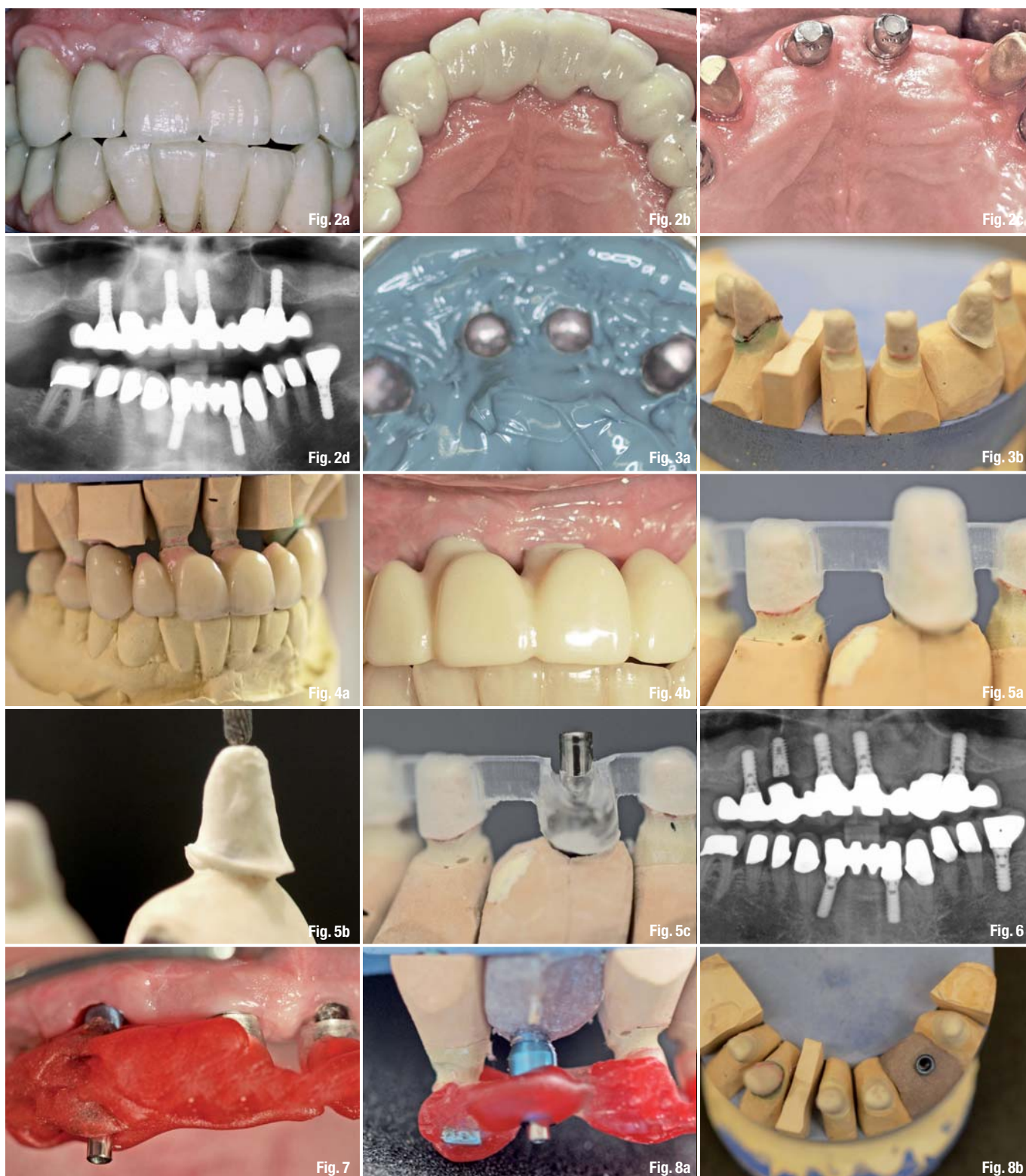


Fig. 2 Restoration after initial treatment, before the accident; a) anterior view; b) intraoral view; c) implants with abutments and teeth #13 and #23 with gold copings in place; d) panoramic radiograph.

Figs. 3a & b a) Impression with the maxillary restoration; b) fabricated cast.

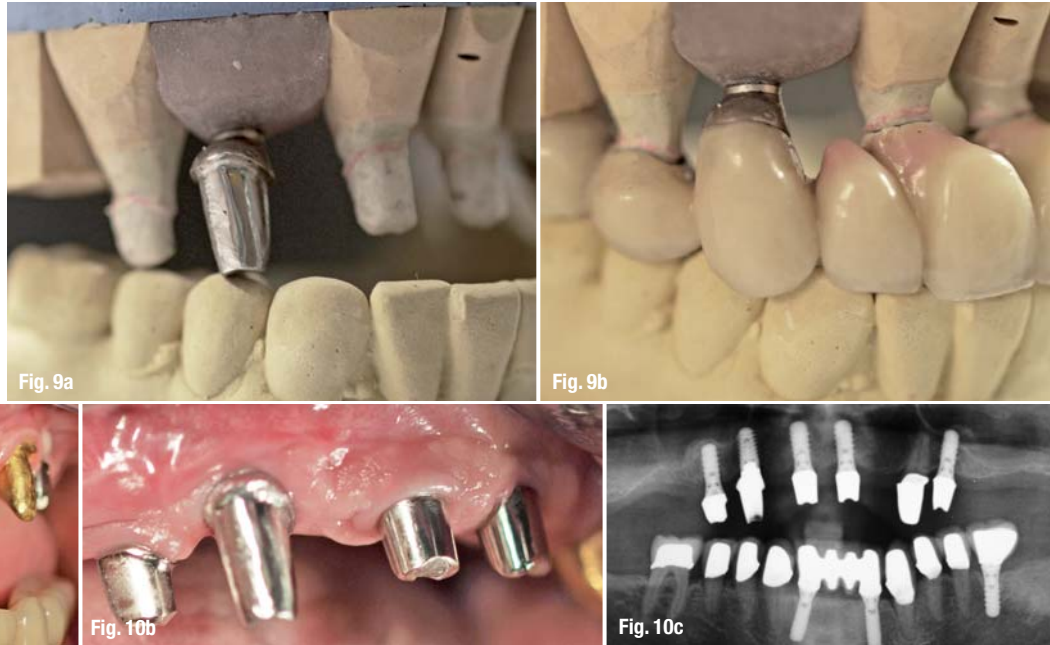
Figs. 4a & b a) Cast articulated using the maxilla restoration as a guide; b) provisional FPD in place.

Figs. 5a-c a) Surgical stent; b) determination of the axial direction; c) drill sleeve was placed into the surgical stent.

Fig. 6 Panoramic radiograph obtained after implant insertion at position #6.

Fig. 7 Impression post in the surgical guide.

Figs. 8a & b a) Transfer of the implant position to mounted cast; b) implant analog in cast.



Figs. 9a & b a) Fabricated customised abutment; b) try-in of the abutment in the restoration.

Figs. 10a–c a) Abutment mounted on the implant; b) try-in of the abutment in the restoration; c) panoramic radiograph of custom-made abutment #13 in place.

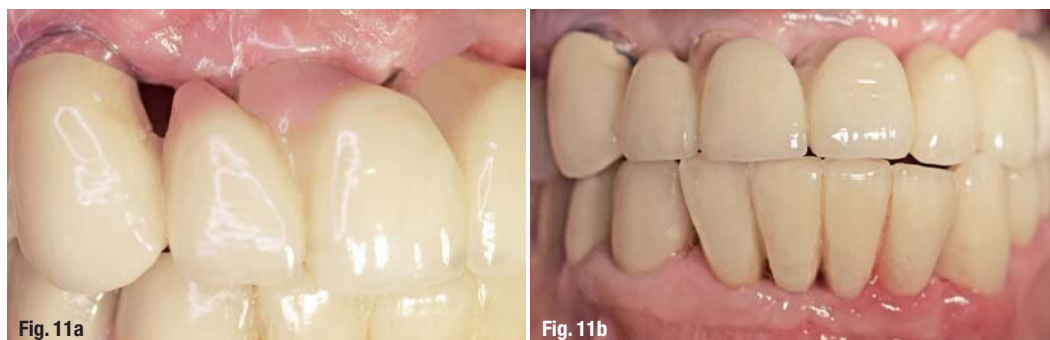was restored with a removable teeth-implant supported, palatal free bridge (Figs. 1a–d) using double crowns as attachments, as previously described.^{2–4}

No implants were placed in regio #16 and #26, since the patient decided against performing sinus lift procedures and the remaining bone height was inadequate to allow implant placement. Furthermore, the patient did not agree to extraction of teeth #13 and #23. Therefore, the final restoration had to be supported by four implants (#14, #11, #21, #24; 4.1 × 10 mm, RN, Straumann, Basel, Switzerland) and two natural teeth (#13, #23) with cantilevers in the areas #15–16 and #25–26 (Figs. 2a–d). Customised implant abutments (torqued to 35 Ncm) and gold copings placed on natural teeth #13 and #23 served as primary telescopes (Fig. 2c). Electroformed pure gold copings with a thickness of 0.25 mm (AGC Galvanogold, Wieland, Pforzheim, Germany), fixated in the superstructure with a self-curing copolymer cement (AGC Cem, Wieland, Pforzheim, Germany), as previously described were used as secondary telescopes.^{5,6} The metal framework was milled from a titan 5 alloy (ZENOTECTi Disc; Wieland) and covered with micro-ceramic com-

posite (Ceramage, SHOFU, Ratingen, Germany). The patient was put on a three-months maintenance schedule. Six years after implant and prosthetic treatment, the patient reported to the office. Tooth #13 had been fractured in a car accident. He refused any new restoration and insisted on keeping the existing one. Thus, implant placement in position #13 was planned. The fractured tooth #13 was extracted. The maxillary denture was inserted and a bite registration in central occlusion was performed using self-curing acrylic resin (pattern resin; GC, Alsip, USA). An impression (Impregum; 3M ESPE, Neuss, Germany) of the maxilla was taken with the denture in place. The denture was removed from the patient's mouth together with the impression (Fig. 3a). This allowed for the fabrication of a cast with an exact duplication of the abutments (Fig. 3b).

The casts were placed in an articulator using the denture as a guide to achieve correct occlusion (Fig. 4a). A temporary fixed partial denture (from #14 to #24 with #15 and #25 cantilevers) from coloured polymethyl methacrylate (PMMA; Zenotec; Wieland, Pforzheim, Germany) was milled based on a scan of the maxilla cast, and was adhered on the abutments using

Figs. 11a & b Denture in place; a) close-up; b) anterior view.



provisional cement (TempBond, Kerr Co., Orange, USA; Fig. 4b). In addition, a surgical stent fitting onto the abutments was milled from clear PMMA (Zenotec; Wieland, Pforzheim, Germany, Fig. 5a). The planned axis of implant #13 was determined using a dental parallelometer (Fig. 5b), and a drill sleeve was placed into the surgical stent (Fig. 5c). An implant (4.5 × 10 mm, SB line; Dentsgri, Duisburg, Germany) was inserted with a torque of 35 Ncm using a two-phase protocol (Fig. 6). Three months after implant placement, an impression post was positioned on the implant and the surgical stent was placed in the patient's mouth after the drill sleeve had been removed. The impression post was attached to the surgical stent using modeling resin (pattern resin, GC, Alsip, USA; Fig. 7). After this, the implant analog was attached to the impression post (Fig. 8a) and fixed in the cast using acrylic resin (Fig. 8b). A customised abutment fitting crown #13 was fabricated (Figs. 9a and b), positioned on the implant #13 and torqued to 35 Ncm (Figs. 10a–c). Subsequently, the denture was inserted (Figs. 11a and b).

Case 2

The patient (male, 61-years-old and in very good general health) had a foul-mouth periodontal-implant and prosthodontic rehabilitation in 1998. After combined periodontal and implant treatment the mandible

was restored with single-fix crowns retained on natural teeth and implants (Fig. 12). The maxilla was restored (in the same way described above for the first case with a removable palatal free metal-ceramic bridge using double crowns, e.g. telescopic crowns, as attachments, retained on seven natural teeth (#14,13–23) and three implants (#13, 24, 25; RN, 10 × 4.1 mm, Straumann, Basel, Switzerland). Because the patient did not consent to a sinus augmentation, no implants were placed in regio #16 and #26. Tooth #14 was treated endodontically and was used as the last abutment (Fig. 12).

Thirteen years after prosthetic rehabilitation, the patient reported to the office with a root fracture in tooth #15. The tooth was extracted, the secondary telescopic crown in regio #15 was removed, and the supraconstruction was temporarily filled with a photo-cured, highly elastic temporary material (Fermit, Ivoclar Vivadent, Ellwangen, Germany). The patient again refused a sinus lift and therefore the immediate implant placement regio #15 was scheduled. The axis of the tooth #15, the fabrication of the transfer key and the implant placement, were performed as previously described in case 1. A short implant (Endopore 4.1 × 9 mm, Sybron Implant Solutions, Bremen, Germany) was inserted into area #15 (Fig. 13). Four months after implant placement, impressions were taken and a cus-

AD

bicon
DENTAL IMPLANTS



SHORT
IMPLANTS

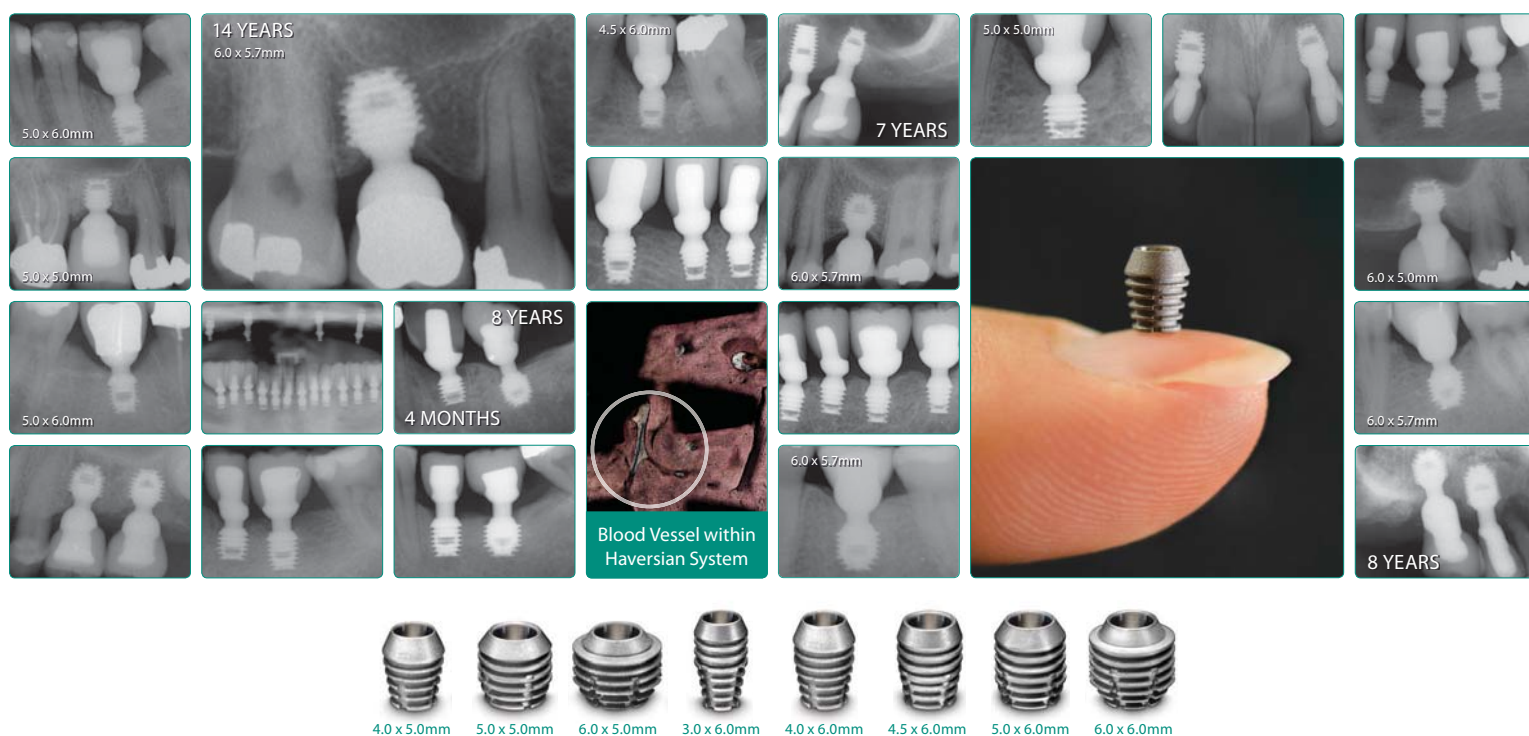

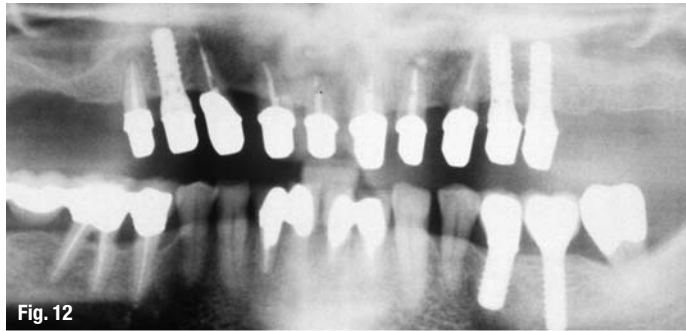


Fig. 12



Fig. 13a

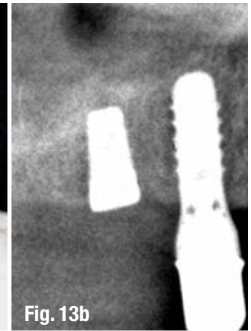


Fig. 13b

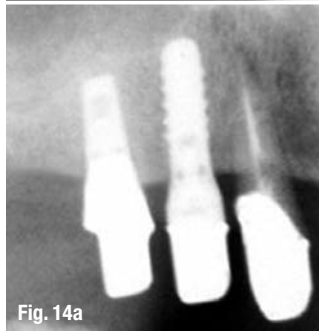


Fig. 14a

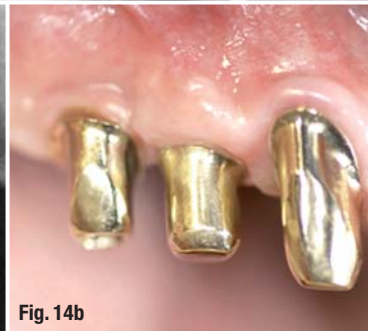

Fig. 14b

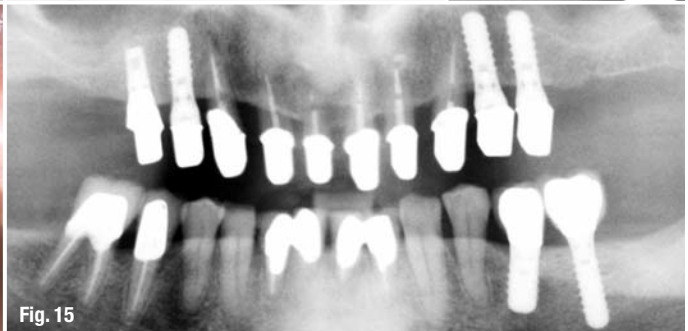

Fig. 15

Fig. 12_ Orthopantomograph taken at the completion of the perio-implant-prosthetic treatment.

Figs. 13a & b_ a) Surgical guide for implant placement #15; b) X-ray after implant placement.

Figs. 14a & b_ Customised gold implant abutment #15 in place; a) X-ray; b) clinical view.

Fig. 15_ Orthopantomograph taken at the completion of treatment.

tomised gold implant abutment and new secondary telescopic crown were fabricated and integrated into the same position as tooth #15 (Figs. 14 and 15). During a healing period as well as after the integration of the new abutment and the new secondary telescope in the bridge, the patient further used his telescopic maxillary restoration (Figs. 16a–d).

Discussion

The use of natural teeth and implants to support dentures incurs risks that may lead to loss of an abutment and, subsequently, the whole restoration. Recent reports have demonstrated a high long-term success rate of removable restorations supported by natural teeth and implants when double crowns, e.g. telescopic crowns, are used as attachments.^{7–9} However, the use of the combination, e.g. connection, of natural teeth and implants to support fixed dentures is not advisable due to the higher risk of complications.^{1,10} Cause for the loss of the abutment in case 1 was trauma from a car accident and not mechanical failure or periodontal infection or bone defects. Nevertheless, the resulting complications are similar to the ones described in the

literature for cases where the above-mentioned causes lead to loss of an implant.¹

In case 2, the natural abutment was lost due to mechanical reasons 13 years after loading. This kind of complications, e.g. fractures, have been reported in the long-term maintenance of fixed or telescopic reconstructions, when endodontically treated teeth were used as abutments.^{11,12} The complication discussed above could be avoided if the endodontically treated last natural tooth abutment #15 was extracted and replaced by an implant.

In cases of full-arch restorations retained on both implants and natural teeth, when a fracture of a natural abutment occurs, removal of the restoration is often necessary, regardless of the type of restoration (removable or fixed). This can cause not only conflicts between patient and dentist, but also high financial and technical efforts. The technique described above allows the successful replacement of the failed abutment by an implant, enabling the continuous use of the existing restoration.

Editorial note: A list of references is available from the publisher.

Fig. 16_ Clinical view.

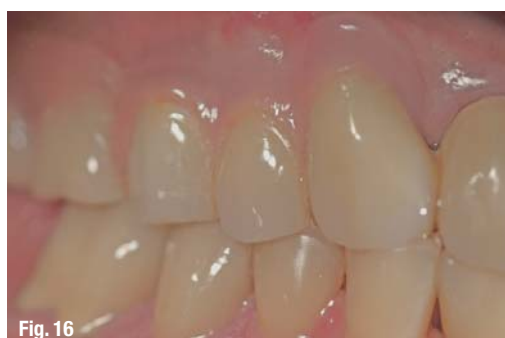

Fig. 16

contact

Prof. Dr Gregory-George Zafiropoulos

Sternstr. 61

40479 Düsseldorf

Germany

zafiropoulos@prof-zafiropoulos.de

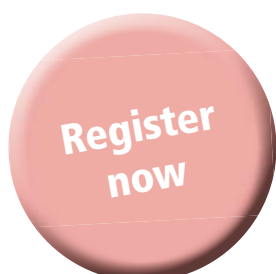


6TH INTERNATIONAL

CAMLOG CONGRESS

JUNE 9 – 11, 2016

KRAKOW, POLAND



TACKLING EVERYDAY CHALLENGES

At the 6th International CAMLOG Congress we will focus on scientifically sound and practical solutions. Experience our practical hands-on workshops, an innovative pre-congress on digitalization and exciting lectures. Participate in interactive discussions and meet internationally renowned speakers in the Network Lounge in a relaxed atmosphere. The attractive ICE Congress center in Krakow offers the perfect platform. Krakow is a lively and fascinating UNESCO World Heritage Site and enthusiastic in many ways. Other congress highlights are the Special Speaker, the legendary CAMLOG Party and the attractive partner programs.

Register early – we look forward to meeting you!

