

CAD/CAM custom-milled titanium bar for rehabilitation of an atrophic upper jaw

Author_ Dr Richard Marcelat, France

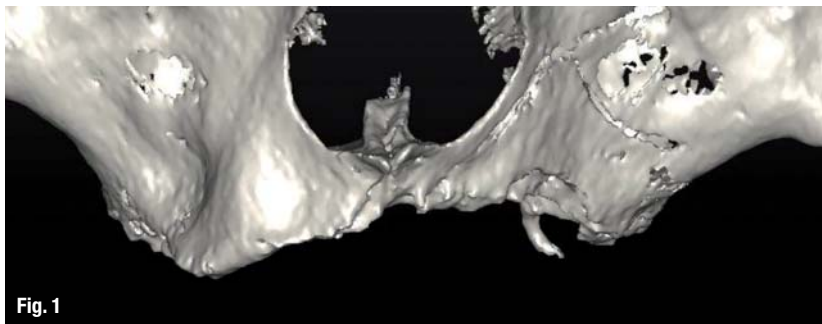


Fig. 1

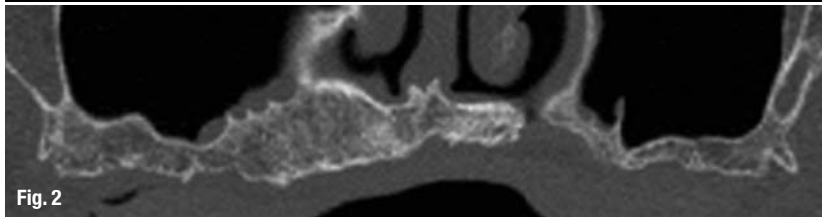


Fig. 2

Figs. 1 & 2_ Scans showing severe bone resorption and atrophy of the upper jaw.

_CAD/CAM is playing an increasing role in the production of implant-retained prostheses. These digital technologies constitute a major advancement in terms of fit accuracy of the superstructure.^{1,2} Rehabilitating a fully edentulous upper jaw with an implant-retained overdenture may require delicate treatment because of the biomechanical and anatomical considerations associated with severe bone resorption. This article describes the contribution of these new digital technologies to the construction of milled bars for rehabilitation in such cases.

_Case presentation

A 75-year-old non-smoking female patient, whose rheumatoid polyarthritis has been treated with methotrexate for seven years, presented. This patient has been fully edentulous in the upper jaw for 30 years. She wore a removable partial denture in the lower jaw and a removable complete denture in the upper jaw. Stability of the latter was very precarious owing to severe crestal bone resorption. The patient's motivations were mostly function orientated; she was eager to regain chewing comfort.

There are centrifugal forces in the lower and centripetal forces in the upper jaw, and bone resorption reduces the volume of the latter, causing an offset between the upper and lower jaws. This offset, which was to be compensated for by the overdenture, must be taken into account at implant placement.

Pre-implantation surgery

DentaScan (GE Healthcare) allows the evaluation, as a complement to the initial panoramic radiograph, of the residual bone volume available for implant-retained rehabilitation. In the present case, this examination confirmed that the upper jaw was atrophic (Figs. 1 & 2). Therefore, bone reconstruction was necessary prior to implant treatment. A bilateral sinus lift with lateral access was performed. The space under

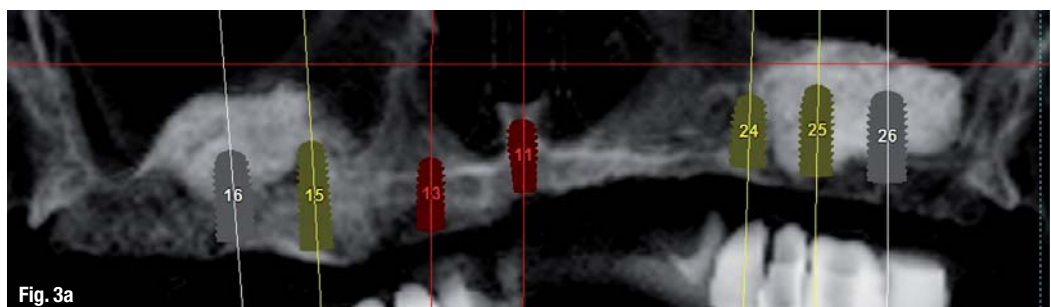



Fig. 3a



Figs. 3a–c_ Implant planning with SIMPLANT after a bilateral sinus lift.

the sinus floor was filled with allogeneic bone (max-graft, botiss biomaterials) mixed beforehand with the venous coagulum collected at the beginning of surgery. The following step entailed covering the allogeneic bone with a collagen membrane (Bio-Gide, Geistlich) and a platelet-rich fibrin membrane. The complete denture was then hollowed out and relined periodically with a soft resin.

Implantation planning

The case was planned using the SIMPLANT (DENTSPLY) treatment planning software. The radiographic guide, which is a duplicate of the existing prosthesis, allows the prediction of the positioning and orientation of the implants to anticipate the dimensions, locations and axes of the implants and abutments. It also allows maximal exploitation of the available bone volume (Figs. 3a–c).

Implant surgery

In order to test the mechanical resistance of the grafted areas on probing, osteogenic stimulation of the sinus filling material was performed with bone matrix Osteotensors (Victory), using the technique described by G. Scortecchi and C. Misch.³ The bone matrix Osteotensors are used in a trans-parietal technique (flapless procedure). This endosteal stimulation also activates the cells. This easy and minimally invasive technique enables the assessment of the quality of the intended implant sites. These techniques have been successfully used in orthopaedic surgery for a decade. Given the good response to osteogenic stimulation, the implantation was planned after 45 days.

Six months postoperatively, seven Axiom PX implants (Anthogyr) were placed in the upper jaw using the radiographic guide. Self-drilling, self-tapping and featuring a reverse conical neck, the conical, double-threaded implants selected for this rehabilitation

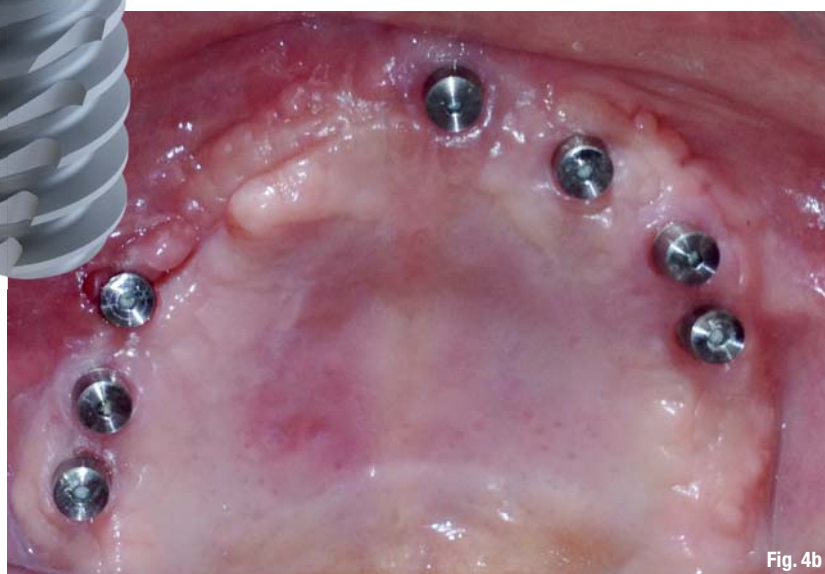(Fig. 4a) allowed us to obtain excellent primary anchoring, as they, along with the drilling protocol, encourage bone condensation in areas with low bone density. Moreover, the osteoconductive potential of their BCP (biphasic calcium phosphate) grit-blasted surfaces promotes osteoblast differentiation in the early stages of osseointegration.

Restorative phase

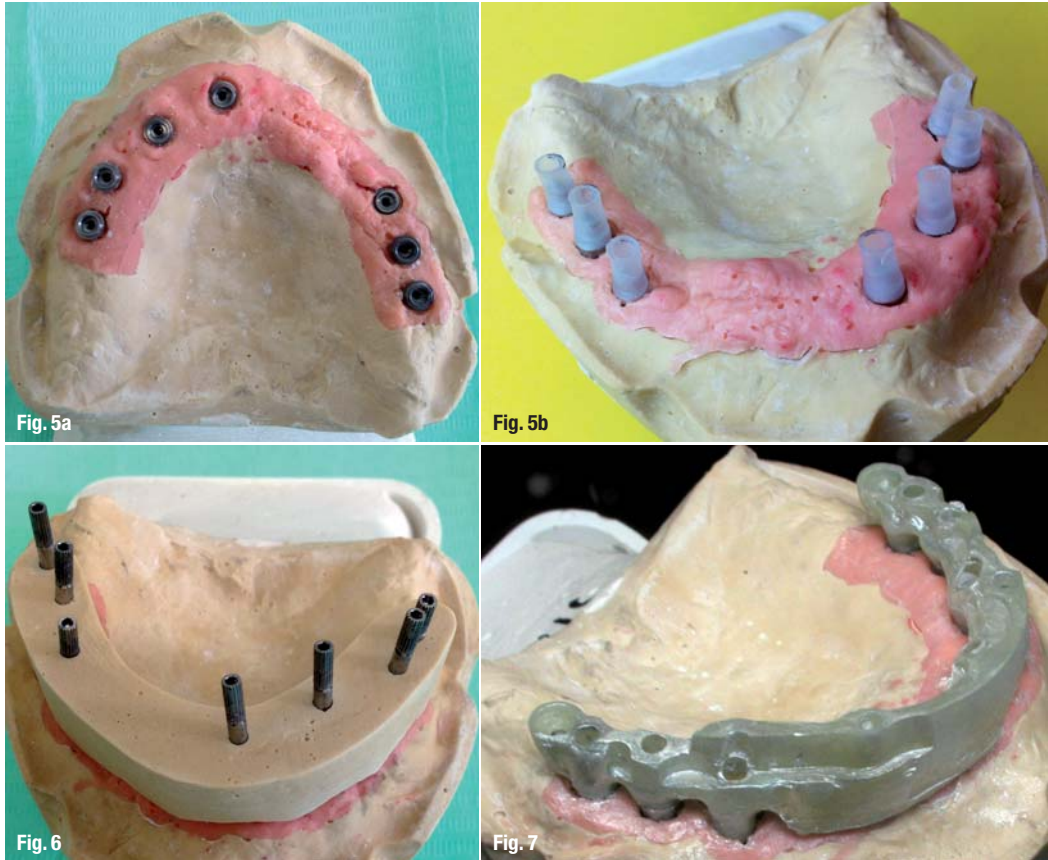
Four months after implantation, preparation for the final restoration began (Fig. 4b). A percussion test on the implants was carried out, and a control radiograph was taken. Straight multi-unit abutments were then placed and definitively torqued to 25 Ncm. Next, a pop-in impression was taken using a polyether impression material (Impregum, 3M ESPE) in a custom tray made by the laboratory technician. For full impressions on multiple implants, we usually prefer to take a pick-up impression, with joined impression transfers, but this technique could not be used here because of limited mouth opening.



Fig. 4a_ Axiom PX implant.
Fig. 4b_ Occlusal view showing the multi-unit abutments and protective caps in place.



Figs. 5a & b_Master cast with silicone gingiva.
Fig. 6_Plaster index for approval.
Fig. 7_The wax pattern fabricated by the laboratory technician.

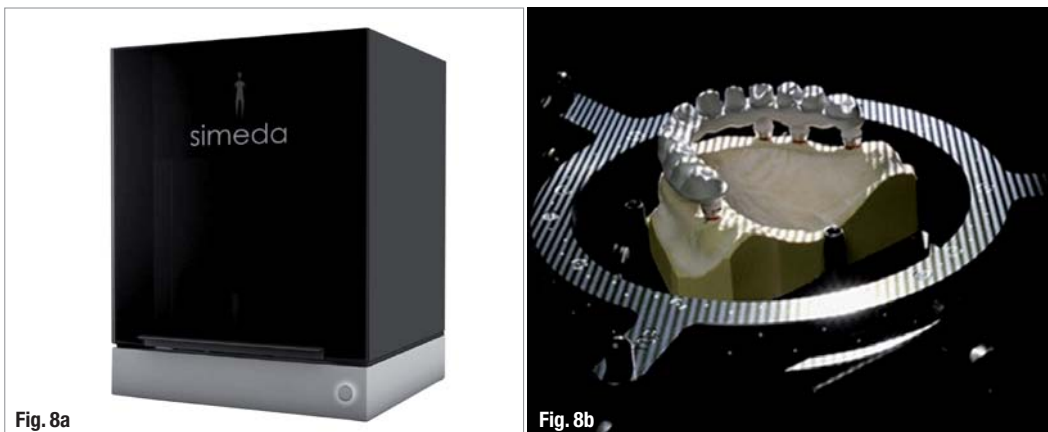


The master cast with abutment analogues and silicone gingiva was fabricated at the laboratory (Figs. 5a & b) and then checked in the dental office using an index made of non-expanding stone in order to ensure absolute precision (Fig. 6). This step is essential to ensure that the master model is perfectly accurate.⁴ The maxillomandibular relationship is then transferred to the articulator by relining the existing prosthesis on conical caps of abutments (a bite wax on a hard basis—a technique considered more accurate by some—can be used instead). The interpupillary line was registered by means of an inclinometer (AmannGirrbach). The aesthetic set-up, maxillomandibular relationship and occlusion were then checked on the patient by means of a denture

set-up placed on a thermoformed hard basis. This set-up reflected the patient's wishes regarding aesthetics too.

The laboratory produced a resin pattern of the substructure (Fig. 7), namely a milled bar as a true anchoring beam, screwed on to the abutments. After approval, the master model and wax-up were sent to Simea (Anthogy). This fabrication centre scans the master model and virtually designs the component to be produced (Figs. 8a & b). After approval of this virtual model at the laboratory by means of a 3-D PDF document (Figs. 9a & b), the bar was milled from a block of titanium, using a five-axis CNC milling machine (Fig. 10).⁵

Fig. 8a_Simea scan.
Fig. 8b_Scanning.



Dear authors, thank you for your contributions in 2015.

Looking forward to working with you in 2016!

To publish, please contact:

Georg Isbaner
Editorial manager
g.isbaner@oemus-media.de



Figs. 9a & b_3-D CAD model.
Fig. 10_Milling.




Fig. 9a

Fig. 9b

Fig. 10

Titanium—four times lighter than semi-precious alloys—is the lightest metal used in dentistry. It offers excellent biocompatibility and very good mechanical properties.⁶ The metal is highly reactive to oxygen: when the metal is exposed to air, a protective film, the passivation layer, builds up on its surface and makes it extremely resistant to corrosion and chemical attacks. Titanium offers additional advantages in oral implantology. The density of the materials used is crucial. The weight of a prosthesis

for an upper jaw appears to be a key factor for treatment success.

A few days later, the bar was tried in the patient's mouth. It was perfectly adjusted and seated passively (Figs. 11a–d). Milled bars exhibit a precision fit better than 10 μ. The substructure was sent back to the laboratory technician, who then produced the framework using the silicone indices of the approved functional and aesthetic set-up.

Figs. 11a & b_Simeda milled titanium bar.
Fig. 11c_The titanium bar in situ.
Fig. 11d_Panoramic radiography for fit control of the bar.

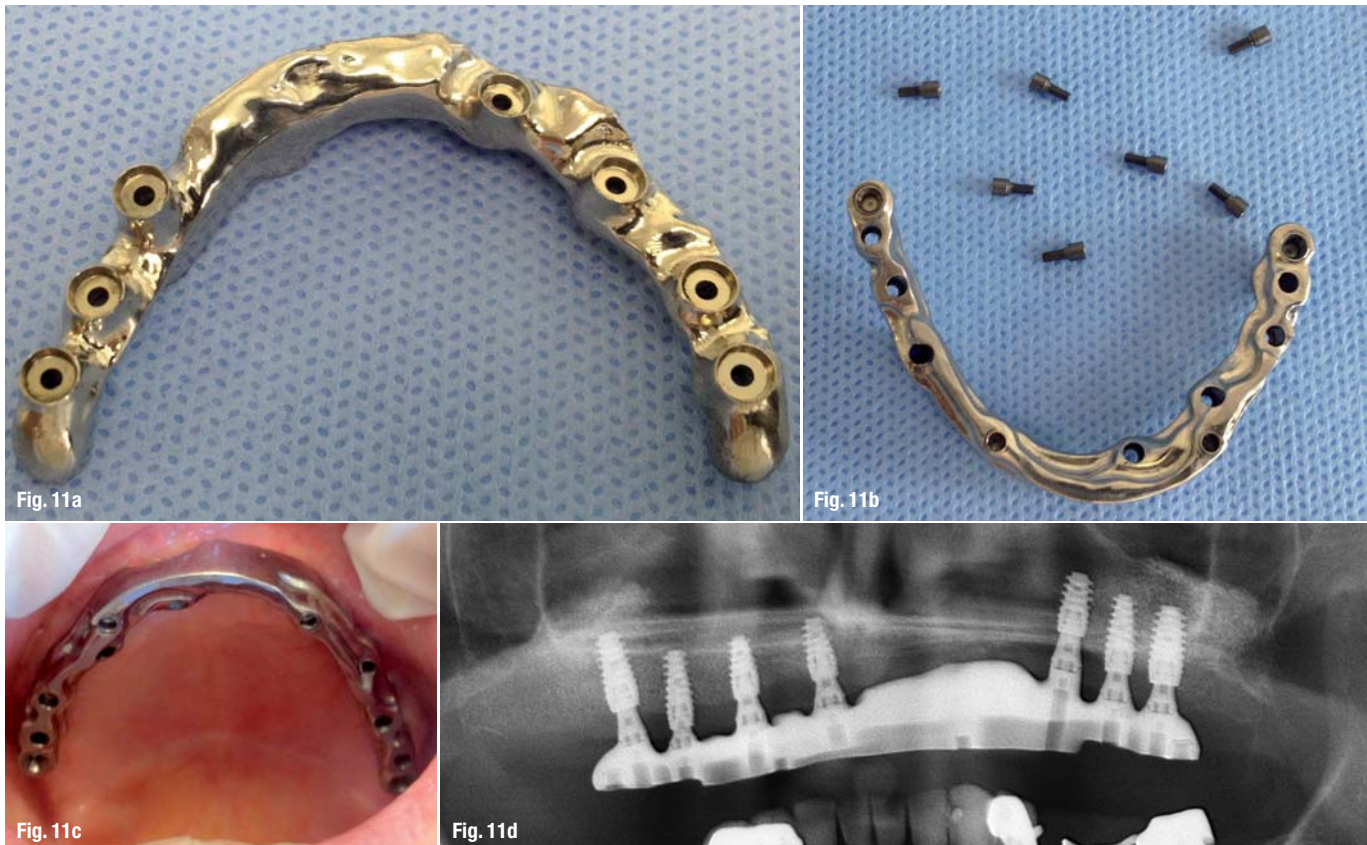

Fig. 11a

Fig. 11b

Fig. 11c

Fig. 11d

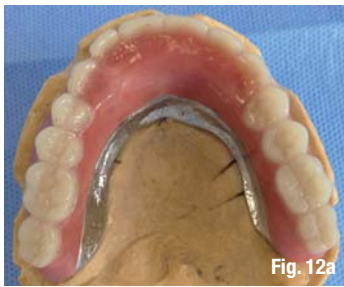

Fig. 12a

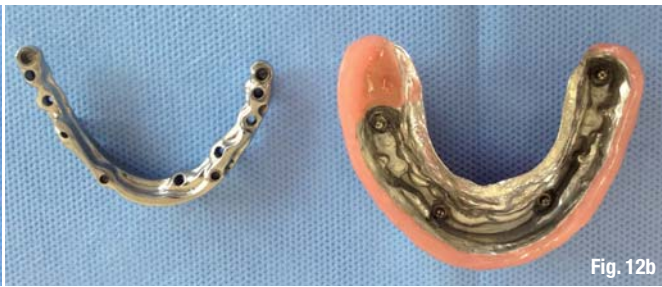

Fig. 12b

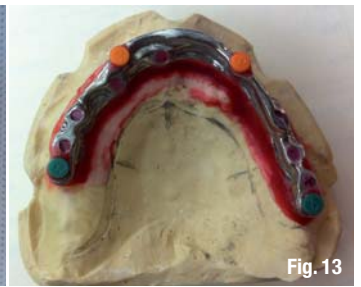

Fig. 13

The restoration consisted of two distinct parts:

- the milled bar screwed on to the multi-unit abutments; and
- the removable telescopic part: the prosthesis, friction-retained on the bar (Figs. 12a & b).^{7,8}

As the seven implants were well distributed over the entire arch, no palatal coverage was needed, meaning enhanced comfort for the patient. Retention of the prosthesis by the bar was enhanced by four CEKA attachments (ALPHADENT; Fig. 13).

A milled bar-retained removable prosthesis can be considered an attractive option for patients presenting with an atrophic upper jaw and/or bruxism because it efficiently compensates for the tissue loss, ensuring a good aesthetic outcome, in addition to excellent stability and retention of the prosthesis.⁹ For this reason, this option is classified by some as falling in the category of removable bridges.⁹⁻¹² The prosthesis is nevertheless resilient enough to withstand high mechanical stress, reducing the risk of fracture, especially that of the veneering layer.^{13,14}

Discussion

With conventional casting techniques, producing a substructure for an implant-retained prosthesis remains technically difficult.^{15,16} The difficulty of achieving passive fit is proportional to the number of elements and volume of the substructure. Despite the advances in casting technology, in the case of large-span substructures, primary or secondary brazing is often needed to compensate for the dimension variations in order to achieve an absolutely passive fit.^{17,18} Such an accurate, passive fit of the substructure is essential for the bone physiology of implants and long-term reliability of implant-retained rehabilitations.^{19,20} Owing to its high precision, CAD/CAM is an invaluable tool for evolving the prosthetic workflow technologically.^{1,21} The restoration is designed based on a 3-D CAD image created from the scanned data.²²⁻²⁴

CAD software allows modelling of the prosthesis, taking into account the material selected (such as zirconia; titanium; cobalt–chromium; IPS e.max, Ivoclar Vivadent; and PMMA).

As the subtractive fabrication technique (milling) associated with this CAD ensures that the material structure will not be altered, a metal substructure featuring optimal density and homogeneity is obtained. In addition, the computerized configuration of this process ensures reproducible results and irreplaceable passive insertion of these substructures.

Conclusion

Today's laboratory scanners can digitize the model, wax-up and implant index. CAD/CAM technology offers unmatched work quality, precision and reproducibility compared with conventional procedures. It is certainly the most appropriate technology for producing implant-retained superstructures. This technology also allows improved passive fit of substructures and facilitates the work of the laboratory technician.

Passive fit as a prerequisite for successful implant-retained prostheses ensures long-term reliability of rehabilitation work.²⁵ Moreover, the fabrication centres can machine biocompatible materials such as titanium and zirconia.

These CAD/CAM techniques, which are already well established in dental laboratories, constitute a major contribution to our daily practice, and will soon be essential in all practices.

The author declares no conflict of interest.

Editorial note: A complete list of references is available from the publisher.

about the author

Dr Richard Marcelat has a DDS in Oral Implantology from the University of Liège and in Basal Implantology from the University of Nice Sophia Antipolis, as well as a Postgraduate Certificate in Implantology from CURAIO in Lyon in France. He can be contacted at richard.marcelat@orange.fr

Figs. 12a & b The telescopic denture on a milled bar.

Fig. 13 CEKA attachments as additional retention devices.