

Complete reconstruction for a patient with chronic tooth decay

The damage undone

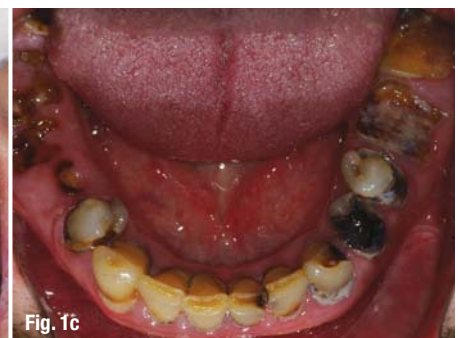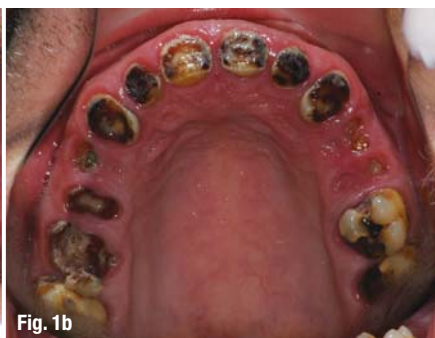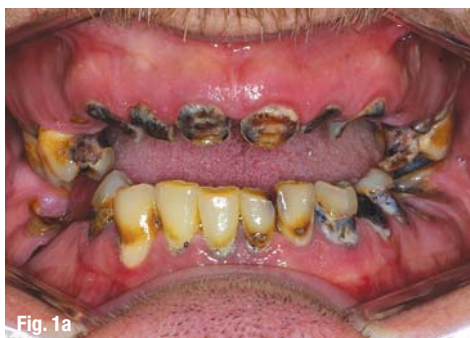Author_Dr Ara Nazarian, USA

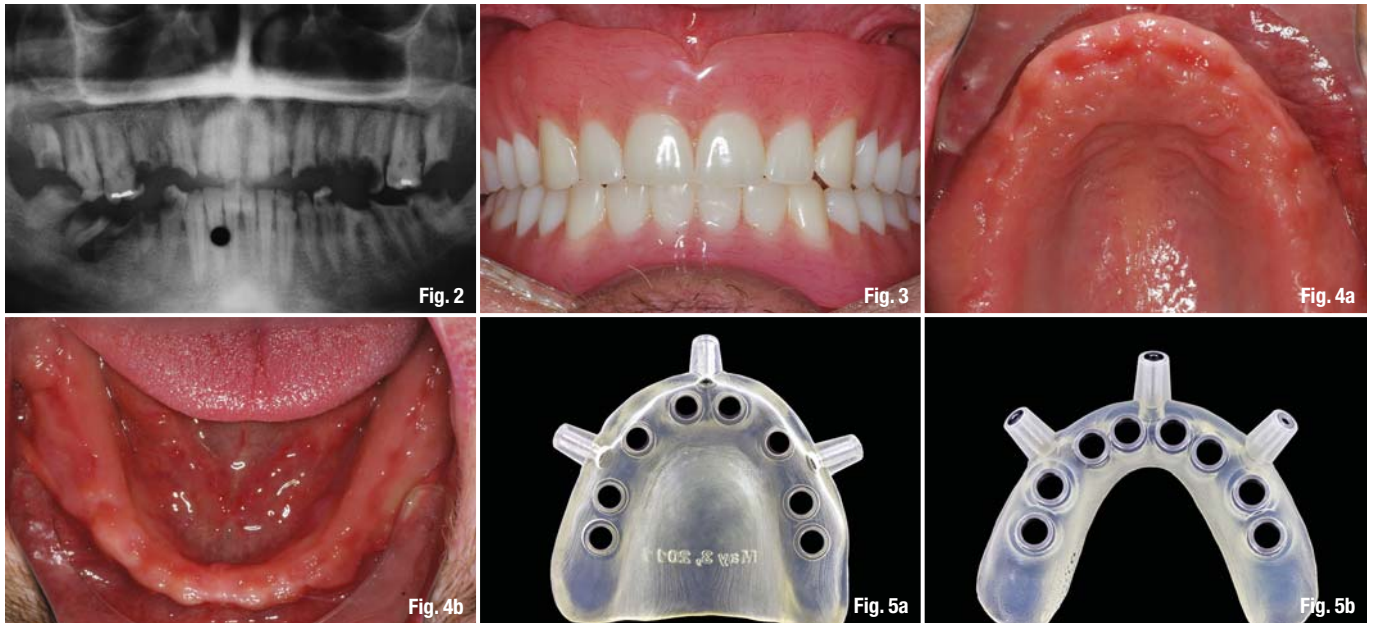
When oral health is neglected for extensive periods of time, dental conditions like tooth decay and periodontal disease can advance to a point that, prior to the advent of implant therapy, was considered hopeless. If a patient presented with extensive caries and a non-restorable set of dentition, practitioners had no choice but to extract the teeth and provide the patient with a complete denture. Although beneficial to patients as a fundamental replacement of their teeth, many patients have found the fit, comfort and retention of such appliances to be problematic.¹ Without any anchorage to hold it in place, the traditional denture has a tendency to move around in the patient's mouth, compromising speech and chewing capabilities. This problem is exacerbated by the recession of the edentulous arch that occurs following tooth loss or extraction. After decades of advancements in implant design, restorative materials, and digital dentistry, we can today provide patients with a higher level of care. Root-form dental implants can be placed predictably to hold a full-arch prosthesis in place, providing greatly improved comfort, function, and quality of life compared to traditional complete dentures.^{2,3} Further,

osseointegrated implants serve to mitigate bone resorption.⁴ This means that in addition to providing the aesthetics of natural dentition, implant-supported restorations also help to preserve the edentulous ridge and the essential support it provides for the mouth and face. The positive impact this can have on personal confidence, emotional health, and social interactions is substantial.⁵

Thus, patients who present with the most acute dental conditions can now be brought back from the brink and become fully restored via implant therapy. If the patient's teeth have deteriorated to the point where they can no longer be saved, they can be extracted, implants are placed, and a full-arch restoration is delivered that closely emulates the form and function of natural dentition. This alternative should be presented to all patients for whom implant therapy is indicated, as individuals who at first may not appear to have the means for high-quality treatment may in fact have the wherewithal after being apprised of their options. Additionally, all patients should be made fully aware of the long-term costs and benefits of tradi-

Figs. 1a–c Retracted frontal, occlusal maxillary and occlusal mandibular views exhibit the non-restorable preoperative state of the patient's dentition.





tional complete dentures vs. implant-supported restorations before making a decision with such life-changing potential. The presentation that follows documents a case in which a patient with severely decayed dentition undergoes a complete oral reconstruction. A treatment plan is developed that harnesses the classic principles of implant placement, the versatility of modern restorative materials, and the precision of digital diagnostics and CAD/CAM fabrication to achieve a predictable, aesthetic restoration for a case that would seem hopeless to many. The case illustrates how implant therapy can afford patients even in the most extreme of dental circumstances an excellent long-term prognosis, restoring not just the teeth, but also the bone, soft tissue, self-esteem, and quality of life.

Case Report

A 36-year-old male patient presented for treatment with advanced, extensive caries and localized periodontal disease (Figs. 1a–c). In addition to not having seen a dentist in more than 20 years, the patient was recovering from an addiction to methamphetamine, which had caused excessive clenching and grinding that had substantially worn down the patient's teeth. The many years of dental neglect combined with these parafunctional habits to render the patient's severely decayed dentition untreatable (Fig. 2). Further, the deterioration of the patient's teeth was accompanied by significant soft-tissue recession and bone resorption.

Although the patient had been quite apprehensive about seeking treatment, pain and discomfort eventually compelled him to take action. The patient had sought treatment from a practice where he could receive all of the necessary treatment from a single provider in the fewest appointments possible. After lo-

osing my practice, the patient found the courage to present for evaluation. It was apparent from the initial visit that he was ashamed of his condition.

The goal was to offer him the best treatment available in order to restore the patient's smile, form and function. Without presuming the appropriate standard of care for the patient based on his condition, it was explained to the patient that his natural teeth could not be saved and a full range of treatment alternatives was presented, from complete dentures to fixed full-arch implant restorations. Before-and-after photos of similar cases were shown to the patient to assist his evaluation of the restorative options. The patient chose full-mouth reconstruction consisting of fixed prostheses delivered over dental implants. A treatment plan was developed that included extraction of the patient's non-restorable dentition, the placement of eight implants in each arch, delivery of Inclusive® Titanium Custom Abutments and BioTemps® restorations (Glidewell Europe GmbH; Frankfurt/Main, Germany), and final restoration with fixed PFM prostheses. The latest tools in digital dentistry would be utilized to maximize the precision of both implant placement and prosthetic fabrication.

Because of the patient's relatively youthful age and his continued bruxing habit, eight implants were proposed for each arch in order to maximize the distribution of occlusal load, the preservation of his ridges, and the long-term prognosis of the restoration. The resorbed state of the patient's maxillary and mandibular ridges necessitated a grafting procedure to create the foundation needed for implant placement. Custom abutments would be used to position the prostheses for optimal aesthetics. Although BruxZir® Solid Zirconia Full-Arch Implant Prostheses (Glidewell Europe

Fig. 2 Panoramic radiograph further illustrates the extensive tooth decay the patient had suffered, which had caused a major infection as evidenced by the radiolucent lesions visible at the tips of several roots. Also note the periodontal lesions visible in the lower arch.

Fig. 3 Following extraction of the patient's dentition, immediate dentures were delivered to provide the patient with a minimum level of function and aesthetics during the healing phase.

Figs. 4a & b Occlusal views of patient's maxillary and mandibular ridges exhibit healthy tissue at the extraction sites.

Figs. 5a & b Surgical guides were 3-D printed to help ensure placement of the implants in accordance with the digital treatment plan.

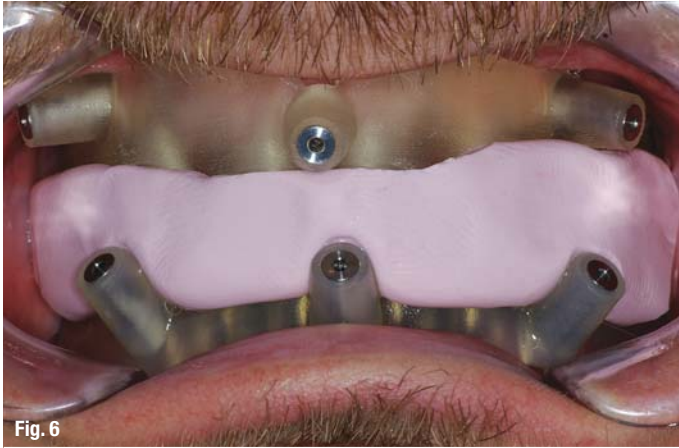


Fig. 6

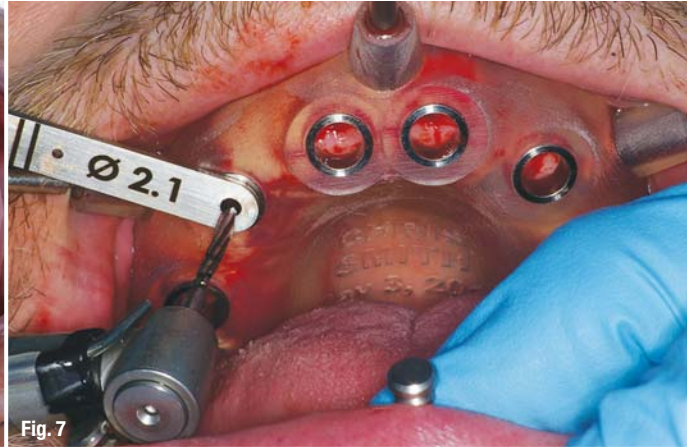

Fig. 7

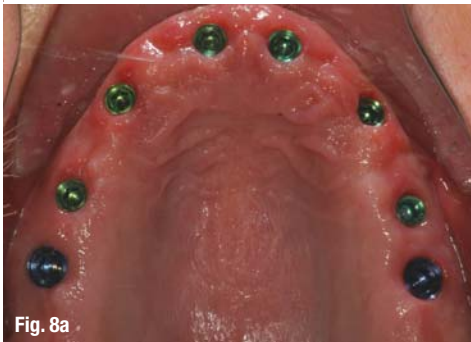


Fig. 8a

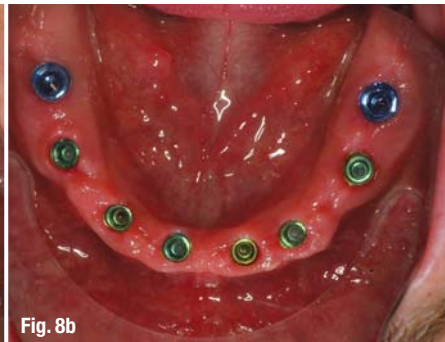

Fig. 8b

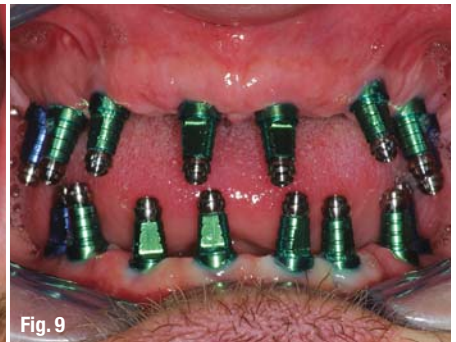

Fig. 9

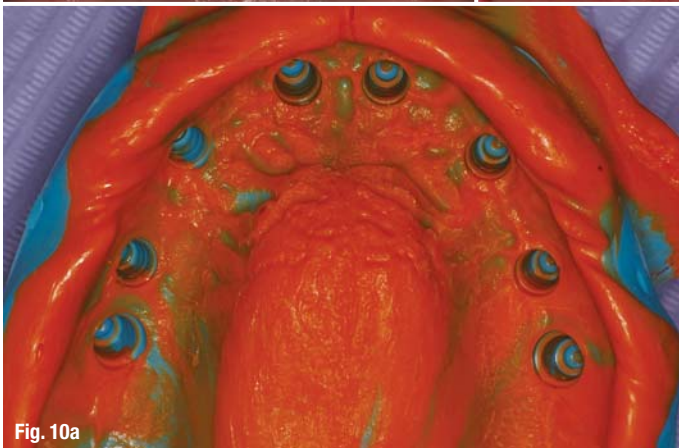


Fig. 10a

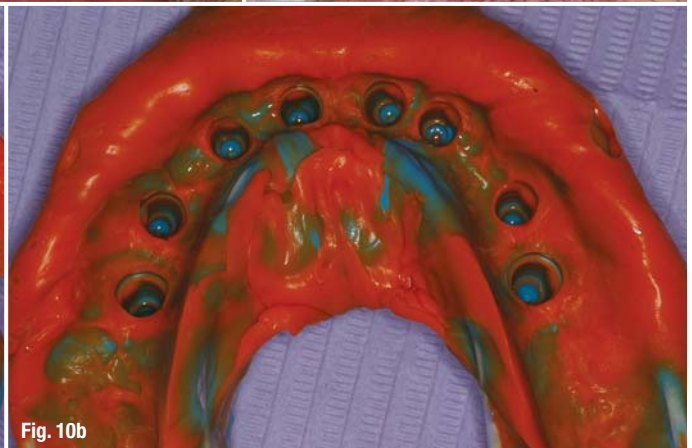


Fig. 10b

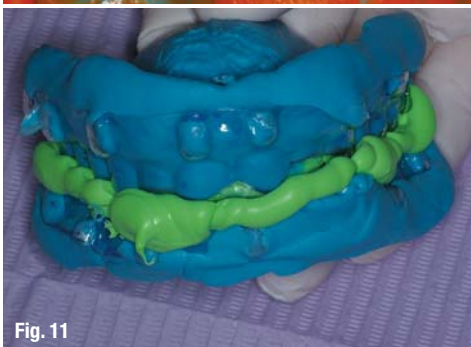

Fig. 11

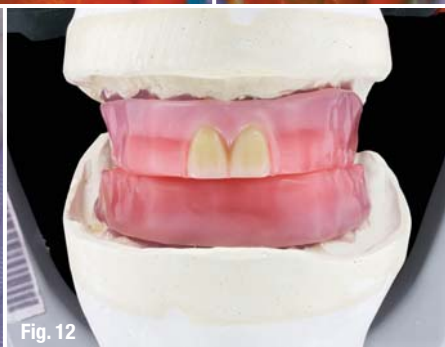

Fig. 12

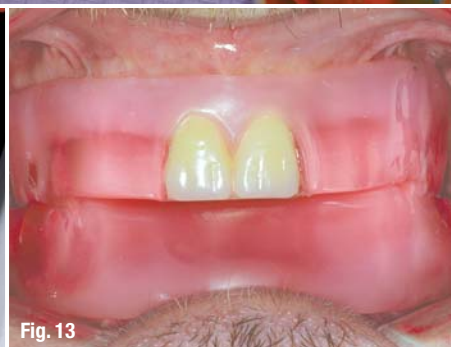

Fig. 13

Fig. 6 The surgical guides were seated in the patient's mouth and secured using the fixation pins and positioning index.

Fig. 7 The surgical guides controlled the positioning of the osteotomies during drilling.

Figs. 8a & b Occlusal views of maxillary and mandibular implants illustrate excellent healing of the soft tissue four months after surgery.

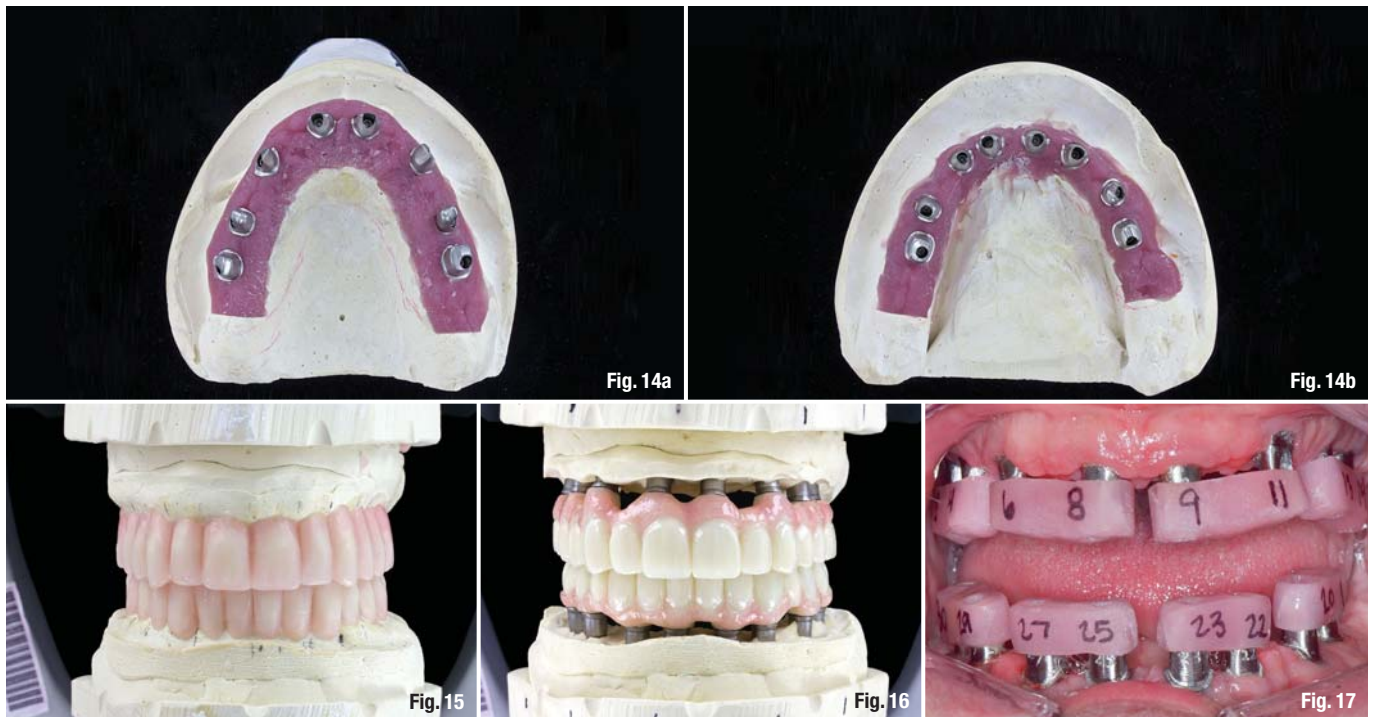
Fig. 9 The impression copings were tightened into place using the ball-top screws.

Figs. 10a & b Upper and lower closed-tray impressions were taken and sent to the lab so working casts could be fabricated.

Fig. 11 Impressions of the patient's immediate dentures were taken along with a bite registration to help guide the design of the definitive prostheses.

Fig. 12 Wax rims were produced by the lab so the patient's interocclusal relationship could be determined.

Fig. 13 The patient's jaw relationship was recorded with the wax rims in place.



GmbH; Frankfurt/Main, Germany) would have been the ideal restorations given the need for long-term durability in this case, the product was not yet available at the time of treatment. Thus, PFM prostheses were chosen in order to avoid acrylic and its susceptibility to staining, wear and fracture. The proposed PFM restorations included layered pink porcelain to recreate the patient's natural gingival contours. All aspects of treatment were explained to and accepted by the patient. The first phase of treatment began by atraumatically extracting the patient's entire dentition using Physics Forceps (Golden Dental Solutions Inc.; Detroit, USA), which allowed for removal of the teeth without causing any damage to the surrounding bone. The extraction sockets were filled with grafting material in order to preserve the sockets and rebuild the maxillary and mandibular ridges for ideal implant placement. The patient was provided with immediate dentures, which were prefabricated based on impressions that were taken at a previous appointment (Fig. 3).

After approximately five months of healing, the patient was called in so cone-beam computed tomography (CBCT) scanning could be performed. The soft tissue of the patient's now-edentulous arches exhibited excellent health (Figs. 4a & b). CBCT scanning confirmed that the grafting procedure was successful in increasing the bone volume available to accommodate the planned implants. The CBCT scanning data was used to devise a virtual treatment plan that would place the eight implants for each edentulous ridge in the maximum amount of bone while adhering to the key implant positions as taught by Dr. Carl Misch.⁶ Surgical guides were fabricated to ensure placement of

the implants in the precise positions called for by the treatment plan (Figs. 5a & b).

At the next appointment, the tissue-supported surgical guides were tried in and found to be well-fitting. The fixation pins of each surgical guide were tightened with a surgical index in place to ensure complete, secure seating of the appliances (Fig. 6). A tissue punch was used to provide access to the implant sites, facilitating a flapless surgical procedure that would minimise gingival trauma. The osteotomies were created through metal inserts placed in the surgical guides, which precisely controlled drilling depth and orientation according to the digital treatment plan (Fig. 7).

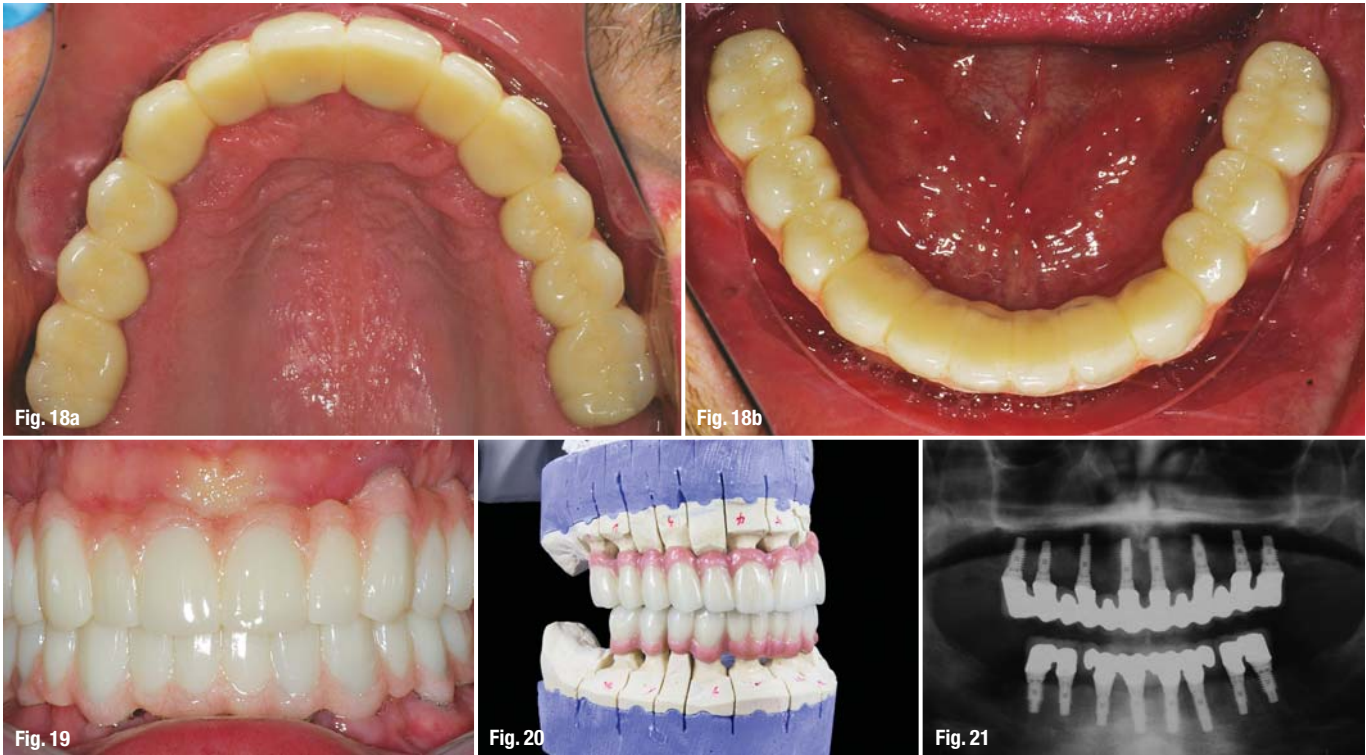
Eight BioHorizons[®] Laser-Lok[®] dental implants (BioHorizons; Birmingham, USA) were placed in each ridge, including 5.7 mm implants in the two distal-most locations of each arch, and 4.5 mm implants in the remaining sites. After placing healing abutments in the implants, a soft reline was performed on the patient's temporary dentures so they could continue to serve as interim prostheses for the duration of healing and osseointegration. Four months after surgery, the patient returned to the office so impressions could be taken. Removal of the healing abutments revealed optimal tissue health surrounding the implant sites (Figs. 8a & b). Transfer posts were seated to capture the position of the implants (Fig. 9). Closed-tray impressions were taken of the upper and lower arches using Take 1[®] Advanced[™] vinyl polysiloxane material (Kerr Corp.; Orange, USA, Figs. 10a & b). At the same appointment, thermoformed suck-down impressions were made and a bite registration taken with the

Figs. 14a & b The lab digitally produced the custom abutments and verified the design on the soft-tissue models.

Fig. 15 A diagnostic wax-up was created to assist in the development of the full-arch reconstructions.

Fig. 16 The BioTemps prostheses were fabricated, and the interocclusal relationship was verified on the articulator prior to patient try-in.

Fig. 17 Acrylic positioning jigs were used to seat the custom abutments in the patient's mouth.



Figs. 18a & b_The BioTemps prostheses were tried in and fit the patient well.

Fig. 19_The interim BioTemps restorations were evaluated for proper occlusion, function and esthetics.

Fig. 20_Based on the final-approved BioTemps prostheses, the final PFM restorations were fabricated on the master casts.

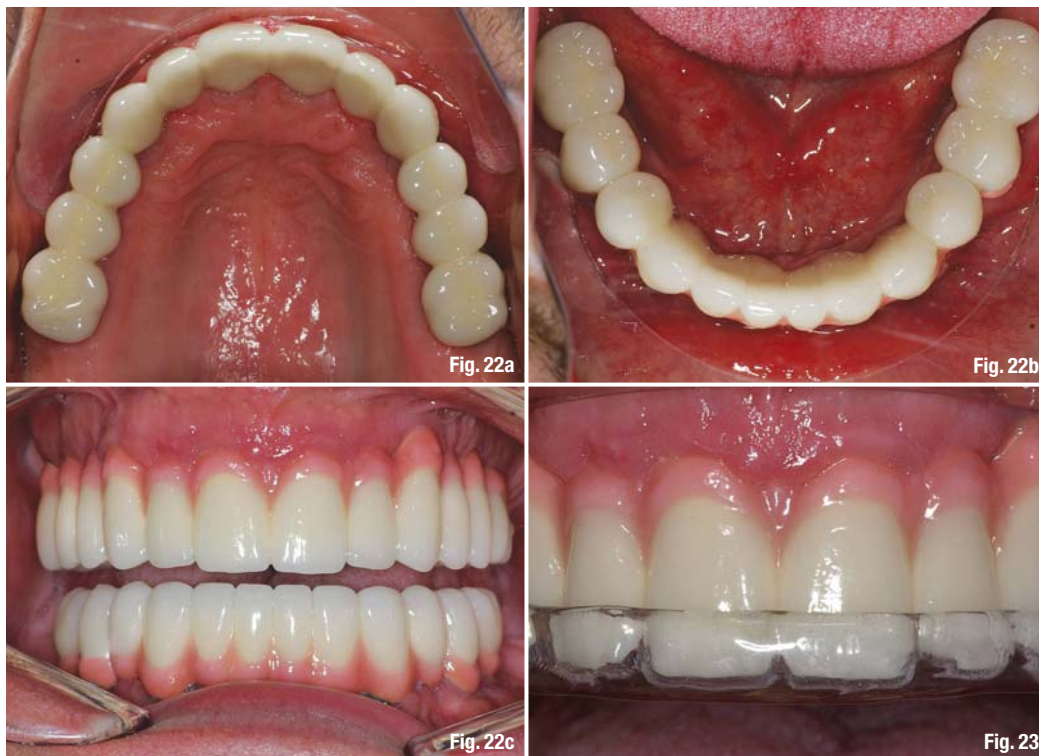Fig. 21_Final panoramic radiograph illustrates proper placement and orientation of the dental implants.

patient's immediate dentures in place, providing the lab with a template for the definitive design of the PFM restorations (Fig. 11).

The lab poured working casts from the VPS impressions of the patient's edentulous arches and produced wax occlusal rims (Fig. 12). After seating the wax rims in the patient's mouth and tightening the temporary cylinder screws, the jaw relationship records were taken (Fig. 13). Note that the patient's vertical dimension had virtually collapsed due to the extensive wear to his teeth. After measuring the distance between the patient's nose and chin during maximum intercuspation, the lab was instructed to open the patient's bite by 2 mm. Next, the lab used CAD software to design Inclusive® Titanium Custom Abutments (Glidewell Europe GmbH; Frankfurt/Main, Germany) for both arches based on the scanned working models. The CAD/CAM-produced custom abutments were seated on the working models so their fit could be verified and they could be used in the development of the definitive prostheses (Figs. 14a & b). Based on the jaw relationship records and the impressions of the patient's immediate dentures, the lab prepared a diagnostic wax-up to help determine the initial design for the PFM restorations (Fig. 15). After finalising the initial design, BioTemps prostheses were fabricated from polymethyl methacrylate (PMMA) material, which is versatile enough to easily accommodate adjustments at the try-in appointment, yet durable enough for provisionalisation (Fig. 16). The working models were sent out along with the custom abutments and BioTemps interim restorations for patient evaluation. At the next

appointment, the titanium custom abutments were transferred to the patient's mouth using the acrylic delivery jigs provided by the lab (Fig. 17). The custom abutments achieved a precise fit and were thus tightened to the appropriate torque, establishing ideal soft-tissue margins and support. Complete seating was verified radiographically, and the screw access holes were covered.

Next, the BioTemps prostheses were tried in and exhibited an accurate fit (Figs. 18a & b). The provisional restorations were attached to the abutments using temporary cement, and the phonetics, aesthetics, bite and function were evaluated (Fig. 19). Minor modifications were made to the BioTemps prostheses, and the patient wore the BioTemps provisionals for an interim of four weeks. This trial period was essential in verifying that the patient was happy with the look, comfort and function of the prosthetic designs before the final PFM restorations were fabricated. After patient approval was provided, alginate impressions were made of the BioTemps prostheses. Models of the final-approved BioTemps restorations were fabricated from the impressions, and a new bite was taken so the definitive prosthetic designs could be adjusted accordingly. Crown & bridge impressions were taken of the final custom abutments in place and would be used by the lab to pour master models, upon which the final PFM prostheses would be produced. The gingival areas for the final PFMs were marked onto the models of the BioTemps restorations, and the case was returned to the lab along with instructions for final adjustments. The final PFM prostheses were fabricated by layering



Figs. 22a–22c Retracted frontal, occlusal maxillary and occlusal mandibular views exhibit the excellent esthetics achieved by the implants and fixed PFM prostheses, reconstructing the patient's dentition as well as the soft tissue.

Fig. 23 The patient was provided with a nightguard to protect his investment against the forces of bruxing.

porcelain over a cast metal framework. Pink porcelain was layered on to form the gingival areas according to the markings indicated on the models of the BioTemps restorations, thus replacing portions of the soft tissue as well as the teeth per Dr. Misch's FP3 (Fixed-Prosthesis-3) principles of prosthetic design.⁶ Because the final prostheses were designed using the models fabricated from the final crown and bridge impressions, a precise fit over the patient's custom abutments was ensured (Fig. 20).

At the final delivery appointment, the PFM restorations were delivered over the custom abutments without issue. A panoramic radiograph was taken to confirm complete seating (Fig. 21). The final prostheses achieved the exact fit, aesthetics and function that the patient had come to expect after six weeks of wearing the BioTemps provisionals, which ultimately served as the bases for the final restorations (Figs. 22a–c). The patient was ecstatic with the results, which reconstructed his teeth and gingiva, along with his confidence and quality of life. A nightguard was produced for the patient to mitigate the impact of his parafunctional habits (Fig. 23).

Conclusion

The predictability of implant treatment and the adaptability of restorative materials enable clinicians to provide patients in the most dire of dental circumstances a complete overhaul, reversing the damage that can result from many years of dental wear and neglect. This goes beyond the restoration of oral func-

tion by preserving the facial aesthetics that are so fundamental to the emotional state and social life of the patient. Provided its life-changing capacity, the fixed full-arch implant restoration should be offered to all patients who present with untreatable dentition, without prejudging a patient's situation and the form of treatment that they will ultimately accept. As the precision, cost-effectiveness and prosthetic versatility of implant therapy expands ever further, so does the patient population that is able to receive high-quality treatment.

Editorial note: Reprinted by permission of ©2015 Glidewell Laboratories, Inclusive magazine. The dental lab work in this case was performed by Glidewell Laboratories. A complete list of references is available from the publisher.

contact



Dr Ara Nazarian

DICOI (Diplomate International Congress of Oral Implantologists)
1857 East Big Beaver Road
Troy, Michigan 48083, USA

www.michiganreconstructiveimplantdentistry.com
www.premierdentalcenter.com

www.aranazariandds.com

drnazarian@premierdentalcenter.com