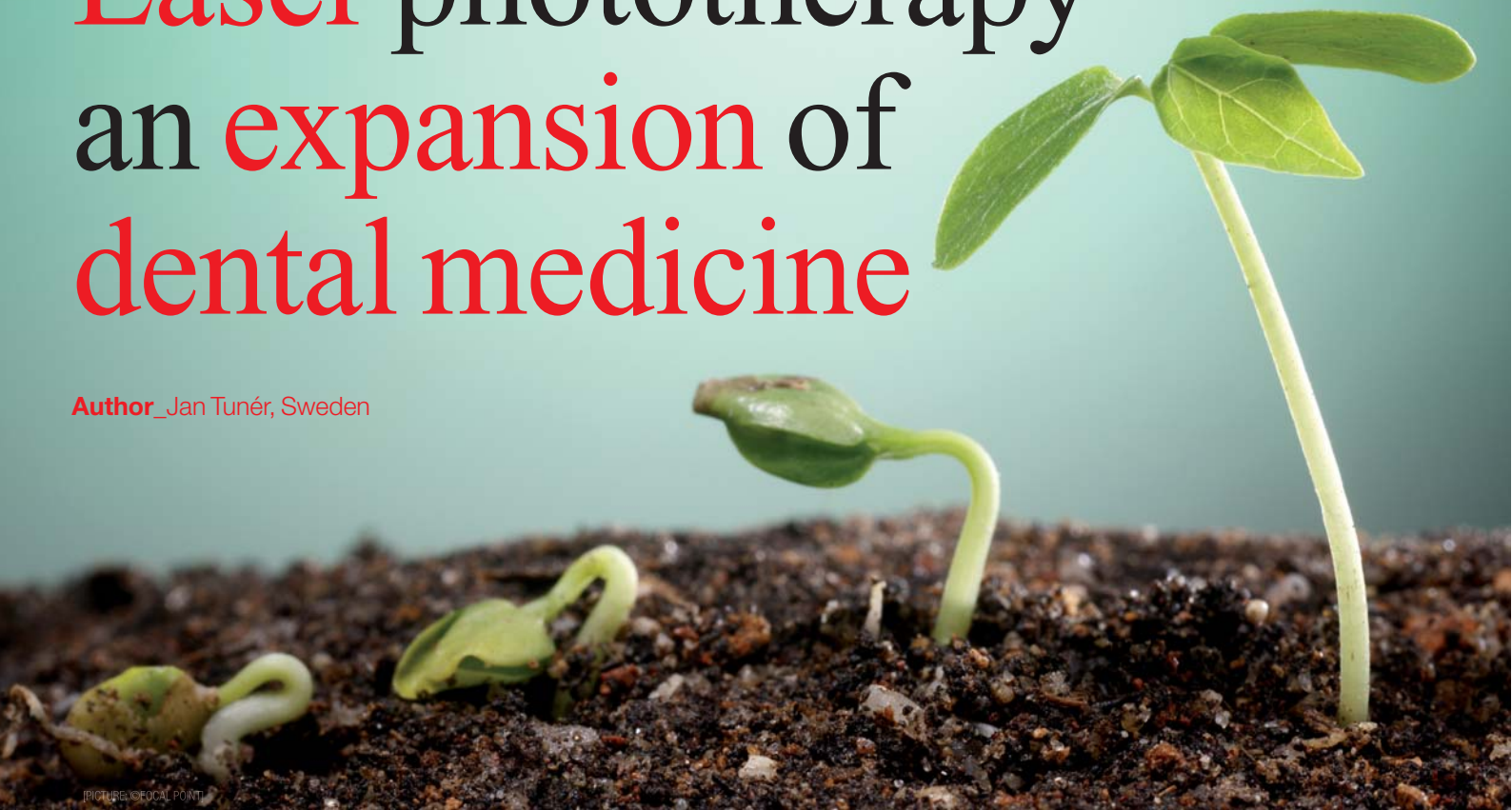


Laser phototherapy— an expansion of dental medicine

Author_Jan Tunér, Sweden



Laser phototherapy has been used in dentistry for several decades. From an initial attitude of incredulity, there is an increasing awareness of the usefulness of this treatment option. Many indications are now recognised, such as reduction of inflammation, pain and oedema. Having the known basic mechanisms in the cellular energy transport system in mind, the wide variation of suggested applications no longer seems illogical. This article will not linger on what is already known and accepted, but rather make an effort to look ahead onto the most recent discoveries. Laser phototherapy (LPT) has been seen as a

suitable intervention when some sort of pathology is present in tissue. A modern approach is to recognise the ability to pre-condition tissue even before a trauma such as surgery. This is a bit contrary to what we have learned in the past. It is well known that the best cellular response comes from cells in a reduced environment, i.e. with a low pH. More or less healthy cells will not react much to LPT. This is shown in the illustration below (Fig. 1).

Indeed, research has confirmed that LPT is not very useful in studies where healthy animals or human volunteers have been enrolled. For instance, a model using genetically diabetic animals has demonstrated a very positive effect on wound healing, whereas the same parameters in healthy animals has been modest.¹ However, the minimal effect of LPT on fairly healthy tissues seems to be enough to prepare the target tissues for a surgical intervention, as a way of “pre-conditioning” the area. In fact, this was one of the earliest discoveries in the field. McGuff et al. reported already in 1966 that animals exposed to radiation developed less side effects if pre-irradiated with LPT.² This effect has later been confirmed in animal and human studies.^{3,4} A clinical study by Nesioonpour used preoperative LPT in patients having surgical fix-

Fig. 1 From: Karu T. Ten lectures on basic science of laser phototherapy. 2007, Prima Books.

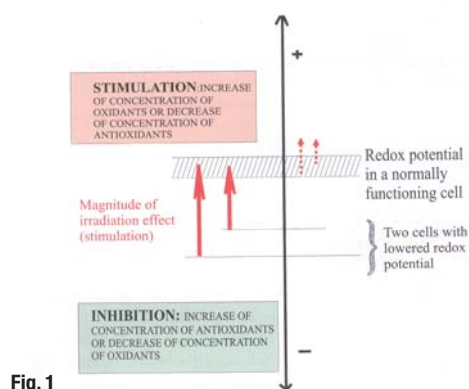


Fig. 1

ation of distal radius fractures.⁵ Intravenous regional anaesthesia was used. The need for painkillers was less in patients having LPT immediately before surgery. The study by Santos aimed to evaluate the effects of LPT immediately before tetanic contractions in skeletal muscle fatigue development and possible tissue damage.⁶ Optimal doses of LPT significantly delayed the development of skeletal muscle performance and protected skeletal muscle tissue against damage. Thus, it is suggested that LPT could be used prior to surgical intervention to reduce postoperative discomfort.

The fact that LPT can be useful even in healthy tissue was suggested already in 1999 by Schindl.⁷ The study showed that patients with recurrent HSV-1 attacks could be successfully treated with LPT even in the "silent" period in-between outbreaks. Dentists could therefore, at advantage, treat known HSV-1 prone patients with LPT even if there is no clinical evidence of an outbreak. The importance of this possibility is underlined by two recent studies where patients with recurrent HSV-1 turned out to have a greater risk of developing Alzheimer's disease later on in life.^{8,9} The connection is unknown, but if patients with recurrent HSV-1 are treated with LPT at conventional dental sessions, the risks may be reduced.

Alzheimer's disease is far from dentistry, but certainly there is a connection between the oral cavity and general medicine. A further example is Burning Mouth Syndrome [BMS]. This is in the oral cavity but considered to be a medical problem. LPT has been tried without success in early studies. However, the origin of BMS is unknown. Two more recent studies used high energies and the outcome was successful.^{10,11} Thus, the effect behind the pain relieving result appears to be inhibition of axonal flow, as demonstrated by Chow.¹² LPT then could not cure these patients, as with any other therapy, but at least serve as a pain relieving therapy, open for dentists.

Diabetes is another non-dental pathology with a deep impact in dentistry. The laser dentist cannot do anything about the pathology itself, but the advantages of treating the side effects of diabetes are obvious. This is among other things demonstrated in the healing process after surgery and periodontal therapy. An animal study by al-Watban showed that wounds in the genetically diabetic animals healed just as fine as for the non-diabetic animals.¹³ The positive effect in periodontal therapy is confirmed by Obradovic.¹⁴ We can therefore expect improved heal-

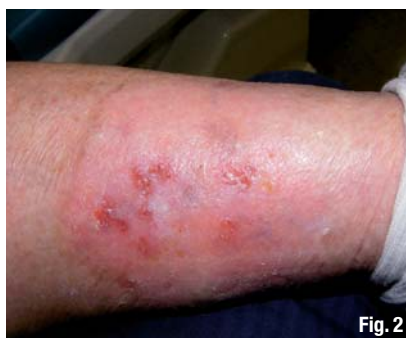

Fig. 2

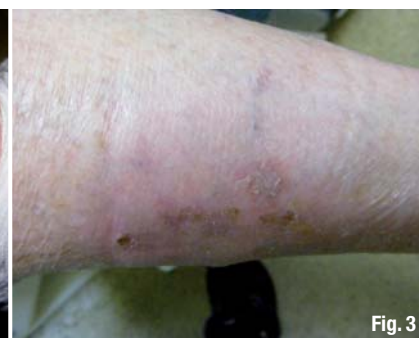

Fig. 3

ing after scaling, extraction and minor surgery if LPT as applied in diabetic patients.

Lichen planus is treated by specialists in the dental field and the general dentist often refers these cases to a specialist or to a medical doctor. A recent study by Dillenburg showed a better result from LPT than for the traditional clobetasol.¹⁵ Pemphigus vulgaris is yet another autoimmune condition where steroids can be replaced by LPT.^{16,17}

TMD is indeed a dental indication, but being multifactorial, it borders to psychology and medicine. Each profession can do its own part. A more holistic attitude is required to cure some of these patients and the muscular problems are often not only related to the masticatory system but to neck and shoulders as well. A laser dentist can make these areas a dental interest and expand the therapeutic possibilities. From a strictly scientific point of view, LPT for TMD is not scientifically proven. This is because even with more than 50 clinical studies, the parameters differ a lot, the laser parameters as well as the therapeutic approaches. Should the lack of Cochrane-style evidence be applied to this treatment, we should be aware of the fact that endodontics is another area where there is no scientific evidence, according to an evaluation by SBU—Swedish Council on Health Technology Assessment.¹⁸ The lack of evidence stems from the use of different materials and methods. Thousands of papers cannot rectify this judgement. Of course, we know that endodontic treatment works well, but we cannot prove it. The same goes for LPT and TMD, for the time being. In fact, SBU has a more positive evaluation of the use of LPT for neck pain.¹⁹

Figs. 2 & 3 Non-healing wound, having been unsuccessfully treated for four months. Initial situation before LPT on January 5 on the right; situation on January 16 on the left. A home care laser device was used.



Dentists on average do not prescribe much NSAIDs and steroids, yet our patients regularly use these pharmaceuticals. They work fine for short-term use but less so for long-term use according to Bjordal.²⁰ The laser dentist can reduce the use by replacing the pharmaceuticals with LPT to a high degree.²¹ The only limitation is that the pharmaceuticals can be taken for a long period at home, whereas the laser treatment is performed in the clinic. To a certain extent this limitation can be reduced by the use of home-care laser units. A consequence of an ageing European population, taking a lot of medications, is xerostomia. Dentists can recommend various gels and sprays to alleviate these problems but with a laser at hand, a rather long-term improvement of the xerostomia can be achieved. This requires an initial treatment in the clinic, followed by a period of the use of a home-care laser.^{22,23}

Acupuncture is not common in dentistry but is an option for the laser dentist. Laser acupuncture has shown similar results as needle acupuncture²⁴ and a recent meta-analysis provides proof of the efficacy of laser acupuncture.²⁵ Even the inexperienced dentists can for instance use the point P6 on the wrist to reduce the gagging reflex. The pain-free and non-invasive quality of laser acupuncture paves the way for a new kind of dental profession.

Bisphosphonate-associated osteonecrosis of the jaw (BRONJ) is an emerging dental problem with an increasing number of patients using bisphosphonates. The healing capacity of these patients is low. Surgical as well as therapeutic lasers are reported to be a valuable tool in treating these cases.^{26,27}

The above is a brief survey of indications which traditionally are not treated by dentists, but where the use of a therapeutic laser can expand the scope of dentistry. Most of the conditions described here are new for laser applications and have fairly scant scientific evidence. However, the lack of side effects of LPT still makes them a reasonable field for dentistry.

Apart from being able to do more for the patients, the laser dentist also has a possibility of treating himself, staff and family for common problems such as tennis elbow, carpal tunnel, burns etc. This poses no legal or ethical problems like treating patients for these ailments would. The legal situation will differ from country to country, but still, the side free effect of LPT opens quite new possibilities for good patient care. The case below is certainly not dentistry, but indeed a dental patient with a health problem (Figs. 2 and 3).

References can be obtained by contacting the author at jan.tuner@swipnet.se

contact

Jan Tunér
Spjutvägen 11
772 32 Grängesberg, Sweden
jan.tuner@swipnet.se
www.tuner.nu

Kurz & bündig

Obwohl die laserunterstützte Phototherapie (LPT) bereits seit mehreren Jahrzehnten angewendet wird, ist die anfängliche Skepsis der Anwender erst in den letzten Jahren einer wachsenden Anerkennung ihrer Stärken gewichen. Mittlerweile ist sie bei vielen Indikationen wie Entzündungen, Schmerz oder Ödemen eine anerkannte Behandlungsoption. Betrachtet man die ihr zugrunde liegenden Mechanismen auf Zellebene, erschließt sich das breite Anwendungsspektrum der Phototherapie. Im vorliegenden Artikel wendet sich der Autor den neuesten Erkenntnissen dieser lasergestützten Behandlung zu.

Eine moderne Herangehensweise macht sich die Eigenschaft der Phototherapie zunutze, Gewebe bereits vor einem möglichen Trauma, wie beispielsweise einem chirurgischen Eingriff, zu präkonditionieren. Gesunde Zellen reagieren schwächer auf LPT als pathogene Zellen, während die beste Zellreaktion in einer reduzierten Umgebung, also einer Umgebung mit einem niedrigen PH-Wert, stattfindet.

Eine Vielzahl der im Artikel beschriebenen Indikationen sind zwar klassischerweise nicht der Zahnmedizin zuzuordnen, können jedoch unter Verwendung eines therapeutischen Lasers zu einem zahnärztlichen Anliegen gemacht werden. Die meisten hier beschriebenen Zustände sind neu für die Laseranwendung und haben eine eher spärliche wissenschaftliche Evidenz. Da die Laser-Phototherapie jedoch keine Nebeneffekte aufweist, kann eine Integration dieser Behandlungsmöglichkeiten in die Zahnmedizin zu einer sinnvollen Erweiterung des zahnärztlichen Anwendungsspektrums beitragen. Der nebenwirkungsfreie Effekt einer LPT eröffnet völlig neue Möglichkeiten für eine erfolgreiche Patientenpflege.



Master of Science (M.Sc.) in Lasers in Dentistry

Next Start: **26th September 2016**
Aachen, Germany
4 semesters



Become part of the International Dental Elite

- Create new economic potential for your practice
- Two year career-accompanying postgraduate programme at the University of Excellence RWTH Aachen
- Combination of lectures, skill training sessions, live ops, tutorials, and practical workshops
- Internationally accepted and accredited by the German Government, the European Union, the Washington Accord and the Bologna Process
- Science-based and practice-orientated on highest national and international level
- Increased patient satisfaction: minimal contact reduced vibration and pain



**RWTH INTERNATIONAL
ACADEMY
AACHEN UNIVERSITY**

RWTH International Academy
Kackertstraße 10 | 52072 Aachen | Germany
phone +49 241 80 23543 | fax +49 241 80 92525
info@academy.rwth-aachen.de
www.academy.rwth-aachen.de

PROFESSIONAL EDUCATION PROGRAMMES

AALZ

Aachen Dental Laser Center

AALZ GmbH
Pauwelsstraße 17 | 52074 Aachen | Germany
phone +49 241 47 57 13 10 | fax +49 241 47 57 13 29
info@aalz.de
www.aalz.de