

Maxillary implant supported removable or fixed prostheses

Author: Dr Scott D. Ganz, USA

Fig. 1: The axial view provides insight into the global topography of the maxilla.

Fig. 2: The volumetric rendering aids in the inspection of the bone but does not the desired restorative position.

Figs. 3a & b: A radiopaque scanning appliance fabricated from a duplicate of a patient's existing well-fitting denture (a) allows inspection of tooth position in relation to the underlying bone (b).

"Pre-surgical prosthetic planning" can be defined as the process of accumulating diagnostic information to determine which course of treatment should be considered for the fully edentate patient. The first step in patient evaluation should include conventional periapical radiographs, panoramic radiographs, oral examination, and mounted, articulated study casts. In the completely edentulous patient it is essential for the clinician to assess several important aspects of the individual anatomical presentation including vertical dimension of occlusion, lip support, phonetics, smile line, over-jet, overbite, ridge contours, and a basic understanding of the underlying bone structures. The accumulation of preliminary data afforded by conventional diagnostics provides a foundation to prepare a course of treatment for the patient. However, if the

review of findings is based upon a two-dimensional panoramic radiograph, it may not be accurate in appreciating the true spatial positioning of vital structures such as the incisal canal, the floor of the nose, or the maxillary sinus. To fully understand each individual patient's actual bone anatomy, it is essential that clinicians adopt an innovative set of virtual, three-dimensional tools. Through the use of advanced imaging modalities new paradigms have been established that in the author's opinion will continue to redefine the process of diagnosis and treatment planning dental implant procedures for years to come. Without the application of computed tomography (CT) or lower radiation dosage cone beam computed tomography (CBCT), an understanding of the three-dimensional anatomic reality cannot be accurately determined, potentially increasing surgical and restorative complications.

The utilization of 3-D imaging modalities as part of pre-surgical prosthetic planning can take several paths. The first involves acquiring a three-dimensional scan directly, without any prior planning or ancillary appliances. The scan process can be accomplished at a local radiology centre, mobile imaging company, or via an in-office CBCT device. The scan itself can be completed within several minutes. Once the data is processed, it can be viewed on the native software of the CBCT machine itself, evaluated for potential implant receptor sites, followed by the surgical intervention, or with a third party interactive treatment planning software. A second path requires the fabrication of a radiopaque "scannographic" appliance that incorporates vital restorative infor-

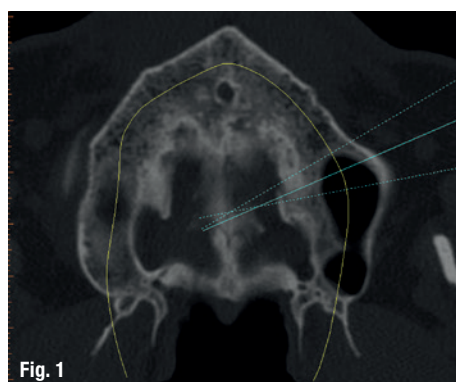


Fig. 1

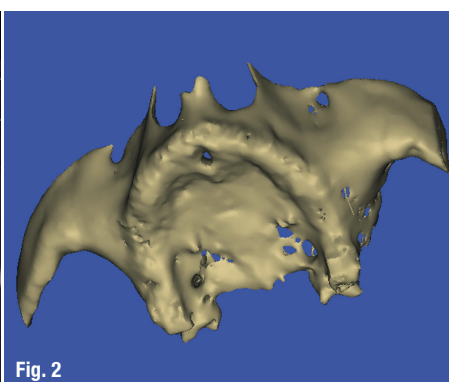


Fig. 2

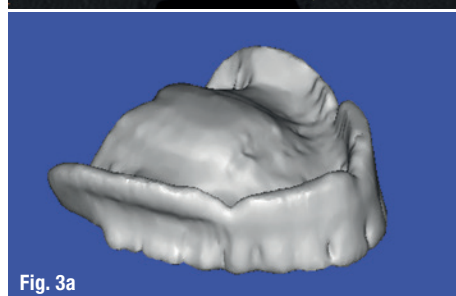
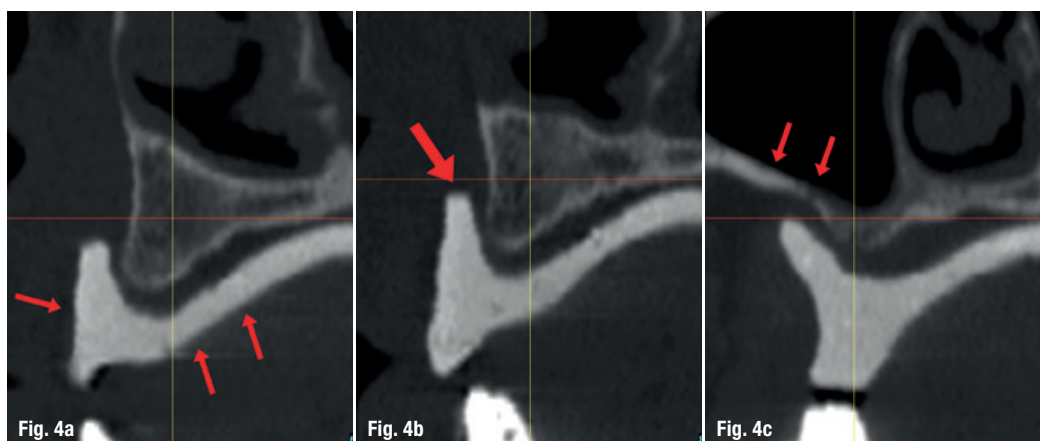


Fig. 3a

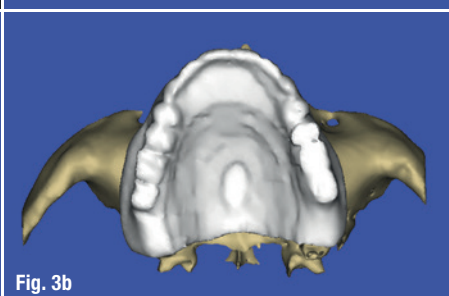

Fig. 3b



Figs. 4a–c: Cross-sectional slice reveals tooth position in relationship to the bone (a) and the extension of the labial vestibule (red arrow) (b). The relationship to the maxillary sinus is essential for planning in the posterior region, where thin cortical plate can be clearly visualized (arrow) (c).

mation that will be worn by the patient during the acquisition of the scan. In this manner, the desired tooth position can be evaluated in relation to the underlying bone and other important anatomic structures such as the maxillary sinus or the inferior alveolar nerve. Certain proprietary methods incorporate the use of fiducial markers to help with the registration process for planning based directly upon the restorative needs for the patient.

The use of interactive treatment planning has expanded dramatically in the past ten years as computing power has increased exponentially. As defined by the author, guided surgery can be divided into three distinct categories once a "virtual" plan has been established based on 3-D scan diagnosis (Ganz-Rinaldi Classification of Guided Implant Surgery Protocols). The first allows the information to be assessed, providing important information to the clinician who will perform the surgical intervention free-hand based upon the software plan, termed "Diagnostic-Freehand". The second category involves the fabrication of a surgical guide or template that is remotely constructed from the digital plan usually through rapid prototyping or stereolithography, CAD/CAM, or laboratory fabricated, termed CT-derived "Template-Assisted". The drilling process is started and can be completed within the template helping to control trajectory and depth with the proper instrumentation. The third category requires a specific template design that allows for accurate

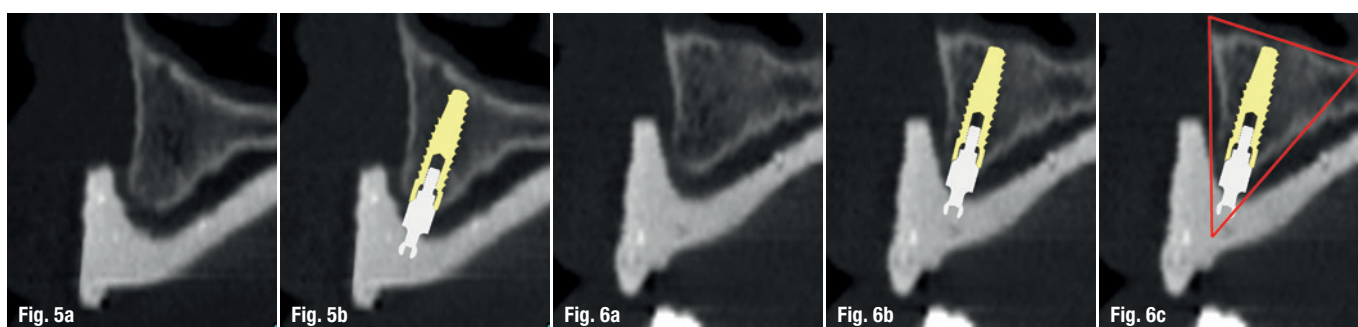
drilling and osteotomy preparation, and with the proper manufacturer-specific carriers the implants can then be accurately delivered through the template, termed, "Full Template Guidance". The use of advanced imaging modalities for pre-surgical prosthetic planning is essential for any type of implant surgical and restorative intervention, from the single tooth, multiple tooth restoration, full arch fixed and removable over-denture reconstruction. However, it is the correct use of three-dimensional tools that provides clinicians with the power to diagnose and treatment plan with the highest degree of acuity and accuracy.

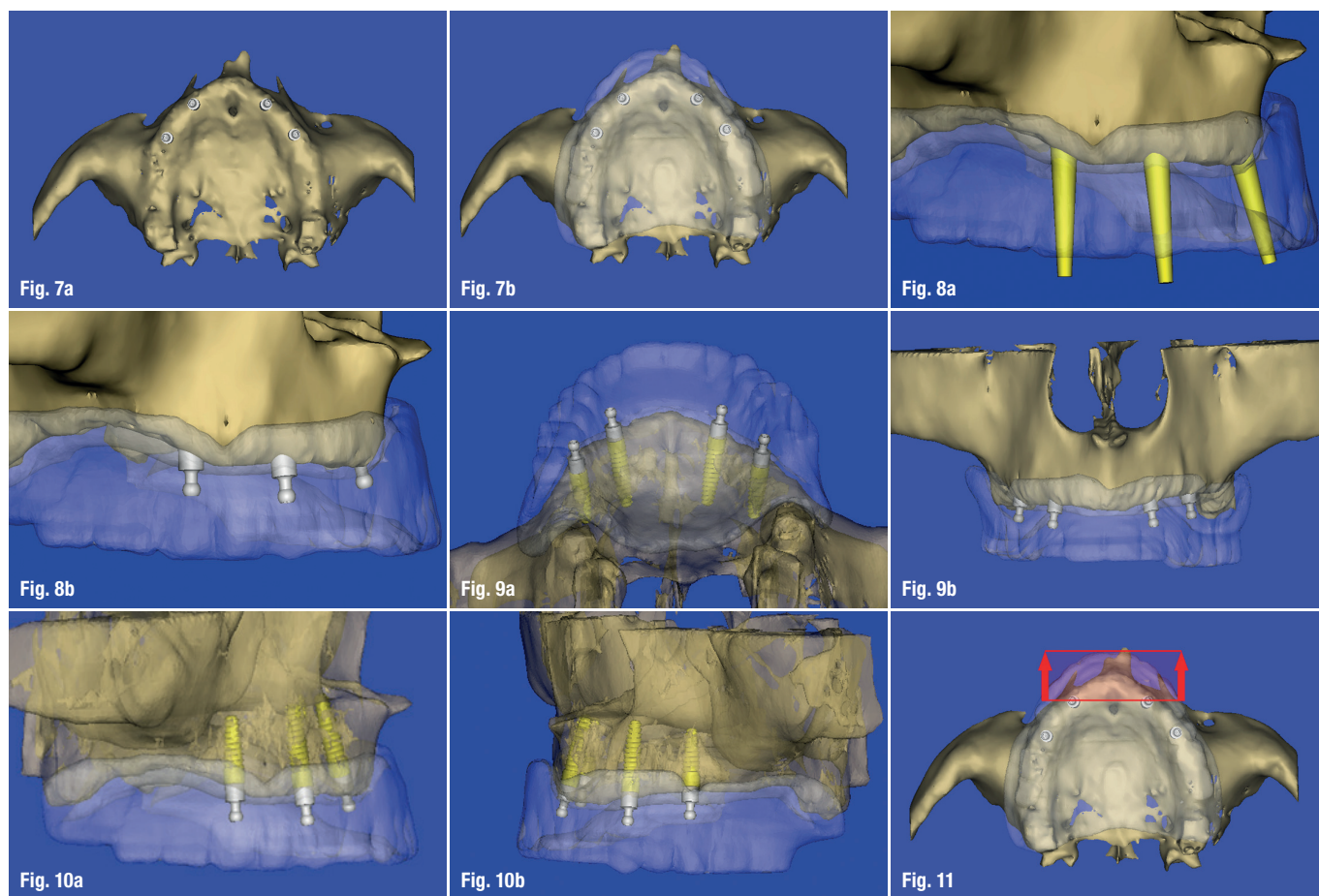
3-D Planning Concepts: Full Arch Maxillary Overdenture

Due to anatomical variations related to the maxillary sinus, the floor of the nose, the incisal canal, the facial trajectory of the anterior segment, thin cortical plates, and diminished overall bone density when compared to the mandible, the completely edentate maxilla offers additional diagnostic challenges for clinicians. The axial view provides insight into the global topography of the maxilla (Fig. 1). The position of the incisal canal can be visualized, along with thin facial and palatal cortical plates. The volumetric rendering aids in the inspection of the bone, but does not offer any information regarding tooth or ultimate restorative position (Fig. 2). In order to achieve the concept of "true restoratively driven implant dentistry" pre-surgical

Figs. 5a & b: Evaluating a potential receptor site within the cross-sectional view (Slice 63) (a). The positioning of the implant(s) need to fall within the envelope of the teeth (b).

Figs. 6a–c: The cross-sectional image reveals a potential receptor site (a); the realistic implant and abutment simulation (b); the author's preference places the implant within a defined zone of available bone defined as the "Triangle of Bone" (TOB) that also acts to relate implant position to the restorative outcome (c).





Figs. 7a & b: The occlusal view of the volumetric rendering aids in the implant-to-implant positioning within the bone (a). Superimposing a translucent scannographic template over the maxilla provides the information to position implants within the restorative envelope (b).

Figs. 8a & b: Use of "selective transparency" with abutment extensions above the occlusal plane (a). Ball abutments positioned at the proper tissue cuff height (b).

Figs. 9a & b: Rotating the views help position implants where they will best support the removable prosthesis.

Figs. 10a & b: Selective transparency allows the realistic implants and ball abutments to be seen through the prosthesis and the maxillary bone.

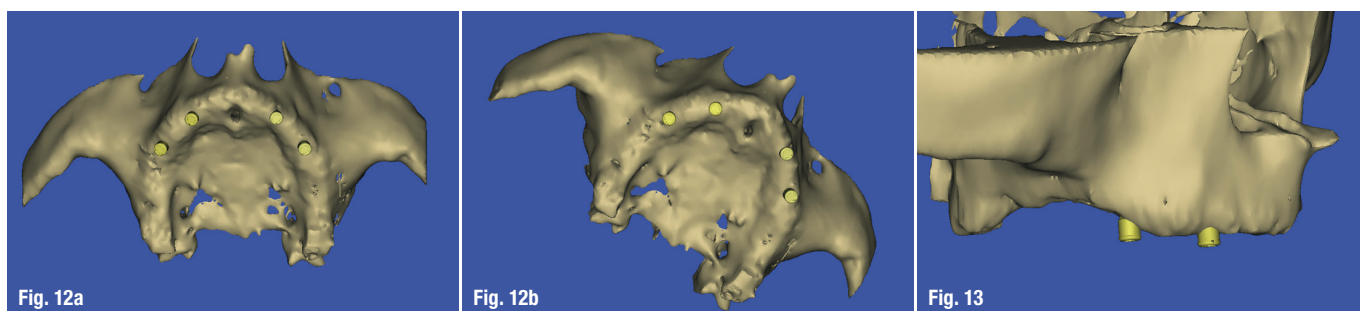
Fig. 11: The distance between the two anterior implants and the maxillary incisor teeth (red arrows) represents a cantilever that could result in tipping of the denture.

prosthetic planning should start prior to any scan being taken. A scanning appliance can be fabricated from a duplicate of a patient's existing well-fitting denture, or a new diagnostic set-up which positions the teeth at the ideal vertical dimension of occlusion, centric relation, and functional/aesthetic components (Fig. 3a). The patient wears the scannographic appliance during the scan, ideally held in place with a pre-determined bite registration to minimize movement. The scan reconstruction will then contain both the tooth position and the underlying bone (Fig. 3b).

The combination of the anatomical scan data with the radiopaque template allows unprecedented diagnostic potential. The template reveals the tooth position (red arrows) in relationship to the underlying bone in the cross-sectional slice (Fig. 4a). The thin cortical plates can be clearly visualized, along with the extension of the labial vestibule (red arrow, Fig. 4b). The relationship to the maxillary sinus is important when deciding if implants might be an option in the posterior region (Fig. 4c). In this example the pneumatization of the sinus has resulted in extremely thin lateral cortical plate (see red arrows). The radiopaque template is helpful when evaluating other receptor sites, and positioning a simulated implant within the

cross-sectional view (Slice 63, Fig. 5a). For an over-denture application the positioning of implants need to fall within the envelope of the teeth, and it is even more practical to visualize the abutments that might be utilized (Fig. 5b). For this example a realistic stock "ball type" abutment was utilized on the virtual realistic implant. In order to provide some guidance, it is the author's preference to place the implant within a defined zone of available bone (Figs. 6a & b). This zone has been previously defined as the "Triangle of Bone" (TOB) that also acts as a decision tree to connect the implant placement to the restorative outcome (Fig. 6c). Positioning the implant within the zone of the TOB, or actually bisecting the triangle, allows for the most bone volume to surround the implant. Following this formula, the implant and abutment will be positioned in a favourable restorative position.

Further inspection through the utilization of additional views can be extremely enlightening with regard to the final positioning of the implants. The occlusal view of the volumetric reconstruction aids in the implant-to-implant positioning within the bone (Fig. 7a). However, without a complete understanding of the tooth position, the implants may not be ideally located based upon the prosthetic plan.



Superimposing a translucent scannographic template over the maxilla provides the important information to position the implants within the restorative envelope (Fig. 7b). The prosthesis design can be evaluated to determine whether to fabricate a complete denture that would extend to incorporate a conventional post-palatal seal, or an open-palate horseshoe type prosthesis. To aid in the final positioning, it is helpful to visualize the outline of the occlusion using the author's concept of "selective transparency", and extend the abutments above the occlusal plane (Fig. 8a). "Selective transparency" is a software tool which can help separate one anatomical structure from another by adjusting the opacity of the various objects. Once the implants are placed, the ball abutments can then be positioned at the proper tissue cuff height (Fig. 8b). Rotating the views can substantiate the plan to place the implants where they will be support the removable prosthesis (Figs. 9a & b).

It is important to assess the clearance within the denture to allow for sufficient thickness of acrylic within the over-denture abutment housing avoiding potential fracture of the prosthesis. This "prosthetic space" requirement may be different depending upon the type of attachment used. Using the power of digital technology and selective transparency, the realistic implant and ball abutment can be seen through the prosthesis and the underlying bone (Figs. 10a & b). These illustrations reveal that the two right implants are parallel, while the left implants are seen to follow the natural trajectory of the maxillary alveolus (a), and the reverse is true after rotating the maxillary volumetric reconstruction to view the left side (b). Finally, when considering the mechanical forces of mastication and movement of the prosthesis, a line can be drawn between the two most anterior implants that establishes the potential for rotation in the occlusal plane (Fig. 11). A second line can be drawn at the most anterior aspect of the maxillary teeth. The distance

between the two anterior implants and the maxillary incisor teeth (red arrows) represents a cantilever that could result in tipping of the denture when the patient bites into an apple.

The ball-abutment is only one potential stock abutment choice for an over-denture application. Another widely used abutment is the Locator attachment (Zest Anchors). The use of realistic Locator attachments allows for a precise understanding of the implant-to-implant relationship, and spacing around the arch which is necessary to gain maximum retention of the prosthesis to resist dislodgement during mastication (Figs. 12a & b). In addition, the utilization of virtual abutments aids in determining the correct tissue cuff heights of the abutments above the bone, and through the soft tissue (Fig. 13). The vertical distance can be evaluated within the framework of the prosthetic design (Fig. 14a). The new digital tools allow for new paradigms to be established assessing the relationship of the implant position, abutment position, and prosthesis prior to the scalpel ever touching the patient. Crown-to-root ratios and the trajectory of the implant-abutment complex can be visualized within the virtual plan, providing valuable surgical and restorative information during the planning phase (Fig. 14b).

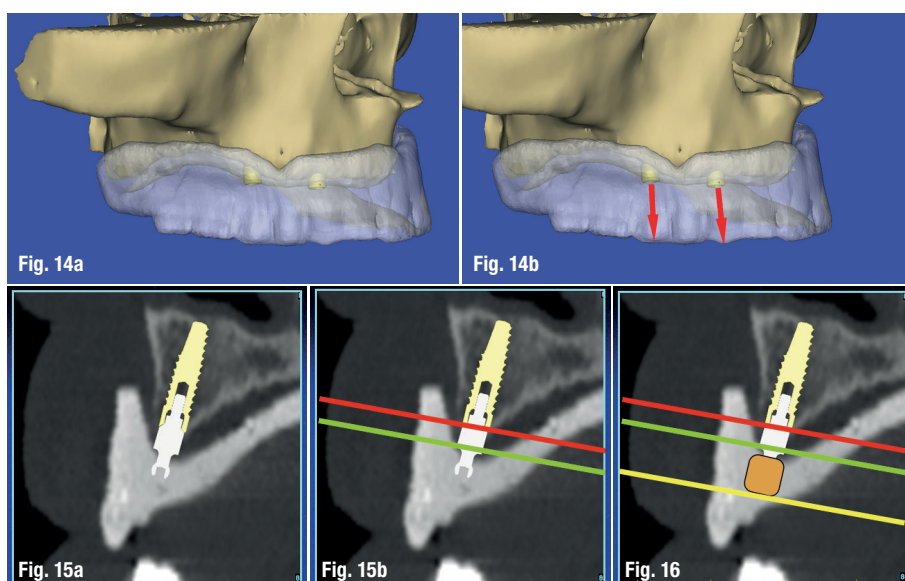
Figs. 12a & b: The use of realistic attachments allows for implant-to-implant positioning around the arch necessary to gain maximum retention and resistance of the prosthesis to dislodgement during mastication.

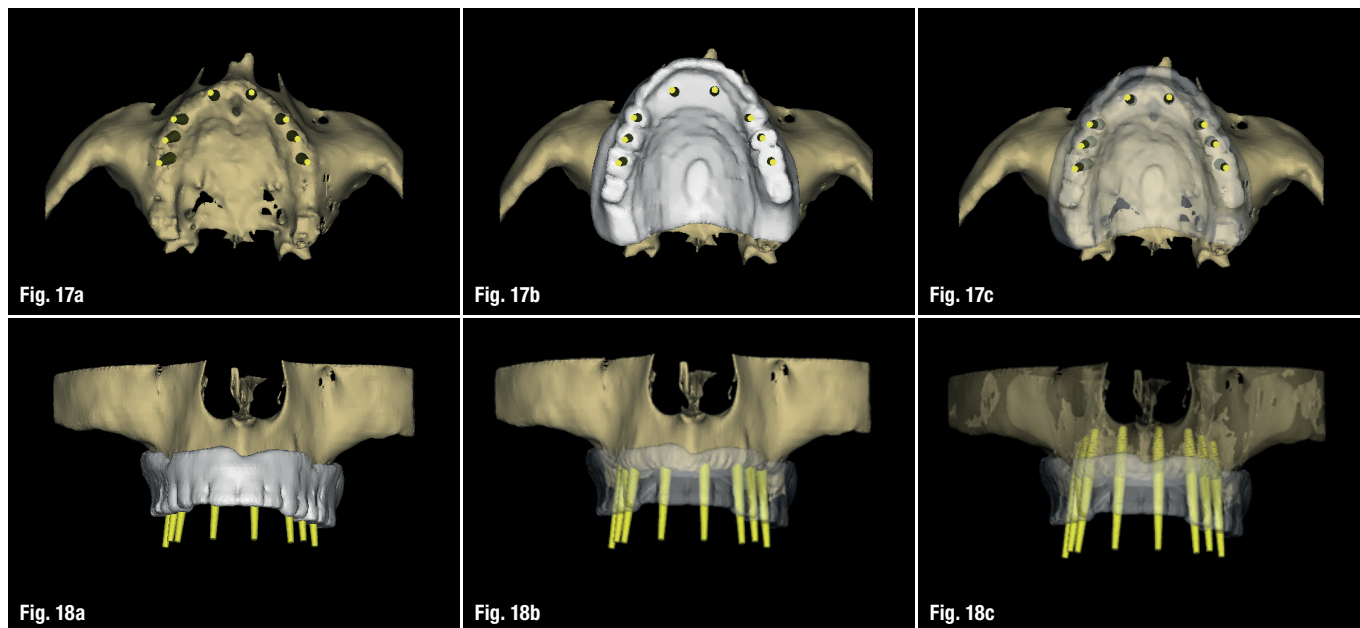
Fig. 13: Utilization of virtual abutments aids in determining the correct tissue cuff heights of the abutments above the bone, and through the soft tissue.

Figs. 14a & b: The vertical distance can be evaluated within the prosthetic design (a), crown-to-root ratios, and the trajectory of the implant-abutment complex can be visualized within the virtual plan.

Figs. 15a & b: The top of the implant (red line) serves as the foundation for the abutment at a specific tissue cuff height (green line) (a); the metal housing represented in gold also has a vertical component (yellow line) (b).

Fig. 16: Once the implant position has been confirmed, the software will generate the virtual design of the template.





Figs. 17a–c: Eight implants positioned to support a fixed restoration **(a)** to fit within the framework of the desired tooth position **(b)**; using “selective transparency” the underlying bone can be visualized **(c)**.

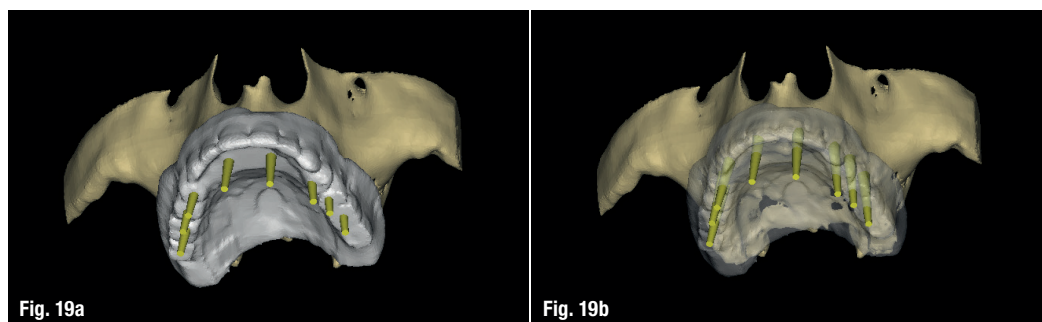
Figs. 18a–c: Frontal view of the scanning template with yellow abutment projections seen above the occlusal plane **(a)**; semi-transparent scanning template **(b)**; and all three objects translucent to visualize the position of the implants within the bone **(c)**.

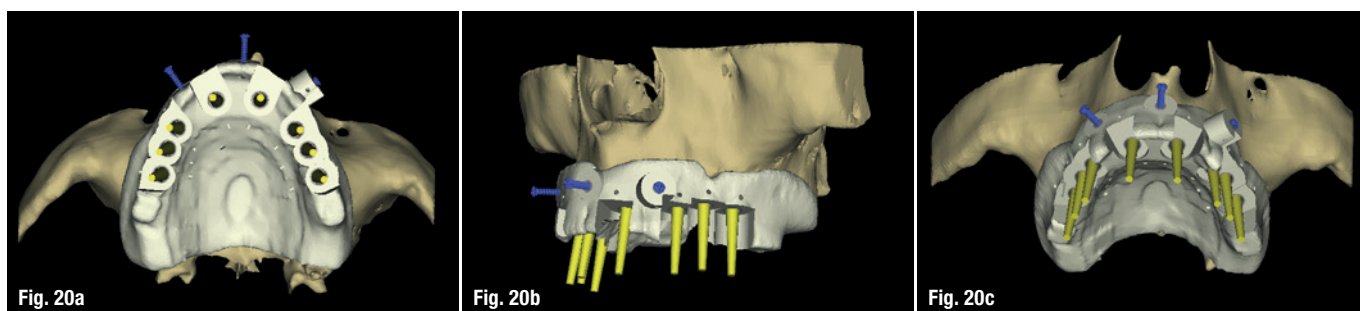
In addition to the axial, panoramic, and three-dimensional reconstructed volume, the importance of the cross-sectional image is critical to fully appreciate the relationship between the implant position within the bone, and the emergence through the tooth. One area that has not been emphasized however, is the ability to determine the prosthetic space required for the abutment as it relates to the thickness of soft tissue supporting the overdenture (Fig. 15a). The realistic ball abutment can be clearly visualized sitting on the coronal aspect of the implant (red line), and the tissue cuff height of the abutment (green line). One component that is not easy to determine is the metal housing that will be processed within the denture. This component part is not yet available within the software libraries to the author's present knowledge. Therefore an approximation was digitally represented (gold), so that the extra height can be visualized (yellow line), revealing the thin palatal aspect of the overdenture (Fig. 15b). Once the virtual plan has been established a surgical template can be designed by the software and then fabricated through 3-D printing, stereolithography, or a CAD/CAM process to assist in the placement of the implants within the anticipated restorative needs of the patient (Fig. 16).

3-D Planning Concepts: Full Arch Maxillary Fixed Prosthesis

There are few differences between 3-D planning concepts for an overdenture prosthetic design, or a fixed prosthetic rehabilitation supported by implants. All aspects of the patient's bone and soft tissue anatomy must be carefully evaluated. After a proper assessment of the available bone, key implant positions are identified, and simulated within the 3-D reconstructed volume as seen in Figure 17a. However, it is important to once again evaluate the potential implant receptor sites based upon the envelope of the occlusion (Fig. 17b). Using “selective transparency” helps to provide an enhanced perspective of how the implant abutment projections (yellow) are spaced within the desired restoration (Fig. 17c). The frontal view clearly illustrates the importance of the implant abutment projections, revealing for this example a nearly parallel placement of the implants (Figs. 18a & b). “Selective transparency” can be applied to multiple structures, to help visualize the entire complex of the implant, abutment projection, radiopaque template, and the underlying bone (Fig. 18c). By rotating the 3-D reconstructed volumes, it is apparent

Fig. 19a & b: Another 3-D view showing the emergence of the abutment projections through the scanning template.





Figs. 20a–c: The template design revealing the guide tubes (a); three blue fixation pins (b); and the entire complex on the 3-D reconstructed volume (c).

how powerful these interactive software tools can be (Figs. 19a & b). Once the final positions of the implants are confirmed for the edentulous presentation, a mucosal-supported template can be designed and fabricated through 3-D printing, stereolithography, or a CAD/CAM process. The mucosal-supported template should be fixated to the bone, to insure accuracy of the drilling sequence. The template with the blue screws can be visualized in Figures 20a–c.

Conclusion

The advent of complete denture fabrication evolved into the adoption of over-denture concepts for both natural and implant supported restorations. Conventional prosthodontic protocols were developed to aid in the diagnosis, treatment planning, and laboratory phase of the reconstruction. These included conventional periapical radiographs, panoramic radiographs, oral examination, and mounted, articulated study casts. The clinician was then expected to assess several important aspects of the patient's anatomical presentation including vertical dimension of occlusion, lip support, phonetics, smile line, overjet, overbite, ridge contours, and a basic understanding of the underlying bone structures. The accumulation of preliminary data afforded by conventional diagnostics provided a foundation to prepare a course of treatment for the patient. However, the conventional review of findings was based upon a two-dimensional assessment of the actual patient's bone anatomy. To fully understand each individual patient's presentation, this article provided clinicians with an appreciation of various innovative virtual, three-dimensional tools based upon the use of advanced three dimensional imaging modalities for both removable and fixed prosthetic treatment alternatives.

The application of CBCT and interactive treatment planning software, empowers clinicians with an accurate understanding of the three-dimensional anatomic reality for our patients as an aid in providing state-of-the-art treatment. Implants will be better positioned, with fewer surgical and

restorative complications, and reduced laboratory remakes based upon these improved diagnostic tools. The benefits will enable clinicians to better understand the relationship between patient anatomy and the desired restorative outcomes, in the process of achieving true restorative driven implant reconstruction. The ability to utilize digital imaging and treatment planning technology is now within the reach of most clinicians through the various software products that are on the market. In addition there are many third party outlets through internet portals that enable clinicians to upload their DICOM data for evaluation, processing, treatment planning, and even surgical template fabrication without actually owning the planning software. New paradigms have been established that in the author's opinion will continue to redefine the process of diagnosis and treatment planning dental implant procedures, both removable and fixed alternatives for years to come. Please remember though that the "template is only as good as the plan".

About the author

Dr Scott D. Ganz

maintains a private practice for prosthodontics, maxillofacial prosthetics and implant dentistry in Fort Lee, New Jersey, USA. He has served as President of the NJ Section of the American College of Prosthodontists and the Computer Aided Implantology Academy (CAI). He has served as President of the New Jersey Section of the American College of Prosthodontists and of the Computer Aided Implantology Academy.

Dr Ganz delivers presentations worldwide on both the surgical and restorative phases of implant dentistry, and has published extensively on these topics. He is considered one of America's leading experts in the evolution of computer utilisation and interactive software for diagnostic and treatment planning applications using CT and newer-generation CBCT imaging modalities.