

Bimaxillary Rehabilitation

Implant-supported zircon-ceramic bridges

Author: OA Dr Björn Dziedo, CA Prof. Dr Dr Stefan Schermer & Dr Elena Mihalcioiu, Germany

Introduction

In September 2014, a dentist-anxious 63-year-old patient from abroad presented with a relatively limited time window and the desire for a fixed, metal-free biological dental restoration in our clinic. The case was discussed in the interdisciplinary team of surgery, prosthodontics, dental technician and anaesthesiology and planned with the patient in our international office as a stationary patient for one-stage full-ceramic treatment case.

workplace need an extremely fast therapy with visible milestones. Experienced surgeons and prosthodontists work hand-in-hand from planning the surgery up until aftercare. The lead prosthodontist requires an extremely experienced and skilled dental technician at his side.

History—clinical examination—consultation

Besides a well-adjusted diabetes mellitus and coronal predisposition after successful cardiac surgery, the patient was well, his medical history without pathological findings. Dental inspection revealed massive horizontal ridge atrophy in the lower jaw and an extensive horizontal and vertical atrophy of the upper jaw. The removable clasp denture would

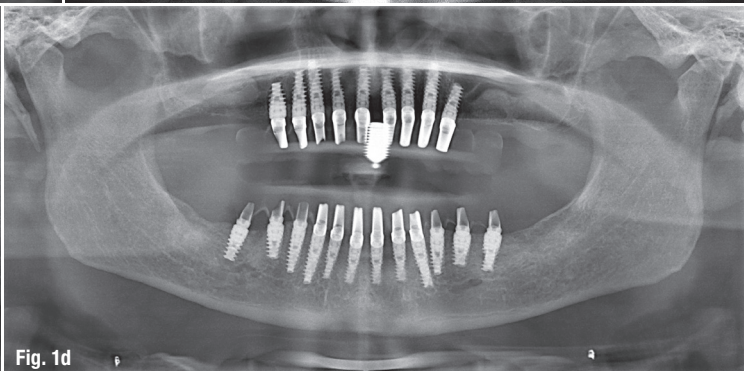
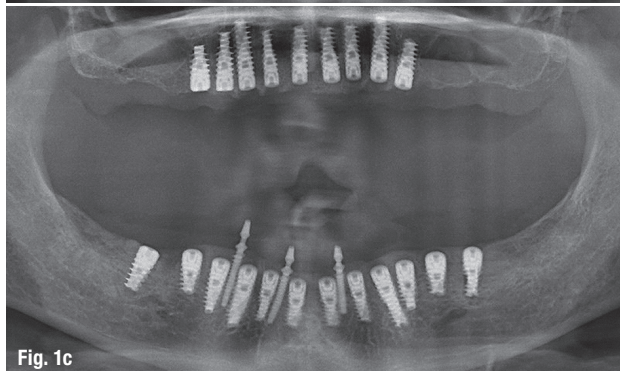
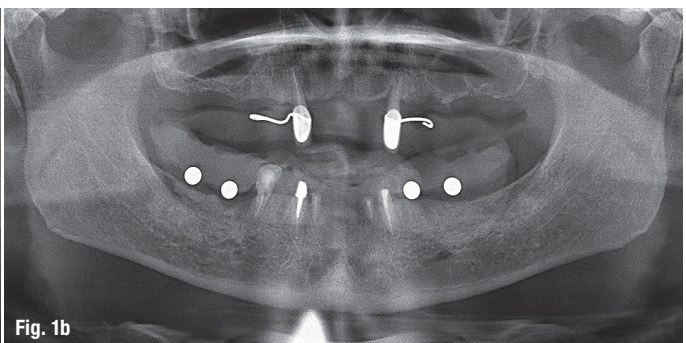
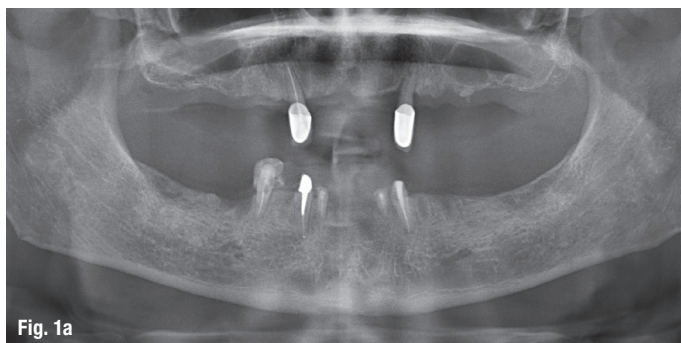
Fig. 1a: OPG initial findings.

Fig. 1b: OPG with reference spheres.

Fig. 1c: OPG postoperative.

Fig. 1d: Control-OPG for evaluation of the fitting of the abutments, the mock-up is seated maxillary, including the radiopaque pin for joint-registration.

The International Office personnel took care of the administrative procedures, visa and travel issues and tried to make the stay optimal here for everyone involved. Foreign patients and anxious patients, as well as patients with a strong involvement into their



This is



Very smart,
very simple,
very iSy.



iSy. The intelligent system.

iSy is the sensible, lean implant system that ensures cost-efficient implant treatment whilst still offering reliable CAMLOG quality. Whether digital or conventional, whether transgingival or subgingival: thanks to its intelligent design, the implant sets and the three treatment models, iSy is versatile and flexible – adding real added value to your daily practice by its easy handling and efficient workflow. And all this at an unbeatable cost-benefit ratio. Have a look and see for yourself:

www.isy-implant.com

Fig. 2a: Situation after implant exposure after two weeks.

Fig. 2b: Impression with individualised foil tray with additional retentions.

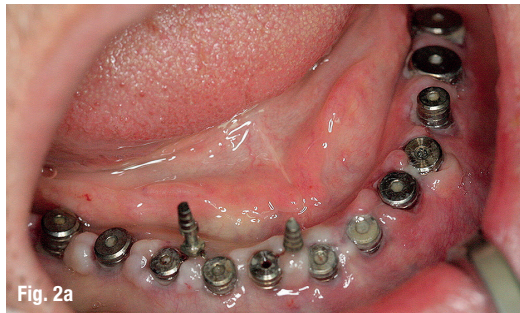

Fig. 2a

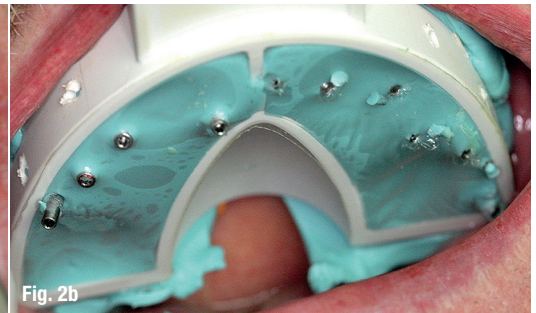


Fig. 2b

have compromised the patient's quality of life significantly, the remaining teeth would have been weakened and bone loss accelerated. In the mandible, an insufficient temporary bridge of 33–45 had been established. Extraorally, a negative lip line, the typical symptom of a vertical loss of occlusal plane, was detected. A CMD-test, in which the maximum jaw movements and symmetries were evaluated at opening and closing, revealed an age-appropriate finding with no evidence of pathological changes of the temporomandibular joints. Oral inspection revealed residual dentition not worth retaining with a mobility of 2 to 3.

To estimate the risk for implant insertion by periodontal pathological bacteria, a bacteria risk test and Interleukin-1 test was taken from gingival fluid on all teeth using sterile paper points. The panoramic X-ray (Fig. 1a) confirms the already known clinical dental report. Neither for the surgery, nor for an advanced treatment plan, digital volume tomography would optimise the final result and was therefore not performed. In the posterior region of the maxilla, due to massive horizontal and vertical bone resorption, implantation is not possible without expanded augmentation on both sides. The lower jaw, however, provides sufficient vertical bone volume, so we can fulfil the desire of the patient of a fully loaded and functional lower jaw by inserting implants and horizontal reconstruction using alloplastic synthetic bone. In the upper jaw, nine implants were planned. To determine the possible implant length on OPG, a 5 mm reference sphere was used (Fig. 1b). The bacterial diagnosis showed a greatly increased bacterial count (> 1 million) of *denticola forsythus* and *treponema denticola*.

Preprosthetic treatment and surgery

In order to reduce the previously identified bacterial load, the patient started two days before surgery with the antibiotic treatment by Clindamycin per os and a professional dental cleaning. When selecting the antibiotic, we followed the recommendation of the laboratory test results, which recommended the use of Metronidazole or Clindamycin. We see Metro-

nidazole as much more prone to possible side effects. We especially followed the recommendations of the American Heart Association with Clindamycin. We have very good experiences with Clindamycin due to its bone penetration ratio. The patient's own medication was maintained.

Impressions and bite registration followed for the production of removable temporary prostheses. In general anaesthesia, all teeth were extracted, followed by the excision of granulation tissue. In the upper jaw, bilateral external sinus lifts were performed with accretion of hydroxyapatite (Ostim®, Heraeus-Kulzer) and membrane (Cerasorb®, Curasan) and a total of nine implants (Alpha bio TEC) were inserted. In the lower jaw, twelve implants and three temporary implants were inserted to stabilise the prosthesis (immediate provisory implant, Nobel Biocare). Bone edges were smoothed, bone defects filled with alloplastic bone substitute material (Ostim®, Heraeus-Kulzer). Tension-free wound closure and the fitting of the temporary prostheses ended the surgery. The patient received inpatient care in the hospital. The postoperative panoramic X-ray was inconspicuous (Fig. 1c). Postoperatively, in addition to the antibiotic, ibuprofen and nose decongestants (Otriven®) were prescribed. Eleven days postoperatively, sutures were removed. All wounds were completely closed, which should allow a good prognosis for hard and soft tissue consolidation. The patient was in a good general condition.

Implant exposure followed four months after implantation. When exposing, the temporary implant in region 32 was extracted due to lack of space.

Implant imprints

After two weeks of healing time after the exposure, the patient presented a well-healed gingiva (Fig. 2a). The prosthesis on the two temporary implants in the lower jaw have fulfilled their function as stabilisers, now they had to be removed before the upcoming impression. The resulting defect was filled with alloplastic bone substitute material. The open impression (pick-up technique) of many close-set implants with laboratory-manufactured individual impression trays is difficult from our perspective.

YES!



I WANT IMPLANTS

MADE BY DENTAURUM.

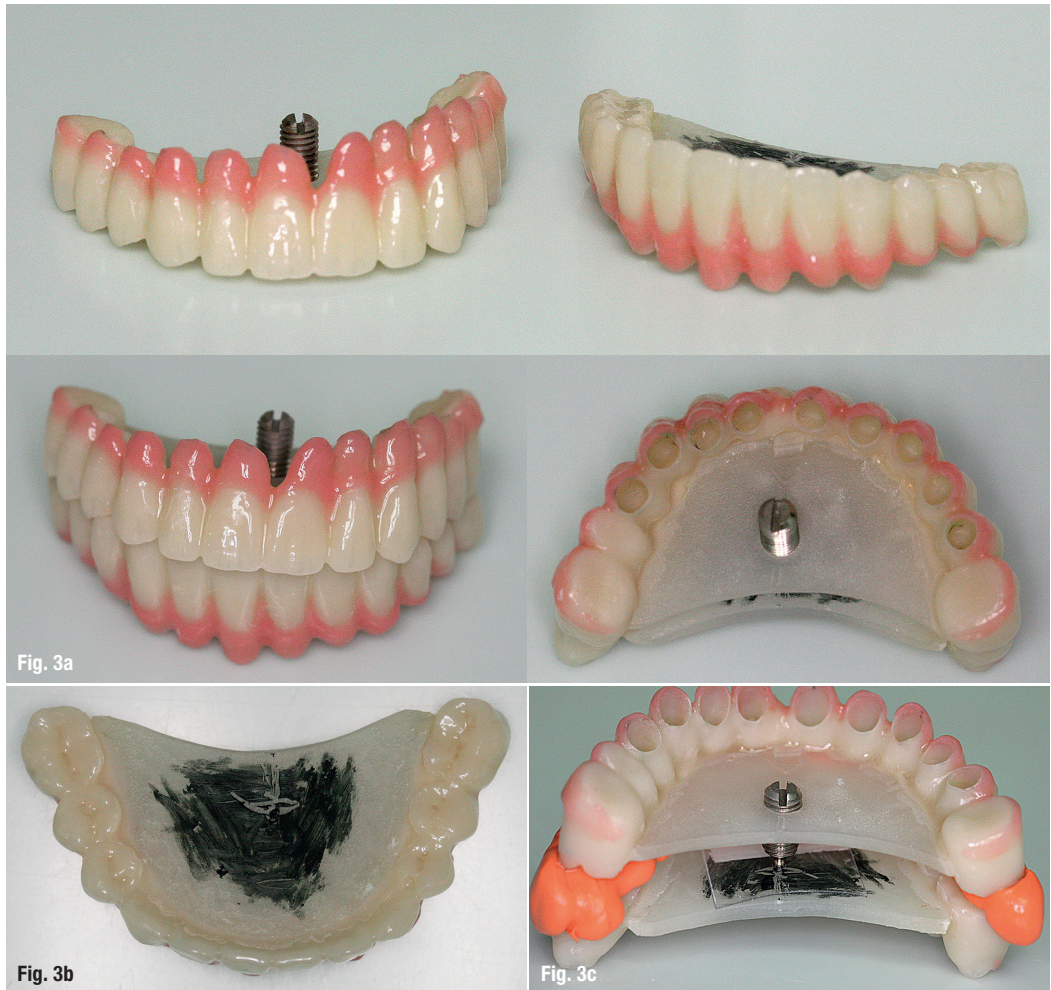More than 20 years of expertise, reliability
and innovation in implantology – worldwide.
Say yes!



Fig. 3a: "PÜR"-mock-up bridges with pin registration set.

Fig. 3b: Visualising the joint movements on the mandibular.

Fig. 3c: Bite encryption of the pin registration plate.

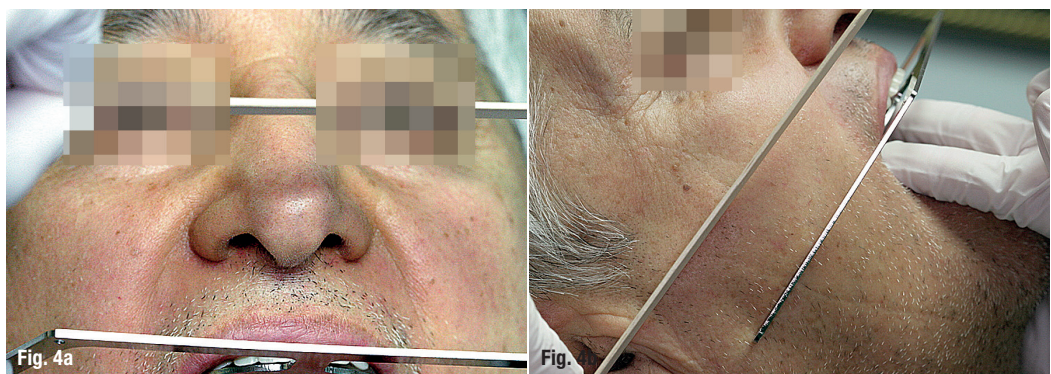

On the one hand, the technician must guess the implant orientation correctly, on the other hand, sometimes the impression material overflows through the impression tray holes due to the pressure exercised while taking the impression. A possibly necessary reworking on the individual tray due to the divergence of implant positions can adversely affect stability, which could lead to breakage during impression taking. That is why we only use the Miratray® impression tray (Hager&Werken) in implant-supported dentures. The penetrable foil seal prevents overflow of the impression material (Fig. 2b). Thus, incorrect positioning of the tray is

almost impossible. The plastic tray can be reworked for patient comfort at the edges and individualised. In this case, retentions can be drilled for the impression material (Fig. 2b). The double-impression technique itself is carried out in a mixing method in combination of high and low viscous silicone. This is followed by the selection of the desired tooth shade. The recommendation of age-appropriate tooth colour shade was refused by the patient and he opted for the VITA colour A1. The gum colour is determined using a gum-colour ring (GC initial gum set) in the presence of the dental technician.

Fig. 4a: Parallelism check between bipupullary line and occlusal plane.

Fig. 4b: Parallelism check between occlusal plane and Camper's plane.



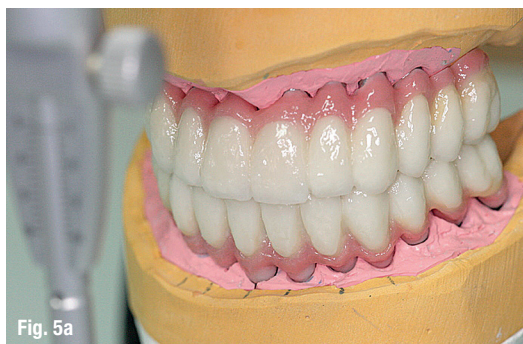

Fig. 5a

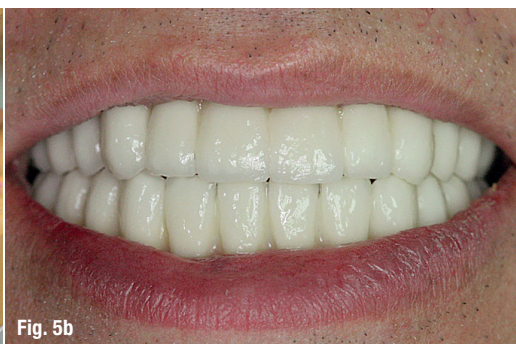

Fig. 5b

Fig. 5a: Bisque ceramic in articulator.

Fig. 5b: Bisque ceramic *in vivo*.

(Aesthetic) Fitting

For large circular fixed restorations, a fully sculpted mock-up was made of model plastic in the desired tooth colour and possible tooth shape (Figs. 3a–c). This prosthetic feature served as a trial run, as a quality transition and a rehabilitation supply ("PÜR"-mock-up Berlin clinic model, Figs. 3a–c) and was originally developed by us specifically for extensive supplies, cases of this kind, and cases with total atrophic alveolar ridges so we could check the fit, the bite and aesthetic wishes of the patient for the future dentures.

In this step, zirconium is not yet milled. If the mock-up does not fit, a second check-up impression can be made simply via the individual implant abutments for the production of a new model for the master technician. The abutments were screwed in with 20 N/cm in accordance to the agreement with the master dental technician and the manufacturer. The seat of the abutments would be evaluated after transferring by using a transfer key on the panoramic X-ray (Fig. 1d). The mock-up was used for the aesthetic check before the ceramic is made. Tooth colour, teeth shape and placing give the patients a real idea about the result. Change requests can easily be modified in the plastic denture. Furthermore, and most importantly for the patients' requirements, the "PÜR"-mock-up serves to hold off the moveable soft tissue, avoiding any need of a repeated exposure of the implants from the newly-grown tissue in the distal lower jaw under local anaesthesia.

The next step was the evaluation of the parallelism of the occlusal plane with the camper's plane and the bipillary line using the Candulor bite fork (American Dental Systems®, Figs. 4a & b). The mock-up was supplied with a registry plate made in the laboratory (Figs. 3a–c). After successful try-in and aesthetic fitting, the functional jaw movement registration via supporting pin registry was done (Fig. 3b) with subsequent bite encryption by registration silicone (Fig. 3c). In the present case, the patient had found his habitual occlusal position. If he had not done so, we would have performed an additional

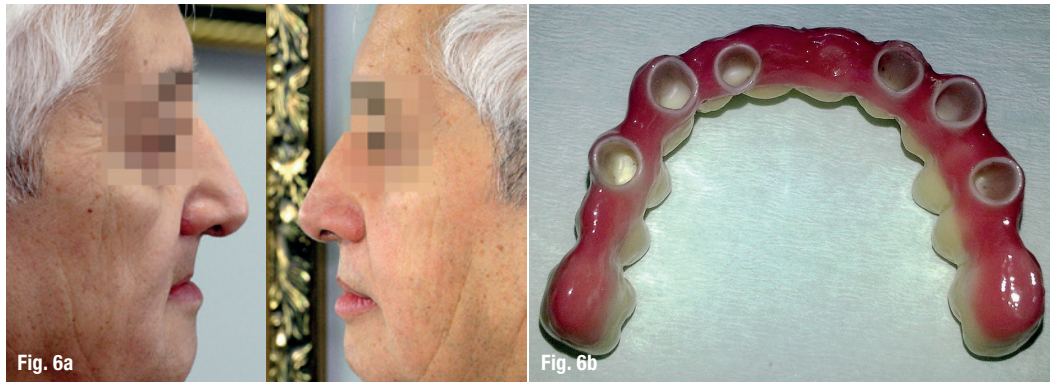temporomandibular joint movement registration using software-supported evaluation (zebris JMA system).

In the laboratory, the zirconium framework was milled and the veneering ceramics were applied according to the wish of the patient. Thus, the next step was the try-in of the bisque ceramic, which was made two days later (Figs. 5a & b). Usually, we advise a few days testing time for the patient to give us a feedback about aesthetics and function of the "PÜR"-mock-up. Due to the quite large phenotypic changes of patients, the testing period is both psychologically and functionally informative. The mock-up also serves as temporary denture and the patient can "practise" his new bite situation. From our point of view, this step significantly reduces the risk of ceramics chipping by habitual improper load or measures sensation induced malocclusion of definitive restorations. By the exclusively implant-supported tooth replacement, the neural feedback of the periodontium is missing. The absence of tactility specifically increases the risk of fracture of ceramic and can lead to traumata of the hard and soft tissue together with pain sensations. Since the patient comes from abroad and wanted to be supplied as soon as possible, the testing period was skipped, which was acceptable due to the good compliance and uncomplicated occlusal conditions of the patient. Practicing the new bite and education about the necessity of careful biting in the first days after placing the dentures were therefore important and crucial for the success of the treatment.

Bisque ceramic try-in

The information supplied by the mock-up was then incorporated into the planning of the zirconium/ceramic work and implemented by the dental technician. The data, which had already been entered to the computer by model scan, were now transmitted to the CNC 5-axis milling machine (Zenotec select hybrid, Wieland Dental), and milled from a solid zirconia blank, minus the space for the veneering ceramic that would be topped up manually by the master dental technician.

Fig. 6a: Profile of the left side without and the right side with bridges.
Fig. 6b: Convex basis of the bridge.



The surface texture and translucency of the ceramics compared to the plastic mock-up surprised the patient and increased his anticipation for the finished work (Fig. 5a & b). After tightening the abutment with a torque wrench to 20 N/cm, both the maxillary and the mandibular bridges were placed into their end position without any tension. Even after the use of pin registration, the bite is unusual for the patient and should be guided by the practitioner. Only after the patient independently reproducible has found the "new" bite, the occlusal examination by Shimstock film (Coltène®) can take place. Deflective occlusal contacts can be removed with a dental drill under water cooling. Bite registra-

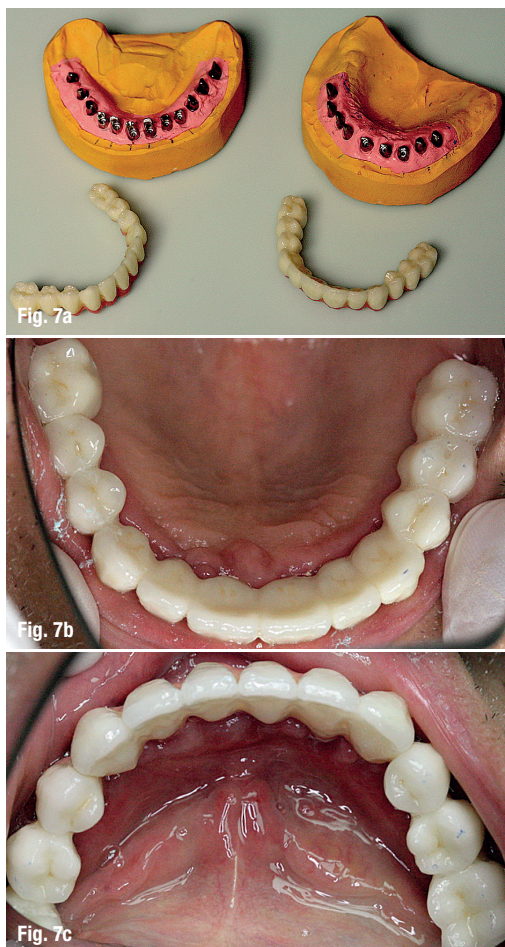
tion serves as visual check for all uniform occlusal contacts.

The profile without and with bridges is shown in figure 6a. It is plain to see how the upper lip seems voluminous, caused by lip support through the maxillary anterior teeth. At the ceramic try-in, oral hygiene was practised together with the patient using interdental brushes (TePe®). Close gap areas were identified interdental or between the ceramic and gingiva and expanded in the laboratory. It is always important to ensure that the basis of the dentures is designed convexly by the dental technician as represented in figure 6b by the bridge of another patient. The hassle-free oral hygiene must be ensured, specifically for older patients with partly limited motor skills.

Completion

Already one day after bisque ceramic try-in, the bridges were finished and inserted (Figs. 7a-c). After removal of gingiva formers, the gum was inflammation-free. The inner edge of the implant was filled with CHX gel and screwed in the abutments with 30N/cm according to the manufacturer's recommendations. Due to the multiple transmitting of the abutments in the previous steps, we used new abutment screws for the final screw, the abutments were cleaned with alcohol and sealed with plastic pellets and Cavit. The fit of the bridges was controlled again. The static and dynamic occlusion was bilaterally sufficient in the posterior area. Front and canines had no static occlusion. The all-ceramic upper and lower bridges were cemented with temp bond NE (Kerr™). Studies prove the good sealing and good biocompatibility of zinc-oxide non-Eugenol cements and recommend it for implant crowns and compounds.⁵ The number of abutments did not give rise to fearing independent loosening of the prosthetic. However, the option of removing the bridges is reasonable for cleaning or reworking reasons. Tooth size and tooth shape were in harmony with the facial appearance (Fig. 8). The patient is very happy with the final result. Then, once again, oral hygiene by using interdental

Fig. 7a: Final mandibular and maxillary bridges ready for the patient.
Fig. 7b: Maxillary bridge *in vivo*.
Fig. 7c: Mandibular bridge *in vivo*.



brushes were explained with urgency by a dental hygienist or a prophylaxis assistant.

Discussion

The patient came to our office with the desire for fixed dentures, which can be achieved in many different ways by using modern therapy concepts. Removable dentures, which would ensure no disadvantage in relation to durability, aesthetics and hygiene, were rejected by the patient. We often experience well-informed patients, who specifically ask for full ceramic, zirconium or one-stage supplies. Therefore, it is very important to discuss all possible treatment options with the patient, because their knowledge often comes from unknown sources, and it can be unclear if they might have too high expectations on the final result.

For a dental prosthesis which is only supported by implants, the jaw bone is the most significant in this context anatomically/physiologically. During the planning we orient ourselves first by the number of tooth roots to be replaced as the minimum number required, to avoid more bone resorption and to safely support the prosthetics. In the upper jaw, nine implants could be placed bilaterally in the posterior region due to strong resorption to replace the total of usually 24 tooth roots (17–27 in a complete dentition in the maxilla). In the lower jaw, twelve implants were inserted quantity to replace the 18 tooth roots in full dentition of 37–37 because of the better bone. Due to the patient who was from far abroad, we decided to do an all-in-one surgical procedure, where we remove all remaining teeth, reconstruct the vertical and horizontal bone defects and insert implants. A two stage surgical procedure with implantation in a second appointment has no significant benefit in this case in our opinion. The interesting discussion about the advantages and disadvantages of both variants would go beyond the scope of this prosthetically-oriented case demonstration.

The biological behaviour of teeth and implants as a carrier of dentures differs fundamentally.¹² Implants are ankylosed, teeth are connected with the bone by the periodontal ligament. The protective mechanoreceptive function,⁴ the better perceptions of bite force^{10,13} and the precise pain perception^{10,13} are lost with extraction of teeth and the associated loss of the periodontal ligament. The tactility of the osseointegrated implant is set off by other sensors. Kineberg and Murray described this compensation in their study of 1999 as "Bone perception",⁶ which cannot achieve the tactility of the periodontium. This bone perception, as an alternative feedback results from an interaction of receptors of the temporomandibular joints, skin, perios-

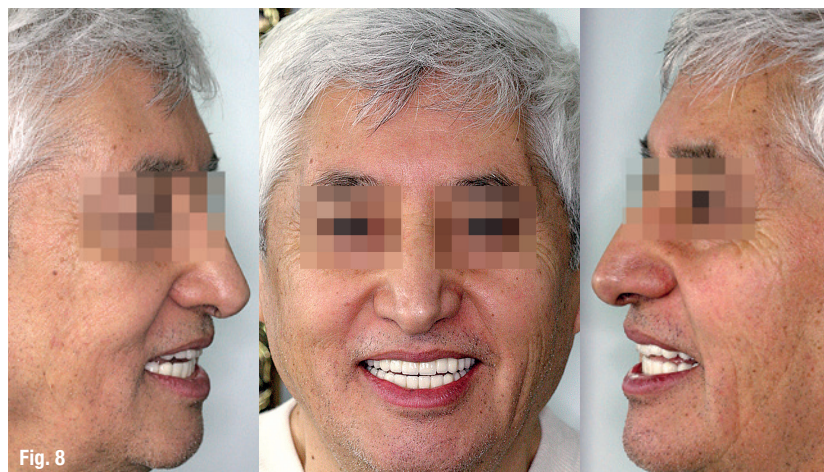


Fig. 8

teum and, in addition, of the mucosa by the use of mucosa carrying dentures. The tactility of implant-supported dentures is up to nine times less compared to natural teeth.^{3,4,9,10} To minimise the risk of overloading bite force by large implant-supported dentures, teeth should be maintained whenever possible to obtain the periodontal feedback,¹² which was not possible in the presented case.

To reduce the risk of crestal bone resorption, screw loosening and fractures on the scaffold or veneering^{3,8} of the definitive zirconium/ceramic restoration by abnormal masticatory forces in static and dynamic occlusion, the plastic mock-up should be worn to condition an alternative neural feedback. For implant impressions, we always use the pick-up technique. This has the highest accuracy compared to the repositioning technique.^{1,7,14} As impression material, we prefer A-silicones rather than polyether because it tends to be more accurate due to its high hardness. In combination with the customisable foil Miratray® implant tray, the impression for purely implant-supported dentures is easy, which is confirmed by stress-free incorporation in a rehearsal of the mock-ups. Performing large surgical/prosthetic restorations of the orofacial system requires close interdisciplinary cooperation between surgeon, prosthodontist, master dental technician as well as good compliance and resilience of the patient.

Editorial note: A list of references is available from the publisher.

contact

OA Dr Björn Dziedo
BERLIN KLINIK
Department of Prosthodontics
Leipziger Platz 3
10117 Berlin, Germany
prothetik@berlin-klinik.de

Fig. 8: Final result after cementation.