



Recurrent aphthous stomatitis

A case presentation with 915 nm diode laser therapy

Author: Dr Foteini Papanastasopoulou, Greece

Recurrent aphthous stomatitis (RAS) is one of the most common oral diseases and it is characterised by round ulcers surrounded by an erythematous halo. The lesions are usually painful due to the exposed nerve endings in the underlying lamina propria and the pain can range from mild to severe, affecting the patient's everyday life. RAS has three clinical presentations: aphthous minor, aphthous major and herpetiform ulcers. The cause of RAS is unknown, although several factors are suspected. These include stress, hormonal changes, genetics, diet, nutritional deficiencies, immunological and systemic disorders (such as Behçet's syndrome, Reiter's syndrome, and gastrointestinal malabsorption disorders).

The treatment of recurrent aphthous stomatitis is symptomatic. Accurate diagnosis of the cause of the disease and a treatment plan that is tailored individ-

ually to each patient can lead to successful management of RAS. The treatment goals are reduction of pain, healing time, number and size of ulcers and prevention of the recurrence of the disease. There are several treatment options for the management of recurrent aphthous stomatitis. Antiseptic mouthwashes containing chlorhexidine decrease the number of ulcers but do not prevent the recurrence of the disease. In addition, chlorhexidine can stain the teeth if it is used frequently. Topical analgesics reduce the pain but cannot be used extensively. Topical and systemic antibiotic treatments are empiric and are used because of a belief that the cause of the disease is an undiscovered infectious agent. Cauterising drugs are used, but they prolong healing time due to their destructive activity. Topical corticosteroids and systemic immunomodulators are commonly used when the immunopathogenesis is the cause of

the ulcer. However, both of them have numerous side effects. Dental lasers have also been used for the treatment of RAS.

It was found that laser irradiation accelerates wound healing, promotes pain relief and decreases recurrence of the lesions. There are three factors that accelerate wound healing: the increased production of ATP which results in greater tissue regeneration in the healing process, increased microcirculation which facilitates the cell multiplication and the formation of new vessels. The reason of pain reduction could be attributed to the release of endogenous pain relievers such as endorphins and enkephalins, the increased production of serotonin and suppression of bradykinin activity.

Case report

A 63-year-old female patient presented with painful lesions in her mouth. The patient was diagnosed with recurrent aphthous stomatitis. The ulcers were extremely painful and she had difficulties in eating, speaking and brushing her teeth. The patient had suffered from ulcers for several weeks and was extremely anxious and very sensitive to pain. She had tried to relieve the pain by many different topical medications, but to no avail. Also, new lesions developed as the older lesions resolved. The patient had no systemic disorders and was a non-smoker. Eight minor ulcers were found in her mouth (Fig. 1): One in the upper left lip (Fig. 1: lesion a1, Fig. 2), two ulcers in the palate (Fig. 1: lesions a4 and a5, Fig. 3: lesion a4), two ulcers in the right buccal area (Fig. 1: lesions a2 and a3, Fig. 3: lesion a2, Fig. 4: lesion a3), two lesions

in the lower lip (Fig. 1: lesions a6 and a7, Fig. 5: lesion a6) and one minor ulcer below the tongue (Fig. 1: lesion a8, Fig. 5). Laser therapy was selected for the treatment of recurrent aphthous stomatitis.

The patient was treated by 915 nm diode laser. A 300 μm fibre was used with power settings of 2 W, cw and in non-contact mode. The tip was moved with circular movements of 1 mm/s in speed from the periphery towards the centre of the lesion. The tip was also moved gradually closer to the lesion from 10 mm to 1 mm distance. The irradiation time of each lesion was 30 s/cm². Consecutive to each irradiation, the patient was asked if she was still feeling pain. Most lesions were irradiated twice (Fig. 1: lesions a4, a5, a6, a7, a8) and the larger and painful lesions were irradiated thrice (Fig. 1: lesions a1, a2, a3). At the end of the treatment, the patient reported that five ulcers were free of pain (Fig. 1: lesions a4, a5, a6, a7, a8) and three out of eight ulcers were mildly sensitive to the touch (Fig. 1: lesions a1, a2, a3). The patient was sent home and instructions were given to avoid hard, acidic and salty foods.

The patient was recalled a week later. She was content and she reported that eating was painless. She felt like the ulcers started healing earlier than the previous attacks. The patient was clinically examined and it was found that five ulcers had completely healed (Fig. 6: lesions a2, a4, a6, a7, a8, Figs. 9 and 10) and three ulcers out of eight were still sensitive to the touch (Fig. 6: lesions a1, a3, a5, Figs. 7 and 8). Additionally, two new painful ulcers were found: one below the tongue (Fig. 6: lesion b2, Fig. 9) and the other on the palate (Fig. 6: lesion b1). The

Initial examination

Fig. 1: Eight minor ulcers were found (a1–a8).

Fig. 2: Ulcer in the upper left lip (a1).

Fig. 3: Ulcer in the right buccal area (a2) and ulcer in the palate (a4).

Fig. 4: Ulcer in the right buccal area (a3).

Fig. 5: Ulcer in the lower lip (a6) and ulcer below the tongue (a8).

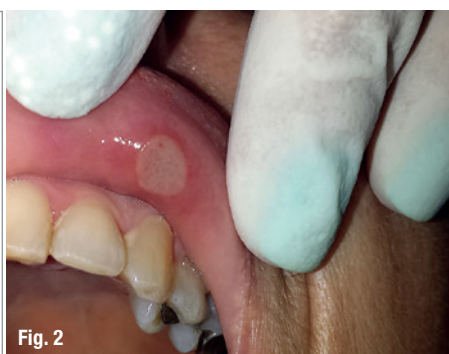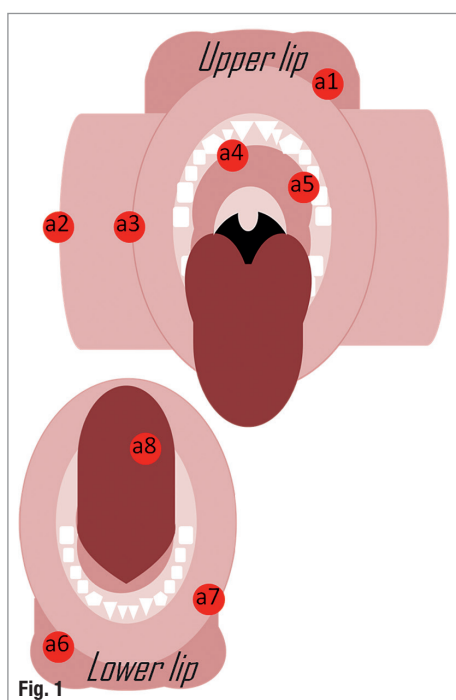


Fig. 2

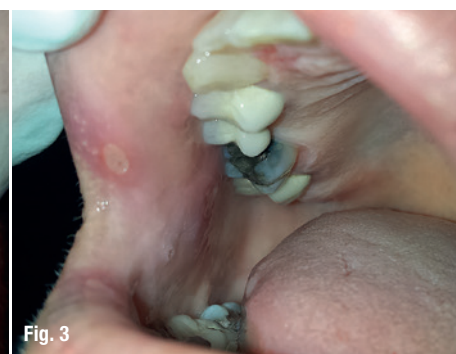

Fig. 3

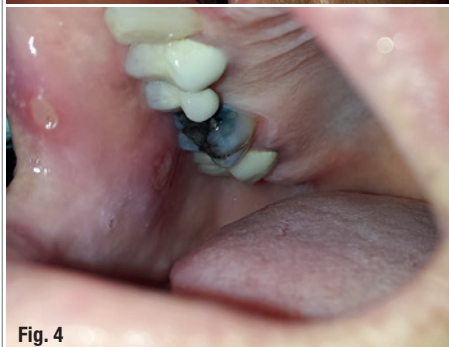

Fig. 4

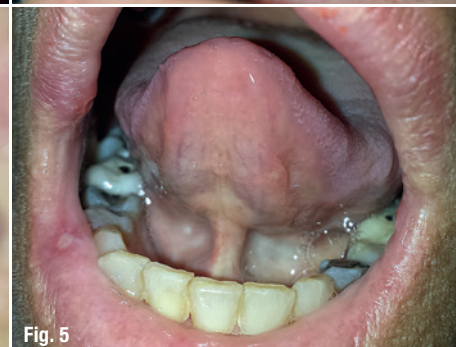
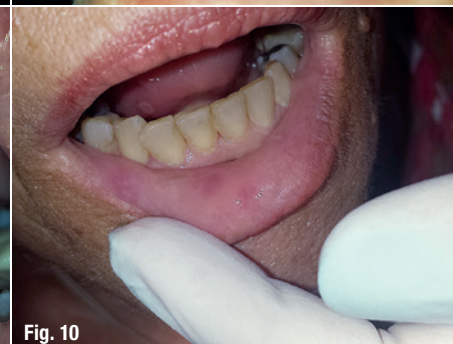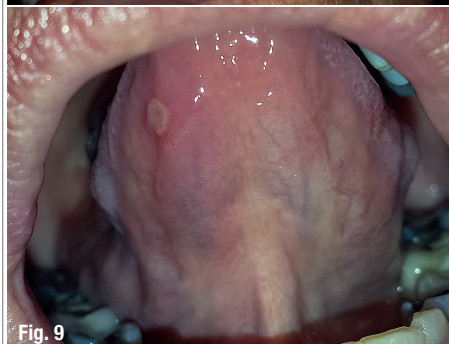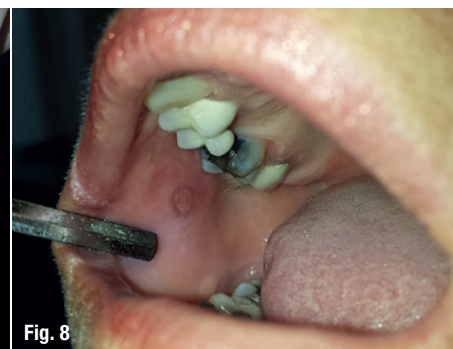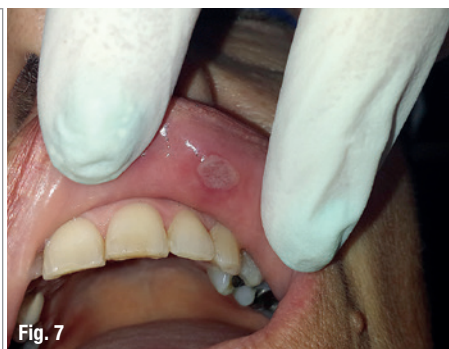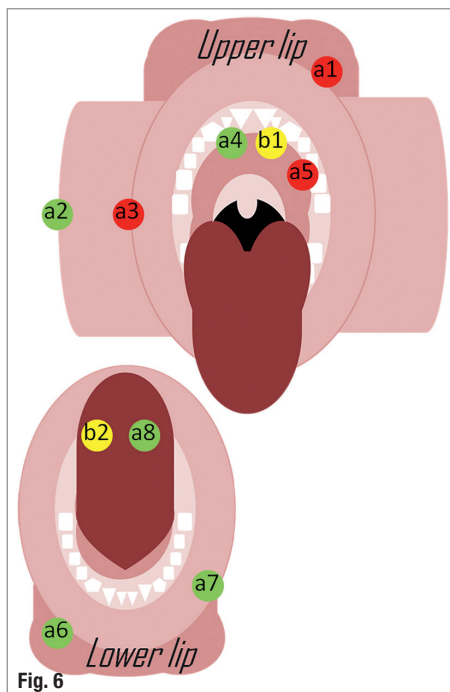


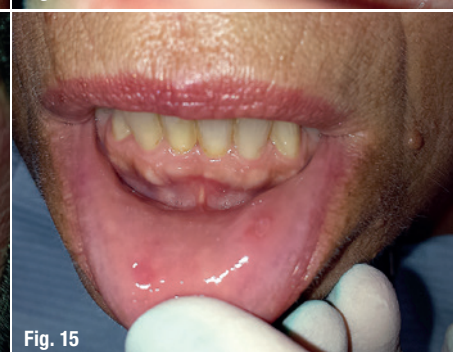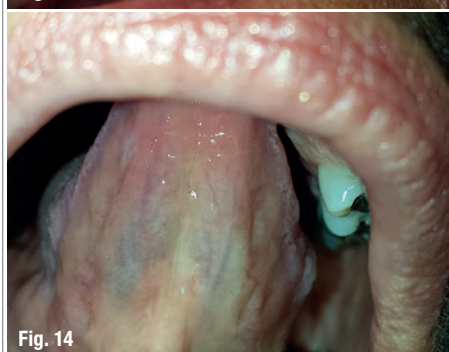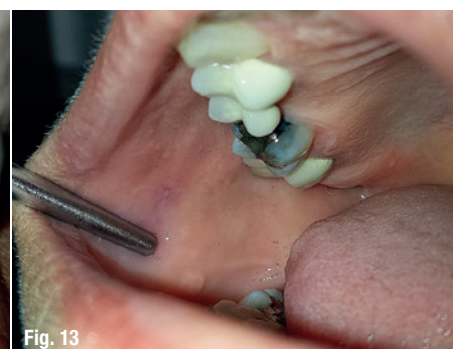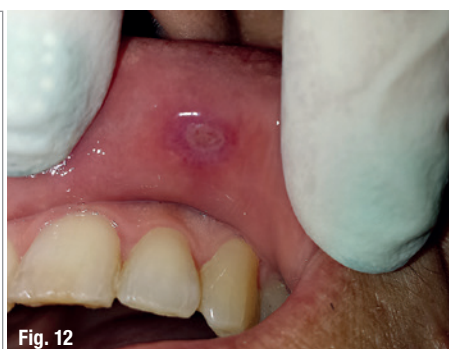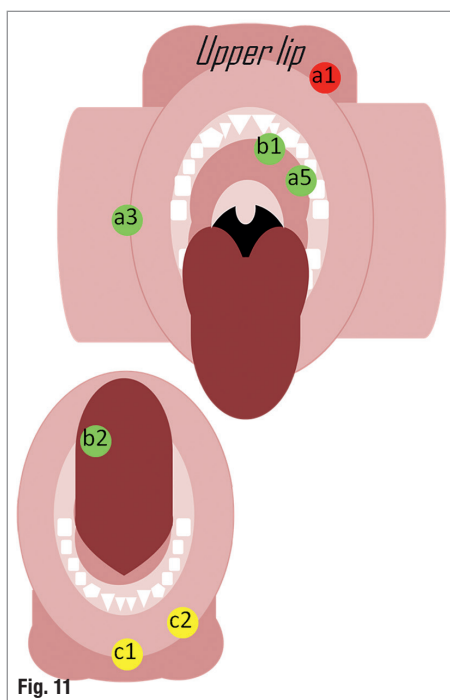
Fig. 5



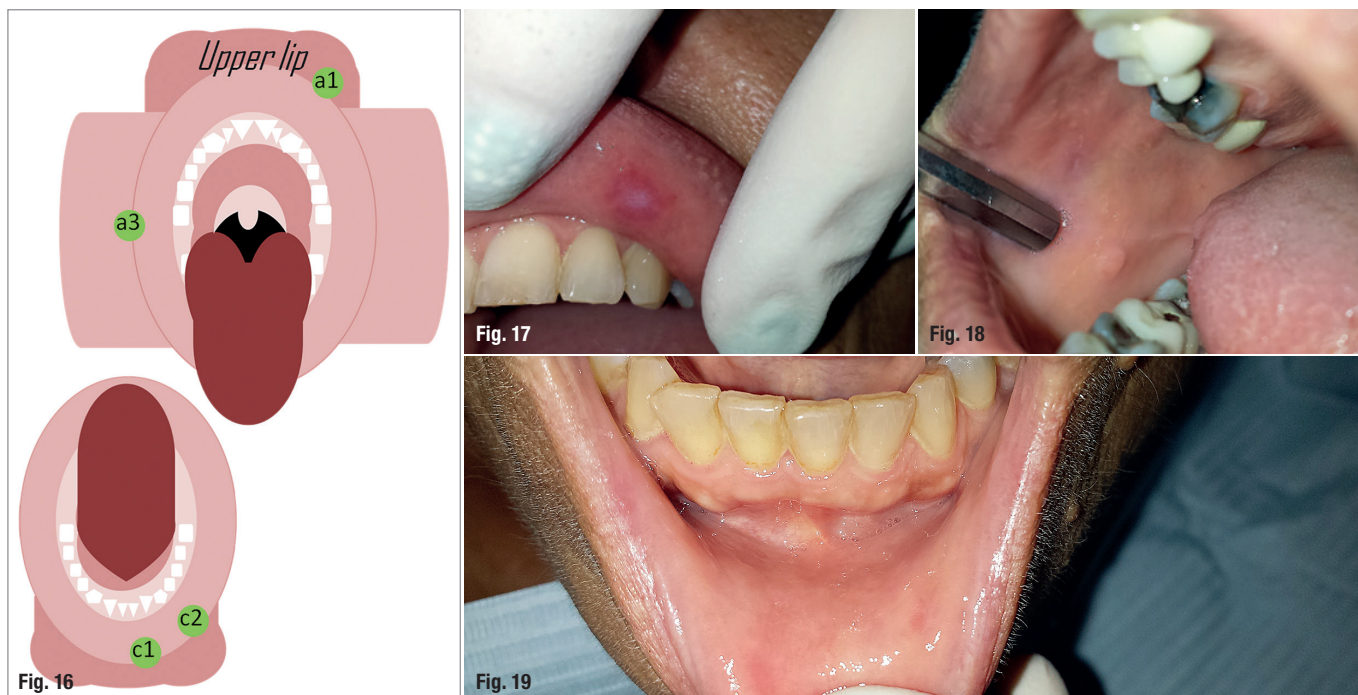
After seven days – Fig. 6: Completely healed ulcers (a2, a4, a6, a7, and a8), still painful old lesions (a1, a3, and a5), new painful ulcers (b1, b2). – **Fig. 7:** Still painful old ulcer in the upper left lip (a1). – **Fig. 8:** Still painful old lesion in the right buccal area (a3). – **Fig. 9:** Completely healed ulcer below the tongue, left side (a8) and new painful lesion below the tongue, right side (b2). – **Fig. 10:** Completely healed ulcer in the lower lip (a6).

same laser treatment protocol was followed for the three old lesions (Fig. 6: lesions a1, a3, a5) and the two new ones (Fig. 6: lesions b1, b2). The old lesions were irradiated two times and the new lesions three times. Then the patient was recalled three days later. All five lesions were without pain and had completely healed (Fig. 11: lesions a1, a3, a5, b1, b2).

However, two new lesions had developed in the lower lip (Fig. 11: c1, c2, Fig. 15). The two new lesions were irradiated three times each with the same laser protocol. After five days all the lesions had completely healed and no new lesions were detected (Fig. 16: lesions a1, a3, c1, c2, Figs. 17–19). A bi-weekly follow-up showed no recurrence of the disease.



After three days (ten days after the first irradiation) – Fig. 11: Completely healed ulcers (a1, a3, a5, b1, b2), new painful ulcers (c1, c2). – **Fig. 12:** Completely healed ulcer in the upper left lip (a1). – **Fig. 13:** Completely healed ulcer in the right buccal area (a3). – **Fig. 14:** Completely healed ulcer below the tongue, right side (b2). – **Fig. 15:** New painful ulcers (c1, c2).



After five days (15 days after the first irradiation) – Fig. 16: Completely healed ulcers (a1, a3, c1, c2). – **Fig. 17:** Completely healed ulcer in the upper left lip (a1). – **Fig. 18:** Completely healed ulcer in the right buccal area (a3). – **Fig. 19:** Completely healed ulcers in the lower lip (c1 and c2).

Conclusion

Laser treatment of recurrent aphthous stomatitis is an easy, fast and pain-free procedure. Multiple appointments were required in order to treat the newly-developed lesions. Studies have shown that ulcers treated by laser therapy provide immediate pain relief and fewer recurrences in the future. The main advantage of the laser treatment compared to other treatment options is that it can be used for all the causes of the disease both without having any side effects

and without the risk of medication overdose. In conclusion, laser treatment offers advantages for both the clinician and the patient.

contact

Dr Foteini Papanastasopoulou, MSc

Private dental practice

L. Kalamakiou 73, Alimos, Greece

foteinel@yahoo.gr

Kurz & bündig

Die Behandlung einer rezidivierenden Stomatitis aphthosa erfolgt in der Regel symptomatisch und ist dann erfolgreich, wenn der Behandlungsplan individuell auf den Patienten zugeschnitten wird und auf eine präzise Diagnostik folgt. Im vorliegenden Fallbericht beschreibt der Autor die lasergestützte Stomatistherapie bei einer 63-jährigen Patientin. Diese stellte sich mit schmerzhaften Aphthen in der Praxis des Autors vor. Die Geschwüre verursachten Probleme beim Essen, Sprechen und bei der Zahnpflege. Da die Patientin bereits seit mehreren Wochen unter den Geschwüren litt, war sie hochgradig ängstlich und schmerzempfindlich. Bevor sie sich beim Behandler vorstellte, hatte sie erfolglos versucht, ihre Schmerzen durch verschiedene topische Medikamente zu lindern. Weiterhin entwickelten sich neue Läsionen dort, wo alte Läsionen abklangen. Nach mehreren Behandlungen mithilfe des 915 nm-Diodenlasers waren alte und neue Geschwüre der Patientin verheilt und es konnte keine Neubildung von Läsionen festgestellt werden. Auch der Recall in zweiwöchigen Intervallen ergab kein Rezidiv.

Der Autor kommt zu dem Schluss, dass die Laserbehandlung einer rezidivierenden Stomatitis aphthosa eine einfache, schnelle und schmerzfreie Therapieoption darstellt. Den Hauptvorteil der Lasertherapie im Vergleich zu anderen Behandlungsansätzen sieht er darin, dass sie individuell, ohne Nebenwirkungen und ohne das Risiko einer Überdosierung angewendet werden kann. Zusammenfassend vereine die lasergestützte Stomatistherapie damit Vorteile für Behandler und Patient.