

Biomodulation in dentistry

Case series on the use of a new flat-top handpiece

Authors: Alberico Benedicenti, Andrea Amaroli, Wayne Selting, Nicola Deangelis & Stefano Benedicenti, Italy

Introduction

The influence of electromagnetic energy on biological tissue has been recognised since the 19th century, with the basic concept of photochemistry dramatically demonstrated in photosynthesis. Photobiomodulation (PBM) is the term applied to the manipulation of cellular behaviour using low-intensity light sources. It works on the principle of inducing a biological response through energy transfer.¹ PBM has been used in clinical practice for more than 40 years and its mechanisms of action at cellular and molecular levels have been studied for about 30 years.² As photonic energy irradiates tissue, it modulates biological processes within that tissue and, at least indirectly, within the biological system of which that tissue is a part.³ It is

generally accepted^{4,5} that the mitochondria of eukaryotic cells are the initial absorption sites for laser radiation in the visible to near-infrared optical region, and cytochrome c oxidase is the responsible photoacceptor.

There are two primary methods of influencing tissue with laser energy – photochemical and photothermal interaction. The most frequently used mechanism of photon energy conversion in laser medicine is photothermal. Very significant heating of irradiated samples occurs with all surgical methods of tissue interaction (cutting, vaporisation, coagulation, and ablation). However, at low light intensities, photochemical conversion of the energy absorbed by a photoacceptor prevails. In order to produce effective photobiomodulation, it is neces-

Fig. 1: Intrabony defect of tooth #23.

Fig. 2: Pre-existent gingival recession.

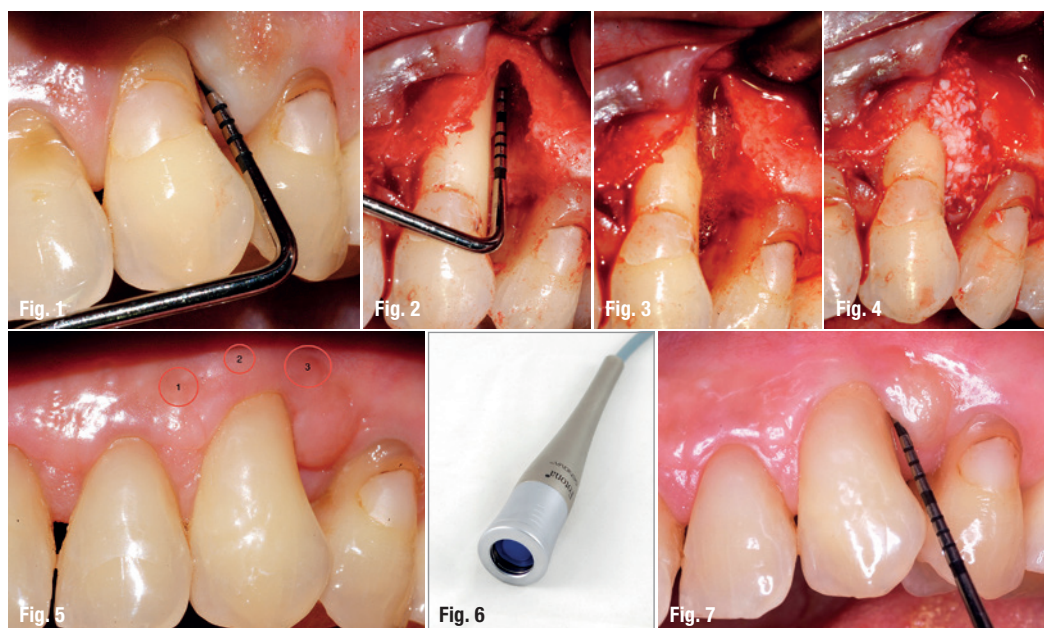
Fig. 3: Debridement of the granulation tissue.

Fig. 4: Placement of a graft.

Fig. 5: Irradiation points after the surgery.

Fig. 6: Genova handpiece.

Fig. 7: Situation after six months.



sary to minimise the thermal increase and to avoid a tissue temperature rise of more than 4–5 degrees Celsius.⁶

In clinical applications, photobiomodulation has been used to successfully induce wound and bone healing^{7–10}, for pain reduction¹¹ and for anti-inflammatory effects^{12–14}. Little is known about the use of the neodymium-doped yttrium aluminium garnet (Nd:YAG) laser in a biostimulatory mode. Most investigations have centred on the use of laser energy in the range of 400 nm to 980 nm. In this range of wavelengths, photons can penetrate effectively to reach deeper structures. Nd:YAG, at a wavelength of 1,064 nm, is near this window and exhibits some advantages. In terms of penetration of the radiation, longer wavelengths, such as produced by the (infrared) diode laser and Nd:YAG laser, penetrate as much as 6 millimetres, whereas laser energy with a shorter wavelength, such as red light produced by the He-Ne laser, has significantly less penetration.¹⁵

Recently, Usumez et al. demonstrated that low-level Nd:YAG laser therapy accelerates the wound healing process by changing the expression of PDGF and bFGF, genes responsible for the stimulation of cell proliferation and fibroblast growth.¹⁶

Significant effort has been made to clarify the parameters of deposited energy that will effectively promote positive change in individual cells while avoiding negative effects. Karu observed that high fluencies cause the destruction of photoreceptors which is accompanied by growth inhibition and cell lethality.¹⁷ Other researchers have also demonstrated that irradiation with fluencies higher than 10 J/cm² damages DNA.^{18,19} Finally, Bensadoun suggested the optimal dose is in the range of 2–3 J/cm² for prophylaxis and not more than 4 J/cm² for therapeutic effects, and recommended application over a single spot on a lesion rather than using a scanning motion over the entire lesion surface.²⁰ The World Association of Laser Therapy (WALT) has stated that applying energy in the range from 3 J/cm² to 10 J/cm² will promote effective biostimulation while avoiding bio-inhibitory effects.²¹

While this range of energy density seems well documented, achieving this goal is problematic. Radiated energy must reach target cells at this intensity level to be effective. Since the cells being targeted often lie deep within the tissue, absorption and scattering in overlying structures has a very significant effect on photon distribution. Laser energy density and distribution at the tissue surface is a poor predictor of deeper tissue distribution. A method of delivering photons to a group of individual cells, often deep

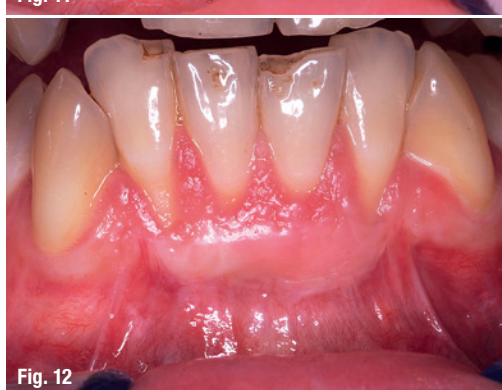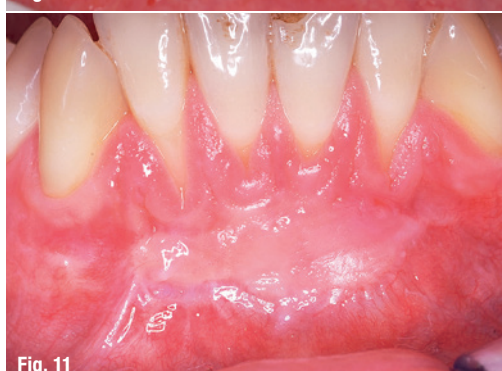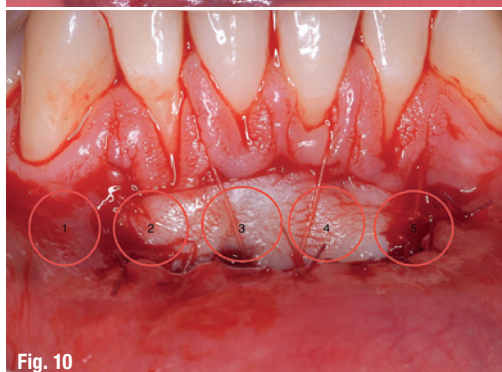


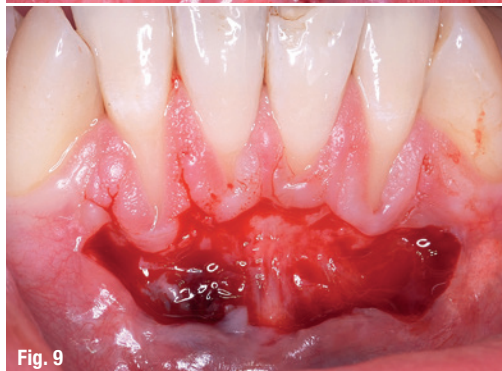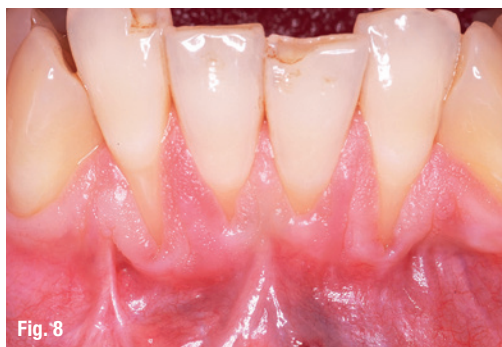Fig. 8: Situation before the mucogingival surgery.

Fig. 9: Creation of the recipient bed.

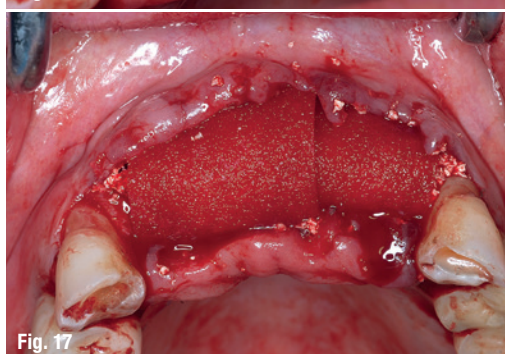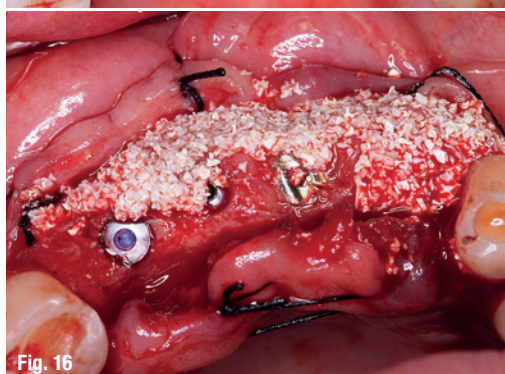
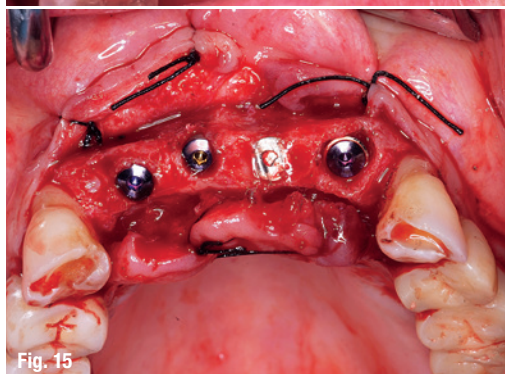
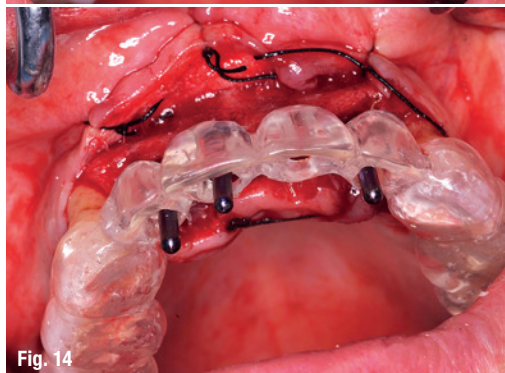
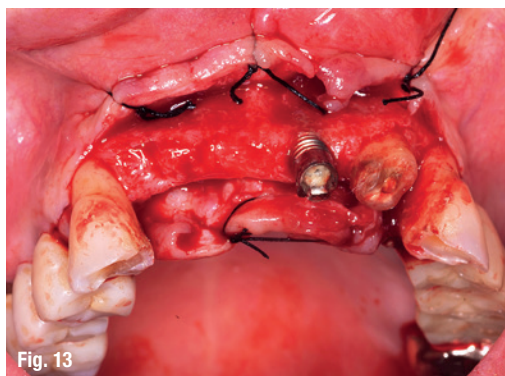
Fig. 10: Irradiation points after graft stabilisation.

Fig. 11: Situation after 14 days.

Fig. 12: Situation after 42 days.

Fig. 13: Fracture of an implant and missing teeth from 12 to 22.

Figs. 14–17: A regenerative procedure with bone substitute.



within a tissue mass, in a uniform and predictable manner, has been lacking.

Several problems complicate the adoption of a standardised protocol. While the biostimulatory effect of laser energy is experienced on a cellular level, the energy is applied macroscopically to large volumes of tissue in a non-uniform manner. As energy passes through tissue, part of it is absorbed so each successive depth of cells is irradiated differently. Beers law is usually used to define this relationship. However, this is inadequate since the dominant form of interaction at wavelengths between 600 nm and 1,400 nm is scattering.²² Thus, as energy enters tissue, its density decreases rapidly.

The output of most clinical lasers is Gaussian in spatial profile. Therefore, cells directly in the centre of the beam are irradiated at a very high fluence, while those on the periphery of the incident beam receive a very low dose. As a result, cells at the beam centre may be overstimulated far above the scientifically recommended range of 3–10 J/cm² and inhibited while those on the periphery receive insufficient cellular energy to produce any effect.

Further complicating standardisation is the issue of beam divergence. Fibre-delivered laser energy exits the fibre with a significant divergence, usually on the order of 8 degrees. The applied energy is, therefore, distributed over an increasing area as the tip-to-tissue distance increases, dramatically affecting energy density at the cellular level. At currently reported beam divergences, energy density can be diminished by 90 per cent with only 3 millimetres of tip-to-tissue distance. This makes the repeatable application of an appropriate energy density extremely technique-sensitive and operator-sensitive.

As a result of these problems, a handpiece was developed that provides homogeneous irradiation over a 1 cm² surface with a constant irradiation area (spot size) irrespective of the tip-to-tissue distance (from 10 to 100 mm) from the target tissue. With the introduction of this new flat-top handpiece,¹⁴ it is now possible to irradiate a target surface with a homogenous energy density, using relatively high-power densities, in less time and without risk of significant thermal damage. This would make the application repeatable and not operator-sensitive,^{14, 23} a significant step forward in standardisation of treatment parameters.

The aim of this study is to present, through a series of clinical cases, a preliminary report on the dental and medical applications of a new flat-top handpiece used in conjunction with an Nd:YAG laser according to the therapeutic protocols described in Benedicenti's textbook.²⁴

WFLD 2016



The 15th Congress of the World Federation for Laser Dentistry

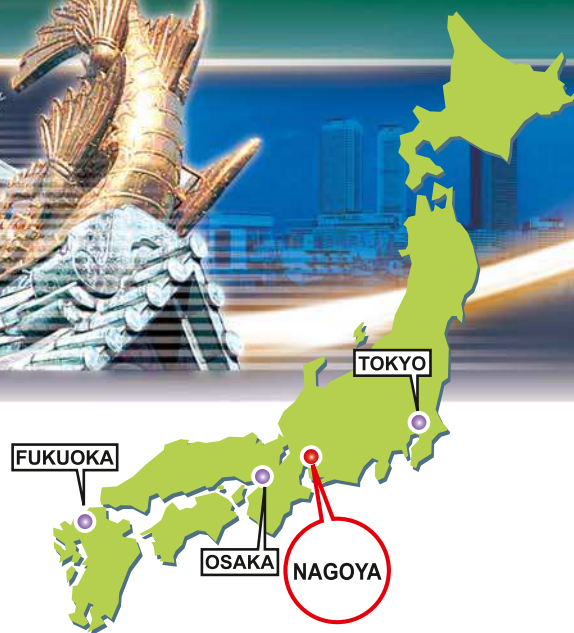Light to brighten the future

in collaboration with:

The 28th Annual Meeting of
Japanese Society for
Laser Dentistry



July 17^(Sun)-19^(Tue), 2016
Nagoya, Japan



Venue

**Aichi Industry & Labor Center
(WINC AICHI)**

Chairperson

Kenji Yoshida, D.D.S., PH.D.
Department of Oral & Maxillofacial Surgery,
School of Dentistry Aichi-Gakuin University

Secretariat

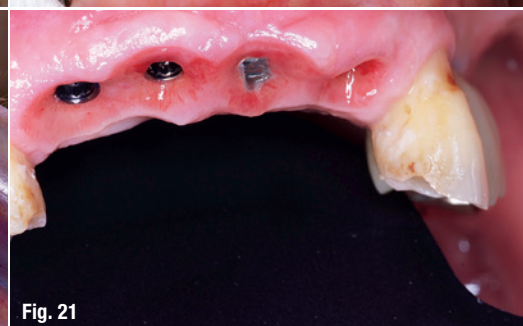
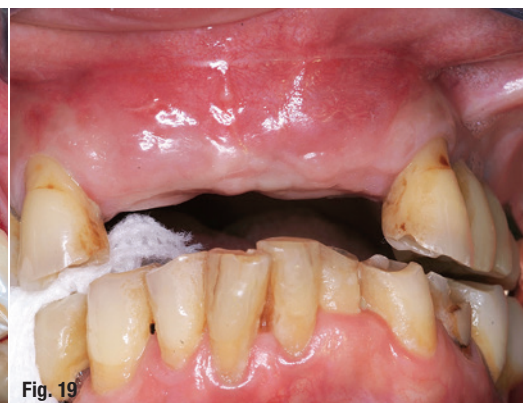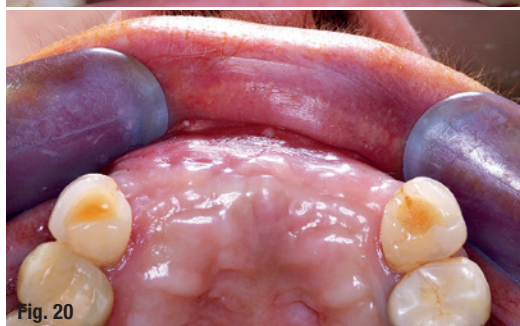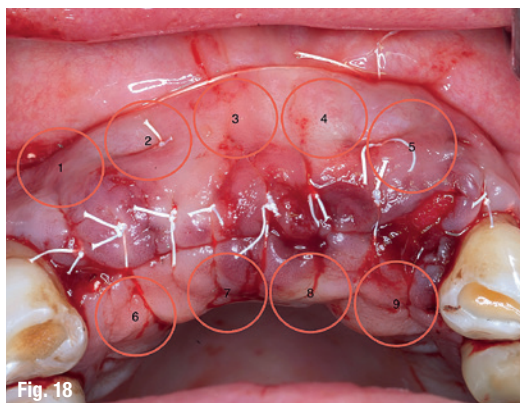
WFLD 2016 Secretariat
c/o Convention Linkage, Inc.
Asahiseimei Bldg., 3-32-20 Sakae, Naka-ku,
Nagoya 460-0008, Japan
Phone: +81-52-262-5070 Fax: +81-52-262-5084
E-mail: wfld2016@c-linkage.co.jp

<http://www.c-linkage.co.jp/wfld2016/>

Fig. 18: Biomodulation spots after suturing.

Figs. 19 & 20: Situation after three months.

Fig. 21: Stable tissue after six months.



Materials and methods

A standard irradiation protocol was used in each instance for the clinical series presented here. In all cases, an Nd:YAG laser (LightWalker ATS, Fotona, Ljubljana, Slovenia) was used in conjunction with a flat-top handpiece (Genova handpiece, Fotona, Slovenia). The laser was used in MSP mode, which produces individual pulses with a width of 100 microseconds. An average power of 0.5 watts and a pulse repetition rate of 10 pulses per second were used in each case, and irradiance was calculated as 0.5 W/cm². Therapy sessions occurred every other day, with the total number of sessions varying in accordance with clinical judgement and the characteristics of the particular tissue target.

Case 1

A 52-year-old female presented with aggressive localised periodontitis. After stabilisation of the acute inflammation, the patient was checked and a deep infrabony defect was evident on the distal aspect of tooth #23 (Fig. 1). The flap design aimed also to correct the pre-existent gingival recession (Fig. 2). A careful debridement of the granulation tissue was done (Fig. 3) and, afterward, a graft with inorganic bovine-derived hydroxyapatite was placed (Fig. 4).

After the surgery (Fig. 5), the area was irradiated with Nd:YAG laser (LightWalker ATS, Fotona, Slovenia) with the flat-top Genova handpiece every other day for ten days (five applications) with the following parameters: 0.5 W, 10 Hz in MSP modality, and 60 sec-

onds per point (Fig. 6). The healing was uneventful, with minimal pain and swelling. A control after six months showed a good stability of both the bone graft and the soft tissue (Fig. 7).

Case 2

A 41-year-old male patient presented with traumatic severe gingival recessions on the lower incisors. After a careful consultation, the patient was scheduled for the mucogingival surgery (Fig. 8). Due to the lack of keratinised tissue and the shallow vestibule, the only possible treatment was to harvest a free gingival graft for the root coverage procedure.

The recipient bed was created with a partial-thickness flap and all of the epithelial part was removed (Fig. 9). The graft was completely stabilised on the area with a tight suture in order to avoid the formation of a thick layer of exudate, which could jeopardise the final outcome of the procedure (Fig. 10).

Biomodulation was performed every other day for 14 days (seven sessions) with the flat-top handpiece in MSP modality, 10 Hz, 0.5 W (LightWalker ATS, Fotona, Slovenia), and 60 sec per point. After the initial phase of 14 days (Fig. 11) and for the whole maturation stage of 42 days (Fig. 12), the graft appeared successful and the root coverage was achieved.

Case 3

A 65-year-old female patient showed a fracture of an implant in the frontal area and missing teeth from

12 to 22 (Fig. 13). At the time of the implant placement, the buccal bone displayed an insufficient thickness, resulting in an improper aesthetic contour. Thus, a regenerative procedure with bone substitute (inorganic bovine derived hydroxyapatite) and an absorbable collagen membrane was performed (Figs. 14–17).

Suture was done carefully to prevent dehiscence and complications in the healing period. Biomodulation was performed to speed up bone healing and graft integration. A flat-top handpiece with Nd:YAG laser was applied every other day for ten days (five sessions) (LightWalker ATS, Fotona, Slovenia) at 0.5 W of power, MSP modality, 10 Hz, and 60 sec per point (Fig. 18).

After three months, the tissues appeared healthy and thick, and simultaneously to the second stage surgery, temporary crowns were placed (Figs. 19 & 20). At six months after implant placement, the tissues could be considered stable to deliver the final prosthesis (Fig. 21).

Conclusion

Within the limitation of this study it can be concluded that:

1. Nd:YAG laser, because of its high penetration, seems to be an appropriate wavelength for biomodulation.
2. With this flat-top Genova handpiece, irradiation is homogenous compared to a conventional defocused handpiece with a Gaussian output profile. Using relatively high power densities, biostimulation may be applied in less time and without risk of thermal damage if proper parameters are used.
3. Homogeneous irradiation is developed over a 1 cm² surface with a distance from the target tissue of 10 to 100 mm. This would make the application repeatable and not operator-sensitive.

Editorial note: A list of references is available from the publisher.

contact

Stefano Benedicenti

University of Genoa, Department of Surgical Sciences and Integrated Diagnostics
L.go Rosanna Benzi 10
16132 Genova, Italy
Tel.: +39 0103537309
benedicenti@unige.it

Kurz & bündig

Die photochemische und die photothermische Interaktion stellen die beiden vorherrschenden Methoden der Gewebemanipulation durch Laserenergie dar. Am häufigsten wird dabei auf photothermische Mechanismen zurückgegriffen. Um dabei möglichst effektiv vorzugehen, sei es notwendig, den resultierenden Temperaturanstieg auf maximal 4°C bis 5°C zu beschränken. Um dies zu erreichen, wurde ein neuartiges Handstück entwickelt, welches eine homogene Bestrahlung von Oberflächen von 1 cm² bei einem festgelegten Bestrahlungsbereich und unabhängig vom Abstand zwischen Laserfaser und Gewebe (10 bis 100 mm) ermögliche. Weiterhin entfalle das Risiko von Hitzeschäden und die Anwendung werde nicht nur wiederholbar, sondern mache auch vorhersagbare Ergebnisse unabhängig vom Anwender möglich. Ziel der vorliegenden Studie ist es, im Rahmen einer Fallstudie die medizinische Anwendbarkeit dieses neuen Flat-Top-Handstücks in Verbindung mit einem Nd:YAG-Laser zu ermitteln. Dies geschah gemäß den therapeutischen Protokollen nach Benedicentis Handbuch.²⁴

Für alle der drei vorgestellten Fälle wurde ein Standard-Bestrahlungsprotokoll verwendet. Hierbei handelte es sich um eine 52-jährige Patientin mit einer aggressiven lokalisierten Parodontitis, einem 41-jährigen Patienten mit traumatischem, gravierendem Zahnfleischrückgang im Bereich der unteren Schneidezähne und eine 65-jährige Patientin mit einem frakturierten Implantat im Frontzahnbereich sowie fehlenden Zähnen in Regio 12 bis 22. Der Nd:YAG-Laser wurde im MSP-Modus und individuellen Pulsen mit einer Breite von 100 ms (0,5 W, 10 pps, Strahlungsbreite 0,5 W/cm²) eingesetzt.

Die Autoren kommen aufgrund der Ergebnisse zu dem Schluss, dass der Nd:YAG-Laser aufgrund seiner hohen Gewebedurchdringung eine geeignete Wellenlänge für die Biomodulation besitze. Weiterhin ermögliche das Flat-Top-Handstück im Vergleich zu konventionellen Geräten eine homogene Behandlung mit relativ hoher Leistungsdichte, sodass im Rahmen der korrekten Parameter die Biostimulation in kürzerer Zeit und ohne das Risiko von Hitzeschäden erfolgen könne. Diese homogene Bestrahlung generiere zudem einen wiederholbaren und anwenderunabhängigen Behandlungsverlauf.