issn 2193-4665

Vol. 8 • Issue 2/2016

# laser

## international magazine of laser dentistry

2 2016

**research**
Laser treatment of gingival melanin hyperpigmentation

**case report**
Diode laser treatment of recurrent aphthous stomatitis

**industry**
Laser-activated irrigation with PIPS®

quintessenz

# Master of Science (M.Sc.) in Lasers in Dentistry

Next Start: **26th September 2016**
Aachen, Germany
4 semesters

**Become part of the International Dental Elite**

- Create new economic potential for your practice
- Two year career-accompanying postgraduate programme at the University of Excellence RWTH Aachen
- Combination of lectures, skill training sessions, live ops, tutorials, and practical workshops
- Internationally accepted and accredited by the German Governent, the European Union, the Washington Accord and the Bologna Process
- Science-based and practice-orientated on highest national and international level
- Increased patient satisfaction: minimal contact reduced vibration and pain

ASIIN e.V.
accredited degree program

RWTH INTERNATIONAL ACADEMY AACHEN UNIVERSITY

RWTH International Academy
Kackertstraße 10 I 52072 Aachen I Germany
phone +49 241 80 23543 I fax +49 241 80 92525
info@academy.rwth-aachen.de
www.academy rwth-aachen.de

**PROFESSIONAL EDUCATION PROGRAMMES**

AALZ
Aachen Dental Laser Center

AALZ GmbH
Pauwelsstraße 17 I 52074 Aachen I Germany
phone +49 241 47 57 13 10 I fax +49 241 47 57 13 29
info@aalz.de
www.aalz.de

Dr Georg Bach

# And yet it moves!

Dear colleagues,

When I first learned about the content of this issue of *laser* international magazine of laser dentistry which you are now holding in your hands, the following famous quote by Galileo Galilei came to my mind: When leaving the court of inquisition, where he was forced to renounce the Copernican world view, he notoriously whispered, "And yet it moves"!

In this line, I would like to tell you that, after all, laser light does make a difference by setting things – and sometimes even people—into motion. I highly recommend this issue of *laser*; it proves a good read and illustrates this sentiment perfectly. The removal of melanin hyperpigmentation, the treatment of recurrent aphthous stomatitis or tissue biomodulation—this large of variety of laser applications leaves no doubt that laser therapy is an enrichment to dentistry. Even if our immediate environment—which forms, by the way, yet another interesting parallel to Galalei and his time—may not always be ready to accept these findings, I am convinced that the application of monochromatic and coherent light has been a substantial enhancement of the scope of dental therapy in the past decades. This is, indeed, a therapeutic gift!

The current issue of *laser* is an eloquent testimony to this view on laser dentistry. If you wish to learn more about the rich spectre of laser dentistry, you will be given ample opportunity in the upcoming weeks, as two assets of modern laser dentistry have organised exciting events this year:

On the one hand, the 15th WFLD Congress will be held in Japan, and on the other hand, DGL will host its 25th anniversary congress in Munich, Germany, in autumn. Both of the two events feature high-calibre speakers and will guarantee an excellent scientific programme within an attractive setting. Make sure to use these opportunities!

Thus, I hope you will enjoy reading this issue of *laser* with a maximum gain in knowledge and that, furthermore, laser light will give many beneficial impulses to you and your day-to-day work.

Warm regards

Your colleague

Dr Georg Bach



## editorial

03 And yet it moves!
Dr Georg Bach

## research

06 Er,Cr:YSGG treatment of gingival melanin hyperpigmentation
Dr Habib Zarifeh *et al.*

## case report

10 Recurrent aphthous stomatitis
Dr Foteini Papanastasopoulou

## industry

14 Biomodulation in dentistry
Alberico Benedicenti *et al.*

20 Laser-activated irrigation with PIPS®
Dr Ralf Schlichting

40 Introducing LASOTRONIX—lasers for generations

## practice management

26 Eleven tips for success in your dental clinic
Dr Anna Maria Yiannikos

## events

30 15th International WFLD Congress—Preview
Claudia Jahn

32 "I want to spend the rest of my life studying light"
Claudia Jahn

## news

34 manufacturer news international

36 news international

## DGL

43 Und es bewegt doch etwas!
Dr. Georg Bach

44 news germany

## about the publisher

50 imprint

Cover image courtesy of Fotona,
www.fotona.com
Original Background: © Tumanyan/Shutterstock.com

Fotona
choose perfection

# The universe at your fingertips.

## TwinLight® Periodontal Treatment

Want to expand your practice with periodontal laser treatments?

- No need to refer patients out to other specialists
- No scalpels, no sutures
- High success rates with no need to repeat procedures
- Minimal or no-pain procedure

LightWalker®

www.lightwalkerlaser.com

TwinLight® treatment video

www.fotona.com

97856 CE ENG/1

# Er,Cr:YSGG treatment of gingival melanin hyperpigmentation

**Authors:** Dr Habib Zarifeh, Dr Monique Hanna & Dr Dany Salameh, Lebanon

## Introduction

In the past few decades, the improvement of intraoral soft tissue aesthetics has become a significant element in clinical dentistry, including gingiva, which is the most commonly affected intraoral tissue, causing an unpleasant appearance.[1,2] In fact, oral pigmentation is a discoloration of the oral mucosa or gingiva due to several exogenous and endogenous factors, such as drugs, heavy metals, genetics, endocrine disturbance, and inflammation.[3-5]

Also, melanin produced by melanocytes can cause melanin pigmentation,[3-5] varying from light to dark brown or black, according to the quantity and distribution of active melanin in the tissue.[4] Oral pigmentation occurs in people of all races.[6] Indeed, oral pigmentation increases in darker-skinned individuals. However, there is no difference in the number of melanocytes between fair-skinned and dark-skinned people. The variation is related to differences in the activity of melanocytes.[7]

Several procedures have been suggested for gingival depigmentation, varying from bur abrasion, surgical scraping, cryotherapy, and electrosurgery to laser therapy. Various lasers, such as carbon dioxide ($CO_2$) laser, Nd:YAG laser, semiconductor diode laser, argon laser, Er:YAG laser and Er,Cr:YSGG laser, have been indicated as an efficient, pleasant and reliable method with minimal postoperative discomfort and faster wound healing for depigmentation procedures.[8]

A healthy 39-year-old male with no previous surgical history and no allergies and no current medication had a chief complaint of dark pigmented areas in the anterior part of the upper and lower maxillary gingiva, stating that he was an occasional smoker. During the clinical examination, no abnormalities nor gum disease were revealed, but deep melanin pigmentation in the upper and lower mucosa, along with the marginal gingiva, was noticed. This lead to a dark gum colour and by consequence a less aesthetic smile (Fig. 1). Laser depigmentation procedure was planned. The process was explained to the patient and his consent obtained.

Digital images of the pigmented gingiva were taken preoperatively and on postoperative visits. Laser safety protocols were respected. The patient was treated with local anaesthesia. A Er,Cr:YSGG laser of

Fig. 1

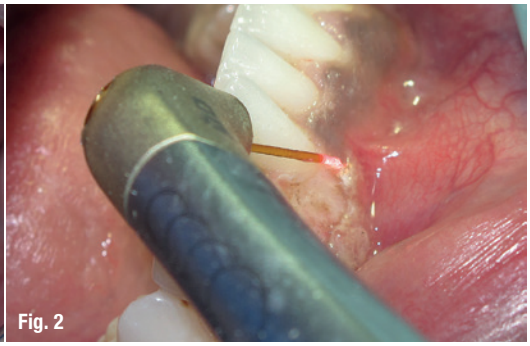
Fig. 2

**Fig. 1:** Melanin pigmentation (preoperative photo).
**Fig. 2:** Melanin depigmentation procedure.

**Fig. 3:** Immediate comparison after depigmentation of half of the upper-maxilla gingiva.
**Fig. 4:** Immediate comparison after depigmentation of the upper-maxilla gingiva.
**Fig. 5:** Immediate postoperative photo of the depigmentation of the upper and lower maxillary gingiva.
**Fig. 6:** Postoperative appearance of the gingiva after two days.
**Fig. 7:** Postoperative appearance of the gingiva after four days.
**Fig. 8:** Postoperative appearance of the gingiva after seven days.

2,780 nm was used with the following parameters: gold handpiece, Z6 tip, 60 % water, 40 % air, H Mode, 3.0 W, 20 pps, direction of the tip was slightly parallel or with 30 degree to the gum surface (Fig. 2), up to the second premolar on both the right and left side of the maxillary and mandibular anterior gingiva. We worked at a distance of 2 to 3 mm in non-contact mode with 30 degrees to the gum surface, with slow shaving movements until the removal of the pigmented layers of the epithelial cells and the connective tissue to remove melanin pigmentation (Figs. 3 & 4).

After the total removal of the pigmented layers of the gum (Fig. 5), an additional application of the Er,Cr:YSGG of 2,780 nm was done using different parameters: gold handpiece, Z6 tip, 0 % water, 0 % air, non-contact mode, S Mode, 2.0 W, 50 pps, direction of the tip 45 degrees to the gum surface. The aim of this procedure was to dehydrate the surface of the connective tissue and by consequence melting the nerve endings, which in the end leads to a reduction or absence of postoperative pain. This method is also referred to as "laser bandage".

The patient was prescribed saline mouthwash three times daily for one week, as well as application of vitamin E three times daily for seven days and paracetamol 500 mg, two tablets every eight hours in case of pain. The patient was advised to avoid hot meals during the first couple of days after surgery.

No infection or significant postoperative complications, such as pain or bleeding, were encountered. The patient was reviewed two, four and seven days after the procedure (Figs. 6–8). The fifteen-month follow-up showed no signs of recurrence of the pigmentation.

## Discussion

Numerous modalities for depigmentation have been used and described in the literature. First, removing pigmented layers can be performed by using chemical methods[9] or surgical methods such as surgical scalpel technique[10], surgical abrasion[9], cryosurgery[11, 12], electrosurgery[13] and laser[14–17].

Chemical methods are not recommended because the chemical action cannot be restricted to the oper-

ative area[11]. The scalpel technique is the most economical procedure compared to other methods requiring a more sophisticated armamentarium. However, this technique causes unpleasant bleeding during and after the operation, and it is necessary to cover the surgical site with periodontal dressing for seven to ten days.

Abrasion involves eliminating the epithelium of pigmented areas using a round diamond bur in a high-speed handpiece with copious irrigation.[18] The use of a large-size diamond bur is recommended, because small burs do not smooth surfaces easily.[9]

Cryosurgery is a treatment method in which the tissue is destroyed by rapid freezing as described by Tal et al.[19] It can be followed by considerable swelling, and it is accompanied as well by increased soft tissue destruction because of its uncontrolled depth of penetration. Electrosurgery has its own limitations because of its repetitive and prolonged use, provoking heat accumulation and undesired tissue destruction.[20]

The documented advantages of lasers for depigmentation consist of removing the melanin pigmentation by a less invasive procedure in order to eliminate a thin layer of epithelium[21], less bleeding during the procedure[22], reduced infection, swelling and scarring[22,23], decreased postoperative pain[24], a fast healing process and increased patient satisfaction regarding aesthetics.[22] The Er:YAG laser used in this case report produced the desired results efficiently. The patient was pleased with the result, which is the definitive objective of any treatment accomplished. Yet, there is no scientific evidence to establish that laser depigmentation is superior to scalpel depigmentation. On the other hand, techniques masking pigmented gingival from less pigmented gingival areas can be done using free gingival grafts[25,26] or acellular dermal matrix allografts[27].

## Conclusion

Considering the results of this case report, the depigmentation procedure was successful and the patient was satisfied. It may be concluded that the application of Er,Cr:YSGG laser appears to be secure and efficient for the treatment of gingival melanin pigmentation._

*Editorial note: A list of references is available from the publisher.*

## contact

**Dr Habib F. Zarifeh**
DDS, MS in Oral surgery, MSc in Laser dentistry
RWTH Aachen University
Head Of Clemenceau Medical Center dental department affiliated with Johns Hopkins International,
Head of HIMC Hospital dental department
Tel.: +96 11488842
Fax: +96 19933338
Habib Zarifeh, PO box: 90993, Jdeidet el-Metn, Lebanon
info@habibzarifeh.com
www.habibzarifeh.com

## Kurz & bündig

Im vorliegenden Artikel vergleicht der Autor anhand einer Zusammenfassung der Erkenntnisse aus der Fachliteratur konservative Ansätze zur lasergestützten Behandlung einer Melaninhyperpigmentation der Gingiva. Ein Fallbericht aus seiner eigenen Praxis beschreibt das mögliche Vorgehen bei einer Laserbehandlung dieser Pigmentationsstörung, welche meist aufgrund einer individuellen Kombination endo- und exogener Faktoren auftritt. Im Vergleich mit der chemischen Behandlung einer Melaninhyperpigmentation oder chirurgischen Ansätzen wie der Skalpelltechnik, der chirurgischen Abrasion, Cryochirurgie oder Elektrochirurgie besitze die Lasertherapie laut Autor und Literatur bereits gut dokumentierte Vorteile: Zum einen werde die Melaninpigmentation durch ein weniger invasives Vorgehen entfernt, indem nur eine dünne Schicht des Epitheliums abgetragen werde.[21] Des Weiteren gäbe es eine geringere Blutungsneigung[22], weniger Infektionen, Schwellungen oder Narbenbildung[22,23], einen weniger starken postoperativen Schmerz[24], einen schnellen Heilungsverlauf und eine gesteigerte Patientenzufriedenheit hinsichtlich der Ästhetik.[22] Im Folgenden beschreibt der Autor anhand des Falles eines 39-jährigen männlichen Patienten die lasergestützte Behandlung dunkel pigmentierter Areale im anterioren Bereich der oberen und unteren maxillaren Gingivia. Der Patient rauchte gelegentlich, wies aber darüber hinaus keine auffällige Krankengeschichte, Allergien oder Medikamentation auf. Im Anschluss an die Behandlung kam es zu keinen signifikanten postoperativen Komplikationen und der Patient zeigte sich hoch zufrieden mit dem ästhetischen Ergebnis. Anhand der Studienlage und des vorliegenden Fallberichts ist laut Autor der Rückschluss zulässig, dass die Anwendung eines Er,Cr:YSGG-Lasers eine sichere und effiziente Methode der Behandlung einer gingivären Melaninpigmentation sei.

# The World's Most Trusted All-Tissue Laser,

# *Now Even Better!*

WaterLase iPlus™

- Cut Hard-Tissue 250% Faster with Less Sensitivity[1]
- World's first turnkey apps to assist in the management of periodontitis and peri-implantitis
- Unrivaled versatility, providing unmatched results in treatment outcomes and outstanding ROI
- Open a new world of clinical capabilities with the most intuitive and easy-to-use graphic user interface
- SureFire™ Delivery System, ergonomically designed for enhanced flexibility, increased precision, and maximum uptime

## Limited Time Offer*

Last Chance to trade-in your old all-tissue laser towards a WaterLase iPlus. Contact your distributor for details.

BIOLASE

biolase.com

Contact your BIOLASE Authorized Distributor to your upgrade your practice to ***WaterLase Dentistry.***

©2016 BIOLASE, Inc. All rights reserved. *Trade-in program ends on 9/30/2016. [1] Data on file

# Recurrent aphthous stomatitis

## A case presentation with 915 nm diode laser therapy

**Author:** Dr Foteini Papanastasopoulou, Greece

**Recurrent aphthous stomatitis** (RAS) is one of the most common oral diseases and it is characterised by round ulcers surrounded by an erythematous halo. The lesions are usually painful due to the exposed nerve endings in the underlying lamina propria and the pain can range from mild to severe, affecting the patient's everyday life. RAS has three clinical presentations: aphthous minor, aphthous major and herpetiform ulcers. The cause of RAS is unknown, although several factors are suspected. These include stress, hormonal changes, genetics, diet, nutritional deficiencies, immunological and systemic disorders (such as Behçet's syndrome, Reiter's syndrome, and gastrointestinal malabsorption disorders).

The treatment of recurrent aphthous stomatitis is symptomatic. Accurate diagnosis of the cause of the disease and a treatment plan that is tailored individually to each patient can lead to successful management of RAS. The treatment goals are reduction of pain, healing time, number and size of ulcers and prevention of the recurrence of the disease. There are several treatment options for the management of recurrent aphthous stomatitis. Antiseptic mouthwashes containing chlorhexidine decrease the number of ulcers but do not prevent the recurrence of the disease. In addition, chlorhexidine can stain the teeth if it is used frequently. Topical analgesics reduce the pain but cannot be used extensively. Topical and systemic antibiotic treatments are empiric and are used because of a belief that the cause of the disease is an undiscovered infectious agent. Cauterising drugs are used, but they prolong healing time due to their destructive activity. Topical corticosteroids and systemic immunomodulators are commonly used when the immunopathogenesis is the cause of

the ulcer. However, both of them have numerous side effects. Dental lasers have also been used for the treatment of RAS.

It was found that laser irradiation accelerates wound healing, promotes pain relief and decreases recurrence of the lesions. There are three factors that accelerate wound healing: the increased production of ATP which results in greater tissue regeneration in the healing process, increased microcirculation which facilitates the cell multiplication and the formation of new vessels. The reason of pain reduction could be attributed to the release of endogenous pain relievers such as endorphins and encephalins, the increased production of serotonin and suppression of bradykinin activity.

## Case report

A 63-year-old female patient presented with painful lesions in her mouth. The patient was diagnosed with recurrent aphthous stomatitis. The ulcers were extremely painful and she had difficulties in eating, speaking and brushing her teeth. The patient had suffered from ulcers for several weeks and was extremely anxious and very sensitive to pain. She had tried to relief the pain by many different topical medications, but to no avail. Also, new lesions developed as the older lesions resolved. The patient had no systemic disorders and was a non-smoker. Eight minor ulcers were found in her mouth (Fig. 1): One in the upper left lip (Fig. 1: lesion a1, Fig. 2), two ulcers in the palate (Fig. 1: lesions a4 and a5, Fig. 3: lesion a4), two ulcers in the right buccal area (Fig. 1: lesions a2 and a3, Fig. 3: lesion a2, Fig. 4: lesion a3), two lesions in the lower lip (Fig. 1: lesions a6 and a7, Fig. 5: lesion a6) and one minor ulcer below the tongue (Fig. 1: lesion a8, Fig. 5). Laser therapy was selected for the treatment of recurrent aphthous stomatitis.

The patient was treated by 915 nm diode laser. A 300 µm fibre was used with power settings of 2 W, cw and in non-contact mode. The tip was moved with circular movements of 1 mm/s in speed from the periphery towards the centre of the lesion. The tip was also moved gradually closer to the lesion from 10 mm to 1 mm distance. The irradiation time of each lesion was 30 s/cm$^2$. Consecutive to each irradiation, the patient was asked if she was still feeling pain. Most lesions were irradiated twice (Fig. 1: lesions a4, a5, a6, a7, a8) and the larger and painful lesions were irradiated thrice (Fig. 1: lesions a1, a2, a3). At the end of the treatment, the patient reported that five ulcers were free of pain (Fig. 1: lesions a4, a5, a6, a7, a8) and three out of eight ulcers were mildly sensitive to the touch (Fig. 1: lesions a1, a2, a3). The patient was send home and instructions were given to avoid hard, acidic and salty foods.

The patient was recalled a week later. She was content and she reported that eating was painless. She felt like the ulcers started healing earlier than the previous attacks. The patient was clinically examined and it was found that five ulcers had completely healed (Fig. 6: lesions a2, a4, a6, a7, a8, Figs. 9 and 10) and three ulcers out of eight were still sensitive to the touch (Fig, 6: lesions a1, a3, a5, Figs. 7 and 8). Additionally, two new painful ulcers were found: one below the tongue (Fig. 6: lesion b2, Fig. 9) and the other on the palate (Fig. 6: lesion b1). The

**Initial examination**

**Fig. 1:** Eight minor ulcers were found (a1–a8).

**Fig. 2:** Ulcer in the upper left lip (a1).

**Fig. 3:** Ulcer in the right buccal area (a2) and ulcer in the palate (a4).

**Fig. 4:** Ulcer in the right buccal area (a3).

**Fig. 5:** Ulcer in the lower lip (a6) and ulcer below the tongue (a8).

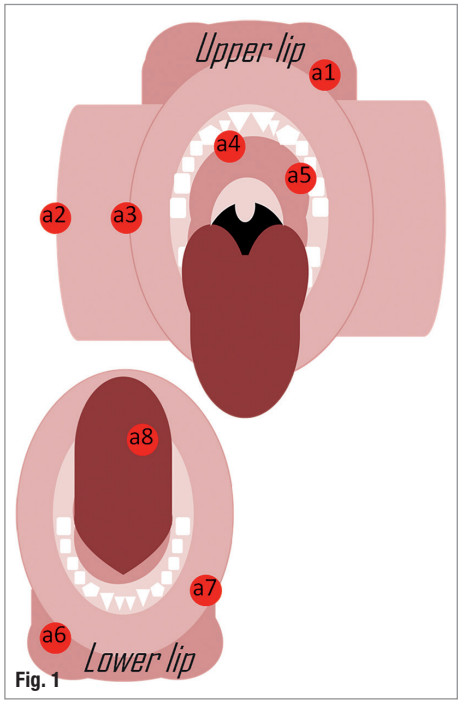

Fig. 1

Fig. 2

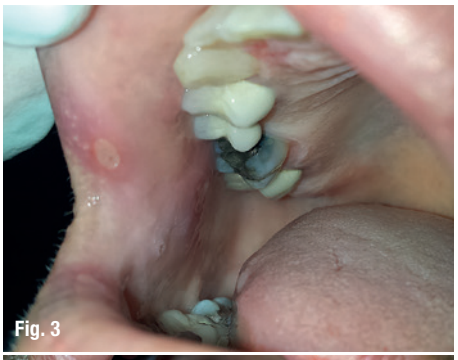
Fig. 3

Fig. 4

Fig. 5

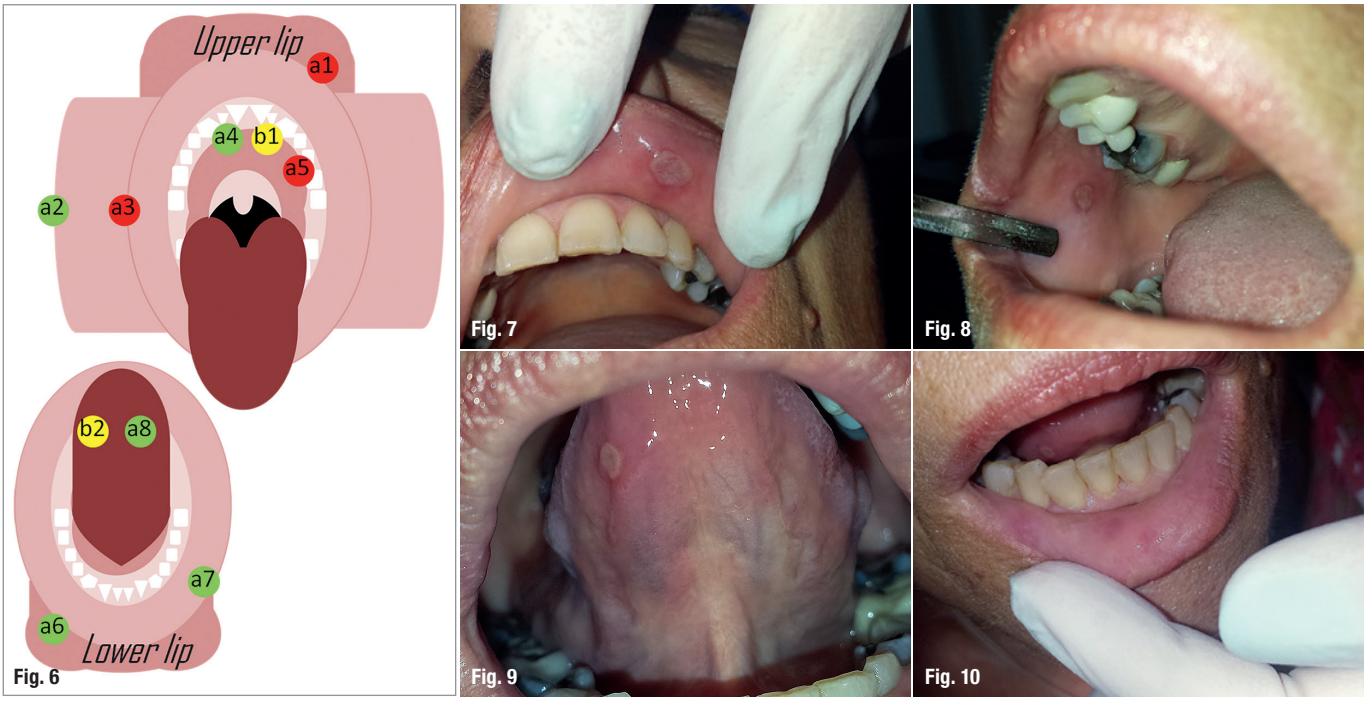


**After seven days – Fig. 6:** Completely healed ulcers (a2, a4, a6, a7, and a8), still painful old lesions (a1, a3, and a5), new painful ulcers (b1, b2). – **Fig. 7:** Still painful old ulcer in the upper left lip (a1). – **Fig. 8:** Still painful old lesion in the right buccal area (a3). – **Fig. 9:** Completely healed ulcer below the tongue, left side (a8) and new painful lesion below the tongue, right side (b2). – **Fig. 10:** Completely healed ulcer in the lower lip (a6).

same laser treatment protocol was followed for the three old lesions (Fig. 6: lesions a1, a3, a5) and the two new ones (Fig. 6: lesions b1, b2). The old lesions were irradiated two times and the new lesions three times. Then the patient was recalled three days later. All five lesions were without pain and had completely healed (Fig. 11: lesions a1, a3, a5, b1, b2). However, two new lesions had developed in the lower lip (Fig. 11: c1, c2, Fig. 15). The two new lesions were irradiated three times each with the same laser protocol. After five days all the lesions had completely healed and no new lesions were detected (Fig. 16: lesions a1, a3, c1, c2, Figs. 17–19). A bi-weekly follow-up showed no recurrence of the disease.

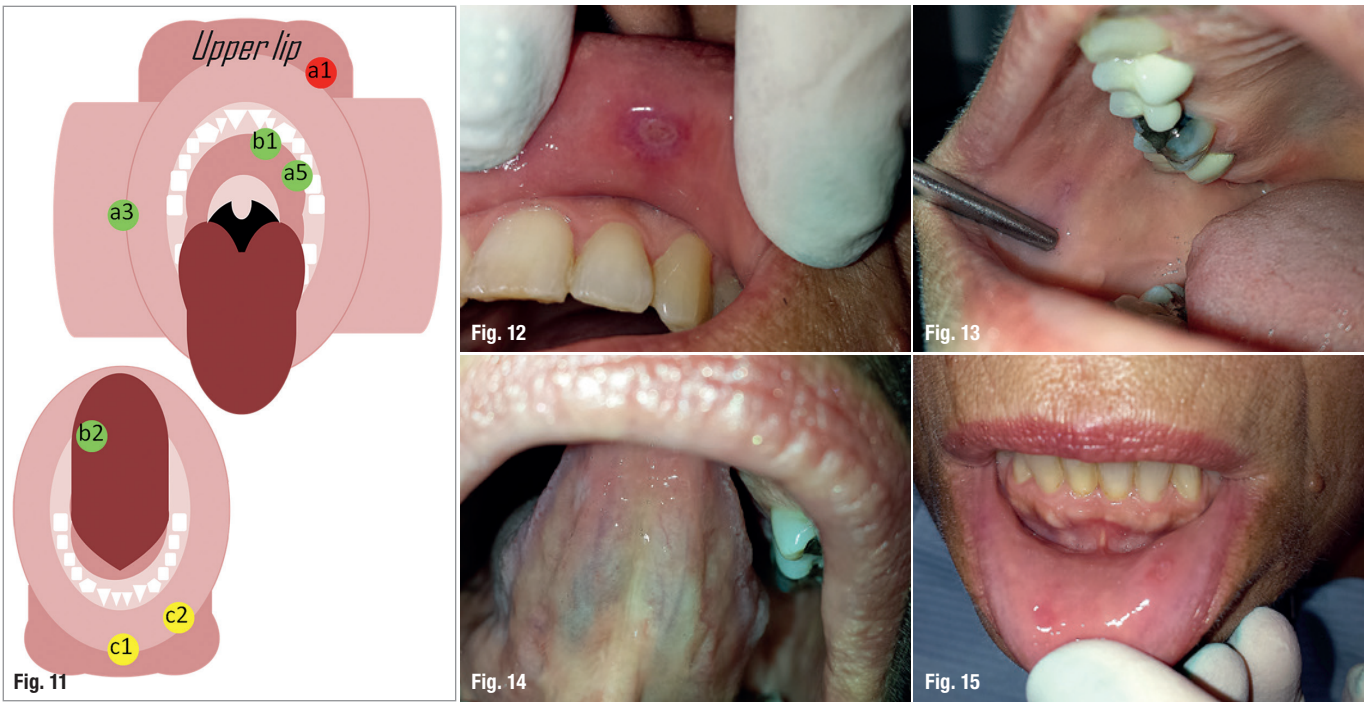


**After three days (ten days after the first irradiation) – Fig. 11:** Completely healed ulcers (a1, a3, a5, b1, b2), new painful ulcers (c1, c2). – **Fig. 12:** Completely healed ulcer in the upper left lip (a1). – **Fig. 13:** Completely healed ulcer in the right buccal area (a3). – **Fig. 14:** Completely healed ulcer below the tongue, right side (b2). – **Fig. 15:** New painful ulcers (c1, c2).

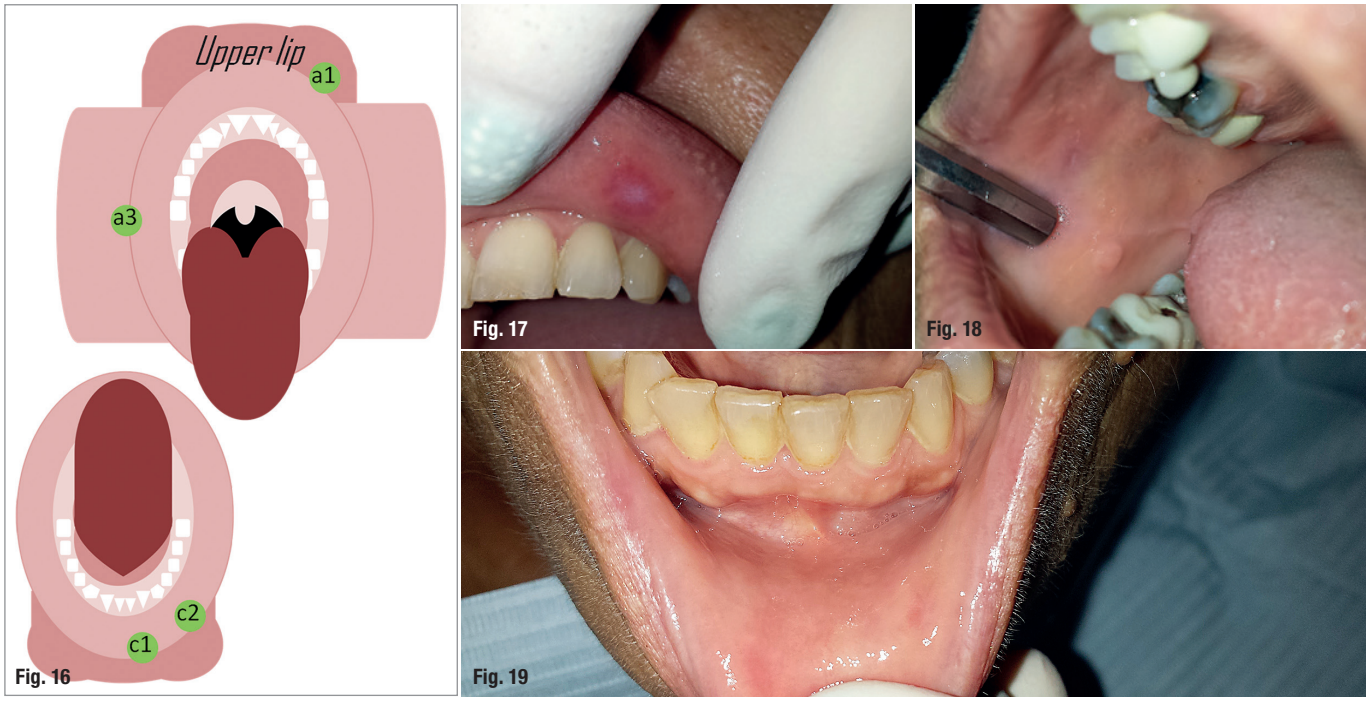


**After five days (15 days after the first irradiation) – Fig. 16:** Completely healed ulcers (a1, a3, c1, c2). – **Fig. 17:** Completely healed ulcer in the upper left lip (a1). – **Fig. 18:** Completely healed ulcer in the right buccal area (a3). – **Fig. 19:** Completely healed ulcers in the lower lip (c1 and c2).

## Conclusion

Laser treatment of recurrent aphthous stomatitis is an easy, fast and pain-free procedure. Multiple appointments were required in order to treat the newly-developed lesions. Studies have shown that ulcers treated by laser therapy provide immediate pain relief and fewer recurrences in the future. The main advantage of the laser treatment compared to other treatment options is that it can be used for all the causes of the disease both without having any side effects and without the risk of medication overdose. In conclusion, laser treatment offers advantages for both the clinician and the patient.

## contact

**Dr Foteini Papanastasopoulou, MSc**
Private dental practice
L. Kalamakiou 73, Alimos,Greece
foteinel@yahoo.gr

## Kurz & bündig

Die Behandlung einer rezidivierenden Stomatitis aphthosa erfolgt in der Regel symptomatisch und ist dann erfolgreich, wenn der Behandlungsplan individuell auf den Patienten zugeschnitten wird und auf eine präzise Diagnostik folgt. Im vorliegenden Fallbericht beschreibt der Autor die lasergestützte Stomatitistherapie bei einer 63-jährigen Patientin. Diese stellte sich mit schmerzhaften Aphthen in der Praxis des Autors vor. Die Geschwüre verursachten Probleme beim Essen, Sprechen und bei der Zahnpflege. Da die Patientin bereits seit mehreren Wochen unter den Geschwüren litt, war sie hochgradig ängstlich und schmerzempfindlich. Bevor sie sich beim Behandler vorstellte, hatte sie erfolglos versucht, ihre Schmerzen durch verschiedene topische Medikamente zu lindern. Weiterhin entwickelten sich neue Läsionen dort, wo alte Läsionen abklangen. Nach mehreren Behandlungen mithilfe des 915 nm-Diodenlasers waren alte und neue Geschwüre der Patientin verheilt und es konnte keine Neubildung von Läsionen festgestellt werden. Auch der Recall in zweiwöchigen Intervallen ergab kein Rezidiv.

Der Autor kommt zu dem Schluss, dass die Laserbehandlung einer rezidivierenden Stomatitis aphthosa eine einfache, schnelle und schmerzfreie Therapieoption darstellt. Den Hauptvorteil der Lasertherapie im Vergleich zu anderen Behandlungsansätzen sieht er darin, dass sie individuell, ohne Nebenwirkungen und ohne das Risiko einer Überdosierung angewendet werden kann. Zusammenfassend vereine die lasergestützte Stomatitistherapie damit Vorteile für Behandler und Patient.

# Biomodulation in dentistry

## Case series on the use of a new flat-top handpiece

**Authors:** Alberico Benedicenti, Andrea Amaroli, Wayne Selting, Nicola Deangelis & Stefano Benedicenti, Italy

### Introduction

The influence of electromagnetic energy on biological tissue has been recognised since the 19th century, with the basic concept of photochemistry dramatically demonstrated in photosynthesis. Photobiomodulation (PBM) is the term applied to the manipulation of cellular behaviour using low-intensity light sources. It works on the principle of inducing a biological response through energy transfer.[1] PBM has been used in clinical practice for more than 40 years and its mechanisms of action at cellular and molecular levels have been studied for about 30 years.[2] As photonic energy irradiates tissue, it modulates biological processes within that tissue and, at least indirectly, within the biological system of which that tissue is a part.[3] It is generally accepted[4,5] that the mitochondria of eukaryotic cells are the initial absorption sites for laser radiation in the visible to near-infrared optical region, and cytochrome c oxidase is the responsible photoacceptor.

There are two primary methods of influencing tissue with laser energy – photochemical and photothermal interaction. The most frequently used mechanism of photon energy conversion in laser medicine is photothermal. Very significant heating of irradiated samples occurs with all surgical methods of tissue interaction (cutting, vaporisation, coagulation, and ablation). However, at low light intensities, photochemical conversion of the energy absorbed by a photoacceptor prevails. In order to produce effective photobiomodulation, it is neces-

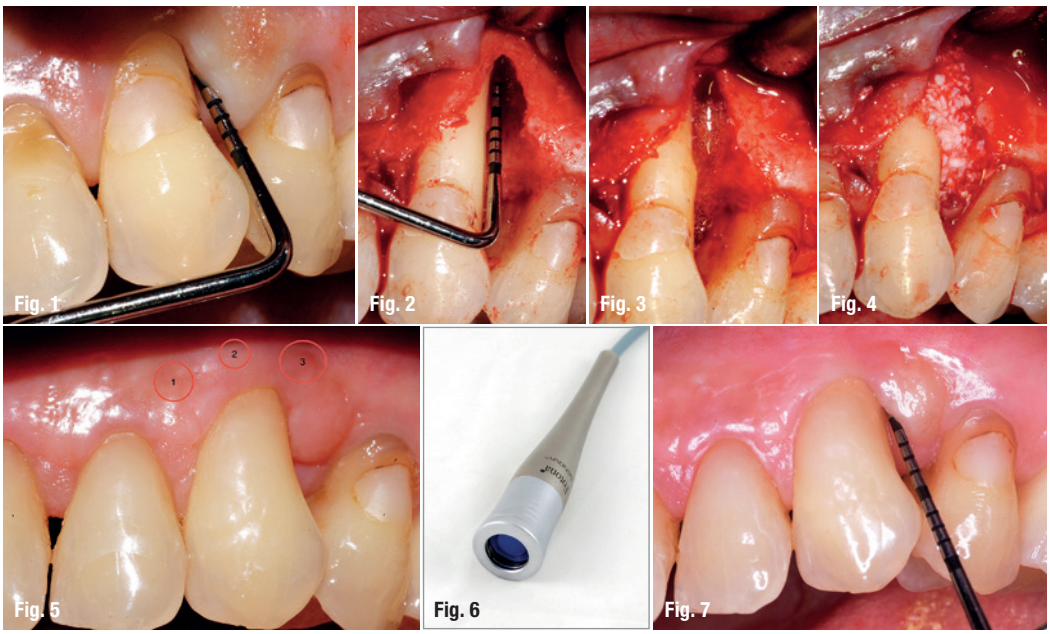


**Fig. 1:** Intrabony defect of tooth #23.
**Fig. 2:** Pre-existent gingival recession.
**Fig. 3:** Debridement of the granulation tissue.
**Fig. 4:** Placement of a graft.
**Fig. 5:** Irradiation points after the surgery.
**Fig. 6:** Genova handpiece.
**Fig. 7:** Situation after six months.

sary to minimise the thermal increase and to avoid a tissue temperature rise of more than 4–5 degrees Celsius.[6]

In clinical applications, photobiomodulation has been used to successfully induce wound and bone healing[7–10], for pain reduction[11] and for anti-inflammatory effects[12–14]. Little is known about the use of the neodymium-doped yttrium aluminium garnet (Nd:YAG) laser in a biostimulatory mode. Most investigations have centred on the use of laser energy in the range of 400 nm to 980 nm. In this range of wavelengths, photons can penetrate effectively to reach deeper structures. Nd:YAG, at a wavelength of 1,064 nm, is near this window and exhibits some advantages. In terms of penetration of the radiation, longer wavelengths, such as produced by the (infrared) diode laser and Nd:YAG laser, penetrate as much as 6 millimetres, whereas laser energy with a shorter wavelength, such as red light produced by the He-Ne laser, has significantly less penetration.[15]

Recently, Usumez et al. demonstrated that low-level Nd:YAG laser therapy accelerates the wound healing process by changing the expression of PDGF and bFGF, genes responsible for the stimulation of cell proliferation and fibroblast growth.[16]

Significant effort has been made to clarify the parameters of deposited energy that will effectively promote positive change in individual cells while avoiding negative effects. Karu observed that high fluencies cause the destruction of photoreceptors which is accompanied by growth inhibition and cell lethality.[17] Other researchers have also demonstrated that irradiation with fluencies higher than 10 J/cm$^2$ damages DNA.[18,19] Finally, Bensadoun suggested the optimal dose is in the range of 2–3 J/cm$^2$ for prophylaxis and not more than 4 J/cm$^2$ for therapeutic effects, and recommended application over a single spot on a lesion rather than using a scanning motion over the entire lesion surface.[20] The World Association of Laser Therapy (WALT) has stated that applying energy in the range from 3 J/cm$^2$ to 10 J/cm$^2$ will promote effective biostimulation while avoiding bio-inhibitory effects.[21]

While this range of energy density seems well documented, achieving this goal is problematic. Radiated energy must reach target cells at this intensity level to be effective. Since the cells being targeted often lie deep within the tissue, absorption and scattering in overlying structures has a very significant effect on photon distribution. Laser energy density and distribution at the tissue surface is a poor predictor of deeper tissue distribution. A method of delivering photons to a group of individual cells, often deep

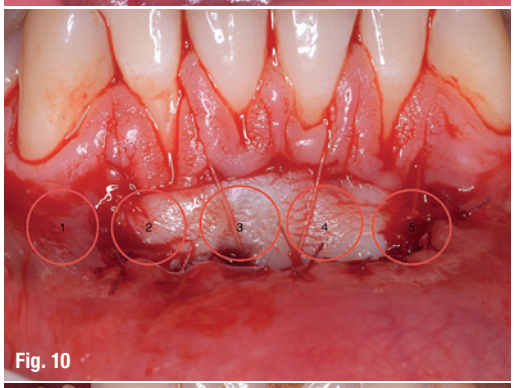

**Fig. 8:** Situation before the mucogingival surgery.
**Fig. 9:** Creation of the recipient bed.
**Fig. 10:** Irradiation points after graft stabilisation.
**Fig. 11:** Situation after 14 days.
**Fig. 12:** Situation after 42 days.

**Fig. 13:** Fracture of an implant and missing teeth from 12 to 22.
**Figs. 14–17:** A regenerative procedure with bone substitute.

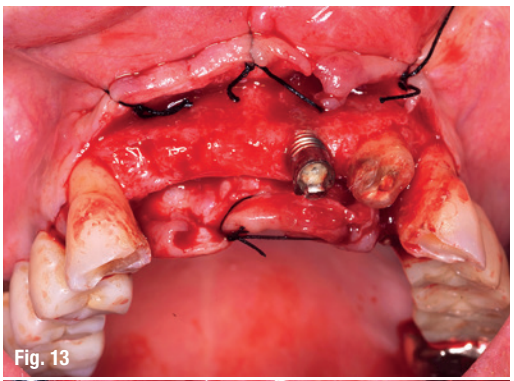
Fig. 13

Fig. 14

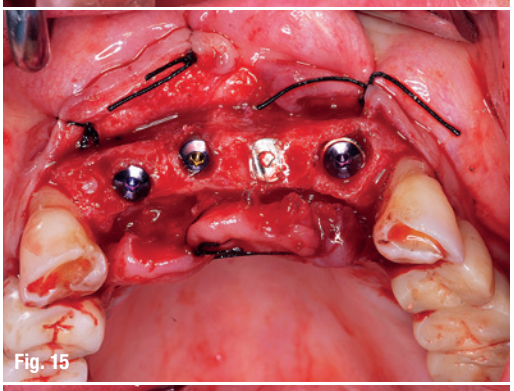
Fig. 15

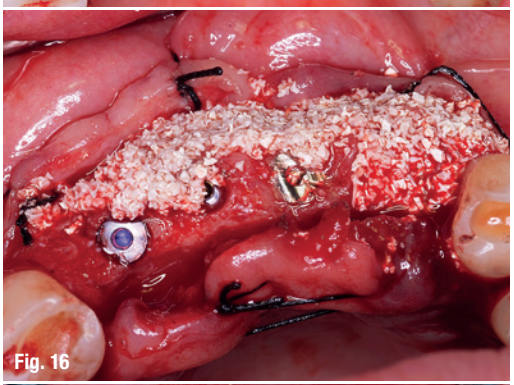
Fig. 16

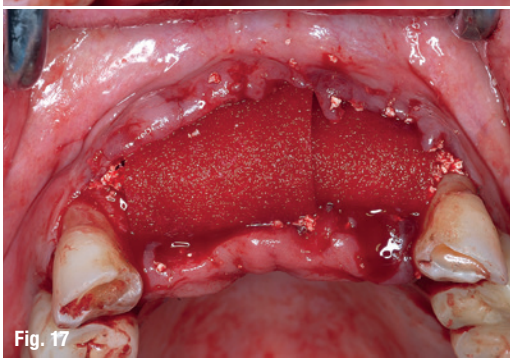
Fig. 17

within a tissue mass, in a uniform and predictable manner, has been lacking.

Several problems complicate the adoption of a standardised protocol. While the biostimulatory effect of laser energy is experienced on a cellular level, the energy is applied macroscopically to large volumes of tissue in a non-uniform manner. As energy passes through tissue, part of it is absorbed so each successive depth of cells is irradiated differently. Beers law is usually used to define this relationship. However, this is inadequate since the dominant form of interaction at wavelengths between 600 nm and 1,400 nm is scattering.[22] Thus, as energy enters tissue, its density decreases rapidly.

The output of most clinical lasers is Gaussian in spatial profile. Therefore, cells directly in the centre of the beam are irradiated at a very high fluence, while those on the periphery of the incident beam receive a very low dose. As a result, cells at the beam centre may be overstimulated far above the scientifically recommended range of 3–10 J/cm$^2$ and inhibited while those on the periphery receive insufficient cellular energy to produce any effect.

Further complicating standardisation is the issue of beam divergence. Fibre-delivered laser energy exits the fibre with a significant divergence, usually on the order of 8 degrees. The applied energy is, therefore, distributed over an increasing area as the tip-to-tissue distance increases, dramatically affecting energy density at the cellular level. At currently reported beam divergences, energy density can be diminished by 90 per cent with only 3 millimetres of tip-to-tissue distance. This makes the repeatable application of an appropriate energy density extremely technique-sensitive and operator-sensitive.

As a result of these problems, a handpiece was developed that provides homogeneous irradiation over a 1 cm$^2$ surface with a constant irradiation area (spot size) irrespective of the tip-to-tissue distance (from 10 to 100 mm) from the target tissue. With the introduction of this new flat-top handpiece,[14] it is now possible to irradiate a target surface with a homogenous energy density, using relatively high-power densities, in less time and without risk of significant thermal damage. This would make the application repeatable and not operator-sensitive,[14,23] a significant step forward in standardisation of treatment parameters.

The aim of this study is to present, through a series of clinical cases, a preliminary report on the dental and medical applications of a new flat-top handpiece used in conjunction with an Nd:YAG laser according to the therapeutic protocols described in Benedicenti's textbook.[24]

# WFLD 2016

WFLD 2016
Nagoya, Japan

## The 15th Congress of the World Federation for Laser Dentistry

*Light to brighten the future*

in collaboration with:

**The 28th Annual Meeting of Japanese Society for Laser Dentistry**

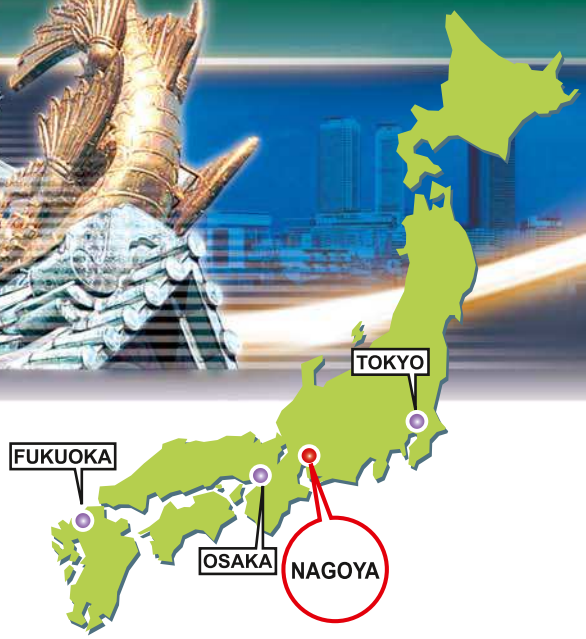


## July 17(Sun)-19(Tue), 2016
## Nagoya, Japan

**Venue** Aichi Industry & Labor Center (WINC AICHI)

**Chairperson** Kenji Yoshida, D.D.S., PH.D.
Department of Oral & Maxillofacial Surgery,
School of Dentistry Aichi-Gakuin University

**Secretariat**

WFLD 2016 Secretariat
c/o Convention Linkage, Inc.
Asahiseimei Bldg., 3-32-20 Sakae, Naka-ku,
Nagoya 460-0008, Japan
Phone: +81-52-262-5070 Fax: +81-52-262-5084
E-mail: wfld2016@c-linkage.co.jp

http://www.c-linkage.co.jp/wfld2016/

**Fig. 18:** Biomodulation spots after suturing.
**Figs. 19 & 20:** Situation after three months.
**Fig. 21:** Stable tissue after six months.

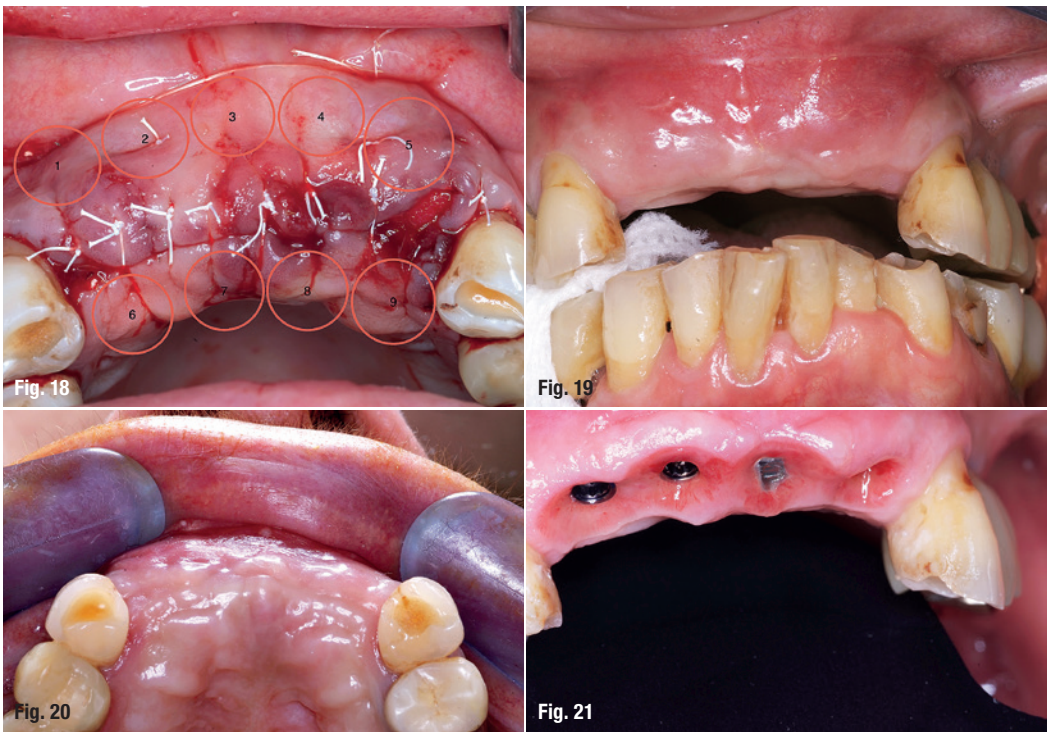


## Materials and methods

A standard irradiation protocol was used in each instance for the clinical series presented here. In all cases, an Nd:YAG laser (LightWalker ATS, Fotona, Ljubljana, Slovenia) was used in conjunction with a flat-top handpiece (Genova handpiece, Fotona, Slovenia). The laser was used in MSP mode, which produces individual pulses with a width of 100 microseconds. An average power of 0.5 watts and a pulse repetition rate of 10 pulses per second were used in each case, and irradiance was calculated as 0.5 W/cm$^2$. Therapy sessions occurred every other day, with the total number of sessions varying in accordance with clinical judgement and the characteristics of the particular tissue target.

## Case 1

A 52-year-old female presented with aggressive localised periodontitis. After stabilisation of the acute inflammation, the patient was checked and a deep infrabony defect was evident on the distal aspect of tooth #23 (Fig. 1). The flap design aimed also to correct the pre-existent gingival recession (Fig. 2). A careful debridement of the granulation tissue was done (Fig. 3) and, afterward, a graft with inorganic bovine-derived hydroxyapatite was placed (Fig. 4).

After the surgery (Fig. 5), the area was irradiated with Nd:YAG laser (LightWalker ATS, Fotona, Slovenia) with the flat-top Genova handpiece every other day for ten days (five applications) with the following parameters: 0.5 W, 10 Hz in MSP modality, and 60 seconds per point (Fig. 6). The healing was uneventful, with minimal pain and swelling. A control after six months showed a good stability of both the bone graft and the soft tissue (Fig. 7).

## Case 2

A 41-year-old male patient presented with traumatic severe gingival recessions on the lower incisors. After a careful consultation, the patient was scheduled for the mucogingival surgery (Fig. 8). Due to the lack of keratinised tissue and the shallow vestibule, the only possible treatment was to harvest a free gingival graft for the root coverage procedure.

The recipient bed was created with a partial-thickness flap and all of the epithelial part was removed (Fig. 9). The graft was completely stabilised on the area with a tight suture in order to avoid the formation of a thick layer of exudate, which could jeopardise the final outcome of the procedure (Fig. 10).

Biomodulation was performed every other day for 14 days (seven sessions) with the flat-top handpiece in MSP modality, 10 Hz, 0.5 W (LightWalker ATS, Fotona, Slovenia), and 60 sec per point. After the initial phase of 14 days (Fig. 11) and for the whole maturation stage of 42 days (Fig. 12), the graft appeared successful and the root coverage was achieved.

## Case 3

A 65-year-old female patient showed a fracture of an implant in the frontal area and missing teeth from

12 to 22 (Fig. 13). At the time of the implant placement, the buccal bone displayed an insufficient thickness, resulting in an improper aesthetic contour. Thus, a regenerative procedure with bone substitute (inorganic bovine derived hydroxyapatite) and an absorbable collagen membrane was performed (Figs. 14–17).

Suture was done carefully to prevent dehiscence and complications in the healing period. Biomodulation was performed to speed up bone healing and graft integration. A flat-top handpiece with Nd:YAG laser was applied every other day for ten days (five sessions) (LightWalker ATS, Fotona, Slovenia) at 0.5 W of power, MSP modality, 10 Hz, and 60 sec per point (Fig. 18).

After three months, the tissues appeared healthy and thick, and simultaneously to the second stage surgery, temporary crowns were placed (Figs. 19 & 20). At six months after implant placement, the tissues could be considered stable to deliver the final prosthesis (Fig. 21).

## Conclusion

Within the limitation of this study it can be concluded that:

1. Nd:YAG laser, because of its high penetration, seems to be an appropriate wavelength for biomodulation.
2. With this flat-top Genova handpiece, irradiation is homogenous compared to a conventional defocused handpiece with a Gaussian output profile. Using relatively high power densities, biostimulation may be applied in less time and without risk of thermal damage if proper parameters are used.
3. Homogeneous irradiation is developed over a 1 $cm^2$ surface with a distance from the target tissue of 10 to 100 mm. This would make the application repeatable and not operator-sensitive._

*Editorial note: A list of references is available from the publisher.*

## contact

**Stefano Benedicenti**
University of Genoa, Department of Surgical Sciences and Integrated Diagnostics
L.go Rosanna Benzi 10
16132 Genova, Italy
Tel.: +39 0103537309
benedicenti@unige.it

## Kurz & bündig

Die photochemische und die photothermische Interaktion stellen die beiden vorherrschenden Methoden der Gewebemanipulation durch Laserenergie dar. Am häufigsten wird dabei auf photothermische Mechanismen zurückgegriffen. Um dabei möglichst effektiv vorzugehen, sei es notwendig, den resultierenden Temperaturanstieg auf maximal 4°C bis 5°C zu beschränken. Um dies zu erreichen, wurde ein neuartiges Handstück entwickelt, welches eine homogene Bestrahlung von Oberflächen von 1 $cm^2$ bei einem festgelegten Bestrahlungsbereich und unabhängig vom Abstand zwischen Laserfaser und Gewebe (10 bis 100 mm) ermögliche. Weiterhin entfalle das Risiko von Hitzeschäden und die Anwendung werde nicht nur wiederholbar, sondern mache auch vorhersagbare Ergebnisse unabhängig vom Anwender möglich. Ziel der vorliegenden Studie ist es, im Rahmen einer Fallstudie die medizinische Anwendbarkeit dieses neuen Flat-Top-Handstücks in Verbindung mit einem Nd:YAG-Laser zu ermitteln. Dies geschah gemäß den therapeutischen Protokollen nach Benedicentis Handbuch.[24]

Für alle der drei vorgestellten Fälle wurde ein Standard-Bestrahlungsprotokoll verwendet. Hierbei handelte es sich um eine 52-jährige Patientin mit einer aggressiven lokalisierten Parodontitis, einem 41-jährigen Patienten mit traumatischem, gravierendem Zahnfleischrückgang im Bereich der unteren Schneidezähne und eine 65-jährige Patientin mit einem frakturierten Implantat im Frontzahnbereich sowie fehlenden Zähnen in Regio 12 bis 22. Der Nd:YAG-Laser wurde im MSP-Modus und individuellen Pulsen mit einer Breite von 100 ms (0,5 W, 10 pps, Strahlungsbreite 0,5 W/$cm^2$) eingesetzt.

Die Autoren kommen aufgrund der Ergebnisse zu dem Schluss, dass der Nd:YAG-Laser aufgrund seiner hohen Gewebedurchdringung eine geeignete Wellenlänge für die Biomodulation besitze. Weiterhin ermögliche das Flat-Top-Handstück im Vergleich zu konventionellen Geräten eine homogene Behandlung mit relativ hoher Leistungsdichte, sodass im Rahmen der korrekten Parameter die Biostimulation in kürzerer Zeit und ohne das Risiko von Hitzeschäden erfolgen könne. Diese homogene Bestrahlung generiere zudem einen wiederholbaren und anwenderunabhängigen Behandlungsverlauf.

# Laser-activated irrigation with PIPS®

## The power of better irrigation

**Author:** Dr Ralf Schlichting, Germany

### Why endodontics?

Bacterial infections of the root canal system are one of the main causes of apical periodontitis.[1] The infection usually enters through the dentinal tubules. Carious lesions, leaky fillings, leaky dental implants, hairlines, traumas, or erosion may be the cause of canal system infections.[2] For the primary and for the secondary infection as well, an intra-radicular mixed bacterial flora was proven.[3] The median bacterial count for the primary infection was $4.6 \times 10^7$ colony forming units (CFU) per apex.[4] For persistent infections, $5.4 \times 10^4$ CFU per apex were determined.[5] Bacteria may enter very deeply into the dentinal tubules and ramifications of the root canal system.[6] Colonies of *E. faecalis*, for example, can be found up to 500 µm away from the main canal (Fig. 1).[7] The bacteria within the infected canal system appear either in plankton form, i.e. swimming in tissue fluid[8], or relatively "organised" in the so-called "biofilm". This is a conglomerate of various bacterial species, which organise themselves in an extra-polysaccharide matrix that adheres tightly to the canal walls and the dentinal tubules (Fig. 2).[9] The almost symbiotic interrelations among the bacteria within the biofilm results in a much higher resistance of the individual bacterial species against antimicrobial agents.[10] In advanced stages of apical periodontitis, you can therefore always refer to an infectious disease triggered by biofilm.[11] With regard to the preferably complete removal of bacteria from the canal system and the dentinal tubules, the increased resistance of the bacteria embedded in biofilm, together with the extremely strong adhesion due to the extra-polysaccharide matrix, is one of the essential problems in endodontic treatment. In summary, bacteria are the main cause of apical periodontitis.[12] The purpose of any endodontic therapy must therefore be the extensive eradication of microorganisms, infected tissue residues, and infected dental hard tissue from the canal system and dentinal tubules.[13]

### Antimicrobial treatment concept

To meet this requirement as best as possible, it is necessary to comply with a strict antimicrobial treatment concept. This includes the imperative application of a dental dam, the removal of potentially infected dental restorations and scrupulously exact caries excavation as well as the preparation of a dentin-adhesive tight pre-endodontic buildup. The preparation of the correct access cavity facilitates all







**Fig. 1:** Bacterial infection of dentinal tubules. Source: Prof. V. Kaitsas.
**Fig. 2:** Biofilm. Source: Prof. V. Kaitsas.

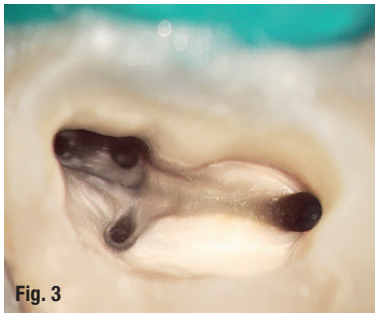


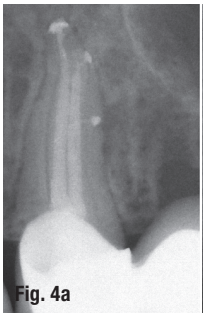


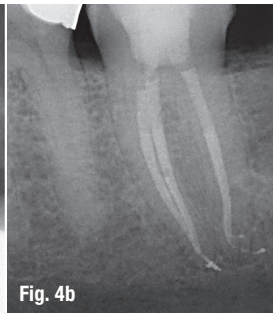


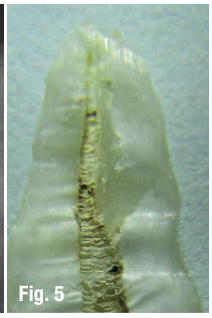


**Fig. 3:** Correctly prepared access cavity of the upper molar.
**Figs. 4a & b:** Upper molars after reciprocal preparation, irrigation with 5 % NaClO and 17 % EDTA, PUI and thermoplastic obturation.
**Fig. 5:** Surface after laser treatment in dry canal with end firing tip; Er:YAG laser at 75 mJ, 15 Hz, 1.1 W, and 300 micron.[57]

work steps following the pre-endodontic build-up. The direct correlation between the correctly prepared endodontic access cavity and the success of endodontic therapy has been verified (Fig. 3).[14] After having applied the access cavity and prepared the coronal root canals, we measure the length of the root canal and determine the working length. Given the development of electrometric measurement systems in the past years, electrometric length determination is the measure of choice for this purpose.[15]

## Chemomechanical preparation

As already mentioned above, bacterial infections of the root canal system are the main cause of apical periodontitis.[16] Solely preparing the root canals mechanically does not lead to sufficient reduction of microbial contamination. It was shown that major parts of the canal were not even attended to mechanically by means of mechanical preparation using rotating instruments.[17] The combination of mechanical preparation, activated irrigation by means of antimicrobial and tissue-resolving agents as well as the application of antimicrobial medication between the treatment sessions may reduce bacterial contamination of the canal system considerably.[18]

## Mechanical preparation

Mechanical root canal preparation, depending on the available anatomy of the canal, may be performed with either manual instruments or rotating nickel-titanium instruments. Compared to manual instruments, the use of rotating instruments leads to considerably improved results with regard to the preparation geometry and the preservation of the original topography of the canal.[19] The introduction of a novel preparation pattern, i.e. reciprocal preparation movements, facilitates an even better mechanical preparation. Besides the reduced risk of fracture[20], better alignment of the files in the canal system and the resulting predictable and repeatable preparation seems to be one of the main advantages of reciprocal movements. Another advantage over fully rotating systems is the effective and thus more rapid canal preparation.[21] Because of the improved mechanical properties of reciprocal file systems, the preparation can be limited to a few file sizes, depending on the available canal anatomy. This makes handling easier for the attending doctor and his/her team.

## Chemical preparation—irrigation solutions

The irrigation solutions applied to reduce bacterial contamination must fulfill various tasks in the root canal system:[22]

1. Antibacterial effectiveness against a broad microbial spectrum
2. Destruction of biofilm
3. Dissolution of potentially infected tissue
4. Removal of the smear layer

The smear layer is debris generated by the mechanical preparation, consisting of die dentin chips, bacteria, infected tissue, organic particles etc.[23] Especially with the rotating or reciprocal preparation, this debris is positively pressed into the dentinal tubules and compacted by the rotational movement. The smear layer thus prevents intra-canal antimicrobial agents and drugs from entering into the dentinal tubules and sub-canals.[24] The combination of sodium hypochlorite (NaClO) and ethylene diamine tetraacetate (EDTA) is the gold standard for the chemical reduction of intra-canal microorganisms to this day and has been proven in many research studies. The combination of both solutions and the mechanical preparation makes it possible to reduce contamination of root canals by the factor of 100 to 1,000.[25] NaClO has an excellent antimicrobial effect against most of the microorganisms that are significant in endodontics.[26] With regard to the tissue-resolving effect, NaClO is clearly superior to all other known irrigation solutions.[27] This tissue-lytic, effect combined with the excellent antimicrobial effectiveness, are key factors to accomplish comprehensive bacterial reduction in the root canal system. Concentrations between 1 per cent and 5.25 per cent are discussed. The higher the concentration, the quicker the lysis of the tissue.[28] Because of the rapid inactivation of NaClO when it contacts organic tissue, a large quantity of irrigation fluid of at least 10 ml per canal is required.[29] Heating the NaClO increases the effectiveness of the irrigation solution in the canal sys-

**Fig. 6:** PIPS® tip.

Fig. 6

tem.[30] Furthermore, you can improve the effectiveness by a longer reaction time.[31]

Ethylene diamine tetra-acetate (EDTA) serves to remove the smear layer mentioned above. Irrigation with approx. 5 ml of EDTA in a concentration of 17 per cent leads to the complete removal of the smear layer within one minute.[32] The reason why this effect is so important is that antimicrobial agents like e.g. NaClO can react deeply in the dentinal tubules only after the smear layer was removed. We should also mention that the effectiveness of EDTA against fungi like e.g. *Candida albicans* has been proven (Fig. 4).[33] The antimicrobial effect of EDTA is of rather minor importance.[34] The combination of the two described irrigation solutions is still the gold standard. Please refer to the related technical literature for more detailed information.

## Laser in endodontics

In the past decades, lasers were established in endodontics.[35] Laser is the abbreviation of light amplification by stimulated emission of radiation. They are electromagnetic waves with a high-energy density. In endodontics, lasers of different wavelengths are used. By photothermal and partly photomechanical effects, laser radiation can unfold its bactericidal effect, depending on the wavelength and the associated absorption in the irradiated tissue. Mostly because of heating and the subsequent change of the osmotic gradient within the bacterial cell wall, the cell dies.[36] Lasers used in endodontics so far differ in their wavelengths, which again have critical influence on the interaction with the irradiated tissue.[37] Nd:YAG lasers function at a wavelength of 1,064 nm, diode lasers within a range between 810 nm and 980 nm, and erbium lasers at 2,780 nm (Er,Cr:YSGG) and 2,940 nm (Er:YAG).

First reports on the application of Nd:YAG lasers in the root canal were published in 1984 already.[38] In this procedure, special endodontic optical fibers were used which could emit the laser light only linearly. For this reason, the optical fiber had to be moved in spirals in the canal to reach as many canal sections as possible. At 15 Hz and 100 mJ, the antibacterial effect may then reach up to 1,000 µm[39] and enter deeply into the dentinal tubules.

Compared to that, the reduction of bacteria using NaClO was proven to a depth of only 100 µm.[40] However, the linear emission and the high energy density in connection with the work in the dry canal had detrimental effects. The antibacterial effect is lower in curved canals because of the linear emission of laser radiation.[41] In addition, heat of up to 38°C developed in the canal, which may cause the dental hard tissue to burn (Fig. 5).[42]

Matusomo et al. explain that, due to the linear emission of the laser beam, on the one hand consistent wall contact was impossible and on the other hand, because of the heat formation, emission over the apex had to be avoided, making the work in the apical third considerably harder.[43] When comparing the disinfecting effect of Nd:YAG lasers with "traditional" disinfection using NaClO and ultrasound, DeMoore et al. arrived at the conclusion that the Nd:YAG laser has no advantage in this respect.[44] The effects described for the Nd:YAG laser apply to the diode laser as well.

Two different wavelengths are differentiated for erbium lasers: 2,780 nm for Er,Cr:YSGG and 2,940 nm for Er:YAG lasers. These wavelengths have their maximum absorption in water and hydroxyapatite.[45] When erbium laser radiation hits the dental hard tissue directly, the water contained in the tissue evaporates immediately and dental hard tissue is ablated "gently" with only minimal thermal effects.[46] With regard to endodontics, experimental studies with erbium lasers proved the removal of the smear layer to be more effective than by other types of lasers and endodontic irrigation solutions.[47] Furthermore, the canal walls were free from debris and smear layer and had mostly open dentinal tubules.[48] Because of the linear emission of the laser beam by the optical fiber and due to the cumbersome handling, the canal walls were cleaned imperfectly.[49]

To resolve these limitations, special endodontic so-called "side-firing" tips were developed, which are intended to emit irradiation laterally and apically sealed:[50] Unfortunately, a construction-related re-

quirement for the application was the minimum preparation size of ISO 60, which resulted in the unnecessary sacrifice of dental hard tissue. Because of the apical sealing, the apical cleaning effect was only low.

## Laser Activated Irrigation (LAI)—a revolution

How can the major advantages of erbium laser radiation be maintained without having to accept the application-related drawbacks? In 2007, Blanken et al. described for the first time the intra-canal application of a pulsed erbium laser in the canal lumen filled with NaClO.[51] They observed a few interesting effects: Each laser pulse caused great acceleration of the fluid in the root canal. At the same time, they proved a strong cavitation effect in the root canal.[52] Both effects combined resulted *in vitro* in a cleaning effect, which is superior to the passive ultrasonic irrigation (PUI), the previous gold standard of cleaning.[53] LAI in root canals, however, had some disadvantages too.

Irrespective of the laser tip design, sometimes a lot of irrigation fluid was extruded through the apical constriction. This extrusion was significantly higher than in conventional irrigation systems.[54] Additionally, the formation of gas bubbles because of the laser pulse may cause the irrigation fluid to vanish from the respective canal section completely, which again may cause thermal damage of dental hard tissue.[55]

## PIPS®—the evolution of revolution

In 2010, DeVito presented a novel tip design for the first time, combining all advantages of erbium laser radiation, Laser Activated Irrigation (LAI) and the minimisation of the risk of irrigation fluid being extruded (Fig. 6).[56]

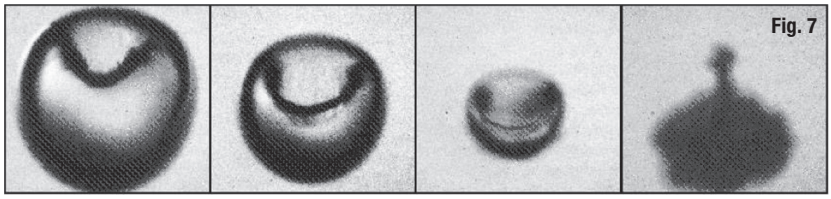


**Fig. 7:** Cavitation. Luther et al. 2001.

PIPS® is the abbreviation of Photon Initiated Photoacoustic Streaming. In this procedure, the PIPS® tip is inserted only into the pulp cavity filled with irrigation fluid. The pulsed laser beam generates shockwaves in the irrigation fluid and cavitation effects in the whole root canal system, intended to create a cleaning effect in the entire canal system, including isthmuses, lateral canals and deep down into the dentinal tubules, which is superior to any of the previous techniques. The almost complete elimination of bacteria, smear layer, and biofilm was proven in the *in vitro* experiment for NaClO and for EDTA.[57] No indication of irrigation fluid being extruded was noticed.[58]

What does the mechanism leading to this superior cleaning effect look like? When the laser pulse starts, the rapid heating of the irrigation fluid causes an expanding vapor bubble to form. The more the vapor bubble expands, the more it cools down, leading finally to its implosion.

This affects the root canal in the following ways:

1. The volume changes of the vapor bubble lead to heavy movement of the fluid in the root canal.[59]
2. The implosion of the bubble is a high-energy process. Shockwaves with large amplitudes and "micro-jets" develop. Shear stress builds up near surfaces (primary cavitation).[60]

AD

for diode laser - 810nm

www.protect-laserschutz.de

New safety spectacles for diode laser in dentistry

- spectacles for wearers of prescription glasses
- excellent color view
- large field of vision
- high-tech cushioned and adjustable side arms guarantee a high wearing comfort

PROTECT® LASERSCHUTZ GMBH

3. In addition to the primary cavitation, secondary cavitation processes are caused by the formation of subsequent, smaller bubbles (Fig. 7).[61]

These laser-induced effects depend on the absorption spectrum of the endodontic irrigation medium. That means: The better a certain medium absorbs the laser radiation, the better is the primary and the secondary cavitation effect. NaClO 5.3 %, EDTA 17 % and water have almost the same absorption spectrum.[62]

Wavelengths that are badly absorbed by the irrigation fluid may cause damage to the root canal walls, dentinal tubules, or even the periodontal ligament. This is one of the key differences between the two erbium wavelengths. The absorption coefficient of Er:YAG at 2,940 nm is almost twice as high as that of Er,Cr:YSGG. The PIPS® system operates exclusively at the wavelength of Er:YAG of 2,940 nm.

The PIPS® tip design is also a key influence on the effectiveness of cleaning: It is a 9 mm long tip with a diameter of 600 µm, the apical 3 mm of which are not sheathed with polyamide and have a tapered end (Fig. 6). The lacking sheath of the apical 3 mm results in better lateral emission. The tip is connected to the laser source (LightWalker®, Fotona, Slovenia) via a special endodontic handpiece. The free axial flexibility facilitates the application even in difficult anatomic situations (Fig. 8).

Fig. 8

The manufacturer recommends the following settings for PIPS®: 50 µS pulse length, 10 to 20 Hz and 0.15 to 0.5 W, i.e. peak powers of 400 W up to 1,000 W are achieved with each pulse due to the interaction with irrigation fluid. Air/water spray is not required. These settings triggered the shockwaves and the strong current of irrigation fluid as described above.[63] The temperature of the root surface increased by only 1.5 °C with the PIPS® activated for 20 to 40 s.[64] Clinical application should follow the manufacturer's instructions.

At the end of the preparation, irrigation with 17 % EDTA is performed to remove the smear layer. The pulp cavity should be flooded with EDTA. Then the PIPS® tip is inserted into the orifice and activated for 30 seconds (Fig. 9). After rinsing intermediately with saline solution, rinsing with NaClO is performed. This is followed by activating the NaClO twice for 30 seconds respectively with a break of 30 seconds between the intervals. A sufficient quantity of fluid in the orifice is important in this procedure. If necessary, the assistant needs to add irrigation fluid continuously.

The research results regarding PIPS® so far have been promising. One study compared the bacterial reduction as well as the biofilm removal between PUI and PIPS® *in vitro*. The application of PIPS® resulted in the reduction of bacterial contamination by 99.5 %, the significantly better reduction of biofilm, and the significantly greater number of samples that are free from bacteria.[65] In another study, Jaramillo et al. compared the removability of biofilm applying various techniques to activate the irrigation. Besides PIPS® (LightWalker®, Fotona, Slovenia), these were the passive ultrasonic irrigation (PUI) and sonic activation (EndoActivator). The laser-induced irrigation with PIPS® was significantly superior to all other techniques as regards removing the biofilm (Fig. 10).[66] Another study deals with the removability of calcium hydroxide from root canals. The authors compared as well PIPS®, PUI, and sonic activation of irrigation fluids. After the laser-activated irrigation with PIPS®, all the samples were free from calcium hydroxide, 24 per cent still showed residues in case of PUI.[67] The removal of *E. faecalis* from artificially infected root canals using PIPS® and the sole irrigation with saline solution without activation was the subject matter of another study. The remarkable result of this study was the complete removal of *E. faecalis* from all canals in the PIPS® group, in which the preparation was effected only to the Pro Taper® F1 file.[68] This study may be an in-

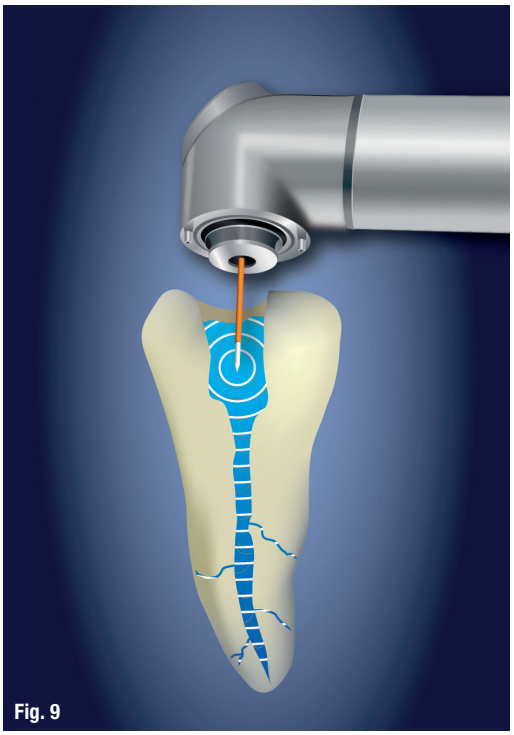
Fig. 9

**Fig. 8:** Fotona LightWalker® and PIPS® handpiece.
**Fig. 9:** PIPS® tip in orifice.

dicator that minimally invasive canal preparation might be possible because of the good cleaning effect of PIPS®, certainly always depending on the anatomic situation.

## PIPS®—the force awakens

The eradication of microorganisms and tissue from the root canal system must be the goal of every endodontic therapy. Complete removal of bacterial contamination was achieved only rarely so far due to complex anatomic canal structures and technology-related limitations. The development of PIPS® to reduce bacteria by laser-induced activation of irrigation fluid could have the crucial advantage over all currently known therapeutic procedures. The research results have been promising so far, but further studies should and will be conducted, in particular *in vivo* studies, to consolidate the positive trend. All endodontic treatment steps must be implemented in the therapy using PIPS®. However, the superior cleaning effect of PIPS® seems to realise two key advantages for dentists specialising in endodontics:

1. Improved cleaning effect of the canal systems, which will result in an improved success rate of endodontic therapies.
2. More substance-friendly preparation because of the better cleaning effect. This preserves the dental material, which again influences the fracture behavior of endodontically treated teeth directly.

The integration of PIPS® into a strictly antibacterial endodontic treatment concept might improve the therapeutic success of endodontic therapies again considerably. PIPS® will be in any case a clear evolution in endodontic treatment. Only the future can show whether the introduction of PIPS® will revolutionise endodontology in a similar way as the introduction of NiTi files. However, the force of laser-induced irrigation has awakened.




**Fig. 10:** Dentinal tubules after PIPS® application. Jaramillo et al. 2010.

*Editorial note: Initially published by dental journal edition 01/2016. A list of references is available from the publisher.*

## contact

**Dr Ralf Schlichting**
Specialist in endodontics
Dr.-Hans-Kapfinger Straße 30
94032 Passau
www.endo-dontie.de

### Kurz & bündig

Bei PIPS® (Photon Induced Photoacoustic Streaming) handelt es sich um eine photoakustische Spülmethode. Durch die Energie eines Er:YAG-Lasers werden nichtthermische photoakustische Schockwellen erzeugt, mit denen die Reinigungs- und Säuberungslösungen in den Kanal eingeführt werden. Nach dieser Behandlung sind die Kanäle und Seitenkanäle gereinigt und die Dentinkanälchen von der Schmierschicht befreit. Zu Beginn des Laserimpulses kommt es durch die rapide Erhitzung der Spülflüssigkeit zur Entstehung einer sich ausdehnenden Dampfblase. Je weiter sich diese Dampfblase ausdehnt, desto mehr kühlt sie sich ab, was letztlich zu ihrer Implosion führt. Dies führt zu folgenden Effekten im Wurzelkanal: Die Volumenänderungen der Dampfblase führen zu einer starken Flüssigkeitsbewegung im Wurzelkanal.[60] Die Implosion der „Bubble" ist ein sehr energiereicher Prozess. Es kommt zur Ausbildung von Schockwellen mit großer Amplitude und zur Ausbildung von „micro-jets". Nahe von Oberflächen kommt es zum Aufbau von Scherspannungen (primäre Kavitation).[61] Neben der primären Kavitation kommt es durch Ausbildung nachfolgender, kleinerer „Bubbles" zu sekundären Kavitationsprozessen (Bild 7).[62] Diese durch Laser induzierten Effekte sind vom Absorptionsspektrum des endodontischen Spülmediums abhängig, das bedeutet, je besser die Absorption der Laserstrahlung durch ein bestimmtes Medium, desto höher der primäre und sekundäre Kavitationseffekt. NaClO 5,3 %, EDTA 17 % und Wasser haben annähernd dasselbe Absorptionsspektrum.

PIPS® ist ebenso wirksam als abschließende Spülung im Vorfeld der Obturation. Zur Anwendung von PIPS® in Ihrer Praxis benötigen Sie einen Fotona Er:YAG-Laser.

# Eleven tips for success in your dental clinic

## Part IV: ROI and PEST

**Author:** Dr Anna Maria Yiannikos, Germany & Cyprus

**Welcome to the fourth part** of the series Eleven tips for success in your dental clinic. Our new tips are about knowing how to choose the right investment for your clinic in order to have the greatest possible ROI!

Now what is ROI? ROI stands for the acronym Return on Investment. Let's explain the term a little bit further. It shows our clinic's ability to use its assets to generate profits. How many of you have bought a new equipment bursting with excitement and, six months later, had completely forgotten about it and never used it? How many of you bought an intra-oral camera and are still using it?

I will present to you now a very unique protocol that I use every time I purchase or I am thinking of purchasing new equipment or making an investment at my clinic. This protocol includes four components:

1. Patients
2. Your clinic
3. The environment
4. The actual investment.

Now, for example, you are thinking of buying a new piece of laser equipment:

### Observe your patients' needs

Which patient needs are we going to cover with laser treatments? Let's brainstorm a little bit more on this! By choosing a laser treatment instead of a conventional treatment, we can cover their needs for: minimal pain, minimal or no anaesthesia, no drill sound, less fear, anxiety or stress, minimal or no bleeding, faster healing, reduced postoperative complications, reduced chair time.

We are responsible to choose the investment with the highest ROI and we can do it by asking our patients for their needs based on an efficient protocol, for example by asking them questions such as: What are the most important treatments for you? Are you getting what you are expecting from us? What new treatments and trends are you interested in?

Never ever buy a new piece of technology because your friend/competitor/colleague has done it! Why? Because he does not have your patients. Please always remember this, it is very important!

Furthermore, you can assess your patients by yourself: What is your main target group? To which society groups do they belong? Are they afraid of the dental procedures or are they comfortable with them? Do you have a lot of patients and need to make more fillings in less time?

### Know thyself and thy clinic

You can achieve this by learning in which areas we should improve ourselves (clinic) and in which areas we are in advantage. We can do that by using a very essential tool every six or twelve months, the so-called SWOT analysis. This is composed of four elements: our strengths, weaknesses, opportunities and threats as dentists. And we have already talked about it in the first part of this series (please see laser 3/2015).

### Analyse your environment

The third component of the protocol that I would love to share with you is PEST analysis. PEST stands for political, economic, social and technological environment. By knowing potential problems in advance, you will be more prepared and capable of finding the correct solutions. By making effective use of PEST analysis, you ensure that what you are doing is positively aligned with the forces of change that are affecting our world. By taking advantage of change, you are

much more likely to be successful than if your activities oppose it. Good use of PEST analysis helps you to avoid taking action which is condemned to failure for reasons beyond your control.

PEST is useful when you start operating in a new country or region. Applying PEST analysis helps you to break free of unconscious assumptions, and helps you to quickly adapt to the realities of the new environment. Its four components include:

- Political aspects: government type and stability, regulation and de-regulation trends, social and employment legislation, tax policy and trade/tariff controls, environmental and consumer-protection legislation, likely changes in the political environment
- Economic aspects: stage of business cycle, current and projected economic growth, inflation and interest rates, unemployment and labor supply, labor costs, tax system (corporate tax: 10% in Cyprus), likely changes in the economic environment
- Socio-cultural aspects: population growth rate and age profile, population health, education and social mobility, and attitudes to these, population employment patterns, job market freedom and attitudes to work, press attitudes, public opinion, social attitudes and social taboos, socio-cultural changes
- Technological environment: impact of emerging technologies, impact of Internet, reduction in communications costs and increased remote working.

Some years ago, Cyprus held the monopoly in communication services, but now the prices have dropped dramatically since there are a lot of players in the market. For example changes, in the government policy may affect the nature of treatments that may be available, for example under the NHS. Changes in the economic climate can have a direct impact on the spending power of patients. The so-called 'feel good factor' amongst home owners when interest rates are low and house price inflation is high is one example of how the state of the economics affects the mood of consumers.

Social changes can also affect our practice. People are tending to work longer hours. This could have an effect on your practice opening hours. Or maybe there are many people in your area who are older than 60 years old and, as a consequence, there is an increased need to treat this group of people. Or there are less births and thus there is no need of orthodontists.

Technology has made a huge impact on our lives and the internet in our workplace. We need to raise

© CHOATphotographer /Shutterstock.com

the expectations of our patients, using for example Google advertisements, Facebook pages etc.

## Make an investment

The last element of this unique protocol is the investment itself. We should see to regaining our money for this investment, as well as when and how we can do that! I have designed a model that could assess whether a dental investment is both viable and profitable according to the data of each clinic. For this, I choose ROI and payback as parameters of assessment. You are going to learn how to choose your investment like an expert by applying the ELIT (Invest Like an Expert Table) table excel formula.

The above protocol is one of the tools that you can be taught by the DBA educational programme full courses and seminars, including how to design your own ELIT. In the next issue, we will reveal two brand new tips and practical solutions that will help you access new opportunities and potentials of your dental clinics and change the way you see and make business in dentistry. Until then, please remember that not only are you the dentist in your clinic, but you are also its manager and leader.

You can always send me your questions and request for more information and guidance at dba@yiannikosdental.com or via our Facebook account. Looking forward to our next trip of business growth and educational development!

## contact

**Dr Anna Maria Yiannikos**
Adjunct Faculty Member of AALZ
at RWTH Aachen University
Campus, Germany
DDS, LSO, MSc, MBA
dba@yiannikosdental.com
www.dbamastership.com

## Kurz & bündig

Im ersten Teil der Serie „11 Tipps zum wünschenswerten Erfolg in Zahnkliniken“ ging es darum, sich als Praxisinhaber intensiv mit den eigenen Fähigkeiten, Stärken und Schwächen auseinanderzusetzen. Der zweite Teil befasste sich im Anschluss mit der Suche nach dem idealen Praxismitarbeiter. Im dritten Teil ging es dann ganz um den Umgang mit den Patienten. Die Autorin zeigt den Lesern in fünf einfachen Schritten, wie sie ihr Terminmanagement optimieren können und auf unvermeidbare Verzögerungen und Wartezeiten reagieren.

Im nun vorliegenden vierten Teil befasst sich die Autorin damit, wie Zahnärzte ermitteln können, welche Investition in ihre Praxis sinnvoll ist. Das Akronym ROI umschreibt dabei den sogenannten Return on Investment, die Investitionsrentabilität. Anhand von vier Schritten lässt sich diese strategisch ermitteln, sodass eine gute Entscheidungsgrundlage für mögliche Investitionen gegeben ist. Diese vier Aspekte umfassen die Erwartungen und Bedürfnisse der Patienten, eine Stärken-Schwächen-Analyse der eigenen Person und Praxis, alle Faktoren im direkten und weiteren Praxisumfeld sowie die finanziellen Aspekte der Investition.

Bei Analyse des Praxisumfelds stehen vier Faktoren im Fokus: politische Aspekte, insbesondere der Gesetzgebung, wirtschaftliche Gesichtspunkte, soziokulturelle Einflüsse sowie der technologische Entwicklungsstand. Die Autorin erläutert alle Punkte ausführlich und gibt so einen Leitfaden zur Entscheidungsfindung. Seien Sie gespannt auf die nächste Ausgabe der *laser* international magazine of laser dentistry, in der Ihnen die Autorin zwei weitere Tipps für Ihren Praxiserfolg an die Hand gibt.

FORTBILDUNGSPUNKTE 16 FORTBILDUNGSPUNKTE

# Fascination of Laser in Munich

## 25th INTERNATIONAL CONGRESS OF THE DGL

## LASER START UP 2016

30 September — 1 October 2016
Munich | The Westin Grand hotel Munich


ORGANIZER/SCIENTIFIC CHAIR
Deutsche Gesellschaft für Laserzahnheilkunde e.V.
Klinik für Zahnerhaltung, Parodontologie und
Präventive Zahnheilkunde
Universitätsklinikum der RWTH Aachen
Pauwelsstraße 30 | 52074 Aachen | Germany
Tel.: +49 241 8088-164 | Fax: +49 241 803388-164
sekreteriat@dgl-online.de | www.dgl-online.de

ORGANIZATION
OEMUS MEDIA AG
Holbeinstraße 29 | 04229 Leipzig | Germany
Tel.: +49 341 48474-308 | Fax: +49 341 48474-290
www.oemus.com | event@oemus-media.de


REGISTRATION
www.dgl-jahrestagung.de | www.startup-laser.de



## Fax Reply +49 341 48474-290

I would like to receive further information on the:

☐ 25th International Congress of the DGL ☐ LASER START UP 2016

Title, Name, Prename

E-mail adress (for digital programme)

Stamp

laser 2/16

# 15th International WFLD Congress—Preview

## International laser summit in Nagoya, Japan

**Author:** Claudia Jahn, Germany

**From 17 to 19 July 2016, Nagoya** is going to host the 15th International WFLD Congress with Hajime Yamamoto and Isao Ishikawa as honorary presidents and Kenji Yoshida as the Chair of the Organising Committee. This year's theme is going to be "Light to brighten the future"—illustrating the society's endeavour to move away from traditional laser dentistry and dental care, towards new developments by incorporating light into both diagnosis and treatment.

### Research and dental practice

As the submission period has already ended in May 2016, the congress organisers are now finalising the congress programme which is composed of invited lectures, symposiums, workshops, oral and poster sessions as well as exhibitions and seminars. International laser specialists from both engineering and medical fields, including dentistry, will assemble to deliver lectures and presentations on the latest scientific findings in their fields: Thus, the preliminary keynote lectures include topics such as "Er:YAG Laser Supported Endodontic Retreatment" by Adam Stabholz (Israel), Aldo Brugnera Junior (Brazil) and Ambrose Chan (Australia), "Low Level Laser Therapy in Esthetic Dentistry" by Carlos de Paula Eduardo (Brazil), Kenji Yoshida (Japan), Norbert Gutknecht (Germany) and Samir Nammour (Belgium), and "Current Surgical and Therapeutic Uses with Future Prospects for $CO_2$ Lasers in Oral and Maxillofacial" by Toni Zeinoun (Lebanon) and Umberto Romeo (Italy). The WFLD2016 organisers hope that the diverse programme will promote further advancement of academic research and clinical applications, heralding "the beginning of a new development of medical devices and a new expansion of the industry in Japan".

### High scientific standards

Strict criteria and high standards were applied to reviewing the scientific abstracts. For example, all submissions with regard to research and studies on human or animal subjects must abide by the Declaration of Helsinki of the World Medical Association, which provides guiding principles for experimental procedures. Furthermore, they must be approved by an IRB (institutional review board). In addition, the WFLD2016 Programme Committee has established

**Fig. 1:** Nagoya, famous for its light illuminations, welcomes WFLD2016 with its theme „Light to brighten the future".

its own set of submission guidelines (please see congress homepage for further information).

## WFLD Basic Laser Certification

In order to give official accreditation for passing a test on the basic knowledge of laser dentistry, WFLD has developed a special Laser Certification course. Lecturers will be high-calibre international professionals who are well-experienced in dental laser applications.

## 15th anniversary in Japan

WFLD's history started in 1988 with the foundation of ISLD (International Society for Laser in Dentistry). In the same year, the first International Congress of Laser Dentistry was held in Tokyo, Japan. Ever since then, the society has been active as an international organisation for laser dentistry, holding its international congresses every two years in different locations. After 14 years, WFLD2016 is going to be the third congress taking place in Japan. Since 2002, the JSLD (Japanese Society for Laser Dentistry) has served as a full WFLD member. History is coming full circle as Hajime Yamamoto, professor emeritus at Tokyo Medical and Dental University and ISLD's first president, is this year's WFLD Congress president. Isao Ishikawa, professor emeritus at Tokyo Medical and Dental University and this year's second congress president, already was appointed congress president in 2002.

## Industry meets history

Nagoya is rich in both history and industry. Located at the centre of Honshu, Japan's main island, it is home to traditional industries such as ceramics and textiles as well as modern industrial branches like automobiles, aviation and machine tools. Not only does Nagoya thus play an important role in Japan's industry, but it also has become an international city of a population of 2.24 million people.

Nagoya's main sites mirror this dichotomy of history and modernism: On the one hand, Nagoya is famous for its castle. Crafted in 1612, its magnificent gold-plated kinshachi (tiger-headed dolphins) on the topmost castle roof are notoriously the most wonderful of all kinshachi in Japan. On the other hand, Nagoya hosted the World Design Expo in 1989, leading to aesthetic developments and modernisations in its infrastructure. A major aspect of these changes, which is still predominant today, is Nagoya's famous light illumination, creating a comfortable and safe atmosphere for citizens and visitors alike. This modern influence is also palpable in Nagoya's famous environment-friendly Oasis 21 area, combining parks, public and commercial facilities. Spaceship-Aqua, a modern-design shopping complex illuminated by large-scale LEDs and fed on well water, has become its flagship. Its axis pointing towards Nagoya Castle, this piece of modern architecture builds a bridge to Nagoya's ancient history.

## contact

**WFLD2016 Secretariat:**
**c/o Convention Linkage, Inc.**
Asahiseimei Bldg., 3–32–20, Sakae, Naka-ku,
Nagoya, 460–0008, Japan
Tel.: +81 52 2625070
wfld2016@c-linkage.co.jp

Online registration closes 8 July, 2016.

**Fig. 2:** Fountain and cherry-blossom trees in Nagoya.
**Fig. 3:** Nagoya Castle.
**Fig. 4:** Spaceship-Aqua in Oasis 21, one of Nagoya's design flagships.

Fig. 1 © katjen/Shutterstock.com

# "I want to spend the rest of my life studying light"

## Munich—Venue of the 25th DGL Congress

**Author:** Claudia Jahn, Germany

**Fig. 1:** The 25th International Annual Laser Congress of the DGL is held in Munich during the this year's last Oktoberfest weekend.

**Born in Munich,** legendary scientist Albert Einstein, made this quote in 1905, at a time when the nature of light was a highly discussed and controversial topic in modern physics and especially quantum physics. One hundred years later, the mechanisms of light have become an integral part in all aspects of society, science and especially medicine. This year's International Annual DGL Congress returns to Einstein's birthplace: From 30 September to 1 October 2016, Munich will be hosting the 25th anniversary of the event which will illuminate laser-light applications in dentistry.

### The city of dreams

The city of Munich is renowned for its relaxed and joyful way of life, its big heart, its green parks and its vast cultural landscape. Founded in 1158 as Apud Munichen—Latin for "Home of the Monks"—near a Benedictine monastery, Munich today is Germany's third-largest German community. With more than 1.4 million inhabitants, the Bavarian capital is home to 2 million people in its metropolitan area alone, among them more than 50,000 students at 13 different universities and enjoys a first-rate reputation as a competence centre for science and medicine. More than 90 museums, a rich theatre landscape and, of course, the typically Bavarian beer gardens will make sure that any visitor will find a place to pass the time. Contrarily to its monastic originals, this mixture makes for anything but a tranquil lifestyle.

However, Munich is also called the German city of dreams because of its romantic landscape and architecture. This includes the many buildings designed by

Fig. 2

Fig. 3

Fig. 4

Fig. 5

King Ludwig I, among them the Siegestor, the Königsplatz, and the Ruhmeshalle. Other famous Munich sites are the Old and New Town Halls, the Frauenkirche and Maximilianstraße, one of Munichs integral boulevards. Munich's modern architecture is exemplified by the Allianz Arena, the internationally renowned football stadium. In addition, Munich features an abundance of parks, among them the famous English Garden, which is bigger than New York's Central Park.

## More than beer: diverse industry

Munich's vast cultural landscape is balanced by its diverse industry. The city has become a centre of banking and finances as well as print, publishing and television. Furthermore, it features manufacturers of precision instruments, optical and electrical as well as high technology appliances, among them important branches of aerospace industry. In addition, you can find one of Europe's largest wholesale markets for vegetables, fruits and animal produce in Munich. And of course, finally, the Bavarian capital is home to several of Germany's largest breweries. Industry and Munich's general joy de vivre come together in celebrating the brewery sector every year with the famous Oktoberfest.

## Oktoberfest

Munich's Oktoberfest originally started as a celebration of the marriage between Crown Prince Ludwig and Princess Therese in 1810. The name Oktoberfest presumably was coined when these celebrations culminated in a grand horse race on 17 October in this year. More than 200 years later, Oktoberfest is still held at the original venue Theresienwiese, located in Munich's borough Ludwigsvorstadt-Isarvorstadt south-west of the city centre. In 2015, the site was visited by more than 6 million people from around the world. This year, even more visitors are expected.

## 25th International Annual DGL Congress

On this year's last Oktoberfest weekend, DGL will hold its 25th International Annual Congress in Munich. Parallely to LASER START UP, the 46th DGZI Congress, the 7th Munich Forum and the 5th Oral Hygiene Day, the two-day event will feature top-level speeches and workshops to enlighten its visitors on all aspects of modern laser dentistry. In addition, participants are invited to a culinary trip through Munich, combining sightseeing via the Munich tram, a diversity of culinary specialities and exclusive musical entertainment by a local DJ. For more information on the 25th International Annual DGL Congress, please visit www.dgl-jahrestagung.de.

**Fig. 2:** Siegestor.
**Fig. 3:** View on the Marienplatz with Munich's Frauenkirche and the new town hall.
**Fig. 4 & 5:** Beer-garden in the English Garden and traditional bavarian beer and brezel.

## contact

**DGL – Deutsche Gesellschaft für Laserzahnheilkunde e.V.**
Pauwelsstraße 30
52074 Aachen, Germany
Tel.: +49 2418088164
Fax: +49 241803388164
www.dgl-online.de

Fotona

## LA&HA Symposium review

The 6th Annual Laser & Health Academy Symposium took place in May at the Slovenian Alpine resort of Lake Bled. During the symposium more than 40 clinical experts from around the world presented the latest innovations and applications in the field of medical laser technology. The field of laser dentistry was well represented this year, with more than a dozen presentations on leading-edge topics such as TwinLight® treatments in periimplantitis, periodontitis and endodontics, as well facial aesthetics and sleep-disordered breathing treatment with NightLase®. And of course there were numerous opportunities for networking and socialising with lecturers and fellow participants.

The annual LA&HA Symposium is held to exchange research and education among medical professionals in the field of laser medicine, with a focus on practical instruction and presentations of the latest laser procedures and research. Over 400 participants attended at this year's meeting, which enjoyed an exceptionally high level of visitor engagement and positive feedback. For further information, visit www.laserandhealthacademy.com.

**Fotona**
**Stegne 7**
**1000 Ljubljana, Slovenia**
**www.fotona.com**

LASOTRONIX

## SMARTM dental diode laser – versatile and functional

LASOTRONIX is launching its new diode-based laser platform for dentistry, the SMARTM series. SMARTM is offered as a combination of two lasers in one package, providing a wide range of applications including microsurgery, dermatosurgery, endodontics, periodontology, whitening, pain therapy, biostimulation and PAD (photoactivated disinfection). Thanks to its thoughtful design that allows integration with the dedicated workstation or a dental unit, the SMARTM laser meets the needs of every dental office and assures perfect operation comfort. At the same time, the small size of this versatile device makes it very easy to carry around, enhancing portability. The laser unit also features a very advanced user interface, including an expandable database covering a set of predefined therapy protocols, which can be modified and assigned to a patient.

Combining two wavelengths (980 nm/10 W and 635 nm/400 mW) in one functional device, LASOTRONIX offers advanced dental laser services for all soft tissue procedures. If you want to join us and promote our innovative products, please kindly contact us.

**LASOTRONIX**
**ul. Żytnia 1**
**05-500 Piaseczno, Poland**
**www.lasotronix.pl**



Lasotronix
LASERS FOR GENERATIONS

PROTECT-Laserschutz

## New spectacles for diode laser in dentistry

The new laser safety spectacles ONTOR and WINDOR XL offer optimum protection during treatments with diode lasers (800–820 nm wavelength) in dentistry (also usable for Excimer- and UV-laser). The laser safety filter is characterised by an excellent colour view and certification according to DIN EN 207.
The model ONTOR can be used as spectacles for wearers of prescription glasses and offers additional wearing comfort due to a soft rubber cushion in the forehead area. The temples can be adjusted in temple length and angle. The eyewear is also available as model WINDOR XL. The aerodynamic spectacles convince with a wide field

of vision due to the wraparound lens and a perfect fit due to flexible sport temples and soft nose pads.
PROTECT-Laserschutz GmbH is a manufacturer of laser safety products, e.g. eyewear, curtains and barriers, as well as work safety products from Nuremberg.

**PROTECT-Laserschutz GmbH**
**Mühlhofer Hauptstraße 7**
**90453 Nuremberg, Germany**
**www.protect-laserschutz.de**

AD

Increasing number of pregnant

## Women seek dental care

A survey conducted by non-profit organisation Delta Dental Plans Association among over 1,300 parents of children aged 6–12 has shown that more expectant women in the US are paying attention to oral health, an important area of health that is frequently overlooked during pregnancy. According to the survey, the number of pregnant women going to the dentist has increased by nearly 7 per cent over the last year.

© Kzenon/Shutterstock.com

In 2015, 57.5 per cent of mothers in the US reported that they had visited the dentist during their pregnancy. The 2016 survey results show that the number has now increased to 63 per cent. Owing to hormonal changes, pregnant women are at an increased risk of developing dental conditions, including gingivitis and periodontitis. In order to avoid these diseases, expectant women should consult with a dentist on a regular basis.

Delta Dental Plans Association conducted the Children's Oral Health Survey between Dec. 16, 2015, and Jan. 14, 2016, among a nationally representative sample. The data was released to coincide with Pregnancy Awareness Month, which was established in 2008 to provide support for expectant women and their families and is celebrated annually during May. The campaign focusses on four key initiatives: education, exercise, nutrition and wellness, as well as nurture.

Brånemark performs first

## Osseointegration Surgery on amputee in US

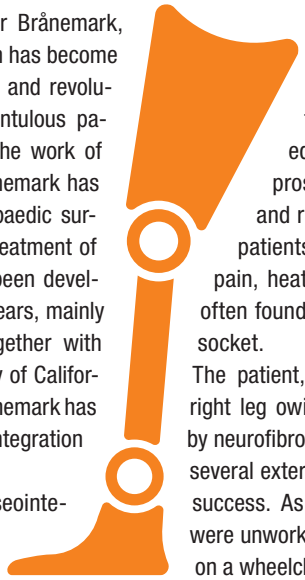

© Rauf Aliyev/Shutterstock.com

Discovered by Prof. Per-Ingvar Brånemark, the concept of osseointegration has become the basis for implant dentistry and revolutionised the treatment of edentulous patients worldwide. Continuing the work of his late father, Dr Rickard Brånemark has adapted the concept to orthopaedic surgery in order to improve the treatment of amputees. His approach has been developed and applied for over 20 years, mainly outside the US, however. Together with his colleagues at the University of California, San Francisco (UCSF), Brånemark has now performed the first osseointegration surgery in the country.

Similar to dental implants, Osseointegrated Prostheses for the Rehabilitation of Amputees (OPRA) consist of an external prosthesis anchored directly to the patient's remaining bone through a permanently implanted titanium screw. Therefore, the prosthesis always attaches correctly and remains firmly in place, preventing patients from suffering pressure sores, pain, heat, chafing and general discomfort often found with traditional solutions using a socket.

The patient, George Kocelj, lost most of his right leg owing to a rare nerve tumor caused by neurofibromatosis. The 54-year-old had tried several external prostheses before, but without success. As the sockets of these prostheses were unworkable for him, he largely had to rely on a wheelchair.

Dental tourism and lasers to fuel

## Growth of dental equipment market

Market research company Transparency Market Research has reported that the global dental equipment market is expected to reach US$7.6 billion by 2018, from US$5.5 billion in 2011, growing at a compound annual rate of 4.7 per cent from 2012 to 2018. Technological innovations and increasing awareness of dental hygiene are contributors to the segment's growth, but high initial costs for dental equipment remain. The report analyses different types of dental equipment, including dental radiology equipment, systems and parts, laboratory machines and hygiene maintenance devices.

Dental lasers are predicted to grow at an accelerated pace owing to the increasing adoption of minimally invasive surgical procedures that remove dental decay without harming the soft and hard tissue. The growing ageing population and the baby boomers are additional factors for the rising demand for dental procedures.

The full report is available for purchase at www.transparencymarketresearch.com/dental-devices-market.html. The Grand View Research report can be bought at www.grandviewresearch.com/industry-analysis/dental-equipment-market.

© ImageFlow/Shutterstock.com

Certain oral bacteria may indicate

## Increased pancreatic cancer risk

© Piotr Marcinski/Shutterstock.com

Researchers have found that the risk of developing pancreatic cancer is associated with specific bacteria in the mouth. They hope that the findings could enable earlier and more precise treatment of the disease. Other studies have shown that pancreatic cancer patients are susceptible to periodontal disease, cavities and poor oral health in general. Therefore, the research team at the NYU Langone Medical Center set out to search for direct links between the makeup of bacteria driving oral disease and subsequent development of pancreatic cancer. The researchers compared bacterial contents in mouthwash samples from 361 American men and women who had developed pancreatic cancer with samples from 371 people of matched age, sex and ethnic origin who did not. They found that men and women whose oral microbiome included *Porphyromonas gingivalis*, a major contributor to periodontal disease, had an overall 59 per cent greater risk of developing pancreatic cancer than those whose microbiome did not contain the bacterium. Similarly, people with oral microbiomes containing *Aggregatibacter actinomycetemcomitans*, which has been associated with severe periodontitis, were at least 50 per cent more likely overall to develop the disease. The findings were first presented on April 19 at the annual meeting of the American Association for Cancer Research in New Orleans.

How electronic cigarettes affect

## Oral health

New York researchers have received a grant to determine the adverse health effects of e-cigarette use on oral health for the first time. "Based on compelling data from our preliminary research, we hypothesise that e-cig aerosol mixtures disrupt the oral cavity's microenvironment, increasing vulnerability to periodontal disease," said Dr. Deepak Saxena from the New York University College of Dentistry, which was awarded a four-year $1.6 million grant by the National Institute of Dental and Craniofacial Research (NIDCR).

"Smoking is a major risk factor for periodontal diseases, immuno-suppression, and impairment of soft tissue and bone cell function," added co-researcher Dr. Xin Li. "The prospective study we proposed to the NIDCR entails the enrollment of 120 individuals."

The researchers will recruit and stratify members of the e-cigarette group by the type of disposable e-cigarette and number of cartridges they consume per week. "To determine the mechanism by which e-cig aerosol affects oral health we will design a novel 3-D epigingival tissue model to mimic the oral microenvironment," Li explained.


© Icon Craft Studio/Shutterstock.com

EU dentists concerned about

## Future of dentistry

On 20 and 21 May, representatives of member and observer organisations of the Council of European Dentists (CED) gathered for the first general meeting under the chairmanship of its new president, Dr Marco Landi, in The Hague/Netherlands. In addition to adopting policy statements on sugar, specialist dentists and dental amalgam, delegates expressed concerns about economic pressures affecting the profession.

© iQoncept/Shutterstock.com

According to Landi, the meeting elucidated the increase of commercial chains that in many European countries are changing dentistry in a direction that is motivated by short-term profits rather than quality. "I am concerned with the commercial drivers affecting patients' rights to receive dental health care in their best interests," he said. "The CED will be dedicating more resources to look into this issue."

Moreover, the association advocated new regulations for dental amalgam that restrict the use of the material to an encapsulated form and suggest the mandatory use of amalgam separators from 1 January 2019. The CED is a non-profit association that represents over 340,000 practising dentists from 30 European countries.

Tooth analysis finds advantages of

## Modern humans vs. Neanderthals

Dental microwear texture analysis involves the examination and analysis of wear features on tooth surfaces at a sub-micrometre scale. By assessing the type and degree of wear on 52 molars that were taken from the remains of European and Levantine individuals from 37 sites dating back to between 500,000 and 12,000 BP, the study examined the possible influence of dietary strategies on human development.

© Nicolas Primola/Shutterstock.com

The results show that the lineage was capable of adapting to severe fluctuations between climatic cycles of the Ice Age. However, while Neanderthals adapted their diet to the resources that were most readily available and easily accessible, modern humans seemed to have invested more effort in obtaining food resources with the help of tools, for example, for getting at roots in the soil. It is this use of new technology that may have given modern humans a crucial benefit over the Neanderthals, the researchers concluded.

The study, titled "Neanderthal versus modern human dietary responses to climatic fluctuations", was conducted by researchers from the University of Tübingen in cooperation with colleagues from the Max Planck Institute for Evolutionary Anthropology in Leipzig in Germany and Stony Brook University and the University of Arkansas in Fayetteville in the US. The results were published online on 27 April in the *PLOS ONE* journal.

Will India be the next

## Big dental market?

© rungkhun chansri/Shutterstock.com

The Indian dental care services market is estimated to experience a double-digit growth rate, reaching up to US$2.2 billion (147 bn. Indian rupees) by 2020. According to Ken Research, India has already witnessed a compound annual growth rate of 12 per cent for the period of 2010 to 2015 as dental awareness and disposable income have increased. Taking into account factors such as continued economic growth and reforms, India might have the potential to become the largest market for dental products and materials worldwide.

According to the Indian Dental Association, India's population of 1.2 billion had access to 180,000 dentists, including 35,000 specialists, in 2014. This number is projected to grow to 300,000 by 2018. Around 5,000 dental laboratories and 300 dental institutes currently provide basic and advanced oral health care. Expected growth in the number of dental chains will increase the share of organised dental clinics across the country. Although the vast majority of dental products are imported from Germany, the US, Italy and Japan, foreign companies continue to invest in India and establish production units. Most importantly, patient demand for better health care facilities has increased.

The publication, *India dental care service market outlook to 2020—Increasing awareness on oral care and rising number of organised players to foster future growth*, is available online at www.kenresearch.com. The report covers various aspects, such as market size, structure and segmentation, as well as the demographics of domestic and foreign customers.

Better treatment of

## Dry mouth disorders

A new study has now determined the previously largely unknown mechanism that triggers salivary secretion. The researchers from the University of Rochester Medical Center hope that the findings will help advance treatment for many diseases. In the study, the researchers focused on intracellular calcium, which is involved in the production and secretion of bodily fluids and regulates such processes as muscle contraction, neurotransmitter release, insulin secretion, and general such as gene expression, proliferation and cell death.

It is known that the presence of the inositol 1,4,5-trisphosphate (IP3) receptor is necessary to increase intracellular calcium. The researchers discovered that all four IP3 molecules are required to activate the channel for calcium to increase in a cell and initiate processes like fluid secretion. This ensures that the calcium channel only opens under strict conditions, avoiding harmful discharge that could kill cells, the researchers explained. The study, titled "Defining the stoichiometry of inositol 1,4,5-trisphosphate binding required to initiate $Ca^{2+}$ release," was published in the April issue of the *Science Signaling* journal. It was conducted in collaboration with the University of British Columbia in Canada.

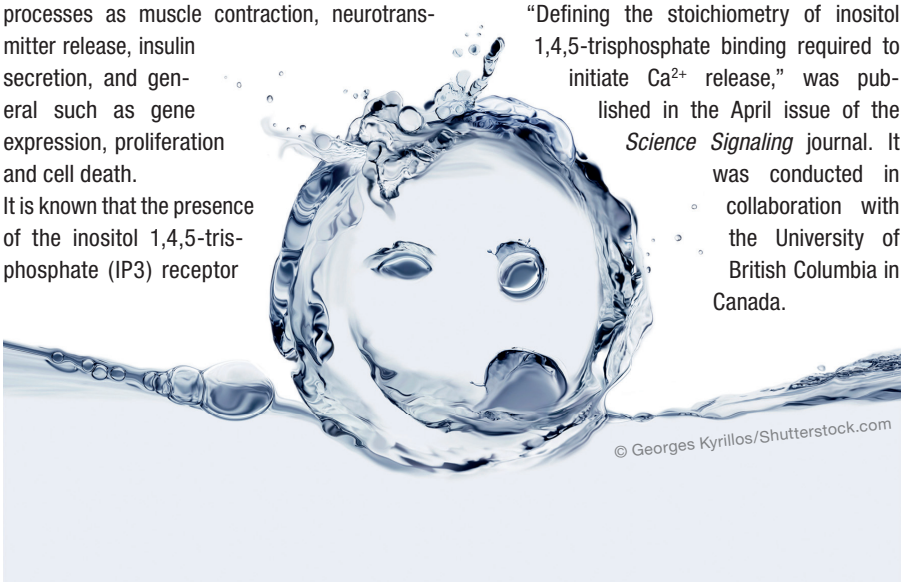

© Georges Kyrillos/Shutterstock.com

CROIXTURE

PROFESSIONAL MEDICAL COUTURE

NEW COLLECTION

EXPERIENCE OUR ENTIRE COLLECTION AT WWW.CROIXTURE.COM

# Introducing LASOTRONIX— lasers for generations

[Picture: © Lukas Maercik/Shutterstock.com]

**With more than twenty years** of experience in laser technology, LASOTRONIX covers a wide range of dental applications thanks to a variety of diode sources and therapy accessories. Cutting-edge technology is the trademark they all have in common: one unit is set to equal five different devices, making the use of $CO_2$, Nd:YAG, low-power diode lasers, PAD lamp or an ozone equipment as well as teeth whitening lamps. Applying the most powerful laser results in the shortest possible treatment time and low operating costs.

Only recently, LASOTRONIX has launched its new diode laser SMART™, especially designed for dentistry. Combining two laser wavelengths (635 nm/400 mW and 980 nm/10 W) enable achieving both photothermal and photobiochemical effects and cover all soft tissue procedures by one device.

Fast cutting and coagulation as well as "cold" stimulation and disinfection never was so easy and complex. In addition, accessories such as wide range of fibre delivery systems, application end tips and a variety of surgical handpieces provide maximum

versatility. As a result, SMART™ is suitable for a vast number of therapies, including microsurgery, endodontics, periodontology, whitening, biostimulation and photoactived disinfection.

The laser unit also features very advanced user interface including an expandable database covering a set of predefined therapy protocols, which can be modified and assigned to a patient. Its unique versatility makes SMART™ an essential asset to any modern dental office.

Lasotronix
LASERS FOR GENERATIONS

## contact

**LASOTRONIX**
ul. Żytnia 1
05-500 Piaseczno, Poland
Tel.: +48 22 7363434
Fax: +48 22 7373435
med@lasotronix.eu
www.lasotronix.pl

Return address
Deutsche Gesellschaft für Laserzahnheilkunde e.V.
c/o Universitätsklinikum Aachen
Klinik für Zahnerhaltung
Pauwelsstraße 30
52074 Aachen, Germany

Tel.: +49 241 8088164
Fax: +49 241 803388164
Credit institute: Sparkasse Aachen
IBAN: DE56 3905 0000 0042 0339 44
BIC.: AACSDE 33

# Membership application form (English)

Name/title: _____

Surname: _____

Date of birth: _____

Approbation: _____

Status: ☐ self-employed ☐ employed ☐ civil servant ☐ student ☐ dental assistant

## Address: Practice/office/institute (delete as applicable)

ZIP/city: _____ Street: _____

Phone/fax: _____ Email: _____

Private/place: _____ Street: _____

Due to an association agreement of DGL and DGZMK, an additional reduced annual fee for DGZMK is charged (€ 85 p.a. if you are not yet a member of DGZMK). The contribution collection is made by the DGMZK office, Liesegangstr. 17a, 40211 Düsseldorf, Germany. You will be addressed hereby.

With the application for membership I ensure that

☐ I am owing an own practice since _____ and are working with the laser type _____ (exact name)

☐ I am employed at the practice _____

☐ I am employed at the University _____

I apply for membership in the German Association of Laser Dentistry (Deutsche Gesellschaft für Laserzahnheilkunde e.V.)

_____

Place, date Signature

Annual fee: for voting members with direct debit € 150

In case of no direct debit authorisation, an administration charge of € 31 p.a. becomes due.

## DIRECT DEBIT AUTHORISATION

I agree that the members fee is debited from my bank account

Name: _____ IBAN: _____

BIC: _____ Credit institute: _____

Signature of account holder This declaration is valid until written notice of its revocation

16 FORTBILDUNGSPUNKTE

# Faszination Laser in München

## 25. INTERNATIONALE JAHRESTAGUNG DER DGL

## LASER START UP 2016

**30. September und 1. Oktober 2016**
**München | The Westin Grand München**

VERANSTALTER/WISSENSCHAFTLICHE LEITUNG
Deutsche Gesellschaft für Laserzahnheilkunde e.V.
Klinik für Zahnerhaltung, Parodontologie und
Präventive Zahnheilkunde
Universitätsklinikum der RWTH Aachen
Pauwelsstraße 30 | 52074 Aachen
Tel.: 0241 8088-164 | Fax: 0241 803388-164
sekreteriat@dgl-online.de | www.dgl-online.de

ORGANISATION
OEMUS MEDIA AG
Holbeinstraße 29 | 04229 Leipzig
Tel.: 0341 48474-308 | Fax: 0341 48474-290
www.oemus.com | event@oemus-media.de

ANMELDUNG
www.dgl-jahrestagung.de | www.startup-laser.de

## Faxantwort an 0341 48474-290

Bitte senden Sie mir folgendes Programm zu (Bitte ankreuzen):

☐ 25. Internationale Jahrestagung der DGL ☐ LASER START UP 2016

Titel, Name, Vorname

E-Mail-Adresse (Für die digitale Zusendung des Programmes.)

Praxisstempel

laser 2/16

Dr. Georg Bach

# Und es bewegt doch etwas!

Liebe Kolleginnen und Kollegen!

Als ich den Inhalt dieser Ausgabe, welche Sie nun in Händen halten, erstmals zu Gesicht bekam, fiel mir spontan der Satz des berühmten Galileo Galilei ein, das er beim Verlassen des Inquisitionsgerichtes gemurmelt haben soll, wo man ihn gezwungen hatte, dem kopernikanischen Weltbild abzuschwören: „Und sie bewegt sich doch!"

In Anlehnung an dieses weltberühmte Zitat würde ich Ihnen gerne zurufen: „Und es bewegt doch etwas – das Laserlicht!" und Ihnen dabei wärmstens die Lektüre dieser Ausgabe ans Herz legen. Ob Entfernung von Melaninhyperpigmentierungen, ob Behandlung rezidivierender Aphthen, oder Biomodulation von Geweben – wer will da noch ernsthaft die Sinnhaftigkeit und vor allem die Nachhaltigkeit laserunterstützter Anwendungen in der Zahnheilkunde infrage stellen? Auch wenn das direkte Umfeld – auch hier übrigens eine interessante Parallele zu Galilei und seiner Zeit – dieser Erkenntnis nicht immer wohlgesonnen gegenübersteht, steht für mich außer Frage, dass der Einsatz des monochromatischen und kohärenten Lichtes eine der ganz wesentlichen Erweiterungen des Therapiespektrums unserer Zahnheilkunde in den vergangenen Jahrzehnten darstellt, in der Tat ein therapeutisches Geschenk!

Als beredter Beweis hierfür möge Ihnen einerseits die vorliegende Ausgabe der *laser* international magazine of laser dentistry dienen. Wer jedoch mehr wissen und erfahren möchte, hat indes in den nächsten Wochen zwei ganz hervorragende Möglichkeiten dafür:

Gleich zwei Aktivposten der modernen Laserzahnheilkunde richten in den kommenden Wochen sehr schöne Veranstaltungen zur Laserzahnheilkunde aus. Da ist zum einen der 15. WFLD Congress in Japan zu nennen, und dann im Herbst der bereits 25. (Jubiläums-) Kongress der DGL. Beide mit bedeutenden Referenten bestückte Veranstaltungen bieten Gewähr für ein hervorragendes wissenschaftliches Programm in einem jeweils hochattraktiven Umfeld. Nutzen Sie diese Gelegenheiten!

Und so wünsche ich Ihnen zunächst viel Spaß und Erkenntnisgewinn beim Lesen der aktuellen Ausgabe der *laser* und ferner auch, dass Laserlicht auch bei Ihnen und in Ihrer täglichen Arbeit etwas „bewegen" möge!

In diesem Sinne grüße ich Sie herzlich und kollegial!

Ihr

Dr. Georg Bach

20. Jubiläum:

# LASER START UP 2016 in München

Save the Date
30. September/
1. Oktober

Abb. 1

Abb. 2

Abb. 3

Programm

**Abb. 1:** Tagungsleiter Dr. Georg Bach. – **Abb. 2 und 3:** Expertenworkshops vermitteln relevante praktische Aspekte der Laserzahnmedizin.

Am 30. September und 1. Oktober 2016 findet im Münchner Hotel The Westin Grand zum 20. Mal der LASER START UP statt. Die Einsteigerveranstaltung für künftige Laser-Anwender kehrt damit auch räumlich in gewisser Weise an ihren Ursprung zurück, denn genau vor zwanzig Jahren war in München der Auftakt für diese erfolgreiche Kongressreihe, die heute in Kooperation und unter wissenschaftlicher Leitung der Deutschen Gesellschaft für Laserzahnheilkunde (DGL) e.V veranstaltet wird. Die Tagungsleitung liegt auch in diesem Jahr in den Händen von Dr. Georg Bach/Freiburg im Breisgau.

Der Einsatz von Laserlicht besitzt in der Humanmedizin einen sehr hohen Stellenwert. Wenn sich angesichts dieses schier unbegrenzten Indikationsspektrums der Laser hingegen in unseren Zahnarztpraxen noch nicht komplett und flächendeckend etabliert hat, so gab es dafür in der Vergangenheit im Wesentlichen zwei Gründe: Zum einen gab es keine universell einsetzbare Lasergerätschaft für alle Anwendungen in der Zahnheilkunde und zweitens waren Laser im Vergleich zu herkömmlichen Instrumenten relativ teuer. Die aktuellen Dentallaser jedoch sind flexibel, leistungsfähig und letztlich wirtschaftlich. Weiterhin gilt: Der Laser kann in der Zahnmedizin in der Regel nichts, was nicht auch mit konventioneller Therapie erreichbar wäre. Aber, und das ist entscheidend, der Laser kann vieles einfacher, schneller und im Verhältnis von Aufwand und Ergebnis deutlich wirtschaftlicher. Genau hier liegt eine ganz wesentliche Chance für einen Lasereinsatz, und was das technische Niveau und die Vielfalt der Einsatzmöglichkeiten anbelangt, waren Dentallaser noch nie so perfekt und ausgereift wie heutige Gerätschaften.

Der LASER START UP 2016 wird in diesem Zusammenhang fachliche Grundlagen in Form von wissenschaftlichen Vorträgen und Hands-on-Kursen vermitteln sowie einen Überblick über die für dieses spezielle Therapiegebiet relevanten Produkte und Anbieter geben.

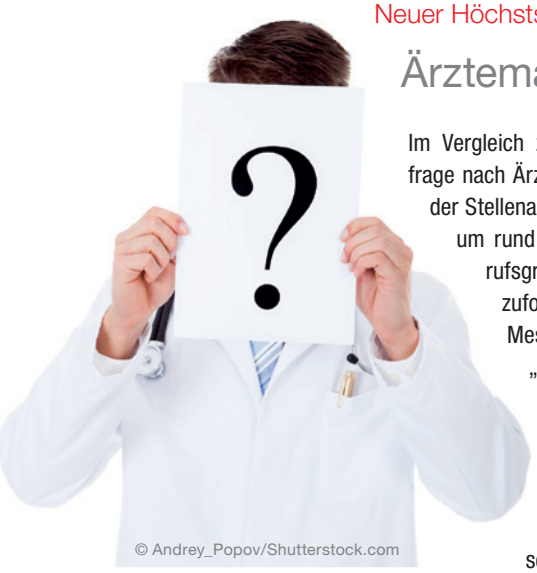
© Andrey_Popov/Shutterstock.com

Neuer Höchststand bei

# Ärztemangel in Deutschland

Im Vergleich zum Vorjahreszeitraum stieg die Nachfrage nach Ärzten um mehr als 14 Prozent, die Anzahl der Stellenausschreibungen für Pflegepersonal sogar um rund 35 Prozent. Damit erreichen beide Berufsgruppen dem StepStone Fachkräfteatlas zufolge neue Höchststände seit Beginn der Messung im Jahr 2012.

„Diese Entwicklung wird sich zukünftig noch verschärfen. Der demografische Wandel sorgt für ein weiter steigendes Patientenaufkommen. Doch schon heute können längst nicht alle offenen Stellen mit qualifiziertem Personal besetzt werden. Arbeitgeber im Gesundheitsbereich befinden sich mittendrin im ‚War for Talents'", erklärt StepStone Arbeitsmarkt-Expertin Dr. Anastasia Hermann. Jeder zweite Arzt und jede zweite Pflegefachkraft nimmt an, bei Bedarf innerhalb von nur drei Monaten eine passende neue Stelle zu finden.

Bei einem Jobwechsel erwarten sieben von zehn Ärzten und Pflegefachkräften ein höheres Gehalt. Mehr als jeder Zweite wünscht sich mehr inhaltliche und organisatorische Freiheiten. Gerade bei Positionen, die aufgrund von tariflichen Bestimmungen wenig Handlungsspielraum bei Gehaltsfragen lassen, kann Gestaltungsfreiheit im Job daher ein entscheidendes Argument sein.

**Quelle: ZWP online**

Mehr Aufmerksamkeit für

## Parodontale Gesundheit

Nachdem die Briten aufgrund ihrer desaströsen Zähne immer wieder in den Fokus lokaler Medien rückten, startete nun die BSP, die British Society of Periodontology, unter dem Claim #howsyoursmile eine landesweite Kampagne, um Menschen verstärkt für das Thema

Zahnfleischerkrankungen und die in diesem Zusammenhang stehenden Auswirkungen auf die Gesundheit zu sensibilisieren.
Die Initiatoren der innovativen Medienkampagne griffen dabei auch auf die Macht der sozialen Netzwerke zurück und machten sich diese geschickt zunutze. In Pubs, Praxen und an Universitäten wurden sogenannte Face Cards verteilt, die ausgeschnitten werden und zeigen sollen, wie Menschen mit Parodontose aussehen können. Neben der Face Cards Kampagne, die sich vorrangig auf Facebook großen Interesses erfreut, läuft auch eine landesweite Videokampagne in Einkaufszentren und an Haltestellen.
Parodontitis ist nicht zu unterschätzen – 45 Prozent der Briten leiden an dieser Erkrankung. Daher erhofft man sich von der Kampagne, dass diese das Bewusstsein für regelmäßige Mundhygiene und den Zahnarztbesuch schärft.

**Quelle: ZWP online**

Zahnfleischentzündung hemmt

## Positive Effekte von Sport

Schlechte Mundhygiene wirkt sich in vielen Fällen negativ auf die Gesundheit des gesamten Körpers aus. Eine neue Studie hat jetzt herausgefunden, dass Zahnfleischentzündungen sogar die positiven Effekte von Sport ganz und gar zunichtemachen können.
Je älter wir werden, desto mehr verkürzt sich die DNA, die für die Erneuerung unserer Zellen zuständig ist. Ausreichend Sport kann diesen Prozess jedoch deutlich verlangsamen oder sogar ganz stoppen und sich positiv auf unser biologisches Alter auswirken. Dadurch bleiben wir länger jung und fit. Bei Untersuchungen konnte Prof. Jörg Eberhard allerdings feststellen, dass sich die DNA bei Personen, die zwar Sport treiben, gleichzeitig aber auch Parodontitis aufweisen, genauso schnell verkürzt wie bei den sogenannten Couch-Potatos. Im Gegensatz zur Kontrollgruppe, ebenfalls sportlich, aber mit einer tadellosen Mundgesundheit. Effektive Zahnpflege hält also nicht nur gesund, sondern auch jung.

**Quelle: ZWP online**

© Frank Fiedler/Shutterstock.com

Plaque enthält

## Mehr DNA als Zähne oder Knochen

Wissenschaftlern des American Journal of Physical Anthropology ist es gelungen, aus 700 Jahre alten Plaque DNA zu sequenzieren. Damit haben sie nicht nur eine neue Möglichkeit gefunden, Rückschlüsse auf das Leben im Mittelalter zu finden, sondern auch eine zuverlässige Quelle, die mehr DNA enthält als Zähne oder Knochen.



© Artem Musaev/Shutterstock.com

Was für den Zahnarzt ein Albtraum ist, entpuppt sich einer neuen Studie zufolge als wahrer Schatz für Anthropologen: Plaque. Die unliebsame Ablagerung an den Zähnen besteht nicht nur aus Speiseresten und Bakterien, sondern konserviert in Kombination mit Speichel auch die menschliche DNA. Die Versteinerung beginnt schon zu Lebzeiten, wenn sie nicht regelmäßig entfernt wird.
Zum Glück, für die Forscher, war die Zahnpflege vor 700 Jahren noch nicht weit fortgeschritten, sodass Plaque mit ausreichend menschlicher DNA noch heute vorhanden ist. Die Wissenschaftler können aus den gewonnenen Erkenntnissen Rückschlüsse auf Populationen und Migrationen ziehen, die bis dato unbekannt waren.

**Quelle: ZWP online**

Lasergestützter Ansatz zur

## Schmerzfreien Antischnarchtherapie

Studien schätzen, dass ca. 45 Prozent aller Männer und 30 Prozent aller Frauen regelmäßig schnarchen. Was viele Patienten nicht wissen: Mit der laserbasierten und schonenden Antischnarchtherapie kann Abhilfe geschaffen werden. Die Antischnarchtherapie ist eine patentgeschützte, schnelle, noninvasive und schonende Methode, um die Schlafqualität von Patienten zu verbessern. Sie mindert die Gefahr eines Atemstillstands im Schlaf und reduziert Schnarchen durch die Nutzung von sanftem, oberflächlichem Er:YAG-Laserlicht. Die Therapie erfordert keine Hilfsmittel oder Geräte, die vom Patienten nachts getragen werden müssen, keine Behandlung mit Medikamenten und keine Anästhetika. Um ihre Indikationen um die Antischnarchtherapie erweitern zu können, benötigen Zahnärzte einen Fotona Er:YAG-Laser. Henry Schein bietet Hands-on-Trainings zur Antischnarchtherapie, um sich mit dem Therapieablauf vertraut zu machen. Hier werden die richtige Anwendung der neuen Therapieform sowie überzeugende Patientenkommunikation vermittelt. Nähere Infos unter: www.henryschein-dental.de

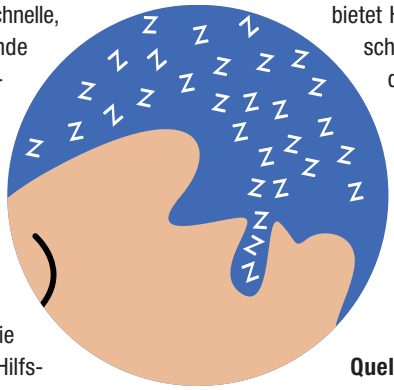

© emily vector/Shutterstock.com

**Quelle: ZWP online**

Analyse des Fraunhofer Insituts lässt

## Duromere durch Laser sprengen

Duromere konnten sich in den vergangenen Jahrzehnten zu Hochleistungswerkstoffen entwickeln. Zu verdanken haben sie dies hauptsächlich den eingesetzten Harzen und Härtern. Wissenschaftler des Fraunhofer-Instituts für Betriebsfestigkeit und Systemzuverlässigkeit LBF haben nun, basierend auf der Expertise in der Polymertechnik, eine Analytik erarbeitet, mit der sie die verwendeten Harze und Härter in Duromeren erstmalig chemisch charakterisieren können.
Zur Identifizierung der verwendeten Harze und Härter haben die Wissenschaftler des Fraunhofer LBF die „Matrix-freie Laser Desorption/Ionization Time-of-Flight Mass Spectrometry“, kurz LDI-ToF-MS evaluiert. Bei diesem Ansatz „sprengen“ die Wissenschaftler mit einem intensiven Laserimpuls Fragmente aus dem Netzwerk des Duromers heraus. Mit der LDI-ToF-MS steht nun eine Analytik zur Verfügung, die es kunststoffverarbeitenden Unternehmen und Anwendern ermöglicht, ihre Duromere am Fraunhofer LBF charakterisieren zu lassen. Auf diese Weise ergeben sich im Schadensfall neue Wege bei der Ursachenfeststellung, beispielsweise ob die eingesetzten Harze oder Härter bei einem Materialversagen mit der Ausgangscharge chemisch identisch sind. Darüber hinaus können Unternehmen ihre Produkte verbessern oder neuartige Duromere entwickeln.

© Fraunhofer LBF

Gebündeltes Expertenwissen:

## Jahrbuch Laserzahnmedizin 2016

Mit der umfassend überarbeiteten und erweiterten 17. Auflage des Jahrbuchs Laserzahnmedizin legt die OEMUS MEDIA AG das aktuelle Kompendium zum Thema Laser in der Zahnarztpraxis vor. Renommierte Autoren aus Wissenschaft, Praxis und Industrie informieren im Jahrbuch Laserzahnmedizin 2016 über die Grundlagen der Lasertechnologie und geben Tipps für den Einstieg in diesen Fachbereich der Zahnmedizin sowie dessen wirtschaftlich sinnvolle Integration in die tägliche Praxis. Darüber hinaus sind die im Jahrbuch enthaltenen aktuellen wissenschaftlichen Beiträge auch für jeden Laseranwender von Interesse. Etliche Fallbeispiele und zahlreiche Abbildungen dokumentieren die breite Einsatzmöglichkeit der Lasertechnologie. Relevante Anbieter stellen ihr Produkt- und Servicekonzept vor. Thematische Marktübersichten ermöglichen die schnelle Information über $CO_2$-, Er:YAG-, Nd:YAG- und Diodenlaser. Präsentiert werden bereits eingeführte Produkte sowie Innovationen, die helfen können, neue Potenziale zu erschließen.
Bei allen von der OEMUS MEDIA AG organisierten Veranstaltungen zum Thema Laserzahnmedizin erhalten die Teilnehmer das Jahrbuch Laserzahnmedizin kostenfrei.
Das Jahrbuch Laserzahnmedizin 2016 ist derzeit zum Preis von 49 Euro (zzgl. MwSt. + Versand) im Onlineshop erhältlich: **www.oemus-shop.de/jahrbücher**. Die Neuauflage, das Jahrbuch Laserzahnmedizin 2017, wird anlässlich des diesjährigen DGL-Kongresses am 30. September und 1. Oktober in München erscheinen.

Antwort:
Deutsche Gesellschaft für Laserzahnheilkunde e.V.
c/o Universitätsklinikum Aachen
Klinik für Zahnerhaltung
Pauwelsstraße 30
52074 Aachen

Tel.: 0241 8088164
Fax: 0241 803388164
E-Mail: sekretariat@dgl-online.de
Bank: Sparkasse Aachen
IBAN: DE56 3905 0000 0042 0339 44
BIC: AACSDE33

# Aufnahmeantrag (Deutsch)

Name/Titel: _____

Vorname: _____

Geb.-Datum: _____

Approbation: _____

Status: ☐ selbstständig ☐ angestellt ☐ Beamter ☐ Student ☐ ZMF/ZAH

## Adresse: Praxis/Dienststelle/Institut (Unzutreffendes bitte streichen)

PLZ/Ort: _____ Straße: _____

Telefon/Fax: _____ E-Mail: _____

Privat/Ort: _____ Straße: _____

Aufgrund des bestehenden Assoziationsvertrages zwischen der DGL und der DGZMK fällt zusätzlich ein reduzierter Jahresbeitrag für die DGZMK an (85,00 € p.a., falls Sie noch nicht Mitglied der DGZMK sind). Der Beitragseinzug erfolgt durch die DGZMK-Geschäftsstelle, Liesegangstr. 17a, 40211 Düsseldorf. Sie werden hierfür angeschrieben.

Mit der Stellung dieses Aufnahmeantrages versichere ich, dass ich

☐ seit dem _____ in der eigenen Praxis
mit einem Laser des Typs _____ arbeite. (genaue Bezeichnung)

☐ in der Praxis _____ beschäftigt bin.

☐ in der Abt. der Universität _____ beschäftigt bin.

Ich beantrage die Aufnahme in die Deutsche Gesellschaft für Laserzahnheilkunde e.V.

_____

Ort, Datum vollständige Unterschrift

**Jahresbeitrag:** Für stimmberechtigte Mitglieder bei Bankeinzug **150,00 €**.

Sofern keine Einzugsermächtigung gewünscht wird, wird ein Verwaltungsbeitrag von 31,00 € p.a. fällig.

## EINZUGSERMÄCHTIGUNG

Ich bin einverstanden, dass der DGL-Mitgliedsbeitrag von meinem Konto abgebucht wird.

Name: _____ IBAN: _____

BIC: _____ Geldinstitut: _____

_____

Unterschrift des Kto.-Inhabers Diese Erklärung gilt bis auf schriftlichen Widerruf

BI-TRE-Projekt für lasergestützten

## Wundverschluss in der Oralchirurgie

Mit Partnern aus Deutschland, Israel, Lettland und der Toscana wird im Projekt „Biophotonic Technologies for Tissue Repair BI-TRE“ der Einsatz biophotonischer Technologien im industriellen, klinischen und medizinischen Bereich konsequent vorangetrieben. Eine dichte Wundabdeckung, ein zuverlässiger Schutz vor eindringenden Keimen als auch ein haftender Verband ist im Mund-Rachen-Raum auch heutzutage immer noch ein ungelöstes Problem der Oralchirurgie. Durch den im BI-TRE-Projekt erforschten Ansatz zur Wundabdeckung mit Kollagenmembranen, welche lasergestützt an der Schleimhaut befestigt werden, wird eine neue Lösung erarbeitet. Behandlungskosten und Behandlungszeit lassen sich erheblich reduzieren, dem Patienten kann eine Transplantation auf diese Weise erspart werden.

Die Anpassung der Laserstrahlquelle, die Konstruktion eines speziellen Handstücks, die Entwicklung geeigneter Wundauflagen und die Integration einer Temperatursensorik sind notwendige Voraussetzungen zur erfolgreichen Realisierung des Ansatzes. Innerhalb des Projekts übernimmt das Fraunhofer-Institut für Lasertechnik ILT die Projektkoordination sowie die Prozessentwicklung für die erfolgreiche Laserfixierung einer Kollagenmembran. BI-TRE wird durch das Bundesministerium für Bildung und Forschung BMBF gefördert, Projektträger ist das VDI Technologiezentrum.

**Quelle: ZWP online**

Neue Lasertherapie zur

## Verhinderung von Zahnausfall

Eine neue Lasertherapie könnte jetzt dabei helfen, bereits lockere Zähne wieder fest zu verankern. Die Behandlung soll schlechte Bakterien abtöten und gleichzeitig die Knochenbildung anregen. Perioblast (Periodontal Biological Laser-Assisted Therapy) wurde von Dr. Francesco Martelli, einem Kieferchirurgen aus Florenz, entwickelt und bereits erfolgreich angewendet. Mithilfe des Lasers werden die Bakterien abgetötet, die für Zahnfleischblutungen verantwortlich sind. Gleichzeitig werden Zellen angeregt, die Knochenbildung voranzutreiben, um den betroffenen Zahn wieder stabiler im Kiefer zu fixieren. Eine Studie mit 2.683 Patienten, die Anfang des Jahres im European Journal of Clinical Microbiology & Infectious Diseases veröffentlicht wurde, konnte bereits erste vielversprechende Ergebnisse liefern. Demzufolge wurde schon nach drei Sitzungen eine Reduzierung der Bakterien festgestellt. Umgerechnet 6.000 bis knapp 9.000 Euro soll die Behandlung kosten. Und auch danach gibt es keine Garantie für eine langfristige Besserung. Ob eine solche Lasertherapie also besser ist als eine regelmäßige professionelle Zahnreinigung, muss nach Angaben der Experten erst noch weiter getestet werden.

**Quelle: ZWP online**

© zlikovec/Shutterstock.com

Spezialisten-Newsletter zum

## Themenschwerpunkt Laserzahnmedizin

Neben den bereits bestehenden Newslettern hat ZWP online das Angebot an monatlichen Updates zu Spezialthemen der Zahnmedizin erweitert. Gerade für Spezialisten ist es unausweichlich, im eigenen Tätigkeitsschwerpunkt immer auf dem aktuellsten Stand zu sein. Die Informationsbeschaffung und -selektion ist im normalen Praxisalltag angesichts der allgemeinen Informationsflut nicht immer ganz so einfach. Hier setzen die Spezialisten-Newsletter von ZWP online an, die zusätzlich zu dem bereits bestehenden Newsletter-Portfolio erscheinen. Die Spezialisten-Newsletter unterscheiden sich in Layout und Struktur, aber vor allem durch ihre thematische Fokussierung, vom sonstigen Angebot. Darüber hinaus enthalten sie neben Nachrichten ein thematisches Video sowie die E-Paper-Verlinkung zur aktuellen Ausgabe der entsprechenden Fachpublikation der OEMUS MEDIA AG. Diese Newsletter bieten in einem spezialisierten redaktionellen Umfeld interessierten Unternehmen eine ideale Plattform zur Präsentation von Produkten und Veranstaltungen sowie sonstigen marktrelevanten Informationen.

# Jahrbücher 2016

*Preise verstehen sich zzgl. MwSt. und Versandkosten (Kein Rückgaberecht).

Jetzt bequem
**online bestellen**
**www.oemus-shop.de**

**OEMUS MEDIA AG**
Holbeinstraße 29
04229 Leipzig
Tel.: 0341 48474-0
Fax: 0341 48474-290
grasse@oemus-media.de

**Jahrbuch Laserzahnmedizin 2016**

____ Exemplar(e)

**Jahrbuch Prävention & Mundhygiene 2016**

____ Exemplar(e)

**Jahrbuch Endodontie 2016**

____ Exemplar(e)

**Jahrbuch Implantologie 2016**

____ Exemplar(e)

**Jahrbuch Digitale Dentale Technologien 2016**

____ Exemplar(e)

Praxisstempel

laser 2/16

# **Jetzt** bestellen!

## Faxantwort an 0341 48474-290

Bitte senden Sie mir mein(e) Exemplar(e) an folgende Adresse:

Name ..... Vorname .....

Straße ..... PLZ/Ort .....

Telefon/Fax ..... E-Mail .....

Datum/Unterschrift .....

# laser

international magazine of laser dentistry

WFLD World Federation for Laser Dentistry
Formerly ISLD, founded 1988

oemus

dgl. Deutsche Gesellschaft für laser Zahnheilkunde e.V.

**Publisher**
Torsten R. Oemus
*oemus@oemus-media.de*

**CEO**
Ingolf Döbbecke
*doebbecke@oemus-media.de*

**Members of the Board**
Jürgen Isbaner
*isbaner@oemus-media.de*

Lutz V. Hiller
*hiller@oemus-media.de*

**Editor in Chief**
Norbert Gutknecht
*ngutknecht@ukaachen.de*

**Coeditors in Chief**
Samir Nammour
Matthias Frentzen

**Managing Editors**
Georg Bach
Leon Vanweersch

**Division Editors**
Umberto Romeo
*European Division*

Melissa Marchesan
*North American Division*

Carlos de Paula Eduardo
*South American Division*

Toni Zeinoun
*Middle East & Africa Division*

Ambrose Chan
*Asia & Pacific Division*

**Senior Editors**
Aldo Brugneira Junior
Kenji Yoshida
Lynn Powell
Dimitris Strakas
Adam Stabholz
Marcia Martins Marques

**Editorial Board**
Peter Steen Hansen, Aisha Sultan, Ahmed A Hassan, Antonis Kallis, Dimitris Strakas, Kenneth Luk, Mukul Jain, Reza Fekrazad, Sharonit Sahar-Helft, Lajos Gaspar, Paolo Vescovi, Ilay Maden, Jaana Sippus, Hideaki Suda, Ki-Suk Kim, Miguel Martins, Aslihan Üsümez, Liang Ling Seow, Shaymant Singh Makhan, Enrique Trevino, Blanca de Grande, José Correia de Campos, Carmen Todea, Saleh Ghabban Stephen Hsu, Antoni Espana Tost, Josep Arnabat, Alaa Sultan, Leif Berven, Evgeniy Mironov Ahmed Abdullah, Boris Gaspirc, Peter Fahlstedt, Ali Saad Alghamdi, Alireza Fallah, Michel Vock, Hsin-Cheng Liu, Sajee Sattayut, Anna-Maria Yannikou, Ryan Seto, Joyce Fong, Iris Brader, Masoud Mojahedi, Gerd Volland, Gabriele Schindler, Ralf Borchers, Stefan Grümer, Joachim Schiffer, Detlef Klotz, Jörg Meister, Rene Franzen, Andreas Braun, Sabine Sennhenn-Kirchner, Siegfried Jänicke, Olaf Oberhofer, Thorsten Kleinert

**Editorial Office**
Georg Isbaner
*g.isbaner@oemus-media.de*

Claudia Jahn
*c.jahn@oemus-media.de*

**Product Manager**
Timo Krause
*t.krause@oemus-media.de*

**Executive Producer**
Gernot Meyer
*meyer@oemus-media.de*

**Designer**
Sandra Ehnert
*s.ehnert@oemus-media.de*

Theresa Weise
*t.weise@oemus-media.de*

**Customer Service**
Marius Mezger
*m.mezger@oemus-media.de*

**Published by**
Oemus Media AG
Holbeinstraße 29, 04229 Leipzig, Germany
Tel.: +49 341 48474-0
Fax: +49 341 48474-290
*kontakt@oemus-media.de*
**www.oemus.com**

**Printed by**
Silber Druck oHG
Am Waldstrauch 1, 34266 Niestetal, Germany

*laser* international magazine of laser dentistry is published in cooperation with the World Federation for Laser Dentistry (WFLD).

**WFLD Headquarters**
University of Aachen Medical Faculty
Clinic of Conservative Dentistry
Pauwelsstr. 30, 52074 Aachen, Germany
Tel.: +49 241 808964
Fax: +49 241 803389644
*ngutknecht@ukaachen.de*
www.wfld-org.info

**www.laser-magazine.com**



## Copyright Regulations

*laser* international magazine of laser dentistry is published by OEMUS MEDIA AG and will appear in 2016 with one issue every quarter. The magazine and all articles and illustrations therein are protected by copyright. Any utilisation without the prior consent of editor and publisher is inadmissible and liable to prosecution. This applies in particular to duplicate copies, translations, microfilms, and storage and processing in electronic systems. Reproductions, including extracts, may only be made with the permission of the publisher. Given no statement to the contrary, any submissions to the editorial department are understood to be in agreement with a full or partial publishing of said submission. The editorial department reserves the right to check all submitted articles for formal errors and factual authority, and to make amendments if necessary. No responsibility shall be taken for unsolicited books and manuscripts. Articles bearing symbols other than that of the editorial department, or which are distinguished by the name of the author, represent the opinion of the afore-mentioned, and do not have to comply with the views of OEMUS MEDIA AG. Responsibility for such articles shall be borne by the author. Responsibility for advertisements and other specially labeled items shall not be borne by the editorial department. Likewise, no responsibility shall be assumed for information published about associations, companies and commercial markets. All cases of consequential liability arising from inaccurate or faulty representation are excluded. General terms and conditions apply, legal venue is Leipzig, Germany.

# laser

international magazine of laser dentistry

**You can also subscribe via www.oemus.com/abo**

## Subscribe now!

☐ I would like to subscribe to laser **international magazine of** laser dentistry (4 issues per year) for € 44 including shipping and VAT for German customers, € 46 including shipping and VAT for customers outside Germany, unless a written cancellation is sent within 14 days of the receipt of the trial subscription. The subscription will be renewed automatically every year until a written cancellation is sent to OEMUS MEDIA AG, Holbeinstr. 29, 04229 Leipzig, Germany, six weeks prior to the renewal date.

▶ **Reply** via Fax +49 341 48474-290 to OEMUS MEDIA AG or per E-mail to grasse@oemus-media.de

Last Name, First Name

Company

Street

ZIP/City/County

E-mail | Signature

Notice of revocation: I am able to revoke the subscription within 14 days after my order by sending a written cancellation to OEMUS MEDIA AG, Holbeinstr. 29, 04229 Leipzig, Germany.

Signature



OEMUS MEDIA AG
Holbeinstraße 29, 04229 Leipzig, Germany, Tel.: +49 341 48474-0, Fax: +49 341 48474-290, E-Mail: grasse@oemus-media.de

# LASER SMART™

## ...BE SMART...BE PART OF THE FUTURE!

## DOUBLE WAVELENGTH DIODE LASER

PERFECT CONFIGURATION FOR:

- PHOTOTHERMAL
- PHOTOCHEMICAL
- PHOTOBIOLOGICAL

... EFFECTS

**... JOIN US AND PROMOTE OUR UNIQUE INNOVATION**

Lasotronix
LASERS FOR GENERATIONS

+48 22 736 34 34
+48 500 100 131
MP@LASOTRONIX.PL
WWW.LASOTRONIX.COM