

# Dental Implants—Treatment Options for Compromised Clinical Situations

## Part I—The Edentulous Mandible

author\_ Suheil M. Boutros, USA

### \_Abstract

The patient who is totally edentulous in the mandible may not be able to consume a normal textured diet secondary to mobility of their denture. As they continue to lose alveolar bone height, the dislodgment pressure from the perioral musculature become greater than the retentive aspects of the prosthesis. This can cause discomfort, sores, and trauma to the mental nerve. The placement of endosseous implants into the anterior mandible is an excellent therapy for reconstruction, restoring these patients to a normal-textured diet, a normal nutritional intake, better health, and improved self-confidence.

The patient's options include a conventional denture, a tissue borne-implant-supported prosthesis, or implant-supported prosthesis. After an initial attempt to wear a conventional denture, many patients look forward to receiving implants because they are confident and comfortable with their decision to spend the money, dedicate the time, and deal with morbidity of implant surgery. In return, these patients often become easier to treat. Once the patient has made an informed decision after considering the recommendations of the implant team, the advantages of the different types of the prostheses, the financial responsibilities, and his or her personal desires and interests, surgery is scheduled.

Fig. 1\_Ball O-rings over-denture.

Fig. 2\_Zest locators over-denture.

Fig. 3\_Four implants locator supported over-denture.

Fig. 4\_Bar supported over-denture.

Fig. 5\_Clips in the over-denture.

Fig. 6\_Spark erosion milled supra-frame.

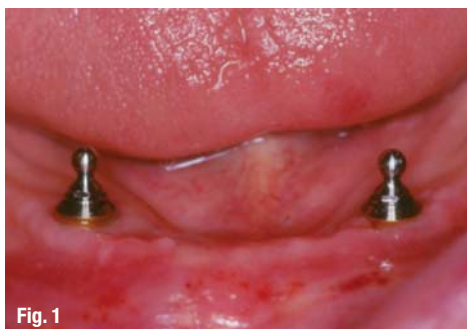

Fig. 1

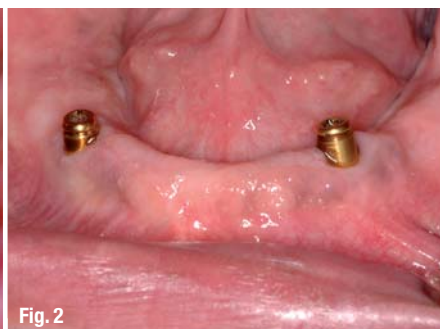

Fig. 2

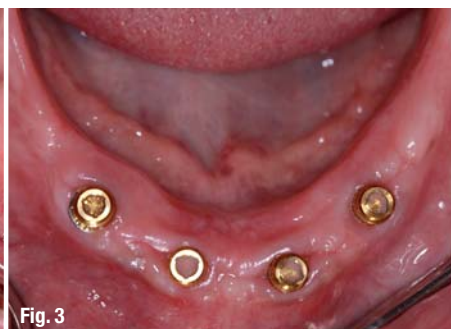

Fig. 3

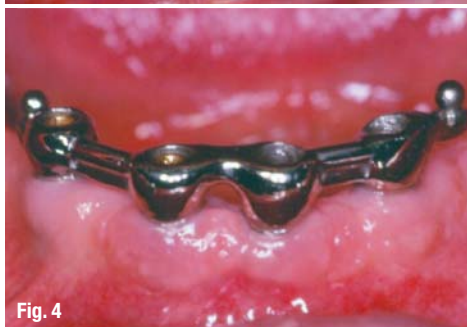

Fig. 4

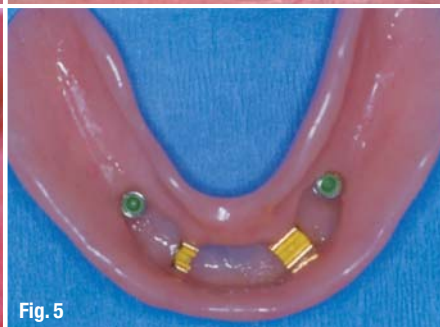

Fig. 5

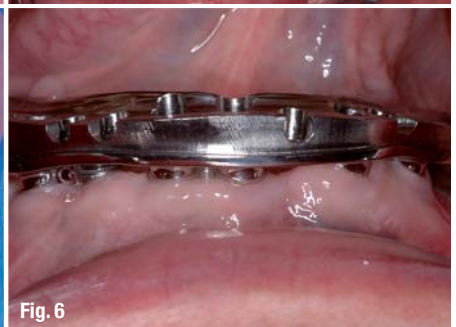
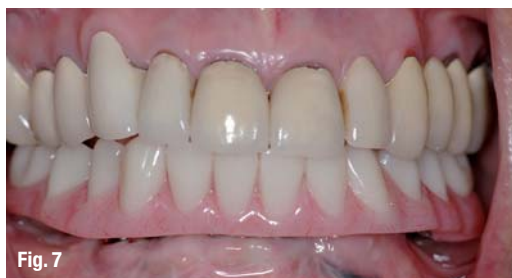
Fig. 6



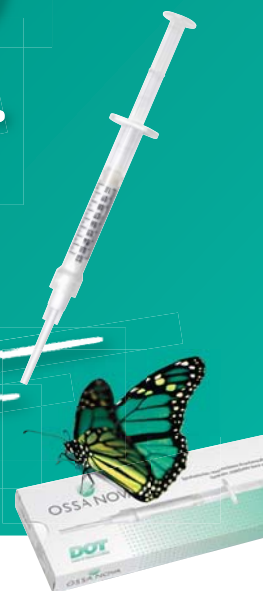### **Two implants (Implants retained tissue-borne prosthesis)**

Generally when placing two implants for an over-denture, consideration should be given to the potential need for additional implants at a later time, in case the patient decides to change from a tissue-borne prosthesis to an implant-supported prosthesis. There are patients who enjoy the over-denture prosthesis, but complain of food getting caught under the denture, mobility of the prosthesis when speaking, swallowing, or chewing, and desire to eliminate changing O-rings or locators. For those patients who wish to retain a fixed-removable prosthesis, two to three additional implants may be placed in the anterior mandible. This is sufficient to support an implant-borne prosthesis. In preparation for a tissue-borne prosthesis, two implants should be 20 mm apart. Each implant 10 mm apart from the midline of the anterior mandible allows for future implant placement. The attachment options are ball O-rings (Fig. 1) or Zest locators (Fig. 2). If better retention is desired, four implants over-denture is recommended (Fig. 3).

### **Four implants (Implant retained and supported prosthesis)**

The incision design is the same when placing four implants into the anterior mandible. The subperiosteal reflection should be sufficient to expose the lingual and labial cortices and the mental foramen bilaterally. After the periosteal reflection is completed, the surgeon has an excellent view of the operative site, the contours of the bone, and the location of the mental foramen. The mental foramen serves as the landmark to locate the distal implants. The most distal implants are placed at least five millimeters anterior to the mental foramen. A small round bur is used to place a depression in the bone to locate the implant site on one side of the mandible. A similar mark is placed on the opposite side of the mandible, a caliper is then set to seven to eight millimeters and the next implant locations are marked. If a fifth implant is to be placed, a mark is made in the midline of the mandible. The implant bodies are placed at a sufficient distance apart to ensure adequate space for restoration and hygiene (Figs. 4 and 5).

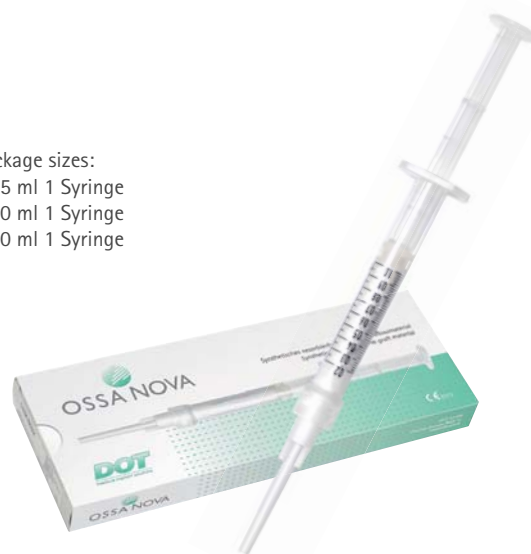Easy.  
Safe.  
Quick.



## **OSSA NOVA Bone Graft Material**

- easy and safe application with a syringe
- pasty consistency for optimal defect alignment
- distinct capillarity for uptake of body fluids
- Integration into the natural bone remodelling process
- unhindered wound healing
- safe material due to synthetic origin

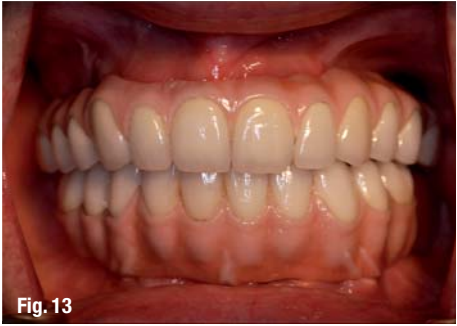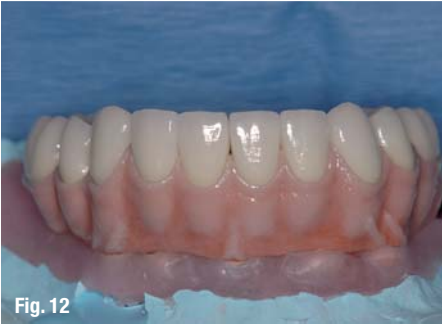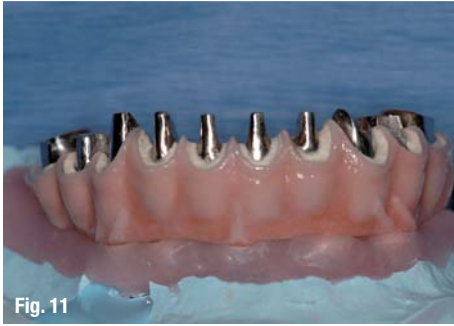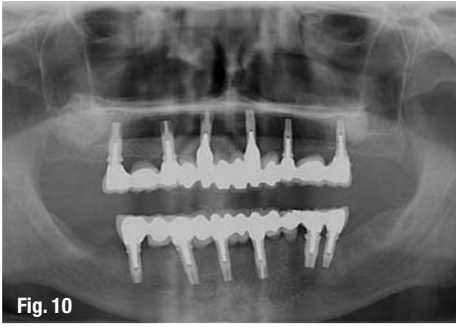
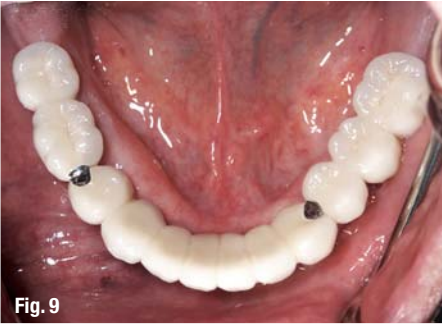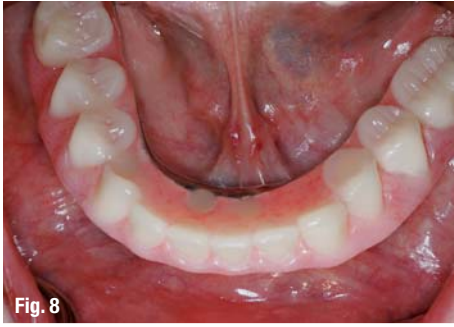Package sizes:  
0,25 ml 1 Syringe  
0,50 ml 1 Syringe  
1,00 ml 1 Syringe



DOT is a leading supplier of innovative solutions for dental and orthopedic implants.

DOT GmbH  
Charles-Darwin-Ring 1a  
D-18059 Rostock  
Germany  
Tel.: +49(0)381- 4 03 35-0  
Fax: +49(0)381- 4 03 35- 99  
biomaterials@dot-coating.de  
www.dot-coating.de

**DOT**  
medical implant solutions



**Fig. 7** Fixed detachable prosthesis.  
**Fig. 8** Fixed detachable prosthesis, occlusal view.  
**Fig. 9** The fixed partial denture.  
**Fig. 10** One year follow-up.  
**Fig. 11** Casted supra-frame.  
**Fig. 12** Porcelain fused to metal crowns.  
**Fig. 13** Final prosthesis, one year in function.

**\_Five implants fixed detachable (Implant supported and retained prosthesis)**

If the patient desires a fixed prosthesis, at least five implants are needed to support this structure. The most distal implants can support a small cantilever. This cantilever should not be longer than a tooth and a half or no more than 16–18 mm in length. In addition, the prosthesis should be at least two millimeters higher than the soft tissue to allow access for adequate oral hygiene. The metal framework can be casted or titanium-milled structure (Figs. 6, 7 and 8).

placement can be done predictably if there is adequate bone, otherwise bone grafting will be needed (Figs. 9 and 10).

The alternative to bone grafting is a supra-frame that compensates for the lost soft and hard tissue. In most cases, the supra-frame can be casted metal and the individual crowns can be porcelain fused to metal (Figs. 11, 12, 13, 14 and 15).

*References are available upon request.*

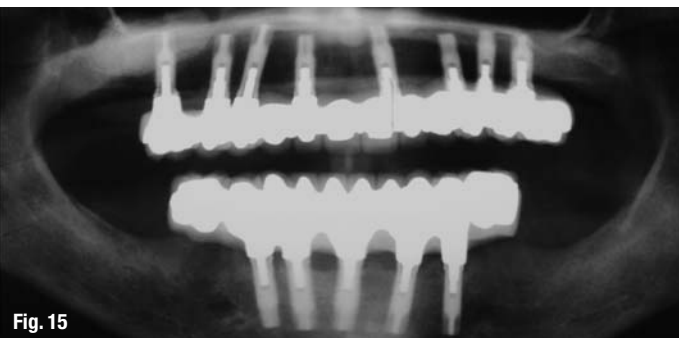
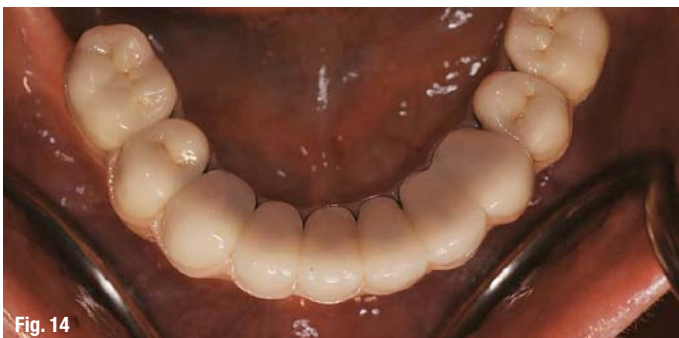In general, the prosthesis does not need to be removed; unless there is a need to access the fixtures, in that case the supra-structure can be removed by carefully removing the retaining screws.

**\_The Fixed Prosthesis**

When the patient wishes to have a fixed prosthesis that mimics their natural teeth, more implants are needed to be placed in the posterior region of the mandible, at least six to eight implants are required. In that case, the restoration can be porcelain fused to a metal fixed partial denture. This form of re-

|  |                 |
|--|-----------------|
| <b>_contact</b>  | <b>implants</b> |
| <p><b>Suheil M. Boutros, DDS, MS</b><br/>                 Assistant Prof, Department of Periodontics<br/>                 University of Michigan<br/>                 Periodontal Specialists of Grand Blanc<br/>                 8185 Holly Road, Suite 19<br/>                 Grand Blanc, MI 48439<br/>                 Phone: +1-810-695-6444<br/>                 Fax: +1-810-695-4414<br/>                 E-mail: sboutros@umich.edu</p> |                 |

**Fig. 14** Crowns cemented on sub-frame.  
**Fig. 15** One year follow-up.





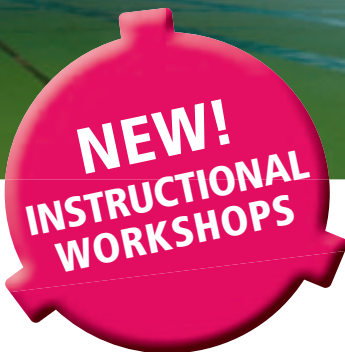


3<sup>RD</sup> INTERNATIONAL

# CAMLOG CONGRESS

JUNE 10<sup>TH</sup> – 12<sup>TH</sup>, 2010

STUTT GART LIEDERHALLE



FROM SCIENCE TO INNOVATIONS AND CLINICAL ADVANCES

## TOPICS

- Scientific and clinical advances, standard or platform switching restorations
- Restorative aspects and technical solutions
- Reports on current research
- Innovations in surgical site development
- Management of complications
- Meet the experts

## SCIENTIFIC COMMITTEE

Prof. Dr. Jürgen Becker, Dr. Sven Marcus Beschnidt, Prof. Dr. Dr. Rolf Ewers

Prof. Dr. Dr. Dr. Robert Sader, PD Dr. Frank Schwarz, Prof. Dr. Dr. Wilfried Wagner

Under the aegis of the

 camlog foundation

More information and registration: [www.camlogcongress.com](http://www.camlogcongress.com)