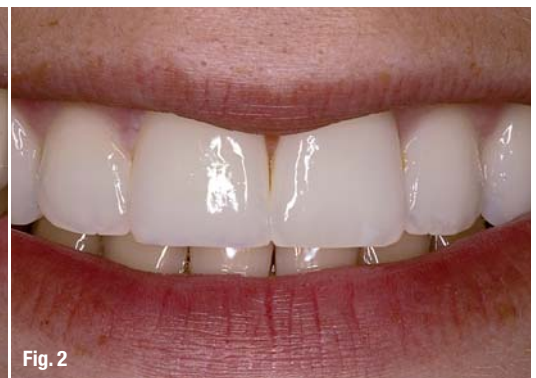
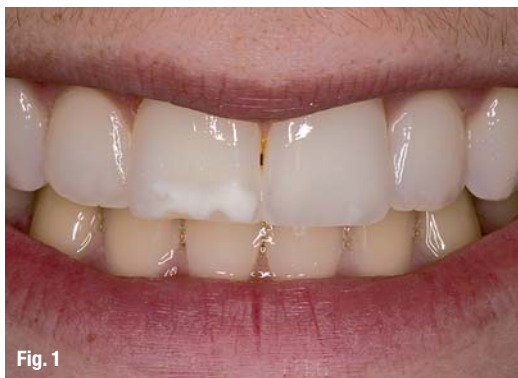
Smile upgrade— Highly aesthetic composite restorations in the anterior region

Author_ Dr Ronald D. Jackson, USA

Figs. 1 & 2_ Female patient with a prominent white spot on the right central incisor: The influence of the white spot on full face appearance is clearly visible.



Figs. 3 & 4_ This 'appearance lesion' was treated with a conservative IPS Empress Direct restoration, showing that a small treatment can have a significant effect on the overall image. Note that the patient underwent tooth bleaching prior to the placement of the restoration.

_The emphasis on appearance is pervasive in today's media-driven culture. It is particularly keen in adolescents as a result of constant exposure to images of beautiful young celebrities (real or media-created) in magazines, television,

pop music and everywhere on the Web. Because the smile is such a significant factor in facial appearance, the impact of this culture shift on dentistry has been enormous. In particular, young teenagers are seeking out aesthetically oriented dentists and requesting correction of mild to moderate imperfections in teeth that previous generations tolerated because dentistry lacked a simple, predictable aesthetic solution (Figs. 1–4).

_History and diagnosis

A sixteen-year-old female patient presented with the chief complaint of being dissatisfied with the previous dental treatment of her maxillary central incisors. Her dental history revealed that she had large white spot lesions in the incisal one third of each of these teeth, which she said appeared following orthodontic treatment. She had seen a dentist several months earlier, who placed composite resin restorations in both centrals, but she was dissatisfied with the result (Fig. 5). The clinical examination showed these



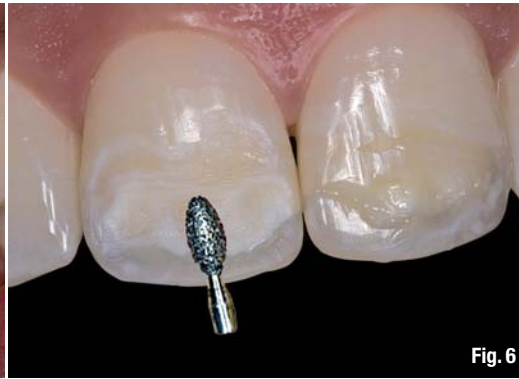
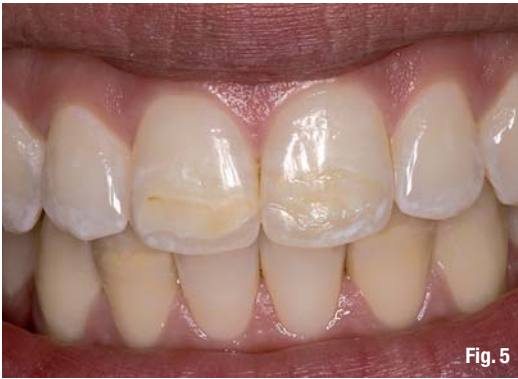
Fig. 5 Clearly visible white spot lesions.

Fig. 6 An oval diamond was used to create a saucer-shaped preparation of approximately 0.8 mm central depth.

quite visible restorations to be lacking in natural appearance and to have marginal discolouration. Although the shade was close to being correct, the lack of a lifelike appearance was deemed to be the result of using a single opacity of composite resin. The discolouration was likely due to inadequate enamel adhesion at the margins.

Clinical technique

It is important to record the shade quickly at the beginning of treatment to avoid the effects of dehydration. Using the middle third of the lateral incisors as a reference, the shade was determined to be A1. Also observed were mild, dispersed white areas scattered irregularly in all the upper incisors.

The existing composite resin on the right central incisor was removed using an oval diamond

(Fig. 6). No anaesthetic was used. The preparation using this diamond is saucer-shaped with a centre depth of approximately 0.8 mm and tapering to a shallow depth at the margins. The preparation is feathered and scalloped another 1.0 mm beyond the outline of the white lesion (Fig. 7).

The preparation, including enamel beyond the margins, was etched with 37 per cent phosphoric acid for 20 seconds, then washed and dried. Since no dentine was exposed, Heliobond, an enamel-bonding resin without hydrophilic monomers or solvent, was placed and light-cured.

A new, naturally shaded composite resin system (IPS Empress Direct) was selected because of its accurate shades and consistent opacities. As the combination of the dentine and enamel

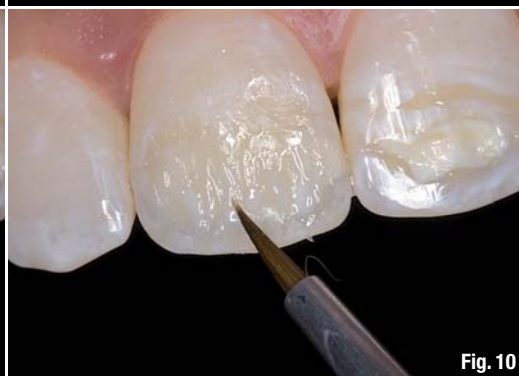
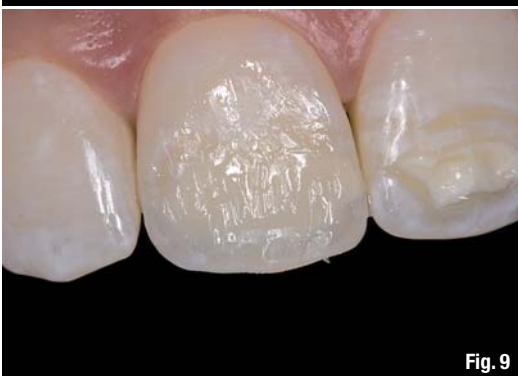
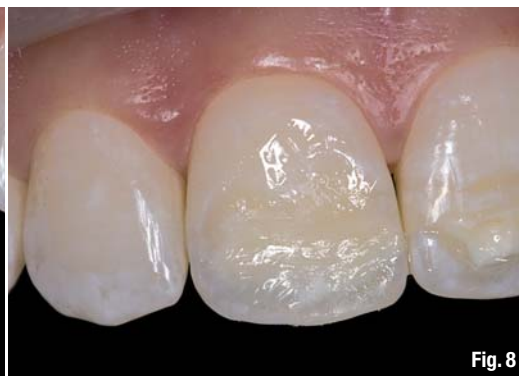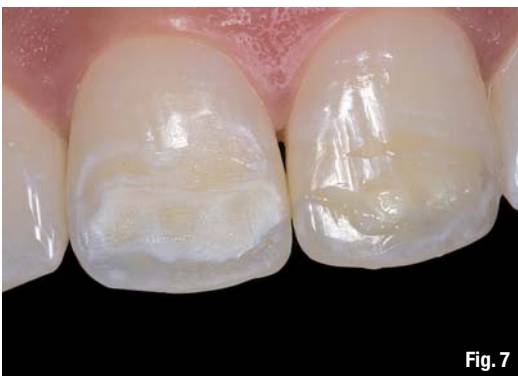Fig. 7 The preparation was feathered and scalloped an additional 1 to 1.5 mm beyond the white spot.

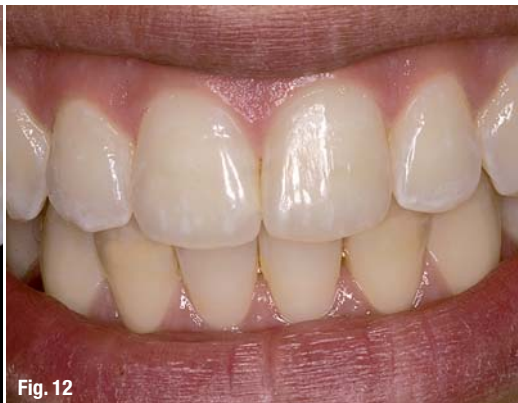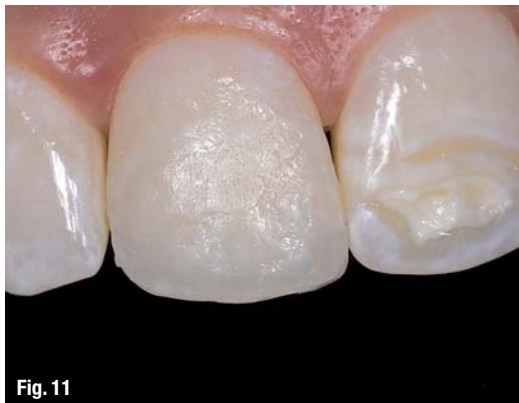Fig. 8 Opaque Dentin shade A1 blocks the visibility of the white spot.

Fig. 9 A1 Enamel was extended to just short of the prepared margin. It occupied approximately two thirds of the remaining depth of the preparation.

Fig. 10 Tetric Color white was placed with a brush.

Fig. 11 The restoration was completed to slight over-contour with a translucent composite resin, Trans 30 (clear).

Fig. 12 Post-op view of the minimally invasive, aesthetic restorations fabricated with the IPS Empress Direct composite resin system.



of the tooth yielded a shade of A1, A1 Dentin- and A1 Enamel-shade composite resins were used to restore the cavity. No recipes or combinations of a darker dentine and lighter enamel were needed.

The A1 Dentin was applied on the white spot area only and occupied about one half the depth of the preparation. Because of the opacity of the dentine composite resin, the white spot was no longer visible (Fig. 8). After curing, the A1 Enamel was applied. This increment of material occupied approximately two thirds of the remaining depth of the preparation and was extended to just short of the prepared margins. Before light curing, multiple grooves and surface irregularities were sculpted with a thin, bladed instrument (Fig. 9). A small amount of Tetric Color white was then placed with a brush and light-cured (Fig. 10).

Depth and natural-looking aesthetics were achieved by the application of translucent composite resin (Trans 30), which completes the restoration to slight over-contour. This layer extended beyond the prepared margins (Fig. 11). Finishing and polishing were accomplished using aluminium oxide discs and the Astropol System. The patient was pleased with the result (Fig. 12).

Conclusion

Today's patients want their dentistry to be more aesthetic but less invasive. Directly placed composite resin accomplishes both. Further, there is no question that the emphasis on appearance and, in particular, the smile, has raised the aesthetic standard in dentistry. Good enough is no longer good enough. Manufacturers have met this challenge by creating materials that better mimic tooth structure. The challenge for dentists is to learn the skills to use them in order to satisfy the desires of today's discerning patients.

Fortunately, this challenge is made much easier when using the naturally shaded composite resin system IPS Empress Direct. The broad range of shades (which are true to the shade guide), the three opacities (Dentin, Enamel and Translucent), each accurate in a narrow range, combined with excellent handling and ease of polish significantly shorten the learning curve. In addition, the new opalescent shade allows an easier and more accurate creation of the effect seen in bleached teeth.

Finally, the joy of creation is enhanced further for dentists when the results are evident to patients. In addition to gratitude, patients express admiration of clinicians' artistic skills.


about the author

cosmetic
dentistry



Dr Ron Jackson has published many articles on aesthetic and adhesive dentistry and has lectured extensively across the United States and abroad. He has presented at all the major US scientific conferences. Dr Jackson is a fellow in the American Academy of Cosmetic Dentistry, a fellow in the Academy of General Dentistry and is director of the Advanced Adhesive Aesthetic Dentistry and Anterior Direct Resin programmes at the Las Vegas Institute for Advanced Dental Studies. He maintains a private practice in Middleburg, VA, USA, emphasising on comprehensive restorative and cosmetic dentistry.

THE AACD IS COMING TO EUROPE!
THURSDAY, SEPTEMBER 23 – SATURDAY, SEPTEMBER 25, 2010



AACD

comes to

EUROPE

London, England

Surround yourself with progressive, world-class dental professionals, educators, and exhibiting partners at this first-of-its-kind event. Experience the camaraderie and values for which AACD is known. Gain confidence in your clinical skills through hands-on workshops and in-depth lectures. Strengthen your team dynamic while fostering your passion for cosmetic dentistry. Register with the AACD today!

This special event is brought to you by the AACD, the British Academy of Cosmetic Dentistry, the Dental University of Paris Study Group, the European Society of Cosmetic Dentistry, the German Society of Cosmetic Dentistry, and the Swedish Academy of Cosmetic Dentistry.



www.aacd.com • info@aacd.com • 608.222.8583

 AMERICAN ACADEMY
OF COSMETIC DENTISTRY