

Modern Surgical Approaches to Long-term Success

Laser Application in the Implantologic Surgery

author_Ute Gleiss, Germany

_Abstract

In implantology and accompanying dental surgery the laser has many advantages in comparison to conventional methods. Presenting three patient cases the use of lasers is demonstrated in the preimplantologic indication (improvement of soft-tissue situation) and the postimplantologic indication (implant exposure, periimplantitis therapy).

_Introduction

Since the beginning of its application in the dental therapy laser has experienced an unprecedented rise. The main cause for this rise are undoubtedly the specific benefits of dental lasers: they allow the practitioner a gentle, effective, minimally invasive work with shortened duration of treatment and at the same time meet the patients desire for a smooth, rapid treatment rather painless with little postoperative discomfort.^{7,9,10} Especially in the field of implantology the laser treatment is very useful by its high bactericidal effects and the possibility of cutting almost without bleeding.

_Preimplantologic Indications

A stable soft tissue support is essential for the longevity of implants. The main objective of preimplantologic indication is to improve the subsequent soft-tissue situation. In particular mentioned are the frenectomy, the vestibuloplasty and the mukogingival surgery.⁴

The advantages of laser application in this area are precise careful cuts, a bleeding-poor and therefore better overseen field of working, reduction of bacteria in the operated area, low post-operative swelling and less scarring by significantly less myofibroblasts.^{7,9,10}

Due to the low postoperative complaints the laser also experiences a high patient acceptance.

_Postimplantologic Indications

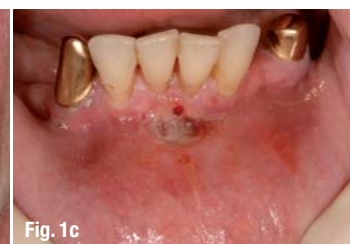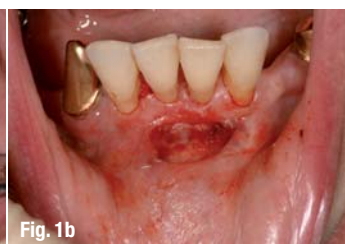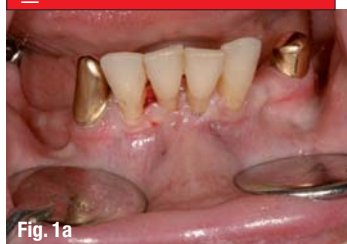Main indications of the postimplantologic use of lasers are uncovering the implant and periimplantitis therapy.⁴ The advantage of the application of lasers in implant uncovering is the immediately possible impression of the situation due to the reduced bleeding area and a faster healing without the requirement of removal of seams. However, adequate soft tissue support with adequate supply of attached gingiva is necessary and in aesthetically relevant areas the indication is limited. Especially in the domain of periimplantitis therapy laser-assisted procedures complete the conventional therapy, often they are even considered as the treatment of choice.^{1,3,4,11} The largest share of periimplantologic problems are seen (beside the biomechanical factors) in the bacterious-infectious etiology—a problem which is frequently connected to inadequate oral hygiene and/or reduced capacity for oral hygiene.

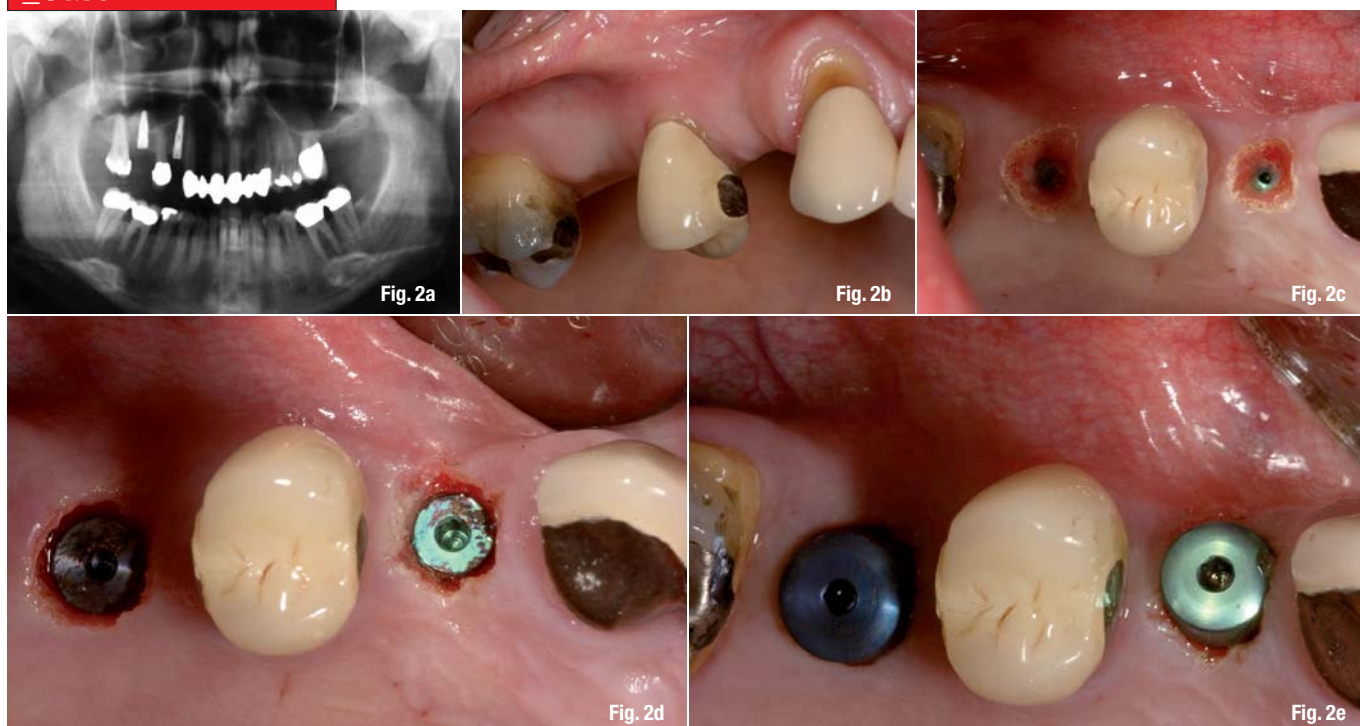
Fig. 1a Frenectomy in the lower jaw — situation before excision.

Fig. 1b Frenectomy in the lower jaw—after excision with the Nd:YAG laser.

Fig. 1c Frenectomy in the lower jaw—after 3 days.

_Case 1



_Case 2

Decontamination in the gingival pocket plays a central role in the treatment of this plaque-induced disease. In this cases the use of the laser light is of great importance.

In literature there are described two basic procedures:

1. The first is the pure decontamination of implant surface and surrounding tissue preferably performed with diode lasers (810 nm and 980 nm) or the CO₂ laser (10,600 nm) after previous cleaning with hand instruments,
2. The second is an ablative procedure with decontamination (concerning granulation, concretions, infected bone and tissue), preferably performed with the Er:YAG laser (2,940 nm) or the Er,Cr:YSGG laser (2,780 nm).^{1,2,3,5,6}

While there already exist excellent long-term results for the pure decontamination (reducing the relapse rate from 30% to 11%^{1,2,3}, the advantage of the ablative procedure is to be seen in the cleaning of the implant surface, removal of the biofilm and additional cleaning of the surrounding bone.^{1,6,11} Depending on the progression of periimplantitis different accompanying measures such as augmentation and membrane application can follow.⁶ The extent of the disease determines the progress and the therapeutic approach. The purpose is to stabilize the periimplantologic structures and avoid the loss of the implant and the bone defects often associated. Due to the increasing number of submitted implants, the development of the age structure of patients and thus possibly associated loss of manual skills, a progression of periimplantitis

can be foreseen. The use of lasers represents a significant expansion of therapeutic range and opens new possibilities for preserving the implant. It also offers innovative enhancements in the treatment spectrum in form of possible implant bed preparations carried out only with the laser.

_Conclusion

Evidence-based clinical trials show that application of lasers has many advantages compared to conventional methods especially in the domain of implantology and accompanying dental surgery. It is a highly effective, precise and gentle treatment instrument and the only instrument of a high patient acceptance. The dynamism in research and development and the change of age structure of patients will let expect large patient collectives. The application of lasers represents a significant expansion of therapeutic range and offers promising visions for the future.

_Case Presentations

Case 1: Frenectomy in the lower jaw

A 54-year-old female patient presented with problems with her prosthesis in the lower jaw. Before placing implants in the posterior region a frenectomy regio 31 had to be performed. Using local anesthesia a Nd:YAG laser (Fotona/Fidelis Plus) with the setting: VSP (pulse duration about 100 microseconds), 2 W, 20 Hz, 300 micron fiber was applied. After excision there could be found

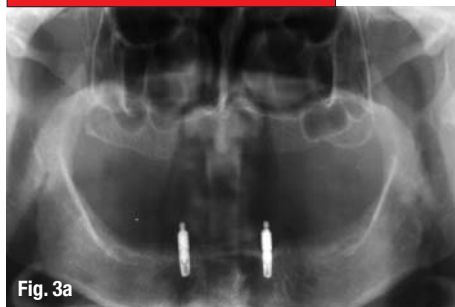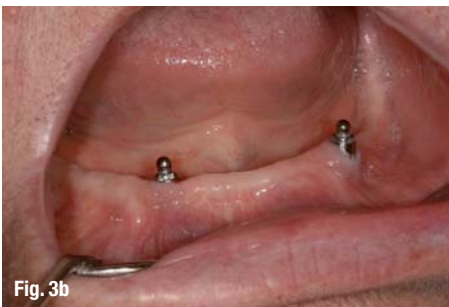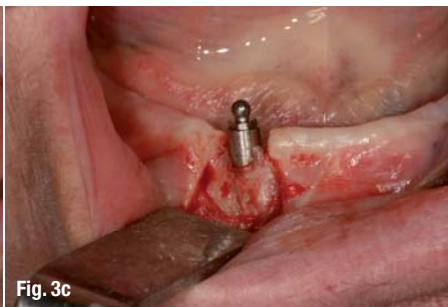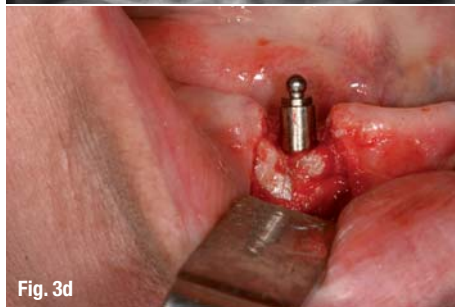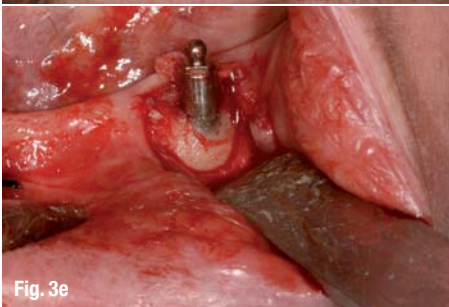
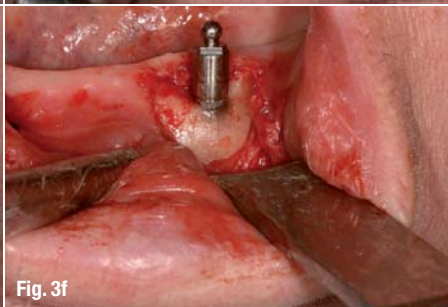
Fig. 2a Implant exposure—radiography.

Fig. 2b Implant exposure—situation before excision.

Fig. 2c Implant exposure—uncovering screws using an Er:YAG laser.

Fig. 2d Implant exposure—screws exposed.

Fig. 2e Implant exposure—healing abutments placed.

_Case 3**Fig. 3a****Fig. 3b****Fig. 3c****Fig. 3d****Fig. 3e****Fig. 3f****Fig. 3a** Periimplantitis therapy—radiography.**Fig. 3b** Periimplantitis therapy—situation before excision 43, 33.**Fig. 3c** Periimplantitis therapy—showing the granulation region 43.**Fig. 3d** Periimplantitis therapy—after removal of granulation using an Er:YAG laser region 43.**Fig. 3e** Periimplantitis therapy—showing the granulation region 33.**Fig. 3f** Periimplantitis therapy—after removal of granulation using an Er:YAG laser region 33.

neither post operative swelling nor complaints. The control after three days showed a significant improvement in the region of the gingiva region 31.

Case 2: Implant exposure

A 51-year-old female patient wanted a quick, pain-free uncovering of the implants placed region 14 and 16 after sinus elevation. Given sufficient attached gingiva the implant exposure was performed with an Er:YAG laser (Fotona/Fidelis Plus) setting: LP (pulse duration approximately 500 microseconds), 200 mJ, 20 Hz using local anesthesia. While uncovering the implants no bleeding could be noticed. An immediate impression of the situation after exposure of the implants was carried out. Neither swelling nor complaints could be noticed subsequently.

Case 3: Periimplantitis therapy

A 71-year-old female patient in good health presented with recurring pain in the region of the implants inserted alio loco region 43 and 33. The radiography showed a generalized horizontal bone resorption with vertical drops region 43 and 33. After preparation of a mucogingival flap the granulation region 43 and 33 was removed using an Er:YAG laser (Fotona/Fidelis Plus) with the setting: SP (pulse duration approximately 275 microseconds), 15 mJ, 15 Hz. Local anaesthesia was used, an augmentation was not necessary.

References

- [1] Bach, G.: Laserzahnheilkunde, Spitta Balingen 2007, pp 141–191.
- [2] Bach, G.: Periimplantitis-Therapie – Laserlichtverfahren: konventionell versus ablativ, Laserzahnheilkunde Handbuch: 55–58 (2007).

- [3] Bach, G.: Integration der Diodenlaser-Oberflächenkontamination in die Therapie der Periimplantitis, Laser-Journal 4/08: 6–13 (2008).

- [4] Deppe, H., Horch, H.: Laseranwendungen in der chirurgischen Zahn-, Mund- und Kieferheilkunde, Laser-Zahnheilkunde 4/07: 219–222 (2007).

- [5] Deppe, H., Horch, H.: Laseranwendungen in der Oralchirurgie und Implantologie, Laser-Zahnheilkunde 3/4/06: 183–188 (2006).

- [6] Grümer St.: Implantologie, in: Der Fidelis Plus Laser von Fotona, Franz-Medien GmbH 2004, p. 49–56.

- [7] Gutknecht, N.: Lasertherapie in der zahnärztlichen Praxis, Quintessenz, 1999, p. 156–182.

- [8] Gutknecht, N.: Laser in der Praxis: Indikationen und Grenzen, in: Proceedings of the 1st International Workshop of Evidence Based Dentistry and Lasers in Dentistry, Quintessence, 2007, p. 205–210.

- [9] Moritz, A.: Orale Lasertherapie, Quintessenz 2006, pp 494–498.

- [10] Nammour, S., Romanos, GE: Lasers in Oral Surgery and Implant Dentistry, in: Proceedings of the 1st International Workshop of Evidence Based Dentistry and Lasers in Dentistry, Quintessence, 2007, p. 129–147.

- [11] Black, F., Ferrari, D., Popovski, C., Becker, J.: Entfernung bakterieller Plaque-Biofilme von strukturierten Titanimplantaten unter Verwendung von Laserwellenlängen im Bereich von 3 µm, Laser-Zahnheilkunde 4/07: 231–238 (2007).

_contact

laser

Dr med dent Ute Gleiss

Korbmacherstr.21

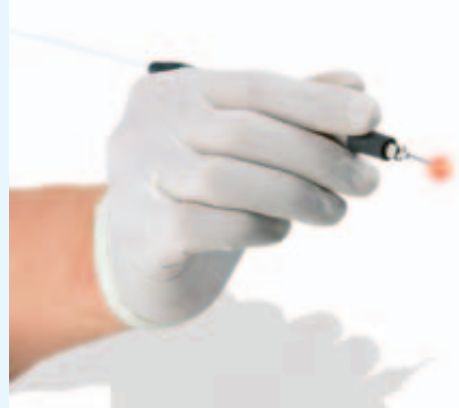46483 Wesel, Germany

Phone: + 49-2 81/2 33 23

E-mail: info@praxis-gleiss.de

Small but amazing.

**The hygienic solution:
Re-sterilisable fibres.**



100 KaVo

The KaVo GENTLEray 980.
The most gentle of all diode LASERs.

- Pain-reduced soft tissue surgery, without use of a scalpel
- Effective decontamination in root canals and periodontal pockets
- Significantly increased, postoperative patient comfort
- Safety and security for those "at risk" patients

www.100-years-kavo.com



Simple. Logic. GENTLEray

KaVo. Over 100 years of dental experience and innovation.



KaVo. Dental Excellence.