

Apical microsurgery— Part III: Access and crypt management

Author_ Dr John J. Stropko, USA

In Parts I and II of this series, we discussed the preparation of the patient, the incision, and atraumatic flap elevation. These are the first three steps necessary to perform predictable apical microsurgery. As was mentioned, it is of utmost importance that each step is completed before proceeding to the next step. If a step is omitted or not completed, the next step will be difficult, if not impossible, to complete properly. The operation will develop into a stressful experience for the patient, the staff, and the doctor, with a less desirable or predictable end result. If all of the steps are completed as outlined, all procedures can be performed without stress and a favourable post-operative result is predictable. I have completed hundreds of apical microsurgical operations and the desirable results were mainly the same with just a few exceptions. The technique is very gentle and predictable—if all of the steps are followed without compromise!

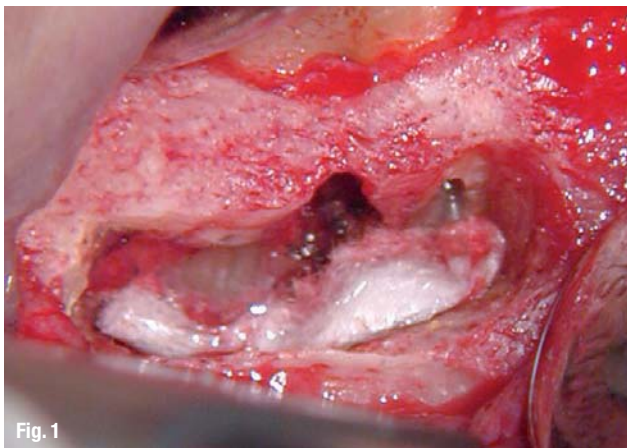


Fig. 1

Fig. 1 _An adequate amount of crestal bone should remain between the osseous crest and the coronal extent of the crypt.

_After the properly designed flap has been atraumatically reflected and retracted, the access preparation is ready. Some important considerations are:

- 1) How much bone exists on the buccal aspect of the root being surgerised? If there is total dehiscence, guided tissue regeneration has to be considered. Ideally, there should be at least 3 to 4 mm of healthy, intact crestal buccal bone remaining after the access preparation has been completed (Fig. 1).

- 2) How much of the apex can be bevelled, or resected? Usually, there is an adequate amount of root length to work with. The shorter the root, the more conservative the operator will have to be when beveling, and the closer the bevel should be to 0°, so less removal of the root end is possible. If an exceptionally long post is present, that is closer to the apical terminus than desired, not as much of the root end can be resected. Or, if the periodontal bone level is less than desired, a more conservative amount of apical root structure should be removed to preserve as much of the crown/root ratio as possible.

Fortunately, the Operating Microscope (OM), and/or the Endoscope, allows the operator the luxury of being ultra-conservative when necessary.

The access to the root end is achieved most effectively with a high-speed handpiece that has no air exiting the working end (Fig. 2a). The usual air-driven handpiece does have air at the working end and using it may result in an air embolism. It is important to use as much water coolant as vision will permit to maintain the moisture in the tissues. Using a fine stream of water from the Stropko Irrigator fitted with a 27-gauge needle, the scope



Fig. 2

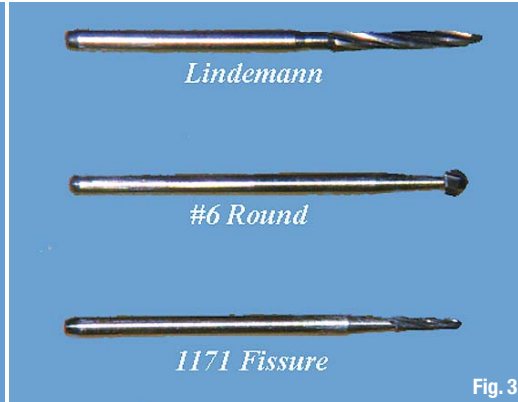


Fig. 3

Fig. 2a The surgical handpiece, such as Impact Air, should be used to prevent the possibility of an air embolism.

Fig. 2b Only three surgical burs are normally necessary for the access and REB.

assistant can keep the area moist and evacuate excess fluids at the same time. The initial access and root end apisection (RER) can be accomplished with just three surgical-length burs: the Lindemann bone bur, a #6 round bur, and an 1,171 fissure bur (Fig. 2b).

There are two different ways to begin the access:

- 1) Estimate the amount of the apex to be resected and with a Lindemann bone-cutting bur, remove the apex and prepare the access opening in one step. If there is any portion of the apex remaining in the crypt, it is curetted out and the access is more or less complete.
- 2) A more accurate procedure is to estimate the location of the apex. Then, using a #6 surgical length, round bur, slowly and gently remove the bone overlying the buccal surface of the root. Once the buccal surface of the apex has been uncovered, bone is removed until the coronal limit of the crypt is established and the general outline of the apex is readily observed and can be resected at this time. Often, especially with larger peri-apical involvement, the lesion can be curetted and the entire apex exposed. If the lesion is more palatal, or lingual, the root apex may prevent the necessary access for curettage and will have to be partially bevelled, or resected as part of the access process. A thorough curettage is important because it is an important first stage of achieving haemostasis from within the crypt. In general, if all of the granulation tissue is removed, the amount of haemorrhage will be greatly reduced, the management of the crypt will be easier to accomplish, and good visibility will be restored. This technique takes more time but results in improved visibility and the ability to be more precise with the initial RER. The finished bevel will be discussed in more detail later in the article.

In general, a biopsy should be performed on all tissue removed from the body. Granted, we are

usually quite confident of the pathological diagnosis of the LEO, but my feeling is that even if the odds are 1 in 100,000 that we are correct, no chances should be taken and a biopsy should be taken on a routine basis.

The final dimension of the access opening varies and is dependent on several factors:

- 1) The size and position of the lesion is important. If the lesion is larger, the access will, of necessity, be larger in order to perform a complete curettage.
- 2) The position of the apex determines the size of the access. The more lingual the apex, the more overlying bone has to be removed and the larger the access has to be for good visibility.
- 3) The access has to be sufficiently large to allow the instruments room to prepare the apical canal system without inhibiting their freedom of movement. The larger the instruments used, the larger the access must be.
- 4) The thickness of overlying bone is also important. If the buccal plate is thick, a wider access is necessary to eliminate a 'tunnel effect', so vision is not compromised.
- 5) The experience and ability of the operator, and equipment available is a great determinant of the size the access will need to be. I use both an Endoscope and the OM when performing apical microsurgery. In some cases, the Endoscope (JedMed) permits a better view of the surgical site owing to increased lighting and magnification. It also increases the ability to view previously difficult, and sometimes impossible, areas to be seen with the OM. The extent of a defect or existing anatomical variations that are lingual to the involved root end are typical examples of the value of also having an Endoscope during microsurgical procedures.

The management of the crypt is one of the most important steps and the operator should take as

Fig. 3 An appropriately sized piece of Telfa Pad can be lightly streaked with ferric sulfate for crypt management.

Fig. 4 Only a small amount of ferric sulfate is used on the Micro Applicator.

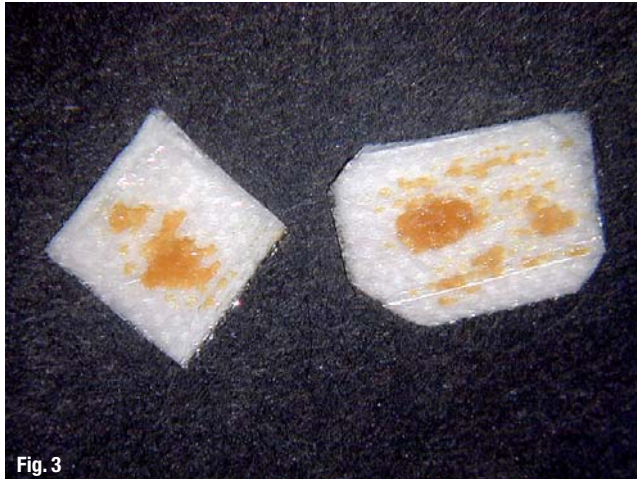

Fig. 3

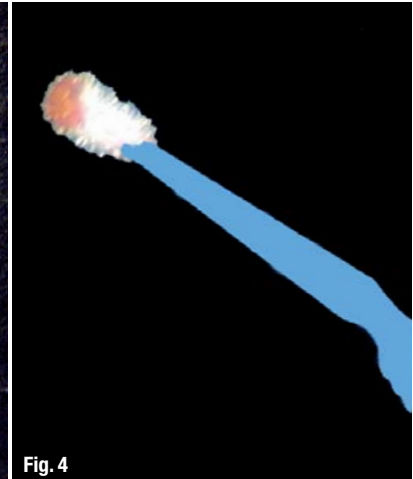


Fig. 4

much time as necessary to achieve the desired result. The clean and well-managed crypt is essential for good visibility and proper use of the retrofill materials. Ferric sulfate (Monsel's Solution, Cutrol), calcium sulphate (Capset, SurgiPlaster), Telfa Pads, and epinephrine-soaked pellets (Epidry, Pascal) are the most commonly used and effective agents for this purpose. I don't use CollaCote because the majority of the other materials mentioned are easier to use and provide a more efficient haemostasis.

After all granulation tissue and other debris have been thoroughly removed from the crypt, haemostasis is often achieved as a result of proper haemostasis-staging injections, discussed in Part II of this series. If that is the case, only an appropriately sized piece of Telfa Pad, lining the floor of the crypt is necessary to enhance lighting. However, this is not always the case and even slight bleeding must be addressed in order to preserve optimum visibility.

Fig. 5 When ferric sulfate is used for crypt management, a dark brown coagulum will result.

Fig. 6 The Telfa Pad should be replaced as necessary to maintain good light reflection in the crypt.

If the crypt exhibits slight haemorrhaging, the surface of a piece of Telfa Pad, trimmed to the correct size to fit, can be lightly streaked with Monsel's Solution and pressed into the floor of the

crypt for a short period of time until the haemorrhaging is completely controlled (Fig. 3).

If there is a moderate haemorrhaging, the Monsel's Solution is carefully applied with a Micro Applicator (Ultradent) directly to the problem area in the floor of the crypt. Keep in mind that only a small amount is necessary (Fig. 4). When ferric sulfate is used to achieve haemostasis, a thick brownish-black coagulum will usually result (Fig. 5). The resultant coagulum can be easily removed from the crypt with a clean Micro Applicator, gently flushed with water using a larger tip on a Stropko Irrigator as the scope assistant is evacuating any debris during irrigation of the crypt. The process is repeated until the bleeding is controlled. As soon as there is complete control of all bleeding in the crypt, the Telfa Pad should be removed and replaced with a fresh piece so there is as much 'white surface' as possible to facilitate light reflection and enhance vision.

On condition that the coagulum resulting from the use of Monsel's Solution has been cleaned out of the crypt after the completion of the surgery, its use has not been shown to affect the healing process.¹ CAUTION: All forms of ferric sulfate must

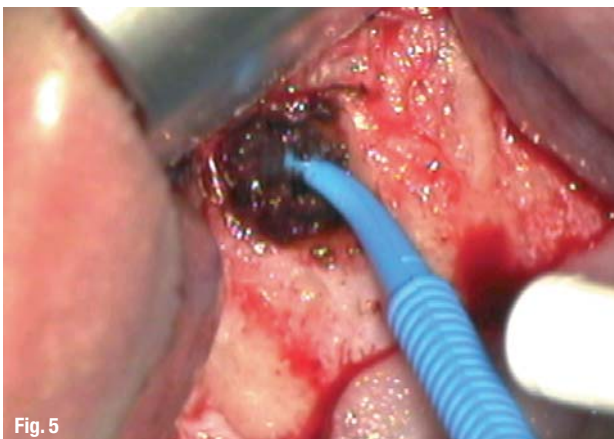


Fig. 5

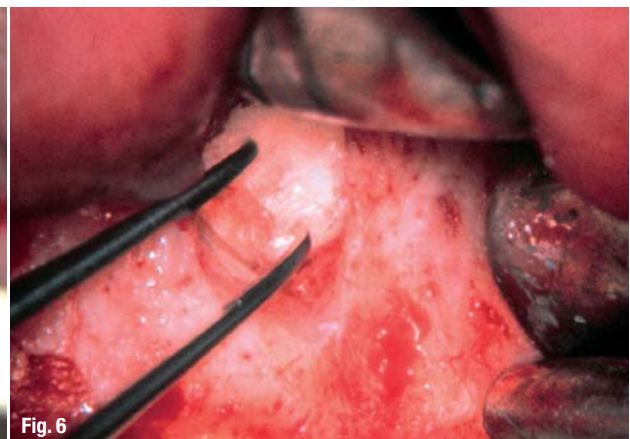


Fig. 6

be kept well within the confines of the crypt. It has an extremely low pH and will instantly chemically cauterise anything it touches! The buccal plate of bone, the periosteum, soft tissue, and the Snyderian membrane should always be avoided! It is important to keep in mind: If a little bit is good, a lot is not better! Use only small amounts on the end of an applicator because a small amount goes a long way (Fig. 4). NOTE: There are two popular forms of ferric sulfate: Monsel's Solution has a concentration of 72 % and Cutrol has one of 53 %. I like Monsel's Solution because it is very effective, readily available and less costly to use.

On a few occasions, severe haemorrhaging occurs. This can be a result of inflammation, a severed interdental artery or a compromised clotting mechanism. At any rate, when the blood flows faster than the evacuator can remove it, there is good reason for a little excitement and fast action! Immediately, pressure must be applied over the crypt with a finger. This will stop the haemorrhaging long enough to prepare the next few steps calmly. First, in a low and controlled voice, instruct the scope assistant to insert a bigger tip into the evacuator and hold it close to the crypt. If after removing your finger the haemorrhaging has not subsided, quickly replace your finger over the crypt as before. It is a good idea to take a radiograph and clinically re-evaluate the surgical area at this time to ensure no unforeseen anatomical structures (mandibular canal, palatine artery, etc.) have been infringed upon. Now it is safe to have your surgical assistant make a 'cotton plug' with a piece of sterile cotton roll large enough to completely fill the crypt, lightly streaking the tissue surface with Monsel's Solution and insert into the crypt, holding it firmly in place with your finger for a minute or so. After a few minutes, the cotton plug can be safely removed and

you can proceed without undue concern. A gentle irrigation with the Stropko Irrigator will remove most of the dark-coloured coagulum.

The above technique has worked all three times I found myself in this situation. In two of the cases, an interdental artery was the cause and the other was highly inflamed granulation tissue remaining in the crypt.

If haemorrhaging occurs on the surface of the exposed buccal plate, a Touch 'n Heat (SybronEndo) can be used. The scope assistant can evacuate the bleeder with a small surgical tip, so its exact source can be determined, and the Touch 'n Heat can be used to effectively cauterise it. After the haemorrhaging has been completely controlled and the crypt relatively cleansed of the coagulum, a fresh piece of Telfa Pad should be placed over the internal surface of the crypt (Fig. 6). Keep in mind when using the OM that light and dryness are the most important factors for good visibility. NOTE: Never proceed to the next step until total crypt management has been accomplished.

Once the crypt management is completed, the doctor can proceed to refinement of the bevel and preparing the retropreps with confidence and good visibility. At the end of this step, all haemorrhaging should be controlled, the grossly resected apical end of the root should be easily seen and the floor of the crypt should be covered with a clean, white piece of Telfa Pad; an apical microsurgeon's dream!_

_Reference

1. Lemon R, Steel P, Jeansonne B. Ferric Sulfate Hemostasis: Effect on Osseous Wound Healing: Left in situ for Maximum Exposure. *J Endod* 1993: 170–173.

_about the author

roots

Dr John J. Stropko received his DDS from Indiana University in 1964 and for 24 years practised restorative dentistry. In 1989, he received a certificate for endodontics from Boston University. He recently retired from the private practice of endodontics in Scottsdale in Arizona. Dr Stropko is an internationally recognised authority on micro-endodontics. He has been a visiting clinical instructor at the Pacific Endodontic Research Foundation (PERF), an Adjunct Assistant Professor at Boston University and an Assistant Professor of graduate Clinical Endodontics at Loma Linda University. His research on in vivo root canal morphology has been published in the *Journal of Endodontics*. He is the inventor of the Stropko Irrigator, has published in several journals and textbooks, and is an internationally known speaker. Dr Stropko has performed numerous live micro-endodontic and microsurgical demonstrations. He is the co-founder of *Clinical Endodontic Seminars*. He can be contacted at topendo@aol.com.

